

UC Irvine

UC Irvine Previously Published Works

Title

Myeloid sarcoma manifesting as generalized lymphadenopathy in a patient with myelofibrosis.

Permalink

<https://escholarship.org/uc/item/8wq6847v>

Journal

Clinical Case Reports, 7(11)

ISSN

2050-0904

Authors

Trennepohl, Christopher

Sorah, Jonathan

Eulitt, Patrick

et al.

Publication Date

2019-11-01

DOI

10.1002/ccr3.2473



Copyright Information

This work is made available under the terms of a Creative Commons Attribution License, available at <https://creativecommons.org/licenses/by/4.0/>

Peer reviewed

CLINICAL IMAGE

Myeloid sarcoma manifesting as generalized lymphadenopathy in a patient with myelofibrosis

Christopher Trennepohl¹ | Jonathan Sorah² | Patrick Eulitt³ | Jonathan Galeotti⁴ |
Joshua F. Zeidner³ | Nathan D. Montgomery⁴  | Catherine C. Coombs³ 

¹School of Medicine, University of North Carolina, Chapel Hill, NC, USA

²Department of Medicine, University of North Carolina, Chapel Hill, NC, USA

³Division of Hematology/Oncology, Department of Medicine, University of North Carolina, Chapel Hill, NC, USA

⁴Department of Pathology, University of North Carolina, Chapel Hill, NC, USA

Correspondence

Catherine C. Coombs, Leukemia, Lymphoma and Myeloma Program, Division of Hematology/Oncology, The University of North Carolina Cancer Center, 170 Manning Drive, CB #7305, Chapel Hill, NC 27599, USA.
Email: catherine_coombs@med.unc.edu

Abstract

Immunophenotyping is critical to the diagnosis of MS, as it can be difficult to differentiate from other diagnoses including lymphoma using conventional light microscopy.

KEYWORDS

hematology, myelofibrosis, myeloid sarcoma, oncology, pathology

A 47-year-old male with no past history developed abdominal distension and fatigue, and was found to have anemia (hemoglobin 7.4 g/dL), thrombocytopenia (platelets $74 \times 10^9/L$), and leukocytosis (WBC $33 \times 10^9/L$) with 8% circulating blasts. Imaging showed marked hepatosplenomegaly and diffuse bulky lymphadenopathy (Figure 1).

Bone marrow biopsy and clinical presentation were consistent with primary myelofibrosis (Figure 2). As lymphadenopathy is rare in PMF, he underwent axillary lymph node biopsy which demonstrated effacement by immature-appearing cells (Figure 3). Flow cytometry showed an immature cell population (CD45 dim) that was negative for CD34, CD56, CD117, and MPO; strongly positive for CD4; and variably

positive for CD10, CD33, HLA-DR, CD68, CD123, and E-cadherin, consistent with myeloid sarcoma (MS). The patient did not respond to induction chemotherapy with daunorubicin, cytarabine, and cladribine, but lymphadenopathy resolved after three cycles of decitabine and ruxolitinib. He progressed after six cycles, and was transitioned to azacytidine and venetoclax. He proceeded to allogeneic stem cell transplant, but died from veno-occlusive disease on day +11.

While MS commonly affects lymph nodes,¹ it rarely presents with diffuse involvement as in this case. Immunophenotyping is critical in diagnosing MS, as it can be difficult to differentiate from other diagnoses, including lymphoma, using light microscopy.²

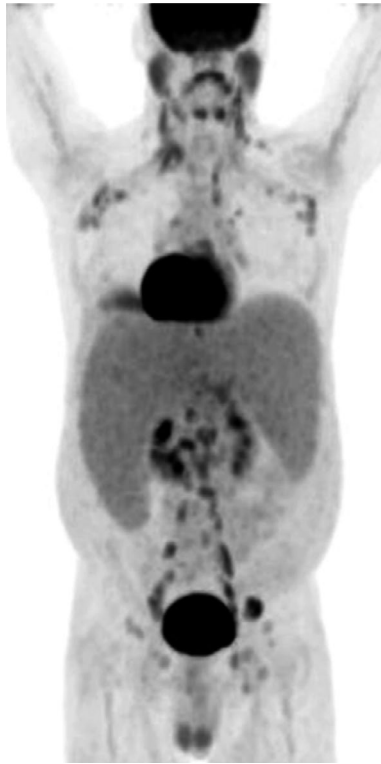

FIGURE 1 A PET/CT scan showing spleen length of 31 cm, liver length of 26 cm, and diffuse bulky lymphadenopathy

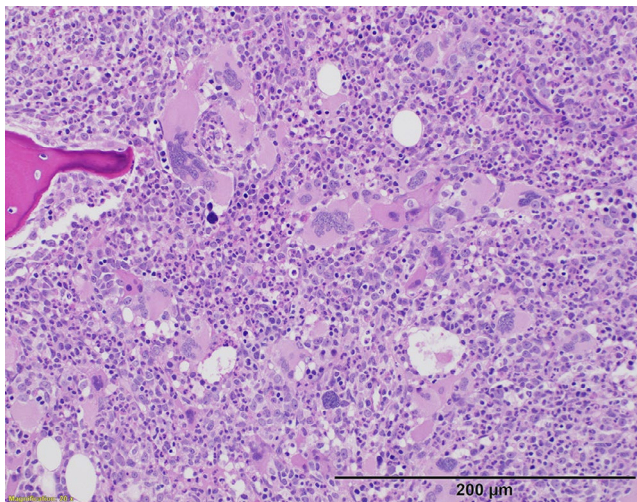


FIGURE 2 Bone marrow biopsy with hematoxylin & eosin staining, 10× objective magnification. Bone marrow is hypercellular (90%) with atypical megakaryocytes, fibrosis (MF-2), and 1% blasts. Molecular testing demonstrated mutations in JAK2(V617F), NRAS(G12D), SETBP1(D868N and D874H), SRSF2(P95L), and TET2(Q916* and R1516*). Karyotype was normal on both bone marrow biopsy and lymph node biopsy

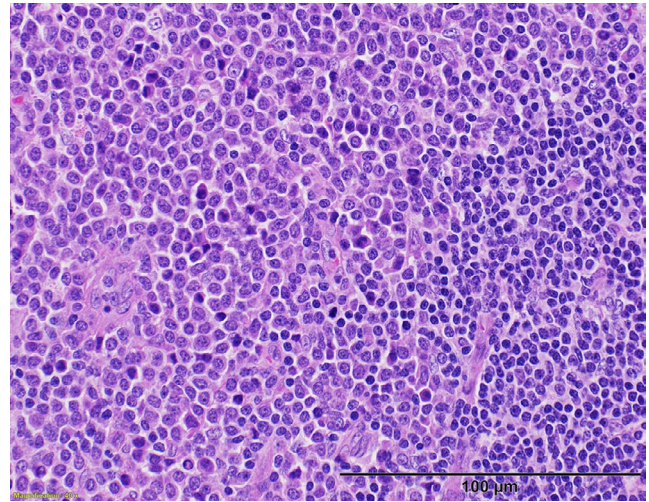


FIGURE 3 Lymph node biopsy with hematoxylin and eosin staining, 20× objective magnification. This shows an aggregate of small lymphocytes in the lower right representing a residual lymph node follicle; the remainder of the lymph node is effaced by immature cells. Karyotype was normal on both bone marrow biopsy and lymph node biopsy

CONFLICT OF INTERESTS


CCC has received honoraria from Abbvie, H3 Biomedicine, and Pharmacyclics, has served as a consultant for Abbvie, has received institutional funding from Gilead, H3 Biomedicine, and Incyte, and has received travel funding from AROG and Incyte, JFZ has received honoraria from Celgene, Tolero, and Agios, has served as a consultant for Celgene and AsystBio Laboratories, and has received research funding from Merck, Takeda, and Tolero, and NDM received free sequencing from ArcherDx, and received prior research and travel funding from Ventana Biosystems, a subsidiary of Roche.

AUTHOR CONTRIBUTIONS

CT: wrote the case report and cared for the patient. JS and PE: cared for the patient and contributed to writing. JG and NDM: reviewed the pathologic specimens and contributed to writing. JFZ: cared for the patient and contributed to revisions. CCC: cared for the patient and contributed to writing and revisions.

ORCID

Nathan D. Montgomery  <https://orcid.org/0000-0003-1765-6623>

Catherine C. Coombs  <https://orcid.org/0000-0003-4656-7304>

REFERENCES

1. Pileri SA, Ascani S, Cox MC, et al. Myeloid sarcoma: clinico-pathologic, phenotypic and cytogenetic analysis of 92 adult patients. *Leukemia*. 2007;21(2):340-350.
2. Paydas S, Zorludemir S, Ergin M. Granulocytic sarcoma: 32 cases and review of the literature. *Leuk Lymphoma*. 2006;47(12):2527-2541.

How to cite this article: Trennepohl C, Sorah J, Eulitt P, et al. Myeloid sarcoma manifesting as generalized lymphadenopathy in a patient with myelofibrosis. *Clin Case Rep*. 2019;7:2274–2276. <https://doi.org/10.1002/ccr3.2473>