

UC Davis
Emergency Medicine

Title

Traumatic Findings on C-spine MRI Following Negative CT Scans in Older Patients following a Fall

Permalink

<https://escholarship.org/uc/item/8zf3h9xb>

Authors

Crushing, Corinne

Tyler, Katren

Homes, James

Publication Date

2020

Data Availability

The data associated with this publication are not available for this reason: N/A



INTRODUCTION

Computed tomography (CT) has long been the standard for evaluating head trauma after a fall. The efficiency and lower cost of performing a CT scan has made it the more practical choice for most emergent situations. However, the soft tissue detail in MRI may show injuries in the brain or spinal cord that would be missed on a CT scan¹. Early detection of brain or spinal injuries after trauma is critical and has large impacts on patient outcomes². Additionally, an unstable injury that is missed on CT but found on MRI may have legal implications.

In elderly patients, this is clinically relevant because injuries after trauma are more likely to be fractures that would be seen on CT and are less likely to be ligamentous injuries that would be identified on MRI³. MRI imaging is loud, claustrophobic, and many patients require sedation to facilitate a good scan. Sedation itself has added risks, especially in older patients. Additionally, elderly patients may already be experiencing baseline confusion that is worsened by being restrained in a bed, being in a C-collar, and being in pain. Sedation to obtain an MRI scan may worsen this delirium and add hours to the patient's ED length-of-stay, potentially without benefit. If doing an MRI does not yield any clinical benefit, MRI should not be used following a negative CT C-spine in elderly patients after trauma.

Research Topic: This case series will evaluate the incidence of positive MRI findings after negative CT C-spine in elderly patients after a ground level fall and discuss if performing an MRI is clinically necessary for these patients.

OBJECTIVES

The objective is to determine the rate of acute traumatic abnormalities on MRI after a negative cervical spine CT. We will also examine the number of patients where a positive finding on MRI changed the clinical management of the patient. We hypothesize that cervical spine MRI does not change clinical management at a statistically significant level and may not be necessary after a non-focal physical examination and negative CT after a ground level fall in patients over 65 years old.

MATERIALS AND METHODS

Chart Identification: Qualifying subjects were identified via selection for patients admitted to the UC Davis Emergency Department over 65 y/o with a history of ground level fall and subsequent MRI. Data was obtained using EMR/EPIC records. 344 charts were reviewed from patients admitted to the Emergency Department between May 2017 to May 2019 to yield a final count of 96 qualifying patients.

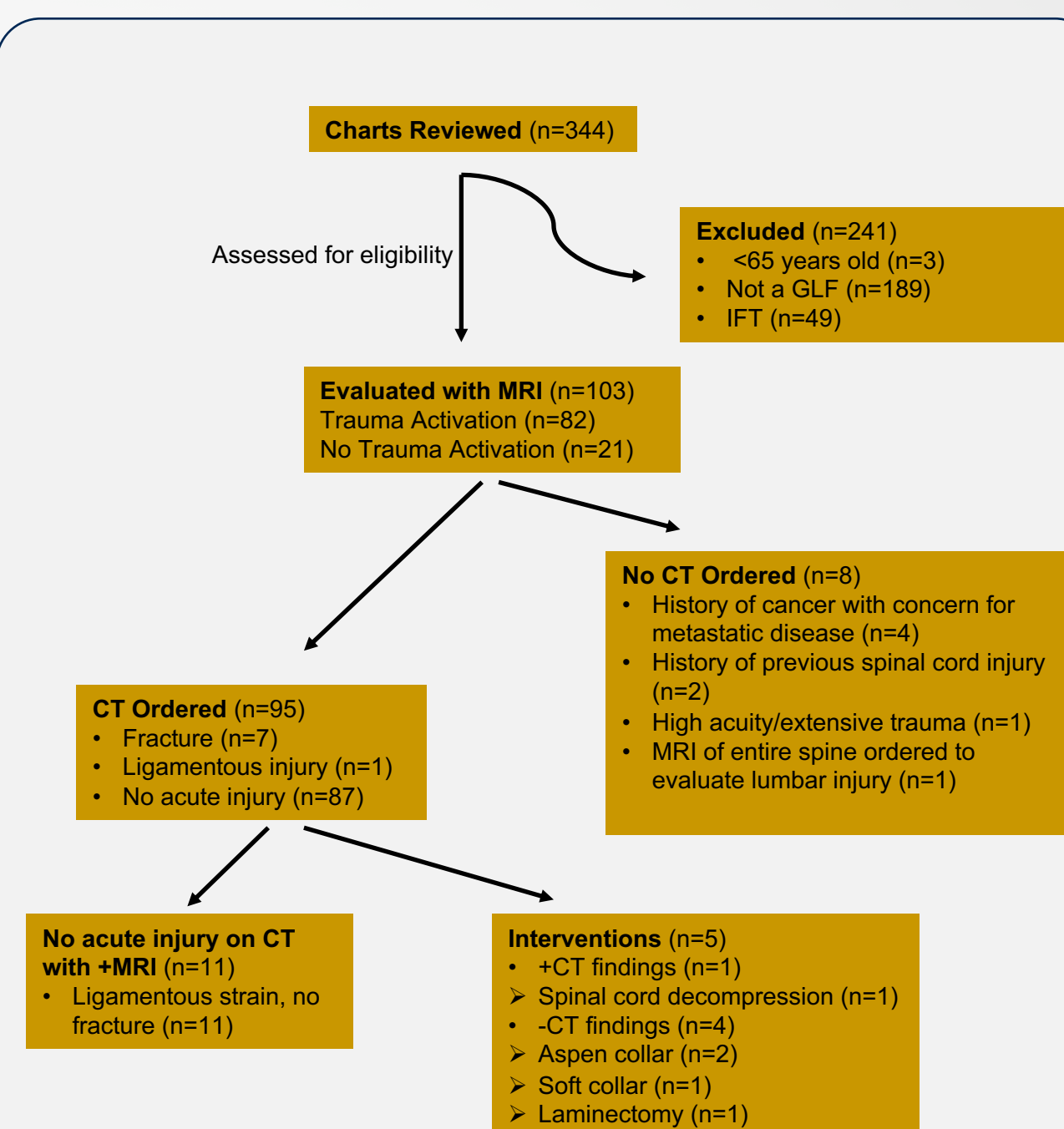
Inclusion/Exclusion Criteria: Inclusion criteria included age over 65 years with history of ground level fall and evaluation with an MRI. Ground level falls were defined as falls from standing, less than three feet or less than 5 stairs. Charts were excluded if the patient was an IFT from another hospital or a prisoner.

Chart Review: Charts were reviewed in EMR/EPIC and information was extracted by one medical student. Negative cervical spine CT scans were defined as those scans without any evidence of acute traumatic injury. Information was also obtained on clinical course, medications given, and time spent in ED. Injury Severity Scores, Charlson Comorbidity Scores, and Revised Trauma Scores were also calculated. Student researcher was trained to prevent bias in the case of missing information during chart review.

Statistical Analysis: Because this is a case series, only basic statistical analysis with simple descriptive statistics were required.

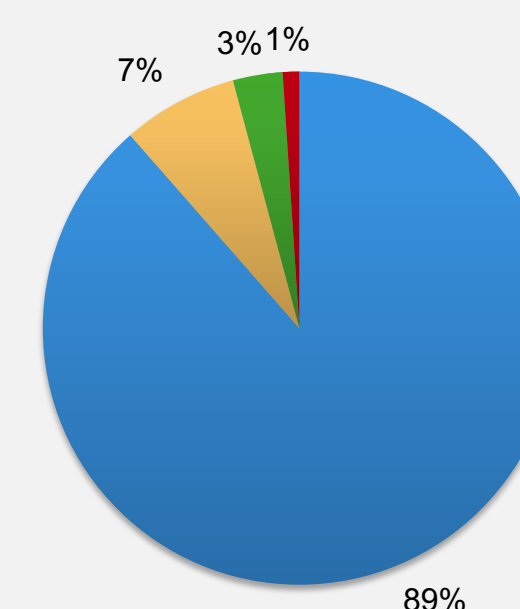
RESULTS

96 patients with a median age = 74 (IQR 69, 84) years had an MRI following a negative cervical spine CT. Median ED length of stay was 8.0 (IQR 5.4, 13.3) hours. Eleven patients (11.5%, 95% CI 5.9, 19.6%), median age = 80 (IQR 70, 85) years had acute traumatic findings on the cervical spine MRI not identified on the cervical CT scan. All 11 of these injuries were classified as ligamentous injuries and seven (64%, 95% CI 35, 89%) were on anticoagulant medication. One of the 96 patients (1.0%, 95% CI 0.0, 5.7%) underwent operative stabilization. This 67-year-old patient had developed bilateral lower extremity weakness immediately following his fall. Three patients were managed conservatively with aspen/soft collars, and seven patients had no additional treatments.



3 patients were excluded from the +MRI, -CT category due to an MRI of entire spine being ordered secondary to history of metastatic disease or previous spinal injury. 1 patient was excluded due to a QI issue that resulted in the patient being discharged before the MRI was read.

Imaging Results



- Patients with -CT and -MRI
- Patients with -CT and +MRI with no change in clinical management
- Patients with -CT and +MRI resulting in application of a collar
- Patients with -CT and +MRI requiring surgical intervention

CONCLUSIONS

In a single center study, over 10% of patients had an acute traumatic injury on cervical spine MRI following a negative CT scan. This indicates that performing an MRI after a negative CT is good clinical practice. However, surgical stabilization was only required in 1 case, and only 3 required stabilization via collar. The clinical management of the other 7 cases was not changed by the +MRI findings.

Further study is required to identify criteria to determine when MRI should be performed in this population. Additional studies could be performed in the future to grade the severity of the initial injury or mechanism with subsequent clinical management.

Of note, Note: 7/11 (64%) of patients with ligamentous injury found on MRI after a negative CT were anticoagulated. This potentially suggests that anticoagulated patients were either more likely to suffer from a ligamentous injury or had small ligamentous injuries that were more likely to be seen on MRI. Additionally, an anticoagulated state could have prompted a trauma activation, increasing the investigation of potential C-spine injuries. Both hypotheses have potential for further investigation.

REFERENCES

1. "CT Scan vs. MRI: What's the Difference?" *Medical Imaging of Fredericksburg*, Radiologic Associated of Fredericksburg, 8 June 2018, mifimaging.com/2016/03/25/ct-scan-vs-mri/.
2. Reid, D C, et al. "Etiology and Clinical Course of Missed Spine Fractures." *Current Neurology and Neuroscience Reports.*, U.S. National Library of Medicine, Sept. 1987, www.ncbi.nlm.nih.gov/pubmed/3656481?dopt=Abstract.
3. Ensrud, Kristine E. "Epidemiology of Fracture Risk With Advancing Age." *OUP Academic*, Oxford University Press, 5 July 2013, academic.oup.com/biomedgerontology/article/68/10/1236/569766.

CONTACT

Corinne Cushing
UC Davis School of Medicine
chcushing@ucdavis.edu

Dr. Katren Tyler
UC Davis Department of Emergency Medicine
krtyler@ucdavis.edu