

UCSF

UC San Francisco Previously Published Works

Title

Life-Threatening MOG Antibody-Associated Hemorrhagic ADEM With Elevated CSF IL-6.

Permalink

<https://escholarship.org/uc/item/8zj6r1w1>

Journal

Neurology: Neuroimmunology & Neuroinflammation, 11(4)

Authors

Moseley, Carson

EliceGUI, Steven

Gerwitz, Lee

et al.

Publication Date

2024-07-01

DOI

10.1212/NXI.0000000000200243

Peer reviewed

Life-Threatening MOG Antibody-Associated Hemorrhagic ADEM With Elevated CSF IL-6

Akash Virupakshaiah, MD,* Carson E. Moseley, MD, PhD,* Steven EliceGUI, BS, Lee M. Gerwitz, MD, Collin M. Spencer, BS, Elizabeth George, MBBS, Maulik Shah, MD, MHS, Bruce A.C. Cree, MD, PhD, MAS, Emmanuelle Waubant, MD, PhD, and Scott S. Zamvil, MD, PhD

Correspondence

Dr. Zamvil
zamvil@ucsf.neuroimmunol.org

Neurol Neuroimmunol Neuroinflamm 2024;11:e200243. doi:10.1212/NXI.000000000200243

Abstract

Acute disseminated encephalomyelitis (ADEM) is one characteristic manifestation of myelin oligodendrocyte glycoprotein antibody-associated disease (MOGAD). A previously healthy man presented with retro-orbital headache and urinary retention 14 days after Tdap vaccination. Brain and spine MRI suggested a CNS demyelinating process. Despite treatment with IV steroids, he deteriorated, manifesting hemiparesis and later impaired consciousness, requiring intubation. A repeat brain MRI demonstrated new bilateral supratentorial lesions associated with venous sinus thrombosis, hemorrhage, and midline shift. Anti-MOG antibody was present at a high titer. CSF IL-6 protein was >2,000 times above the upper limits of normal. He improved after plasma exchange, then began monthly treatment alone with anti-IL-6 receptor antibody, tocilizumab, and has remained stable. This case highlights how adult-onset MOGAD, like childhood ADEM, can rapidly become life-threatening. The markedly elevated CSF IL-6 observed here supports consideration for evaluating CSF cytokines more broadly in patients with acute MOGAD.

Case Presentation

A previously healthy 35-year-old man presented to an urgent care with 9 days of retro-orbital headache. Two weeks before symptom onset, he received tetanus toxoid, reduced diphtheria toxoid, and acellular pertussis (Tdap) vaccination. He was diagnosed with migraine but returned to care 3 days later with persistent headache and new-onset urinary retention, visual disturbance (blurred vision in the left eye), and vertigo. MRI with contrast demonstrated an enhancing white matter T2/FLAIR hyperintense lesion in the anterior right lateral aspect of the pons with additional subcortical white matter lesions in the posterior right frontal lobe (Figure 1). There were anterior central T2 hyperintense lesions in the thoracic cord that enhanced with gadolinium. CSF analysis demonstrated a lymphocytic predominant pleocytosis (214 cells/ μ L) and elevated protein (61 mg/dL). There were no CSF-specific oligoclonal bands. He was treated with IV methylprednisolone (IVMP) 1,000 mg daily for 3 days and started intermittent bladder catheterization. Three days after IVMP, he returned to the emergency department with lower extremity weakness and difficulty with walking and urination. Despite additional IVMP followed by oral prednisone, his symptoms persisted, and he also developed lower extremity paresthesia.

At an outpatient neurology appointment 10 days later, his examination was notable for hyperreflexic patellar stretch and extensor plantar responses. Blood was drawn for a comprehensive serologic evaluation (eTable 1), and he remained on prednisone 60 mg daily. Over the next few days, he developed worsened lower extremity weakness, altered mental status, and language disturbance. He was hospitalized because of alertness and required intubation. Brain

*These authors are co-first authors.

From the UCSF Weill Institute for Neurosciences (A.V., C.E.M., C.M.S., M.S., B.A.C., E.W., S.S.Z.), University of California, San Francisco; University of Nevada Reno School of Medicine (S.E.); Renown Health (L.M.G.), Reno, NV; Department of Radiology and Biomedical Imaging (E.G.); and Program in Immunology (S.S.Z.), University of California, San Francisco.

Go to [Neurology.org/NN](https://www.neurology.org/NN) for full disclosures. Funding information is provided at the end of the article.

The Article Processing Charge was funded by the authors.

This is an open access article distributed under the terms of the Creative Commons Attribution-NonCommercial-NoDerivatives License 4.0 (CC BY-NC-ND), which permits downloading and sharing the work provided it is properly cited. The work cannot be changed in any way or used commercially without permission from the journal.

Glossary

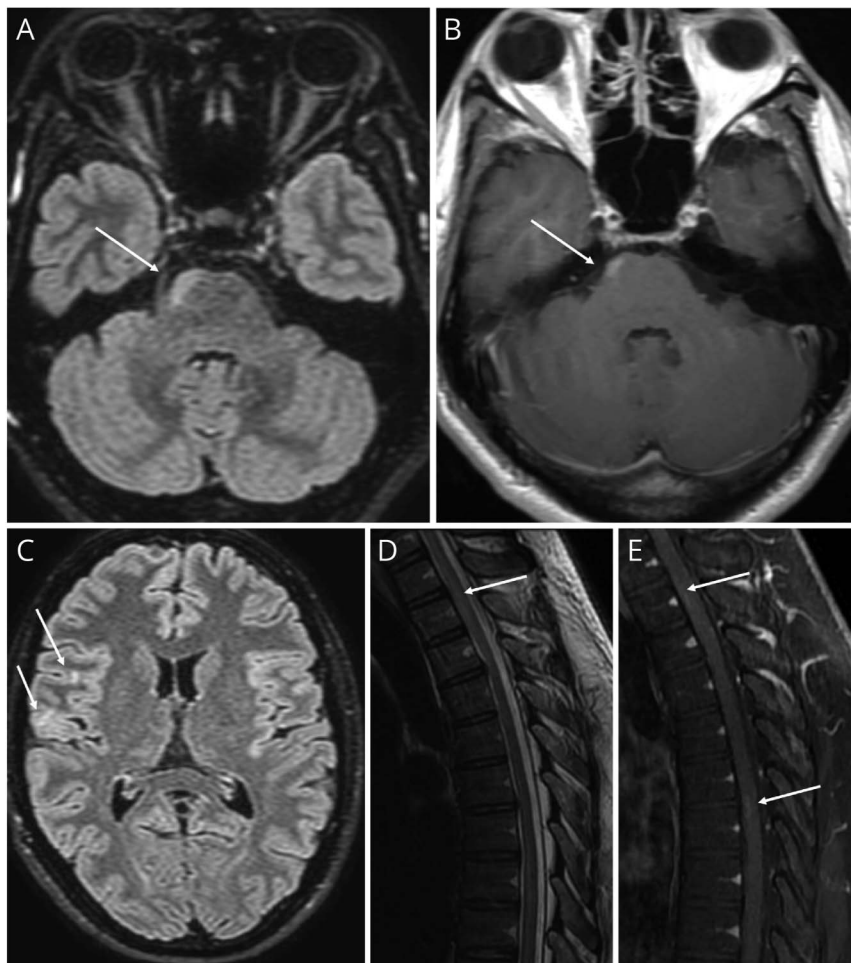
ADEM = acute disseminated encephalomyelitis; **CVST** = cerebral venous sinus thrombosis; **IVMP** = IV methylprednisolone; **MOGAD** = myelin oligodendrocyte glycoprotein antibody-associated disease; **PLEX** = plasma exchanges; **TT** = Tetanus toxoid.

MRI with contrast demonstrated new multifocal T2/FLAIR hyperintensities in the supratentorial white matter, corpus callosum, and basal ganglia with peripheral enhancement and extensive intrasubcortical blood products. Hemorrhagic T2/FLAIR hyperintensities of the bilateral thalami were noted with evidence of thrombosis of the bilateral internal cerebral veins, straight sinus, transverse sinus, and right sigmoid sinus (Figure 2). No lesions were noted on the spinal MRI at this time. CSF analysis showed RBC of 105 cells/ μ L, WBC of 87 cells/ μ L (85% polys), and 89 mg/dL protein.

He was transferred to a tertiary care center for further management. Serum MOG-IgG that had been drawn at his outpatient neurology appointment returned positive at a titer level

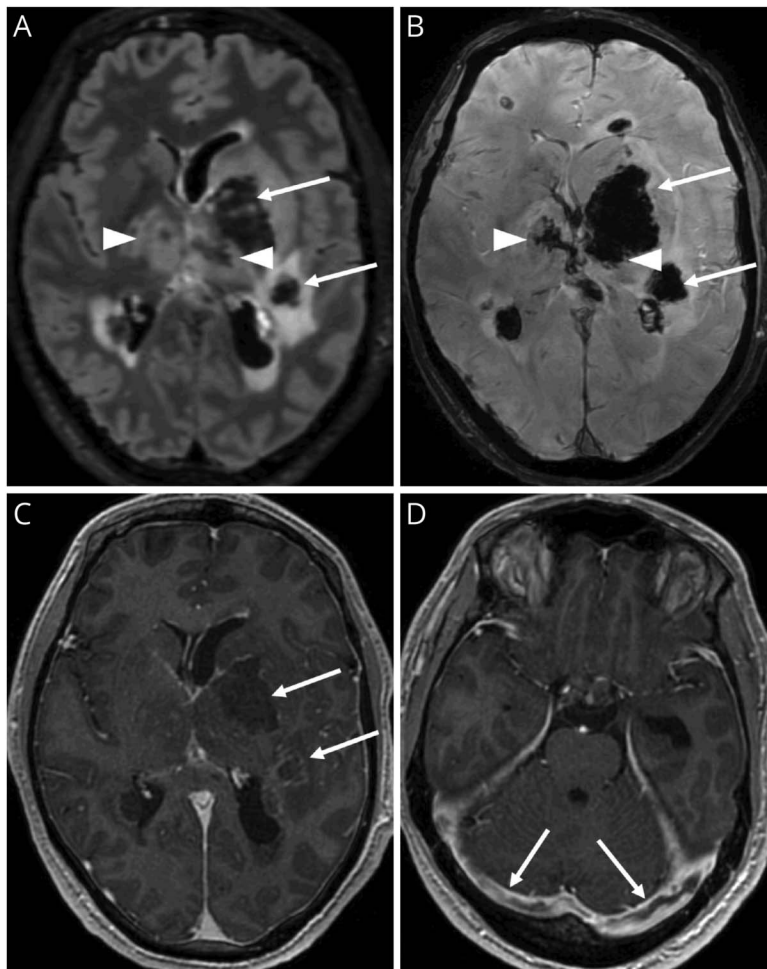
of 1:1,000 by cell-based assay (eTable). CSF interleukin-6 (IL-6) level was elevated at 17,904.6 pg/mL (normal level \leq 7.5 pg/mL) (Table). Given his worsening despite IV steroid treatment, he underwent 5 sessions of plasma exchange (PLEX), and the cerebral venous sinus thrombosis (CVST), presumed secondary to inflammation from MOGAD, was treated with anticoagulation. He improved clinically, and this was attributed to PLEX treatment. Interval imaging showed decreased enhancement and a marked decrease in vasogenic edema surrounding numerous hemorrhagic lesions in the supratentorial brain (Figure 3). After his inpatient hospitalization, he was transferred to a rehabilitation hospital. Given the elevated CSF IL-6 level, he was started on the IL-6R antagonist tocilizumab 8 mg/kg every 4 weeks, which he has continued for more than one year. He

Figure 1 Brain and Spinal Cord Imaging at the Time of Clinical Presentation



Brain MRI at presentation demonstrates small T2-FLAIR hyperintense lesions of the right frontal subcortical white matter and right lateral pons (A, C, arrows) with mild enhancement (B, arrow). Thoracic spine MRI demonstrates T2 hyperintensity at T2-3 (D, arrow) and enhancement involving the ventral cord at T2-3 and T6-7 (E, arrows).

Figure 2 Brain Imaging at the Time of Clinical Deterioration



Brain MRI at the time of clinical deterioration demonstrates new supratentorial T2-FLAIR hyperintense lesions involving the white matter and left globus pallidus (A, arrows) with extensive hemorrhage (B, arrows) and peripheral enhancement (C, arrows). Bilateral thalamic T2-FLAIR hyperintensity (A, arrowheads) with hemorrhage (B, arrowheads) and bilateral transverse sinus thrombosis (D, arrows). Internal cerebral vein thrombosis not shown.

completed a slow oral prednisone taper 10 months later. His serum MOG-IgG level remains positive at 1:1,000. Currently, he ambulates without assistance but struggles with neurocognitive deficits. He has not been able to return to work.

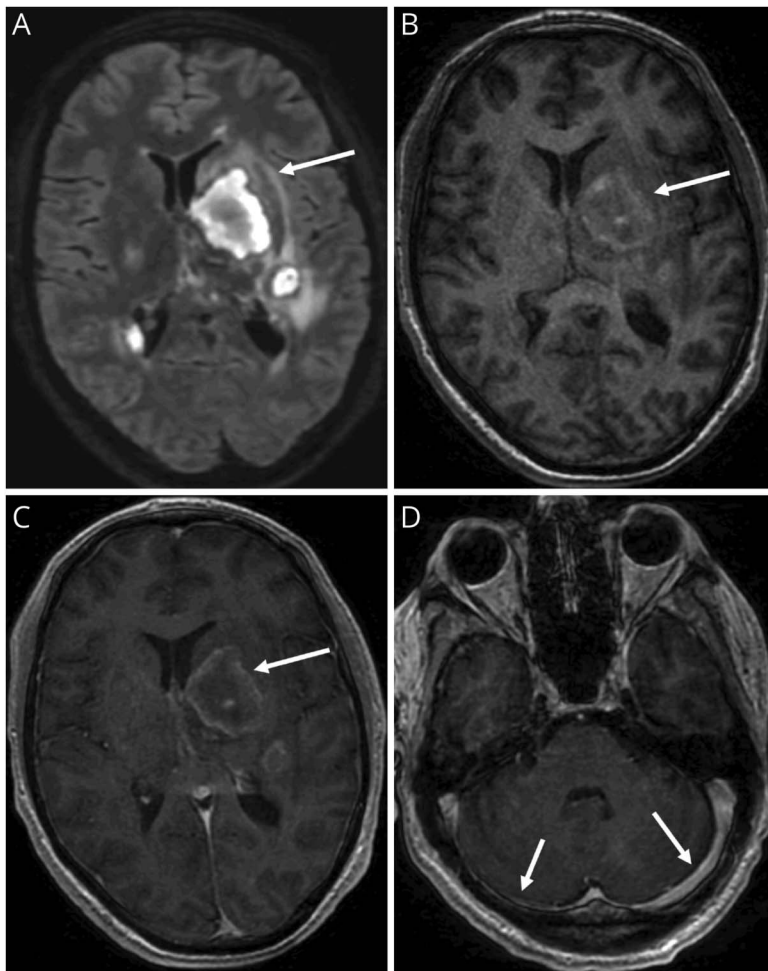
Discussion

MOGAD is a recently recognized CNS demyelinating disorder that can affect both children and adults.^{1,2} The MOG-specific antibodies in patients with MOGAD are predominantly IgG1, a T-cell-dependent Ig subclass.^{1,3} In this report, we present a 35-year-old man who exhibited a distinct clinical phenotype subsequent to Tdap vaccination leading to the diagnosis of MOGAD. Our patient manifested optic-spinal involvement with a notably rapid progression in severity. Severe ADEM, as we observed in this case, is more common in children than adults.^{2,4,5} Our patient had multifocal T2/FLAIR hyperintensities within the supratentorial white matter, corpus callosum, basal ganglia, and spinal cord, which are characteristic of MOGAD.^{2,6,7} Notably, the

Table CSF Cytokine Analysis Performed in the Intensive Care Unit

CSF interleukins	Results	Flag	Units	Reference range
Interferon gamma	9.8	High	pg/mL	≤4.2
Interleukin 10	64.8	High	pg/mL	≤12.7
Interleukin 12	<1.9	Normal	pg/mL	≤1.9
Interleukin 13	30.8	High	pg/mL	≤7.3
Interleukin 17	<1.4	Normal	pg/mL	≤4.6
Interleukin 1 beta	36.8	High	pg/mL	≤6.5
Interleukin 2	2.3	High	pg/mL	≤2.1
Interleukin 2 receptor, soluble	33.5	High	pg/mL	≤26.8
Interleukin 4	<2.2	Normal	pg/mL	≤5.2
Interleukin 5	8.8	High	pg/mL	≤2.1
Interleukin 6	17,904.6	High	pg/mL	≤7.5

Figure 3 Brain Imaging After Plasma Exchange (PLEX)



Brain MRI after treatment with 5 PLEX sessions demonstrates decrease in edema associated with supratentorial T2-FLAIR hyperintense lesions (A, arrow) with intrinsic T1 hyperintensity (B, arrow) and minimal peripheral enhancement (C, arrow). Improvement in previously seen transverse sinus thrombosis (D, arrows).

association with CVST is an unusually prominent feature in this case of MOGAD.^{8,9} The rapid progression may have contributed to the CVST and subsequent hemorrhage, possibly due to elevated venous pressure. This patient's rapid response to PLEX emphasizes the potential benefit of PLEX in patients with severe MOGAD who are refractory to IV steroids.

In addition to the presentation of hemorrhagic leukoencephalomyelitis, other features of this case are unusual. In general, one does not routinely perform CSF cytokine protein analysis in clinical practice. The exceptionally high level of CSF IL-6 in association with MOGAD that we observed is uncommon, although one research study identified elevated CSF IL-6 in MOGAD and neuromyelitis optica spectrum disorder.¹⁰ Unfortunately, we did not collect peripheral blood IL-6 simultaneously. IL-6, a pleiotropic cytokine primarily recognized for its proinflammatory activity, is produced by myeloid cells, B cells, and T cells.¹¹⁻¹³ IL-6 is the hallmark cytokine driving Th17 differentiation.¹⁴ In this regard, observational studies suggest benefit of tocilizumab in MOGAD, and satralizumab, another IL-6 receptor antagonist, is

currently being tested in a phase III, randomized, double-blind, placebo-controlled MOGAD trial.^{5,15,16} Our patient has remained stable on tocilizumab monotherapy suggesting benefit, although his risk of relapse is unclear. Nevertheless, our observation regarding CSF IL-6 elevation provides further support for testing inhibitors of the IL-6 pathway in MOGAD.

Vaccinations against specific bacteria and viruses provide protective immunity for most individuals, yet it is recognized that rare adverse events can occur.^{17,18} It is possible that Tdap vaccination before the onset of neurologic symptoms contributed to this patient's development of ADEM and diagnosis of MOGAD. Unfortunately, we do not know whether the patient was MOG IgG seropositive before Tdap vaccination. However, it is known that ADEM and MOGAD can occur weeks after infection and vaccinations,^{19,20} and epidemiologic research has shown a statistically significant elevated risk of ADEM after Tdap vaccination.²¹ Cases of MOG antibody-associated ADEM have been reported shortly after SARS-CoV-2 vaccination²² or infection.^{23,24} However, our patient had no history of SARS-CoV-2 infection; his most recent SARS-CoV-2 mRNA

vaccination was received 6 months before his clinical deterioration and he tested negative during hospitalization, essentially eliminating a possible association with either SARS-CoV-2 vaccination or SARS-CoV-2 infection in this patient's development of CVST and hemorrhagic ADEM. Of interest, although tetanus toxoid (TT) and MOG are dissimilar proteins, amino acid sequences of 2 known human T-cell epitopes of TT²⁵ are homologous to sequences of MOG that stimulate MOG-specific T cells in patients with MS and controls (eFigure 1).^{26,27} Thus, the TT of Tdap could serve as a molecular mimic of MOG. Tdap also contains alum, an adjuvant that augments the innate and adaptive immune response to vaccination.²⁸ Nevertheless, although the onset of neurologic symptoms 14 days after Tdap vaccination aligns with the WHO criteria for causality,²⁹ there are plausible immunologic mechanisms and literature associating Tdap with the onset of ADEM, one cannot conclude with scientific certainty that Tdap vaccination had a causal role in the development of MOGAD in this patient.

In summary, our case highlights an unusual presentation of severe MOGAD, emphasizes the potential benefit of PLEX in severe MOGAD cases refractory to steroid treatment, and demonstrates how assessment of CSF IL-6 may help guide treatment decisions. One may wish to consider testing CSF cytokines in patients with acute manifestations of MOGAD more widely.

Study Funding

The authors report no targeted funding.

Disclosure

A. Virupakshaiah is supported by fellowship support from Biogen, EMD Serono and Novartis. C.E. Moseley is supported by a National Multiple Sclerosis Society Clinician Scientist Development Award # FAN-2107-38301. S.S. Zamvil is supported by NIH grants 1 R01 AI131624-01A1 and 1 RO1 AI170863-01A1. All other authors report no disclosures relevant to the manuscript. Go to [Neurology.org/NN](https://www.neurology.org/NN) for full disclosures.

Publication History

Received by *Neurology: Neuroimmunology & Neuroinflammation* January 4, 2024. Accepted in final form February 14, 2024. Submitted and externally peer reviewed. The handling editor was Editor Josep O. Dalmau, MD, PhD, FAAN.

Appendix Authors

Name	Location	Contribution
Akash Virupakshaiah, MD	UCSF Weill Institute for Neurosciences, University of California, San Francisco	Drafting/revision of the manuscript for content, including medical writing for content; major role in the acquisition of data; study concept or design; analysis or interpretation of data

Appendix (continued)

Name	Location	Contribution
Carson E. Moseley, MD, PhD	UCSF Weill Institute for Neurosciences, University of California, San Francisco	Drafting/revision of the manuscript for content, including medical writing for content; major role in the acquisition of data; study concept or design; analysis or interpretation of data
Steven EliceGUI, BS	University of Nevada Reno School of Medicine	Drafting/revision of the manuscript for content, including medical writing for content; major role in the acquisition of data
Lee M. Gerwitz, MD	Renown Health, Reno, Nevada	Drafting/revision of the manuscript for content, including medical writing for content; major role in the acquisition of data; analysis or interpretation of data
Collin M. Spencer, BS	UCSF Weill Institute for Neurosciences, University of California, San Francisco	Drafting/revision of the manuscript for content, including medical writing for content; major role in the acquisition of data; analysis or interpretation of data
Elizabeth George, MBBS	Department of Radiology and Biomedical Imaging, University of California, San Francisco	Drafting/revision of the manuscript for content, including medical writing for content; major role in the acquisition of data; analysis or interpretation of data
Maulik Shah, MD, MHS	UCSF Weill Institute for Neurosciences, University of California, San Francisco	Drafting/revision of the manuscript for content, including medical writing for content; major role in the acquisition of data; analysis or interpretation of data
Bruce A.C. Cree, MD, PhD, MAS	UCSF Weill Institute for Neurosciences, University of California, San Francisco	Drafting/revision of the manuscript for content, including medical writing for content; analysis or interpretation of data
Emmanuelle Waubant, MD, PhD	UCSF Weill Institute for Neurosciences, University of California, San Francisco	Drafting/revision of the manuscript for content, including medical writing for content; major role in the acquisition of data; analysis or interpretation of data
Scott S. Zamvil, MD, PhD	UCSF Weill Institute for Neurosciences; Program in Immunology, University of California, San Francisco	Drafting/revision of the manuscript for content, including medical writing for content; major role in the acquisition of data; study concept or design; analysis or interpretation of data

References

- Zamvil SS, Slavin AJ. Does MOG Ig-positive AQP4-seronegative opticospinal inflammatory disease justify a diagnosis of NMO spectrum disorder? *Neurol Neuroimmunol Neuroinflamm*. 2015;2(1):e62. doi:10.1212/NXI.0000000000000062
- Banwell B, Bennett JL, Marignier R, et al. Diagnosis of myelin oligodendrocyte glycoprotein antibody-associated disease: international MOGAD Panel proposed criteria. *Lancet Neurol*. 2023;22(3):268-282. doi:10.1016/S1474-4422(22)00431-8

3. Nurieva RI, Chung Y. Understanding the development and function of T follicular helper cells. *Cell Mol Immunol*. 2010;7(3):190-197. doi:10.1038/CMI.2010.24
4. Hachohen Y, Banwell B. Treatment approaches for MOG-Ab-associated demyelination in children. *Curr Treat Options Neurol*. 2019;21(1):2. doi:10.1007/S11940-019-0541-X
5. McLendon LA, Gambrah-Lyles C, Viaene A, et al. Dramatic response to anti-IL-6 receptor therapy in children with life-threatening myelin oligodendrocyte glycoprotein-associated disease. *Neurol Neuroimmunol Neuroinflamm*. 2023;10(6):e200150. doi:10.1212/NXL.000000000000200150
6. Chia NH, Redenbaugh V, Chen JJ, Pittcock SJ, Flanagan EP. Corpus callosum involvement in MOG antibody-associated disease in comparison to AQP4-IgG-seropositive neuromyelitis optica spectrum disorder and multiple sclerosis. *Mult Scler*. 2023;29(6):748-752. doi:10.1177/13524585221150743
7. Sacco S, Virupakshaiiah A, Papinutto N, et al. Susceptibility-based imaging aids accurate distinction of pediatric-onset MS from myelin oligodendrocyte glycoprotein antibody-associated disease. *Mult Scler*. 2023;29(14):1736-1747. doi:10.1177/13524585231204414
8. Al-Ani A, Chen JJ, Costello F. Myelin oligodendrocyte glycoprotein antibody-associated disease (MOGAD): current understanding and challenges. *J Neurol*. 2023;270(8):4132-4150. doi:10.1007/s00415-023-11737-8
9. Fontana A, Greco F, Smilari P, et al. Anti-MOG antibody syndrome and cerebral sinovenous thrombosis: a cause-effect hypothesis. *J Pediatr Neurol*. 2021;19(02):127-131. doi:10.1055/s-0040-1716345
10. Kaneko K, Sato DK, Nakashima I, et al. CSF cytokine profile in MOG-IgG+ neurological disease is similar to AQP4-IgG+ NMOSD but distinct from MS: a cross-sectional study and potential therapeutic implications. *J Neurol Neurosurg Psychiatry*. 2018;89(9):927-936. doi:10.1136/JNNP-2018-317969
11. Barr TA, Shen P, Brown S, et al. B cell depletion therapy ameliorates autoimmune disease through ablation of IL-6-producing B cells. *J Exp Med*. 2012;209(5):1001-1010. doi:10.1084/JEM.20111675
12. Molnarfi N, Schulze-Topphoff U, Weber MS, et al. MHC class II-dependent B cell APC function is required for induction of CNS autoimmunity independent of myelin-specific antibodies. *J Exp Med*. 2013;210(13):2921-2937. doi:10.1084/JEM.20130699
13. Fujihara K, Bennett JL, de Seze J, et al. Interleukin-6 in neuromyelitis optica spectrum disorder pathophysiology. *Neurol Neuroimmunol Neuroinflamm*. 2020;7(5):e841. doi:10.1212/NXL.0000000000000841
14. Bettelli E, Carrier Y, Gao W, et al. Reciprocal developmental pathways for the generation of pathogenic effector TH17 and regulatory T cells. *Nature*. 2006;441(7090):235-238. doi:10.1038/nature04753
15. Ringelstein M, Azyzenberg I, Lindenblatt G, et al. Interleukin-6 receptor blockade in treatment-refractory MOG-IgG-associated disease and neuromyelitis optica spectrum disorders. *Neurol Neuroimmunol Neuroinflamm*. 2022;9(1):e1100. doi:10.1212/NXL.0000000000001100
16. *Study Details | A Study to Evaluate the Efficacy, Safety, Pharmacokinetics, and Pharmacodynamics of Satralizumab in Patients With Myelin Oligodendrocyte Glycoprotein Antibody-Associated Disease | ClinicalTrials.gov*. Accessed November 30, 2023. clinicaltrials.gov/study/NCT05271409
17. Liang JL, Tiwari T, Moro P, et al. Prevention of pertussis, tetanus, and diphtheria with vaccines in the United States: recommendations of the Advisory Committee on Immunization Practices (ACIP). *MMWR Recomm Rep*. 2018;67(2):1-44. doi:10.15585/MMWR.RR6702A1
18. Schonberger LB, Bregman DJ, Sullivan-bolyai JZ, et al. Guillain-Barre syndrome following vaccination in the National Influenza Immunization Program, United States, 1976-1977. *Am J Epidemiol*. 1979;110(2):105-123. doi:10.1093/OXFORDJOURNALS.AJE.A112795
19. Longbrake E. Myelin oligodendrocyte glycoprotein-associated disorders. *Continuum (Minneapolis, Minn)*. 2022;28(4):1171-1193. doi:10.1212/CON.0000000000001127
20. Jarius S, Ruprecht K, Kleiter I, et al. MOG-IgG in NMO and related disorders: a multicenter study of 50 patients. Part 2: epidemiology, clinical presentation, radiological and laboratory features, treatment responses, and long-term outcome. *J Neuroinflammation*. 2016;13(1):280. doi:10.1186/S12974-016-0718-0
21. Baxter R, Lewis E, Goddard K, et al. Acute demyelinating events following vaccines: a case-centered analysis. *Clin Infect Dis*. 2016;63(11):1456-1462. doi:10.1093/CID/CIW607
22. Francis A, Palace J, Fugger L. MOG antibody-associated disease after vaccination with ChAdOx1 nCoV-19. *Lancet Neurol*. 2022;21(3):217-218. doi:10.1016/S1474-4422(22)00043-6
23. Faksova K, Walsh D, Jiang Y, et al. COVID-19 vaccines and adverse events of special interest: a multinational Global Vaccine Data Network (GVDN) cohort study of 99 million vaccinated individuals. *Vaccine*. Published online February 12, 2024. doi:10.1016/j.vaccine.2024.01.100
24. Johnsson M, Asztely F, Hejnebo S, et al. SARS-COV-2 a trigger of myelin oligodendrocyte glycoprotein-associated disorder. *Ann Clin Transl Neurol*. 2022;9(8):1296-1301. doi:10.1002/ACN3.51609
25. Reece JC, Geysen HM, Rodda SJ. Mapping the major human T helper epitopes of tetanus toxin. The emerging picture. *J Immunol*. 1993;151(11):6175-6184. doi:10.4049/jimmunol.151.11.6175
26. Weissert R, Kuhle J, de Graaf KL, et al. High immunogenicity of intracellular myelin oligodendrocyte glycoprotein epitopes. *J Immunol*. 2002;169(1):548-556. doi:10.4049/JIMMUNOL.169.1.548
27. Varrin-Doyer M, Shetty A, Spencer CM, et al. MOG transmembrane and cytoplasmic domains contain highly stimulatory T-cell epitopes in MS. *Neurol Neuroimmunol Neuroinflamm*. 2014;1(2):e20. doi:10.1212/NXL.0000000000000020
28. Eisenbarth SC, Colegio OR, O'Connor W, Sutterwala FS, Flavell RA. Crucial role for the Nalp3 inflammasome in the immunostimulatory properties of aluminium adjuvants. *Nature*. 2008;453(7198):1122-1126. doi:10.1038/NATURE06939
29. The use of the WHO-UMC system for standardised case causality assessment. Accessed December 16, 2023. who.int/publications/m/item/WHO-causality-assessment