

UC Davis

UC Davis Previously Published Works

Title

Repeatability of Choroidal Thickness Measurements on Enhanced Depth Imaging Optical Coherence Tomography Using Different Posterior Boundaries

Permalink

<https://escholarship.org/uc/item/905716zx>

Authors

Vuong, Vivian S
Moisseiev, Elad
Cunefare, David
[et al.](#)

Publication Date

2016-09-01

DOI

10.1016/j.ajo.2016.06.023

Peer reviewed



Published in final edited form as:

Am J Ophthalmol. 2016 September ; 169: 104–112. doi:10.1016/j.ajo.2016.06.023.

Repeatability of Choroidal Thickness Measurements on Enhanced Depth Imaging OCT using Different Posterior Boundaries

Vivian S. Vuong^{1,2}, Elad Moisseiev¹, David Cunefare³, Sina Farsiu³, Ala Moshiri¹, and Glenn Yiu¹

¹Department of Ophthalmology & Vision Science, University of California, Davis, Sacramento, CA, United States

²School of Medicine, University of California, Davis, Sacramento, CA, United States

³Department of Biomedical Engineering, Duke University, Durham, NC, United States

Abstract

PURPOSE—To assess the reliability of manual choroidal thickness measurements by comparing different posterior boundary definitions of the choroidal-scleral junction on enhanced depth imaging optical coherence tomography (EDI-OCT).

DESIGN—Reliability analysis

METHODS—Two graders marked the choroidal-scleral junction with segmentation software using different posterior boundaries: 1) the outer border of the choroidal vessel lumen, 2) the outer border of the choroid stroma, and 3) the inner border of the sclera, to measure the vascular choroidal thickness (VCT), stromal choroidal thickness (SCT), and total choroidal thickness (TCT), respectively. Measurements were taken at 0.5 mm intervals from 1.5 mm nasal to 1.5 mm temporal to the fovea, and averaged continuously across the central 3 mm of the macula. Intraclass correlation coefficient (ICC) and coefficient of reliability (CR) were compared to assess intergrader and intragrader reliability.

RESULTS—Choroidal thickness measurements varied significantly with different posterior boundaries ($P = <0.001$ for all). Intergrader ICCs were greater for SCT (0.959 – 0.980) than TCT (0.928 – 0.963) and VCT (0.750 – 0.869), even in eyes where choroidal-scleral junction visibility was $<75\%$. Intergrader CRs were lower for SCT (41.40 – 62.31) than TCT (61.13 – 74.24) or VCT (72.44 – 115.11). ICCs and CRs showed greater reliability for averaged VCT, SCT, or TCT measurements, than at individual locations. Intragrader ICCs and CRs were comparable to intergrader values.

Corresponding Author: Glenn Yiu, MD, PhD, Department of Ophthalmology, UC Davis Eye Center, 4860 Y St. Suite 2400, Sacramento, CA 95817, USA, Tel: +1 916 734 6602, Fax: +1 916 734 6197, gyiu@ucdavis.edu.

Supplemental Material available at AJO.com

Publisher's Disclaimer: This is a PDF file of an unedited manuscript that has been accepted for publication. As a service to our customers we are providing this early version of the manuscript. The manuscript will undergo copyediting, typesetting, and review of the resulting proof before it is published in its final citable form. Please note that during the production process errors may be discovered which could affect the content, and all legal disclaimers that apply to the journal pertain.

CONCLUSIONS—Choroidal thickness measurements are more reproducible when measured to the border of the choroid stroma (SCT) than the vascular lumen (VCT) or sclera (TCT).

INTRODUCTION

The choroidal vasculature is difficult to visualize on conventional spectral-domain optical coherence tomography (SD-OCT) due to its posterior location and light scatter from the retinal pigment epithelium (RPE). Enhanced-depth imaging OCT (EDI-OCT) is an imaging technique that provides better visualization of the choroid by positioning the zero-delay line at a more posterior location.¹ Since Spaide's description of the technique in 2008,¹ more than 700 citations have been published in biomedical literature using EDI-OCT to measure choroidal thickness in various conditions. Choroidal thickness changes have been described in age-related choroidal atrophy,² pachychoroid spectrum conditions like central serous chorioretinopathy,^{3,4} and choroidal inflammatory diseases including Vogt-Koyanagi-Harada syndrome.⁵⁻⁷ Choroidal thinning has also been implicated in age-related macular degeneration,⁸⁻¹¹ diabetic retinopathy,^{12,13} retinal vein occlusions,^{14,15} and as a consequence of anti-vascular endothelial growth factor (anti-VEGF) therapy.¹⁶⁻¹⁹

In contrast to retinal thickness measurements, however, there is a lack of widely-available algorithms for measuring choroidal thickness, resulting in a variety of nonstandardized manual and automated methods for choroidal thickness measurements that are difficult to compare.²⁰⁻²⁴ Much of the difficulty in achieving reliable choroidal thickness measurements is due to the variable and often obscure appearance of the choroidal-scleral junction (CSJ) that determines the posterior boundary of the choroid. While some studies appear to use the border of the choroidal vascular lumen as the posterior boundary,^{15,25-28} others defined the border of the choroid stroma or sclera as the CSJ.²⁹⁻³² In some individuals, there is also a hyporeflective band corresponding to the suprachoroidal layer, which may further contribute to variability in choroidal thickness measurements.³³ We have shown previously that choroidal thickness measurements can vary significantly using different definitions of the CSJ as posterior boundaries including: 1) the inner border of the choroidal vessel lumen; 2) the outer border of the choroid stroma; and 3) the inner border of the sclera.³³ The purpose of this study is to determine which of these posterior boundary definitions are most reproducible, to standardize the definition of the CSJ for measuring choroidal thickness, and to improve the reliability of choroidal thickness measurements in future clinical and research studies.

METHODS

Subject and eye selection

A retrospective, cross-sectional analysis was performed on 91 normal eyes of 91 patients who underwent EDI-OCT imaging at the UC Davis Eye Center. This study was approved by the Institutional Review Board of University of California, Davis and was conducted in accordance with the tenets of the Declaration of Helsinki. Subjects were identified from a database search of all patients seen on the Vitreoretinal service at UC Davis between September 1st, 2014 and October 31st, 2015. Study eyes were selected if they had a normal ophthalmological examination and EDI-OCT imaging, including 1) eyes evaluated for

possible macular pathology, but in which no abnormalities were found, 2) eyes with mild vitreomacular interface abnormalities such as epiretinal membranes or vitreomacular traction without distortion of the outer retina, and 3) contralateral eyes in cases of unilateral ocular pathologies that are not known to affect choroidal thickness such as retinal tear or retinal detachment. Exclusion criteria for study eyes include any retinal or choroidal disease beyond mild vitreomacular interface abnormalities, history of vitreoretinal surgery, and myopia greater than -6 diopters (D) spherical equivalent. Only one eye from each subject was included for analysis. If both eyes qualified based on inclusion and exclusion criteria, the eye with the best-corrected visual acuity (BCVA) was selected. If BCVA was equal between the two eyes, the right eye was selected for patients with an even-number birth month, and the left eye selected for an odd-number birth month. For all study eyes, images were obtained from the subject's first visit at which they had EDI-OCT imaging. Charts were also reviewed to collect demographic and clinical data, including age, sex, best-corrected visual acuity (logMAR), refractive error (D), intraocular pressure (mmHg), and lens status (phakic, pseudophakic, or aphakic).

Choroidal thickness measurements

EDI-OCT images were obtained using the Spectralis SD-OCT unit (Heidelberg Engineering, Heidelberg, Germany), and were performed by trained ophthalmic photographers at the UC Davis Eye Center. A single 30-degree horizontal line scan (approximately 9mm), centered on the fovea, taken in either high-speed EDI-mode (768 A-scans per B scan) or high-resolution EDI-mode (1536 A-scans per B-scan) was selected for analysis. Using the eye-tracking Automatic Real-time (ART) mode in Spectralis, up to 100 frames were captured per image, with an average of 75.08 ± 23.38 frames per image. EDI-OCT images were exported from Heidelberg Eye Explorer software (version 1.8.6.0) to Duke Optical Coherence Tomography Retinal Analysis Program (DOCTRAP, version 62.0), a custom image segmentation software designed using MATLAB (Mathworks) for semi-automated segmentation and CSJ tracing.³⁴ For all choroidal thickness measurements, the inner boundary was automatically determined by DOCTRAP as the outer border of the hyperreflective line corresponding to the RPE/Bruchs membrane complex, while the outer boundary was manually traced across the entire B-scan by two independent trained graders (observer A [VV] and observer B [EM]) using three different posterior boundaries: 1) the outer border of the choroidal vessel lumen, 2) the outer border of the choroid stroma, and 3) the inner border of the sclera, which were used to determine respectively, the vascular choroidal thickness (VCT), stromal choroidal thickness (SCT) and total choroidal thickness (TCT), as previously described (Figure 1).³³ Based on these definitions, TCT is distinct from the SCT in eyes where the suprachoroidal layer is visible. DOCTRAP software was used to measure choroidal thickness at the fovea (subfoveal VCT, SCT, and TCT) and at 0.5 mm intervals up to 1.5 mm nasal and 1.5 mm temporal to the fovea. Choroidal thickness was also averaged continuously across the central 3 mm to provide an "averaged" VCT, SCT, and TCT. Choroidal thickness measurements from both graders (observer A and observer B) were compared to evaluate intergrader repeatability. One grader repeated the CSJ tracings 1 month later (observer A and observer A') to determine intragrader reliability.

Visibility of the CSJ was also categorized independently by the two graders as clear (>75% CSJ visibility) or unclear (<75% CSJ visibility). The presence of a visible suprachoroidal layer was also determined by the two graders. Any disagreements in CSJ visibility or suprachoroidal layer visibility were resolved by open arbitration, and by a senior grader (GY) if an agreement could not be reached. Observers A and B were masked to the other's measurements, and observer A was masked to her previous measurements for her second session. All measurements were conducted at a 1:1 pixel ratio.

Statistical analyses

One-way analysis of variance (ANOVA) with Bonferroni's post-tests were used to compare mean choroidal thickness measurements using different posterior boundaries (VCT, SCT, and TCT). Paired t-tests were used to compare choroidal thickness measurements between observers A and B. Multivariate regression analysis was used to determine any independent association of choroidal thickness with age and refractive error. $P < 0.05$ was considered to be statistically significant.

Intergrader and intragrader repeatability of choroidal thickness measurements were assessed by ICC and the Bland-Altman method.³⁵ The coefficient of repeatability (CR) describes the smallest possible change in choroidal thickness measurements that represents a true change, and was calculated by multiplying the standard deviation of the differences between the two measurements by 1.96.³⁶ The difference between two measurements is expected to be less than the CR for 95% of pairs of observations. The upper and lower 95% limits of agreement (LOA) are calculated by adding and subtracting the CR value from the mean difference, respectively.³⁵ Statistical analyses were performed using STATA statistical software (version 13.0; StataCorp LP, College Station, TX). Bland-Altman plots and boxplots were created with MedCalc for Windows, version 14.8.1 (MedCalc Software, Ostend, Belgium).

RESULTS

Demographics and clinical characteristics

A total of 91 normal eyes from 91 subjects with no known retinal or choroidal diseases were included in the analysis. Mean age was 56.8 (range, 10 – 88 years), with mostly phakic eyes, and similar proportions of males versus females and right versus left eyes (Table 1). Mean best-corrected visual acuity was 0.116 ± 0.156 or Snellen equivalent of 20/26; and mean refractive error was -1.15 ± 2.34 D.

Choroidal thickness measured with different posterior boundaries

Choroidal thickness varied significantly using different posterior boundaries at all locations across the macula ($P = <0.001$ for all). Averaging the measurements made by the two observers, mean subfoveal VCT was 208.36 ± 69.68 μm , mean subfoveal SCT was 274.57 ± 78.86 μm , and mean subfoveal TCT was 287.36 ± 75.59 μm (Figure 2). Comparing the two observers, there were no significant differences in SCT and TCT measurements between observers A and B at all locations ($P = 0.092 - 0.596$), except for VCT which showed small but significant mean differences of 12.38 ± 49.15 to 28.15 ± 58.73 μm between the two observers ($P = <0.001 - 0.018$) (Figure 3: left panel).

When continuously averaged across the central 3mm segment, averaged choroidal thicknesses also varied significantly with different posterior boundaries ($P = <0.001$), with mean averaged VCT of $204.10 \pm 58.067 \mu\text{m}$, mean averaged SCT of $266.52 \pm 75.03 \mu\text{m}$, and mean averaged TCT of $279.60 \pm 73.50 \mu\text{m}$. Again, there was a small but significant difference between the two observers in averaged VCT, but not in averaged SCT or TCT (Table 2, Figure 3: right panel).

Prior studies have shown that the choroid becomes thinner with advanced age³⁷ and myopic refractive error.^{38,39} Consistent with prior results, subfoveal VCT, SCT, and TCT all showed an inverse association with age (VCT: $R^2 = 0.112$; $P = 0.001$; SCT: $R^2 = 0.179$; $P = <0.001$; TCT: $R^2 = 0.176$; $P = <0.001$), and a positive association with refractive error (VCT: $R^2 = 0.092$; $P = 0.031$; SCT: $R^2 = 0.117$; $P = 0.014$; TCT: $R^2 = 0.129$; $P = 0.010$). Hence, while the three posterior boundaries measure choroidal thickness differently, all three measurements reflect known physiologic associations of choroidal thickness.

Reliability of choroidal thickness measurements

Overall, all intergrader and intragrader ICC values were greater than 0.75, indicating good repeatability of choroidal thickness measurements using all three posterior boundaries. Intergrader ICCs were greater for SCT (0.959 – 0.980) than TCT (0.928 – 0.963) or VCT (0.750 – 0.869) at all locations including the fovea (Table 2). Intragrader ICC was also greater for SCT (0.967 – 0.987) than TCT (0.912 – 0.949) or VCT (0.915 – 0.967) at these locations (Supplemental Table 1). When choroidal thickness measurements were continuously averaged across the central macula (averaged VCT, SCT, and TCT), both intergrader and intragrader ICCs showed better repeatability than individual locations (Table 2, Supplemental Table 1).

The CR is another estimate of the reliability of choroidal thickness measurements, and represents the smallest possible change in choroidal thickness measurements that represents true change. Consistent with the ICC results, both intergrader and intragrader CRs were lower for SCT (30.77 – 62.31 μm) than TCT (50.21 – 75.17 μm) or VCT (41.14 – 115.11 μm), and when averaged across the macula (30.77 – 72.44 μm) than at individual locations (32.87 – 115.11 μm) (Table 2, Supplemental Table 1).

Intragrader ICCs and CRs followed the same trends as intergrader values, but intragrader ICCs were greater than intergrader ICCs, and intragrader CRs were lower than intergrader CRs (Supplemental Table 1).

Bland-Altman plots demonstrate that choroidal thickness measurements generally lie within the 95% limits of agreement except for VCT, which also showed larger limits of agreement compared to SCT and TCT (Figure 4, Supplemental Figure 1). An outlier in TCT measurements was noted to arise from the inclusion of a deep hyporeflective space near the fovea likely representing a short posterior ciliary vessel in the segmentation by one observer for only the TCT measurement, but not the other measurements. Intergrader and intragrader analyses also showed greater variance between observers and between sessions as choroidal thickness increased, as previously demonstrated.^{25,40} This phenomenon is likely due to the decrease in signal transmission through thicker choroids, resulting in a less distinct CSJ.

Together, these results suggest that choroidal thickness measurements are more reproducible when measured to the border of the choroid stroma (SCT) than the vascular lumen (VCT) or sclera (TCT), and that averaging of choroidal thickness measurements across the central macula is more reproducible than measuring choroidal thickness at individual locations.

Effect of choroidal-scleral junction (CSJ) visibility

Previous studies have shown that the reliability of choroidal thickness measurements are reduced in eyes with thicker choroids.⁴¹ We hypothesize that this may result from the reduced visibility of the CSJ, and analyzed the subset of eyes with a clearly-demarcated CSJ, defined as $\geq 75\%$ CSJ visibility, compared with those with ill-defined CSJ of $<75\%$ visibility. Both groups showed similar demographic and clinical characteristics (Table 1). The eyes with $\geq 75\%$ CSJ visibility demonstrated much higher intergrader ICCs of 0.840 – 0.986, compared to ICCs of 0.455 – 0.958 for eyes with $<75\%$ CSJ visibility. Interestingly, while intergrader ICCs for SCT (0.904 – 0.986) is higher than TCT (0.856 – 0.975) and VCT (0.455 – 0.954) in both subgroups, the advantage is more pronounced in eyes with poor CSJ visibility (Table 3). Likewise, intergrader CRs in both subgroups were lower for SCT (26.22 – 83.85 μm) than TCT (37.95 – 99.02 μm) or VCT (35.71 – 150.98 μm), and were lower when averaged across the macula (26.22 – 96.75 μm) than at individual locations (31.40 – 150.98 μm). Intragrader ICCs and CR followed the same pattern as intergrader values.

We also compared the reliability of images captured in high-resolution (1536 A-scans per B-scan) or high-speed (768 A-scans per B-scan) mode. Similar to eyes with greater CSJ visibility, high-resolution images also showed greater ICCs (0.954 – 0.994) than those of high-speed images (0.783 – 0.976), and the superior repeatability of SCT is more apparent in high-speed images, which were captured at a lower resolution (Supplemental Table 2).

Together, these data indicate that while all three posterior boundaries may provide reliable choroidal thickness measurements if the CSJ is clearly defined, SCT provides superior reproducibility in lower resolution images, or in images where the CSJ is not well visualized.

Effect of suprachoroidal layer visibility

Since the SCT and TCT are only distinguishable in eyes with a visible suprachoroidal space separating the outer border of the choroidal stroma from the inner border of the sclera, we analyzed the subset of eyes with a visible suprachoroidal layer to determine if the difference in reliability of SCT and TCT measurements are more pronounced. The suprachoroidal layer was visible in 14 of 91 (15.4%) of subjects. The mean age was 59.5 (range, 42 – 78 years), with only phakic eyes, and similar proportions of males versus females and right versus left eyes. Subjects tended to be more myopic, with mean refractive error of -2.25 ± 2.93 D. Within this subset, the ICCs and CRs of those with visible suprachoroidal layer compared to those without were comparable (Supplemental Table 3). Thus, the presence of a visible suprachoroidal space does not appear to impact the reproducibility of choroidal thickness measurements.

DISCUSSION

Despite the growing number of published studies measuring choroidal thickness from EDI-OCT images, choroidal thickness measurements remain highly variable due to the lack of a standardized CSJ definition. Unlike the boundaries of the retina, the posterior border of the choroid is poorly defined, histologically consisting of a gradual transition from the loose collagen fibers of the choroid stroma to the more compact architecture of the sclera, rather than a clear anatomical demarcation. In addition, signal roll-off from choroidal pigment and posterior shadowing from retinal fluid can further obscure the CSJ, resulting in poorly reproducible choroidal thickness measurements in clinical use and research studies.

Our data showed that choroidal thickness measurements are more reproducible when measured to the outer border of the choroid stroma (SCT) than the inner border of the choroidal vascular lumen (VCT) or sclera (TCT). In most cases, TCT was comparable to SCT in reliability since the boundaries are generally the same except in eyes where a suprachoroidal layer is clearly visible. We hypothesize that the VCT was much less reliable because it follows the irregular contour of the large choroidal vessels, rather than the smooth contour of the choroid stroma (SCT) or sclera (TCT). Our results also showed that choroidal thickness continuously averaged across the central 3mm of the macula on an EDI-OCT B-scan is more repeatable than at individual locations, likely due to a reduction in variance from the averaging process.

Interestingly, SCT was the most reproducible measure, particularly in eyes with ill-defined CSJ. This is important since the CSJ is often obscured on EDI-OCT in eyes with thicker choroid or pathological conditions, where choroidal thickness measurements can be less reliable.^{33,41,42} Although some studies exclude OCT images where the CSJ is poorly visible, doing so may result in selection bias for subjects with thinner choroid or eyes with less severe pathology.

The results of our study compare favorably to previous studies. Intergrader CRs in our study ranged from 41.40 μm for averaged SCT to 105.98 for subfoveal VCT, but decreased to as low as 26.22 μm when only clear images with well-defined CSJ (75% visibility) were included. These CR values are consistent with a previous report by Cho et al. which reported a range of CR from 27.8 μm for thin choroids to 106.4 μm for thick choroids where the CSJ may be less distinct.⁴¹ Of note, since the CR describes the smallest possible change in choroidal thickness measurements that represents a true change, studies that report choroidal thickness changes of only 10 – 20 μm may be of limited clinical relevance.

Our results showed small, but significant intergrader bias between observers for VCT only, but not SCT or TCT. This further supports the notion that the choroidal vessel lumen border is not a reliable boundary for choroidal thickness measurements.

The present study has several limitations. First, the study is a retrospective cross-sectional analysis to assess the reliability of image interpretation. Intervisit repeatability, which may take into account variations in scanning conditions and image acquisition, could not be assessed. Second, the use of custom segmentation software to manually trace the posterior boundary may be slightly different from other methods of manual choroidal thickness

measurements, such as caliper-drawing. Finally, our study intentionally did not exclude EDI-OCT images with reduced CSJ visibility, although this may be construed as a strength of the study in accounting for the variable appearance of the CSJ in real-world clinical use.

In conclusion, our study showed that choroidal thickness measurements using the border of the choroid stroma may be more reliable than the vessel lumen border or sclera, even in eyes without a clearly-defined CSJ. We recommend using the outer border of the choroid stroma as the posterior boundary, and averaging choroidal thickness from at least several locations in the area of interest in order to maximize the reliability of choroidal thickness measurements. Future studies may address whether these results are consistent in pathological eyes.

Supplementary Material

Refer to Web version on PubMed Central for supplementary material.

Acknowledgments

A. **Funding/Support:** VV is supported by the National Center for Advancing Translational Sciences and NIH UL1TR000002 and linked award TL1TR000133. GY is supported by the E. Matilda Ziegler Foundation for the Blind, Barr Foundation for Retinal Research, Alcon Research Institute, and NIH K08 EY026101. AM is supported by Research to Prevent Blindness and the International Retina Research Foundation. No funding organizations had any role in the design or conduct of this research. The content is solely the responsibility of the authors and does not necessarily represent the official views of the funding agencies.

B. **Financial Disclosures:** SF has patents pending in OCT imaging and analysis. VV, EM, DC, AM, and GY have no relevant financial disclosures.

C. **Contribution of Authors:** Design of the study (VV,EM,GY); Conduct of the study (VV, EM, DC, AM, GY); Data collection and management (VV, EM); Data analysis and interpretation (VV, EM, DC, SF, GY); Preparation of manuscript (VV, GY); Review and approval of manuscript (VV, EM, DC, SF, AM, GY).

References

1. Spaide RF, Koizumi H, Pozzoni MC. Enhanced depth imaging spectral-domain optical coherence tomography. *Am J Ophthalmol.* 2008; 146(4):496–500. [PubMed: 18639219]
2. Spaide RF. Age-related choroidal atrophy. *Am J Ophthalmol.* 2009; 147(5):801–810. [PubMed: 19232561]
3. Kim JH, Kang SW, Kim JR, Kim SJ. Variability of subfoveal choroidal thickness measurements in patients with age-related macular degeneration and central serous chorioretinopathy. *Eye (Lond).* 2013; 27(7):809–815. [PubMed: 23598679]
4. Maruko I, Iida T, Sugano Y, Ojima A, Ogasawara M, Spaide RF. Subfoveal choroidal thickness after treatment of central serous chorioretinopathy. *Ophthalmology.* 2010; 117(9):1792–1799. [PubMed: 20472289]
5. da Silva FT, Sakata VM, Nakashima A, et al. Enhanced depth imaging optical coherence tomography in long-standing Vogt-Koyanagi-Harada disease. *Br J Ophthalmol.* 2013; 97(1):70–74. [PubMed: 23099292]
6. Maruko I, Iida T, Sugano Y, Go S, Sekiryu T. Subfoveal Choroidal Thickness in Papillitis Type of Vogt-Koyanagi-Harada Disease and Idiopathic Optic Neuritis. *Retina.* 2015; 36(5):992–9.
7. Nakayama M, Keino H, Okada AA, et al. Enhanced depth imaging optical coherence tomography of the choroid in Vogt-Koyanagi-Harada disease. *Retina.* 2012; 32(10):2061–2069. [PubMed: 23095726]

8. Sigler EJ, Randolph JC. Comparison of macular choroidal thickness among patients older than age 65 with early atrophic age-related macular degeneration and normals. *Invest Ophthalmol Vis Sci*. 2013; 54(9):6307–6313. [PubMed: 23982844]
9. Jonas JB, Forster TM, Steinmetz P, Schlichtenbrede FC, Harder BC. Choroidal thickness in age-related macular degeneration. *Retina*. 2014; 34(6):1149–1155. [PubMed: 24220257]
10. Ueda-Arakawa N, Ooto S, Ellabban AA, et al. Macular choroidal thickness and volume of eyes with reticular pseudodrusen using swept-source optical coherence tomography. *Am J Ophthalmol*. 2014; 157(5):994–1004. [PubMed: 24491418]
11. Yiu G, Chiu SJ, Petrou PA, et al. Relationship of central choroidal thickness with age-related macular degeneration status. *Am J Ophthalmol*. 2015; 159(4):617–626. [PubMed: 25526948]
12. Adhi M, Brewer E, Waheed NK, Duker JS. Analysis of morphological features and vascular layers of choroid in diabetic retinopathy using spectral-domain optical coherence tomography. *JAMA Ophthalmol*. 2013; 131(10):1267–1274. [PubMed: 23907153]
13. Gerendas BS, Waldstein SM, Simader C, et al. Three-dimensional automated choroidal volume assessment on standard spectral-domain optical coherence tomography and correlation with the level of diabetic macular edema. *Am J Ophthalmol*. 2014; 158(5):1039–1048. [PubMed: 25127697]
14. Tsuiki E, Suzuma K, Ueki R, Maekawa Y, Kitaoka T. Enhanced depth imaging optical coherence tomography of the choroid in central retinal vein occlusion. *Am J Ophthalmol*. 2013; 156(3):543–547. e541. [PubMed: 23688711]
15. Kim H, Lee K, Lee CS, Byeon SH, Lee SC. Subfoveal choroidal thickness in idiopathic choroidal neovascularization and treatment outcomes after intravitreal bevacizumab therapy. *Retina*. 2015; 35(3):481–486. [PubMed: 25313710]
16. Unlu C, Erdogan G, Onal Gunay B, Sezgin Akcay BI, Kardes E. Subfoveal choroidal thickness changes after intravitreal bevacizumab therapy for neovascular age-related macular degeneration. *Int J Ophthalmol*. 2015; 8(4):849–851. [PubMed: 26309892]
17. Ting DS, Ng WY, Ng SR, et al. Choroidal Thickness Changes in Age-Related Macular Degeneration and Polypoidal Choroidal Vasculopathy: A 12-Month Prospective Study. *Am J Ophthalmol*. 2015; 164:128–136. e1. [PubMed: 26743619]
18. Razavi S, Souied EH, Darvizeh F, Querques G. Assessment of Choroidal Topographic Changes by Swept-Source Optical Coherence Tomography After Intravitreal Ranibizumab for Exudative Age-Related Macular Degeneration. *Am J Ophthalmol*. 2015; 160(5):1006–1013. [PubMed: 26275471]
19. Yiu G, Manjunath V, Chiu SJ, Farsiu S, Mahmoud TH. Effect of anti-vascular endothelial growth factor therapy on choroidal thickness in diabetic macular edema. *Am J Ophthalmol*. 2014; 158(4):745–751. e742. [PubMed: 24952275]
20. Alonso-Caneiro D, Read SA, Collins MJ. Automatic segmentation of choroidal thickness in optical coherence tomography. *Biomed Opt Express*. 2013; 4(12):2795–2812. [PubMed: 24409381]
21. Lin P, Mettu PS, Pomerleau DL, et al. Image inversion spectral-domain optical coherence tomography optimizes choroidal thickness and detail through improved contrast. *Invest Ophthalmol Vis Sci*. 2012; 53(4):1874–1882. [PubMed: 22410550]
22. Philip AM, Gerendas BS, Zhang L, et al. Choroidal thickness maps from spectral domain and swept source optical coherence tomography: algorithmic versus ground truth annotation. *Br J Ophthalmol*. 2016 Jan 14.
23. Tian J, Marziliano P, Baskaran M, Tun TA, Aung T. Automatic segmentation of the choroid in enhanced depth imaging optical coherence tomography images. *Biomed Opt Express*. 2013; 4(3):397–411. [PubMed: 23504041]
24. Zhang L, Lee K, Niemeijer M, Mullins RF, Sonka M, Abramoff MD. Automated segmentation of the choroid from clinical SD-OCT. *Invest Ophthalmol Vis Sci*. 2012; 53(12):7510–7519. [PubMed: 23060139]
25. Chen W, Song H, Xie S, Han Q, Tang X, Chu Y. Correlation of macular choroidal thickness with concentrations of aqueous vascular endothelial growth factor in high myopia. *Curr Eye Res*. 2015; 40(3):307–313. [PubMed: 25300046]

26. Dadaci Z, Alptekin H, Oncel Acir N, Borazan M. Changes in choroidal thickness during pregnancy detected by enhanced depth imaging optical coherence tomography. *Br J Ophthalmol*. 2015; 99(9): 1255–1259. [PubMed: 25710725]
27. Erol MK, Coban DT, Ozdemir O, Dogan B, Tunay ZO, Bulut M. Choroidal Thickness in Infants with Retinopathy of Prematurity. *Retina*. 2015; 36(6):1191–1198.
28. Kim JS, Knickelbein JE, Jaworski L, et al. Enhanced Depth Imaging Optical Coherence Tomography in Uveitis: An Intravital and Interobserver Reproducibility Study. *Am J Ophthalmol*. 2016; 164:49–56. [PubMed: 26829594]
29. Chung SE, Kang SW, Lee JH, Kim YT. Choroidal thickness in polypoidal choroidal vasculopathy and exudative age-related macular degeneration. *Ophthalmology*. 2011; 118(5):840–845. [PubMed: 21211846]
30. Falcao MS, Goncalves NM, Freitas-Costa P, et al. Choroidal and macular thickness changes induced by cataract surgery. *Clin Ophthalmol*. 2014; 8:55–60. [PubMed: 24368877]
31. Maruko I, Iida T, Oyamada H, Sugano Y, Saito M, Sekiryu T. Subfoveal choroidal thickness changes after intravitreal ranibizumab and photodynamic therapy for retinal angiomatous proliferation. *Retina*. 2015; 35(4):648–654. [PubMed: 25627088]
32. Adhi M, Ferrara D, Mullins RF, et al. Characterization of Choroidal Layers in Normal Aging Eyes Using Enface Swept-Source Optical Coherence Tomography. *PLoS One*. 2015; 10(7):e0133080. [PubMed: 26172550]
33. Yiu G, Pecan P, Sarin N, et al. Characterization of the choroid-scleral junction and suprachoroidal layer in healthy individuals on enhanced-depth imaging optical coherence tomography. *JAMA Ophthalmol*. 2014; 132(2):174–181. [PubMed: 24336985]
34. Chiu SJ, Li XT, Nicholas P, Toth CA, Izatt JA, Farsiu S. Automatic segmentation of seven retinal layers in SDOCT images congruent with expert manual segmentation. *Opt Express*. 2010; 18(18): 19413–19428. [PubMed: 20940837]
35. Bland JM, Altman DG. Statistical methods for assessing agreement between two methods of clinical measurement. *Lancet*. 1986; 1(8476):307–310. [PubMed: 2868172]
36. Vaz S, Falkmer T, Passmore AE, Parsons R, Andreou P. The case for using the repeatability coefficient when calculating test-retest reliability. *PLoS One*. 2013; 8(9):e73990. [PubMed: 24040139]
37. Margolis R, Spaide RF. A pilot study of enhanced depth imaging optical coherence tomography of the choroid in normal eyes. *Am J Ophthalmol*. 2009; 147(5):811–815. [PubMed: 19232559]
38. Fujiwara T, Imamura Y, Margolis R, Slakter JS, Spaide RF. Enhanced depth imaging optical coherence tomography of the choroid in highly myopic eyes. *Am J Ophthalmol*. 2009; 148(3): 445–450. [PubMed: 19541286]
39. Nishida Y, Fujiwara T, Imamura Y, Lima LH, Kurosaka D, Spaide RF. Choroidal thickness and visual acuity in highly myopic eyes. *Retina*. 2012; 32(7):1229–1236. [PubMed: 22466466]
40. Karaca EE, Ozdek S, Yalcin NG, Ekici F. Reproducibility of choroidal thickness measurements in healthy Turkish subjects. *Eur J Ophthalmol*. 2014; 24(2):202–208. [PubMed: 23934822]
41. Cho AR, Choi YJ, Kim YT. Medscape. Influence of choroidal thickness on subfoveal choroidal thickness measurement repeatability using enhanced depth imaging optical coherence tomography. *Eye (Lond)*. 2014; 28(10):1151–1160. [PubMed: 25214002]
42. Gupta P, Cheng CY, Cheung CM, et al. Relationship of ocular and systemic factors to the visibility of choroidal-scleral interface using spectral domain optical coherence tomography. *Acta Ophthalmol*. 2015; 94(2):e142–9. [PubMed: 26109294]

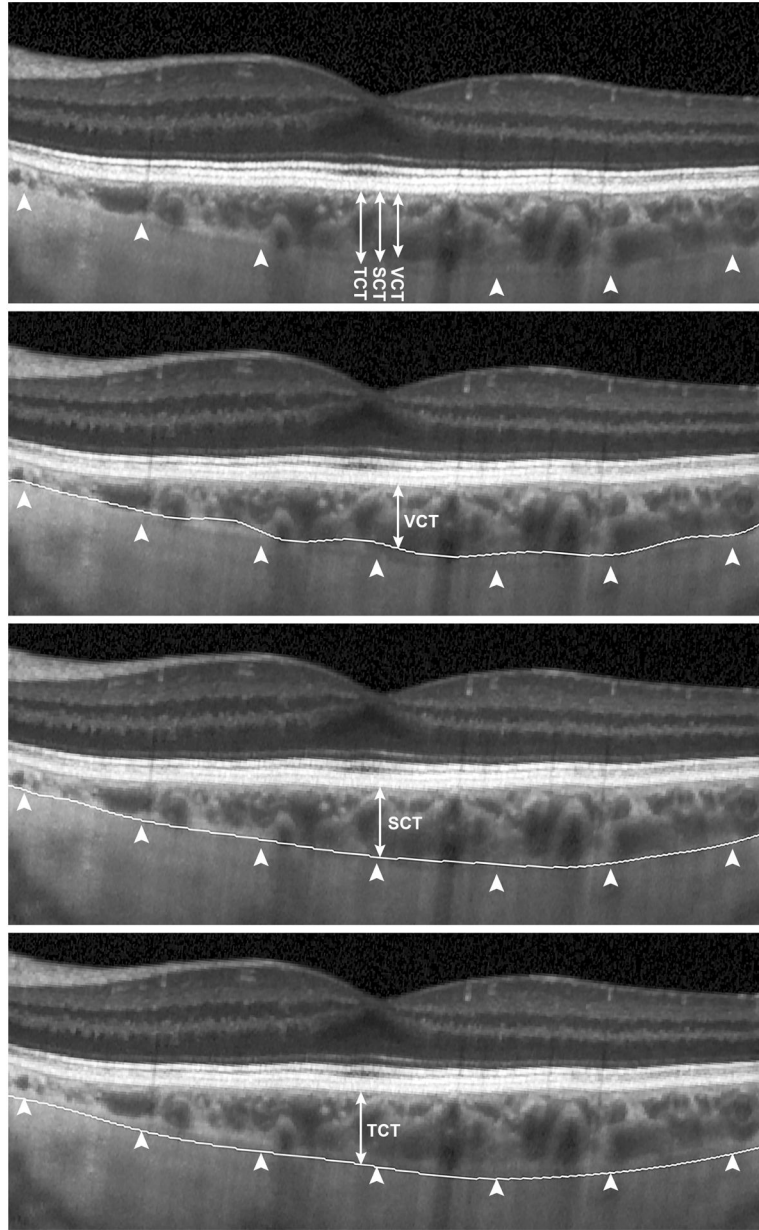


FIGURE 1. (Top) Images of horizontal enhanced-depth imaging ocular coherence tomography line scans through the fovea with 75% choroidal-scleral junction visibility and a visible suprachoroidal layer (arrowheads), using three different posterior boundaries (double-headed arrows) to segment and measure the (Upper center) vascular choroidal thickness (VCT), (Lower center) stromal choroidal thickness (SCT), and (Bottom) total choroidal thickness, TCT.

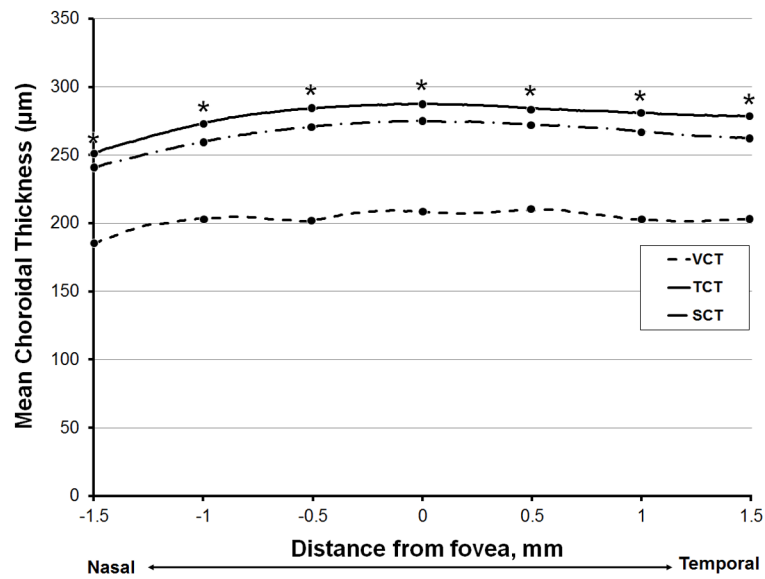


FIGURE 2. Line graph comparing averaged measurements of two masked graders for vascular choroidal thickness (VCT), stromal choroidal thickness (SCT), and total choroidal thickness (TCT) across the macula of all subjects. Asterisks indicate significant differences between the 3 measurements ($P < 0.05$).

Author Manuscript

Author Manuscript

Author Manuscript

Author Manuscript

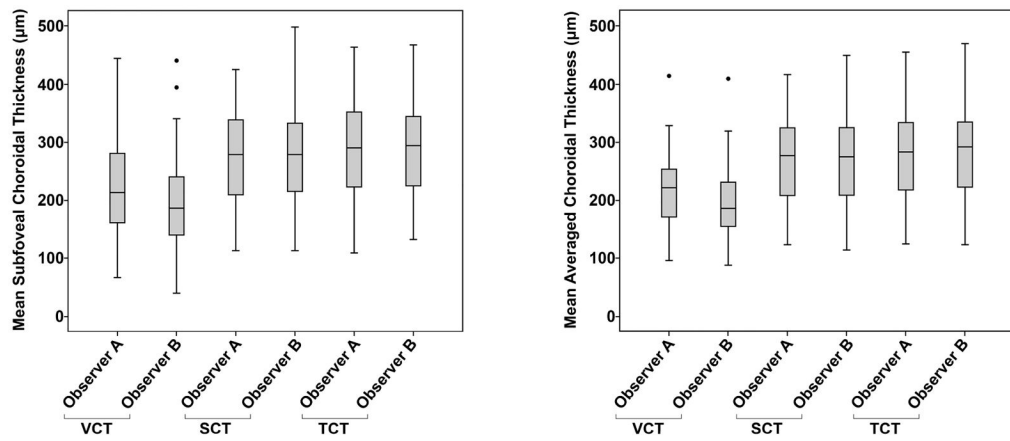


FIGURE 3. Box-and-whisker plots showing distribution of (Left) subfoveal and (Right) averaged vascular choroidal thickness (VCT), stromal choroidal thickness (SCT), and total choroidal thickness (TCT) measurements, between two independent observers (Observer A and Observer B).

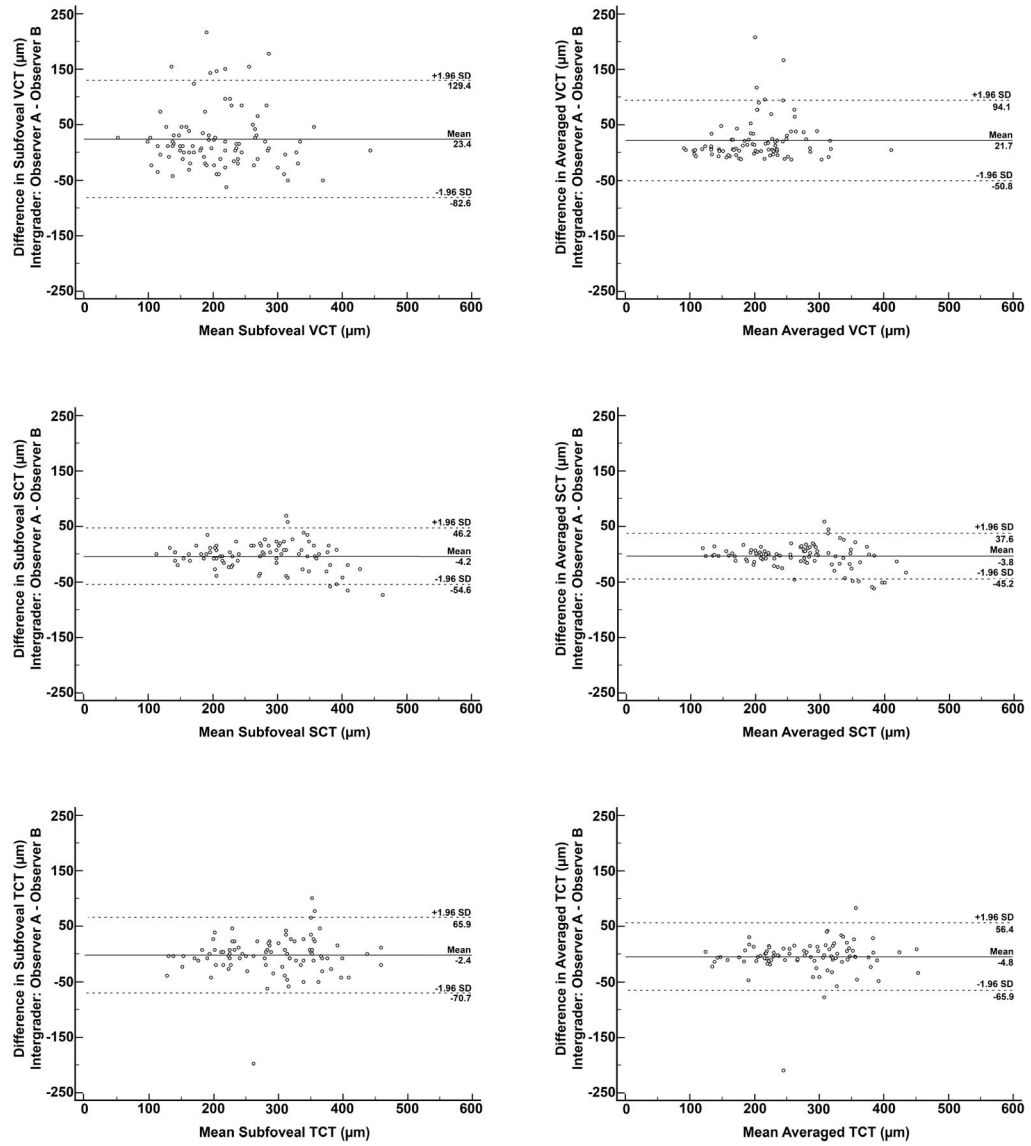


FIGURE 4. Bland-Altman plots of intergrader differences for mean subfoveal (Top left, center left, bottom left) and mean averaged (Top right, center right, bottom right) choroidal thickness using different posterior boundaries, including (Top left and top right) vascular choroidal thickness (VCT), (Center left and center right) stromal choroidal thickness (SCT), and (Bottom left and bottom right) total choroidal thickness (TCT) measurements. Solid lines: mean difference. Dashed lines: 95% limits of agreement.

TABLE 1

Demographics and clinical characteristics

	All eyes (n=91)	Eyes with 75% CSJ visible (n=52)	Eyes with <75% CSJ visible (n=39)
Age (years), mean \pm SD	56.77 \pm 17.58	58.52 \pm 18.03	54.44 \pm 16.92
Sex (male/female)	45/46	26/26	19/20
Eye (right/left)	45/46	26/26	19/20
Lens (phakic/pseudophakic)	81/10	46/6	35/4
Visual acuity (logMAR), mean \pm SD	0.116 \pm 0.156	0.125 \pm 0.183	0.104 \pm 0.110
IOP (mmHg), mean \pm SD	15.41 \pm 3.29	15.56 \pm 3.15	15.33 \pm 3.48
Refractive Error (diopters), mean \pm SD	-1.15 \pm 2.34	-1.62 \pm 2.57	-0.625 \pm 1.98

Abbreviations: CSJ, choroidal-scleral junction; IOP, intraocular pressure

Author Manuscript

Author Manuscript

Author Manuscript

Author Manuscript

TABLE 2

Summary of intergrader comparisons of choroidal thickness measurements using different posterior boundaries at different anatomic locations.

Location	VCT			SCT			TCT					
	Mean (SD) Difference (µm)	P-value	ICC	CR (µm)	Mean (SD) Difference (µm)	P-value	ICC	CR (µm)	Mean (SD) Difference (µm)	P-value	ICC	CR (µm)
1.5mm nasal	24.07 (57.09)	<0.001	0.786	111.90	-5.74 (27.18)	0.119	0.973	53.27	-8.59 (35.35)	0.227	0.953	69.29
1.0mm nasal	20.71 (58.51)	<0.001	0.750	114.68	-4.59 (27.83)	0.047	0.970	54.55	-3.61 (35.40)	0.332	0.952	69.38
0.5mm nasal	28.15 (58.73)	<0.001	0.752	115.11	-2.51 (31.47)	0.119	0.959	61.68	-2.38 (36.61)	0.536	0.945	71.76
subfoveal	23.43 (54.07)	<0.001	0.827	105.98	-4.21 (25.72)	0.449	0.973	50.41	-2.38 (34.84)	0.516	0.947	68.29
0.5mm temporal	24.07 (53.12)	<0.001	0.818	104.11	-3.57 (31.79)	0.287	0.959	62.31	-4.30 (37.82)	0.282	0.963	74.13
1.0mm temporal	21.43 (51.31)	<0.001	0.823	100.57	-2.64 (24.85)	0.314	0.972	48.71	-6.93 (36.62)	0.074	0.934	71.78
1.5mm temporal	12.38 (49.15)	<0.001	0.860	96.33	-3.70 (27.24)	0.198	0.964	53.39	-7.74 (37.88)	0.054	0.928	74.24
averaged	21.65 (36.96)	<0.001	0.869	72.44	-3.77 (21.12)	0.092	0.980	41.40	-4.76 (31.19)	0.149	0.954	61.13

Abbreviations: CR, coefficient of repeatability; ICC, intraclass correlation; SCT, stromal choroidal thickness; TCT, total choroidal thickness; VCT, vascular choroidal thickness.

TABLE 3

Summary of intergrader comparisons of choroidal thickness measurements using different posterior boundaries based on visibility of choroidal-scleral junction.

Location	VCT			SCT			TCT					
	Mean (SD) Difference (µm)	P-value	ICC	CR (µm)	Mean (SD) Difference (µm)	P-value	ICC	CR (µm)	Mean (SD) Difference (µm)	P-value	ICC	CR (µm)
75% Choroidal-Scleral Junction (CSJ) Visibility												
subfoveal	13.55 (34.72)	0.007	0.900	68.05	3.65 (19.63)	0.122	0.986	38.47	-1.12 (27.25)	0.769	0.957	53.41
averaged	11.15 (18.22)	<0.001	0.954	35.71	1.51 (13.28)	0.416	0.986	26.03	-1.04 (19.36)	0.700	0.974	37.95
<75% Choroidal-Scleral Junction (CSJ) Visibility												
subfoveal	36.62 (70.68)	0.003	0.753	138.53	-14.69 (29.19)	0.003	0.953	57.21	-4.07 (43.28)	0.561	0.891	84.83
averaged	35.67 (49.36)	<0.001	0.768	96.75	-10.81 (27.03)	0.017	0.958	52.98	-9.71 (41.92)	0.156	0.890	82.16

Abbreviations: CR, coefficient of repeatability; ICC, intraclass correlation; SCT, stromal choroidal thickness; TCT, total choroidal thickness; VCT, vascular choroidal thickness.