

# UC Davis

## Dermatology Online Journal

### Title

Bevacizumab-induced subungual hemorrhage

### Permalink

<https://escholarship.org/uc/item/9107p3v4>

### Journal

Dermatology Online Journal, 30(5)

### Authors

Owen, Jacob J

Long, Sloan

Mullinax, Kimberly

et al.

### Publication Date

2024

### DOI

10.5070/D330564427

### Copyright Information

Copyright 2024 by the author(s). This work is made available under the terms of a Creative Commons Attribution-NonCommercial-NoDerivatives License, available at

<https://creativecommons.org/licenses/by-nc-nd/4.0/>

Peer reviewed

# Bevacizumab-induced subungual hemorrhage

Jacob J Owen<sup>1</sup> BA, Sloan Long<sup>1</sup> MS, Kimberly Mullinax<sup>2</sup> MD, John Griffin<sup>2,3</sup> MD

Affiliations: <sup>1</sup>Texas A&M School of Medicine, Dallas, Texas, USA, <sup>2</sup>Kelsey Seybold Clinic-Dermatology, Houston, Texas, USA, <sup>3</sup>Texas A&M School of Medicine, Houston, Texas, USA

Corresponding Author: John Griffin MD, Kelsey-Seybold Clinic, 9110 Katy Fwy, Houston, TX 77055, Tel: 713-442-6900, Email: [John.Griffin@kelsey-seybold.com](mailto:John.Griffin@kelsey-seybold.com)

## Abstract

Exudative (wet) age-related macular degeneration can be treated with the vascular endothelial growth factor (VEGF)-inhibiting monoclonal antibody bevacizumab. Currently, bevacizumab therapy is associated with known skin-related side effects, such as rash, mucosal hemorrhage, and hemorrhagic ulcers. While subungual “splinter” hemorrhage is a documented side effect of VEGF receptor antagonists and Raf protein inhibitors, there are no prior reports of bevacizumab-induced subungual hemorrhage to the best of our knowledge. Thus, we present the case of a 71-year-old female diagnosed with bilateral age-related macular degeneration, who, during six months of intravitreal bevacizumab treatment, began noticing fingernail discoloration, described as similar to that of a bruise. Given our patient’s history of bevacizumab therapy and the documented reports of bevacizumab-associated mucosal and ulcerative hemorrhage, we hypothesize that the discoloration and hemorrhage are likely unreported adverse effects associated with bevacizumab therapy.

*Keywords: bevacizumab, macular degeneration, subungual hemorrhage*

## Introduction

Age-related macular degeneration (AMD) includes two subtypes: nonexudative (dry) and exudative (wet). Nonexudative AMD is more common and is characterized by subretinal deposition of lipids and drusen. Patients experience gradual vision loss related to progressive atrophy of the retinal pigment

epithelium. Exudative AMD is characterized by neovascularization of the choroid, a layer between the retina and sclera, which leads to bleeding and subretinal fluid leakage. Patients experience rapid loss of central vision and metamorphopsia, which is the distortion of straight grid lines appearing wavy or warped [1]. Fundamental to the pathophysiology of exudative AMD is the aberrant signaling of vascular endothelial growth factor (VEGF). VEGF signals vascular endothelial cells to proliferate, leading to blood vessel branching and the formation of new networks. The treatment of exudative AMD involves intravitreal injections with bevacizumab, a recombinant monoclonal antibody (IgG<sub>1</sub>) that binds all circulating isoforms of VEGF [2]. By blocking VEGF from binding to its receptor, bevacizumab inhibits endothelial cell proliferation and angiogenesis of retinal vasculature, preventing further vision loss [3]. Bevacizumab, like any other drug, has a number of side effects, including dermatologic adverse reactions (**Table 1**). These include rash, delayed wound healing, mucosal bleeding, and hemorrhagic ulcers [2,4,5]. We present a patient with subungual hemorrhage being treated for exudative AMD with bevacizumab.

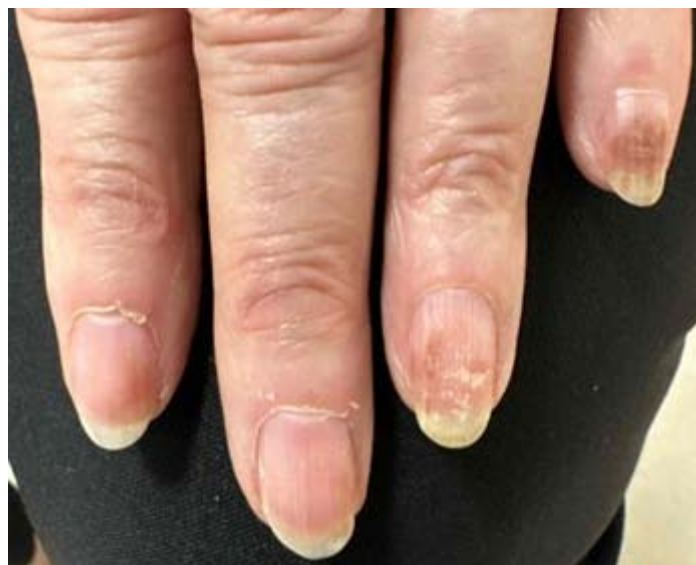## Case Synopsis

A 71-year-old woman presented to the dermatology clinic with discoloration beneath her fingernails that she described as appearing “similar to a bruise.” In 2019, she received a diagnosis of idiopathic choroidal neovascular membrane in her left eye following the identification of exudation and submacular hemorrhage. Intravitreal bevacizumab

**Table 1.** Known cutaneous side effects of bevacizumab.

Bevacizumab side effects	
Maculopapular eruption	Papulopustular rash
Mucosal hemorrhage [1,2]	Ulceration of striae
Disturbed wound healing [1]	Perforating folliculitis
Facial skin redness	Perforating dermatosis
Exanthem	Hand-foot syndrome
Exfoliative dermatitis	Hemorrhagic ulcers [5]

injections effectively controlled the bleeding, allowing discontinuation of bevacizumab therapy without recurrence of hemorrhage. However, eight months later, the patient began experiencing blurry vision in her right eye, ultimately leading to a diagnosis of bilateral exudative age-related macular degeneration. This prompted the resumption of bevacizumab injections, now in both eyes. Once again, the hemorrhage stabilized with treatment and therapy was withdrawn, only for the hemorrhage to return three years later. Bilateral bevacizumab 1.25mg injection therapy was resumed again in three dose cycles, but this time with increased injection frequency every 4-6 weeks. Six months into the patient's third round of treatment, she noticed discoloration on her fingernails after receiving an increased dose of 2.5mg bilaterally. She denied tapping, hitting, or otherwise traumatizing her nails. Although the proximal 3-4mm of all nails appeared normal, digits three through five on the left hand and digits four and five on the right displayed a muddy



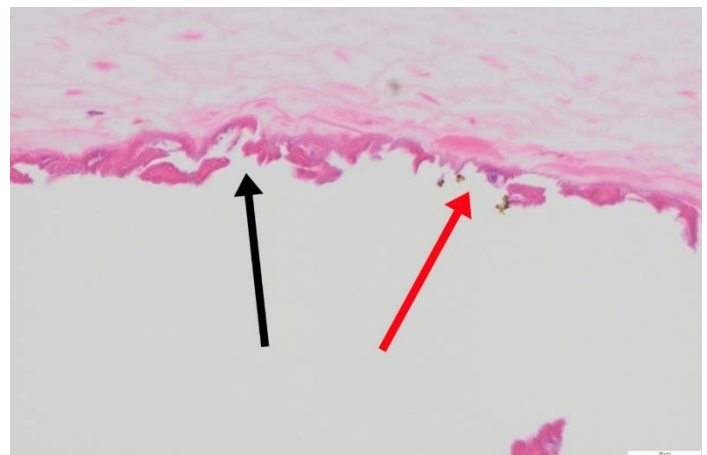
**Figure 1.** Poorly defined, muddy brown subungual pigment including longitudinal splinters can be seen on the distal nails of multiple digits.

brown discoloration consistent with hemorrhage distally, showing longitudinal splinters along with areas suggesting red cell extravasation beyond the rete ridges (**Figure 1**). Notably, no nail thickening, subungual hyperkeratosis (onychauxis), or other pertinent findings were observed. Microscopic examination of a nail clipping revealed hemosiderin deposition on the underside of the nail plate, consistent with findings of subungual hemorrhage (**Figure 2**).

### Case Discussion

Bevacizumab is a monoclonal antibody that binds circulating isoforms of VEGF, preventing it from binding to extracellular receptor tyrosine kinases. This results in irregular vascular permeability and a reduction in the number of endothelial cells and capillaries [2]. Bevacizumab is often combined with other neoplastic agents to treat lung, breast, and colorectal cancers, as well as glioblastoma multiforme and renal cell carcinoma [2,5]. Although bevacizumab is an efficacious chemotherapy drug, it is associated with many adverse effects, including nephrotic syndrome, hypertension, congestive heart failure, epistaxis, wound dehiscence, thromboembolism, and gastrointestinal tract perforation [4,5].

Besides trauma, subungual splinter hemorrhage is traditionally linked to bacterial endocarditis and manifests as longitudinal lines or clusters of red,



**Figure 2.** Small collections of golden brown, round pigment that are adherent to the underside of the nail plate, H&E, 60x. Black arrow: underside of the nail plate. Red arrow: pigment globules.

black, and brown pigmentation. This is due to blood extravasated from papillary dermal vessels [6, 7]. In addition to endocarditis, this may occur due to trauma, vasculitides, fungal infections, diabetes, and medications. Common drug classes associated with subungual hemorrhage are listed in **Table 2**. With regard to medications that affect angiogenesis and the VEGF pathway, various potential mechanisms exist that may cause the associated side effects of hemorrhage, abnormal wound healing, and thrombosis. These underlying mechanisms may include direct injury to endothelial cells, platelet dysfunction, or decreased expression of endothelial tissue factor [5,6,7]. The tyrosine kinase inhibitors sunitinib and sorafenib have also been shown to induce apoptosis of vascular endothelial cells, resulting in blood vessel damage [2,6]. In addition, blocking the VEGF pathway may lead to deficient renewal of endothelial cells and an inability to repair damaged blood vessels [5,6,7]. This principle is particularly important when considering the spiral capillaries beneath fingernails, which are prone to frequent microinjuries. We propose that bevacizumab damages vascular endothelial cells in the nail bed and prevents endothelial cell renewal, leading to vessel instability, subungual hemorrhage, and an inability to repair nail-bed capillaries. This hypothesis is supported by multiple documented cases of VEGF receptor antagonists sunitinib and sorafenib causing distal subungual splinter

**Table 2.** Other drugs associated with subungual hemorrhage.

Drug class	Examples	
VEGF receptor inhibitors	Sorafenib	Sunitinib
Antiplatelet agents	Clopidogrel	Ticagrelor
Anticoagulants	Warfarin	Dabigatran
Taxanes	Paclitaxel	Docetaxel
Tetracyclines	Tetracycline	Doxycycline
Other	Zolpidem	Ganciclovir
	Nitrofurantoin	Terbinafine

hemorrhage [2,6,7]. Furthermore, imatinib and cabozantinib, which inhibit multiple tyrosine kinase receptors, have also been associated with subungual hemorrhage [6,8]. As bevacizumab treatment has been described to cause mucosal bleeding and hemorrhagic ulcers, we suspect that the subungual hemorrhage observed in this patient is likely an adverse cutaneous effect of bevacizumab [4,5].

## Conclusion

This patient's fingernail discoloration was consistent with subungual splinter hemorrhage, representing an adverse effect of intravitreal bevacizumab injection therapy. We propose that subungual hemorrhage be considered a potential adverse effect associated with this drug.

## Potential conflicts of interest

The authors declare no conflicts of interest.

## References

1. Thomas CJ, Mirza RG, Gill MK. Age-related macular degeneration. *Med Clin North Am.* 2021;105:473-491. [PMID: 33926642].
2. Wozel G, Sticherling M, Schön MP. Cutaneous side effects of inhibition of VEGF signal transduction. *J Dtsch Dermatol Ges.* 2010;8:243-249. [PMID: 19832927].
3. Garcia J, Hurwitz HI, Sandler AB, et al. Bevacizumab (Avastin®) in cancer treatment: A review of 15 years of clinical experience and future outlook. *Cancer Treat Rev.* 2020;86:102017. [PMID: 32335505].
4. Hapani S, Sher A, Chu D, Wu S. Increased risk of serious hemorrhage with bevacizumab in cancer patients: a meta-analysis. *Oncology.* 2010;79:27-38. [PMID: 21051914].
5. Kiuru M, Schwartz M, Magro C. Cutaneous thrombogenic vasculopathy associated with bevacizumab therapy. *Dermatol Online J.* 2014;20:13030/qt41f655g9. [PMID: 24945646].
6. Robert C, Faivre S, Raymond E, Armand JP, Escudier B. Subungual splinter hemorrhages: a clinical window to inhibition of vascular endothelial growth factor receptors? *Ann Intern Med.* 2005;143:313-314. [PMID: 16103482].
7. Verheul HM, Pinedo HM. Possible molecular mechanisms involved in the toxicity of angiogenesis inhibition. *Nat Rev Cancer.* 2007;7:475-485. [PMID: 17522716].
8. Zuo RC, Apolo AB, DiGiovanna JJ, et al. Cutaneous adverse effects associated with the tyrosine-kinase inhibitor cabozantinib. *JAMA Dermatol.* 2015;151:170-177. [PMID: 25427282].