

UC Davis

UC Davis Previously Published Works

Title

Fusarium Solani Infection Following Burn Injury: A Case Report.

Permalink

<https://escholarship.org/uc/item/91r677jx>

Journal

World journal of plastic surgery, 8(3)

ISSN

2228-7914

Authors

Goussous, Naeem

Abdullah, Anas

Milner, Stephen

Publication Date

2019-09-01

DOI

10.29252/wjps.8.3.406

Peer reviewed

Fusarium Solani Infection Following Burn Injury: A Case Report

Naeem Goussous*, Anas Abdullah, Stephen M. Milner

Johns Hopkins Burn Center, Michael D.
Hendrix Burn Research Center, Johns Hopkins
University School of Medicine, Baltimore, USA

ABSTRACT

Fungal infections are becoming increasingly recognized among burn patients. Infection with *Fusarium*, a filamentous mold, is rarely encountered and mainly seen in immunocompromised patients. High mortality and morbidity were reported with these virulent infections. We present a rare case of refractory septic shock from upper extremity fungal infection with *Fusarium solani* in a burn patient. Multiple operative debridements and below elbow amputation caused resolution of septic shock. Closure was achieved with a split thickness skin graft. Aggressive approach should be adopted in managing burn patients with *Fusarium* infection. Serial debridements and extremity amputation should be considered in attempts to improve survival.

KEYWORDS

Fusarium solani; Fungus; Mold; Infection; Burn

Please cite this paper as:

Goussous N, Abdullah A, Milner SM. *Fusarium Solani* Infection Following Burn Injury: A Case Report. World J Plast Surg 2019;8(3):406-409. doi: 10.29252/wjps.8.3.406.

INTRODUCTION

Fusarium is a saprophytic filamentous mold found ubiquitously in the soil and water. Infection with this organism has been reported in patients with suppressed immunity in conditions including: leukemia, lymphoma, aplastic anemia, and those on chemotherapy. *Fusarium solani* is the most frequently isolated species, where high mortality rates have been associated ranging from 40-50%. Burned skin acts as a portal for entry of fungi and the impaired immune status facilitates deep invasion.¹

The practice of early excision of burn wounds and the application of topical antibacterial agents have led to decreased incidence of bacterial wound infections. Despite these advances, the incidence of fungal infections continues to be unchanged.²⁻⁵ *Candida* species have been the most commonly cultured organisms; although non-candidal infections are associated with a higher risk of tissue invasiveness and mortality.⁶ A recent study from Australia demonstrated a 25% mortality rate in burn patients with non-candidal mold infection despite aggressive therapy with systemic antifungal agents and surgical debridement.⁷ Reports of infections with *Fusarium* are sparse in the literature. We present a case of cutaneous fusarial infection in a patient who sustained severe burn injury.

*Corresponding Author:

Naeem Goussous, MD;
Department of General Surgery,
Transplant Division,
University of Maryland School of
Medicine, 29 Greene St., Suite 200,
Baltimore, MD 21201, USA.

Tel: +1-410-328-6016

Fax: +1- 410-328-6343

Email: n_goussous@hotmail.com

Received: October 16, 2018

Revised: August 11, 2019

Accepted: August 20, 2019

CASE REPORT

A 55-year-old male presented initially to an outside facility after being found unconscious in a house fire. He sustained a 35% total body surface area (TBSA) full thickness burn to his back, upper chest and bilateral upper extremities along with an inhalational injury. His carboxy hemoglobin at presentation was 28.9%. He was intubated, resuscitated and treated with hyperbaric oxygen. After 48 hours post-injury, the patient was transferred to our facility. Examination revealed bilateral swollen upper extremities with compartment syndrome from circumferential deep burns.

Escharotomies were performed promptly at the bedside. The patient developed a fever with leukocytosis. *H. influenzae* and *S. aureus* were isolated from sputum and blood, respectively. He was started on piperacillin/tazobactam and vancomycin. He then underwent staged excision of his burn wounds. Twelve days after admission, he developed septic shock and acute kidney injury requiring hemodialysis. Examination of the wounds in the left upper extremity revealed friable tissues with blackish discoloration of the underlying deep tissues and muscles with a yellowish discharge and a bad odor.

Following further operative debridement and exploration the interossei muscles and the extensors of the forearm were necrotic (Figures 1 and 2). Initial results of the tissue cultures showed an unspecified mold, and the patient was treated with voriconazole. The mold was subsequently identified as *F. solani* (Figure 3). Despite the initiation of antifungal therapy and aggressive operative debridement, the patient's condition continued to worsen; his white cell count continued to rise and peaked at 30,000 and the vasopressor requirement continued to escalate.

After further examination, the forearm deemed to be unsalvageable and due to concerns of worsening septic shock with the risk of hematogenous dissemination of the mold, he underwent left below elbow amputation and placement of a split thickness skin graft. Soon after the surgery, his clinical status showed remarkable improvement enabling weaning the vasopressor support and resolution of his sepsis. The rest of his hospital course was uneventful, the left upper extremity stump showed successful recovery and engraftment (Figure 4). He was

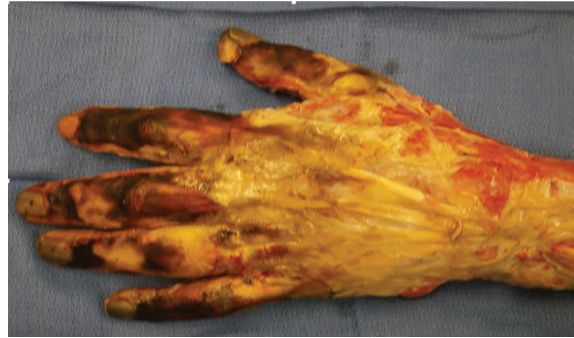

Fig. 1: Intra-operative image of the left hand and distal forearm, extensor aspect.

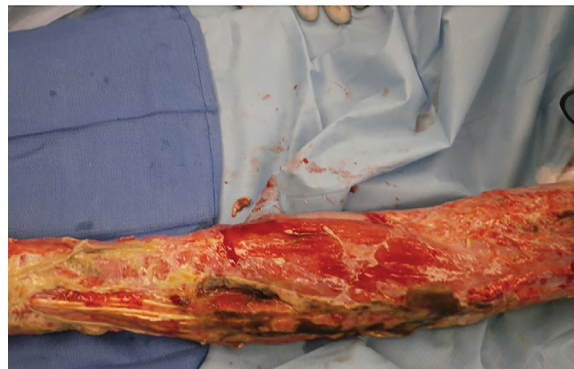


Fig. 2: Intra-operative picture of the left forearm, dorsal aspect, showing necrosis around the extensor tendons.

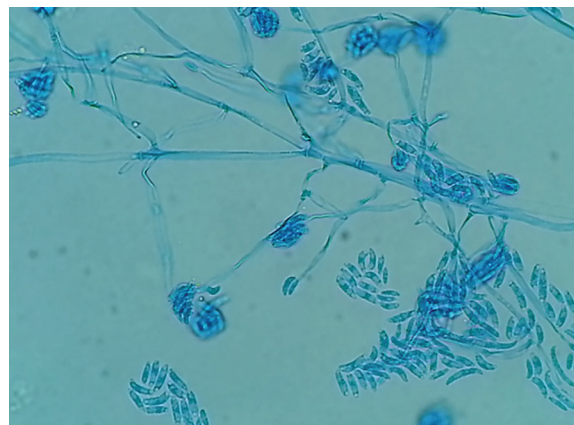

Fig. 3: *F. solani* under light microscopy with a lactophenol cotton blue stain.

discharged to an inpatient rehabilitation center for further physical therapy.

DISCUSSION

Fusarium infections are mainly encountered in immunocompromised patients. These infections are limited to a few case reports and small case series with an incidence of 0.06-1.4% of fungal infected burn wounds.^{7,8} All cases shared a rapidly progressive deterioration in

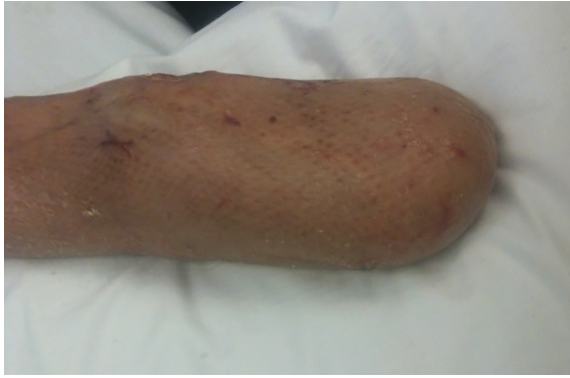

Fig. 4: Appearance of the left upper stump at discharge.

the clinical status with aggressive deep tissue invasion, progression of necrosis and distant dissemination. The mortality was almost universal.⁹⁻¹¹ Diagnosis of these infections begins by having a high clinical suspicion. Several risk factors have been identified that predispose to develop invasive fungal infections including increasing burned TBSA, length of hospital stay, polymicrobial infections and the presence of inhalational injury.^{4,5}

Tissue biopsy should be obtained immediately for both tissue culture and histopathological examination. Vascular invasion with thrombosis and tissue necrosis has been observed with fusarial infections. On microscopic examination, there was a close similarity between *Aspergillus* and *Fusarium*. The identification of *F. solani* can be challenging and may take up to 5-7 days to speciate. The addition of PCR can aid in the diagnosis.^{12,13} Treatment of fusarial infections center on surgical debridement and initiation of antifungal therapy. Early and aggressive surgical excision of all necrotic tissues is paramount.¹

The initiation of antifungal therapy should be prompt and started as soon as the fungus is identified on light microscopy and before awaiting further speciation. Amphotericin B or voriconazole as a monotherapy has been shown to have equivalent success rates. Barret *et al.* reported eradication of deep and superficial angioinvasive fungal infections with the use of topical nystatin at a concentration of 6,000,00 units/g in four pediatric burn patients.¹⁴ Invasive fungal infections are fortunately uncommon in our unit. The early excision of burns, restricted use of prophylactic antibiotics and administration of fluconazole in burns >40%

may be responsible for our low rate.¹⁵

CONFLICT OF INTEREST

The authors declare no conflict of interest.

REFERENCES

- 1 Muhammed M, Anagnostou T, Desalermos A, Kourkoupetis TK, Carneiro HA, Glavis-Bloom J, Coleman JJ, Mylonakis E. Fusarium infection: report of 26 cases and review of 97 cases from the literature. *Medicine (Baltimore)* 2013;**92**:305-16. doi: 10.1097/MD.0000000000000008.
- 2 Branski LK, Al-Mousawi A, Rivero H, Jeschke MG, Sanford AP, Herndon DN. Emerging infections in burns. *Surg Infect (Larchmt)* 2009;**10**:389-97. doi: 10.1089/sur.2009.024.
- 3 Struck MF, Gille J. Fungal infections in burns: a comprehensive review. *Ann Burns Fire Disasters* 2013;**26**:147-53.
- 4 Pasalar M, Mohammadi AA, Rajaeefard A, Neghab M, Tolidie H, Mehrabani D. Epidemiology of burns during pregnancy in southern Iran: Effect on maternal and fetal outcomes. *World Appl Sci J* 2013;**28**:153-8.
- 5 Murray CK, Loo FL, Hospenthal DR, Cancio LC, Jones JA, Kim SH, Holcomb JB, Wade CE, Wolf SE. Incidence of systemic fungal infection and related mortality following severe burns. *Burns* 2008;**34**:1108-12. doi: 10.1016/j.burns.2008.04.007.
- 6 Manafi A, Kohanteb J, Mehrabani D, Japoni A, Amini M, Naghmachi M, Zaghi AH, Khalili N. Active immunization using exotoxin A confers protection against *Pseudomonas aeruginosa* infection in a mouse burn model. *BMC Microbiol* 2009;**9**:23. doi: 10.1186/1471-2180-9-23.
- 7 Katz T, Wasiak J, Cleland H, Padiglione A. Incidence of non-candidal fungal infections in severe burn injury: an Australian perspective. *Burns* 2014;**40**:881-6. doi: 10.1016/j.burns.2013.11.025.
- 8 Capoor MR, Gupta S, Sarabahi S, Mishra A, Tiwari VK, Aggarwal P. Epidemiological and clinico-mycological profile of fungal wound infection from largest burn centre in Asia. *Mycoses* 2012;**55**:181-8. doi: 10.1111/j.1439-0507.2011.02065.x.
- 9 Abramowsky CR, Quinn D, Bradford WD,

- Conant NF. Systemic infection by fusarium in a burned child. The emergence of a saprophytic strain. *J Pediatr* 1974;**84**:561-4. doi: 10.1016/s0022-3476(74)80681-5.
- 10 Keshavarzi A, Kardeh S, Dehghankhalili M, Varahram MH, Omidi M, Zardosht M, Mehrabani D. Mortality and Body Mass Index in Burn Patients: Experience from a Tertiary Referral Burn Center in Southern Iran. *World J Plast Surg* 2019;**8**:382-7. doi: 10.29252/wjps.8.3.382.
- 11 Latenser BA. Fusarium infections in burn patients: a case report and review of the literature. *J Burn Care Rehabil* 2003;**24**:285-8. doi: 10.1097/01.BCR.0000085845.20730.AB.
- 12 Nucci M, Anaissie E. Fusarium infections in immunocompromised patients. *Clin Microbiol Rev* 2007;**20**:695-704. doi: 10.1128/CMR.00014-07.
- 13 White PL, Perry MD, Barnes RA. An update on the molecular diagnosis of invasive fungal disease. *FEMS Microbiol Lett* 2009;**296**:1-10. doi: 10.1111/j.1574-6968.2009.01575.x.
- 14 Barret JP, Ramzy PI, Hegggers JP, Villareal C, Herndon DN, Desai MH. Topical nystatin powder in severe burns: a new treatment for angioinvasive fungal infections refractory to other topical and systemic agents. *Burns* 1999;**25**:505-8. doi: 10.1016/s0305-4179(99)00037-6.
- 15 Pelz RK, Hendrix CW, Swoboda SM, Diener-West M, Merz WG, Hammond J, Lipsett PA. Double-blind placebo-controlled trial of fluconazole to prevent candidal infections in critically ill surgical patients. *Ann Surg* 2001;**233**:542-8. doi: 10.1097/00000658-200104000-00010.