UCLA
UCLA Previously Published Works

Title
A Female Patient with Down Syndrome and Low-Penetrance Leber's Hereditary Optic Neuropathy

Permalink
https://escholarship.org/uc/item/9536z12f

Journal
Case Reports in Ophthalmology, 5(3)

ISSN
1663-2699

Authors
Frousiakis, Starleen E
Pouw, Andrew E
Karanjia, Rustum
et al.

Publication Date
2014

DOI
10.1159/000369612

Peer reviewed

eScholarship.org Powered by the California Digital Library
University of California

Case Reports in Ophthalmology

Case Rep Ophthalmol 2014;5:405–410

DOI: 10.1159/000369612
Published online: November 27, 2014

© 2014 S. Karger AG, Basel
1663–2699/14/0053–0405$39.50/0
www.karger.com/cop

Karger Open access

This is an Open Access article licensed under the terms of the Creative Commons Attribution-NonCommercial 3.0 Unported license (CC BY-NC) (www.karger.com/OA-license), applicable to the online version of the article only. Distribution permitted for non-commercial purposes only.

A Female Patient with Down Syndrome and Low-Penetrance Leber's Hereditary Optic Neuropathy

Starleen E. Frousiakis[a] Andrew E. Pouw[a] Rustum Karanjia[b] Alfredo A. Sadun[b]

[a]Keck School of Medicine, University of Southern California, and [b]DOHENY Eye Centres UCLA, Los Angeles, Calif., USA

Key Words
Neuro-ophthalmology · Optic neuropathy · Leber's hereditary optic neuropathy · Down Syndrome · Mitochondria · Oxidative stress

Abstract
We present the case of a 19-year-old female with a history of Down syndrome (DS) who was referred to our neuro-ophthalmology clinic for evaluation of Leber's hereditary optic neuropathy (LHON). The patient's family history was significant for a known G11778A mutation in a maternal relative, consistent with LHON. The patient was also positive for the G11778A mutation; however, the genotype demonstrated low penetrance in the pedigree, with only 1 out of 10 adult male offspring showing signs or symptoms of the disease. Mitochondrial mutations implicated in LHON have been shown to impair complex I of the electron transport chain and thereby reducing the effective generation of adenosine triphosphate and increasing the production of toxic reactive oxygen species. Although the partial or complete triplicate of chromosome 21 constitutes the etiology of DS, some of the pleiotropic phenotypes of the syndrome have been attributed to oxidative stress and mitochondrial dysfunction. Given the low penetrance of the mutation and the patient's sex, this case illustrates the possibility that the mitochondrial mutation demonstrated increased penetrance due to pre-existing mitochondrial dysfunction related to DS. © 2014 S. Karger AG, Basel

Introduction

Leber's hereditary optic neuropathy (LHON) is a debilitating, blinding mitochondrial disease with subacute onset and rapid progression at a young age. The 3 most common

Starleen E. Frousiakis
Keck School of Medicine
University of Southern California
1975 Zonal Avenue, Los Angeles, CA 90098 (USA)
E-Mail whitt@usc.edu

mutations of LHON, including those at mtDNA positions 11778, 3460 and 14484, account for approximately 95% of cases worldwide, and affect different subunits of complex I, the first complex of the electron transport chain [1]. The most common locus is 11778/ND4. Dysfunction of the complex I molecule may inhibit specific cellular mechanisms, including the generation of adenosine triphosphate via oxidative phosphorylation, the biosynthesis of amino acids and the reduction of cytotoxic reactive oxygen species [2]. These deficits appear to preferentially reduce the viability of retinal ganglion cells, thereby leading to the clinical findings of retinal nerve fiber layer thinning, although the precise mechanism of this phenomenon remains an area of contention. Carriers of a known mtDNA mutation may never express symptoms of the disease, as factors affecting penetrance include heteroplasmy, environmental influences, the mitochondrial background as well as nuclear modifying genes [3]. In the pathogenesis of Down syndrome (DS), Valenti et al. [4] described mitochondrial dysfunction as a result of a defect in the oxidative phosphorylation machinery, specifically related to a defect in the complex I molecule. Indeed, recent investigations have demonstrated that reduced visual acuity and retinopathy are frequent in DS [5]. In this case, a patient with concomitant DS expressed a low-penetrance familial mutation, the 11778/ND4 genotype, raising the possibility that underlying mitochondrial dysfunction in DS lowers the threshold for expression of the LHON phenotype.

Case Presentation

Prior to visiting our clinic, a 19-year-old female with a history of DS presented to an outside ophthalmology clinic for the evaluation of reduced visual acuity. Based on the observations by her family members, the patient had a 1-year history of a marked decrease in 'visual activities'. The patient's past medical history was significant for DS and sensorineural hearing loss. It was also notable for duodenal atresia repair 10 years prior to presentation. Her family history was significant for only 1 male cousin with LHON. One unaffected member of the extended family had previously undergone documented genetic testing for the LHON mutation, which revealed that a sister of the patient's grandmother was a carrier of the 11778 mutation. Additionally, several maternal relatives of the patient reported positivity for the mutation, although evidence from previous genetic analysis could not be found. Given that all maternal offspring would be expected to be carriers of the disease, there were 25 unaffected carriers of the mutation, of which 9 were male heirs (fig. 1) [6].

The patient was referred to our clinic approximately 1 year after her diagnosis. On examination, visual acuity was 20/200 bilaterally. There was no relative afferent pupillary defect, though Amsler grid testing revealed bilateral central scotomata. Color plate testing revealed 5/6 color plates bilaterally. The patient had 10 diopters of esotropia on straight gaze with full ductions, and the intraocular pressures were 17 and 19 mm/Hg, respectively. An examination of the anterior segment, her lens and the vitreous were unremarkable. Dilated fundus examination demonstrated pale optic nerves and bilateral cup-to-disc ratios of 0.8 (fig. 2). The retina was otherwise unremarkable. A generalized neurological examination demonstrated a mild cognitive impairment.

Six months prior to her visit, the patient had undergone an MRI of the head and orbits for evaluation of compressive, ischemic or demyelinating disease. MRI had revealed an increased T2 signal within the optic chiasm and the optic nerves bilaterally, suggestive of a metabolic or mitochondrial disorder. Subsequent mitochondrial genetic testing was performed via pyrosequencing, and the LHON G11778A mutation was confirmed. In our clinic, the patient was unable to complete a Humphrey visual field examination or tangent

field testing; therefore, a Goldmann visual field was administered in order to confirm the presence of central field defects (fig. 3). Though the patient had poor fixation, bilateral central scotomata were present. Subsequent optical coherence tomography of the optic nerve head demonstrated a mild thinning of the retinal nerve fiber layer, with an average retinal nerve fiber layer thickness measuring 81 μm OD and 77 μm OS. The average cup-to-disc ratio was noted to be 0.81 OD and 0.75 OS.

Treatment

Prior to her visit at our clinic, the patient had been started on idebenone 150 mg t.i.d. Idebenone is a short-chain benzoquinone that acts on the mitochondrial electron transport chain to improve cellular respiration. It has been proposed that idebenone allows electrons to bypass complex I, effectively maintaining the production of ATP despite an alteration of complex I [6]. Recent studies have demonstrated the therapeutic efficacy of idebenone in treating LHON; therefore, treatment with this agent was continued [7]. Results of a recent trial of idebenone 900 mg/day in patients with LHON demonstrated safety and tolerability at this dose, and the dose for the patient was increased from 150 mg t.i.d. to 150 mg q.i.d. to account for her recent increase in body mass index [8]. She was asked to return to the clinic every 4 months for ongoing neuro-ophthalmology assessment.

Discussion

LHON is a disease of the mitochondria in which a mutation in mtDNA leads to a phenotype of optic nerve atrophy secondary to the attrition of the retinal ganglion cell layer of the retina. LHON presents as subacute painless vision loss, usually in young men, and has a reported prevalence of 3.2 in 100,000, though there appears to be variability between populations [9]. Though the disease is acquired via maternal inheritance, women who harbor one of the primary mutations have an approximately 10% risk of developing optic nerve atrophy, while men have a risk as high as 50% [10]. This sex bias suggests that environmental and gender-specific genetic factors are superimposed on the penetrance of the mutation [11]. In the above case, the patient's family history was notable for having a single male relative who was affected by an LHON 11778 mutation. There were 26 family members who were unaffected carriers of the mutation and who did not express the disease phenotype, indicative of a low-penetrance mutation. Acquired causes of mitochondrial dysfunction have been shown to trigger the development of LHON, including pharmacologic agents such as chloramphenicol [12] and ethambutol [13]. Similarly, it is a reasonable hypothesis that the patient's co-expression of the DS phenotype, with superimposed dysfunction of the oxidative phosphorylation pathway, led to the predisposition for developing signs and symptoms of LHON.

The chief clinical features of DS (or Trisomy 21) are neurological and cognitive deficiencies, but there is also a predisposition for neoplastic disease and sequelae of accelerated aging, such as dementia and osteoporosis [14]. Although the partial or complete triplicate of chromosome 21 constitutes the etiology of DS, some of the pleiotropic phenotypes of the syndrome have been attributed to oxidative stress and mitochondrial dysfunction. In 1998, mitochondrial structural abnormalities in a mouse model of DS were found to include abnormally shaped mitochondria, abnormal filaments and microtubule deficiency [15]. Deficiencies of mitochondrial enzymes involved in oxidative phosphorylation, including

monoamine oxidase, cytochrome oxidase and isocitrate dehydrogenase, were found in platelets of patients with DS, suggesting that mitochondria in DS were susceptible to oxidative damage [16]. Druzhyna et al. [17] showed that mitochondria in DS are indeed more vulnerable to oxidative damage as a result of the aberrant expression of CuZn superoxide dismutase, perhaps leading to the accelerated development of phenotypes associated with aging. In a mouse model of DS, superoxide formation was increased by more than 50% when compared to controls, indicating an increased mitochondrial oxidative burden in DS [18]. It is therefore possible that otherwise low-penetrance mutations of LHON may be more easily expressed when coupled with an underlying progeroid syndrome, such as DS, and concomitant mitochondrial dysfunction.

It is possible that heteroplasmy, or the unequal distribution of mutated mitochondrial DNA amongst cells, played a role in the penetrance of the mutation. However, the patient's family reported that 3 maternal relatives had undergone genetic testing, revealing positivity for the mitochondrial mutation. These individuals did not demonstrate signs or symptoms of conversion. Although the status of these individuals as carriers could not be confirmed, it is likely that they were indeed positive for the 11778 mutation. Furthermore, the 11778 mutation tends to progress toward homoplasmy in successive generations; yet, the aforementioned pedigree did not reflect an increased incidence of conversion [19].

This case demonstrates the possibility of a 'two-hit' hypothesis in the expression of a low-penetrance LHON mutation when coupled with a pre-existing mitochondrial dysfunction. In considering the differential diagnosis of subacute vision loss in patients with DS and other genetic diseases with mitochondrial dysfunction, a high clinical suspicion for LHON should be raised, and molecular characterization by DNA blood testing should be performed.

References

1 Sadun AA, La Morgia C, Carelli V: Leber's hereditary optic neuropathy. Curr Treat Options Neurol 2011;13:109–117.
2 Haefeli RH, Erb M, Gemperli AC, Robay D, Courdier Fruh I, Anklin C, et al: NQO1-dependent redox cycling of idebenone: effects on cellular redox potential and energy levels. PLoS One 2011;6:e17963.
3 Hudson G, Carelli V, Spruijt L, Mowbray C, Achilli A, Pyle A, Elson J, Howell N, La Morgia C, Valentino ML, Huoponen K, Savontaus ML, Nikoskelainen E, Sadun AA, Salomao SR, Belfort R Jr, Griffiths P, Man PY, de Coo RF, Horvath R, Zeviani M, Smeets HJ, Torroni A, Chinnery PF: Clinical expression of Leber hereditary optic neuropathy is affected by the mitochondrial DNA-haplogroup background. Am J Hum Genet 2007;81:228–233.
4 Valenti D, Menente GA, Moro L, Marra E, Vacca RA: Deficit of complex I activity in human skin fibroblasts with chromosome 21 trisomy and overproduction of reactive oxygen species by mitochondria: involvement of the cAMP/PKA signaling pathway. Biochem J 2011;435:679–688.
5 Felius J, Beauchamp CL, Stager DR Sr: Visual acuity deficits in children with nystagmus and Down Syndrome. Am J Ophthalmol 2014;157:458–463.
6 Lin CS, Sharpley MS, Fan W, Waymire KG, Sadun AA, Carelli V, et al: Mouse mtDNA mutant model of Leber hereditary optic neuropathy. Proc Natl Acad Sci USA 2012;109:20065–20070.
7 Carelli V, La Morgia C, Valentino ML, Rizzo G, Carbonelli M, De Negri AM, et al: Idebenone treatment in Leber's hereditary optic neuropathy. Brain 2011;134:e188.
8 Klopstock T, Yu-Wai-Man P, Dimitriadis K, Rouleau J, Heck S, Bailie M, Atawan A, Chattopadhyay S, Schubert M, Garip A, Kernt M, Petraki D, Rummey C, Leinonen M, Metz G, Griffiths PG, Meier T, Chinnery PF: A randomized placebo-controlled trial of idebenone in Leber's hereditary optic neuropathy. Brain 2011;134:2677–2686.
9 Man PY, Turnbull DM, Chinnery PF: Leber hereditary optic neuropathy. J Med Genet 2002;39:162–169.
10 Harding AE, Sweeney MG, Govan GG, Riordan-Eva P: Pedigree analysis in Leber hereditary optic neuropathy families with a pathogenic mtDNA mutation. Am J Hum Genet 1995;57:77–86.
11 Infantino V, Castegna A, Iacobazzi F, Speri I, Scala I, Andria G, et al: Impairment of methyl cycle affects mitochondrial methyl availability and glutathione levels in Down's syndrome. Mol Genet Metab 2011;102:378–382.

12 Harley RD, Huang NN, Macri CH, Green WR: Optic neuritis and optic atrophy following chloramphenicol in cystic fibrosis patients. Am Acad Ophth Otol 1970;74:1011–1031.
13 Alvarez KL, Kro LC: Ethambutol induced ocular toxicity revisited. Ann Pharmacother 1993;27:102–103.
14 Perluigi M, Butterfield DA: Oxidative stress and Down syndrome: a route toward Alzheimer-like dementia. Curr Gerontol Geriatr Res 2012;2012:724904.
15 Smith KH, Johns DR, Heher KL, Miller NR: Heteroplasmy in Leber's hereditary optic neuropathy. Arch Ophthalmol 1993;111:1486–1490.
16 Prince J, Jia S, Bave U, ANneren G, Oreland L: Mitochondrial enzyme in Down's syndrome. J Neural Transm Park Dis Dement Sect 1994;8:171–181.
17 Druzhyna N, Nair RG, LeDoux SP, Wilson GL: Defective repair of oxidative damage in mitochondrial DNA in Down's syndrome. Mutat Res 1998;409:81–89.
18 Schuchmann S, Heinemann U: Increased mitochondrial superoxide generation in neurons from trisomy 16 mice: a model of Down's syndrome. Free Radic Biol Med 2000;28:235–250.
19 Bersu ET, Ahmad FJ, Schwei MJ, Baas PW: Cytoplasmic abnormalities in cultured cerebellar neurons from the trisomy 16 mouse. Brain Res Dev Brain Res 1998;109:115–120.

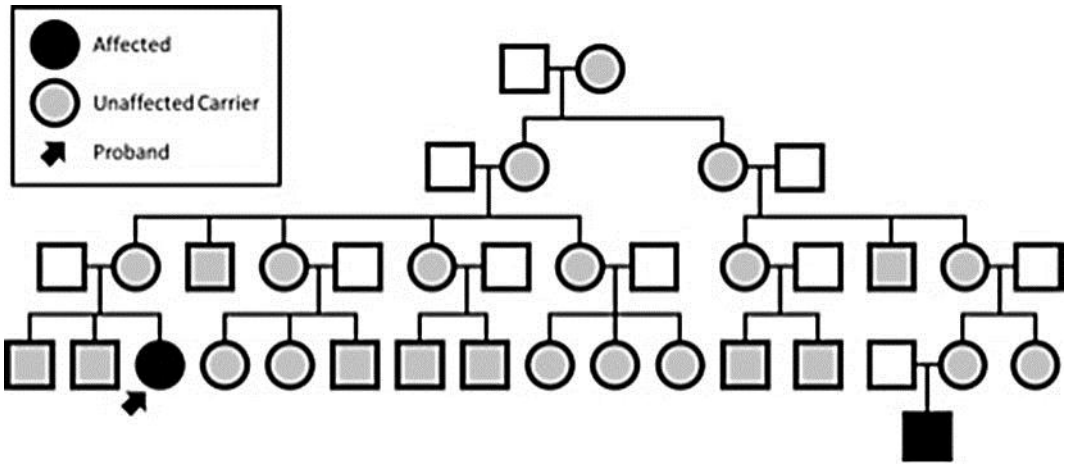

Fig. 1. Family pedigree. Note that only 1 maternal family member, with the exception of the proband, had documented genetic testing.

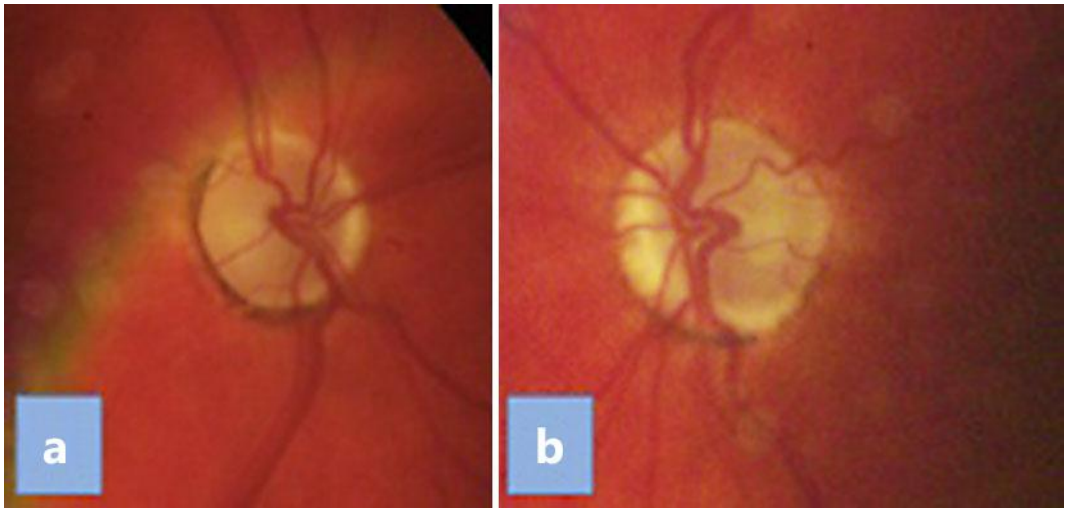

Fig. 2. Goldmann perimetry was used to evaluate the peripheral visual fields. **a** OS and **b** OD. Note the centrocecal scotomas OU.

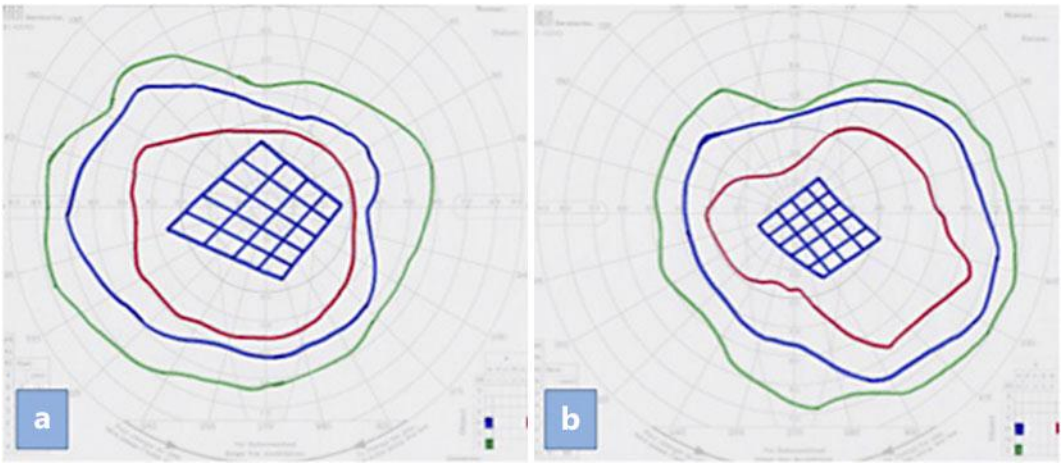

Fig. 3. Fundus photos. **a** OD and **b** OS.