

UCLA

UCLA Previously Published Works

Title

Higher risk of superficial injection during injection laryngoplasty in women

Permalink

<https://escholarship.org/uc/item/95j896mq>

Journal

American Journal of Otolaryngology, 35(2)

ISSN

0196-0709

Authors

Jamal, Nausheen
Mundi, Jagmeet
Chhetri, Dinesh K

Publication Date

2014-03-01

DOI

10.1016/j.amjoto.2013.09.002

Peer reviewed



Published in final edited form as:

Am J Otolaryngol. 2014 ; 35(2): 159–163.

Higher Risk of Superficial Injection during Injection Laryngoplasty in Women

Nausheen Jamal, MD¹, Jagmeet Mundi, MD², and Dinesh K. Chhetri, MD²

¹Temple University School of Medicine, Department of Otolaryngology-Head & Neck Surgery

²David Geffen School of Medicine, University of California, Los Angeles, Department of Head and Neck Surgery

Abstract

Purpose—To review our clinical experience with percutaneous injection laryngoplasty at a single institution over a three-year period, and to specifically assess the rate of unintentional injection into the superficial lamina propria (SLP) and compare with results found in the literature.

Materials and Methods—Medical records were retrospectively reviewed to identify patients who underwent office-based injection laryngoplasty (OBIL) over a three-year period. Video documentation and the written notes of the procedures were reviewed to determine the rate of inadvertent placement of injectate into the SLP. A literature review was performed to identify other reports of this complication and contributing factors.

Results—113 consecutive patients were identified who underwent OBIL in the study period. Of these, 100 patients had adequate records and follow-up available for this review. All patients underwent injection augmentation with bovine collagen using a percutaneous trans-membrane or trans-cartilaginous technique. 96 had improvement in their vocal quality and/or effort. Four patients, who were all women, had unintentional injection into the SLP with resultant no change in voice or worsened voice. All superficially placed injectates were managed conservatively.

Conclusions—Injection into the SLP is a well-recognized possible complication of OBIL. Our results suggest that this complication occurs more often in women than in men, perhaps due to differing laryngeal anatomy and size.

Keywords

dysphonia; vocal fold paralysis; injection laryngoplasty; vocal fold augmentation; superficial injection

© 2013 Elsevier Inc. All rights reserved.

Corresponding author: Nausheen Jamal, MD, Temple University School of Medicine, Department of Otolaryngology-Head & Neck Surgery, Kresge West Building, SW Corner Broad and Tioga Streets, Philadelphia, PA 19140, nausheen.jamal@gmail.com, Phone: 215-707-3665.

Financial Disclosure: None

Conflict of Interest: None

Publisher's Disclaimer: This is a PDF file of an unedited manuscript that has been accepted for publication. As a service to our customers we are providing this early version of the manuscript. The manuscript will undergo copyediting, typesetting, and review of the resulting proof before it is published in its final citable form. Please note that during the production process errors may be discovered which could affect the content, and all legal disclaimers that apply to the journal pertain.

Introduction

Vocal fold injection laryngoplasty was first introduced by Bruening as a method to correct glottic insufficiency due to unilateral vocal fold paralysis.^{1,2} The indications for this procedure have subsequently been expanded to treat a variety of vocal fold insufficiency states such as vocal cord atrophy, paresis, and scarring.³ Older injection materials such as Teflon® (DuPont, Wilmington, Delaware) and silicone have been supplanted by a variety of materials such as bovine collagen (Zyplast; Inamed Aesthetics, Fremont, CA), hyaluronic acid based materials (Restylane®, Medicis Aesthetics, Scottsdale, Arizona, and Juvederm®, Allergan, Irvine, California), autologous fat, carboxymethylcellulose (Radiesse Voice Gel, Merz Aesthetics, Inc., Franksville, WI), micronized acellular dermal matrix (Cymetra®, Life Cell Corporation, Branchburg, New Jersey), and calcium hydroxylapatite (Radiesse Voice, Merz Aesthetics, Inc., Franksville, WI).⁴⁻¹⁰

While injection laryngoplasty has become one of the more commonly performed laryngeal procedures, it is not without risks. Documented complications include: local abscess formation, malposition/migration of the injectate, hypersensitivity reactions, and association with development of collagen vascular disease (the latter two specific for bovine collagen).¹⁰⁻¹² In this clinical review, we aim to highlight an additional potential complication of the procedure: injection into the superficial layer of the lamina propria (SLP). In our experience with 100 patients over a three-year period, we have noted an increased propensity of this complication to occur in the female population. Based upon anatomical studies and observations, we believe that this may be due to the distinct anatomy of the female larynx.

Materials and Methods

Institutional Review Board approval from the University of California, Los Angeles, was obtained for this study. All injections were performed at a single institution by one surgeon (DKC) between 2006 and 2009. Medical records were reviewed to identify all consecutive patients who had undergone office-based injection laryngoplasty (OBIL). All consecutive patients who underwent injection augmentation during the study period were included, unless video documentation or medical records were inadequate or unavailable for review.

One hundred and thirteen patients were found to have undergone OBIL in the study period. No injections were performed in the operating room during this time frame, as is typical for this institution. 100 patients met the inclusion and exclusion criteria. All patients were injected awake and unsedated following application of topical anesthesia to the nasal cavities. Injections were performed via a trans-cartilaginous or trans-membranous percutaneous approach with bovine dermal collagen (Zyplast®; Inamed Aesthetics, Fremont, CA) using a 27 gauge needle, while the larynx was visualized via video nasolaryngoscopy. Video recordings of the injections were reviewed to assess for any superficial injection. This observation was made based on visualization of superficial extravasation of injectate with simultaneous blanching of the vocal fold surface with stiffening and disruption of the mucosal wave in this region, as noted on video recordings

from the time of injection (Figure 1). Medical records were also reviewed to check the remarks made at the time of injection, which included notation of whether the injection was superficial or not, whether voice improved, and if there were any immediate complications. A successful injection was defined by the reported subjective improvement in voice by the patient as well as by the clinician, based on a “yes” or “no” question response documented in the chart. Failure was defined as lack of any improvement of voice or the occurrence of a notable complication such as incorrect injectate placement.

The records for those patients who received superficial injection from OBIL were reviewed and compared. In addition, a review of the literature was conducted to identify relevant studies that highlighted superficial injectate placement during injection laryngoplasty.

Results

One hundred patients underwent OBIL in the study period (Table 1). There were 60 male and 40 female patients with ages ranging from 23-89 years (mean age of 64 years). The most common indication for OBIL was paralysis, which occurred in seventy-six patients (76%): fourteen (14%) developed paralysis as a result of thyroid surgery, thirty-four (34%) due to surgery for other neoplastic process (metastatic squamous cell carcinoma, esophageal cancer, carotid body tumors, leiomyosarcomas, vagal schwannomas, and thymomas), twelve (12%) due to other surgical procedures (heart transplants, lung transplants, cardiac surgery and esophageal surgery), and sixteen (16%) were idiopathic. Thirteen patients (13%) were treated for dysphonia due to vocal fold atrophy. Five patients (5%) were treated for paresis. The remaining six patients (6%) underwent OBIL for other reasons (Table 2). Of the above one hundred patients, eight had a concomitant systemic neurologic process such as Parkinson’s disease, myasthenia gravis, or polyneuropathy.

Patient and clinician subjective assessment as recorded in procedure notes suggested improvement in vocal quality after OBIL in 96 out of 100 patients. Four patients received inadvertent superficial vocal fold injection and were found to have no change or worsened vocal quality. In all four of these cases, injection into the superficial lamina propria was noted by blanching of the superior vocal fold surface with concomitant mucosal wave disruption on subsequent videostroboscopy. Injection laryngoplasty procedures were terminated as soon as superficial injection was noticed. No superficial injections occurred in patients with improved vocal quality. All four with superficial injection were women (10% of all women, 4% of total population), and this difference was found to be statistically significant ($p=0.012$). Their complications were managed conservatively via observation until the collagen resorbed in the following four to six months. This resorption rate was similar to that for collagen injected appropriately into the paraglottic space. There were no other major complications such as bleeding or airway compromise. There were no hypersensitivity reactions such as neck swelling, unexplained laryngeal inflammation, arthralgias, arthritis, fever, urticaria, generalized swelling, shortness of breath, and other airway complications. All patients tolerated the procedure very well in the office.

Discussion

This report supports the now well-established safety and efficacy of vocal augmentation via injection laryngoplasty. Our results concur with the largest series published to date, an institutional review at the University of California, Los Angeles, in 2007. This retrospective study examined 895 patients who underwent 1290 collagen injections. Of the 1290 injections, 83% were considered successful, with 200 patients reporting an unchanged or worsened voice.⁵ However, that study did not detail how many injections were unsuccessful due to superficial injection. Kimura and colleagues also reviewed their clinical experience with injection laryngoplasty. They performed a retrospective review of 275 injected patients and reported improvement in mean objective measures and clinician perceptual ratings with no major complications.¹³ Ford and colleagues also reported no complications in 45 patients undergoing 70 injections of collagen via an oro-tracheal injection device.¹⁴

A well-known and dreaded complication of OBIL is superficial injection into the SLP. Courey demonstrated in an *ex vivo* larynx study that injection into the SLP results in stiffening and loss of normal oscillatory function, which corresponds to the stroboscopic findings in our patient population.¹⁵ However, the type of patients at risk for superficial injection has not been previously discussed in the literature. Remacle cautioned against superficial injection, stating that it may lead to permanent ballooning and stiffening of the mucosa with subsequent loss of the mucosal wave but did not discuss gender issues.¹⁶ Anderson described a case report of a 38-year-old woman who received collagen injection *intentionally* into the SLP, at the site of a sulcus vocalis, and subsequently developed a submucosal fusiform collagen mass on the superior surface of the true vocal fold. This mass impaired the mucosal wave and required surgical removal in the operating room.¹⁰ Berke reported on 35 patients with Parkinson's disease and glottic insufficiency that underwent OBIL with collagen.⁸ Two of these patients developed collagen nodules as a result of sub-epithelial injectate placement. They later underwent microlaryngoscopy with excision of these nodules to rehabilitate their voice. The gender of these two patients was not mentioned. Sulica et al. recently published a large and more recent series of injection laryngoplasties.¹⁷ They reported that in 228 injections performed in awake, unsedated patients, 4 were complicated by "injectable-related misadventure, most commonly superficial injection." However, the gender of these patients was not mentioned.

In the present study, all four patients who were underwent injection of collagen into the SLP were women, which was a statistically significant finding. We suspect that this is most likely due to the smaller size of the female larynx. Zeitler and Amin examined the anatomical differences between male and female larynges.²⁰ They measured the mean difference from the thyroid notch (T) to three standardized points: (A) to the lateral aspect of the arytenoids, (V) to the tip of the vocal process, and (M) to mid-vocal fold level. The mean distances in men and women, respectively, were found to be: (T-A) 27.6 vs. 27.1 mm, (T-V) 27.4 vs. 19.7 mm, and (T-M) 21.8 vs. 15.5 mm. Mau and Courey also examined the influence of gender on vocal fold augmentation by injecting cadaveric larynges with calcium hydroxylapatite into the lateral and medial aspect of the vocal fold. Men required 50-60% more material than women, with a higher rate of frank extrusion in female larynges secondary to the smaller larynx anatomy. The male larynx is larger than the female larynx

by a factor of 1.3, which includes measurements of vocal fold length, anterior thyroid cartilage height, and anterior-to-posterior length of the thyroid ala. These differences in laryngeal anatomy have been demonstrated in multiple studies.^{22,23}

Our review of our clinical experience revealed that the 4 out of 100 patients with an unsuccessful OBIL were all as a result of injection into the SLP, and that all superficial injections occurred in women. All of our superficial injections occurred when the injectate were placed in a trans-cartilaginous fashion, percutaneously through the thyroid cartilage. The vertical height between the vocal folds and inferior thyroid ala is smaller in women and we believe this poses a risk for superficial injection. It has been suggested that an alternate form of percutaneous injection may improve visualization and decrease the rate of SLP injection. Zeitler and Amin describe a trans-thyrohyoid approach to in-office injection augmentation. They argue that a trans-cartilaginous approach in which the needle is passed through the thyroid cartilage into the endolarynx does not provide adequate visualization of the tip of the needle, therefore leading to a higher risk of superficial injection.²⁰ The thyrohyoid approach has the advantages of patient tolerance and performance under local anesthesia seen with other percutaneous injection techniques with the addition of better visualization. However, it requires tedious application of topical anesthesia to the endolarynx to allow for accurate and comfortable needle placement. Additionally, one may still be limited by the anatomical constraints of female laryngeal anatomy. Amin noted that the thyrohyoid approach is difficult in individuals in whom the entry angle is not attainable, particularly in patients with shorter larynges and without a prominent thyroid notch – as may frequently be the case with the female larynx.²⁴

An additional consideration is that in this series, all injections were performed with bovine collagen. By including a single injection material, we aimed to exclude substance type as a confounding variable while reviewing a patient group with long-term follow-up. Collagen's ease of injection and rapid rate of resorption distinguishes this material somewhat from current synthetic substances. Calcium hydroxylapatite (CaHA) in particular is designed for longer-term augmentation, with results lasting up to 36 months.²⁵ Improper injection of this substance into the SLP is a cause for greater concern, and is more likely to require surgical extraction – unlike in our patient population, where the collagen resorbed spontaneously and uneventfully. This complication has been demonstrated by others using CaHA, although due to lack of gender stratification and use of trans-oral injection under general anesthesia (as opposed to percutaneous OBIL), their superficial injection rates in women versus men are not directly comparable with ours.^{12,26,27} Nonetheless, it would be prudent to proceed with caution when performing any percutaneous OBIL – and we suggest that perhaps one should be especially cautious when using CaHA in women.

This study is hindered by a number of limitations. It is a retrospective study with limited objective voice analysis. Voice improvement was determined by a subjective “yes or no” response by the patient and physician, which has the potential for bias. In addition, we did not perform any injection laryngoplasties in the operating room under anesthesia, and thus our findings cannot be extended to the sedated, trans-oral techniques. However, our goal was to primarily evaluate whether gender differences existed in inadvertent injection into the SLP. Furthermore, despite these limitations, this report highlights all injections performed

by a single surgeon using a single, and the finding of superficial injection in only women was statistically significant. Thus, these findings are clinically relevant to surgeons performing injection laryngoplasty using the percutaneous technique.

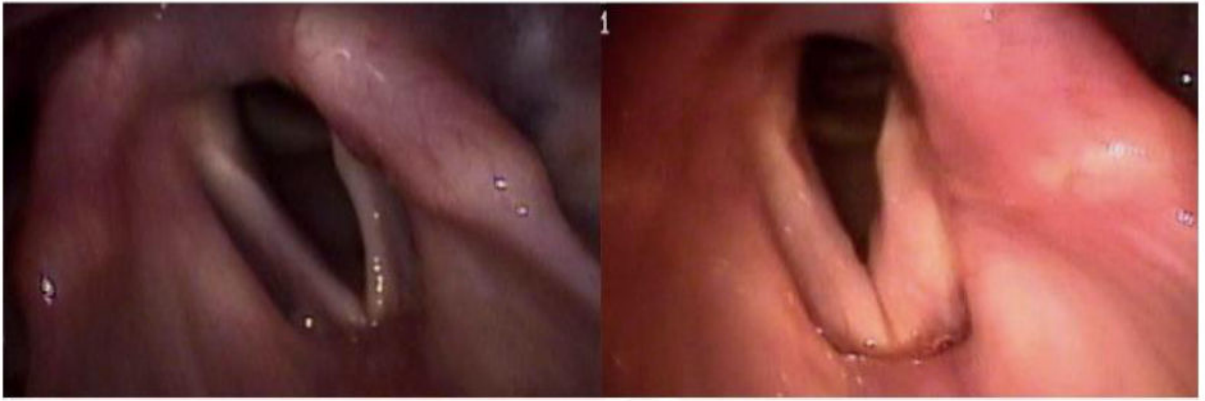Conclusions

Injection into the SLP is a rare but well-known and dreaded complication of OBIL. A review of our data and the pertinent literature highlights the increased risk of this complication in female patients. This is likely secondary to the anatomical differences between the male and female larynx. Percutaneous injections, particularly with long-lasting substances, should be performed with more caution in the female population.

References

1. Bruening W. Uber eine neue behandlungsmethode der rekurrenzslahmung. *Ver Deutsch Laryng.* 1911; 18:93–151.
2. Courey MS. Injection Laryngoplasty. *Otolaryngol Clin North Am.* 2004; 37(1):121–38. [PubMed: 15062690]
3. Ford CN, Bless DM, Loftus JM. Role of injectable collagen in the treatment of glottic insufficiency: a study of 119 patients. *Ann Otol Rhinol Laryngol.* 1992; 101(3):237–47. [PubMed: 1543333]
4. Ford CN, Martin DW, Warner TF. Injectable collagen in laryngeal rehabilitation. *Laryngoscope.* 1984; 94(4):513–8. [PubMed: 6708694]
5. Luu Q, Tsai V, Mangunta V, et al. Safety of percutaneous injection of bovine dermal crosslinked collagen for glottic insufficiency. *Otolaryngol Head Neck Surg.* 2007; 136(3):445–9. [PubMed: 17321875]
6. Ward PH, Hanson DG, Abemayor E. Percutaneous Teflon injection of the paralyzed vocal fold: a new technique. *Laryngoscope.* 1985; 95(6):644–9. [PubMed: 3999897]
7. Hirano M, Tanaka S, Tanaka Y, et al. Transcutaneous intrafold injection for unilateral vocal fold paralysis: functional results. *Ann Otol Rhinol Laryngol.* 1990; 99(8):598–604. [PubMed: 2382931]
8. Berke GS, Gerratt B, Kreiman J, et al. Treatment of Parkinsonian hypophonia with percutaneous collagen augmentation. *Laryngoscope.* 1999; 109(8):1295–9. [PubMed: 10443836]
9. Lundy DA, Casiano RR, McClinton ME, et al. Early results of percutaneous injection laryngoplasty with micronized acellular dermis vs. type I thyroplasty for glottic incompetence dysphonia due to unilateral vocal fold paralysis. *J Voice.* 2003; 17(4):589–95. [PubMed: 14740939]
10. Anderson TD, Sataloff RT. Complications of collagen injection of the vocal fold: report of several unusual cases and review of the literature. *J Voice.* 2004; 18(3):392–7. [PubMed: 15331113]
11. Hanke CW, Higley HR, Jolivette DM, et al. Abscess formation and local necrosis after treatment with Zyderm or Zyplast Collagen Implant. *J Am Acad Dermatol.* 1991; 25(2 Pt 1):319–26. [PubMed: 1918471]
12. DeFatta RA, Chowdhury FR, Sataloff RT. Complications of injection laryngoplasty using calcium hydroxyl apatite. *J Voice.* 2012; 26(5):614–8. [PubMed: 22056892]
13. Kimura M, Nito T, Sakakibara K, et al. Clinical experience with collagen injection of the vocal fold: a study of 155 patients. *Auris Nasus Larynx.* 2008; 35(1):67–75. [PubMed: 17804185]
14. Ford CN, Bless DM. Selected problems treated by vocal fold injection of collagen. *Am J Otolaryngol.* 1993; 14(4):257–61. [PubMed: 8214319]
15. Courey MS. Homologous collagen substances for vocal fold augmentation. *Laryngoscope.* 2001; 111(5):747–58. [PubMed: 11359151]
16. Remacle M, Marbaix E, Hamoir M, et al. Correction of glottic insufficiency by collagen injection. *Ann Otol Rhinol Laryngol.* 1990; 99(6 Pt 1):438–44. [PubMed: 2350128]
17. Sulica L, Rosen CA, Postma GN, et al. Current practice in injection augmentation of the vocal folds: indications, treatment principles, techniques, and complications. *Laryngoscope.* 2010; 120:319–25. [PubMed: 19998419]

18. Ford CN, Staskowski PA, Bless DM. Autologous collagen vocal fold injection: a preliminary clinical study. *Laryngoscope*. 1995; 105(9 Pt 1):944–8. [PubMed: 7666730]
19. Remacle M, Lawson G, Jamart J, et al. Treatment of vocal fold immobility by injectable homologous collagen: short-term results. *Eur Arch Otorhinolaryngol*. 2006; 263(3):205–9. [PubMed: 16177917]
20. Zeitler DM, Amin MR. The thyrohyoid approach to in-office injection augmentation of the vocal fold. *Curr Opin Otolaryngol Head Neck Surg*. 2007; 15(6):412–6. [PubMed: 17986881]
21. Mau T, Courey MS. Influence of gender and injection site on vocal fold augmentation. *Otolaryngol Head Neck Surgery*. 2008; 138(2):221–5.
22. Sprinzel GM, Eckel HE, Sittel C, et al. Morphometric measurements of the cartilaginous larynx: an anatomic correlate of laryngeal surgery. *Head Neck*. 1999; 21(8):743–50. [PubMed: 10562688]
23. Tayama N, Chan RW, Kaga K, et al. Geometric characterization of the laryngeal cartilage framework for the purpose of biomechanical modeling. *Ann Otol Rhinol Laryngol*. 2001; 110(12): 1154–61. [PubMed: 11768707]
24. Amin MR. Thyrohyoid approach for vocal fold augmentation. *Ann Otol Rhinol Laryngol*. 2006; 115(9):699–702. [PubMed: 17044543]
25. Carroll T, Rosen CA. Long-term results of calcium hydroxylapatite for vocal fold augmentation. *Laryngoscope*. 2010; 121:313–9. [PubMed: 21271580]
26. Chheda NN, Rosen CA, Belafsky PC, et al. Revision laryngeal surgery for the suboptimal injection of calcium hydroxylapatite. *Laryngoscope*. 2008; 118:2260–3. [PubMed: 19029857]
27. Ting JY, Patel R, Halum SL. Managing voice impairment after injection laryngoplasty. *J Voice*. 2012; 26(6):797–800. [PubMed: 22633331]



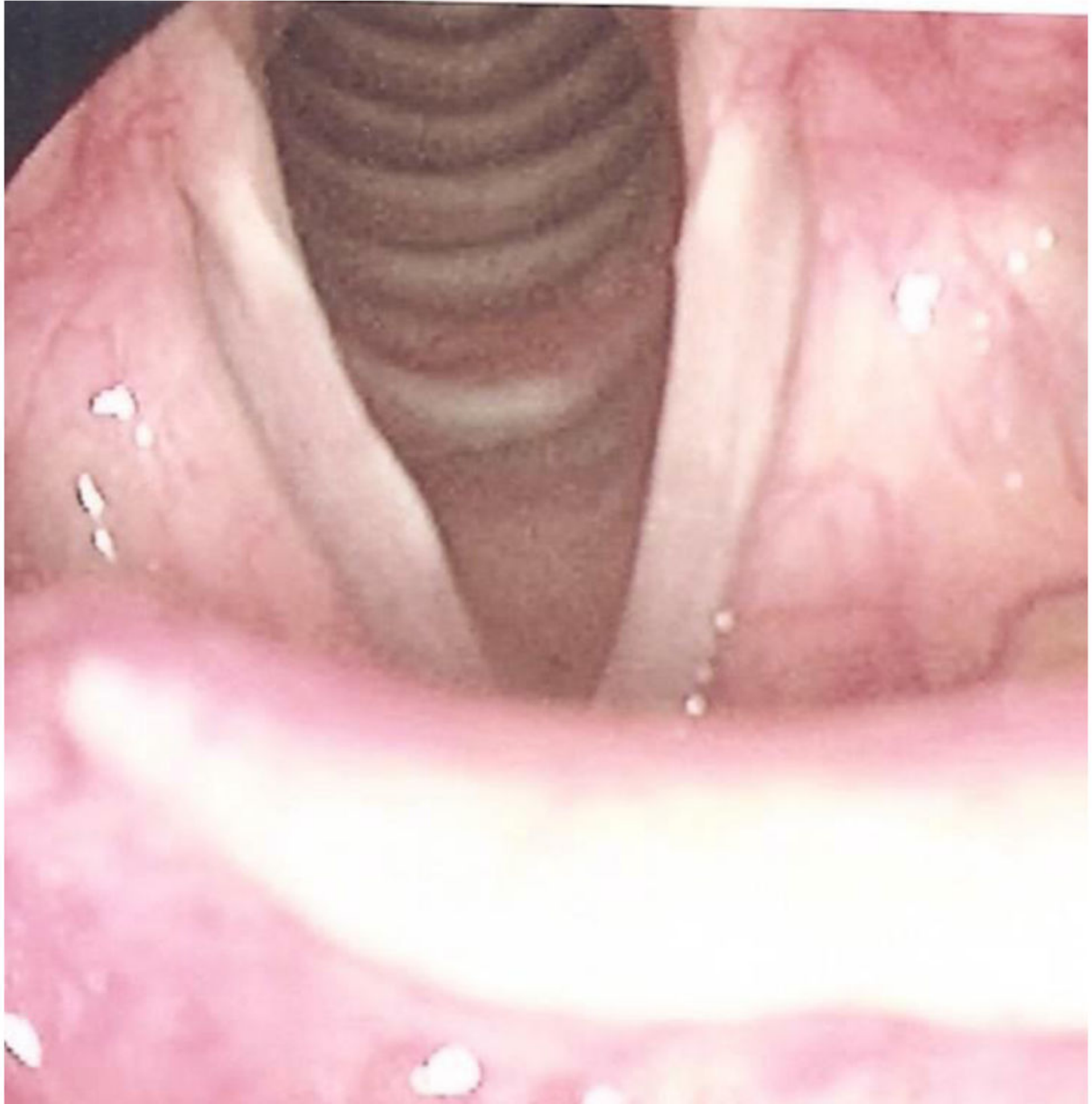


Figure 1.

A: Typical “before” and “after” appearance of a normal injection laryngoplasty.

B: Representative appearance of the larynx after injection into the superficial lamina propria of the right mid-membranous vocal fold.

Table 1

Age and Gender Distribution of Patients

Age Range	Women	Men
20-29	3	2
30-39	2	0
40-49	3	6
50-59	9	9
60-69	5	23
70-79	5	14
80-89	13	6
Total	40	60

Table 2

Clinical indications for injection laryngoplasty by gender

Primary Reason for Injection	Women	Men	Total
Paralysis	31	45	76
Paresis	2	3	5
Atrophy	5	8	13
Scarring	1	2	3
Other	1	2	3
Total	40	60	100