

# UC Davis

## Dermatology Online Journal

### Title

Pediatric pustular psoriasis responsive to cyclosporine bridged to etanercept: A treatment approach

### Permalink

<https://escholarship.org/uc/item/9787b6c0>

### Journal

Dermatology Online Journal, 23(11)

### Authors

Georgeses, Corey  
Wildman, Horatio  
Wang, Xuan  
[et al.](#)

### Publication Date

2017

### License

[CC BY-NC-ND 4.0](#)

Peer reviewed

# Pediatric pustular psoriasis responsive to cyclosporine bridged to etanercept: A treatment approach

Corey Georgesen MD, Horatio Wildman MD, Xuan Wang MD PhD, and Cynthia Magro MD

Affiliations: New York Presbyterian/Weill Cornell Medical College, New York

Corresponding Author: Corey Georgesen, 1305 York Avenue, Dermatology, 9th floor, New York, NY 10021, Tel: 646-962-3376, Fax: 646-962-0033, Email: corey.georgesen@gmail.com

## Abstract

Pustular psoriasis occurs rarely in children but can present with acute toxicity requiring inpatient admission. For the best approach, medical providers should have an evidence based and systematic treatment algorithm in their armamentarium. To illustrate this point, we describe a 13-year-old girl who was admitted with generalized pustular psoriasis and who responded dramatically to “wet wrap” therapy and cyclosporine bridged to etanercept. Using this case example, we highlight the three most important considerations in any patient with new onset pustular psoriasis: avoidance of disease complications, acute “rescue” therapy, and maintenance therapy.

*Keywords: pustular psoriasis, psoriasis, cyclosporine, etanercept*

## Introduction

Pustular psoriasis presents with pustules in the skin and potentially life threatening systemic manifestations. Described variants include generalized, localized (acrodermatitis of Hallopeau), annular, and exanthematous forms of pustular psoriasis. Complications include dehydration, electrolyte imbalances (hypocalcemia), and infection [1].

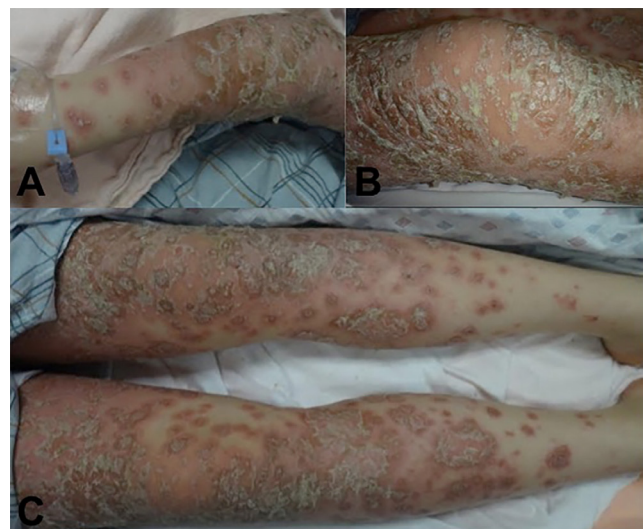
Pustular psoriasis is even more rare in pediatrics. A meta-analysis [2] that utilized PubMed and Embase to identify pediatric patients (defined as less than 18 years old) with pustular psoriasis treated with a

systemic agent found only 24 cases that fit inclusion criteria.

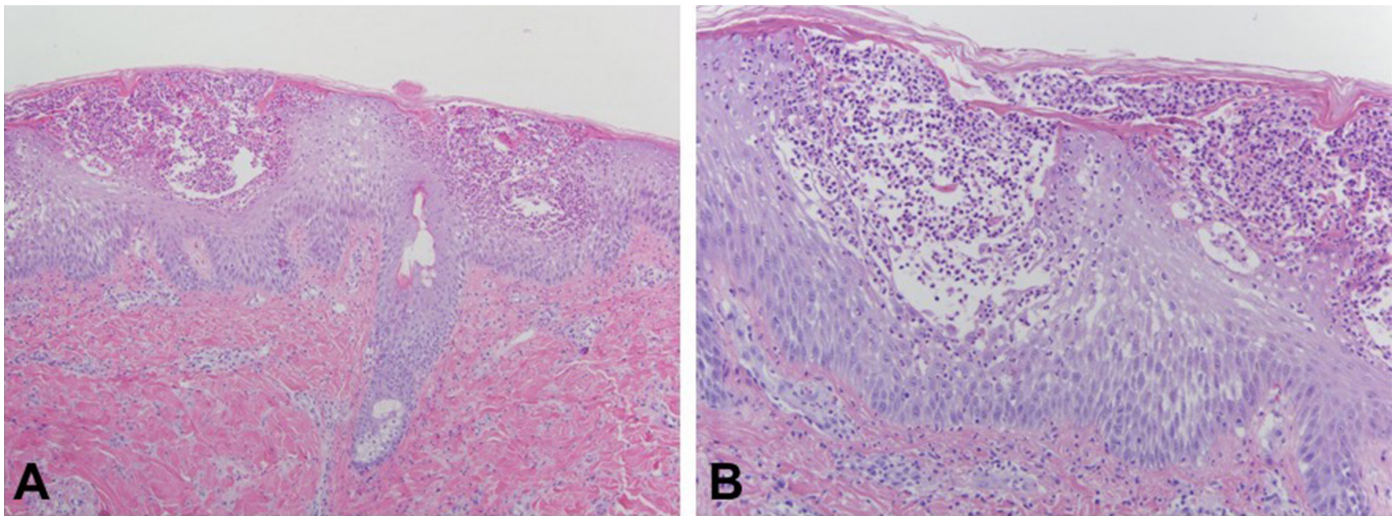
A wealth of clinical trials in adult cohorts has led to the development of numerous biologics with high efficacy in treating psoriasis. The evidence base in pediatric populations is not as robust. Clinicians must critically analyze the data that is available in formulating a treatment plan for a child with severe psoriasis that is both effective and safe. Herein we suggest one such approach.

## Case Synopsis

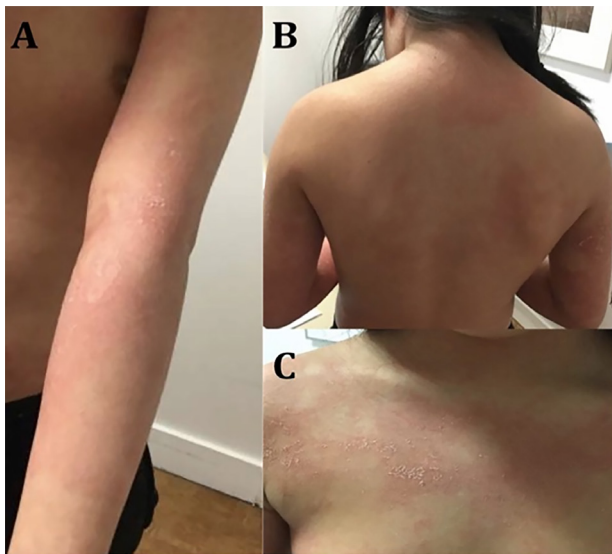
A 13-year-old girl with no significant past medical history presented to our tertiary care institution with a new onset of a generalized body rash. The eruption started 3-4 months previously and was initially localized to one ear. Over the ensuing months, the



**Figure 1.** Diffuse pink psoriatic plaques with extensive pustular crusting cover the right arm (A), right knee (B), and bilateral lower extremities (C).



**Figure 2.** A) Subcorneal pustulation is apparent. The epidermis exhibits psoriasiform hyperplasia, a high rete to plate ratio, and diminution of the granular layer. H&E, 4%.



**Figure 3.** A few scattered thin pink patches with mild flaking scale are present on the left arm (A), back (B), and chest (C).

rash became more generalized and tender with involvement of the face, neck, chest, abdomen, back, buttocks, and all four extremities. She denied the use of systemic or topical medications. Otherwise, the patient felt well, without fever, chills, cough, sore throat, abdominal pain, or change in bowel movements. Of note, she was a recent immigrant from China, having relocated to the United States one year previously. There was no family history of skin disease. On initial exam, the patient had erythematous scaly plaques with desquamation on the anterior scalp, face, neck, chest, abdomen, back, buttocks, and bilateral upper and lower extremities. Multiple plaques had surrounding 1mm pustules on the upper and lower extremities (Figure 1).

Given the suspicion for pustular psoriasis, the patient was admitted to the hospital and labs were assessed. Blood counts, comprehensive metabolic panel, magnesium, phosphorus, uric acid, lipid panel, urinalysis, hepatitis B, hepatitis C, quantiferon-gold, HIV, pregnancy test, calcium level, anti-streptolysin, and DNase B were all normal. A skin biopsy showed psoriasiform epidermal hyperplasia with a high rete ridge to plate ratio associated with conspicuous subcorneal pustules and spongiosis, a diminished to absent granular cell layer, and dilated dermal papillae capillaries intimately apposed to the epidermal basement membrane (Figure 2). Direct immunofluorescence studies were nonspecific. A diagnosis was made of pustular psoriasis.

The patient was started on cyclosporine 4 mg/kg/day divided twice daily. Additionally, she was immediately initiated on a "wet wrap" regimen. At our institution, we employ wet wraps in the following manner: After a shower (or ideally soaking in a lukewarm bath), triamcinolone 0.1 percent ointment is applied to all the affected areas. This is then covered by an emollient (i.e. hydrophor). Finally, the skin is covered by Saran wrap (or wet towels) and dry pajamas.

The patient experienced rapid improvement of her skin symptoms with the above measures. She was discharged three days later and at one-week follow-up her skin had reached 85 percent clearance (Figure 3). However, both her cholesterol and triglycerides were elevated at 422 and 342 respectively. Cyclosporine was therefore tapered off over the ensuing 2 months

and she was simultaneously initiated on etanercept 50mg subcutaneously once weekly. The patient has been maintained on this dosing of etanercept with 100 percent clearance of her skin.

## Case Discussion

The diagnosis of pustular psoriasis in a child necessitates appropriate monitoring and treatment. Important differential diagnostic considerations for a widespread rash with subcorneal pustulation include impetigo, staphylococcal scalded skin syndrome, acute generalized exanthematous pustulosis, pemphigus foliaceus, Sneddon-Wilkinson disease, and IgA pemphigus. In infants presenting with an eruption clinically mimicking pustular psoriasis one must be cognizant of the CARD14 mutation, the autoinflammatory syndrome associated with an interleukin 36 genetic deficiency [3], as well as the genetic deficiency of interleukin 1 receptor antagonist, especially in children from Puerto Rico [4]. Furthermore, in children receiving TNF inhibitors for the treatment of inflammatory bowel disease, a potential adverse side effect is the abrupt onset of pustular psoriasis [5]. These entities can be ruled out with a clinical and medication history, bacterial cultures, and direct immunofluorescent studies.

Once the diagnosis of pustular psoriasis has been made, our recommended approach is threefold:

### **1. Monitoring and Management of Acute Disease Complications**

First, clinicians should diligently search for any inciting factors. In children and adolescents these most often include infection, systemic corticosteroid use, vaccination, and pregnancy [6]. Streptococcal labs along with a pregnancy test should be considered. Calcium should be monitored regularly, as hypocalcemia has been cited as both a trigger and complication of generalized pustular psoriasis [7]. In a retrospective review of 27 juvenile patients with generalized pustular psoriasis [5], other common complications included fever, leukocytosis, arthritis, and elevated liver function tests. Finally, clinicians should have a low threshold to treat any signs of systemic infection in those with a compromised skin barrier.

### **2. Acute “Rescue” Treatment**

The goal of early treatment should be prompt and rapid clearance of the skin. All patients should undergo topical therapy, preferably with “wet wrap” therapy [8] as described in the case synopsis. Proper education and instruction are the most important components of this technique. This includes education of not only the patient and family but also the primary inpatient team and nurses. Ideally, the dermatologist should perform the initial wet wrap in the presence of primary providers and nursing staff, in addition to providing a detailed description in the patient’s medical chart.

Because the goal is rapid clearance, systemic therapies are often needed. It is important that providers select an agent that is not only effective but also safe. Cyclosporine is a preferred agent at our institution, as there is a sizable data pool in pediatric patients with severe psoriasis relative to other systemic agents. Standard pediatric dosing ranges from 3 to 5 mg/kg/day [9-14]. Other options include acitretin and methotrexate, all of which have been shown to have comparable reduction of Psoriasis Area and Severity Index score [14]. Regarding generalized pustular psoriasis, however, it should be noted that those treated with systemic agents in the literature are mostly limited to case series and case reports [6].

Regardless of the agent selected, it is paramount to monitor for adverse events, as exemplified in our case patient who developed hyperlipidemia. It should be noted that serious adverse events to cyclosporine in pediatric patients are rare, with most reported treatment complications being laboratory abnormalities [9, 10]. Therefore, we suggest that patients be monitored at two week intervals (with blood counts, electrolyte panels, kidney and hepatic function, uric acid, magnesium, glucose, and blood pressure) and that cyclosporine be tapered off as soon as possible (ideally within 6 months).

### **3. Maintenance Treatment**

The goal of the physician should be effective and safe long-term therapy. Laboratory screening as detailed in the case synopsis should be obtained upon initial presentation, prior to the initiation of any biologic agent. Etanercept is a reliable choice given its documented safety profile in juvenile idiopathic arthritis [15, 16]. Of particular importance

is the recent open-label study by Paller et al. [17] investigating the efficacy and safety of etanercept in pediatric psoriasis patients. Of the 182 patients on etanercept monitored over 5 years, the majority (89 percent) reported adverse events including upper respiratory infection and headache, but only one patient developed a severe adverse event that was deemed to be treatment related. Rates of 75 percent improvement in Psoriasis Area and Severity Index score (60-70 percent) were maintained throughout the study. Pediatric dosing of etanercept described in this study was 0.8 mg/kg once weekly.

Salkaly et al. [18] specifically sought to characterize biologic use in pediatric generalized pustular psoriasis. Twelve cases were identified that met inclusion criteria and among those, five patients achieved total control with etanercept. Five patients in this review improved with infliximab and three with adalimumab, suggesting these may be reasonable alternative therapies.

Although newer biologic agents including interleukin-17 inhibitors have the potential for improved clearance with even fewer adverse events, we cannot recommend routine use until adequate long-term safety data has been reported in children. In any case, physicians should recognize the potential for adverse events with any biologic agent. Those patients who have achieved long-term remission deserve a trial of systemic drug cessation and/or transition to topical therapy whenever possible.

**Conclusion:** Generalized pustular psoriasis is rarely reported in children. Through this representative case example, we suggest a systematic approach in the evaluation and treatment of this disease. First, inciting triggers should be investigated and disease complications avoided. The goal is rapid and sustained clearance of the skin. Aggressive topical therapy is essential; we suggest "wet wraps" as detailed in this report. A short-term systemic agent such as cyclosporine or acitretin should not be delayed understanding the need for adverse event and laboratory monitoring. Soon thereafter (or concurrently), a maintenance therapy should be started. We suggest etanercept given the available safety data in pediatrics. Effective communication with both the patient family and inpatient providers

must be employed throughout this stepwise approach.

## References

1. Prystowsky JH, Cohen PR. Pustular and erythrodermic psoriasis. *Dermatol Clin*. 1995 Oct;13(4):757-70. [PMID: 8785881].
2. Posso-De Los Rios CJ, Pope E, Lara-Corrales I. A systematic review of systemic medications for pustular psoriasis in pediatrics. *Pediatr Dermatol*. 2014 Jul-Aug;31(4):430-9. [PMID: 24890463].
3. Ellingford JM, Black GC, Clayton TH, Judge M, Griffiths CE, Warren RB. A novel mutation in IL36RN underpins childhood pustular dermatosis. *J Eur Acad Dermatol Venereol*. 2016 Feb;30(2):302-5.
4. Minkis K, Aksentijevich I, Goldbach-Mansky R, Magro C, Scott R, Davis JG, Sardana N, Herzog R. Interleukin 1 receptor antagonist deficiency presenting as infantile pustulosis mimicking infantile pustular psoriasis. *Arch Dermatol*. 2012 Jun;148(6):747-52. [PMID: 22431714]
5. Pourciau C, Shwayder T. Occurrence of pustular psoriasis after treatment of Crohn disease with infliximab. *Pediatr Dermatol*. 2010 Sep-Oct;27(5):539-40. [PMID: 20796241].
6. Lau BW, Lim DZ, Capon F, Barker JN, Choon SE. Juvenile generalized pustular psoriasis is a chronic recalcitrant disease: an analysis of 27 patients seen in a tertiary hospital in Johor, Malaysia. *Int J Dermatol*. 2017 Apr;56(4):392-399. [PMID: 28194751].
7. Guerreiro de Moura CA, de Assis LH, Góes P, Rosa F, Nunes V, Gusmão ÍM, Cruz CM. A Case of Acute Generalized Pustular Psoriasis of von Zumbusch Triggered by Hypocalcemia. *Case Rep Dermatol*. 2015 Dec 3;7(3):345-51. [PMID: 26955330].
8. Harper J. Topical corticosteroids for skin disorders in infants and children. *Drugs*. 1988;36 Suppl 5:34-7. [PMID: 2978289].
9. Dogra S, Mahajan R, Narang T, Handa S. Systemic cyclosporine treatment in severe childhood psoriasis: A retrospective chart review. *J Dermatolog Treat*. 2017 Feb;28(1):18-20. [PMID: 27771982].
10. Di Lernia V, Stingeni L, Boccaletti V, Calzavara Pinton PG, Guarneri C, Belloni Fortina A, Panzone M, Corazza M, Neri I, Cambiaghi S, Lasagni C, Ficarelli E, Gisondi P. Effectiveness and safety of cyclosporine in pediatric plaque psoriasis: A multicentric retrospective analysis. *J Dermatolog Treat*. 2016 Oct;27(5):395-8. [PMID: 26571044].
11. Pereira TM, Vieira AP, Fernandes JC, Sousa-Basto A. Cyclosporin A treatment in severe childhood psoriasis. *J Eur Acad Dermatol Venereol*. 2006 Jul;20(6):651-6. [PMID: 16836490].
12. Perrett CM, Ilchyshyn A, Berth-Jones J. Cyclosporin in childhood psoriasis. *J Dermatolog Treat*. 2003 Jun;14(2):113-8. [PMID: 12775319].
13. Mahé E, Bodemer C, Pruszkowski A, Teillac-Hamel D, de Prost Y. Cyclosporine in childhood psoriasis. *Arch Dermatol*. 2001 Nov;137(11):1532-3. [PMID: 11708969].
14. Ergun T, Seckin Gencosmanoglu D, Alpsoy E, Bulbul-Baskan E, Saricam MH, Salman A, Onsun N, Sariöz A. Efficacy, safety and drug survival of conventional agents in pediatric psoriasis: A multicenter, cohort study. *J Dermatol*. 2016 Dec 10. [PMID: 27943425].
15. Amarilyo G, Tarp S, Foeldvari I, Cohen N, Pope TD, Woo JM, Christensen R, Furst DE. Biological agents in polyarticular juvenile idiopathic arthritis: A meta-analysis of randomized withdrawal trials. *Semin Arthritis Rheum*. 2016 Dec;46(3):312-318. [PMID: 27989499].
16. Davies R, Gaynor D, Hyrich KL, Pain CE. Efficacy of biologic therapy across individual juvenile idiopathic arthritis subtypes: A systematic review. *Semin Arthritis Rheum*. 2016 Nov 1. pii: S0049-0172(16)30153-6. [PMID: 27914689].
17. Paller AS, Siegfried EC, Pariser DM, Rice KC, Trivedi M, Iles J, Collier DH, Kricorian G, Langley RG. Long-term safety and efficacy of etanercept in children and adolescents with plaque psoriasis. *J Am Acad Dermatol*. 2016 Feb;74(2):280-7.e1-3. [PMID: 26775775].

18. Saikaly SK, Mattes M. Biologics and Pediatric Generalized Pustular Psoriasis: An Emerging Therapeutic Trend. *Cureus*. 2016 Jun 22;8(6):e652. [PMID: 27462478].