

UCLA

UCLA Previously Published Works

Title

Adjustable Augmented Rectus Muscle Transposition Surgery with or Without Ciliary Vessel Sparing for Abduction Deficiencies

Permalink

<https://escholarship.org/uc/item/97f059d9>

Journal

Strabismus, 22(2)

ISSN

0927-3972

Authors

Hendler, Karen
Pineles, Stacy L
Demer, Joseph L
[et al.](#)

Publication Date

2014-06-01

DOI

10.3109/09273972.2014.904901

Peer reviewed

Published in final edited form as:

Strabismus. 2014 June ; 22(2): 74–80. doi:10.3109/09273972.2014.904901.

Adjustable Augmented Rectus Muscle Transposition Surgery with or Without Ciliary Vessel Sparing for Abduction Deficiencies

Karen Hendler, MD¹, Stacy L. Pineles, MD¹, Joseph L. Demer, MD, PhD^{1,2}, Dawn Yang, MD¹, and Federico G. Velez, MD^{1,3}

¹Department of Ophthalmology, Jules Stein Eye Institute, University of California, Los Angeles, California

²Department of Neurology, University of California, Los Angeles, California

³Department of Surgery, Division of Pediatric Ophthalmology, Olive View-UCLA Medical Center, Sylmar, California

Abstract

Background—Vertical rectus transposition (VRT) is useful in abduction deficiencies. Posterior fixation sutures enhance the effect of VRT, but usually preclude the use of adjustable sutures. Augmentation of VRT by resection of the transposed muscles allows for an adjustable technique that can reduce induced vertical deviations and overcorrections.

Methods—We retrospectively reviewed the records of all patients undergoing adjustable partial or full tendon VRT augmented by resection of the transposed muscles. Ciliary vessels were preserved in most of the patients by either splitting the transposed muscle or by dragging the transposed muscle without disrupting the muscle insertion.

Results—Seven patients with abducens palsy and one with esotropic Duane syndrome were included. Both vertical rectus muscles were symmetrically resected by 3–5 mm. Preoperative central gaze esotropia of 30.6 ± 12.9 (range, 17–50) decreased to 10.6 ± 8.8 (range, 0–25) at the final visit ($p = 0.003$). Three patients required postoperative adjustment by recession of one of the transposed muscles due to an induced vertical deviation (mean 9.3 reduced to 0), coupled with overcorrection (mean exotropia 11.3 reduced to 0 in two patients and exophoria 2 in one patient). At the final follow-up visit 3.8 \pm 2.6 months postoperatively, one patient had a vertical deviation <4 , and none had overcorrection or anterior segment ischemia. Three patients required further surgery for recurrent esotropia.

Conclusions—Augmentation of VRT by resection of the transposed muscles can be performed with adjustable sutures and vessel-sparing technique. This allows for postoperative control of overcorrections and induced vertical deviations as well as less risk of anterior segment ischemia.

© Informa Healthcare USA, Inc.

Correspondence: Federico G. Velez, MD, 100 Stein Plaza, Los Angeles, CA 90095. Tel: 310-825-2872. Fax: 310-825-0151
velez@jsei.ucla.edu..

DECLARATION OF INTEREST

The authors report no conflict of interest.

Keywords

Adjustable; augmented; esotropia; transposition; vessel-sparing

INTRODUCTION

Vertical rectus transposition (VRT) surgery was first described as a treatment for abducens palsy by Hummelsheim in 1907.¹ The surgery he described was a partial VRT, utilizing the temporal halves of the superior and inferior rectus muscles and transposing them to the palsied lateral rectus muscle. The Hummelsheim procedure continues to be performed today for abduction deficiencies, due to its ciliary vessel-sparing quality. In 1959, full tendon VRT was described² and has been accepted as a more powerful procedure. In 1997, Foster showed that the addition of posterior fixation sutures (PFS) to the transposed muscles enhanced the abducting effect of the transposition without the need for simultaneous medial rectus recession.³ This enhanced effect was shown in magnetic resonance imaging studies to be a mechanical effect caused by the shifting of the transposed muscle pulleys laterally.⁴ Many modifications of VRT have been proposed over the years, in order to reduce important complications such as anterior segment ischemia, scleral perforation, overcorrections, and induced vertical deviations.⁵⁻¹⁵ Adjustable VRT was first described by Carlson and Jampolsky, who proposed a technique of union of the transposed halves of the vertical muscles to permit self-adjustment of the vertical axis and allow for postoperative horizontal adjustment.⁷ Laby and Rosenbaum later described an adjustable suture technique for postoperative adjustment of induced vertical deviations or overcorrection.⁸ In the last decade, it has been suggested that VRT may be augmented not only by PFS, but also by resection of the transposed muscles before attachment to the sclera along the spiral of Tillaux without PFS.^{12,13} This approach has only been described with partial VRT, and not as an adjustable procedure.

We describe the outcomes of a series of patients who underwent adjustable augmented partial or full VRT for abducens nerve palsy and esotropic Duane syndrome. Some patients also underwent ciliary vessel sparing.

SUBJECTS AND METHODS

This study was approved by the UCLA Institutional Review Board and conformed to the requirements of the US Health Insurance Portability and Accountability Act. We retrospectively reviewed the records of all patients with abducens nerve palsy or esotropic Duane syndrome who underwent adjustable suture partial or full tendon VRT augmented by resection of the transposed muscles. The surgical technique used was as follows: superotemporal and inferotemporal conjunctival incisions were made. The superior and inferior rectus muscles were isolated. Depending on the procedure, a 6-0 polyglactin suture was placed either through the full tendon or through the temporal half of the tendon at a predetermined distance posterior to the muscle insertion, and the anterior portion of the muscle (or its temporal half) was resected (Figure 1a, b). The muscles were then attached to the sclera via an adjustable suture at the superior and inferior borders of the lateral rectus

muscle along the spiral of Tillaux (Figure 1c). Ciliary vessels were preserved in the patients with partial VRT by splitting the transposed muscle to spare at least one if not both of the ciliary vessels. In 2 patients, a novel technique was developed in which a short incision of approximately 2.5 mm was made perpendicular to the path of the muscle on the temporal side of the muscle, sparing the ciliary vessels, at a predetermined distance from the insertion of the muscle, and a 6-0 polyglactin suture was woven through the posterior part of the transected portion of the muscle (Figure 2a). The muscle was then dragged towards the lateral rectus muscle without disrupting the muscle insertion or splitting the muscle (Figure 2b), increasing muscle tension. The transposed muscle portions were then adjustably sutured to the sclera along the spiral of Tillaux on the superior and inferior sides of the lateral rectus muscle insertion, respectively (Figure 2c). The muscle insertion and the ciliary vessels running along the muscle path were left intact.

The following characteristics were recorded from the patients' records: age at surgery, diagnosis, etiology, visual acuity, motor alignment in primary position at distance and near, ductions, head position, previous surgical procedures, and current surgical procedure. Motor alignment was evaluated by prism cover testing. Ductions were measured on a scale of 0 to -4 (with 0 indicating full duction and -4 indicating no movement past the midline). Head position was assessed by the same observer preoperatively and postoperatively. Measures were recorded at the preoperative visit, time of adjustment, postoperative visit, and final visit. The final visit was either the last documented visit in the patient's chart, or the last visit before a reoperation.

Statistical analyses were performed using Microsoft Excel® (Microsoft Corporation, Redmond, Washington). Student's t-test was used to compare differences of means, with $p < 0.05$ considered statistically significant.

RESULTS

Seven patients with abducens palsy and one with esotropic Duane syndrome who underwent adjustable augmented VRT between September 2010 and November 2012 were included in this study. Patient characteristics including diagnosis, previous surgery, and procedure performed are presented in Table 1. Three patients had full VRT, 3 patients had partial VRT, and 2 patients had a modified augmented non-splitting ciliary vessel-sparing full VRT. Resection of 3–5 (mean \pm SD, 3.8 ± 0.7) mm was performed in all patients; both vertical rectus muscles were resected symmetrically in each patient. Postoperative follow-up was 3.8 ± 2.6 months. One patient had a recess/resect adjustable suture procedure on the medial rectus of the contralateral eye, as has been described previously¹⁶ at the same time of the VRT procedure. Surgical results are shown in Table 2.

Preoperative esotropia measured at distance in central gaze averaged 30.6 ± 12.9 (range, 17–50), and was decreased to 10.6 ± 8.8 (range, 0–25) at the final visit ($p = 0.003$). Preoperative esotropia measured at near in central gaze measured 19.3 ± 11.4 , and was decreased to 4.1 ± 5.0 postoperatively ($p = 0.01$). Mean correction of esotropia for distance viewing was 33.3 ± 15.5 before any adjustments were made, and was 20.0 ± 11.2 at the final visit, as seen in Table 3. Abduction improved from -3.6 to -2.8 ($p = 0.03$,

Table 4). There was no significant change in pre- and postoperative adduction in our patients.

Three patients required postoperative adjustment to correct an induced vertical deviation (mean of 9.3 before adjustment). Those patients also had an overcorrection of esotropia to consecutive exotropia before adjustment (mean exotropia of 11.3). During adjustment, just one muscle was recessed corresponding to the vertical deviation; in two patients the inferior rectus was recessed, and in one patient the superior rectus was recessed. The adjustment corrected both the vertical deviation and the exotropia in these patients. At the final visit, one of the patients with an original induced vertical deviation had a recurrent vertical deviation of 3. None of the patients was overcorrected at the last follow-up visit. Patients 1, 4, and 6 required additional surgery for recurrent esotropia.

Five patients had previous surgery including medial rectus recession and lateral rectus resection (Table 1). The three patients who had full VRT did not have previous rectus muscle surgery. The rest of the patients had a ciliary vessel-sparing procedure, including patients 2 and 3, who underwent the modified technique of dragging the entire muscle without disinsertion as described in the “Methods” section (Figure 2). In patient 6, although the procedure was a partial VRT, both ciliary vessels on each of the vertical rectus muscles were on the nasal side, so that all ciliary vessels were spared in this patient.

One patient (patient 5) who experienced post-operative hypertropia had an intraoperative tear of the transposed temporal ½ of the inferior rectus muscle at the time of attempted transposition. Subsequently, the remaining nasal half of the inferior rectus muscle was split in half, thus ending up with a transposed ¼ of the inferior rectus muscle, and a non-transposed ¼ muscle. This may explain that patient’s hypertropia after surgery and the need for recession of the transposed ½ superior rectus muscle. No anterior segment ischemia was recognized in any of the patients throughout the follow-up period.

DISCUSSION

For abduction deficiencies such as abducens palsy and esotropic Duane syndrome, VRT has been advocated as the procedure that best enlarges the field of binocular vision (17). VRT is reserved for cases in which there is complete loss of lateral rectus muscle function. If function remains, rectus muscle resection or plication rather than transposition is preferred.¹⁷ Full tendon VRT is believed to be more powerful than partial tendon VRT. However, in a partial VRT, unlike standard full VRT, which is usually performed without ciliary vessel sparing technique, ciliary vessels can be spared to diminish the risk of anterior segment ischemia. This allows for simultaneous surgery on another rectus muscle if needed. The PFS introduced by Foster was shown to increase the correction achieved by VRT, with less need for further weakening procedures for the medial rectus muscle.³ However, the use of a PFS precluded the use of adjustable sutures for these procedures. The augmented Hummelsheim procedure introduced by Brooks et al. in which the transposed halves of the rectus muscles were resected 4–8 mm avoided PFS and was adequate to correct large deviations in different types of rectus muscle palsies and rectus muscle damage.¹² Since this procedure augmented the VRT without necessitating PFS, this could now be performed with

adjustable sutures. All the patients in our study were treated with an augmented transposition procedure with an adjustable technique.

Rosenbaum foresaw the possibility of transposition surgery without disinserting the muscle, thus sparing all ciliary vessels.¹⁷ In this study, we have introduced in two patients this novel technique in which the transposed muscles are dragged towards the anterior border of the lateral rectus muscle. This technique can be viewed as a full VRT because the entirety of the muscle is actually transposed towards the lateral rectus, but with full sparing of the ciliary vessels. Our modification performed in these two patients is similar to a technique described by Nishida et al.,¹¹ in that the muscle is never disinserted, thus sparing all ciliary vessels. However, our procedure allows for dragging of the entire muscle, not only half of it, thus potentially allowing for greater correction. In addition, our procedure allows for postoperative adjustment, since the muscle is sutured to the sclera along the spiral of Tillaux and not posteriorly.

Although the augmented Hummelsheim procedure introduced by Brooks et al. did not require PFS, most of the patients in that study underwent large recessions of the antagonist muscle.¹² The mean distance correction achieved in their study was 52°. Also in the more recent study by Couser et al., reporting on augmented Hummelsheim in patients with complete abducens palsy, the mean correction was 39°, and all but one patient had simultaneous medial rectus recession.¹³ The resections performed by Brooks et al. were larger (4–8 mm) than those performed by Couser et al. (4 mm). These results are comparable to the correction achieved by full VRT coupled with simultaneous or subsequent medial rectus weakening by either botulinum toxin or recession.^{17,18} In the study by Laby and Rosenbaum, the effect of full VRT alone corrected approximately 25–30 PD of esotropia from abducens palsy and Duane syndrome, leaving most of the patients with residual esotropia necessitating medial rectus weakening with botulinum toxin.⁸ After the subsequent procedure, a total mean correction of 50° was achieved. Foster was able to achieve a mean correction of approximately 55° in his patients with abducens palsy using the PFS enhanced full VRT. Velez et al. showed a mean correction of 16.4° in patients with Duane syndrome using the Foster technique, compared to only 8.5° in patients who had transposition without PFS.¹⁹ In the study by Britt et al. on patients with abduction deficiency who underwent partial VRT with PFS, there was also a mean correction of 50° in those with abducens palsy; they all had previous medial rectus weakening.²⁰ In the crossed-adjustable technique described by Phamonvaechavan et al. for abducens palsy, simultaneous medial rectus weakening was needed less (37%) than in the conventional transposition group (83%).¹⁵ Recently, Mehendale et al. have shown the surgical option of superior rectus transposition alone combined with medial rectus recession to have reduced a mean esotropia of 44° to 10° in patients with Duane syndrome and abducens palsy.²¹ In our patients, the mean preoperative deviation was 30.6° with a postoperative correction of 33.3° and a final correction of 20.0°. Five patients had previous medial rectus weakening, along with additional procedures in 4 of them. The patients with the larger deviations of 50° (who had not been operated before) had the largest amount of correction without medial rectus weakening; however, they both had a full tendon VRT, and one of them also had 5 mm of resection, which may itself increase the amount of correction. The amount of correction immediately after surgery before adjustment was more than documented at the final visit due

to the overcorrection in three of the patients, and the esotropic shift over follow-up in most of the patients. This shows that the procedure is a powerful one; however it seems not as powerful as when adding a PFS, and showed a possible loss of effect over time in our patients.

The adjustable nature of this procedure is an advantage whereby the surgeon can “fine tune” the results. In our study, 3 patients had induced vertical deviations that were relieved by the adjustment. In the study by Couser et al. on the Hummelsheim procedure augmented by resection for patients with abducens palsy, vertical deviations were noted at the final follow-up visit in 2 of 12 patients.¹³ Foster reported 4 of 21 patients with vertical deviations less than 2°. In Yazdian et al., only 3 of 62 patients had induced vertical deviations.²² But other studies have reported a larger percentage, with larger deviations ranging from 8.5% with deviations larger than 8° in Ruth et al. on patients with Duane syndrome, to 20%–40% in abducens palsy.^{8,18,23,24} As in our patient who developed a recurrent vertical deviation, Phamonvaechavan et al. reported on the number of patients with vertical deviations increasing at the 6–10 week postoperative visit.¹⁵ Of the 3 patients in our study with a vertical deviation immediately following surgery, all had overcorrection as well. During adjustment, the release of the corresponding muscle corrected both the vertical deviation as well as the overcorrection. If there was an overcorrection without vertical deviation, it would be possible to recess both superior and inferior muscles in order to weaken the transposition procedure.⁸ We cannot rule out that the procedure is less powerful in some of the patients due to the adjustable suture technique. For example, patient 8 had a more powerful outcome before adjustment. Due to the vertical deviation, the patient was adjusted and the power of the transposition was thus reduced.

This study must be understood within the context of its limitations. Because it is a retrospective study, it is subject to measurement and interpretation errors that can accompany retrospective studies. For example, the choice of the procedure performed on each patient correlates directly to the history of previous surgery and the amount of deviation of the specific patient. Also, it is difficult to accurately assess the effect of surgery when dealing with so few patients, especially when the surgery for all patients was not exactly the same. Since this is a procedure just recently undertaken by our group, the follow-up time is short. There was recurrence to >10° esotropia in 4 of our patients. Longer follow-up would be needed to provide more substantial evidence of the strength of our procedure.

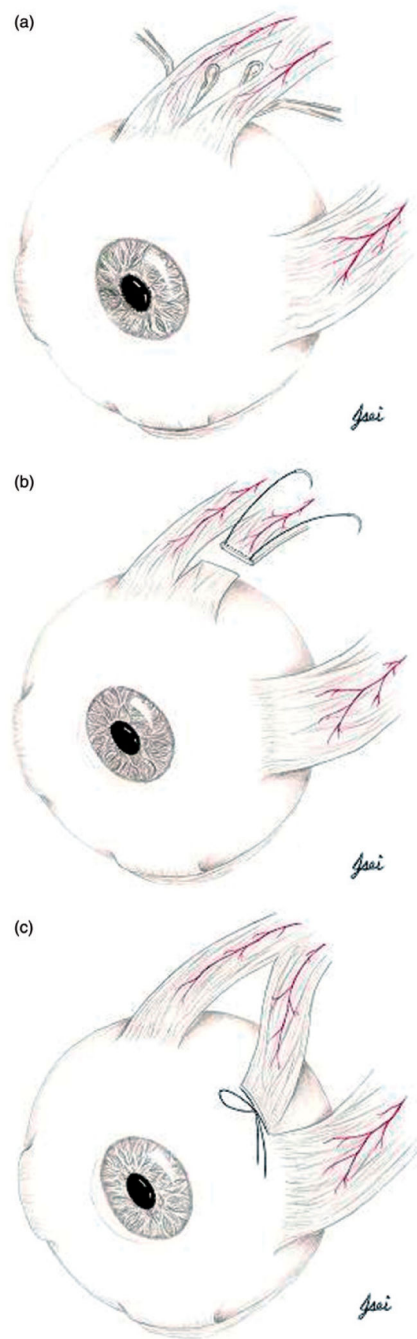
In conclusion, we show the advantages of a vertical transposition procedure augmented by resection of the transposed muscles with ciliary vessel-sparing and adjustable technique. With our procedure, we are reducing the risk for anterior segment ischemia, scleral perforation, vertical deviations, and overcorrection, thus improving the chances for a beneficial effect without causing harm.

Acknowledgments

This work was supported by: US Public Health Service grants EY021762 and EY08313, and the Knights Templar Eye Foundation.

REFERENCES

1. Hummelsheim E. Uber Schnentransplantation am Auge. *Ophthal Gesselschft.* 1907; 34:248.
2. Schillinger RJ. A new type of tendon transplant operation for abducens paralysis. *J Int Coll Surg.* 1959; 31:593–600. [PubMed: 13654827]
3. Foster RS. Vertical muscle transposition augmented with lateral fixation. *J AAPOS.* 1997; 1:20–30. [PubMed: 10530981]
4. Clark RA, Demer JL, Rosenbaum AL. Rectus extraocular muscle pulley displacement after surgical transposition and posterior fixation for treatment of paralytic strabismus. *Am J Ophthalmol.* 2002; 133:119–128. [PubMed: 11755847]
5. Jensen CDF. Rectus muscle union: a new operation for paralysis of the rectus muscles. *Trans Pac Coast Otoophthalmol Soc.* 1964; 45:359–387.
6. Kushner BJ. Jensen procedure modified. *Ann Ophthalmol.* 1979; 11:1255–1257. [PubMed: 556153]
7. Carlson MR, Jampolsky A. An adjustable transposition procedure for abduction deficiencies. *Am J Ophthalmol.* 1979; 87:382–387. [PubMed: 373456]
8. Laby DM, Rosenbaum AL. Adjustable vertical rectus muscle transposition surgery. *J Pediatr Ophthalmol Strabismus.* 1994; 31:75–78. [PubMed: 8014790]
9. Struck MC. Augmented vertical rectus transposition surgery with single posterior fixation suture: modification of Foster technique. *J AAPOS.* 2009; 13:343–349. [PubMed: 19482496]
10. Neugebauer A, Fricke J, Kirsch A, et al. Modified transposition procedure of the vertical recti in sixth nerve palsy. *Am J Ophthalmol.* 2001; 131:359–363. [PubMed: 11239870]
11. Nishida Y, Inatomi A, Aoki Y, et al. A muscle transposition procedure for abducens palsy, in which the halves of the vertical rectus muscle bellies are sutured onto the sclera. *Jpn J Ophthalmol.* 2003; 47:281–286. [PubMed: 12782165]
12. Brooks SE, Olitsky SE, deB Ribeiro G. Augmented Hummelsheim procedure for paralytic strabismus. *J Pediatr Ophthalmol Strabismus.* 2000; 37:189–195. [PubMed: 10955540]
13. Couser NL, Lenhart PD, Hutchinson AK. Augmented Hummelsheim procedure to treat complete abducens nerve palsy. *J AAPOS.* 2012; 16:331–335. [PubMed: 22929448]
14. Paysse EA, Brady McCreery KM, Ross A, et al. Use of augmented rectus muscle transposition surgery for complex strabismus. *Ophthalmology.* 2002; 109:1309–1314. [PubMed: 12093656]
15. Phamonvaechavan P, Anwar D, Guyton DL. Adjustable suture technique for enhanced transposition surgery for extraocular muscles. *J AAPOS.* 2010; 14:399–405. [PubMed: 21035065]
16. Thacker NM, Velez FG, Rosenbaum AL. Combined adjustable rectus muscle resection-recession for incomitant strabismus. *J AAPOS.* 2005; 9:137–140. [PubMed: 15838440]
17. Rosenbaum AL. Costenbader Lecture: the efficacy of rectus muscle transposition surgery in esotropic Duane syndrome and VI nerve palsy. *J AAPOS.* 2004; 8:409–419. [PubMed: 15492732]
18. Rosenbaum AL, Kushner BJ, Kirschen D. Vertical rectus muscle transposition and botulinum toxin (Oculinum) to medial rectus for abducens palsy. *Arch Ophthalmol.* 1989; 107:820–823. [PubMed: 2730398]
19. Velez FG, Foster RS, Rosenbaum AL. Vertical rectus muscle augmented transposition in Duane syndrome. *J AAPOS.* 2001; 5:105–113. [PubMed: 11304819]
20. Britt MT, Velez FG, Thacker N, et al. Partial rectus muscle-augmented transpositions in abduction deficiency. *J AAPOS.* 2003; 7:325–332. [PubMed: 14566314]
21. Mehendale RA, Dagi LR, Wu C, et al. Superior rectus transposition and medial rectus recession for Duane syndrome and sixth nerve palsy. *Arch Ophthalmol.* 2012; 130:195–201. [PubMed: 22332212]
22. Yazdian Z, Rajabi MT, Ali Yazdian M, et al. Vertical rectus muscle transposition for correcting abduction deficiency in Duane's syndrome type 1 and sixth nerve palsy. *J Pediatr Ophthalmol Strabismus.* 2010; 47:96–100. [PubMed: 20349902]
23. Ruth AL, Velez FG, Rosenbaum AL. Management of vertical deviations after vertical rectus transposition surgery. *J AAPOS.* 2009; 13:16–19. [PubMed: 19117778]
24. Fitzsimons R, Lee JP, Elston J. Treatment of sixth nerve palsy in adults with combined botulinum toxin chemodenervation and surgery. *Ophthalmology.* 1988; 95:1535–1542. [PubMed: 3211462]

**FIGURE 1.**

(a) The vertical rectus muscle is split longitudinally in half, preserving the nasal ciliary vessels. (b) Suture is placed within the temporal half of the split muscle at a predetermined distance from the muscle insertion and the temporal half of the muscle is resected and (c) sutured to the sclera by the LR insertion at the spiral of Tillaux on adjustable suture.

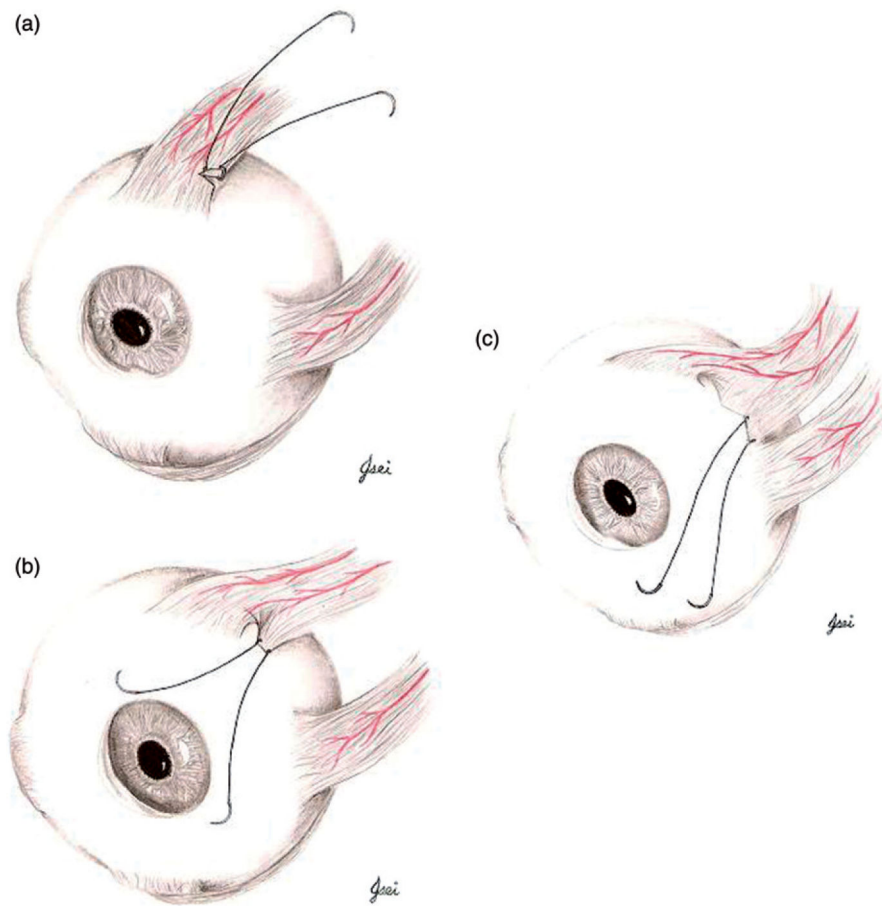


FIGURE 2.

(a) A 2.5-mm transverse incision is made temporally at a predetermined distance from the muscle insertion. Suture is woven through the posterior part of the incision, (b) muscle is dragged without disruption of the original insertion or splitting the muscle and (c) sutured to the sclera by the LR insertion at the spiral of Tillaux on adjustable suture.

TABLE 1

Patient characteristics and surgical data.

Patient no.	Age (y)/Sex	Dx	Prior sx	Procedure	Resection (mm)
1	56/M	6th NP OD	None	FVRT	5
2	62/M	6th NP OS	LMRc, LLRs	FVRT, vessel sparing, RMRc/s	4
3	42/F	Duane's OS	LMRc	FVRT, vessel sparing	3
4	49/F	6th NP OS	None	FVRT	3
5	60/F	6th NP OS	LLRs, RMR c/s, LMRc, LLRs	PVRT	3
6	26/F	6th NP OD	RMRc, RLRs	PVRT	4
7	48/F	6th NP OD	RLRs, RMRc, LMRc	PVRT	4
8	47/F	6th NP OS	None	FVRT	4

FVRT = full vertical rectus transposition; PVRT = partial vertical rectus transposition; NP = nerve palsy; MR = medial rectus; LR = lateral rectus; c = recession; s = resection; OD = right eye; OS = left eye.

TABLE 2

Surgical results.

Patient no.	Preoperative Deviation ()		Postoperative Dev (before adjustment) ()		Adj	Postadjustment Deviation ()		Final Deviation ()		Follow-up (m)
	Horiz	Vert	Horiz	Vert		Horiz	Vert	Horiz	Vert	
1	ET 50	0	XT 14	12 RHot	IR recessed 2 mm	X 2	0	ET 14	3 RHoT	2.8
2	ET 30	1 LHoT	0	1 LHoT	None			ET 6	0	8.0
3	ET 25	0	ET 7	0	None			ET 14	0	0.8
4	ET 50	2 LHoT	ET 12	0	None			ET 18	0	5.3
5	ET 18	0	XT 10	6 LHT	SR recessed 3 mm	0	0	0	0	4.9
6	ET 30	0	ET 6	0	None			ET 25	0	2.1
7	ET 25	0	0	0	None			0	0	1.6
8	ET 17	0	XT 10	10 LHoT	IR recessed 2 mm	0	0	ET 8	0	0.9
MEAN	30.6							10.6		3.8

Dev = distance deviation; Adj = adjustment; Horiz = horizontal; Vert = vertical; XT = exotropia; X = exophoria; ET = esotropia; HT = hypertropia; HoT = hypotropia; IR = inferior rectus; SR = superior rectus; m = months.

TABLE 3

Amount of correction ().

Patient no.	Correction postop ()	Correction final ()
1	64	36
2	30	24
3	18	11
4	50	32
5	28	18
6	24	5
7	25	25
8	27	9
MEAN	33.3	20

Correction postop = amount of change in deviation from the preoperative visit exam to the postoperative pre-adjustment exam; correction final = amount of change in deviation from the preoperative visit exam to the final visit exam.

TABLE 4

Preoperative and postoperative ductions and head posture.

Patient no.	Abduction		Adduction		Head posture	
	Preop	Postop	Preop	Postop	Preop	Postop
1	-4	-1.5		-0.5		
2	-3.5	-3	-0.5	-0.5	20 deg to L	Small to L
3	-4	-4	-1	-0.5	20 deg L	10 deg L
4	-3.5	-3	0	0	40 deg L	15 deg L
5	-4	-4	0	0	25 deg L	None
6	-3	-2	0	0	to R	<5 deg R
7	-4	-3	-1	-1	25 deg R, 15 deg R tilt	none
8	-3	-2	0	0	15 deg L, 15 deg tilt L	10 deg L
MEAN	-3.6	-2.8	-0.4	-0.3		

L = left, R = right.