

UCSF

UC San Francisco Previously Published Works

Title

Torsades de pointes in SARS-CoV-2 (COVID-19) pneumonia: medicine reconciliation and careful monitoring of QTc interval may help prevent cardiac complications

Permalink

<https://escholarship.org/uc/item/9d2974m0>

Journal

BMJ Case Reports, 14(3)

ISSN

1757-790X

Authors

Aslam, Waqas
Lamb, Carla R
Ali, Nadia

Publication Date

2021-03-01

DOI

10.1136/bcr-2020-239963

Peer reviewed

Torsades de pointes in SARS-CoV-2 (COVID-19) pneumonia: medicine reconciliation and careful monitoring of QTc interval may help prevent cardiac complications

Waqas Aslam ¹, Carla R Lamb,² Nadia Ali³

¹Pulmonary and Critical Care Medicine, Interventional Pulmonology, University of California San Francisco, Fresno, California, USA

²Pulmonary and Critical Care Medicine, Interventional Pulmonology, Lahey Hospital and Medical Center, Burlington, Massachusetts, USA

³Internal Medicine & Geriatrics, Hebrew Senior Life, Harvard Medical School Affiliate, Roslindale, Massachusetts, USA

Correspondence to

Dr Waqas Aslam;
drwaqasaslam@yahoo.com

Accepted 16 February 2021

SUMMARY

Hydroxychloroquine has been widely prescribed to treat patients with COVID-19 pneumonia. A 73-year-old woman with COVID-19 pneumonia was treated with dexamethasone and hydroxychloroquine. Her home medications, citalopram and donepezil, were continued. The ECG prior to starting hydroxychloroquine showed normal sinus rhythm with prolonged corrected QT (QTc) of 497 ms, due to citalopram and donepezil therapy. Repeat ECG on days 3 and 4 of hydroxychloroquine therapy showed significantly prolonged QTc of 557 ms and 538 ms, respectively, despite normal serum electrolytes. All QT-prolonging medications including hydroxychloroquine were discontinued on day 4; however, she suffered a transient torsades de pointes lasting for about 15 s, which resolved before any intervention. QTc improved to 477 ms, after discontinuation of QT-prolonging medications. The patient had QTc prolongation and torsades de pointes due to therapy with multiple QT-prolonging medications. Medicine reconciliation and careful monitoring of QTc may help prevent cardiac complications in patients with COVID-19 treated with hydroxychloroquine.

BACKGROUND

Hydroxychloroquine is a safe and well-tolerated medication, used in the management of malaria and connective tissue disorders including rheumatoid arthritis and systemic lupus erythematosus for decades.¹ Hydroxychloroquine has been widely prescribed in the past few months to treat patients with COVID-19 disease due to its anti-inflammatory and antiviral properties, especially after Gautret *et al*² showed significant reduction in SARS-CoV-2 viral load with hydroxychloroquine therapy. The antiviral effect of hydroxychloroquine was proposed to be further reinforced by adding azithromycin to the regimen.² We report an interesting case of corrected QT (QTc) prolongation and torsades de pointes in a patient with SARS-CoV-2 (COVID-19) pneumonia, provoked by therapy with multiple QTc-prolonging medications.

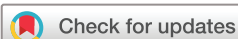CASE PRESENTATION

A 73-year-old woman with a medical history of diabetes mellitus type II, hyperlipidaemia, dementia, depression and gastro-oesophageal reflux disease was sent to the emergency room (ER) from an assisted living facility with fever 101.7°F

and rhinorrhoea for 2 days. The patient was noted to be restless with intermittent agitation in the ER. On initial evaluation in the ER, she was febrile with temperature 100.2°F and hypotensive with a blood pressure of 89/53 mm Hg. Oxygen saturation was 90% on room air. She responded appropriately to fluid resuscitation with an improved blood pressure of 143/65 mm Hg after administration of 2 L 0.9% normal saline. Otherwise, the physical examination was unremarkable.

INVESTIGATIONS

Pertinent laboratory work-up revealed leucopenia (white cell count $2.94 \times 10^9/L$), lymphopenia (absolute lymphocyte count $0.71 \times 10^9/L$), mild thrombocytopenia (platelet count $108 \times 10^9/L$), elevated lactate (2.5 mmol/L), elevated blood glucose (185 mg/dL), elevated C reactive protein (19.5 mg/L), normal troponin I, normal renal and liver tests, and a negative influenza A and B test. Chest radiograph showed few bilateral pulmonary infiltrates, suspicious for COVID-19. Nasopharyngeal swab for COVID-19 was obtained and she was admitted to the hospital with sepsis and acute hypoxic respiratory failure requiring oxygen supplementation at 2–3 L/min via nasal cannula. The patient's home medications, including citalopram 20 mg daily, donepezil 10 mg daily and gabapentin 300 mg three times per day, were continued. The ECG prior to starting hydroxychloroquine showed normal sinus rhythm with a prolonged QTc of 497 ms (figure 1), due to citalopram and donepezil therapy. Coronavirus SARS-CoV-2 (COVID-19) test came back positive and she was started on dexamethasone and hydroxychloroquine monotherapy for 5 days (800 mg for 1 day followed by 400 mg for 4 days). Azithromycin was not started due to prolonged QTc. Her medical condition continued to decline with worsening hypoxia requiring medical intensive care unit admission. She initially required oxygen supplementation via non-rebreather and high-flow nasal oxygen, followed by endotracheal intubation and mechanical ventilation. She required fentanyl and propofol infusions for sedation. Echocardiogram revealed normal left and right ventricular function. Repeat ECG on days 3 and 4 of hydroxychloroquine therapy showed significantly prolonged QTc of 557 ms and 538 ms (figure 2), respectively. Electrolytes including potassium, magnesium and calcium were normal. All QTc-prolonging medications including



© BMJ Publishing Group Limited 2021. No commercial re-use. See rights and permissions. Published by BMJ.

To cite: Aslam W, Lamb CR, Ali N. *BMJ Case Rep* 2021;**14**:e239963. doi:10.1136/bcr-2020-239963

Heart rate	65	BPM	Normal sinus rhythm
PR interval	146	ms	Low voltage QRS
QTc duration	84	ms	Prolonged QT
QTc	478/497	ms	Abnormal ECG
P-R-T axes	63	19	9

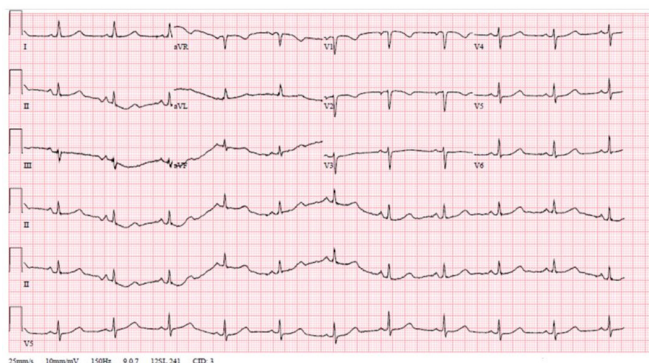


Figure 1 ECG with prolonged QTc of 497 ms. BPM, beats per minute; QTc, corrected QT.

hydroxychloroquine were discontinued on day 4, however the patient suffered a transient torsades de pointes lasting for about 15 s, which resolved spontaneously before any intervention. She had QTc prolongation and torsades de pointes, provoked by multiple QT-prolonging medications including citalopram, donepezil, propofol and hydroxychloroquine. QTc improved to 477 ms (figure 3) after discontinuation of hydroxychloroquine and other QT-prolonging medications. Remdesivir was not available at that time for treatment of COVID-19 pneumonia.

TREATMENT

QTc improved to 477 ms after discontinuation of hydroxychloroquine and other QT-prolonging medications. QTc was monitored closely with daily ECG. Serum electrolytes were closely monitored and replaced as appropriate.

OUTCOME AND FOLLOW-UP

The patient’s intensive care unit course was complicated by prolonged respiratory failure, methicillin-resistant *Staphylococcus aureus* pneumonia, metabolic encephalopathy, right lower extremity deep venous thrombus and upper gastrointestinal bleed. She did not have any recurrence of torsades de pointes or any other ventricular arrhythmia. Unfortunately, she

Heart rate	66	BPM	Normal sinus rhythm
PR interval	138	ms	Slight left: right bundle branch block
QTc duration	90	ms	Non-specific ST and T wave abnormality
QTc	514/538	ms	Prolonged QT
P-R-T axes	80	62	82

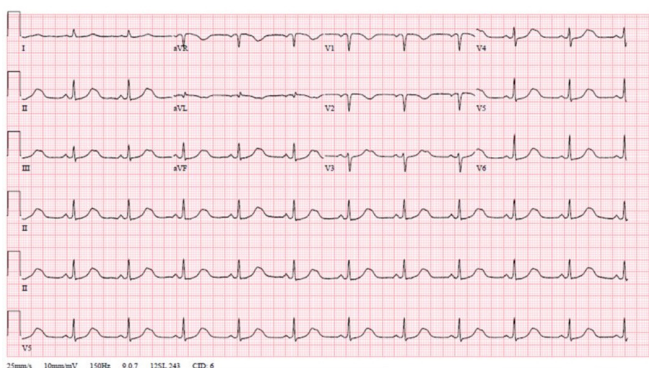


Figure 2 ECG with prolonged QTc of 538 ms. BPM, beats per minute; QTc, corrected QT.

Heart rate	79	BPM	Normal sinus rhythm
PR interval	161	ms	Low voltage QRS
QTc duration	80	ms	Non-specific T wave abnormality
QTc	416/477	ms	Abnormal ECG
P-R-T axes	32	19	-13

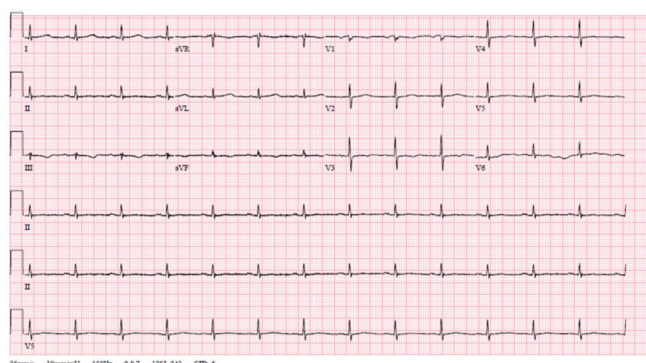


Figure 3 ECG with QTc of 477 ms after discontinuation of QT-prolonging medications. BPM, beats per minute; QTc, corrected QT.

was transitioned to comfort care on day 18 of the intensive care unit stay after a failed extubation.

DISCUSSION

Hydroxychloroquine can cause acute and chronic toxicity. Potential adverse effects of hydroxychloroquine include gastrointestinal disturbance, skin photosensitivity, retinopathy, cardiac toxicity, hypoglycaemia, neuropsychiatric effects including agitation, confusion and psychosis, and haemolysis, especially in patients with glucose-6-phosphate dehydrogenase deficiency.^{3 4}

Cardiac complications from hydroxychloroquine are rare but can be severe and life-threatening. Hydroxychloroquine-related cardiac adverse effects are conduction abnormalities, ventricular hypertrophy, restrictive cardiomyopathy, heart failure, pulmonary arterial hypertension and valvular dysfunction.^{5 6} Various cardiac conduction abnormalities include first-degree atrioventricular block, second-degree atrioventricular block, complete heart block, prolonged QTc, torsades de pointes and other ventricular arrhythmias.^{5 6} Risk factors for hydroxychloroquine-associated cardiac arrhythmia are inherited long QT syndrome, ischaemic heart disease, cardiomyopathy, congestive heart failure, history of ventricular arrhythmia, unexplained syncope, family history of premature sudden cardiac death, polypharmacy with QTc-prolonging medications, electrolyte abnormalities (hypokalaemia, hypomagnesaemia, hypocalcaemia), hepatic and renal failure.⁷⁻⁹

Hospitalised patients and those with risk factors for hydroxychloroquine-associated cardiac arrhythmia should be recommended an ECG before considering hydroxychloroquine therapy, unless they had one within the last 3 months.⁸ Patients with normal QTc and no risk factors for cardiac toxicity can be treated without delay.^{8 9} Patients with slightly prolonged QTc ≥ 470 ms (men) or ≥ 480 ms (women) but QTc < 500 ms should be treated with caution; with a repeat ECG in 48 and 96 hours to re-evaluate QTc.^{8 9} Patients with prolonged QTc ≥ 500 ms should be reassessed after correction of electrolytes and discontinuation of other QT-prolonging medications.^{8 9} If QTc persists ≥ 500 ms, evaluation of benefits and risks of therapy and expert consultation may be considered.^{8 9} Patients on multiple QTc-prolonging medications should have a repeat ECG in 48 hours; if QTc increases by ≥ 60 ms or becomes ≥ 500 ms, re-evaluate benefits and risks of therapy.^{8 9} Citalopram, donepezil and propofol have all been associated with QTc prolongation and ventricular

arrhythmia.^{10–13} Our patient received multiple QTc-prolonging medications including citalopram, donepezil and propofol along with hydroxychloroquine, which caused significant QTc prolongation and provoked torsades de pointes. Medicine reconciliation and careful monitoring of QTc can prevent cardiac complications in patients with COVID-19 treated with hydroxychloroquine. The role of hydroxychloroquine in COVID-19 has been evaluated in various clinical trials and recent studies do not support any clinical benefit of hydroxychloroquine therapy in COVID-19.^{14–17}

Learning points

- ▶ Citalopram, donepezil and propofol can cause QT prolongation and ventricular arrhythmia.
- ▶ Hydroxychloroquine-associated adverse effects include gastrointestinal disturbance, skin photosensitivity, retinopathy, cardiac toxicity, hypoglycaemia and neuropsychiatric adverse effects.
- ▶ Hydroxychloroquine can cause cardiac conduction abnormalities including first-degree and second-degree atrioventricular block, complete heart block, prolonged corrected QT (QTc), torsades de pointes and other ventricular arrhythmias.
- ▶ Cardiac comorbidities, polypharmacy with QT-prolonging medications, electrolyte abnormalities, hepatic and renal failure increase the risk of hydroxychloroquine-associated cardiac complications.
- ▶ Medicine reconciliation and careful monitoring of QTc can prevent cardiac complications in patients with COVID-19 treated with hydroxychloroquine.
- ▶ Recent studies do not support any clinical benefit of hydroxychloroquine therapy in COVID-19.

Contributors WA was involved in direct patient care with full access to the patient data and drafted the initial manuscript. CRL and NA reviewed the manuscript, provided feedback and helped in the final editing of the manuscript.

Funding The authors have not declared a specific grant for this research from any funding agency in the public, commercial or not-for-profit sectors.

Competing interests None declared.

Patient consent for publication Next of kin consent obtained.

Provenance and peer review Not commissioned; externally peer reviewed.

This article is made freely available for use in accordance with BMJ's website terms and conditions for the duration of the covid-19 pandemic or until otherwise

determined by BMJ. You may use, download and print the article for any lawful, non-commercial purpose (including text and data mining) provided that all copyright notices and trade marks are retained.

ORCID iD

Waqas Aslam <http://orcid.org/0000-0003-0096-5841>

REFERENCES

- 1 Costedoat-Chalumeau N, Hulot J-S, Amoura Z, *et al.* Heart conduction disorders related to antimalarials toxicity: an analysis of electrocardiograms in 85 patients treated with hydroxychloroquine for connective tissue diseases. *Rheumatology* 2007;46:808–10.
- 2 Gautret P, Lagier J-C, Parola P, *et al.* Hydroxychloroquine and azithromycin as a treatment of COVID-19: results of an open-label non-randomized clinical trial. *Int J Antimicrob Agents* 2020;56:105949.
- 3 Juurlink DN. Safety considerations with chloroquine, hydroxychloroquine and azithromycin in the management of SARS-CoV-2 infection. *CMAJ* 2020;192:E450–3.
- 4 Sinha N, Balayla G. Hydroxychloroquine and COVID-19. *Postgrad Med J* 2020;96:550–5.
- 5 Chatre C, Rouville F, Vernhet H, *et al.* Cardiac complications attributed to chloroquine and hydroxychloroquine: a systematic review of the literature. *Drug Saf* 2018;41:919–31.
- 6 Chen C-Y, Wang F-L, Lin C-C. Chronic hydroxychloroquine use associated with QT prolongation and refractory ventricular arrhythmia. *Clin Toxicol* 2006;44:173–5.
- 7 Kapoor A, Pandurangi U, Arora V, *et al.* Cardiovascular risks of hydroxychloroquine in treatment and prophylaxis of COVID-19 patients: a scientific statement from the Indian heart rhythm Society. *Indian Pacing Electrophysiol J* 2020;20:117–20.
- 8 Sapp JL, Alqarawi W, MacIntyre CJ, *et al.* Guidance on minimizing risk of drug-induced ventricular arrhythmia during treatment of COVID-19: a statement from the Canadian heart rhythm Society. *Can J Cardiol* 2020;36:948–51.
- 9 Giudicessi JR, Noseworthy PA, Friedman PA, *et al.* Urgent guidance for navigating and circumventing the QTc-Prolonging and torsadogenic potential of possible pharmacotherapies for coronavirus disease 19 (COVID-19). *Mayo Clin Proc* 2020;95:1213–21.
- 10 Beach SR, Celano CM, Noseworthy PA, *et al.* QTc prolongation, torsades de pointes, and psychotropic medications. *Psychosomatics* 2013;54:1–13.
- 11 Alušik Štefan, Paluch Z. [Citalopram and QT prolongation]. *Vnitř Lek* 2018;63:952–6.
- 12 Takaya T, Okamoto M, Yodoi K, *et al.* Torsades de pointes with QT prolongation related to donepezil use. *J Cardiol* 2009;54:507–11.
- 13 Abrid VA, Ramakrishna H, Mehta A, *et al.* The possible role of propofol in drug-induced torsades de pointes: a real-world single-center analysis. *Int J Cardiol* 2017;232:243–6.
- 14 Self WH, Semler MW, Leither LM, *et al.* Effect of hydroxychloroquine on clinical status at 14 days in hospitalized patients with COVID-19. *JAMA* 2020;324:2165.
- 15 RECOVERY Collaborative Group, Horby P, Mafham M, *et al.* Effect of hydroxychloroquine in hospitalized patients with Covid-19. *N Engl J Med* 2020;383:2030–40.
- 16 Cavalcanti AB, Zampieri FG, Rosa RG. Hydroxychloroquine with or without azithromycin in mild-to-moderate COVID-19. *N Engl J Med* 2020;383:2041–52.
- 17 Boulware DR, Pullen MF, Bangdiwala AS, *et al.* A randomized trial of hydroxychloroquine as postexposure prophylaxis for Covid-19. *N Engl J Med* 2020;383:517–25.

Copyright 2021 BMJ Publishing Group. All rights reserved. For permission to reuse any of this content visit <https://www.bmj.com/company/products-services/rights-and-licensing/permissions/>
BMJ Case Report Fellows may re-use this article for personal use and teaching without any further permission.

Become a Fellow of BMJ Case Reports today and you can:

- ▶ Submit as many cases as you like
- ▶ Enjoy fast sympathetic peer review and rapid publication of accepted articles
- ▶ Access all the published articles
- ▶ Re-use any of the published material for personal use and teaching without further permission

Customer Service

If you have any further queries about your subscription, please contact our customer services team on +44 (0) 207111 1105 or via email at support@bmj.com.

Visit casereports.bmj.com for more articles like this and to become a Fellow