

# UCSF

## UC San Francisco Previously Published Works

### Title

Diagnosis and Treatment of Fetal Cardiac Disease

### Permalink

<https://escholarship.org/uc/item/9dq2k9vh>

### Journal

Circulation, 129(21)

### ISSN

0009-7322

### Authors

Donofrio, Mary T  
Moon-Grady, Anita J  
Hornberger, Lisa K  
et al.

### Publication Date

2014-05-27

### DOI

10.1161/01.cir.0000437597.44550.5d

Peer reviewed

## Diagnosis and Treatment of Fetal Cardiac Disease: A Scientific Statement From the American Heart Association

Mary T. Donofrio, Anita J. Moon-Grady, Lisa K. Hornberger, Joshua A. Copel, Mark S. Sklansky, Alfred Abuhamad, Bettina F. Cuneo, James C. Huhta, Richard A. Jonas, Anita Krishnan, Stephanie Lacey, Wesley Lee, Erik C. Michelfelder, Sr, Gwen R. Rempel, Norman H. Silverman, Thomas L. Spray, Janette F. Strasburger, Wayne Tworetzky and Jack Rychik on behalf of the American Heart Association Adults With Congenital Heart Disease Joint Committee of the Council on Cardiovascular Disease in the Young and Council on Clinical Cardiology, Council on Cardiovascular Surgery and Anesthesia, and Council on Cardiovascular and Stroke Nursing

*Circulation*. 2014;129:2183-2242; originally published online April 24, 2014;  
doi: 10.1161/01.cir.0000437597.44550.5d

*Circulation* is published by the American Heart Association, 7272 Greenville Avenue, Dallas, TX 75231  
Copyright © 2014 American Heart Association, Inc. All rights reserved.  
Print ISSN: 0009-7322. Online ISSN: 1524-4539

The online version of this article, along with updated information and services, is located on the World Wide Web at:

<http://circ.ahajournals.org/content/129/21/2183>

An erratum has been published regarding this article. Please see the attached page for:

<http://circ.ahajournals.org/content/129/21/e512.full.pdf>

**Permissions:** Requests for permissions to reproduce figures, tables, or portions of articles originally published in *Circulation* can be obtained via RightsLink, a service of the Copyright Clearance Center, not the Editorial Office. Once the online version of the published article for which permission is being requested is located, click Request Permissions in the middle column of the Web page under Services. Further information about this process is available in the [Permissions and Rights Question and Answer](#) document.

**Reprints:** Information about reprints can be found online at:  
<http://www.lww.com/reprints>

**Subscriptions:** Information about subscribing to *Circulation* is online at:  
<http://circ.ahajournals.org/subscriptions/>

## Diagnosis and Treatment of Fetal Cardiac Disease A Scientific Statement From the American Heart Association

*Endorsed by the American Society of Echocardiography and Pediatric and Congenital Electrophysiology Society*

*The American Institute of Ultrasound in Medicine supports the value and findings of the statement.\**

*The Society of Maternal Fetal Medicine supports the statement's review of the subject matter and believe it is consistent with its existing clinical guidelines.†*

Mary T. Donofrio, MD, Chair; Anita J. Moon-Grady, MD; Lisa K. Hornberger, MD;  
Joshua A. Copel, MD; Mark S. Sklansky, MD; Alfred Abuhamad, MD; Bettina F. Cuneo, MD;  
James C. Huhta, MD; Richard A. Jonas, MD; Anita Krishnan, MD; Stephanie Lacey, DO;  
Wesley Lee, MD; Erik C. Michelfelder, Sr, MD; Gwen R. Rempel, RN;  
Norman H. Silverman, MD, DSc, FAHA; Thomas L. Spray, MD, FAHA; Janette F. Strasburger, MD;  
Wayne Tworetzky, MD; Jack Rychik MD; on behalf of the American Heart Association Adults With  
Congenital Heart Disease Joint Committee of the Council on Cardiovascular Disease in the Young and  
Council on Clinical Cardiology, Council on Cardiovascular Surgery and Anesthesia, and Council on  
Cardiovascular and Stroke Nursing

**Background**—The goal of this statement is to review available literature and to put forth a scientific statement on the current practice of fetal cardiac medicine, including the diagnosis and management of fetal cardiovascular disease.

**Methods and Results**—A writing group appointed by the American Heart Association reviewed the available literature pertaining to topics relevant to fetal cardiac medicine, including the diagnosis of congenital heart disease and arrhythmias, assessment of cardiac function and the cardiovascular system, and available treatment options. The American College of Cardiology/American Heart Association classification of recommendations and level of evidence for practice guidelines were applied to the current practice of fetal cardiac medicine. Recommendations relating to the specifics of fetal diagnosis, including the timing of referral for study, indications for referral, and experience suggested for performance and interpretation of studies, are presented. The components of a fetal echocardiogram are described in detail, including descriptions of the assessment of cardiac anatomy, cardiac function, and rhythm. Complementary modalities for fetal cardiac assessment are reviewed, including the use of advanced ultrasound techniques, fetal magnetic resonance imaging, and fetal magnetocardiography and electrocardiography for rhythm assessment. Models for parental counseling and a discussion of parental stress and depression assessments are reviewed. Available fetal therapies, including medical management for arrhythmias or heart failure and closed or open intervention for diseases affecting the cardiovascular system such as twin–twin transfusion syndrome, lung masses, and vascular tumors, are highlighted. Catheter-based intervention strategies to prevent the progression of disease in utero are

\*The American Institute of Ultrasound in Medicine (AIUM) has reviewed this statement and acknowledges it as a comprehensive review of the subject of fetal echocardiography. This document does not replace AIUM's existing practice guideline on fetal echocardiography, which is available on the AIUM Web site or in AIUM's journal (*J Ultrasound Med.* 2013;32:1067–1082).

†The Society of Maternal Fetal Medicine (SMFM) has reviewed this statement and acknowledges it as a comprehensive review on the subject of fetal echocardiography. This document does not replace SMFM's existing clinical guidelines, which are available on the SMFM Web site (<http://www.smfm.org>).

The American Heart Association makes every effort to avoid any actual or potential conflicts of interest that may arise as a result of an outside relationship or a personal, professional, or business interest of a member of the writing panel. Specifically, all members of the writing group are required to complete and submit a Disclosure Questionnaire showing all such relationships that might be perceived as real or potential conflicts of interest.

This statement was approved by the American Heart Association Science Advisory and Coordinating Committee on October 21, 2013. A copy of the document is available at <http://my.americanheart.org/statements> by selecting either the "By Topic" link or the "By Publication Date" link. To purchase additional reprints, call 843-216-2533 or e-mail [kelle.ramsay@wolterskluwer.com](mailto:kelle.ramsay@wolterskluwer.com).

The American Heart Association requests that this document be cited as follows: Donofrio MT, Moon-Grady AJ, Hornberger LK, Copel JA, Sklansky MS, Abuhamad A, Cuneo BF, Huhta JC, Jonas RA, Krishnan A, Lacey S, Lee W, Michelfelder EC Sr, Rempel GR, Silverman NH, Spray TL, Strasburger JF, Tworetzky W, Rychik J; on behalf of the American Heart Association Adults With Congenital Heart Disease Joint Committee of the Council on Cardiovascular Disease in the Young and Council on Clinical Cardiology, Council on Cardiovascular Surgery and Anesthesia, and Council on Cardiovascular and Stroke Nursing. Diagnosis and treatment of fetal cardiac disease: a scientific statement from the American Heart Association. *Circulation.* 2014;129:2183–2242.

Expert peer review of AHA Scientific Statements is conducted by the AHA Office of Science Operations. For more on AHA statements and guidelines development, visit <http://my.americanheart.org/statements> and select the "Policies and Development" link.

Permissions: Multiple copies, modification, alteration, enhancement, and/or distribution of this document are not permitted without the express permission of the American Heart Association. Instructions for obtaining permission are located at [http://www.heart.org/HEARTORG/General/Copyright-Permission-Guidelines\\_UCM\\_300404\\_Article.jsp](http://www.heart.org/HEARTORG/General/Copyright-Permission-Guidelines_UCM_300404_Article.jsp). A link to the "Copyright Permissions Request Form" appears on the right side of the page.

© 2014 American Heart Association, Inc.

also discussed. Recommendations for delivery planning strategies for fetuses with congenital heart disease including models based on classification of disease severity and delivery room treatment will be highlighted. Outcome assessment is reviewed to show the benefit of prenatal diagnosis and management as they affect outcome for babies with congenital heart disease.

**Conclusions**—Fetal cardiac medicine has evolved considerably over the past 2 decades, predominantly in response to advances in imaging technology and innovations in therapies. The diagnosis of cardiac disease in the fetus is mostly made with ultrasound; however, new technologies, including 3- and 4-dimensional echocardiography, magnetic resonance imaging, and fetal electrocardiography and magnetocardiography, are available. Medical and interventional treatments for select diseases and strategies for delivery room care enable stabilization of high-risk fetuses and contribute to improved outcomes. This statement highlights what is currently known and recommended on the basis of evidence and experience in the rapidly advancing and highly specialized field of fetal cardiac care. (*Circulation*. 2014;129:2183-2242.)

**Key Words:** AHA Scientific Statements ■ cardiology, pediatric ■ congenital ■ fetus ■ heart defects, congenital

Examination of the fetal heart and cardiovascular system has evolved considerably over the past 2 decades, mostly as a result of advances in imaging technology. In the past, the role of the pediatric cardiologist as it pertained to the fetus was to provide a basic, often limited, anatomic cardiac diagnosis with the primary goal of counseling families on what to expect after delivery if the fetus survived to be evaluated postnatally. Counseling was based on the premise that nothing could be done in utero and that what we understand to be true of postnatal disease applied to the fetus as well. Treatment of the fetus was the responsibility of the high-risk obstetrician; resuscitation of the newborn in the delivery room was the responsibility of the neonatologist; and the care of the baby became the responsibility of the pediatric cardiologist only once the baby arrived in the nursery or the neonatal intensive care unit. With technological advances and increasing experience and interest in fetal medicine, the multidisciplinary specialty of fetal cardiology has emerged. In the modern era, it is now expected that ultrasound will be able to diagnose structural heart disease with precise detail, and now the goal has become to understand the fetus as a patient, knowing that the fetal circulation is different from the postnatal circulation, that structural disease may progress in utero, and that cardiac function and stability of the cardiovascular system play an important role in fetal wellness. Given the expanded roles of the pediatric cardiologist specializing in fetal medicine and the maternal fetal specialist as collaborative caregivers for fetuses with structural heart disease, arrhythmias, or cardiovascular dysfunction, a new standard of care for the practice of the multidisciplinary, rapidly advancing, and highly specialized field of fetal cardiac medicine is needed.

This article covers important topics relevant to fetal cardiac medicine, including the diagnosis of heart disease, assessment of cardiac function and the cardiovascular system, and treatment options that are available. Recommendations relating to the specifics of fetal diagnosis, including the timing of referral for study, indications for referral, and experience suggested for performance and interpretation of studies, are presented. The components of a fetal echocardiogram are described in detail, including descriptions of the assessment of cardiac anatomy, cardiac function, and rhythm. Complementary modalities for fetal cardiac assessment are reviewed, including the use of advanced ultrasound techniques, fetal magnetic resonance imaging (MRI), fetal electrocardiography, and fetal magnetocardiography (fMCG) for rhythm assessment. Models for parental counseling and a discussion of parental stress and depression

assessments are reviewed. Available fetal therapies, including medical management for arrhythmias or heart failure and closed or open intervention for diseases affecting the cardiovascular system such as twin–twin transfusion syndrome (TTTS), lung masses, and vascular tumors, are highlighted. Experimental catheter-based intervention strategies to prevent the progression of disease in utero also are discussed. Recommendations for delivery planning strategies for fetuses with congenital heart disease (CHD) including models based on classification of disease severity and delivery room treatment are highlighted. Outcome assessment is reviewed to show the benefit of prenatal diagnosis as it affect outcome for babies with CHD.

A writing group appointed by the American Heart Association (AHA) reviewed the available literature pertaining to important topics relevant to fetal cardiac medicine, including references on the diagnosis of CHD, assessment of cardiac function and cardiovascular system, and treatment options that are available. The American College of Cardiology/AHA classification of recommendations (COR) and level of evidence (LOE) were assigned to each recommendation according to the 2009 methodology manual for American College of Cardiology/AHA Guidelines Writing Committee (Table 1, updated July 3, 2012). LOE classification combines an objective description of the existence and type of studies that support the recommendations and expert consensus according to the following categories: *Level of Evidence A*, recommendation is based on evidenced from multiple randomized trials or meta-analysis; *Level of Evidence B*, recommendation is based on evidence from a single randomized trial or nonrandomized studies; and *Level of Evidence C*, recommendation is based on expert opinion, case studies, or standards of care.

### Indications for Referral for Fetal Cardiac Evaluation

The incidence of CHD has been estimated at 6 to 12 per 1000 live births<sup>1-4</sup>; however, reasonable estimates in fetuses are less abundant. A study from Belgium<sup>5</sup> reported an incidence of 8.3% in live and stillborn infants of  $\geq 26$  weeks of gestation without chromosome abnormalities. There is likely an even higher incidence in early gestation given spontaneous and elective pregnancy termination.

A multitude of factors are associated with an increased risk of identifying CHD in the fetus that are related to familial, maternal, or fetal conditions. The leading reason for referral for fetal cardiac evaluation is the suspicion of a structural heart abnormality

Table 1. Applying Classification of Recommendations and Level of Evidence

		SIZE OF TREATMENT EFFECT				
		CLASS I <i>Benefit &gt;&gt;&gt; Risk</i> Procedure/Treatment <b>SHOULD</b> be performed/administered	CLASS IIa <i>Benefit &gt;&gt; Risk</i> Additional studies with <i>focused objectives needed</i> <b>IT IS REASONABLE</b> to perform procedure/administer treatment	CLASS IIb <i>Benefit ≥ Risk</i> Additional studies with <i>broad objectives needed; additional registry data would be helpful</i> Procedure/Treatment <b>MAY BE CONSIDERED</b>	CLASS III <i>No Benefit or CLASS III Harm</i>	
				Procedure/ Test	Treatment	
				COR III: No benefit	No Proven Benefit	
				COR III: Harm	Excess Cost w/o Benefit or Harmful to Patients or Harmful	
ESTIMATE OF CERTAINTY (PRECISION) OF TREATMENT EFFECT	LEVEL A Multiple populations evaluated* Data derived from multiple randomized clinical trials or meta-analyses	<ul style="list-style-type: none"> <li>Recommendation that procedure or treatment is useful/effective</li> <li>Sufficient evidence from multiple randomized trials or meta-analyses</li> </ul>	<ul style="list-style-type: none"> <li>Recommendation in favor of treatment or procedure being useful/effective</li> <li>Some conflicting evidence from multiple randomized trials or meta-analyses</li> </ul>	<ul style="list-style-type: none"> <li>Recommendation's usefulness/efficacy less well established</li> <li>Greater conflicting evidence from multiple randomized trials or meta-analyses</li> </ul>	<ul style="list-style-type: none"> <li>Recommendation that procedure or treatment is not useful/effective and may be harmful</li> <li>Sufficient evidence from multiple randomized trials or meta-analyses</li> </ul>	
	LEVEL B Limited populations evaluated* Data derived from a single randomized trial or nonrandomized studies	<ul style="list-style-type: none"> <li>Recommendation that procedure or treatment is useful/effective</li> <li>Evidence from single randomized trial or nonrandomized studies</li> </ul>	<ul style="list-style-type: none"> <li>Recommendation in favor of treatment or procedure being useful/effective</li> <li>Some conflicting evidence from single randomized trial or nonrandomized studies</li> </ul>	<ul style="list-style-type: none"> <li>Recommendation's usefulness/efficacy less well established</li> <li>Greater conflicting evidence from single randomized trial or nonrandomized studies</li> </ul>	<ul style="list-style-type: none"> <li>Recommendation that procedure or treatment is not useful/effective and may be harmful</li> <li>Evidence from single randomized trial or nonrandomized studies</li> </ul>	
	LEVEL C Very limited populations evaluated* Only consensus opinion of experts, case studies, or standard of care	<ul style="list-style-type: none"> <li>Recommendation that procedure or treatment is useful/effective</li> <li>Only expert opinion, case studies, or standard of care</li> </ul>	<ul style="list-style-type: none"> <li>Recommendation in favor of treatment or procedure being useful/effective</li> <li>Only diverging expert opinion, case studies, or standard of care</li> </ul>	<ul style="list-style-type: none"> <li>Recommendation's usefulness/efficacy less well established</li> <li>Only diverging expert opinion, case studies, or standard of care</li> </ul>	<ul style="list-style-type: none"> <li>Recommendation that procedure or treatment is not useful/effective and may be harmful</li> <li>Only expert opinion, case studies, or standard of care</li> </ul>	
Suggested phrases for writing recommendations		should is recommended is indicated is useful/effective/beneficial	is reasonable can be useful/effective/beneficial is probably recommended or indicated	may/might be considered may/might be reasonable usefulness/effectiveness is unknown/unclear/uncertain or not well established	COR III: No Benefit is not recommended is not indicated should not be performed/administered/other is not useful/beneficial/effective	COR III: Harm potentially harmful causes harm associated with excess morbidity/mortality should not be performed/administered/other
Comparative effectiveness phrases†		treatment/strategy A is recommended/indicated in preference to treatment B treatment A should be chosen over treatment B	treatment/strategy A is probably recommended/indicated in preference to treatment B it is reasonable to choose treatment A over treatment B			

A recommendation with *Level of Evidence B or C* does not imply that the recommendation is weak. Many important clinical questions addressed in the guidelines do not lend themselves to clinical trials. Although randomized trials are unavailable, there may be a very clear clinical consensus that a particular test or therapy is useful or effective.

\*Data available from clinical trials or registries about the usefulness/efficacy in different subpopulations such as sex, age, history of diabetes mellitus, history of prior myocardial infarction, history of heart failure, and prior aspirin use.

†For comparative effectiveness recommendations (Class I and IIa; Level of Evidence A and B only), studies that support the use of comparator verbs should involve direct comparisons of the treatments or strategies being evaluated.

on obstetric ultrasound, which results in a diagnosis of CHD in 40% to 50% of fetuses referred. Other factors such as maternal metabolic disease or family history of CHD are also reason for referral; however, many of these indications have been estimated to carry a <5% to 10% risk. Whether any increase over the baseline risk of 0.3% to 1.2% necessitates additional expenditure of resources and at what level (screening ultrasound or fetal echocardiogram) are topics of debate. The answers vary, depending on the healthcare system environment, skill of screening operators, and available resources. Thus, recommendations for indications for referral for fetal echocardiogram must take into account risk for CHD in individual populations. In general, risk levels of ≥2% to 3% as defined by prenatal screening tests (such as maternal serum screening) result in a recommendation for

consideration for additional testing; therefore, it is reasonable to perform fetal echocardiography at this risk level, whereas if risk exceeds 3%, fetal echocardiography should be performed. Fetal echocardiography may be considered when risk is estimated at 1% to 2%, although the relative benefit of this additional testing in this population is less clear. When risk approaches that of the general population (≤1%), fetal echocardiography is not indicated. It should be noted, however, that all fetuses with an abnormal screening ultrasound of the heart should have a detailed fetal echocardiogram by a trained examiner. Table 2 summarizes the current risk factors or conditions that may trigger referral for fetal echocardiogram with supporting COR and LOE. Table 3 summarizes the most common indications for referral for fetal echocardiogram.



**Table 2. Factors Associated With Increased Risk of CHD in the Fetus**

	Absolute Risk, % live births	Relative Risk or Likelihood Ratio (CI)	COR/LOE	Timing/Frequency of Evaluation	Comments
<b>Maternal factors</b>					
Pregestational DM (preconception metabolic control may affect risk) <sup>6-9</sup> or DM identified in the first trimester	3-5	≈5	I/A	18-22 wks Repeat evaluation in third trimester if HbA <sub>1c</sub> >6% may be considered	DM is associated with a higher relative risk of certain specific cardiac defects, including 6.22 for heterotaxy, 4.72 for truncus arteriosus, 2.85 for d-TGA and 18.24 for single- ventricle defects Poorly controlled DM is associated with ventricular hypertrophy in the third trimester
Gestational diabetes mellitus with HbA <sub>1c</sub> <6%	<1	1	III/B		If HbA <sub>1c</sub> >6%, fetal echocardiography in the third trimester may be considered to assess for ventricular hypertrophy
Phenylketonuria <sup>10-12</sup> (preconception metabolic control may affect risk)	12-14	10-15	I/A	18-22 wk	Only if periconception phenylalanine level >10 mg/dL
Lupus or Sjögrens only if SSA/SSB autoantibody positive <sup>13-17</sup> Note: increased risk with maternal hypothyroidism <sup>18</sup> or maternal vitamin D deficiency <sup>19</sup>	1-5	Unknown	Ia/B	16 wk, then weekly or every other week to 28 wk	Recent studies have suggested that high SSA values (≥50 U/mL) correlate with increased fetal risk <sup>17</sup> Concern for late myocardial involvement <sup>20</sup> may justify additional assessments in the third trimester
With prior affected child with CHB or neonatal lupus, risk increased	11-19		I/B	16 wk, then at least weekly to 28 wk	
<b>Medication exposures</b>					
Teratogens <sup>21-24</sup>	1-2	1.1-1.8			Unless otherwise specified, exposure in the first trimester of pregnancy. For a more detailed review, see elsewhere <sup>25</sup>
Anticonvulsants	1.8		IIb/A	18-22 wk	
Lithium	<2		IIb/B	18-22 wk	
ACE inhibitors	2.9		Ia/B	18-22 wk	
Retinoic acids <sup>24</sup>	8-20		I/B	18-22 wk	
Vitamin A (>10 000 IU retinol/d) <sup>27</sup>	1.8		IIb/B	18-22 wk	
SSRIs <sup>26,28-30</sup>	1-2	1.2-1.72	IIb/A (for paroxetine) III/A (for others)	18-22 wk	3.3 (95% CI, 1.3-8.8) for RVOT lesions only
Vitamin K antagonists <sup>31</sup> (ie, Coumadin)	<1	1	III/B	Not indicated	Detailed anatomic survey should be performed
NSAIDs <sup>32</sup>	1-2% for structural CHD 5-50% for ductal constriction <sup>33,34</sup>	1.8 (1.32-2.62)	IIb/B (first-trimester exposure I/A (third-trimester exposure)	18-22 wk Up to daily during exposure	Recommendation for exclusion of ductal constriction only
Maternal infection <sup>25,35,36</sup>	1-2	1.8 (1.4-2.4)	I/C (rubella) III/C (other viruses with only seroconversion) I/C (if pericarditis/ myocarditis suspected)	18-22 wk	Certain infections, specifically maternal rubella, have been associated with a higher incidence of specific cardiac malformations. <sup>35</sup> Parvovirus, coxsackie virus, adenovirus, and cytomegalovirus have been implicated in fetal myocarditis
Use of assisted repro- duction technology <sup>37-43</sup>	1.1-3.3		Ia/A	18-22 wk	Both IVF alone and IVF with ICSI seem to carry similar risk <sup>43,44</sup>

(Continued)

Table 2. Continued

	Absolute Risk, % live births	Relative Risk or Likelihood Ratio (CI)	COR/LOE	Timing/Frequency of Evaluation	Comments
Family history					
Maternal structural cardiac disease <sup>45-48</sup>	3-7 (all) 10-14 (AVSD) 13-18 (AS) <3 (TOF, d-TGA)	≈5	I/B	18-22 wk	
Paternal structural cardiac disease <sup>45,48-50</sup>	2-3, although may be slightly higher		I/B	18-22 wk	A single study reported a 7.5% recurrence when fetal echocardiography was used in addition to postnatal evaluation <sup>51</sup> ; this study included small VSDs and ASDs that were not detectable on fetal echocardiography
Sibling with structural disease <sup>2,45,49,52-54</sup>	3%, 8% for HLHS <sup>55</sup>	≈4	I/B	18-22 wk	For most lesions, <50% concordance has been observed, although exact concordance may be in the range of 20%-35% for the majority of cardiac malformations <sup>45,50,51</sup>
Second-degree relative with structural cardiac disease <sup>46,51</sup>	<2	1.39 (1.25-1.54)	IIb/B	18-22 wk	Studies have established heritability for left-sided obstructive lesions <sup>52,53,56</sup> ; and some now advocate screening for all first- and second-degree relatives of affected individuals
Third-degree relatives with structural cardiac disease <sup>46</sup>	≈1	1.18 (1.05-1.32)	III/B		
First- or second-degree relative with disease, disorder, or syndrome with mendelian inheritance associated with structural cardiac disease <sup>55</sup>	Up to 50		I/C	18-22 wk	There is little value to fetal echocardiography in detecting disease with postnatal onset of cardiovascular manifestations such as hypertrophic cardiomyopathy, Marfan or Ehler-Danlos syndromes
Fetal factors					
Suspected cardiac abnormality on obstetric ultrasound <sup>57-59</sup>	>40		I/B	At detection	Repeat fetal echocardiography if abnormality is found or if progressive disease is suspected
Rhythm abnormalities:					
Tachycardia <sup>60,61</sup>	1% for associated CHD		I/C	At detection	Fetal echocardiography to ascertain the mechanism of tachycardia and to guide therapy <sup>62-64</sup>
Bradycardia/CHB <sup>65</sup>	50-55		I/C	At detection	Fetal echocardiography to ascertain mechanism of bradycardia, and if persistent, monitoring to assess heart rate, rhythm and cardiac function
Irregular rhythm <sup>66</sup>	0.3% with CHD; 2% with arrhythmia	(0-0.7)	I/C (frequent) IIa/C (persistent > 1-2 wks)	At detection 1-2 wk after detection	Baseline fetal echocardiography and if persistent weekly heart rate monitoring until resolved to assess for tachycardia
Noncardiac abnormality <sup>67-74</sup>	20-45		I/B	At detection	Risk depends on organ systems affected (Table 4)
Known or suspected chromosomal abnormality <sup>65</sup>	Varies, may be as high as 90		I/C	12-14 wk and/or 18-22 wk	See the Extracardiac Assessment of the Fetus With CHD section for specific risks for aneuploidies and deletion syndromes

(Continued)

Table 2. Continued

	Absolute Risk, % live births	Relative Risk or Likelihood Ratio (CI)	COR/LOE	Timing/Frequency of Evaluation	Comments
Increased NT, mm					
3.0–3.4 <sup>75</sup>	3		Ia/A I/A if abnormal ductus venosus flow <sup>76</sup>	18–22 wk	
≥3.5 <sup>77–79</sup>	6	24	I/A	12–14 wk and/or 18–22 wk	
>6 <sup>79,80</sup>	24		I/B		
>8.5	>60		I/B		
Abnormality of umbilical cord, placenta, or intra-abdominal venous anatomy <sup>73,81,82</sup>	3.9	>2	Ib/C	18–22 wk	Significant bias may be present in estimate
Monochorionic twinning <sup>83,84</sup>	2–10	9.18 (5.5–15.3)	I/A	12–14 w and 18–22 wk; additional evaluation based on clinical findings	Estimated at 2%–2.5%; 11% when pregnancy complicated by TTTS
Hydrops fetalis <sup>85,86</sup>	15–25		I/B	At diagnosis	Can be extended to the evaluation of the at-risk fetus and to the fetus with effusions in the absence of hydrops (isolated pericardial or pleural effusion, ascites)

ACE indicates angiotensin-converting enzyme; AS, aortic stenosis; ASD, atrial septal defect; AVSD, atrioventricular septal defect; CHB, complete heart block; CHD, congenital heart disease; CI, confidence interval; COR, classification of recommendation; DM, diabetes mellitus; d-TGA-transposition of the great arteries; HbA<sub>1c</sub>, hemoglobin A<sub>1c</sub>; HLHS, hypoplastic left heart syndrome; ICSI, intracytoplasmic sperm injection; IVF, in vitro fertilization; LOE, level of evidence, NSAID, nonsteroidal anti-inflammatory drug; NT, nuchal translucency; RVOT, right ventricular outflow tract; SSRI, selective serotonin reuptake inhibitor; TOF, tetralogy of Fallot; TTTS, twin-twin transfusion syndrome; and VSD, ventricular septal defect.

## Maternal Factors

### Diabetes Mellitus

Diabetes mellitus (DM) is one of the most common maternal conditions complicating pregnancies, affecting ≈3% to 10%. Of these, 20% (or ≈1% of all pregnant women) have DM before conception and are considered to have pregestational DM.<sup>87</sup> Overall, there is nearly a 5-fold (3%–5%) increase in CHD compared with the general population in women with pregestational DM,<sup>6</sup> with a higher relative risk noted for specific cardiac defects, including 6.22 for heterotaxy, 4.72 for truncus arteriosus, 2.85 for transposition of the great arteries (d-TGA), and 18.24 for single-ventricle defects.<sup>7</sup> Several studies indicate that lack of preconceptional glycemic control, as evidenced by elevation in serum hemoglobin A1C (HbA<sub>1c</sub>) levels >8.5% in the first trimester, is associated with an increase in all congenital malformations,<sup>8</sup> whereas strict glycemic control before conception and during pregnancy reduces risk to a level comparable to that in the nondiabetic population.<sup>88</sup> Additional studies, however, have suggested that there is no threshold HbA<sub>1c</sub> value that increases risk for fetal CHD.<sup>7,89</sup> In a study of 3 different diabetic populations, HbA<sub>1c</sub> values slightly above the normal range (mean, 6.4%) were associated with a significantly increased risk of cardiac malformation of 2.5% to 6.1% in offsprings.<sup>7</sup> Therefore, it appears that although the risk may be highest in those with HbA<sub>1c</sub> levels >8.5%, all pregnancies of pregestational diabetic women are at some increased risk. Given this information, a fetal echocardiogram should be performed in all women with pregestational DM. Insulin resistance acquired in the third trimester,

or gestational DM, does not appear to confer an increased risk of CHD in the fetus.<sup>90</sup> For this reason, a fetal echocardiogram is not indicated for these pregnancies. Fetuses may develop ventricular hypertrophy late in gestation in the presence of poorly controlled maternal gestational or pregestational DM, and the degree of hypertrophy has been shown to be related to glycemic control. In women with HbA<sub>1c</sub> levels <6% in the second half of pregnancy, the effects are mild, so fetal echocardiogram is not recommended.<sup>91</sup> If HbA<sub>1c</sub> levels are >6%, fetal echocardiogram in the third trimester to assess for ventricular hypertrophy may be considered, but its usefulness has not been determined.

### Phenylketonuria

Maternal phenylketonuria, when untreated, results in adverse pregnancy outcomes, including mental retardation, microcephaly, growth restriction, and CHD in offspring.<sup>10,92</sup> Elevated maternal serum levels of phenylalanine (>15 mg/dL) are associated with a 10- to 15-fold increased risk of CHD.<sup>10,11</sup> The risk for CHD in fetuses has been reported to be 12% if control is not achieved by 10 weeks of gestation<sup>12</sup>; therefore, a fetal echocardiogram is indicated for these pregnancies. With good preconceptional dietary control, risk can be greatly reduced. A large, prospective, international collaborative study of 576 completed pregnancies in women with phenylketonuria and 101 control subjects revealed no cases of CHD if maternal phenylalanine levels were <6 mg/dL before conception and during early organogenesis.<sup>11</sup> This study suggests that a fetal echocardiogram is not indicated for women with well-controlled phenylketonuria if preconception and first trimester



**Table 3. Common Indications for Referral for Fetal Echocardiogram**

Indications with higher risk profile (estimated >2% absolute risk)	
Maternal pregestational diabetes mellitus	
Diabetes mellitus diagnosed in the first trimester	
Maternal phenylketonuria (uncontrolled)	
Maternal autoantibodies (SSA/SSB <sup>+</sup> )	
Maternal medications	
ACE inhibitors	
Retinoic acid	
NSAIDs in third trimester	
Maternal first trimester rubella infection	
Maternal infection with suspicion of fetal myocarditis	
Assisted reproduction technology	
CHD in first degree relative of fetus (maternal, paternal or sibling with CHD)	
First or second degree relative with disorder with Mendelian inheritance with CHD association	
Fetal cardiac abnormality suspected on obstetrical ultrasound	
Fetal extracardiac abnormality suspected on obstetrical ultrasound	
Fetal karyotype abnormality	
Fetal tachycardia or bradycardia, or frequent or persistent irregular heart rhythm	
Fetal increased NT >95% (≥3 mm)	
Monochorionic twinning	
Fetal hydrops or effusions	
Indications with lower risk profile (estimated >1% but <2% absolute risk)	
Maternal medications	
Anticonvulsants	
Lithium	
Vitamin A	
SSRIs (only paroxetine)	
NSAIDs in first/second trimester	
CHD in second degree relative of fetus	
Fetal abnormality of the umbilical cord or placenta	
Fetal intra-abdominal venous anomaly	
Not indicated (≤1% risk)	
Maternal gestational diabetes mellitus with HbA <sub>1c</sub> <6%	
Maternal medications	
SSRIs (other than paroxetine)	
Vitamin K agonists (Coumadin), although fetal survey is recommended	
Maternal infection other than rubella with seroconversion only	
Isolated CHD in a relative other than first or second degree	

ACE indicates angiotensin-converting enzyme; CHD, congenital heart disease; HbA<sub>1c</sub>, hemoglobin A<sub>1c</sub>; NSAID, nonsteroidal anti-inflammatory drug; NT, nuchal translucency; and SSRI, selective serotonin reuptake inhibitor.

phenylalanine levels are <10 mg/dL. If levels are >10 mg/dL, fetal echocardiogram should be performed.

#### **Autoimmune Disease and Autoantibody Positivity**

The association of maternal lupus and other connective tissue diseases with congenital complete heart block (CHB) is well known.<sup>93</sup> Fetuses can be affected in the presence of maternal serologic evidence of disease and no overt clinical symptoms.

The exact prevalence of symptomatic or asymptomatic maternal autoantibody (anti-Ro/SSA or anti-La/SSB) positivity in the general population is unknown. In prospectively examined pregnancies of mothers with known antibodies and no prior affected child, the reported incidence of fetal CHB was between 1% and 5%. The number of affected pregnancies increases to 11% to 19% for those with a previously affected child with CHB.<sup>13–17</sup> In addition, women with both autoantibodies and hypothyroidism are at a 9-fold increased risk of having an affected fetus or neonate compared with those with SSA or SSB alone.<sup>18</sup>

In addition to abnormalities in the conduction system, up to 10% to 15% of SSA-exposed fetuses with conduction system disease may also develop myocardial inflammation, endocardial fibroelastosis, or atrioventricular (AV) valve apparatus dysfunction.<sup>94</sup> Because of the perception that the inflammatory effects resulting from antibody exposure may be preventable if detected and treated at an early stage, it has been recommended that SSA/SSB-positive women be referred for fetal echocardiography surveillance beginning in the early second trimester (16–18 weeks).<sup>14,16,95</sup> The mechanical PR interval has been measured in fetuses at risk with the use of a variety of M-mode and pulsed Doppler techniques and compared with gestational age-adjusted normal values.<sup>96</sup> Although the value of serial assessment for the detection of the progression of myocardial inflammation or conduction system disease from first-degree block (PR prolongation) to CHB has not been proved, serial assessment at 1- to 2-week intervals starting at 16 weeks and continuing through 28 weeks of gestation is reasonable to perform because the potential benefits outweigh the risks. For women who have had a previously affected child, more frequent serial assessment, at least weekly, is recommended.

#### **Medication Exposure**

Most of the current literature implicating maternal medications in congenital abnormalities comes from retrospective patient interviews and voluntary registries and therefore may be subject to bias. Nevertheless, a number of human teratogens are used clinically in women of childbearing age, and exposure to these medications in the period of cardiogenesis increases the risk of CHD. Among the most studied include anticonvulsants, lithium, angiotensin-converting enzyme inhibitors, retinoic acid, selective serotonin reuptake inhibitors (SSRIs), and nonsteroidal anti-inflammatory agents (NSAIDs).

#### **Anticonvulsants**

Anticonvulsants used in pregnancy include carbamazepine, diphenylhydantoin, and valproate. In a meta-analysis including a group of untreated epileptic women as control subjects, 1.8% of 1208 carbamazepine-exposed fetuses exhibited cardiac malformations.<sup>21</sup> This proportion was similar whether the mothers were taking carbamazepine alone or in combination with other anti-epileptic drugs. The incidence of malformations in the unmedicated epileptic control subjects was similar to that for the normal population. Fetal echocardiogram may be considered, although its usefulness has not been established if exposure occurs.

#### **Lithium**

Lithium has been reported to be associated with cardiac malformations in up to 8% of offspring in a registry study.<sup>25</sup> However, more recent prospective case-control studies<sup>22</sup> and literature analyses<sup>97</sup> have suggested that the risk is not as high

as initially thought, with a risk ratio for cardiac anomalies of 1.1 (95% confidence interval [CI], 0.1–16.6).<sup>22</sup> Fetal echocardiogram may be considered, although its usefulness has not been established if exposure occurs.

#### *Angiotensin-Converting Enzyme Inhibitors*

Angiotensin-converting enzyme inhibitor exposure in the first trimester is associated with increased risk for CHD, with 2.9% of exposed infants affected and a risk ratio of 3.72 (95% CI, 1.89–7.30) compared with 0.78% of unexposed infants in a large control population.<sup>23</sup> Of note, most of the reported defects were atrial septal defects or patency of the ductus arteriosus, which would not have been detectable prenatally. Fetal echocardiogram is reasonable if exposure occurs.

#### *Retinoic Acid*

Retinoic acid, a vitamin A analog, is teratogenic in laboratory animals and contraindicated in pregnancy; however, inadvertent use occurs. Cardiac malformations (conotruncal defects and aortic arch anomalies predominating) were reported in 8% of exposed fetuses in a small retrospective series, although this number rose to 20% (12 of 54) if the 95 with first-trimester pregnancy terminations were included.<sup>24</sup> Fetal echocardiogram is recommended if exposure occurs.

#### *Selective Serotonin Reuptake Inhibitors*

The use of SSRIs in pregnancy has been investigated.<sup>26,28–30</sup> Results indicate that there is no increased risk of CHD associated with the use of most SSRIs, although paroxetine may be an exception. In a meta-analysis,<sup>26</sup> first-trimester paroxetine exposure was associated with increased risk of CHD with an odds ratio of 1.72 (95% CI, 1.22–2.42), although the authors also reported a very high rate of ultrasound use in exposed pregnancies that may have introduced an ascertainment bias. In a study of nearly 10000 infants with birth defects, SSRI use was not associated with an increase in risk of CHD (3724 subjects, 100 exposed; odds ratio, 1.2; 95% CI, 0.9–1.6),<sup>29</sup> but additional analysis in a small number of patients showed a possible increase in paroxetine exposure among infants with right ventricular outflow tract obstruction (odds ratio, 3.3; 95% CI, 1.3–8.8). Fetal echocardiogram may be considered if exposure to paroxetine occurs.

#### *Vitamin K Antagonists*

Warfarin and other Coumadin derivatives when used in the first trimester of pregnancy have been reported to be teratogenic. In a recent multicenter, prospective study of >600 exposed pregnancies and 1000 controls, equal numbers of cardiac malformations were seen in the exposed and control groups (3 in each), suggesting that there was no increased risk of CHD despite a clear increased risk of other birth defects.<sup>31</sup> Fetal echocardiogram is not indicated if exposure occurs; however, a detailed anatomy scan should be performed.

#### *Nonsteroidal Anti-Inflammatory Agents*

NSAIDs are sometimes used for tocolysis. Doppler evidence of ductal constriction is evident in 25% to 50% of indomethacin-exposed late second- and third-trimester fetuses, although it is usually mild and resolves with drug discontinuation.<sup>33,98</sup> Ductal constriction may also occur with the use of other NSAIDs.<sup>34</sup> Fetal echocardiogram is recommended with NSAID use in the late second or third trimester. The use of NSAIDs in early

gestation has been associated with a small increased risk for CHD with an odds ratio of 1.86 (95% CI, 1.32–2.62).<sup>32</sup> For this reason, fetal echocardiogram may be considered, although its usefulness is not established if early exposure occurs.

#### *Infection*

The effect of nonspecific maternal infection (other than with specific viruses such as rubella) is difficult to separate definitively from the effects of medications used to treat the illness and the systemic maternal effects that result from the infection such as fever. In 1 population-based study, febrile illness was positively associated with the occurrence of CHD in offspring with an odds ratio of 1.8 (95% CI, 1.4–2.4).<sup>35</sup> Because of the risk for structural disease, a fetal echocardiogram should be performed with first-trimester maternal infection with rubella. Exposure to or seroconversion associated with other viral agents in pregnancy is not likely to be associated with positive cardiac findings in the absence of other ultrasound findings (ie, effusions, hydrops); therefore, seroconversion alone is not an indication for fetal echocardiogram, although it should be performed if fetal pericarditis or myocarditis is suspected.

#### *Assisted Reproduction Technology*

The use of assisted reproductive technologies has increased over the past 2 decades. In 2005, an estimated 1% of all live births in the United States were conceived with the use of in vitro fertilization with or without intracytoplasmic sperm injection.<sup>99</sup> There are conflicting reports on the direct association of the use of this technology and CHD malformations in offspring, with the more recent reports suggesting that the increased incidence of CHD in these pregnancies may be attributable to the increased risk specifically for multiple gestations and that singletons conceived with in vitro fertilization are not at increased risk.<sup>37</sup> In addition, because of the influence of advanced maternal age on CHD risk,<sup>100</sup> the known increased risk associated with monozygous twinning (increased with in vitro fertilization), and the unknown effect of the underlying reason for subfertility in couples using in vitro fertilization/intracytoplasmic sperm injection, the direct causation from the technology remains unknown.<sup>38–40</sup> Nevertheless, the overall risk of CHD in infants conceived through in vitro fertilization seems to be slightly higher than that for reference populations with a risk of 1.1% to 3.3% (95% CI, 0.3–1.8).<sup>37,38,41,42,44</sup> The majority of defects identified are atrial and ventricular septal defects,<sup>42,101</sup> which may be difficult to detect in fetal life and are of minor clinical significance in many cases. Fetal echocardiogram is reasonable to perform in pregnancies of assisted reproductive technologies.

#### **Family History**

##### *Maternal Cardiac Disease*

The risk of recurrence of nonsyndromic, nonchromosomal CHD is >2 times as high if the mother is affected versus the father or a sibling.<sup>45,46</sup> Risk varies greatly with the specific maternal diagnosis and is reported to be highest with heterotaxy and AV septal defects (AVSD) at ≈10% to 14%<sup>45–48</sup> or aortic stenosis (AS) at 13% to 18%.<sup>48,49,102</sup> For the majority of maternal cardiac diagnoses, the risk of recurrence is in the range of 3% to 7%. The recurrence risk for isolated tetralogy of Fallot (TOF) or d-TGA has been reported to be ≤3%.<sup>45,48</sup> Fetal echocardiogram is indicated if there is maternal CHD.

**Paternal Cardiac Disease**

Although reported risk varies somewhat with lesion type, most studies cite a 2% to 3% risk of cardiac malformation if the father is affected with nonsyndromic CHD.<sup>45,48–50</sup> Recurrence risk for AS may be higher,<sup>49</sup> although in some populations, bicuspid aortic valve has been shown to be more highly heritable than other defects,<sup>103</sup> which may account for this difference. Fetal echocardiogram is indicated if there is paternal CHD.

**Affected Siblings**

The risk of recurrence of cardiac malformations in siblings is lower than the risk in the offspring of affected parents; however, studies suggest that recurrence risk if a sibling is affected with unaffected parents is 2% to 6%.<sup>2,45,49,52</sup> Risk for recurrence increases if >1 sibling is affected.<sup>51,104</sup> Fetal echocardiogram is indicated, especially if >1 sibling has been affected.

**Second- and Third-Degree Relatives**

Recurrence risk in second- and third-degree relatives with CHD is not well studied. In 1 report,<sup>45</sup> a <0.3% prevalence of CHD was reported in second- and third-degree relatives of patients with TOF, with no cases of recurrence of AVSD or d-TGA. Although the risk of familial recurrence may cluster for specific lesions,<sup>53</sup> overall risk of CHD in second- and third-degree relatives of a proband is low with an odds ratio of 1.39 (95% CI, 1.25–1.54) in second-degree relatives and 1.18 (95% CI, 1.05–1.32) in third-degree relatives in 1 large study.<sup>46</sup> Fetal echocardiogram may therefore be considered if there is a family history of isolated, nonsyndromic CHD in second-degree relatives, but it is not indicated in isolated third-degree relatives.

**Diseases, Disorders, or Syndromes With Mendelian Inheritance**

In pregnancies in which a prior child is affected by an recessively inherited disease, in pregnancies in which a parent is affected by an autosomal-dominant genetic disorder with increased risk for cardiac malformation, or in pregnancies with a deletion syndrome known to be associated with a significant incidence of cardiac phenotype (eg, 22q11 deletion, Alagille syndrome, or Williams syndrome), the recurrence risk in the fetus is high. In these situations, a fetal echocardiogram is recommended, given the limitations inherent in detecting disease with variable penetrance or expressivity.<sup>55</sup> For a more extensive

review of the available literature on the genetic basis of CHD, please see the Genetic Abnormalities section.

**Fetal Factors**

**Suspected Cardiac Abnormality on Obstetric Ultrasound**

Numerous studies have documented that the diagnostic yield for fetal echocardiography detection of CHD when the referral indication is an abnormal 4-chamber screening view on obstetric ultrasound is >40%.<sup>57–59</sup> Suspicion of an abnormality of the outflows or great vessels on a screening ultrasound is less well studied. In 1 report, 52% of fetal echocardiograms were abnormal when referred for an indication of abnormality on a screening examination incorporating both 4-chamber and outflows tract views.<sup>58</sup> Studies incorporating the view of 3 vessels with trachea into screening obstetric examinations have also increased the detection of CHD.<sup>105,106</sup> Fetal echocardiogram should be performed in all fetuses with a suspected cardiac abnormality noted on obstetric ultrasound.

**Suspected Abnormality of Heart Rate or Rhythm**

Fetal tachycardia rarely may be associated with CHD. In contrast, fetal bradycardia resulting from abnormal AV conduction (CHB) has been reported to be associated with CHD in ≈50% to 55% of cases.<sup>65</sup> Fetal bradycardia resulting from long-QT syndrome (LQTS) may present as isolated mild sinus bradycardia or 2:1 AV block.<sup>107–109</sup> A fetal echocardiogram should be performed in all fetuses with suspected or confirmed tachyarrhythmias or bradyarrhythmias to assess cardiac structure and function, to ascertain the mechanism of the tachycardia or bradycardia (discussed in the Bradycardia and Tachycardias sections), and to guide therapy.

An irregular fetal rhythm such as that caused by atrial extrasystoles has a low diagnostic yield for CHD (0.3%; 95% CI, 0–0.7 in 1 series) but may be the harbinger of more malignant arrhythmias if it is persistent.<sup>66</sup> Because premature atrial contractions may be difficult to distinguish from premature ventricular contractions and other types of more significant arrhythmias, fetuses with frequent ectopic beats (bigeminy, trigeminy, or more than every 3–5 beats on average) should have a baseline fetal echocardiogram to assess cardiac structure and function and to determine the mechanism of the arrhythmia (discussed in the Irregular Rhythm section). In fetuses with less frequent extrasystoles, if there is any question about the mechanism, if the ectopic beats persist beyond 1 to 2 weeks, or if the practitioner lacks sufficient training or experience to differentiate a benign irregular rhythm from a pathological one, a fetal echocardiogram is reasonable to perform.

**Noncardiac Abnormalities**

CHD may be present in fetuses with extracardiac malformations even in the presence of normal karyotype.<sup>67</sup> The incidence of CHD in the presence of ≥1 extracardiac malformations is estimated to be 20% to 45%, depending on the population studied, the type of malformation, and the gestational age at which ultrasound screening was performed.<sup>67–74</sup> Cardiac malformations have been observed in 30% of omphaloceles, in 20% of duodenal atresia, in 30% of congenital diaphragmatic hernias, in 5% to 15% of central nervous system malformations, and in up to 71% of genitourinary abnormalities. (Table 4). Realizing that within these general categories,

**Table 4. Population Surveys of Extracardiac Anomalies and Risk of Fetal Cardiac Disease**

System	Greenwood et al <sup>110</sup>	Gallo et al <sup>111</sup>	Wallgren et al <sup>112</sup>	Miller et al <sup>113</sup>
Extracardiac abnormalities, %				
Central nervous	6.9	3.2	6.0	23.2
Respiratory	3.8	8.0	5.2	10.5
Gastrointestinal	4.2	...	15.5	25.2
Genitourinary	5.3	...	13.1	23.1
Musculoskeletal	8.8	4.5	16.1	35.0
Total	25.2	32.9	43.9	28.6
Total in study, n	1566	1354	1000	7984

Ellipses indicate data not available.



risk of CHD associated with specific anomalies (ie, unilateral cleft lip, isolated mild ventriculomegaly) may be low, a fetal echocardiogram should be performed in all fetuses with identified extracardiac abnormalities unless the specific anomaly is known to confer low risk and has been well demonstrated by other testing (including obstetric scan that includes normal 4-chamber and outflow tract views) to be isolated.

#### **Known or Suspected Chromosomal Abnormality**

If fetal chromosome testing reveals a genetic mutation, deletion, rearrangement, or aneuploidy, the risk of congenital anomalies is high, and fetal echocardiogram should be performed. The interested reader is referred to the AHA scientific statement for a more comprehensive discussion of the genetic basis for CHD.<sup>55</sup>

#### **Increased Nuchal Translucency on First-Trimester Screening**

A transient subcutaneous collection of fluid seen posteriorly in the neck in human fetuses at 10 to 14 weeks of gestation as determined by crown-rump length is called the nuchal translucency (NT). When increased, the NT has been shown to correlate with an increased risk of aneuploidy and other malformations.<sup>114–116</sup> The cause of an increased NT is speculative, and studies of cardiac function at this gestational age do not support a causal relation between decreased heart function and increased nuchal fluid.<sup>117,118</sup> Normal values have been established and vary with crown-rump length. In addition, percentiles in the large population studies can be roughly correlated with absolute measurements for use in clinical practice. Generally speaking, the 95th percentile cutoff is at 3.0 mm and the 99th percentile cutoff 3.5 mm.<sup>115</sup>

The association of an increased NT with CHD in chromosomally normal fetuses, first recognized in 1996,<sup>75</sup> has been the subject of a number of studies. In an early report, the NT had a sensitivity of 56% for detecting CHD using the 95th percentile and 40% using the 99th percentile cutoff.<sup>119</sup> Subsequent studies have demonstrated a much lower sensitivity: 31% (range, 25%–55%) in a meta-analysis using the 99th percentile<sup>77</sup> and only 10% to 15% in several studies of low-risk populations using the 99th percentile threshold.<sup>78,120,121</sup> The likelihood of a fetus with normal karyotype having CHD once an increased NT is detected increases from 1% to ≈3% for NT above the 95th percentile and to ≈6% for NT at or above the 99th percentile.<sup>78,79,122–124</sup> The risk for CHD rises exponentially with increasing NT measurement,<sup>79,122–125</sup> with a risk estimated at 24% if NT is ≥6 mm<sup>80</sup> and >60% with a NT ≥8.5 mm.<sup>79</sup> Some centers advocate use of the 95th percentile cutoff for a specific crown-rump length to determine the NT value above which a fetal echocardiogram should be offered.<sup>119</sup> With this methodology, smaller NT cutoffs at earlier crown-rump length measurements would qualify for fetal echocardiography. Others have recommended relying on the multiple of the median method with a cutoff of 2.5 for specific crown-rump length, which corresponds to the 99th percentile.<sup>78</sup> Given the difficulty of applying these methodologies in clinical practice, a simple cutoff of NT ≥3.5 mm or an NT ≥3.0 mm is suggested.

Absence or reversal of flow with atrial contraction in the ductus venosus Doppler in the first trimester has been associated with an increased risk of CHD, aneuploidy, and poor outcome.<sup>126</sup> In a meta-analysis, euploid fetuses with NT at

or above the 95th percentile and abnormal ductus venosus flow had a 15% incidence of major heart malformations.<sup>76</sup> When NT was at or above the ≥99th percentile, the incidence increased to ≈20%.<sup>127</sup> This indicates that the addition of ductus venosus Doppler analysis is useful for identifying those at greatest risk among the high-risk screening population.

Given the available data, a fetal echocardiogram should be performed if there is an NT ≥3.5 mm and is reasonable to perform with an NT ≥3.0 mm but <3.5 mm. A fetal echocardiogram is not indicated in fetuses with an isolated NT <3.0 mm. In fetuses with reversed flow in the ductus venosus, especially in association with an enlarged NT, a fetal echocardiogram is recommended.

#### **Abnormalities of the Umbilical Cord and Venous System**

The presence of a single umbilical artery has been associated with an increased incidence of CHD in the fetus, as high as 3.9% in 1 study.<sup>81</sup> In another study, more than twice as many infants with a single umbilical artery had CHD compared with infants with a normal cord.<sup>73</sup> Anomalies of the human fetal venous system occur sporadically and have been associated with cardiac malformations, in particular, agenesis of the ductus venosus.<sup>128</sup> Occasionally, the absence of the ductus venosus results in unimpeded placental return because the umbilical vein drains through alternate low-resistance fetal venous pathways, which can lead to significant volume overload and heart failure.<sup>129</sup> The true incidence of fetal venous malformations is undefined, but because of the frequently reported occurrence of cardiac abnormalities,<sup>82</sup> fetal echocardiogram has previously been recommended. Given the existing data, fetal echocardiography may be reasonable to consider in the presence of an umbilical cord or venous abnormality; however, because considerable ascertainment bias may have been introduced in the available studies, usefulness is not well established, especially if obstetric ultrasound is otherwise normal.

#### **Monochorionic Twinning**

Spontaneous twinning in humans occurs in 1% of pregnancies, although the incidence is higher with the use of assisted reproductive technologies. Monozygous twinning, in which division of the early embryonic cell mass results in 2 fetuses with identical genomes, occurs in ≈3 to 4 per 1000 live births; two thirds are monochorionic.<sup>130</sup> Twin pregnancies have higher rates of congenital malformations than singleton gestations, and monochorionic twins are at increased risk<sup>130,131</sup> over dichorionic twins. Overall, in monochorionic twins, the risk for CHD has been estimated at 2% to 9%.<sup>83,130,132</sup> TTTS has been reported to occur in 10% of monochorionic twin pregnancies. TTTS has been associated with polyhydramnios and myocardial changes, including acquired right ventricular outflow tract obstruction, which occurs in ≈10% of recipient twin fetuses.<sup>84</sup> Atrial septal defects have also been reported postnatally in either twin.<sup>84,133</sup> The incidence of pulmonary stenosis may be lower if the pregnancy is successfully treated with invasive laser photocoagulation of the intertwin anastomosis.<sup>84,133,134</sup> Fetal echocardiogram is recommended in all monochorionic twin gestations.

#### **Nonimmune Hydrops Fetalis and Effusions**

Fetal hydrops refers to the pathological accumulation of fluid in ≥2 fetal compartments, including the pleural or

pericardial spaces, abdominal cavity, integument, or placenta. The mechanism of the development of hydrops in the fetus is thought to be a combination of increased hydrostatic pressure, decreased oncotic pressure, and in some, lymphatic obstruction. Approximately 15% to 25% of fetuses with non-immune hydrops have cardiac abnormalities or arrhythmias. Abnormalities that result in increased venous pressure from volume overload caused by valve regurgitation, pressure overload from biventricular outflow obstruction, or decreased diastolic filling time during tachycardia are among the causes that have been reported.<sup>85,86</sup> An additional 10% of fetuses with hydrops have a high cardiac output state caused by fetal anemia, acardiac twinning, sacrococcygeal teratomas, or fetal or placental vascular malformations. Fetal echocardiogram is recommended in fetuses with nonimmune hydrops or effusions.

### Obstetric Screening

Fetal echocardiography has been shown to have a much higher sensitivity for the detection of CHD than routine obstetric scanning, which initially included only a 4-chamber view of the heart; however, more recently, has expanded to include assessment of outflow tracts. In fact, fetal echocardiography in experienced hands has been reported to detect up to 90% of serious CHD in low-risk populations.<sup>135,136</sup> Because of the very low yield (10%–26% detection of CHD) of obstetric screening,<sup>137–139</sup> some have advocated for routine fetal echocardiogram in pregnancy. The feasibility of this approach is a matter of question,<sup>140</sup> and obstetric ultrasound screening protocols incorporating multiple views of the heart have become the mainstay of screening for fetal cardiac malformations in the United States. The 4-chamber view can be reliably obtained in 95% to 98% of pregnancies<sup>58,141</sup> and theoretically detects >50% of serious cardiac malformations when performed in midgestation. Addition of the outflow tracts and 3 vessel with trachea view increases sensitivity to as high as 90%.<sup>142–144</sup>

Because only 10% of fetuses with CHD present for imaging with an identifiable “risk factor,”<sup>135</sup> it is suggested that all fetuses, regardless of maternal, familial, or fetal factors, be approached as if they have the potential to have a cardiac malformation. Recent studies in the United States have indicated that up to 99% of women giving birth to babies with serious CHD had obstetric ultrasound examinations in the second or third trimester; however, only ≈30% of the fetuses were identified prenatally to have CHD.<sup>145,146</sup> The detection rates for CHD have been shown to vary by type of ultrasound practice and level or type of training of the examiner.<sup>145,147</sup> In low- and high-risk populations evaluated in university settings in the recent era, anatomic survey that included the 4-chamber view and outflow tracts minimized the need for detailed fetal echocardiogram.<sup>148</sup> It stands to reason that with uniform standards for training and performance, detection rates may improve,<sup>144</sup> with fetal echocardiography being reserved for those expectant women in whom obstetric scanning suggests the possibility of an abnormality.

### Fetal Echocardiography

The fetal echocardiogram represents the primary tool for the detailed diagnosis and evaluation of fetal cardiovascular pathology from the late first trimester to term. Despite the central importance of the technique to the field of fetal cardiology,

the definition and scope of fetal echocardiography remain controversial. The expansion of obstetric screening of the fetal heart to include outflow tracts and, in some settings, color flow imaging has diminished the distinction between obstetric cardiac screening and fetal echocardiography. At the same time, advances in computer processing and transducer technology have expanded the capacity of the fetal echocardiogram to include a wide variety of new modalities and sophisticated measures of structure and function.

In an attempt to clarify the fundamental role of fetal echocardiography and the specific components that constitute a fetal cardiac examination, several subspecialty organizations have published formal practice guidelines.<sup>149–152</sup> These guidelines vary, with no consensus on which modalities and measurements should be required as a minimum standard.<sup>153</sup> Recently, a task force with representation from multiple societies developed revised guideline for the performance of fetal echocardiogram.<sup>154</sup> This effort represents an initial step toward consensus among specialties. Table 5 highlights the required and optional elements each published guideline recommends. Discrepancies may be partially attributed to professional/training biases among subspecialty groups and, perhaps more importantly, to a deficiency in relevant supportive literature and evidence. Moreover, some guidelines describe exhaustive, comprehensive approaches to fetal cardiovascular system evaluation, whereas others describe a more basic approach to anatomic imaging.

Recommendations for the specific components that constitute a fetal echocardiogram should reflect a consensus of expert opinion from multiple disciplines and incorporate evidence-based recommendations to the extent that such evidence can be identified from the literature. Because fetal cardiac imaging may include an expansive number of both standard and more advanced measurements and modalities, the fetal echocardiogram can be described by first including the essential elements and then detailing what is available as part of a more expanded examination. Table 6 lists all the potential elements of a fetal echocardiogram; some are recommended as mandatory components for all studies, and others are suggested as useful. It should be noted, however, that some elements that are not considered mandatory for all studies will be indicated in specific clinical situations. Many factors contribute to the decision of whether to perform the standard examination or to add various additional elements that can be included as part of a more extended cardiac examination.

### Timing of Fetal Echocardiogram

#### *Initial Fetal Echocardiogram*

The timing in gestation in which a fetal echocardiogram should be performed is determined by multiple factors, including the reason for referral and the gestational age at which cardiac or extracardiac pathology is detected by obstetric ultrasound. Fetal echocardiography for screening of pregnancies at risk for CHD (discussed in Indications for Referral for Fetal Cardiac Evaluation) generally should be performed at 18 to 22 weeks of gestation, the time at which most routine midtrimester obstetric ultrasound assessments are performed to screen for other fetal abnormalities. It must be recognized that this strategy for screening may not identify diseases that progress in utero from subtle pathology in midgestation to more obvious disease closer to term.<sup>136,155</sup> In addition, fetal



**Table 5. Components of a Fetal Echocardiogram Among Published Guidelines**

Guidelines	ASE, 2004	ISUOG, 2008	AIUM, 2010	AIUM, 2013	AHA,* 2014
<b>2D cardiovascular anatomy</b>					
Situs	M	M	M	M	M
Cardiac position/axis	M	M	M	M	M
Pericardial effusion	M	M	NC	M	M
Systemic venous connections	M	M	M	M	M
Pulmonary venous connections	M	M	M	M	M
Atrial morphology	M	M	M	M	M
Atrial septal morphology	M	M	M	M	M
AV connection	M	M	M	M	M
Ventricular morphology, size, and size relationship	M	M	M	M	M
Ventricular-arterial connection	M	M	M	M	M
AV valve morphology, size, and size relationship	M	M	M	M	M
Semilunar valve morphology, size, and size relationship	M	M	NC	M	M
Ventricular septal morphology (exclude VSD)	M	M	M	M	M
Great artery anatomic and size relationship	M	M	M	M	M
3-Vessel and trachea views	M	M	M	M	M
Aortic arch morphology	M	M	M	M	M
Ductal arch morphology	M	M	M	M	M
Proximal branch PAs	M	NC	NC	M	M
<b>Cardiac and general biometry</b>					
Cardiothoracic ratio	M	NC	NC	O	O
Atrial dimensions	NC	O	O	O	O
Ventricular dimension	M	O	O	O	O
AV valve diameters	M	O	O	O	O
Semilunar valve diameters	M	O	O	O	O
Ascending aortic and main PA diameters	M	O	O	O	O
Aortic and ductal arch diameters	M	O	O	O	O
Branch PA diameters	M	NC	O	O	O
Fetal biometry	M	NC	NC	NC	O
<b>Color Doppler</b>					
Superior and inferior vena cavae	M	M	NC	M	M
Foramen ovale	M	NC	O	M	M
AV valves/ventricular inflows	M	M	O	M	M
Ventricular septum	M	NC	O	M	M
Semilunar valves/ventricular outflows	M	M	O	M	M
Ductus venosus	M	M	NC	M	M
Umbilical vein/arteries	M	NC	NC	O	O
Pulmonary veins	M	M	O	M	M
Great arteries and arches	M	M	O	M	M
Branch PAs	NC	NC	NC	NC	O

(Continued)

**Table 5. Continued**

Guidelines	ASE, 2004	ISUOG, 2008	AIUM, 2010	AIUM, 2013	AHA,* 2014
<b>Pulsed-wave Doppler</b>					
AV valves/LV and RV inflows	M†	O	O†	M	M
Semilunar valves/ventricular outflows	M†	O	O†	M	M
Superior/inferior vena cavae	M†	O	NC	O	O
Ductus venosus	M†	NC	NC	M	M
Umbilical vein	M†	NC	NC	O	O
Pulmonary veins	M†	O	O†	O	O
Great arteries and arches	M†	O	O†	O	O
Branch PAs	NC	NC	NC	NC	O
Umbilical artery	M†	NC	NC	O	O
Middle cerebral artery	NC	NC	NC	NC	O
<b>Other Doppler</b>					
CW Doppler	M†	O	O†	O	O
Power Doppler	NC	O	O	NC	NC
Tissue Doppler	O	O	O	O	O
<b>Additional cardiac function indexes</b>					
Ventricular shortening fraction	NC	O	O	O	O
Myocardial performance index	NC	O	O	O	O
Cardiac output	NC	O	O	O	O
Heart rate and rhythm assessment	M	O	O	M	M
Cine clips	M	O	NC	M	M

Summary of recommendations for the performance of fetal echocardiography from the American Institute of Ultrasound in Medicine in conjunction with the American College of Obstetrics and Gynecology, the American College of Radiology, the Society of Maternal Fetal Medicine, and American Society of Echocardiography (for the 2013 version only),<sup>149,154</sup> International Society of Ultrasound in Obstetrics and Gynecology,<sup>150</sup> American Society of Echocardiography,<sup>151</sup> and American Heart Association (current guidelines).

2D indicates 2-dimensional; AHA, American Heart Association; AIUM, American Institute of Ultrasound in Medicine; ASE, American Society of Echocardiography; AV, atrioventricular; CW, continuous-wave; ISUOG, International Society of Ultrasound in Obstetrics and Gynecology; LV, left ventricular; M, mandatory; NC, no comment or importance not certain based on what is stated; O, optional; PA, pulmonary artery; RV, right ventricle; and VSD, ventricular septal defect.

\*For the AHA 2014 statement, this table lists required (Class I) elements for fetal echocardiography as mandatory; additional elements that are reasonable to include (Class IIa) or may be reasonable (Class IIb) are listed as optional.

†ASE guidelines state that Doppler evaluation of the noted structures is mandatory (M), however the option of color, pulsed, or CW Doppler is given; AIUM 2010 guidelines state that Doppler evaluation of noted structures, including color, pulsed, or CW Doppler, is optional (O).

arrhythmias may evolve late in the second or third trimester. This is particularly true for premature beats and tachycardias, which often do not manifest before 25 to 26 weeks of gestation and, in some cases, only in the third trimester.<sup>156,157</sup>

Abnormal findings on routine obstetric ultrasound should prompt performance of a fetal echocardiogram if there is a suspected cardiac diagnosis as soon as is feasible. Lesions at risk for fetal cardiovascular compromise, in particular, should be referred urgently (the same day or next day if feasible). Fetal echocardiographic assessment of an affected pregnancy should be performed sufficiently early to provide time for

**Table 6. Components of the Fetal Echocardiogram**

2-Dimensional imaging
Cardiac size (qualitative)
Cardiac axis (levocardia, mesocardia, dextrocardia)
Cardiac position (dextroposition, levoposition)
Visceral and atrial situs determination
Systemic venous anatomy/connections
Pulmonary venous anatomy/connections
Qualitative atrial size and atrial septal morphology/ localization of defect if present
AV connections
Tricuspid and mitral valve morphology and size
Ventricular morphology, looping determination, size (with comparison of right and left)
Ventricular septal morphology with exclusion/ localization of defect if present
Ventricular-arterial connections
Pulmonary and aortic valve morphology and size (with comparison of right and left)
Great artery relationship and size
Aortic and ductal arch morphology
Aortic/ductal relationship relative to the trachea
Proximal right and left branch pulmonary arteries
Assessment for pericardial or pleural effusions
<i>Tricuspid and mitral annulus diameters</i>
<i>Atrial dimensions</i>
<i>Ventricular length and width</i>
<i>Pulmonary and aortic valve annulus diameters</i>
<i>Main pulmonary artery and ascending aorta diameters</i>
<i>Ductus arteriosus diameter</i>
<i>Aortic transverse arch diameter</i>
<i>Cardiothoracic ratio measurement*</i>
<i>Branch pulmonary artery diameters†</i>
Rhythm assessment
Heart rate
A-V relationship/rhythm
<i>Mechanical PR (A-V) interval‡</i>
<i>Description of A-V relation including arrhythmia onset/offset, duration‡</i>
Color flow map imaging
Tricuspid and mitral valves/ventricular inflows
Pulmonary and aortic outflows/ventricular outflows
Aortic arch/ductal arch
Ventricular and atrial septal flow
Superior and inferior vena cavae
Pulmonary veins
Ductus venosus
<i>Proximal branch pulmonary arteries</i>
<i>Umbilical vein</i>
<i>Umbilical artery</i>
Pulsed Doppler interrogation
Tricuspid and mitral inflows
Pulmonary and aortic outflows

(Continued)

**Table 6. Continued**

Ductus venosus
<i>Pulmonary veins</i>
<i>Umbilical vein</i>
<i>Umbilical artery</i>
<i>Aortic and ductal arches</i>
<i>Superior/Inferior vena cavae</i>
<i>Branch pulmonary arteries†</i>
<i>Middle cerebral Doppler†</i>
Continuous-wave Doppler
<i>Valvar insufficiency (if present)</i>
<i>Ventricular outflows (if pulse Doppler abnormal)</i>
<i>Ductus arteriosus (if pulse Doppler abnormal)</i>
Ventricular function parameters
Exclusion of hydrops
Exclusion of cardiomegaly
Qualitative assessment of ventricular contractility
<i>Systemic venous Doppler examination*</i>
<i>Pulmonary venous Doppler examination*</i>
<i>Ventricular Doppler inflow examination*</i>
<i>Right and left ventricular cardiac output*</i>
<i>Ventricular shortening fraction*</i>
<i>Isovolumic contraction and relaxation time*</i>
<i>Myocardial performance index*</i>
<i>Cardiovascular profile score*</i>

Required (Class I) elements for fetal echocardiography are in plain text; elements that are reasonable to include (Class IIa) are indicated in italics. Note: In specific clinical situations, italicized elements may be recommended and therefore mandatory to perform.

AV indicates atrioventricular.

\*Elements that can be used for assessment of a known/suspected cardiac function abnormality.

†Additional elements whose usefulness is not well established but may be considered (Class IIb).

‡Required elements (Class I) for a known/suspected rhythm abnormality or if indication for examination relates to potential for rhythm abnormality.

additional testing, including amniocentesis for fetal karyotype or other appropriate testing to facilitate counseling, to provide the pregnant patient with as many options as possible for the pregnancy and for delivery planning.

#### **Follow-Up Fetal Echocardiogram**

When fetal CHD is identified or suspected, given the risk of progression for some fetal CHD,<sup>136,155</sup> serial fetal echocardiography is recommended. The necessity, timing, and frequency of serial assessment should be guided by the nature and severity of the lesion, coexisting signs of heart failure, the anticipated timing and mechanism of progression, and the options that are available for prenatal and perinatal management. Table 7 lists the potential mechanisms through which cardiac defects diagnosed before birth may evolve. This information should be incorporated into the counseling and planning of ongoing surveillance. Of note, for pregnancies at risk, if imaging of the fetal heart is inadequate on the initial scan, then a follow-up scan should be performed.

**Table 7. Mechanisms of Progression of Fetal Heart Disease**


---

Progressive atrioventricular or semilunar valve insufficiency that may result in progressive ventricular dilation <sup>158–160</sup>
Progressive atrioventricular or semilunar valve obstruction <sup>155,161,162</sup>
Progressive atrioventricular valve, ventricular, great artery, branch pulmonary artery, and arch hypoplasia secondary to obstructive lesions or reduced blood flow <sup>136,161,163–166</sup>
Development of myocarditis or cardiomyopathy <sup>167–170</sup>
Progressive myocardial dysfunction secondary to structural, functional, or rhythm disturbances that may lead to the evolution of hydrops or sudden fetal demise <sup>85</sup>
Development/progression/regression of cardiac tumors <sup>171,172</sup>
Development/progression/resolution of fetal arrhythmias (premature atrial and ventricular beats, atrioventricular block, tachyarrhythmias) <sup>156,157</sup>
Premature constriction of the ductus arteriosus <sup>173,174</sup>
Restriction of the foramen ovale <sup>175–178</sup>
Progressive cardiomegaly with high-cardiac-output states <sup>129,179–181</sup>

---

### Early Fetal Echocardiogram

A fetal echocardiogram may be performed at earlier gestational ages, including the late first and early second trimesters (<18 weeks of gestation). This has been prompted by advances in image resolution with the development of higher-frequency transducers, including those specialized for transvaginal imaging, and increasing detection of extracardiac pathology<sup>182,183</sup> at earlier gestational ages. Indications for earlier fetal echocardiogram are similar to those for midtrimester assessment; however, the earlier examinations are usually reserved for pregnancies at highest risk for CHD or for those families with a significant history of a previous child with serious CHD. The indication that has yielded the greatest number of pregnancies with a fetal cardiac diagnosis in a series of late first- and early second-trimester diagnoses is the finding of an increased NT noted on first-trimester screening ultrasound.<sup>184,185</sup> In the absence of aneuploidy, a variety of fetal heart defects have been identified in pregnancies referred for an increased NT, including atrial septal defects, ventricular septal defects, TGA, TOF, and AVSDs.<sup>78,79,122,125,184</sup> Transabdominal imaging to visualize the structures of the fetal heart is feasible in most pregnancies at 13 to 14 weeks, allowing detection of pathology<sup>184</sup>; before that time, however, transvaginal imaging may be necessary because of both the distance of the fetus from the maternal abdominal wall and the small size of the heart structures.<sup>186</sup> As a consequence of the small size of cardiac structures, image resolution at 11 to 14 weeks is typically less than that observed at later gestational ages; however, detailed segmental evaluations are still possible in the majority of fetuses, particularly at 12 to 16 weeks of gestation, with the aid of color Doppler.<sup>187</sup> Furthermore, at these earlier gestational ages, growth of the fetal heart and great arteries is more accelerated than at later gestational ages; thus, the potential for evaluating anatomic details improves significantly every week. Given the limitations in image resolution with potential to miss more subtle cardiac lesions and the potential for the progression of lesions undetectable at earlier gestation, repeat midtrimester assessment of all pregnancies evaluated before 15 to 16 weeks should be performed.

### Technical Considerations

#### Equipment

Small cardiac structures, rapid fetal heart rate, substantial depth of imaging through the pregnant abdomen, and suboptimal imaging conditions, including limited acoustic windows, maternal obesity, and fetal lie in the prone position, all contribute to the challenges of imaging the fetal heart. The ultrasound systems to be used in the performance of fetal echocardiogram should have 2-dimensional (2D) or gray scale, M-mode, color, and pulsed-wave Doppler capabilities. The use of high-frequency transducers optimizes imaging of the diminutive heart structures; therefore, the highest frequency that provides sufficient penetration for a given patient should be chosen. In the midtrimester, high-frequency transducers are sufficient for most pregnancies in women with normal body habitus and, most importantly, provide better image resolution for the smaller fetal heart structures. Later in pregnancy, lower-frequency transducers may improve penetration and permit better imaging of the fetal cardiac structures. In the late first and early second trimesters, the highest-frequency transducers should be used for both transabdominal and transvaginal imaging.<sup>187</sup>

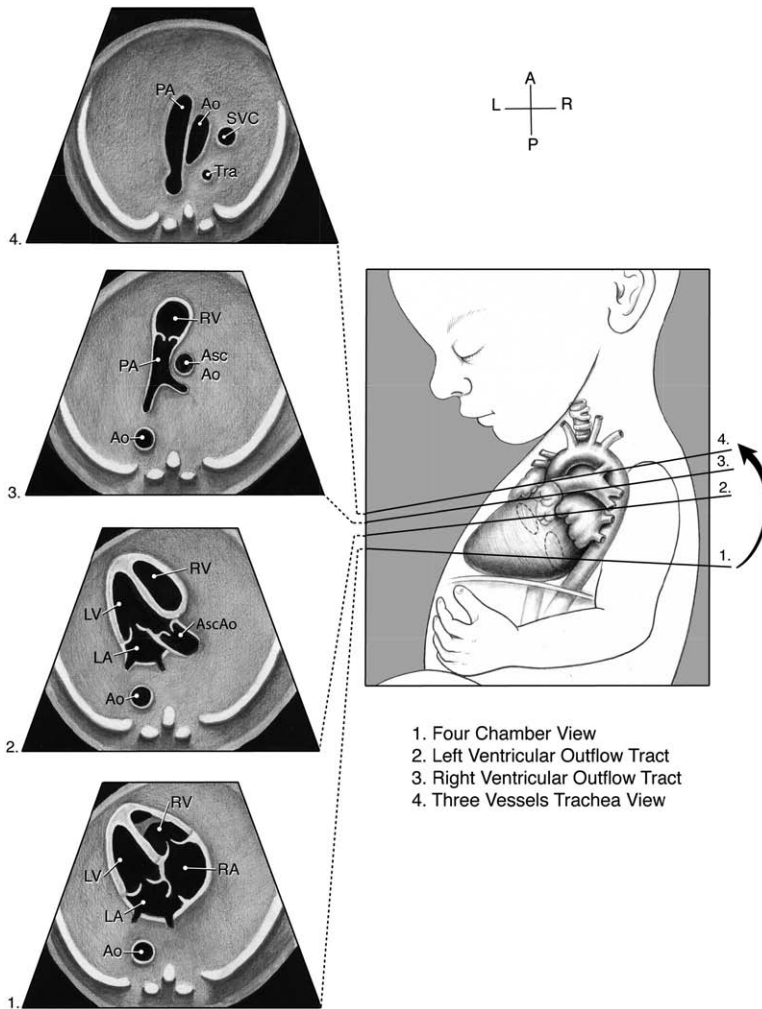
The rapid fetal heart rate necessitates optimization of individual systems to provide the highest frame rate possible (preferably >50 Hz). Narrowing the imaging depth and sector width and using dynamic zoom capabilities will increase frame rates and thus image resolution. Use of settings including little to no persistence assists in the evaluation of the rapidly beating fetal heart. A compression setting allowing a narrow dynamic range (gray scale) has better sensitivity and defines the blood-tissue interfaces. Limited use of harmonic imaging provides better penetration and endocardial definition, particularly in later gestations.

#### Ultrasound Safety

Concerns have been raised about the use of repeated ultrasound examination and the potential risk for fetal injury, in particular, modalities that have higher outputs such as Doppler and harmonic imaging.<sup>188,189</sup> Although no documented case of fetal injury related to diagnostic imaging has ever been reported, the US Food and Drug Administration has published guidelines on the intensity of ultrasound used during fetal scanning (Code of Federal Regulations Title 21, part 884, subpart C, section 884.2660), which includes maintaining low mechanical and thermal indexes.<sup>190,191</sup> The standard approach to fetal echocardiography should take into consideration the ALARA (as low as reasonably achievable) principle, limiting examinations to those that are medically necessary and the length of the assessments to what is necessary, particularly the application of higher-output modalities. This becomes especially important at earlier gestational ages when fetal tissues may be more susceptible to injury.<sup>192</sup>

#### Responsible Personnel

Given the spectrum and complexity of cardiac pathology encountered in fetal life, fetal echocardiography should be performed and interpreted by personnel who have had formal training or experience in fetal echocardiography and exhibit continuing education in and experience with the diagnosis of CHD. Fetal echocardiography demands detailed evaluation of cardiac anatomy and cardiac function with 2D imaging, M-mode imaging (for rhythm assessment), and Doppler interrogation that goes beyond the basic screening examination typically used in obstetric ultrasound. Guidelines for training for physicians who evaluate



**Figure 1.** Standardized transverse scanning planes for fetal echocardiography include an evaluation of the 4-chamber view (1), arterial outflow tracts (2, 3), and 3-vessel trachea view (4). Ao indicates descending aorta; Asc Ao, ascending aorta; LA, left atrium; LV, left ventricle; PA, pulmonary artery; RA, right atrium; RV, right ventricle; SVC, superior vena cava; and Tra, trachea. Reprinted with permission of the American Institute of Ultrasound in Medicine.<sup>149</sup> Copyright © 2013, American Institute of Ultrasound in Medicine.

1. Four Chamber View
2. Left Ventricular Outflow Tract
3. Right Ventricular Outflow Tract
4. Three Vessels Trachea View

and interpret these specialized examinations exist; a detailed discussion is outside the scope of this document and may vary regionally. It is recommended that only well-trained or experienced pediatric cardiologists, maternal-fetal medicine specialists, obstetricians, or radiologists who have acquired the appropriate knowledge base and skills should supervise and perform fetal echocardiograms. Once a diagnosis is made, consultation or referral to a provider experienced in fetal cardiology should be made before detailed counseling on diagnosis, management and outcome. Complex cases, including those with severe CHD, significant arrhythmias, or heart failure, should be referred to centers with extensive experience in fetal/pediatric cardiovascular care and the management of congenital cardiovascular disorders.

## Fetal Heart Examination

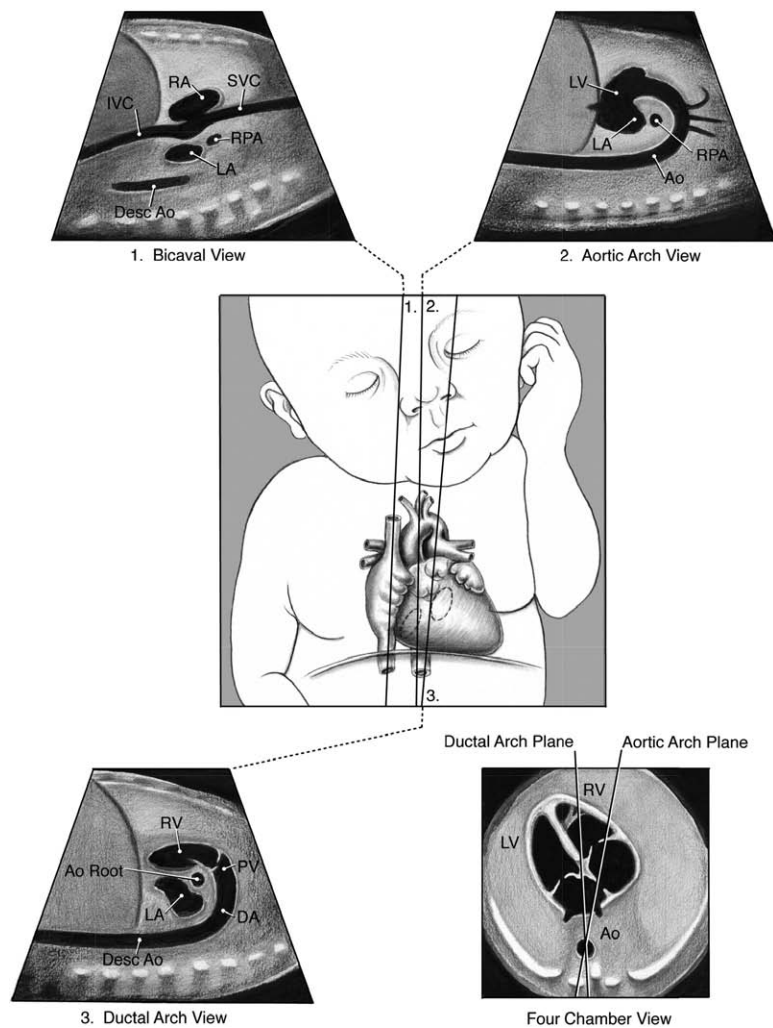
### *Elements of the Fetal Echocardiographic Examination*

All fetal echocardiograms should include acquisition of essential elements (Class I) that are necessary for exclusion of structural, functional, and rhythm-related cardiac disease (Table 6). Inclusion of additional elements (Class IIa) can be useful in the basic examination; however, they should be performed in the setting of CHD, in the presence of certain extra-cardiac anomalies, or if there is risk or concern for abnormal heart function or abnormal cardiac rhythm.

The fetal echocardiogram should include detailed 2D/gray-scale imaging of all cardiovascular structures; color Doppler interrogation of all the valves, veins, arteries, and atrial and ventricular septae; pulsed Doppler of the valves and ductus venosus; and assessment of cardiac rhythm and function. Additional measurements (cardiac biometry, including chamber length and valve measurements, additional pulsed Doppler measures, and quantitative evaluation of cardiac function) can be useful and are reasonable to perform (Table 6). The inclusion of such elements, beyond those considered to be required elements of the examination, provides the fetal specialist with additional information, facilitating the recognition and quantification of subtle pathology that may not be otherwise suspected.

For every examination, the initial assessment must include determination of fetal position for accurate assessment of visceral and atrial situs. Although standard planes of imaging used in postnatal cardiac imaging are not always possible because of variable and often suboptimal fetal position, cross-sectional and sagittal sweeps through the fetal torso and long- and short-axis sweeps of the fetal heart should be attempted. In addition, the 4-chamber view with sweeps through the outflow tracts and the 3-vessel view with sweeps through the mediastinum should be obtained.<sup>151</sup> Figures 1 through 3 show representative views and sweeps of the fetal heart.<sup>149</sup>





**Figure 2.** Sagittal views of the superior and inferior vena cavae (1), aortic arch (2), and ductal arch (3). The scan angle between the ductal arch and thoracic aorta ranges between  $10^{\circ}$  and  $19^{\circ}$  during pregnancy as illustrated by the 4-chamber view diagram. Ao Root indicates aortic root; Desc Ao or Ao, descending aorta; DA, ductus arteriosus; IVC, inferior vena cava; LA, left atrium; LV, left ventricle; PV, pulmonary valve; RA, right atrium; RPA, right pulmonary artery; RV, right ventricle; and SVC, superior vena cava. Reprinted with permission of the American Institute of Ultrasound in Medicine.<sup>149</sup> Copyright © 2013, American Institute of Ultrasound in Medicine.

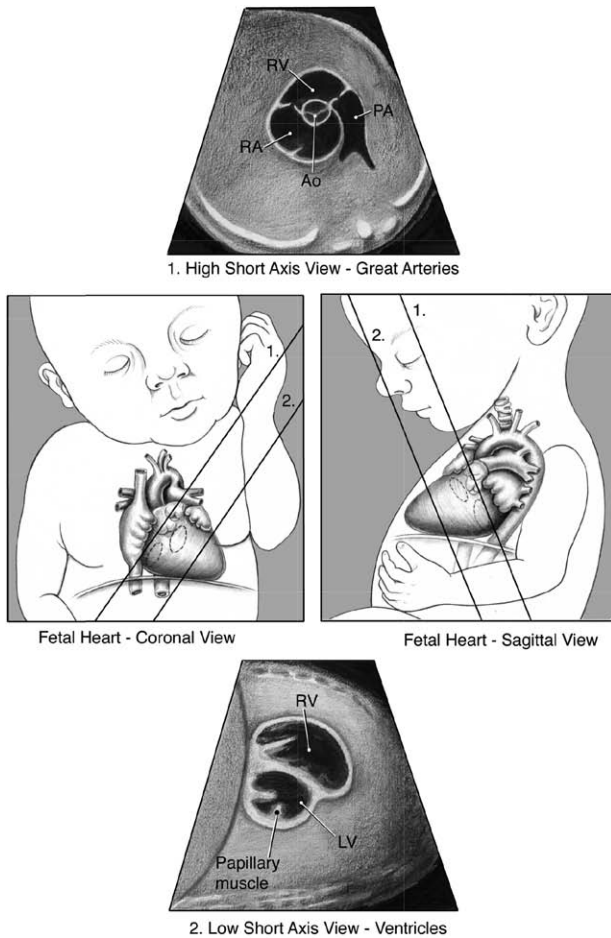
As is true after birth, a segmental approach to defining cardiac anatomy and pathology is an important component of fetal cardiac assessment. The examination should start with a gross assessment of the cardiac position and axis, which may be altered in the presence of cardiac or extracardiac intrathoracic pathology.<sup>193</sup> A segmental approach should include definition of systemic and pulmonary venous connections, atrial and ventricular connections and morphology (including relative chamber size, wall thickness, and anatomy of the atrial/ventricular septum), AV and semilunar valve morphology and size, ventricular arterial connections, great artery size and position relationships, and an assessment of aortic and ductal arches, including their position relative to the trachea and their size relationship with each other. Heart disease in the fetus may involve any or all aspects of the cardiac anatomy. Given that subtle lesions such as semilunar valve obstruction and coarctation of the aorta may progress<sup>136,155</sup> and may be clues to more important underlying extracardiac diagnoses,<sup>194</sup> when an abnormality is identified, a detailed assessment reduces the likelihood of missing aspects of the cardiac anatomy that may contribute critically to the surgical risks and prognosis of the lesion. All major structural CHD and many less severe forms of heart disease have been documented by fetal echocardiogram, and the accuracy of fetal echocardiography in defining

specific anatomical details beyond the basic diagnosis has been demonstrated.<sup>195–198</sup>

Imaging of the fetal heart is unique relative to that of other aspects of the fetal anatomy in that the heart is a dynamic, constantly moving structure that rhythmically beats usually more than twice per second. Static 2D images do not demonstrate abnormalities of fetal heart structure, function, and rhythm; thus, they negate the basic purpose of fetal echocardiography. The dynamic assessment of cardiac structures has been recommended in previous guidelines for a detailed fetal echocardiogram.<sup>150–152</sup> Therefore, during the performance of a fetal echocardiogram, digital cine clips of the beating heart should be acquired, stored, and retained for subsequent review.

In addition to the assessment of fetal heart structures, basic fetal biometric measurements, including head circumference, biparietal diameter, abdominal circumference, and femur length, are reasonable to obtain if not readily available from the obstetric examination. An evaluation for the presence of pleural and pericardial effusions, ascites, and integumentary edema should be made. Two or more of these features establish a diagnosis of fetal hydrops. Nonimmune hydrops accounts for 76% to 87% of all cases of hydrops, and of those, primary cardiovascular disorders account for 15% to 25%,<sup>85</sup> whereas many noncardiac causes of nonimmune hydrops alter





**Figure 3.** Low and high short-axis views of the fetal heart. Ao indicates aortic valve; LV, left ventricle; PA, pulmonary artery; RA, right atrium; and RV, right ventricle. Reprinted with permission of the American Institute of Ultrasound in Medicine.<sup>149</sup> Copyright © 2013, American Institute of Ultrasound in Medicine.

cardiac loading and heart function and result in the evolution of fetal heart failure, also manifested as hydrops.<sup>85,86</sup>

### Doppler Imaging

Color Doppler adds utility to fetal cardiovascular assessment by providing confirmatory information on valve function and vessel patency. Pulsed Doppler interrogation of the valves may provide additional information to color Doppler and thus should be included in the performance of the fetal echocardiographic examination. Since the late 1980s, all published investigations describing the application of fetal echocardiography in the detection and evaluation of fetal heart disease have included the use of Doppler modalities, lending further support for their importance.

Most of the evidence for the routine application of Doppler in the evaluation of the fetal heart has focused on the use of color Doppler. Color Doppler has been shown to confirm the patency of ventricular inflows, outflows, anatomy, and flow through the arches; competency of AV and semilunar valves; appropriate connection of systemic and pulmonary veins; and documentation or exclusion of septal defects.<sup>199–201</sup> In the normal fetus, it reduces scanning times, permitting rapid assessment of the relationship and patency of cardiac structures.<sup>199</sup> It

facilitates recognition of normal and abnormal anatomy when 2D image resolution is suboptimal<sup>199</sup> and may be especially helpful at earlier gestational ages.<sup>187,202</sup> In 1 study, color-flow mapping was documented to be essential for accurate anatomic diagnosis in 29% and useful in making a complete diagnosis in an additional 47% of pregnancies.<sup>200</sup> In another large study, color-flow mapping was shown to be additive, particularly with the detection of AV valve insufficiency, demonstration of turbulent high-velocity jets of semilunar valve stenosis, altered ductal and distal arch flow, and septal defect shunting.<sup>201</sup> More subtle outflow tract obstruction has been identified through the detection of flow acceleration across the pulmonary or aortic valves that may otherwise have been missed in routine 2D imaging.<sup>203</sup> In the presence of more severe fetal CHD, abnormal flow patterns through the ductal or aortic arch, particularly flow reversal as identified by color and pulsed Doppler, have been shown to herald the presence of critical pulmonary or aortic outflow tract obstruction.<sup>204,205</sup> Color Doppler has also been shown to facilitate identification of the source of pulmonary blood flow in more complex disease.<sup>206</sup> Color Doppler interrogation of all valves and cardiac vessels, including veins and arteries, the septae, and ductus venosus, should be included in all fetal echocardiographic examinations (Table 6).

Less evidence exists to support the additive value of pulsed Doppler in the routine assessment of the fetal heart. Nevertheless, pulsed Doppler has been shown to contribute importantly to the understanding of fetal heart function and fetal circulation in both normal fetuses and those with disease. Normative data are available that define blood flow patterns and peak velocities through the mitral and tricuspid valves,<sup>207</sup> aortic and pulmonary valves,<sup>208,209</sup> branch pulmonary arteries,<sup>210</sup> aortic isthmus,<sup>211</sup> ductus arteriosus,<sup>209</sup> and pulmonary<sup>212</sup> and systemic veins.<sup>213</sup> Pulsed Doppler interrogation of the ventricular inflows, systemic and pulmonary veins, ductus venosus, and umbilical vein provides clues to the diastolic properties and filling of the ventricles not obtainable with color Doppler.<sup>167</sup> Pulsed Doppler assessment of ventricular outflows can be used to calculate ventricular stroke volumes and outputs<sup>214</sup> and may be helpful in pregnancies at risk for high fetal cardiac output, including but not limited to anemias, arteriovenous malformations, acardiac twin gestations, and agenesis of the ductus venosus.<sup>129,179,180</sup> Reversal of flow in diastole in the aortic isthmus may identify the fetus with significant vasodilation of brain vessels or “brain sparing.”<sup>211</sup> Pulsed Doppler interrogation of pulmonary venous flow may be used not only to confirm normal and abnormal pulmonary venous connections<sup>215</sup> but also to provide evidence of the severity of left atrial hypertension in fetuses with hypoplastic left heart syndrome (HLHS) and a restrictive or intact atrial septum.<sup>175–177</sup> Although the additional information contained in the pulsed-wave Doppler signal over the information present in an apparently normal color Doppler signal in an otherwise normal fetal heart has not been directly studied except in specific diseases such as TTTS and maternal DM, the subtle functional and structural abnormalities that produce an abnormal pulsed Doppler signal may provide additional important information for the fetal heart assessment. It is therefore recommended that pulsed Doppler of the AV inflows and ventricular outflows, in addition to interrogation of the ductus

venous, be included in the fetal echocardiographic examination (Table 6). Additional measures and pulsed Doppler interrogation of other structures and vessels is reasonable, particularly on a disease-specific basis in fetuses with suspected cardiovascular or extracardiac pathology.

Continuous-wave Doppler may be useful as an adjunct to pulsed Doppler in the performance of a fetal echocardiogram, although this technology may not be available on curvilinear probes and cardiac specific probes may be needed. Continuous-wave Doppler can be used to assess ventricular systolic pressures through interrogation of AV valve insufficiency jets<sup>161,216</sup> or gradients through ventricular outflow tracts<sup>161</sup> and arches.<sup>173,174</sup> This information may provide additional insight into the pathophysiology and severity of a given lesion, although it must be interpreted in the context of gestational age, ventricular function, and the specifics of the fetal circulation. Of note, the fetal circulation provides challenges to defining lesion severity in the presence of the unique fetal shunts that permit redistribution of ventricular preload and output to the contralateral ventricle or great artery. Significant postnatal Doppler gradients may not be present prenatally; therefore, Doppler data must be interpreted with an understanding of fetal cardiac physiology.

### **Cardiac Biometry**

The presence of ventricular or great artery size discrepancy may provide important clues to the basic diagnosis and the spectrum of severity. A smaller pulmonary valve or main pulmonary artery compared with the aortic valve or ascending aorta suggests the presence of pulmonary outflow tract obstruction.<sup>163,217</sup> Conversely, a significantly smaller aorta relative to the main pulmonary artery and aortic relative to the ductal arch may suggest the presence of important left heart obstruction such as coarctation of the aorta.<sup>164,218</sup> Chamber size discrepancy with a smaller left relative to right side of the heart could be secondary to altered pulmonary venous return<sup>219</sup> or a restrictive foramen ovale.<sup>178</sup> It may also occur as a consequence of right heart pathology that leads to an increased volume load to the right heart, including tricuspid<sup>158,159</sup> or pulmonary insufficiency,<sup>160</sup> severe pulmonary outflow obstruction,<sup>220</sup> or ductus arteriosus constriction.<sup>173</sup> Right heart dilation may also be observed in the presence of arteriovenous malformations such as vein of Galen aneurysm<sup>221</sup> or in agenesis of the ductus venosus where umbilical venous return results in preferential streaming to the right heart.<sup>129</sup>

Valve and chamber size can be assessed qualitatively or quantitatively. Quantitative assessment includes 2D measurement of valve diameter and chamber length, with comparison of the right side with the left side of the heart. For both qualitative and quantitative assessment, the valves on the right side of the heart should be slightly larger than those on the left, and the right ventricular length should be equal to the left ventricular length in the 4-chamber view. Measurements and *z* scores that adjust the measures for gestational age are available for determining whether a measurement falls outside the normal range for gestational age and may facilitate the detection of subtle abnormalities or disease progression during serial assessment.<sup>222–225</sup> Qualitative assessment of chamber and valve size should be included in the performance of a fetal echocardiogram with comparison of right- and left-sided structures.

Additional quantitative measurement of valve diameters and right and left ventricular length is reasonable and particularly beneficial if qualitative assessment suggests an abnormality. Measurement of structures using *z* scores is useful when serial examinations are being done to determine disease progression.

### **Cardiac Function Assessment**

Intrinsic abnormalities of the fetal myocardium, structural heart defects, persistent tachyarrhythmias and bradyarrhythmias, and altered loading conditions may contribute to reduced fetal myocardial function. Increased ventricular and atrial filling pressures associated with more severe myocardial dysfunction or cardiac/systemic venous compression lead to increased central venous pressures, which ultimately culminate in the evolution of fetal heart failure manifested as hydrops.<sup>85</sup> Myocardial dysfunction may also jeopardize the well-being of the fetus through the development of fetal hypoxia and acidosis secondary to altered umbilical venous return, reduced placental function, and altered cardiac output, which may result in sudden fetal demise presumably in the face of limited reserve and hypoxia. Finally, fetal hypoxia secondary to more severe placental insufficiency may also contribute to myocardial dysfunction.<sup>226,227</sup> Although the assessment of fetal heart function is one of the main functions of the fetal echocardiogram, consensus does not exist as to the extent to which such an evaluation, whether qualitative or quantitative, should be done, particularly as part of the basic fetal echocardiogram. A qualitative assessment of heart function is recommended as part of a fetal echocardiogram; however, a wide variety of approaches for the evaluation of fetal cardiac function are available and may be useful, particularly in certain disease processes as outlined below and elsewhere in this document (Table 6).

Cardiomegaly is an important sign of altered fetal heart function.<sup>168,228,229</sup> The cardiac size relative to the thorax may be evaluated from cross-sectional images through the fetal chest with measurements of cardiothoracic diameter, cardiothoracic area, and cardiothoracic circumference ratios.<sup>228,229</sup> From a cross-sectional view of the thorax, the heart area is usually about one third the size of the thorax. Although quantitative assessment is not necessary if qualitatively there is a normal cardiothoracic ratio, measurement may be useful in the assessment of fetuses with structural or functional CHD or in those at risk for myocardial dysfunction or high cardiac output states.

Systolic function of the fetal heart should include qualitative assessment of both the right and left ventricles with evaluation of contraction using real-time or video cine clip images. Both ventricles should be equally dynamic. In the expanded examination, quantitative measurement of ventricular internal dimensions during systole and diastole from 2D<sup>223</sup> or M-mode<sup>230,231</sup> images permitting calculation of shortening fraction (shortening fraction=[end-diastolic–end-systolic ventricular diameter]/end-diastolic dimension) should be considered. The calculation of shortening fraction is more appropriately applied to the left ventricle given that the right ventricle tends to contract by shortening along its long axis as a consequence of differences in fiber orientation. Left ventricular shortening fraction does not change from the mid to the third trimester.<sup>230</sup> Measures of shortening fraction may be useful in assessing and following up the fetus at risk for myocardial dysfunction; however,

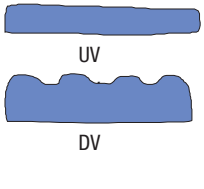
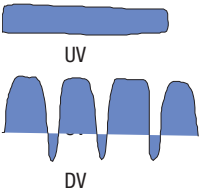

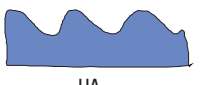
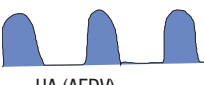
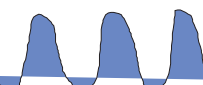
errors may be made if the planes through the fetal heart do not remain constant as the ventricles contract and if the fetal position does not permit measurements axial to the plane of imaging. Estimation of ejection fraction with a modified Simpson technique has also been reported in the fetus with validation in animal models.<sup>231</sup> The diminutive nature of the fetal heart, with potential to amplify calculation errors and assumptions of the ventricular geometry that may not be true of the fetal heart, contribute to the inaccuracy of this measure of systolic function in utero and therefore is not recommended.

Several parameters using pulsed Doppler are available to assist in the evaluation of systolic and diastolic function in the fetus.<sup>232-234</sup> Diastolic function may be assessed by ventricular inflow Doppler patterns, including duration and the relationship of filling during early and late diastole, and assessment of systemic venous Doppler waveforms. Diastolic dysfunction may be less well tolerated by the fetal circulation than systolic dysfunction, as suggested in a retrospective study of fetal cardiomyopathies in which diastolic dysfunction was associated with an 8-fold increased risk of fetal mortality relative to other parameters of fetal heart function in a multiple logistic regression analysis.<sup>168</sup> Short-duration, monophasic ventricular inflow Doppler flow patterns have been observed in fetal cardiomyopathies, the recipient in TTTS, ductus arteriosus constriction, and severe semilunar valve stenosis,<sup>161,168,173,174,235-237</sup> and have been shown to be predictive of progressive ventricular hypoplasia in the presence of severe semilunar valve obstruction.<sup>235,236</sup> Doppler interrogation of blood flow in the inferior vena cava or hepatic veins, ductus venosus, and umbilical vein can also be used in the assessment of functional pathology of the fetal

heart. Increased "a" wave reversal in the inferior vena cava, the presence of any "a" wave reversal in the ductus venosus, and umbilical venous pulsations are abnormal and often are seen in the presence of increased central venous pressures. Other measures of ventricular function may be assessed in the fetus at risk for or with myocardial dysfunction. From simultaneous left ventricular inflow and outflow samplings, the isovolumic relaxation time of the left ventricle, a measure of diastolic function, can be assessed<sup>238,239</sup> and may be prolonged in the presence of certain fetal cardiomyopathies, CHD associated with ventricular dysfunction, or growth restriction.<sup>168,216,239,240</sup> Global left or right ventricular function can be estimated from calculations of the myocardial performance index (MPI) in which the sum of the isovolumic relaxation and contraction times (or the ejection time subtracted by the time interval between 2 consecutive inflows) are divided by the ejection time.<sup>241,242</sup> An abnormal MPI has been demonstrated in many fetal cardiac abnormalities associated with altered function, including myocardial pathology in TTTS recipient twin, ductus arteriosus constriction, and Ebstein anomaly.<sup>168,242,243</sup> Ventricular function assessment with pulsed Doppler can be useful as part of the expanded fetal cardiac examination for fetuses at risk for or with myocardial dysfunction.

The prognosis of some forms of fetal heart failure can be assessed with the cardiovascular profile (CVP) score<sup>244</sup> (Table 8). Scoring of the 5 categories (2 points for each), including hydrops, venous Doppler, heart size, heart function, and arterial Doppler, has been studied as it relates to prognosis in fetuses with hydrops, CHD, and growth restriction.<sup>226,245,246</sup> The CVP score may be useful in the baseline and serial evaluations for fetuses at risk for or with myocardial dysfunction. Finally, abnormalities of

**Table 8. Cardiovascular Profile Score**

	Normal, 2 Points	-1 Point	-2 Points
Hydrops	None	Ascites or pleural effusion or pericardial effusion	Skin edema
Venous Doppler (Umbilical vein and ductus venosus)	 UV DV	 UV DV	 UV pulsations
Heart size (heart area/ chest area)	>0.20 and ≤0.35	0.35-0.50	>0.50 or <0.20
Cardiac function	Normal TV and MV RV/LV FS >0.28 Biphasic diastolic filling	Holosystolic TR or RV/LV FS <0.28	Holosystolic MR or TR dP/dt < 400 or monophasic filling
Arterial Doppler (umbilical artery)	 UA	 UA (AEDV)	 UA (REDV)

Note: Cardiovascular profile score is 10 if there are no abnormal signs and reflects 2 points for each of 5 categories: hydrops, venous Doppler, heart size, cardiac function, and arterial Doppler.

AEDV indicates absent end-diastolic velocity; dP/dt, change in pressure over time of tricuspid regurgitant jet; DV, ductus venosus; FS, ventricular fractional shortening; LV, left ventricle; MR, mitral valve regurgitation; MV, mitral valve; REDV, reversed end-diastolic velocity; RV, right ventricle; TR, tricuspid valve regurgitation; TV, tricuspid valve; UA, umbilical artery; and UV, umbilical vein.

Hofstaetter et al,<sup>245</sup> copyright © 2006, Informa Healthcare. Reproduced with permission of Informa Healthcare.



myocardial structure and function may affect the fetal circulation, including placental blood flow and fetal growth,<sup>247</sup> and conversely, placental pathology may contribute to fetal hemodynamic compromise through fetal hypoxia.<sup>226,227</sup> The assessment of umbilical artery pulsatility may be useful in these conditions. Recent experience has also suggested that fetal cardiac pathology can influence cerebral blood flow.<sup>248,249</sup> Thus, assessment of middle cerebral Doppler flow might be useful; however, the definitive link between cerebral Doppler changes, neurological insult, and long-term neurodevelopmental outcomes is still to be elucidated.

### Fetal Rhythm Assessment

A fetal echocardiogram should always include assessment of the fetal heart rate and rhythm. Several techniques are available for these assessments, including 2D, M-mode, and pulsed Doppler imaging.<sup>250</sup> M-mode imaging was the first modality used to define arrhythmia mechanism. With the sample cursor placed through the more trabeculated right atrium and either ventricle, the relationship between atrial and ventricular contractions can be demonstrated, and heart rate can be measured.<sup>60,61</sup> Pulsed Doppler recordings of simultaneous left ventricular inflow and outflow,<sup>251</sup> superior vena cava and ascending aortic flow,<sup>62</sup> or pulmonary artery and pulmonary venous flow permit documentation of the relationship between mechanical atrial and ventricular systole.<sup>63</sup> In the presence of a fetal arrhythmia, including isolated ectopy, bradycardia, or tachycardia, documentation of the relationship between atrial and ventricular contractions is important. Differentiating between types of arrhythmia mechanisms is helpful in establishing a differential diagnosis and may be useful in determining the most optimal therapy and the likelihood of success of arrhythmia treatment (discussed in the Fetal Therapy section).<sup>62,63</sup> Any of the techniques mentioned may be used to evaluate arrhythmia mechanism and should be included as part of the expanded fetal echocardiogram to assess the fetus with a suspected or documented arrhythmia.

### Limitations of Fetal Echocardiography

Certain fetal heart abnormalities will not be consistently identified, particularly when image resolution or fetal lie is suboptimal. Fortunately, most of these lesions represent pathologies that do not affect fetal health or the well-being of the infant at birth. Small or moderately sized ventricular or atrial septal defects, minor valve lesions, single/partial anomalous pulmonary venous connections, and coronary artery anomalies are among the lesions that may be undetectable before birth.<sup>197</sup> Certain postnatally acquired forms of CHD such as supralvalvar mitral ring and fibromuscular subaortic stenosis are typically not diagnosed before birth. Cardiac lesions that progress later in gestation, including obstructive lesions, rhabdomyomas, and certain cardiomyopathies, may not be evident in earlier gestation and warrant repeated assessment for pregnancies at risk.<sup>136,155,167,169,171,172,252</sup>

### Advanced Techniques in the Evaluation of the Fetal Heart

The evaluation of the fetal heart relies principally on 2D echocardiography and color-flow and pulsed Doppler techniques. Advanced modalities provide complementary perspectives, offering additional insights into fetal cardiac structure, function, and rhythm. The evaluation of fetal cardiac structure/function

has been expanded with the development and application of 3-dimensional (3D) and 4-dimensional (4D) fetal cardiac imaging, cardiovascular MRI, tissue Doppler imaging (TDI), and strain/strain rate imaging of the fetal heart. At the same time, the evaluation of fetal cardiac rhythm has been enhanced with the development and application of fetal electrocardiography and fMCG. Table 9 summarizes current COR and LOE about the usefulness of these tools in clinical practice. These new technologies are still under investigation; however, in specific instances, some are reasonable to consider in clinical practice.

### Three-Dimensional and 4D Ultrasound

#### Uses

Three-dimensional and 4D ultrasound has been applied to fetal cardiac screening, the evaluation of CHD, and the quantitative, volumetric assessment of cardiac chamber size and function. The acquisition, display, and manipulation of 3D and 4D cardiac volumes require specialized transducers, sophisticated algorithms, and technical expertise. These considerations, along with resolution concerns and a substantial learning curve, have slowed the widespread clinical application of 3D/4D technology to fetal cardiac imaging. Nevertheless, various applications of this technology have enhanced the quantitative measurement of fetal cardiac chamber volumes and ejection fractions.<sup>253</sup> Clinically, the technique has the potential to improve screening of low-risk pregnancies for CHD, particularly when combined with telemedicine and algorithms to automate extraction of various planes from the 3D/4D data set.<sup>254</sup>

#### Acquisition

Acquisition of 3D/4D volumes of the fetal heart currently may be performed with 3 different approaches: nongated reconstructive 3D, gated reconstructive 3D/4D, or real-time, volumetric 3D/4D.

The most basic approach to 3D volume acquisition uses an automated, nongated sweep of a 2D image plane across the fetal heart. Simultaneous acquisition of spatial coordinates enables the reconstruction of a single-volume data set. The reconstructed volume contains a large number of still, tomographic ultrasound images, with no regard to temporal or spatial motion. Advantages of the static 3D acquisition of the fetal heart include its rapid speed of acquisition (0.5–2 seconds) and the ease of volume manipulation. Major disadvantages of static 3D acquisition include its limited resolution and inability to assess events related to the cardiac cycle, valve motion, and myocardial contractility. Moreover, nongated reconstructive acquisitions fail to provide important clues to cardiac anatomy offered with gated acquisitions.<sup>255</sup>

The technique of gated reconstructive 3D/4D sweeps the ultrasound plane across the fetal heart while obtaining spatial coordinates for each pixel within each plane; however, in addition, this technique uses a sophisticated algorithm to evaluate temporal information on the cardiac cycle, thus enabling the reconstruction of multiple volumes, each representing a discrete point in the cardiac cycle. First described in 1996,<sup>256,257</sup> the technique was adapted to clinical ultrasound as spatiotemporal image correlation.<sup>258–260</sup> Spatiotemporal image correlation acquisitions may be combined with other imaging modalities such as color, power, or high-definition-flow Doppler.<sup>261,262</sup>

**Table 9. Summary of Current and Potential Roles of Advanced Techniques in Evaluating the Fetal Heart**

Technique	Current Uses	COR/LOE	Potential Future Uses*	COR/LOE
3D/4D echocardiography	N/A		Screening for CHD Qualitative assessment of cardiac structure Quantitative assessment of cardiac function/volumes	IIb/B
Cardiovascular MRI	Evaluation of viscerocardiac situs, venous returns, and associated extracardiac malformations	IIa/C	Assessment of cardiac structure and ventricular volume and function	IIb/B
Tissue Doppler	Evaluation of time intervals and rhythm	IIa/B	Evaluation of ventricular function	IIb/B
Strain and strain rate imaging	N/A		Evaluation of ventricular function	IIb/B
Fetal electrocardiogram	Fetal monitoring after rupture of membranes	IIa/A	Noninvasive assessment of fetal conduction/rhythm abnormalities	IIb/C
Fetal magnetocardiography	Evaluation of fetal arrhythmias, known or suspected conduction disorders, sinus/atrioventricular node disease (note: limited use because of a lack of availability)	IIa/B	Mobile fetal magnetocardiography unit for potential on-site use	IIb/C

CHD indicates congenital heart disease; COR, class of recommendation; LOE, level of evidence; MRI, magnetic resonance imaging; N/A, not applicable; 3D/4D, 3-dimensional/4-dimensional fetal echocardiography.

\*Potential uses are assigned Class IIb given that the clinical utility of these applications remains under investigation

Four-dimensional ultrasound with spatiotemporal image correlation for the measurement of fetal cardiac ventricular volume, stroke volume, and ejection fraction has been validated in small balloon and animal models<sup>263,264</sup> and can be used in mid and late gestation in human fetuses.<sup>253,264–266</sup> Disadvantages of reconstructed, gated acquisitions include prolonged acquisition times, which introduce artifact related to fetal movements or maternal breathing during the acquisition.

Real-time 3D/4D volume acquisitions of the fetal heart have been performed since 1999.<sup>267</sup> The major advantages of real-time 3D/4D acquisitions are that gating of the heart rate is not required and that volumes of the beating heart are displayed instantaneously. Current technology allows either biplane imaging (the display of 2 simultaneous planes without the need for moving the transducer)<sup>268</sup> or a rendered real-time display of any portion(s) of the pyramidal volume data set.<sup>269,270</sup> Several small postnatal studies have shown the superiority of real-time 3D/4D imaging compared with conventional 2D ultrasound in the evaluation of CHD,<sup>272,272</sup> but there have been no such comparison studies in fetuses with CHD. Currently available systems are limited by the size of the acquired volume, often too small for a complete evaluation of the fetal heart and great vessels. Over time, sweep volume<sup>273</sup> and full-volume (multiple volumes acquired in succession) techniques may mitigate this limitation of current real-time 3D/4D technology.

### Display

Options for display of data from fetal cardiac volumes include selected, orthogonal 2D images from within the volumes (multiplanar displays) or internal/external spatial views of the heart (volume-rendered/surface-rendered displays). Guidelines for standardization of display of postnatal 3D/4D cardiac views have been published.<sup>274</sup>

The multiplanar display conventionally includes 3 orthogonal 2D planes and has been used for nongated and gated reconstructive and for real-time 3D/4D fetal echocardiography. Advantages of the multiplanar display include its use of

familiar 2D planes and nonconventional planes and the ability to view cardiac abnormalities from 3 orthogonal views simultaneously. The addition of color Doppler to multiplanar displays has been shown to be feasible for the evaluation of normal and abnormal hearts.<sup>275</sup> Tomographic ultrasound imaging represents a variation on the multiplanar display that provides a sequential anatomic view of a region within the acquired volume.<sup>276,277</sup> This method resembles the display of images from computed tomography and MRI.

Algorithms for the automatic extraction and display of diagnostic cardiac planes<sup>278–280</sup> or cavities<sup>281</sup> from 3D/4D volumes have been described. Automated sonography has the potential to standardize and simplify the ultrasound examination of the fetal heart by eliminating the need to acquire multiple views in real time. Tomographic ultrasound imaging may facilitate the clinical application of automated sonography, controlling for inherent variability in fetal cardiac anatomy (cardiac axis, cardiac position in chest, size of chest) by providing multiple parallel planes for review. This approach has been applied to evaluation of the outflow tracts in fetuses with d-TGA.<sup>282</sup> Rendered displays mimic actual visualization of external features (surface renderings) or internal features (surgeon's eye views), combining data from multiple planes into a single display. These modes have enabled 4D visualization of normal and abnormal fetal cardiac anatomy and may be useful in evaluating the anatomy and morphology of the AV valves, the ventricular septum, and the arrangements of the great arteries.<sup>283,284</sup>

The current resolution of 3D/4D cardiac imaging data sets has limited the clinical utility of the technique. However, in some settings, the use of 3D/4D fetal cardiac imaging may complement or enhance the ability of conventional 2D imaging to provide important structural and functional information. The ability to store entire volume data sets enables virtual examinations of the fetal heart after data acquisition, either on site or remotely via electronic transmission. Nevertheless, image resolution remains relatively low, and significant potential remains for missed or false diagnoses. In a recent study, remote analysis of volume data sets



by experts in fetal cardiac diagnosis yielded mostly correct diagnoses, but the details of anatomy were not thought to be accurate enough for exclusive use in clinical decision making.<sup>285</sup>

In summary, 3D/4D fetal cardiac imaging is currently a research tool and is not adequate for use as an alternative to conventional fetal cardiac imaging. However, this technology may be useful to facilitate screening for CHD or for complementary imaging in fetuses identified as having CHD.

## Cardiovascular MRI

### Uses

Although advances in magnetic resonance technology have expanded the clinical role of MRI for pediatric patients with CHD, the application of MRI to the fetal heart has been limited because of the small size of fetal cardiac structures, random fetal motion, and the challenge of gating the rapidly beating fetal heart in the absence of a fetal electrocardiogram. Furthermore, in contrast to conventional ultrasound technology, MRI requires expensive, large, less portable equipment, as well as specialized expertise to perform and interpret. Nevertheless, MRI offers several advantages over obstetric ultrasound. Fetal position, rib calcification, maternal obesity, and oligohydramnios, particularly during the third trimester, interfere more with ultrasound imaging than with MRI. If the challenges relating to motion and cardiac gating can be overcome, MRI has the potential to provide high-resolution imaging of the fetal heart in multiple planes and to generate volume data sets with greater resolution than those obtained with ultrasound, offering the potential to provide robust quantitative evaluation of cardiac function and chamber volumes and to provide unique perspectives on venous and arterial anatomy, viscerotrial situs, and thoracic extracardiac malformations affecting fetal cardiovascular structure/function.

### Acquisition

Early feasibility studies in fetuses have used half-acquisition single-shot turbo spin echo sequences with variable success.<sup>286,287</sup> Some investigators, by combining these sequences and balanced steady-state free-precession sequences, have achieved better images.<sup>288,289</sup> The development of these more sophisticated sequences, with improved temporal resolution, has enhanced the ability of MRI to evaluate fetal cardiac structure despite fetal motion and rapid fetal heart rates.<sup>290,292</sup> However, although these advanced sequences can generate highly useful information without true gating, this single-shot imaging approach has limited spatial resolution.<sup>287</sup> High-resolution, gated fetal cardiac MRI has been performed in chronically instrumented sheep with the use of cine steady-state sequences.<sup>292</sup> The ongoing development of additional algorithms, including metric-optimized gating,<sup>293</sup> may help to establish a clinical role for gated fetal cardiac MRI, but at present, its use mostly lies in the research arena.

In summary, with increasingly sophisticated MRI technology, faster imaging sequences, improvements in resolution, and innovative gating algorithms, fetal cardiac MRI has the potential to complement ultrasound imaging in the evaluation of fetal viscerotrial situs,<sup>288,290,294</sup> cardiac structure,<sup>286,288–292</sup> and cardiac function.<sup>287,292</sup> Although the clinical utility of the technology has not been well established and although it currently is used

mostly as a research tool, fetal cardiac MRI is reasonable to perform in the evaluation of certain forms of fetal cardiovascular disease, including heterotaxy and systemic venous anomalies, and in the assessment of associated extracardiac malformations.

### Risk

Fetal cardiac MRI poses small theoretical risks from associated electromagnetic fields, thermal heating, and acoustic noise. However, MRI of the fetal heart appears to be safe for both the fetus and the mother.<sup>295,296</sup>

## Tissue Doppler and Strain and Strain Rate Imaging

### Uses

Tissue Doppler, 2D speckle, and tissue and feature tracking are among the newer ultrasound-based techniques that have been demonstrated postnatally to provide enhanced, quantitative, noninvasive assessment of myocardial motion and mechanics, including analysis of wall motion and calculation of myocardial strain and strain rate. These techniques have been applied to the fetus in a variety of settings.

### Tissue Doppler Imaging

TDI represents a quantitative and temporally precise analysis of segmental wall motion and myocardial velocity. TDI has been shown to be useful in the evaluation of impaired systolic and diastolic cardiac function in children and adults and can be of clinical value in the early identification of cardiac dysfunction.<sup>297</sup> In the fetus, TDI has been applied to the evaluation of myocardial motion- and time-related event analysis.<sup>96,298,299</sup> Reference ranges for TDI time intervals, including mechanical PR intervals, have been established<sup>96</sup> and may be useful in the assessment of fetuses at risk for AV block. Myocardial TDI velocity indexes obtained with color TDI have been reported, including normal data of fetal myocardial velocities and MPI in the left and right annulus and the interventricular septum.<sup>96,300</sup> In a prospective study in 25 growth restricted fetuses, TDI demonstrated both systolic and diastolic tissue velocity abnormalities compared with normal fetuses, whereas pulsed Doppler detected only an increase in left ventricular MPI with all other indexes, including E/A ratios, outflow tract velocities, and right ventricular MPI, being similar to those in controls.<sup>301</sup> TDI has also been applied to the assessment of diastolic dysfunction in fetuses of diabetic mothers and other complicated pregnancies<sup>302,303</sup> and in the presence of TTTS,<sup>304</sup> CHD,<sup>305</sup> heart failure,<sup>306</sup> and arrhythmias.<sup>307</sup>

In summary, TDI evaluation of fetal cardiac function may be considered in clinical practice, although its usefulness has not been established and the technique currently remains a research tool. However, TDI evaluation is reasonable to use in the assessment of fetal cardiac rhythm.

### Strain and Strain Rate Imaging

The deformation of tissue, normalized to its initial size or shape and expressed as a percentage, is referred to as strain. Strain rate is the rate at which this tissue deformation occurs. The initial application of strain imaging used Doppler technology. Another method, known as 2D speckle tracking, relies on identifying patterns of gray scale within small regions and allows direct calculation of strain from changes in distance

between tracked features rather than calculating on the basis of velocity measurements.

There have been several small studies of strain and strain rate in fetuses using color Doppler TDI or 2D speckle tracking at various gestations in normal fetuses.<sup>233,308–319</sup> Several of these studies have applied 2D speckle tracking echocardiography to the normal midgestation to late-gestation fetus for the assessment of longitudinal mechanics, although only 1 study to date has also addressed circumferential strain.<sup>318</sup> In general, feasibility is reasonable, although some studies have reported up to 20% to 30% interobserver variability. Absolute measures of strain and strain rate differ between color Doppler TDI and 2D speckle tracking, and the techniques have been shown not to be interchangeable within the same fetus,<sup>319</sup> although changing trends during gestation should be similar. There are conflicting data using strain and strain rate analysis in normal fetuses. Peak longitudinal strain for the right ventricle is higher than for the left ventricle in most studies, but there is disagreement about gestational age–related change. Technique variation and variation in reporting (global versus regional values) may also be factors contributing to discrepant results across studies.<sup>310,311,313,317</sup>

The clinical relevance of the information obtained with strain techniques with respect to fetal myocardial function remains to be proven. Concerns exist about vendor-specific image acquisition, storage, and processing, resulting in limited cross-vendor applicability.<sup>145,320–324</sup> Standardization in measurement and reporting has still not been achieved. Frame rate limitations, which may result in a loss of temporal detail and dramatically increase the variability of measurement even within the same fetus,<sup>316</sup> are problematic. Thus, at present, the role of strain and strain rate imaging in the assessment of fetal cardiac function is yet to be determined, and its usefulness has not been established in clinical practice.

## Advanced Evaluation of Fetal Cardiac Rhythm

### Uses

The evaluation of fetal rhythm ideally should extend beyond diseases associated with bradycardia or tachycardia to include conditions in which conduction disturbances are possible, including maternal medication exposure, hydrops, myocardial dysfunction, intrauterine growth restriction, and TTTS, among others. Although a fetal echocardiogram alone can diagnose many fetal arrhythmias (discussed in the Fetal Echocardiography section), the technique relies on assembly of the sequence of atrial and ventricular events that represent mechanical activation rather than electric activation of the heart, and it is fundamentally limited in its potential to identify fetal conduction disease. fMCG and fetal electrocardiography are able to more precisely diagnose fetal arrhythmias and conduction disorders and can define the finer nuances of arrhythmia diagnosis, uncover unsuspected arrhythmias, accurately assess the effects and toxicity of antiarrhythmic therapy, and provide insight into developmental fetal electrophysiology.<sup>325–331</sup>

### Fetal Electrocardiography

Although fetal electrocardiography has been available for decades, its clinical application has been slowed for several reasons. First, the technique (which involves the use of up to 12 maternal abdominal leads, a single ground lead across the

maternal body, and a mildly abrasive cream) requires time and skill to ensure good-quality signals. Second, throughout gestation and despite sophisticated and sensitive equipment, the fetal electrocardiogram has relatively low signal-to-noise ratios. Moreover, between 24 and 35 weeks of gestation, the vernix caseosa has electric insulating properties that can further attenuate or even eliminate the fetal electrocardiography signal. Normal values for fetal electrocardiography have been reported.<sup>96,332</sup> Compared with mechanical PR intervals derived from fetal pulsed Doppler, fetal electrocardiogram PR intervals were shorter than those obtained by pulsed Doppler.<sup>96,333</sup> The utility of fetal electrocardiography in assessing first-degree AV block associated with maternal collagen vascular disease has been demonstrated.<sup>332</sup> Fetal electrocardiography during labor (using a scalp lead) for the detection of fetal compromise has been studied extensively. The ST-segment analysis algorithm measures the ratio of QRS to T amplitude, ST-segment depression, and T-wave changes to predict abnormal fetal cord blood metabolic state.<sup>334</sup> With this technique, T-wave amplitude was noted to be increased during states of asphyxia; these changes were believed to be attributable to myocardial potassium liberation during glycolysis.<sup>335</sup> Results of several randomized, clinical trials using fetal electrocardiography involving >15 000 patients after 36 weeks' gestation<sup>336–338</sup> have shown variable results in the outcome measures of reduction in metabolic acidosis, decrease in moderate/severe neonatal encephalopathy, and operative delivery rate. Although the use of fetal electrocardiography may be reasonable to consider in the assessment of cardiac conduction and rhythm in fetuses with known or suspected diseases of the conduction system, its utility has not been established. Monitoring of fetal heart rate with fetal electrocardiography during labor after the rupture of membranes can be useful and is reasonable to perform.

### Fetal Magnetocardiography

fMCG is a noninvasive means of assessing electromagnetic characteristics of fetal cardiac conduction. Magnetometers used to perform fMCG use superconductor physics principles to measure magnetic fields. The studies must be performed within a magnetically shielded room that excludes magnetic interference from environmental sources. Unlike MRI, fMCG devices represent passive receivers that do not produce energy or alter magnetic energy states. Because of the requirement for specialized equipment and expertise, fMCG is currently performed in only a small (albeit increasing) number of centers worldwide.

fMCG provides heart rate trend analysis, raw rhythm recordings at gestations >17 to 24 weeks, and signal-averaged recordings.<sup>339</sup> The fMCG captures the P wave, PR interval, QRS interval, ST-T waves, QT interval, and RR interval in most fetuses of >24 weeks' gestation and QRS and RR intervals in fetuses of >17 weeks' gestation.<sup>340–343</sup> With the use of fMCG, normative data for cardiac intervals, including gender-based intervals and those in multiple pregnancies, have been established.<sup>340,341,344,345</sup> Compared with mechanical PR intervals derived from fetal pulsed Doppler, fMCG PR intervals were shorter than those obtained by pulsed Doppler.<sup>346</sup> Similar to Holter monitoring, the fMCG can display uninterrupted segments of recorded time during normal rhythm or during arrhythmias.<sup>343,347</sup> fMCG may therefore be especially useful for analyzing complex rhythm

and rate patterns such as irregular, multiple, or transient arrhythmias and for providing a more accurate differential diagnosis of tachycardias and bradycardias. No other current method can detect repolarization abnormalities such as T-wave alternans.<sup>331</sup> Over the past decade, fMCG has been reported in case series and has increased the understanding of the pathophysiology of life-threatening arrhythmias such as LQTS,<sup>348</sup> CHB,<sup>330,349,350</sup> and various tachyarrhythmias with or without Wolff-Parkinson-White syndrome.<sup>351,352</sup> fMCG has led to modifications in medical therapy of arrhythmias in some cases.<sup>329–331,353</sup>

Unlike fetal electrocardiography, fMCG allows raw signal analysis even in the presence of an irregular rhythm. fMCG holds an inherent advantage over fetal electrocardiography in signal-to-noise ratios because the conductance properties of magnetic signals are not affected by poor conductivity of fetal and maternal tissues. Only a limited number of studies have compared contemporaneous fetal electrocardiography and fMCG recordings.<sup>354,355</sup> Case studies and small case series documenting postnatal follow-up present compelling evidence that fMCG provides prenatal information concordant with postnatal findings during persistent fetal arrhythmias.<sup>329</sup> Although fMCG currently has limited availability, use of this technique is reasonable in the assessment of cardiac conduction and rhythm in fetuses with known or suspected disease of the conduction system.

### Extracardiac Assessment of the Fetus With CHD

The wide range of associations between CHD and other anomalies have been known for decades, and it is considered axiomatic in prenatal diagnosis that any fetus with 1 anomaly may also have others.<sup>68</sup> Some of these anomalies lend themselves to prenatal diagnosis through imaging, whereas others may manifest only after birth. In addition, our knowledge about genetic conditions in general is rapidly expanding, with diagnostic modalities such as array comparative genomic hybridization testing now revealing new insights into genetic origins for an expanding number of conditions in which CHD is present in isolation or in combination with other anomalies. Some fetuses will come to cardiac evaluation after being first diagnosed with other extracardiac anomalies or genetic abnormalities (discussed in the Indications for Referral for Fetal Cardiac Evaluation section), whereas for other fetuses, the CHD prompts investigation for extracardiac abnormality or genetic syndrome. In all, surveillance during the remainder of gestation may be recommended because of the increased risk for fetal compromise resulting from the cardiac or extracardiac anomalies. Because of implications for pregnancy management and outcomes, all fetuses with recognized CHD should undergo assessment for extracardiac abnormalities.

### Genetic Abnormalities and CHD

#### *Incidence*

Approximately 15% of infants with CHD have recognizable chromosomal abnormalities.<sup>356</sup> Most of these are aneuploidies, with trisomies 21, 13, and 18 and monosomy X making up the majority. Fetuses with CHD, however, exhibit a much higher incidence of karyotype abnormalities, on the order of 30% to 40% in most series<sup>194,357–362</sup> and up to 56% in selected high-risk populations.<sup>202,363</sup> Cardiac defects in the fetus have

been associated with autosomal trisomies, many of which are not seen clinically in postnatal life, including trisomy 9, 16, and 8 and partial monosomy for chromosomes 4p, 5p, 8p, 10p, 11q, and 20, among others.<sup>55</sup> The disparity between fetal and postnatal incidence and spectrum of disease is likely attributable to a higher in utero mortality in many of these patients. Additionally, gestational age at assessment of the population will affect the incidence because some abnormalities are compatible with longer duration of intrauterine survival than others.<sup>364,365</sup>

#### *Available Genetic Testing*

Many types of genetic testing are currently clinically available, with other testing still in the research phase.<sup>55</sup> Conventional metaphase chromosome banding for karyotyping of fetal cells obtained via amniocentesis or chorionic villus sampling has been the mainstay of prenatal genetic testing for decades. High-resolution banding permits analysis of smaller regions of the chromosome than standard karyotyping but is used less often. More recently, fluorescent in situ hybridization for the detection of abnormal complement of chromosomes 13, 18, or 21 or sex chromosomes in interphase (nondividing) cells has become available with the advantage that the test provides results much more rapidly than karyotyping, which requires cells to be actively dividing and may require 7 to 10 days for results to be available. Fluorescent in situ hybridization techniques can also be used to assess metaphase chromosome preparations for microdeletions not detectable by visual banding techniques through the use of region-specific labeled probes to detect copy-number variation in the region of interest. This is widely used in clinical practice for the detection of deletions of chromosome 22q11.

Noninvasive prenatal testing for fetal aneuploidy has been made available recently using massively parallel sequencing of cell free DNA in the maternal circulation.<sup>366</sup> A detection rate of trisomy 21 of 99.5% with a screen positive rate of 0.2% has been reported.<sup>366</sup> Although noninvasive prenatal testing is not currently commercially available for subchromosomal analysis, research studies have already been published on the ability of this technology to detect fetal 22 q11 deletion and other deletions and duplications.<sup>367,368</sup>

Abnormalities of chromosome complement do not account for all cases of fetal heart malformation. It has been estimated that 70% to 85% of fetuses with isolated cardiac malformation and 25% to 65% of those with additional extracardiac abnormalities will have normal karyotype and fluorescent in situ hybridization.<sup>194,357,369,370</sup> These patients may benefit from microarray-based comparative genomic hybridization testing, which has been shown to detect abnormalities in an additional 5.2% (95% CI, 1.9–13.9) of fetuses with ultrasound-detected anomalies and normal karyotype.<sup>371</sup> Many submicroscopic chromosomal rearrangements that lead to copy-number gains or losses have been identified in fetuses with CHD through the use of comparative genetic hybridization testing. The question of whether this test should be used as a replacement for routine testing with traditional cytogenetics (karyotyping and fluorescent in situ hybridization) has been a topic of recent debate.<sup>372,373</sup> Microarray analysis is not useful when there is no net gain or loss of chromosomal material. Balanced rearrangements such as reciprocal and robertsonian translocations, inversions, and balanced insertions are not detectable by comparative genetic



hybridization testing. This has led most clinicians to adopt a sequential approach to testing whereby advanced testing is performed only after a normal karyotype result has been obtained.<sup>374</sup> Because microarray-based comparative genomic hybridization testing may also uncover copy-number variants, microdeletions, and chromosomal derangements of unknown significance, there is a risk of introducing uncertainty in prognosticating that should be disclosed thoroughly to the patient before testing in the context of relative risk versus benefit of this type of testing.

Other tests that can be performed prenatally are DNA mutation analysis and direct sequence analysis. Commercially available DNA mutation analysis is available for several disorders involving cardiac structural, functional, and electrophysiological conditions. If the index of suspicion is high such as in a fetus with a family history or suspicion of LQTS, commercial testing of amniotic fluid may be considered. The diagnosis of Noonan syndrome can also be made with this analysis in fetuses with normal karyotype and findings including pulmonary stenosis, polyhydramnios, and pleural effusions.<sup>375</sup> Other single-gene disorders with familial inheritance may also lend themselves to prenatal genetic testing, although this should be reserved in most cases for instances in which a family member has been previously confirmed to be affected.

Although invasive sampling of the pregnancy has been necessary until recently, the refining of techniques for recovery of fetal DNA from maternal serum is showing promise for the development of noninvasive assessment for fetal aneuploidies.<sup>376–379</sup> This will likely change the way genetic testing of the fetus found to have sonographic evidence of disease is managed in the future. As a means of keeping abreast of the latest genes and availability of testing, the reader is referred to online resources such as Online Mendelian Inheritance in Man ([www.ncbi.nlm.nih.gov/omim](http://www.ncbi.nlm.nih.gov/omim)) and GeneTests (<http://www.genetests.org/>), which are updated regularly. In addition, a more detailed analysis and review of the current status of knowledge about the genetic basis for CHD were the subject of a recent AHA scientific statement.<sup>55</sup> The interested reader is referred to this publication for a more in-depth discussion.

#### Genetic Abnormalities Associated With CHD

Certain cardiac lesions are recognizable as being associated with a higher prevalence of abnormal chromosome complement, microdeletions, or individual gene variations. Ventricular septal defects and AVSDs are the lesions most often found to be associated with karyotype abnormality<sup>357</sup>; however, several other cardiac defects also carry a higher-than-expected incidence of chromosomal aberrations (Table 10). In 1 series, aneuploidy rates were highest for AVSD (80%), coarctation (49%), TOF, and ventricular septal defects (45%),<sup>361</sup> but in other series, the detection rates of aneuploidy in AVSD and TOF have been reported to be closer to 55% and 20% to 25%<sup>365</sup> respectively.<sup>381,382</sup>

On the order of 50% to 70% of fetuses with AVSDs and normal situs have been found to have trisomy 21.<sup>360,381,383</sup> Conotruncal lesions and right aortic arch have been found to be associated with 22q11 deletion. In 1 fetal series, 15% to 50% of fetuses diagnosed with TOF had a 22q11 deletion.<sup>384</sup> Similar findings are true of truncus arteriosus,<sup>385</sup> TOF with absent pulmonary valve,<sup>386</sup> and TOF with pulmonary atresia<sup>387</sup> at 32%, 26%, and 25%, respectively. An isolated right aortic

**Table 10. Risk of Aneuploidy With Selected Cardiac Malformations**

Lesion	Risk, % <sup>113,360,380</sup>
Atrioventricular septal defect	46–73
Coarctation/arch interruption	5–37
Double-outlet right ventricle/conotruncal malformations	6–43
Hypoplastic left heart syndrome	4–9
Heterotaxy/cardiosplenic syndromes	0
Pulmonic stenosis/atresia with intact septum	1–12
Transposition of great arteries	0
Tetralogy of Fallot	7–39
Truncus arteriosus	19–78
Tricuspid valve dysplasia (including Ebstein malformation)	4–16

arch was found in 10% of fetuses with 22q11 deletion. If there were additional cardiac findings, the incidence of 22q11 deletion rose to 21%<sup>388</sup> (Table 11). A diagnosis of cardiac tumor (single or multiple) in the mid-gestation or late-gestation fetus should also prompt genetic testing and evaluation because >60% of fetuses will have tuberous sclerosis.<sup>171,172</sup>

Conversely, certain cardiac defects are rarely associated with aneuploidy; these include heterotaxy syndrome,<sup>194</sup> d-TGA,<sup>381,389</sup> congenitally corrected TGA,<sup>382,390</sup> and pulmonary atresia with intact ventricular septum (PA/IVS).<sup>381,389</sup> Parents of fetuses with these diagnoses should still be offered genetic testing in association with genetic counseling but with the expectation that for most the testing will provide negative results that will reassure but may not necessarily contribute to prognosis for the current pregnancy. As greater experience develops with microarray-based comparative genomic hybridization testing, many of these lesions will have genetic markers identified.<sup>391</sup>

#### Genetic Testing of Fetuses With CHD

Given that fetuses with “isolated” CHD diagnosed by ultrasound carry at least a 15% to 30% risk of chromosomal abnormality,<sup>357</sup> genetic testing and counseling should be recommended for all fetuses with a diagnosis of cardiac malformation regardless of whether other anomalies are present. Detection of a chromosomal or genetic abnormality in a fetus with CHD serves several purposes. Identification of an abnormality may prompt further investigation for additional anomalies. Knowledge of a genetic cause for the cardiac defect will allow more specific and appropriate assessment of recurrence risk for the parents of the fetus and for the child as he or she reaches reproductive age. In some cases, genetic testing of the parents may be indicated either as a surrogate for testing the fetus (in single-gene, autosomal-dominant syndromes such as DiGeorge, Holt-Oram, Williams, and Alagille) or as adjunctive testing in assessment of recurrence risk (in cases of suspected balanced translocation in 1 parent) or clinical significance of copy-number variants detected on microarray-based comparative genomic hybridization testing. Finally, decisions on terminating the pregnancy or carrying to term but not pursuing aggressive postnatal management may be greatly influenced by knowledge of the genetic basis of disease, specifically in cases of aneuploidy or microdeletions associated with poor functional or neurodevelopmental outcomes.

**Table 11. Estimated 22q11 Deletion Frequency With Selected Cardiac Defects**

Lesion	Estimated Frequency, % <sup>113,361,380</sup>
Interrupted aortic arch	50–90
Ventricular septal defect (overall)	10
Ventricular septal defect with aortic arch anomaly	45
Truncus arteriosus	35–40
Tetralogy of Fallot	8–35
Isolated aortic arch anomaly	25
Double-outlet right ventricle	<5
Transposition of the great arteries	<1

Modified with permission from Pierpont et al.<sup>65</sup> Copyright © 2007 American Heart Association, Inc.

## Extracardiac Abnormalities

### Incidence

Infants with CHD may have additional extracardiac anomalies in up to 20% of cases.<sup>1</sup> In fetuses, this percentage is higher, with as high as 50% to 70% reported.<sup>139,194,357,361</sup> Ventricular septal defects and tricuspid atresia are often associated with other anomalies, whereas other CHD lesions such as d-TGA and PA/IVS are more often isolated. All organ systems can be affected. The frequent association of fetal cardiac anomalies with other extracardiac anomalies drives the need for any fetus identified as having CHD to have a thorough detailed ultrasound examination of all other fetal anatomy.<sup>68,95,194</sup> Other imaging modalities, including MRI, have also been used in this population. Even with vigilance and high index of suspicion, a significant number of extracardiac anomalies may go undetected or may be undetectable until later in gestation (as may be the case with some gastrointestinal anomalies); therefore, a low threshold for repeat anatomic assessment later in gestation after an initially normal extracardiac evaluation may be appropriate in some instances.<sup>194</sup>

The evaluation for extracardiac anomalies in fetuses with CHD may help guide pregnancy and postnatal management decisions. Whether the result of a specific association or coincidence, the presence of an extracardiac anomaly in a fetus with CHD may have a profound impact on neonatal care. Major abnormalities associated with CHD, including but not limited to congenital diaphragmatic hernia, renal anomalies, omphalocele, intestinal atresia, transesophageal fistula, or central nervous system abnormalities, may affect parental decisions to proceed with the pregnancy or affect the plan for postnatal care. A thorough evaluation of the remainder of fetal anatomy is thus crucial to the prenatal evaluation of any fetus with a heart anomaly.

### Fetal Survey

The components of a detailed fetal anatomy survey may vary with the clinical situation<sup>392</sup> and go beyond those of standard obstetric scanning. The Society for Maternal Fetal Medicine has issued recommendations on the detailed fetal survey,<sup>393</sup> which, according to the statement, should be performed and interpreted by an operator with expertise, and it is expected that performance of these scans will be rare outside referral practices with special expertise in the identification of and

counseling for fetal abnormalities. A detailed fetal anatomy survey is recommended in all fetuses diagnosed with CHD.

### Fetal MRI

Developmental structural brain abnormalities can be diagnosed in the fetus with MRI<sup>394</sup>; however the role of MRI in anomaly screening of the fetus with identified CHD in the presence of a normal ultrasound examination has not been established. If an abnormality is suspected on ultrasound, the yield for fetal brain MRI is high,<sup>394</sup> and it should be considered, although expertise is limited to tertiary centers at present, and the incremental benefit has not been studied. The use of MRI to assess fetal brain maturation and acquired abnormalities in the presence of CHD has also been studied,<sup>395</sup> but at present, it is considered a research tool. MRI determination of fetal lung volumes has been shown to correlate with prenatal and postnatal lung volume<sup>396</sup> and outcome in patients with lung hypoplasia in the setting of congenital diaphragmatic hernia,<sup>397</sup> and it has been used to assess fetal lung volumes in patients with CHD who are at risk for pulmonary hypoplasia.<sup>398</sup> If lung hypoplasia is suspected, MRI may be considered, although experience concerning its usefulness outside the setting of congenital diaphragmatic hernia is very limited.

## Fetal Wellness Assessment

### Rationale

The American College of Obstetrics and Gynecology has issued a practice bulletin on fetal surveillance that suggests that certain antepartum testing may be appropriate in high-risk pregnancies in which there is an increased risk of fetal demise.<sup>399</sup> Antenatal testing may identify fetal compromise and thus afford the opportunity to intervene. Some cardiac structural anomalies, functional disorders, or arrhythmias have the potential to compromise fetal cardiac output and tissue oxygen delivery. Antepartum testing may be considered in these selected cases to minimize the risk of stillbirth and related morbidities. It is important to recognize that none of these recommendations have been tested specifically in the fetus with isolated CHD, that benefits remain theoretical, and that the nature of testing and inherent false-positive results may expose the fetus and mother to unnecessary risks, including cesarean section and iatrogenic preterm delivery.

### Fetal Movement Assessment by Mother (“Kick Counts”)

Although methods may vary somewhat, the general premise of maternal fetal movement assessments relies on daily counting of perceived fetal movement events over a prespecified time period. Theoretically, decreased fetal movement will correlate with deteriorating fetal condition. Although widely practiced, there has only been 1 randomized, controlled trial of fetal movement assessment in a large population-based group of >68 000 pregnant women. This study showed no benefit, with an antepartum fetal death rate of 2.9 in 1000 in the intervention group versus 2.7 in 1000 in the control group.<sup>400,401</sup> Unfortunately, there are no such trials in high-risk pregnancies with fetal anomalies such as CHD or cardiac conditions that might put the fetus at risk as a result of hemodynamically unfavorable circumstances such as severe AV or semilunar valve regurgitation or arrhythmias. In populations with structural, functional, or rhythm-related CHD that put the fetus at



risk for developing acidosis, it may be reasonable to encourage daily maternal movement assessments beginning at 26 to 28 weeks of gestation when movement can be reliably felt; however, the usefulness is not well established.

#### ***Cardiotocography and Nonstress Testing***

Cardiotocography is a widely used method of assessing fetal well-being in high-risk pregnancies. The technique uses an ultrasound transducer on the maternal abdomen for continuous recording of fetal heart rate and a second transducer on the uterine fundus for monitoring of uterine activity. Components of the fetal heart rate that are assessed include baseline rate, variability, accelerations, and decelerations. In this way, fetal heart rate variability and reaction to uterine contractions can be monitored noninvasively. Nonstress testing monitors at baseline, whereas contraction stress testing is performed while uterine contractions are being stimulated (usually with oxytocin or nipple stimulation). Normal fetal heart rate tracings have a high predictive value for fetal wellness, with a false-negative rate of <1%<sup>402</sup>; however, the positive predictive value for an abnormal test is fairly low.<sup>401,402</sup> Cardiotocography and nonstress testing are unlikely to be useful in fetuses with arrhythmias, particularly bradycardia and CHB, but may be considered as an adjunct to other monitoring in high-risk pregnancies with at-risk structural, functional, or rhythm-related fetal heart disease beginning in the third trimester and continuing periodically until delivery, although their usefulness has not been established.

#### ***Biophysical Profile***

Ultrasound-determined biophysical profile (BPP) includes visualization of gross fetal movements, fetal tone, and fetal breathing and ultrasound assessment of amniotic fluid volume. Assessment of the fetal heart rate by cardiotocography also may be incorporated in BPP. The BPP is performed in an effort to identify fetuses who may be at risk of poor pregnancy outcome. A score is generated with a maximum (best) score of 8 or 10 (depending on whether fetal heart rate is included in the score), with 2 points for each variable noted within a 30-minute time period. When abnormal ( $\leq 6$  of 10), the fetal BPP score is a measure of the probability of tissue hypoxia and the likely degree of central acidemia, and it has been correlated with fetal venous blood pH.<sup>403</sup> A Cochrane review of randomized studies comparing BPP with conventional monitoring in high-risk pregnancies<sup>404</sup> found no evidence of survival benefit or improvement in Apgar scores in the BPP group ( $n=2974$ ). There are no randomized trials of BPP use in fetuses with CHD. In those fetuses with CHD at risk for hypoxemia and acidosis, it may be reasonable to institute BPP testing in the third trimester in combination with nonstress testing in fetuses for whom delivery might afford the opportunity to alter hemodynamics and to improve cardiac output and tissue oxygen delivery. This theoretical framework may apply to those with severe right-sided valve regurgitation (where reduction in pulmonary vascular resistance postnatally could be beneficial) or tachyarrhythmias or bradyarrhythmias refractory to transplacental therapy. Widespread recommendation for testing in these populations should be withheld until the efficacy in improving outcomes has been tested because it is likely to result in early delivery of these infants, which may introduce additional comorbidities.

### **Prenatal Counseling and Parental Stress**

Once an accurate diagnosis of prenatal CHD is made, the condition and its implications must be conveyed to the family<sup>405</sup> with prenatal counseling. The aims of prenatal counseling are 4-fold: providing an accurate diagnosis of the malformation, providing a clear and truthful picture of the prognosis, outlining management and treatment options that are available, and helping parents reach decisions concerning the form of management that is best for them.<sup>405</sup>

Once the findings and the ramifications of fetal CHD are conveyed, the care team, which may include social workers, genetic counselors, and nurse practitioners, should be available to provide support. This relates to the acknowledgment of and emotional support for parents who may wish to discontinue the pregnancy or to the sustained education and guidance of families during the time period between initial prenatal diagnosis and the point in which treatment takes place after birth.

Little research has been undertaken in determining the most effective techniques for performing prenatal counseling for CHD or the most effective strategies for providing family support. Nevertheless, a sensible, rational approach to prenatal counseling and support is possible and should be undertaken after a diagnosis of fetal CHD.<sup>405</sup>

### **Prenatal Counseling**

#### ***Essential Elements***

Prenatal counseling is an integral part of the diagnostic encounter and has an impact on overall outcome.<sup>406</sup> Counseling should be offered in temporal sequence shortly after the fetal echocardiogram, ideally on the same day. It should offer information on the nature of the specific diagnosis, with the practitioner providing an honest and truthful account of the findings. Limitations of the findings should also be discussed, including that maternal body habitus, fetal position, or early gestational age may limit the extent and accuracy of the diagnosis. Counseling should offer information on the natural history in utero, the potential for a change in or progression of disease, and prognosis for the remainder of the pregnancy. Parents should be made aware of the possible associations of CHD with specific genetic, chromosomal, or syndromic anomalies and their possible implications for management and outcome. Counseling should help alleviate parental guilt that is commonly associated with the prenatal diagnosis of fetal malformations.

Expectant parents should be informed about the possible range of treatment and management strategies in utero and after birth. Families are hoping for a normal lifespan for their child. It is important that they understand the limitations of our knowledge in this respect and the challenge in fully predicting lifelong morbidity and impact on life span for many forms of CHD.<sup>407</sup> Counseling should include information on the long-term postnatal prognosis and should be based on the most accurate and contemporary data. Such data are continually evolving as the number of survivors of CHD into adulthood increases. The counselor should be familiar with the latest outcomes data for the prenatal cardiovascular condition or should be able to refer the parents to other specialists or resources where such data are available. Known specific challenges that survivors face or unknowns for the future should be

discussed, albeit with the caveat that new solutions for current challenges may yet be discovered as the field moves forward.

### **Techniques**

The most effective techniques and styles of counseling for prenatal CHD vary, depending on the clinical condition or family situation and dynamics. Specific counseling techniques for situations when prenatal CHD is detected have not been scientifically studied. Investigational efforts in defining proper end points for good-quality counseling and in understanding the variables that influence effective counseling would be helpful in identifying the best techniques.

Despite the absence of rigorous investigational work, there are a number of basic principles of prenatal counseling for CHD.<sup>408–410</sup> Counselors must have good communicative skills and human empathy. Skills in the assessment of body language and emotional perception are important. The level of parental understanding must be judged on a continuous basis during the counseling session and adjusted accordingly. The shock and immediate grief of receiving news of the diagnosis may limit the ability of the parents to absorb all of the information being conveyed at the initial visit. Counselors should continuously judge the progress of the counseling session and try to avoid information overload. Multiple sessions may be necessary to complete adequate counseling, particularly if the mother is present alone at the initial encounter. Serial, sustained counseling should be available to parents for the duration of the pregnancy and should be offered during follow-up fetal echocardiograms or at separate encounters.

The initial counseling encounter includes an explanation of complex medical information under conditions of parental duress. As an aid for the counselor, a preset algorithm of what to say and the order in which information is given can be helpful. Such an algorithm will allow certainty in making sure all topics for discussion are covered. Printed diagrams, hand drawings, models, videos, and other media materials may be helpful in effectively conveying the diagnosis to parents. Counselors should advise about the utility of the Internet and online Web sites for information but should warn families about misleading data. One should be prepared to answer questions about conflicting information that may be found in various sources to dispel parental confusion. As innovative and experimental diagnostic or therapeutic techniques evolve, counseling may include information on new techniques and treatment options for fetal cardiovascular care that are available only at specific centers such as regional specialized centers of fetal care.

During the counseling session, the option of termination of pregnancy should be discussed. Information on the time constraints for termination based on individual state or regional legal limits should be conveyed. Timely identification of genetic/chromosomal abnormalities may strongly influence decisions concerning termination of pregnancy.<sup>411</sup> Amniocentesis and additional imaging (eg, high-level obstetric ultrasound, fetal MRI) can contribute to a more complete characterization of the fetus and may be offered to the family. Such testing may aid in making decisions about the continuation of the pregnancy or in planning for specific needs at birth for care beyond the heart.<sup>412,413</sup>

### **Decision Making**

Decision making about pregnancy termination or about non-intervention and palliative care at birth for severe anomalies

is a complex and personal process.<sup>414</sup> Parents come to their decisions with various degrees of ease or deliberation, which influences what they seek from the healthcare professional in terms of information, opinions, and support.<sup>415</sup> In a large meta-analysis of studies looking at parental decision making for child health care, influential factors included information, others with whom to talk including concerns about pressure from others, and a feeling of a sense of control over the process.<sup>416</sup> Regardless of a choice made, counselors and care providers should provide support for the decision parents make. Counselors should refrain from imposing personal bias into the discussion and should strive for the goal of providing families with all of the tools and support necessary to come to a decision that is best suited for them.<sup>417</sup>

## **Parental Stress**

### **Maternal and Paternal Effects**

The experience of prenatal testing for possible congenital anomalies is extremely stressful. Referral for fetal echocardiogram is associated with increased maternal anxiety.<sup>418</sup> Detection of CHD further increases maternal anxiety and creates unhappiness during pregnancy.<sup>419</sup> Difficulty in coping, psychological dysfunction, and distress are increased in parents given a prenatal diagnosis of CHD compared with a postnatal diagnosis, and such differences may persist even months after birth.<sup>420–422</sup> Identification of potential modifiable variables of maternal stress during pregnancy in which there is prenatal diagnosis of CHD may alter the burden of stress and is worthy of investigation. In a study of mothers given a prenatal diagnosis of CHD, psychometric testing was performed at an average of 27 weeks' gestation; depression was seen in 22%, state anxiety in 31%, and traumatic stress in 39%. Partner/marital satisfaction was associated with less maternal stress, and use of the coping mechanism of denial was associated with more maternal stress, anxiety, and depression.<sup>423</sup>

### **Fetal Effects**

Elevated maternal psychological stress during pregnancy can negatively affect fetal and child outcomes. Alterations in somatic growth, neurocognitive development, and cardiovascular health have been reported to be associated with maternal stress during pregnancy.<sup>424–427</sup> Offspring outcomes may be influenced by elevations in maternal cortisol caused by stress during pregnancy.<sup>428,429</sup> Potential physiological influences on the developing fetus such as alterations in maternal uterine artery flow and fetal hemodynamics may be the cause<sup>430–432</sup> and is worthy of exploration.

## **Fetal Therapy for Cardiovascular Conditions Before Birth**

Fetal therapy, the process of offering treatment to the human fetus before birth, is now possible and practical in a number of conditions. In addition to improved accuracy in diagnostic capacities, managing and treating the fetus as a patient are now possible. Current fetal therapeutic strategies range from maternal administration of medication with transplacental transfer to the fetus to ultrasound or minimally invasive fetoscopic-guided techniques to invasive open uterine

fetal surgery. Despite dramatic innovations, the field of fetal therapy is still young. Few randomized, controlled studies have been performed, none of which pertain to fetal cardiac therapy. Much of the hesitation with regard to fetal therapy is because of the risk to the mother and the substantial resources

and interdisciplinary personnel necessary to safely and effectively perform such care. Deciding on fetal therapy for otherwise modifiable or lethal disorders must always be weighed against the risks to the mother and against the potential for successful treatment of the condition after birth.

**Table 12. In Utero Management of Bradycardias**

Diagnosis	Primary Causes	In Utero Treatment/Management	COR/LOE	Comments
Sinus bradycardia	Ectopic atrial Pacemaker	Rule out fetal distress as a cause for bradycardia	I/A	Can be seen with heterotaxy syndromes (right and left atrial isomerism)
	Sinus node dysfunction (including immune mediated or infection)	Close surveillance until bradycardia resolves	I/A	Test for maternal anti-SSA/SSB antibodies Maternal IgG/IgM for TORCH diseases and parvovirus
	Channelopathies (including LQTS)	Surveillance for VT and second-degree AV block	I/A	Postnatal genetic test for mutations in sodium (SCN5A) and cardiac pacemaker HCN4 ion channels
		Avoid QT-prolonging drugs	I/A	Ventricular tachycardia and second-degree AV block seen in <25%. Diagnosis can be made in utero by fMCG. Postnatal 12-lead ECG, with/without genetic test for LQTS mutations
	Secondary causes (including maternal medications, maternal hypothyroidism, fetal distress or fetal CNS abnormalities)	Treat underlying cause of bradycardia	I/A	
Blocked atrial bigeminy	Atrial ectopy	Observe/reduce maternal stimulants	I/A	10% Risk of fetal SVT Baseline fetal echocardiography with weekly FHR auscultation by OB/MFM until arrhythmia resolves
AV block	Immune mediated (SSA/SSB antibody)	Observation	I/A	Structurally normal heart May have concomitant EFE or myocardial or valvar dysfunction
		Dexamethasone For second-degree block or first-degree block with findings of cardiac inflammation	IIb/B	Note: for idiopathic AV block or AV block resulting from damage to a normal AV node (ie, SSA/SSB antibody negative block), observation only, dexamethasone not recommended
		For CHB as prevention for death or cardiomyopathy	IIb/B	
		IVIg (note: IVIg as prophylaxis is not recommended)	IIb/C	
		Sympathomimetics for rate <55 bpm or higher rates with associated cardiac dysfunction or hydrops	IIa/C	
	Developmental abnormality of the AV node	Observation	I/A	Associated cardiac defects (CC-TGV, left atrial isomerism, AVSD, DORV)
		Sympathomimetics for rate <55 bpm or higher rates with associated CHD, cardiac dysfunction, or hydrops	IIa/C	
Channelopathies (including NKX2.5, LQTS)	Observation	I/A	May be associated with structural cardiac defects, progressive conduction system disease, or dilated cardiomyopathy (Lenegre syndrome)	
	Avoid QT-prolonging drugs	I/A		
	Surveillance for VT	I/A		

AV indicates atrioventricular, AVSD, atrioventricular septal defect; CC-TGV, congenitally corrected transposition of the great vessels; CHB, complete heart block; CHD, congenital heart disease; CNS, central nervous system; COR, classification of recommendations; DORV, double-outlet right ventricle; ECG, electrocardiogram; EFE, endocardial fibroelastosis; FHR, fetal heart rate; fMCG, fetal magnetocardiogram; Ig, immunoglobulin; IVIG, intravenous infusion of  $\gamma$ -globulin; LOE, level of evidence; LQTS, long-QT syndrome; MFM, maternal fetal medicine specialist; OB, obstetrician; and SVT, supraventricular tachycardia; TORCH, toxoplasma IgG, Rubella IgG, Cytomegalovirus IgG, and Herpes Simplex 1 and 2 IgG; and VT, ventricular tachycardia.

## Fetal Arrhythmia Management

### *Fetal Bradycardia*

The cause and mechanism of fetal bradycardia determine treatment strategy in utero. Table 12 provides a summary of bradycardias, including COR and LOE for treatment. The treatment of fetal bradycardia involves close observation for signs of fetal compromise or distress. Decisions on early delivery and the complications of prematurity must be weighed against therapies available, their effectiveness, and the risk to both mother and fetus. If bradycardia persists postnatally, it should be evaluated.

### *Sinus or Low Atrial Bradycardia*

Basic mechanisms include congenital displacement of atrial activation, acquired damage to the sinoatrial node, ion channel dysfunction, and secondary suppression of sinus node rate. Both left and right atrial isomerism can result in bradycardia as a result of low atrial rhythm or dual sinoatrial nodes. In these conditions, fetal heart rates range between 90 and 130 bpm. In patients with Sjögren's syndrome antibodies (SSA or SSA/SSB) or viral myocarditis, inflammation and fibrosis of the sinus node have been observed. Maternal treatment with  $\beta$ -blockers, sedatives, or other medications has been noted to suppress the sinus node rate. No fetal treatment is recommended for sinus or low atrial bradycardia.

### *LQTS and Other Ion Channelopathies*

Asymptomatic, persistent fetal bradycardia (heart rate below the third percentile)<sup>433</sup> is one of the most consistent presentations of congenital LQTS.<sup>434,435</sup> For assessment, it is critical to link fetal heart rate to gestational age–based normative values to adequately recognize these life-threatening conditions during the fetal period.<sup>435</sup> Management of the fetus with suspected LQTS includes close observation, postnatal evaluation, and measurement of the QTc by fMCG or fetal electrocardiography if available.<sup>436</sup> Fetal treatment is not recommended for bradycardia; however, torsades de pointes and ventricular tachycardia (VT) require treatment if they occur (Tables 13 and 14).<sup>435</sup> Maternal electrolyte abnormalities, especially hypomagnesemia and hypocalcemia, should be avoided, as well as drugs and anesthetic agents that lengthen the QT interval. A frequently updated list of these drugs can be found on several Web sites, most notably [www.torsades.org](http://www.torsades.org).

### *Atrial Bigeminy With Block*

Blocked atrial bigeminy produces fetal heart rates between 75 and 90 bpm when conduction is in a 2:1 AV pattern.<sup>437</sup> This condition can be mistaken for second-degree AV block. The management of atrial bigeminy is the same as for isolated premature atrial contractions. No treatment is required, although the occurrence of supraventricular tachycardia (SVT) has been documented in  $\approx 10\%$ . A baseline fetal echocardiogram to assess cardiac structure and weekly fetal heart rate auscultation by the obstetrician or maternal fetal specialist until resolution of the arrhythmia occurs is recommended.

### *AV Block*

Three types of fetal CHB have been described. A congenitally malformed conduction system associated with complex structural cardiac defects is seen in  $\approx 50\%$  to  $55\%$  of fetuses presenting

with CHB. Isoimmune CHB associated with maternal Sjögren antibodies (SSA/SSB) represents  $\approx 40\%$ . A third group has an undetermined origin. Treatment of CHB depends on the origin, the ventricular rate, and the presence and degree of heart failure. Regardless of the origin (immune mediated or structural CHB), the use of  $\beta$ -sympathomimetics (terbutaline, salbutamol, isoprenaline) to augment fetal ventricular rates when  $<55$  bpm has been reported.<sup>353</sup>  $\beta$ -Sympathomimetics are reasonable to use in fetuses with heart rates  $<55$  bpm or in fetuses with higher heart rates if there is underlying severe CHD or symptoms of fetal heart failure or hydrops. Terbutaline appears to be well tolerated, although maternal resting heart rates of 100 to 120 bpm and benign ectopy are commonly encountered.<sup>353</sup> Unfortunately, although terbutaline may increase fetal rates and prolong pregnancy, no studies have shown survival benefit. Although there is merit to the notion, because of significant technical limitations, fetal pacing has not been shown to be successful in improving survival or prolonging gestation<sup>436</sup> and therefore at present is experimental and not recommended as part of usual care.

Unlike CHB resulting from congenital malformation of the conduction system, immune-mediated block may benefit from in utero treatment with fluorinated steroids, intravenous infusion of  $\gamma$ -globulin (IVIG), or both.<sup>438–441</sup> Reported benefits of dexamethasone (4–8 mg/d) include reduction of inflammation,<sup>438</sup> reversal or stabilization of incomplete block, and improvement or resolution of hydrops or endocardial fibroelastosis.<sup>438–443</sup> Important complications of dexamethasone that have been reported include growth restriction, oligohydramnios, ductal constriction (conveyed also by the collagen vascular disease itself), maternal DM, and central nervous system side effect.<sup>441,444,445</sup> Despite these potential complications, a trial of dexamethasone for second-degree AV block or first-degree AV block if there are additional cardiac findings of inflammation (echogenicity, valve regurgitation, cardiac dysfunction, effusion, etc) may be considered to prevent progression to CHB, although its usefulness is not well established. Dexamethasone treatment of fetuses with established CHB and no heart failure may also be considered with the goal of improving survival or reducing the incidence of dilated cardiomyopathy, although its usefulness has not been established given that studies to date have been retrospective and nonrandomized and have had incomplete follow-up.<sup>444,446</sup> Given the significant risks and limited data on benefit, extensive maternal counseling should be undertaken before the initiation of dexamethasone, and the drug should be discontinued if significant maternal or fetal side effects develop. Prospective, randomized trials or a registry is necessary to establish definitive treatment recommendations for the fetus with CHB. IVIG, usually administered with dexamethasone, may be considered given that it improved survival when endocardial fibroelastosis or systolic dysfunction was present in 1 retrospective multicenter study.<sup>439</sup> The most optimal timing of administration and intervals of repeat dosing remain unknown. IVIG prophylaxis in early pregnancy is not recommended.<sup>443</sup> Risks of IVIG treatment are mainly exposure to blood products and allergic reactions.

### *Other Conditions Associated With CHB*

Idiopathic CHB has a better prognosis than other forms of CHB and can be managed without fetal treatment. Channelopathies



**Table 13. In Utero Management of Tachycardias**

Diagnosis	In Utero Treatment/Management	COR/LOE	Comments
Intermittent tachycardia (not occurring the majority of time or <≈50% of time monitored)			
SVT or AF	Observation	I/B	Frequent FHR auscultation (weekly or more frequently if needed)
VT ≥200 bpm, no LQTS	Antiarrhythmic treatment (see below)	IIa/C	
VT ≥200 bpm, fetal LQTS (suspected or confirmed)	Antiarrhythmic treatment (see below)	IIa/C	
Sustained tachycardia (occurring the majority of time or >≈50% of time monitored)			
Sinus tachycardia	Treat secondary cause	I/A	Check maternal thyroid functions and MCA Doppler for anemia
SVT or atrial flutter with hydrops or ventricular dysfunction	First or second line (transplacental):		See Table 14 for dosing ranges and monitoring recommendations Transplacental transfer of several antiarrhythmic agents decreases with hydrops. Combined therapies have been used for severe drug-refractory cases Consider delivery if near term
	Digoxin	I/B	
	Flecainide	I/B	
	Sotalol	I/B	
	Combination transplacental treatment	IIb/B	
	Third line (transplacental):		
	Amiodarone	I/B	
	Contraindicated: verapamil	III/A	
	Contraindicated: procainamide	III/B	
	Direct fetal treatment:		
Intramuscular digoxin	IIa/B		
Intracordal digoxin or amiodarone	IIb/B		
Contraindicated: intracordal adenosine (deaths reported with intracordal route)	III/B		
SVT ≥200 bpm without hydrops or ventricular dysfunction (most SVT occurs at rates ≥220 bpm; consider other mechanism if rate <220 bpm)	First or second line:		See Table 14 for dosing ranges and monitoring recommendations Frequent monitoring of fetal well-being and maternal/fetal drug toxicity Consider delivery if near term
	Digoxin	I/B	
	Flecainide	I/B	
	Sotalol	I/B	
	Third line:		
	Amiodarone	IIb/B	
Contraindicated: verapamil	III/A		
	Contraindicated: procainamide	III/B	
SVT <200 bpm without hydrops or ventricular dysfunction	Observation	I/B	
Atrial flutter	Sotalol	I/B	Digoxin will increase AV block and slow ventricular response Consider delivery if near term
	Digoxin	I/B	
	Amiodarone	IIb/B	
	Contraindicated: procainamide	III/B	
VT with or without hydrops First-line therapy	Magnesium (intravenously)	I/C	fMCG (if available) to measure QTc interval First magnesium intravenously, then lidocaine load plus maintenance Note: maternal intravenous magnesium should not be used for >48 h Amiodarone should be used only short term given potential side effects For VT, consider delivery if near term
	Lidocaine (intravenously)	I/C	
	Propranolol (oral)	I/C	
	Mexiletine (oral)	I/C	
VT (normal QTc) with or without hydrops Second-line therapy	Flecainide	I/C	
	Sotalol	I/C	
	Amiodarone	I/C	
VT (fetal LQTS suspected or confirmed)	Contraindicated: flecainide	III/C	
	Contraindicated: sotalol	III/C	
	Contraindicated: amiodarone	III/C	
Accelerated ventricular rhythm (intermittent or <200 bpm)	Observation	I/C	
Rare tachycardias with average rate ≥200 bpm			
MAT	Digoxin, sotalol, or flecainide	I/C	Rarely, tachycardia-induced cardiomyopathy can occur at heart rate <200 bpm
AET	Digoxin, sotalol, or flecainide	I/C	Consider delivery if near term
PJRT	Flecainide or sotalol	I/C	
JET	Flecainide, sotalol, or amiodarone	I/C	
JET caused by SSA/SSB	Dexamethasone	IIb/C	

AET indicates atrial ectopic tachycardia; AF, atrial fibrillation; AV, atrioventricular; COR, classification of recommendation; FHR, fetal heart rate; fMCG, fetal magnetocardiogram; JET, junctional ectopic tachycardia; LOE, level of evidence; LQTS, long-QT syndrome; MAT, multifocal atrial tachycardia; MCA, middle cerebral artery; OB, obstetrician; PJRT, persistent junctional reciprocating tachycardia; SVT, supraventricular tachycardia; and VT, ventricular tachycardia.

**Table 14. Antiarrhythmic Drugs**

Drug	Therapeutic Maternal Dose Range	Therapeutic Level and Effect	Toxicity
Digoxin	LD: 1200–1500 µg/24 h IV, divided every 8 h MD: 375–750 µg/d divided every 8 to 12 h PO (Fetal intramuscular dose: 88 µg/kg q12 h, repeat 2 times)	0.7–2.0 ng/mL Nausea, fatigue, loss of appetite, sinus bradycardia, first-degree AV block, rare nocturnal Wenckebach AV block	Nausea/vomiting +++, sinus bradyarrhythmia or AV block +++, proarrhythmia Fetal intramuscular: sciatic nerve injury or skin laceration from injection
Flecainide	100–300 mg/d divided every 8–12 h PO	0.2–1.0 µg/mL, Mild P and QRS widening, first-degree AV block, QTc ≤0.48 s, headache	Visual/CNS symptoms, BBB, QTc ≥0.48 s, maternal/fetal proarrhythmia
Sotalol	160–480 mg/d divided every 8 to 12 h PO	Levels not monitored Bradycardia, first-degree AV block, P and QRS widening, QTc ≤0.48 s	Nausea/vomiting, dizziness, QTc ≥0.48 s, fatigue, BBB, maternal/fetal proarrhythmia
Amiodarone	LD: 1800–2400 mg/d divided every 6 h for 48 h PO; lower (800–1200 mg PO) if prior drug therapy MD: 200–600 mg/d PO Consider discontinuation of drug and transition to another agent once rhythm is converted or hydrops has resolved.	0.7–2.8 µg/mL Maternal/fetal sinus bradycardia, decreased appetite, first-degree AV block, P and QRS widening, QTc ≤0.48 s	Nausea/vomiting ++, thyroid dysfunction ++, photosensitivity rash, thrombocytopenia, BBB, QTc ≥0.48 s, maternal/fetal proarrhythmia, fetal torsades with LQTS, fetal goiter, neurodevelopmental concerns
Propranolol	60–320 mg/d divided every 6 h PO	25–140 ng/mL First-degree AV block, bradycardia, increased uterine tone	Fatigue, bradycardia +++, hypotension +++, AV block, fetal growth restriction, increased uterine tone
Lidocaine	LD: 1–1.5 mg/kg IV followed by infusion of 1–4 mg/min	1.5–5 µg/mL	Nausea/vomiting ++, CNS symptoms, proarrhythmia
Mexiletine	600–900 mg/day divided every 8 h PO	0.5–2 µg/mL	Nausea/vomiting ++, CNS symptoms, proarrhythmia
Magnesium sulfate	LD: 2–6 g IV over 20 min followed by 1–2 g/h Treatment for >48 h is not recommended but redosing may be considered if VT recurs	<6 mEq/L Monitor patellar reflex	Fatigue, CNS symptoms, STOP for loss of patellar reflex and/or levels of >6 mEq/L Levels >5 mEq/L associated with maternal changes on ECG and proarrhythmia

Proarrhythmia means worsening of an arrhythmia as the result of treatment.

AV indicates atrioventricular block; BBB, bundle-branch block; CNS, central nervous system; ECG, electrocardiogram; IV, intravenously; LD, loading dose; LQTS, long QT syndrome; MD, maintenance dose; PO, orally; VT, ventricular tachyarrhythmia; and +++, very common; ++, common; and +, occasional.

such as NKX2.5, Herg (LQT2), SCN5A mutations (LQT3, Brugada syndrome), and LQT8 can manifest as AV block. Diagnosis of these syndromes can be confirmed by genetic testing after birth.

### **Fetal Tachycardia**

Fetal tachycardia constitutes a rare but important cause of intrauterine fetal nonimmune hydrops, premature delivery, and perinatal morbidity and mortality. In utero therapy for treatment of fetal tachycardia depends on its cause. In general, the goal of treatment is not conversion to 100% sinus rhythm but rather establishment of sufficient sinus rhythm to allow resolution of hydrops or ventricular dysfunction. The management of fetal tachycardia depends on gestational age at presentation, the presence and degree of fetal compromise, hydrops or other risk factors, maternal condition, and potential maternal risk from both fetal therapy and early delivery. In these instances, decisions about early delivery and the complications from prematurity must be weighed against the therapies available, their effectiveness, and the risks to both mother and fetus. For sustained tachycardias, noted for the majority of the time of evaluation (more than ≈50%), decisions about treatment depend on

fetal and maternal risk analysis with little data to support the specific treatment protocol that is likely to be most effective and to carry the lowest risk. In contrast, the treatment of intermittent tachycardia (noted less than ≈50% of the time) is likely to include close observation if the risk of treatment outweighs the benefit. Pharmacological treatment is recommended for all but the near-term fetus with sustained tachycardia with or without hydrops or for intermittent tachycardia in the presence of cardiac dysfunction or hydrops. In general, for fetuses near term, delivery is recommended. Table 13 provides a summary of tachycardias, including the COR and LOE for treatment. Medications used in transplacental (given orally or intravenously to the mother) and direct fetal treatment of tachycardias, including suggested dosing, are listed in Table 14.

### **Intermittent Tachyarrhythmias**

The majority of intermittent tachycardias remain intermittent during fetal life with no signs of cardiac compromise. These fetuses do not need treatment<sup>447</sup>; however, close follow-up is necessary in the rare event that tachycardia becomes sustained. The exception is VT with rates >200 bpm, for which treatment is reasonable because of the risk of rapid progression to hydrops.

After birth, intermittent tachycardia may require treatment; thus, empiric observation for 48 to 72 hours is recommended.

#### *Sustained SVT*

Sustained SVT, which usually occurs at rates  $\geq 220$  bpm, includes reentrant SVT, atrial flutter, and rare tachyarrhythmias. Fetal treatment is recommended if delivery does not offer lower risk; however, the choice of first- and second-line antiarrhythmic therapy and criteria for decisions about management after initial treatment failure are controversial. The use of combination therapies presents greater risk of maternal/fetal complications than monotherapy. For reentrant SVT, in many centers, digoxin, administered maternally either orally or intravenously, is used as first-line therapy because of its relatively safe profile, its long history of use during pregnancy, and the familiarity with its use. In some centers, flecainide or sotalol is used as primary therapy.<sup>448–450</sup> These agents are all reasonable as first-line agents, although there is no study to support which is the best initial therapy. Digoxin, flecainide,<sup>449,451,452</sup> sotalol,<sup>449</sup> and amiodarone<sup>453</sup> have been used as second-line therapy. Amiodarone has a more significant toxicity profile for the expectant mother and fetus<sup>454</sup> than other drugs and should be reserved as third-line treatment of life-threatening tachyarrhythmias. The duration of therapy with amiodarone should be minimized with discontinuation after hydrops resolves. Verapamil and procainamide are no longer used to treat fetal tachyarrhythmias.

Because transplacental transfer of drugs is significantly reduced with hydrops, direct fetal treatment concomitantly with transplacental therapy has been used to restore sinus rhythm more rapidly.<sup>447,455</sup> This approach may be reasonable to consider in the severely hydropic fetus, especially if the modified BPP is abnormal. Direct treatment can be intramuscular to the fetal buttock or thigh, or intracordal. Intramuscular digoxin has restored sinus rhythm successfully and safely in the hydropic fetus. Intracordal antiarrhythmic therapy has been successful in converting tachyarrhythmias; however, caution should be exercised given that there are reports of fetal deaths with the use of this strategy.<sup>456</sup> Intracordal treatment with adenosine has not been effective in maintaining sinus rhythm in fetal SVT and therefore is not recommended. After delivery, medical treatment must be reassessed relative to the antiarrhythmic drug used in utero, the length of time since the last recurrence, and the mechanism of clinical tachycardia. As many as 50% of reentrant SVT cases have no postnatal tachycardia recurrence.<sup>457</sup>

#### *Atrial Flutter*

Atrial flutter accounts for  $\approx 30\%$  of fetal tachyarrhythmias<sup>329</sup> and can be seen with myocarditis, CHD, and SSA/SSB isoimmunization. Accessory AV pathways and reentrant SVT are a common association.<sup>457</sup> Sotalol is recommended given that it has been effective in converting 50% to 80% of fetuses with atrial flutter without mortality.<sup>450</sup> Digoxin is also recommended, and amiodarone may be considered.<sup>453</sup> Procainamide is contraindicated. After delivery, transesophageal pacing or synchronized cardioversion is recommended to restore sinus rhythm. It is important to be prepared with backup external pacing after conversion because sinus node suppression may occur, although rarely, from in utero drug therapy. After delivery, medical treatment must be reassessed given that the arrhythmia may not recur.

#### *Rare Tachycardias*

Chaotic or multifocal atrial tachycardia is rare and usually is seen during the last few weeks of pregnancy. It can be associated with Costello syndrome.<sup>458</sup> Atrial ectopic tachycardia causes persistent variable atrial rates of 180 to 220 bpm with 1:1 conduction pattern, similar to persistent junctional reciprocating tachycardia, which also varies in rate. These tachycardias are difficult to treat and most often occur in the late second or third trimester. If the average heart rate is  $>200$  bpm (or  $>160$ – $200$  bpm with associated cardiac dysfunction), treatment is recommended. Junctional ectopic tachycardia is commonly associated with SSA isoimmunization in the fetus and has been noted in both the presence and absence of AV block.<sup>330,459</sup> Rare familial pedigrees with this life-threatening arrhythmia have been observed.<sup>460</sup> Digoxin is suggested as first-line solo therapy for multifocal atrial tachycardia and atrial ectopic tachycardia without hydrops or ventricular dysfunction, although sotalol or flecainide may be considered. Flecainide or sotalol is recommended as the initial treatment for persistent junctional reciprocating tachycardia or rapid atrial ectopic tachycardia. Treatment for junctional ectopic tachycardia is similar, although amiodarone has been used. Dexamethasone may be considered in the treatment of junctional ectopic tachycardia if it occurs with maternal SSA/SSB antibodies. After delivery, medical treatment is usually continued.

Tachycardia caused by positive anti-thyroid antibodies can be mistaken for atrial ectopic tachycardia or persistent junctional reciprocating tachycardia; however, ventricular dysfunction is uncommon.<sup>329</sup> Sinus tachycardia at rates of 180 to 190 bpm can be associated with infection, anemia, drug/medication use, trauma, or hyperthyroidism in the mother. Treatment of the underlying cause is recommended.

#### *Sustained VT*

VT has been observed in association with AV block, cardiac tumors, acute myocarditis, and hereditary ion channelopathies. When tachyarrhythmias and bradyarrhythmias coexist, LQTS is likely.<sup>348</sup> Rapid torsades de pointes and monomorphic VT with significant ventricular dysfunction, AV valve regurgitation, and hydrops have been reported in LQTS.<sup>329</sup> A prolonged QTc interval by fMCG can confirm the diagnosis and affect antiarrhythmic selection in this setting. If the tachycardia is related to isoimmunization or to myocarditis, dexamethasone and IVIG have been used.<sup>325,330</sup> Maternal intravenous magnesium is recommended as first-line treatment for fetal VT at rates  $>200$  bpm, but its use should be limited to  $<48$  hours duration.<sup>348,434,461</sup> Redosing may be considered in cases of recurrent VT as long as maternal magnesium levels are  $<6$  mEq/L<sup>462</sup> and there are no signs of maternal toxicity. In addition to short-duration magnesium, treatment for VT includes intravenous lidocaine, particularly with associated hydrops, or oral propranolol or mexiletine. If LQTS can be excluded, sotalol, amiodarone, and flecainide have been given, resulting in successful termination of VT.<sup>348,434</sup> Given that there are no data to support which agent is most effective, all can be considered. Of note, however, is that in the presence of suspected or confirmed LQTS or torsades de pointes, drugs with QT-prolonging potential such as flecainide, sotalol, and amiodarone are contraindicated. After delivery, medical treatment of VT should be continued.

Accelerated ventricular rhythms are slightly faster than the sinus rate, and are a more benign form of VT. They are usually seen late in gestation and generally do not require treatment prenatally or postnatally.

### **Irregular Rhythm**

Fetal ectopy occurs in 1% to 3% of all pregnancies and in general is a relatively benign condition. Because premature atrial contractions may be difficult to distinguish from premature ventricular contractions and other types of more significant arrhythmias (LQTS, second degree AV block), fetuses who present with frequent ectopic beats (bigeminy, trigeminy, or more than every 3–5 beats on average) should have a baseline fetal echocardiogram to assess cardiac structure and to determine the mechanism of the arrhythmia. In fetuses with less frequent extrasystoles, if there is any question as to the mechanism or if the ectopic beats persist beyond 1 to 2 weeks, a fetal echocardiogram is probably indicated and reasonable to perform. Atrial ectopy is 10-fold more common than ventricular ectopy. Risk of fetal tachycardia is about 0.5% to 1%, although couplets and blocked atrial bigeminy may increase this risk. Medical treatment is not recommended for either premature atrial contractions or blocked atrial bigeminy; however, interval auscultation of the fetal heart rate by the obstetrician weekly is recommended for premature ventricular contractions or frequent premature atrial contractions until resolution of the arrhythmia is documented. Table 15 provides a summary, including COR and LOE for treatment.

### **Arrhythmia Medications**

With most antiarrhythmic drugs, relatively high doses must be used during the second and third trimesters because both maternal circulating blood volume and renal clearance are increased. Maternal transplacental treatment initiated in the hospital is the mainstay of therapy, and in most cases, oral administration of antiarrhythmic agents is recommended. Exceptions include intravenous digoxin loading (in which conversion using the oral route is often delayed), short-term intravenous magnesium, and lidocaine. Direct treatment of the fetus by intracordal or intramuscular injections may have a role in more rapidly restoring sinus rhythm in the hydropic fetus, but experience with these routes is limited, and mortality for the intracordal route has been higher than with other routes. In most cases, therapy is continued until delivery. Limited information exists on the maternal-fetal transfer of antiarrhythmic agents in humans. Most drugs, with the exception of sotalol and flecainide, have diminished transplacental transfer with fetal hydrops.<sup>464</sup> These 2 drugs concentrate in the amniotic fluid in greater concentrations than in the fetus.<sup>464</sup> Neonatal conduction abnormalities have been reported with flecainide.

Serious maternal adverse effects are rare in most reported series and have in general resolved with discontinuation of therapy.<sup>250</sup> Close assessment of calcium, magnesium, electrolytes, and vitamin D for the duration of treatment is recommended to reduce the possibility of proarrhythmia in the mother and the fetus. A history of LQTS or drug-induced

**Table 15. In Utero Management of Irregular Rhythm**

Diagnosis	Cause	In Utero Management	COR/LOE	Comments
Second-degree AV block	Immune-mediated	Dexamethasone	IIb/B	May halt progression to CHB If available, fetal magnetocardiogram to exclude LQTS
	Structural CHD	Weekly follow-up	I/C	
	Channelopathy (Table 12)	Weekly follow-up	I/C	
Ventricular or frequent atrial premature beats	Idiopathic	Observation with FHR assessment at 1-wk intervals by OB until arrhythmia resolves for PVCs or frequent PACs (bigeminy, trigeminy or every 3–5 beats)	I/A	2% Also have first- or second-degree AV block; 0.5%–1% risk of developing SVT with PACs; Unknown risk for VT with PVCs. Most episodes are short-lived and benign. Evaluate for secondary causes
	Fossa ovalis aneurysm			
Secondary causes Ventricular or frequent atrial premature beats	Myocarditis	Observation with FHR assessment at 1-wk intervals by OB  Frequent assessment (1- to 2-wk intervals) of cardiac function and other parameters of fetal heart failure	I/C	
	Cardiac tumors	Observation with FHR assessment at 1-wk intervals by OB	I/C	
	Ventricular or atrial aneurysm or diverticulum	Observation with FHR assessment at 1-wk intervals by OB	I/C	
	Maternal stimulants	Observation with FHR assessment by OB	I/C	

AV indicates atrioventricular; CHB, complete heart block; COR, classification of recommendation; FHR, fetal heart rate; LOE, level of evidence; LQTS, long-QT syndrome; OB, obstetrician; PAC, premature atrial contraction; PVC, premature ventricular contraction; SVT, supraventricular tachycardia; and VT, ventricular tachycardia.



torsades de pointes in the patient or close family member should be elicited before treatment with QT-prolonging drugs, and close monitoring for maternal QTc lengthening >500 milliseconds is important. Frequent monitoring of drug levels and maternal electrocardiogram is recommended to assess drug effect and toxicity, especially with dose escalation. There are no randomized, multicenter, clinical trials for the use of antiarrhythmic agents in fetal tachyarrhythmias; therefore, treatment protocols remain center specific.

**Medical Therapy for Fetal Congestive Heart Failure**

The treatment of fetal heart failure with transplacental digoxin may be considered, although its usefulness is not well established. In a study of fetuses with heart failure, heart function improved as measured by the CVP score in a small group of fetuses treated with digoxin.<sup>465,466</sup> A dose of 0.25 mg orally twice a day was used with no maternal complications.

**Fetal Cardiac Catheter Intervention**

**Overview**

Cardiac lesions that are amenable to fetal intervention are distinctive in that they can progress rapidly from mild to severe during gestation such that there is significant irreversible myocardial damage and chamber, valve, or vessel hypoplasia at the time of birth. In this unique group of defects, there is commonly a time-limited window of opportunity to intervene when deleterious effects on cardiac growth and function are deemed to be potentially reversible. The objective of fetal cardiac intervention is to alter the natural history of an anomaly so that it either is lifesaving to the fetus or results in an improved state at birth that leads to reduction in short- or long-term morbidity or mortality (Table 16).

In the development of fetal cardiac intervention, a number of principles have been recognized. Procedural technical success does not always translate into clinical success after birth. Understanding the natural history of the malformation and the continual ability to refine patient selection are critical. When faced with novel, potentially risky prenatal therapies,

it is important to note that most forms of CHD are not lethal and that standard postnatal palliative therapy is still an option in most situations. However, for some anomalies in which an alteration in prenatal natural history for the better is possible and for those with extremely poor outcome, fetal cardiac intervention may be the best course of action and is a reasonable therapeutic option.

**Cardiac Lesions Amenable to Fetal Intervention**

*AS With Evolving HLHS*

HLHS is a form of CHD in which the left heart structures are unable, by virtue of inadequate size, function, or a combination of both, to support the systemic circulation after birth. Several developmental pathways can result in HLHS, most of which are not amenable to fetal cardiac intervention. The lesion that has been the main focus of fetal cardiac intervention over the past 2 decades is severe AS in early gestation and midgestation, which has been shown to evolve into HLHS at birth.<sup>165,236,467-474</sup> AS in the fetus is rarely isolated. The papillary muscles, mitral valve, and endomyocardium are affected to various degrees, raising the question of whether this is a more diffuse developmental defect or secondary as a result of the valvar abnormality. Unlike many other forms of univentricular CHD, which are embryological malformations from the earliest point in development, it is hypothesized that AS with evolving HLHS starts out with the cardiac chambers normally formed and most often with normal function in the first and even second trimesters.<sup>475,476</sup> As the stenosis becomes more severe, progressive LV dysfunction develops, and flow reversal at the foramen ovale and aortic arch eventually occurs such that blood is diverted away from the left heart. This, along with myocardial and valvar damage and hypoplasia, results in HLHS at birth. The goals of fetal intervention with in utero balloon dilation of the aortic valve are to improve left ventricular function, to improve flow through the left heart, to reverse the ongoing damage to the left heart structures, and consequently to promote left heart growth and the prevention of progression to HLHS.

**Table 16. Fetal Cardiac Intervention**

Anomaly	Objectives of Fetal Intervention	Effect	Indications for Fetal Intervention	COR/LOE
Aortic stenosis with evolving HLHS	Opening of the aortic valve to promote antegrade flow, to encourage growth of left-sided structures, and to create candidacy for biventricular repair	Disease modifying	Retrograde flow in transverse aorta; severe left ventricular dysfunction; monophasic and short mitral valve inflow; left-to-right flow across the foramen ovale	IIb/B
HLHS with restrictive/intact atrial septum	Opening of the atrial septum, relief of left atrial hypertension and prevention of pulmonary vasculopathy, improved oxygenation at birth	Lifesaving	Pulmonary venous Doppler pattern indicating severe impediment to left atrial egress; absence of pulmonary vasoreactive response to maternal hyperoxygenation	IIb/C
Dilated left ventricle with severe mitral regurgitation, aortic stenosis, restrictive/intact atrial septum	Opening of the atrial septum or aortic valve, decompression of left atrium and left ventricle, improved right ventricle filling	Lifesaving	Similar criteria as for HLHS with intact atrial septum; severe left atrial and ventricular dilation with compression of right-sided structures	IIb/C
Pulmonary atresia/intact ventricular septum	Opening of the pulmonary valve to encourage growth of right-sided structures and to create candidacy for biventricular repair or to treat fetal hydrops in cases of severe tricuspid regurgitation	Disease modifying or lifesaving	Factors predicting need for univentricular palliation or development of fetal hydrops	IIb/C

COR indicates classification of recommendation; HLHS, hypoplastic left heart syndrome; and LOE, level of evidence.

Timely fetal intervention preventing the evolution of AS to HLHS in utero has been reported.<sup>236</sup> Of 70 fetuses who had in utero aortic balloon valvuloplasty, the procedure was technically successful in 52 (74%). More than 30% of those delivered who underwent a technically successful fetal cardiac intervention had a biventricular circulation from birth, and another 8% were converted to a biventricular circulation after initial univentricular palliation.

Because fetal AS with evolving HLHS is relatively uncommon and probably more often than not goes undetected prenatally, clinical experience with fetal intervention for this lesion is limited. Despite the relatively small numbers, insight into the natural and unnatural histories of this lesion has been gained that has enabled more accurate selection of patients who might attain benefit from this intervention. Selection guidelines have been described and are reasonable to use for assistance in determining which fetuses are likely to benefit. First, the anatomy must be favorable in that there is AS and not atresia with evidence for antegrade flow across the aortic valve on Doppler assessment of the valve. In addition, there should be no or minimal subvalvar left ventricular outflow obstruction. Second, there should be strong evidence for the process of evolving HLHS based on the presence of depressed left ventricular function and flow abnormalities determined by fetal echocardiogram. Flow abnormalities include either retrograde or bidirectional flow in the transverse aortic arch or at least 2 of the following: monophasic inflow across the mitral valve, left-to-right flow across the atrial septum, or bidirectional flow across the pulmonary veins. Factors predicting a favorable outcome for 2-ventricle repair include a left ventricular long-axis  $z$  score  $>-2$ , the left ventricle being able to generate a pressure of at least 10 mm Hg across the aortic valve or a 15-mm Hg mitral regurgitant jet, and a mitral valve diameter  $z$  score of  $>-3$ . In essence, the larger the left ventricle and mitral valve are and the greater the ability is for the left ventricle to generate reasonable pressure, the greater the likelihood is of a successful ultimate biventricular circulation.<sup>236</sup> Given the morbidity and mortality associated with palliative surgery for HLHS, aortic valve dilation may be considered in fetuses with AS in whom the selection criteria are met. Before the procedure, extensive family counseling should detail the risks of the procedure to mother and fetus and lay out the expected clinical course for those who undergo intervention to those who choose more standard management.

Essential in the treatment of evolving HLHS is postnatal management of the infant. The neonatal and ongoing management of these patients requires insight and experience with the natural and unnatural histories of the borderline left heart. A key element of achieving a biventricular circulation in these patients is the postnatal decision making, including the use of specialized interventional catheterization procedures and surgery. Fetal intervention alone is unlikely to be adequate therapy to achieve a biventricular circulation in all candidates; therefore, delivery and management at a specialized congenital heart center are recommended.

Although it is important to appreciate the potential benefits and promise of fetal cardiac catheter intervention for critical AS evolving into HLHS by possibly creating a postnatal 2-ventricle system, the long-term benefits and outcomes of this procedure are unknown. Although outcomes for HLHS after the Fontan operation and the limitations of this strategy are relatively clear, the fetus undergoing a cardiac catheter intervention for AS may be at future risk for multiple operations, valve replacements, ventricular

dysfunction, and possibly pulmonary hypertension within the context of a borderline-size small left ventricle. Families should be counseled about these concerns and about the lack of data on long-term outcomes. Comparative analysis of these alternative strategies through careful investigational efforts is warranted.

#### *HLHS With Restrictive or Intact Atrial Septum*

HLHS with highly restrictive or intact atrial septum is among the most challenging CHDs with the constellation of defects having an extremely high mortality and substantial morbidity even after neonatal survival.<sup>477</sup> The fetus with this condition is stable in utero, although there is likely continuing damage to the pulmonary vasculature and lung parenchyma as a result of obstructed left atrial egress and impediment to pulmonary venous drainage.<sup>477,478</sup> Typically, the newborn becomes critically ill immediately after birth when blood is unable to exit the left atrium and succumbs to a combination of hypoxia, acidosis, and pulmonary edema. If such a patient goes undiagnosed prenatally and is born outside a cardiac center, survival is unlikely. If diagnosed prenatally, a well-planned delivery with urgent transfer to the catheterization laboratory can be arranged for decompression of the left atrium by balloon dilation or stent dilation of the atrial septum; however, outcomes remain poor.<sup>479,480</sup> Theoretically, some of the devastating effects on the lungs and vasculature may be reversible if an intervention can be performed at a critical point in gestation.

Because some level of restriction at the atrial septum is typical in HLHS, identifying those in whom a critical degree of atrial obstruction is present is essential in identifying candidates who will benefit from fetal intervention. Fetal Doppler assessment of pulmonary venous flow patterns can aid in gauging the degree of impediment to left atrial egress, with greater prominence of flow reversal during atrial contraction reflecting greater restriction.<sup>176,177,481</sup> Assessment of pulmonary arterial impedance through Doppler imaging during maternal hyperoxygenation can test for pulmonary vasoreactivity in the fetus with HLHS. A diminished vasoreactive response to maternal hyperoxygenation suggests an abnormal pulmonary vasculature and indicates clinically important restriction at the foramen ovale.<sup>482</sup> Either or both of these assessments are reasonable to obtain for determination if fetal intervention may be beneficial.

Several techniques used to open the atrial septum have been reported. The techniques that usually involve puncture and tearing with a balloon are complicated by the fact that the atrial septum is typically thick and not amenable to tearing. Questions concerning the most effective technique for opening the atrial septum in utero, including balloon atrial septoplasty versus stent placement, in addition to the optimal timing to perform the procedure to mitigate against the development of pulmonary vasculopathy, remain unanswered.<sup>483-486</sup> However, given the significant mortality and morbidity of HLHS with a restrictive or intact atrial septum, fetal intervention may be reasonable to perform in this disease, not only to stabilize the patient in the immediate postnatal period but also to potentially prevent or reverse the damage to the lungs and vasculature.

#### *Mitral Valve Dysplasia Syndrome With Mitral Regurgitation and AS*

A unique form of left-sided heart disease has been described in which there is severe AS or atresia with a dilated left

ventricle and severe mitral regurgitation.<sup>487,488</sup> Incompetence of the mitral valve is typically attributable to a mitral valve arcade with combined stenosis and insufficiency. Severe mitral regurgitation leads to left atrial dilatation with a restrictive or intact atrial septum. Unlike the condition of AS with evolving HLHS in which the hypothesized primary anomaly is obstruction at the aortic valve, mitral incompetence with severe regurgitation is believed to be the primary hemodynamic abnormality in this condition. Mitral regurgitation results in a dilated left ventricle, a dilated left atrium, and secondary closure of the foramen ovale. Severe dilatation of left-sided structures may compress the right side, leading to hydrops, which, if present, is most often lethal. Fetal cardiac intervention may be considered to open the aortic valve and to promote forward flow<sup>487</sup>; however, aortic regurgitation after the procedure may complicate the physiology. Opening of the atrial septum with the goal of decompressing the left atrium and improving filling of the right side has also been proposed<sup>488</sup> and may be considered. Left ventricular dysfunction and mitral valve disease may still prevent the use of the left ventricle for a biventricular repair, and a single-ventricle strategy may still be necessary after birth.

#### *Pulmonary Atresia With Intact Ventricular Septum*

Only a small subset of fetuses with PA/IVS should be considered candidates for fetal cardiac intervention. The goal is to prevent the need for single-ventricle palliation after birth. Intervention in this lesion is controversial because there are limited studies describing the natural history and fetal predictors of postnatal outcome.<sup>235,489,490</sup> The threshold for right ventricular inadequacy and nonviability as a pulmonary ventricle is much higher than is the threshold for inadequacy of the left ventricle as a systemic ventricle. Even in very small right ventricles, as long as the tricuspid valve is of an appropriate size, continued rehabilitation of the right ventricle can take place through staged surgical palliation after birth, which can result in successful achievement of a biventricular repair. In addition to promoting right ventricle growth and avoiding a single-ventricle palliation, another possible indication for intervention in right-sided disease is in the group with PA/IVS, severe tricuspid regurgitation, and hydrops in whom impending fetal demise is anticipated.<sup>491</sup> In such circumstances, prenatal intervention may be lifesaving to the fetus.

The technique for intervention in PA/IVS is more difficult than it is for the aortic valve given that the right ventricular cavity is commonly small, hypertrophied, and located behind the sternum.<sup>166</sup> Defining the optimal candidates for prenatal opening of the pulmonary valve and developing effective techniques that are unique to the right side of the heart are continuing challenges. Fetal intervention may be considered in select cases; however, benefit is uncertain.

## **Twin–Twin Transfusion Syndrome**

### *Pathophysiology*

TTTS is a serious complication occurring in  $\approx 10\%$  to  $20\%$  of monochorionic twin gestations. Fetal mortality approaches  $90\%$  to  $100\%$  if left untreated. The presence of placental vascular anastomoses is a requisite for the development of TTTS. These placental vascular anastomoses may allow intertwin transfer of vasoactive mediators, with

resultant polyhydramnios, hypervolemia, and hypertension in the “recipient” twin and oligohydramnios and hypovolemia in the “donor” twin.<sup>492–495</sup> Multiple studies have documented elevated activity of renin,<sup>493,496,497</sup> angiotensin,<sup>496</sup> and endothelin-1<sup>498</sup> in the recipient twin, which could offer a pathophysiological explanation for the observed findings in this syndrome.

### *Cardiac Effects*

In TTTS, cardiac changes in the recipient twin are well described.<sup>499–503</sup> Ventricular systolic dysfunction, cardiac chamber enlargement, ventricular hypertrophy, and AV valve regurgitation are often seen in the recipient twin of affected pregnancies. Right ventricular outflow tract abnormalities such as pulmonary stenosis, pulmonary atresia, and pulmonary insufficiency have also been reported.<sup>162,503–505</sup> Despite successful fetoscopic laser therapy, a significant proportion of right ventricular outflow tract abnormalities documented in utero persist after birth.<sup>84</sup>

Changes in venous Doppler flow patterns in the hepatic veins, ductus venosus, and umbilical vein consistent with elevated fetal central venous pressure can manifest, particularly in the recipient twin of TTTS. Quantitative methods to assess cardiac function have been used to characterize changes in TTTS, including Doppler MPI,<sup>239,499,501</sup> an index of global systolic and diastolic function.<sup>506</sup> Diastolic dysfunction in particular appears early in the disease process. The diastolic filling time may be an early cardiac finding of TTTS, distinguishing TTTS from other causes of fetal growth or amniotic fluid discordance.<sup>237,304,499</sup> These imaging techniques may provide clinicians with advanced tools to differentiate TTTS from other disease processes and may be reasonable to perform as part of the assessment of monochorionic twin gestations.

### *Diagnosis and Hemodynamic Assessment*

In clinical practice, the severity of TTTS is most often characterized by a staging system proposed by Quintero et al.<sup>507</sup> Although preliminary studies have suggested that cardiac changes may present even in early Quintero stages,<sup>239,499,501</sup> cardiac findings are not incorporated into the Quintero assessment of TTTS severity. This has led to the development of cardiovascular scoring systems to characterize the severity of cardiac involvement in TTTS.<sup>508,509</sup> The Cincinnati staging system uses fetal echocardiography to detect recipient-twin cardiomyopathy and modifies staging on the basis of the severity of recipient-twin echocardiographic abnormalities. The severity of recipient-twin cardiomyopathy is scored as an aggregate impression of the severity of AV valve regurgitation, ventricular wall hypertrophy, and ventricular function as assessed by the MPI<sup>508</sup> (Table 17). The Children’s Hospital of Philadelphia scoring system uses an inventory of 5 domains of cardiovascular status, 4 within the recipient and 1 within the donor. Abnormalities in each finding within the domains are given a higher score for worsening abnormality<sup>509</sup> (Table 18). Despite widespread appreciation for the cardiovascular pathology observed in TTTS, the role of fetal echocardiography in clinical decision making remains controversial. There are very limited data to suggest that specific cardiovascular findings are predictive of outcome.<sup>510,511</sup> Some centers integrate fetal echocardiogram findings into pretherapy evaluation of TTTS and incorporate fetal cardiac findings into the



**Table 17. Cincinnati Staging of Cardiomyopathy in TTTS**

Parameter	Mild Cardiomyopathy	Moderate Cardiomyopathy	Severe Cardiomyopathy
Tricuspid or mitral valve regurgitation	Mild	Moderate	Severe
Ventricular hypertrophy	Mild	Moderate	Severe
MPI	LV or RV MPI z score >2	LV or RV MPI z score >3	LV and/or RV MPI z score >4

Cardiomyopathy severity is assigned by the greatest degree of abnormality in any of the 3 categories: AV valve regurgitation, ventricular hypertrophy, or myocardial performance index.

LV indicates left ventricle; MPI, myocardial performance index; RV, right ventricle, and TTTS, twin–twin transfusion syndrome.

Reprinted from Habli et al,<sup>508</sup> copyright © 2011, ISUOG. Published by John Wiley & Sons, Ltd.

clinical decision-making process.<sup>512,513</sup> Other studies such as the Eurofetus trial<sup>514</sup> have suggested that laser therapy is the optimal therapy regardless of fetal status or TTTS stage and recommend laser therapy in all cases of TTTS regardless of severity of cardiac findings. This approach is perhaps supported in turn by data suggesting that cardiovascular findings are not predictive of outcome after fetoscopic laser therapy for TTTS, although this has not been systematically studied and reports are conflicting.<sup>510,515</sup> Given the body of evidence of cardiovascular manifestations in affected twin pairs, fetal echocardiography should be performed in the diagnostic assessment and initial management of TTTS.

Fetal echocardiography has been performed as part of post-procedural evaluation to assess cardiovascular response to laser therapy in TTTS. It has been shown that although the majority of cardiovascular perturbations will improve within days to weeks of therapy and ultimately resolve,<sup>516</sup> some will not and the hemodynamic condition of either fetus may suddenly worsen.<sup>517,518</sup> Therefore, although experience is thus far limited, fetal echocardiography for surviving twins should be considered at 24 to 48 hours after the procedure with additional follow-up dictated by clinical findings thereafter.

Right ventricular outflow tract abnormalities and valvar regurgitation may persist in postnatal life and not infrequently require cardiac management. In addition, after delivery, diastolic function abnormalities have been reported in surviving recipient twins,<sup>519</sup> and abnormalities in vascular function have been reported in surviving donor twins.<sup>520</sup> Given these data documenting postnatal persistence of cardiac abnormality in TTTS, postnatal echocardiogram may be considered in cases of TTTS.

## Fetal Surgery

### *Surgical Techniques*

Invasive fetal intervention is indicated if it can save the life of the fetus or alter the natural history of a condition and thus improve postnatal outcome.<sup>521</sup> Invasive fetal interventions currently exist for the treatment and management of primary extracardiac anomalies. Fetal surgery can be performed with hysterotomy and exposure of the fetus or through laparoscopic techniques with a closed uterus, depending on the anomaly

**Table 18. Domains and Specific Elements of the CHOP TTTS Cardiovascular Scoring System**

Cardiovascular Parameters	Scores		
<b>1. Ventricular elements</b>			
Cardiac enlargement*	None (0)	Mild (1)	>Mild (2)
Systolic dysfunction†	None (0)	Mild (1)	>Mild (2)
Ventricular hypertrophy‡	None (0)	Present (1)	
<b>2. Atrioventricular valve function</b>			
Tricuspid regurgitation§	None (0)	Mild (1)	>Mild (2)
Mitral regurgitation§	None (0)	Mild (1)	>Mild (2)
<b>3. Venous Doppler assessment</b>			
Tricuspid inflow	2 Peaks (0)	1 Peak (1)	
Mitral inflow	2 Peaks (0)	1 Peak (1)	
Ductus venosus flow¶	All forward (0)	Decreased atrial contraction (1)	Reversal with atrial contraction (2)
Umbilical venous pulsation	None (0)	Present (1)	
<b>4. Great vessel analysis</b>			
Outflow tracts¶¶	PA>Ao (0)	PA=Ao (1)	PA<Ao (2) RVOTO (3)
Pulmonary insufficiency	None (0)	Present (1)	
<b>5. Umbilical artery flow in donor</b>			
Umbilical artery Doppler	Normal (0)	Decreased diastolic flow (1)	Absent or reversed diastolic flow (2)

Note: domains 1 through 4 relate to findings in the recipient. Domain 5 relates to umbilical arterial flow in the donor.

Ao indicates aorta; CHOP, Children's Hospital of Philadelphia; PA, pulmonary artery; RVOTO, right ventricular outflow tract obstruction; and TTTS, twin–twin transfusion syndrome.

\*Cardiac size is determined by cardiothoracic ratio: normal <0.33; mild cardiomegaly, 0.33–0.5; >mild cardiomegaly, >0.5.

†Systolic dysfunction is assessed via qualitative visualization of ventricular function or shortening fraction with mild dysfunction of 25%–30% and >mild dysfunction <25%.

‡Ventricular hypertrophy is assessed as present or absent on the basis of qualitative visualization or right ventricular free wall z score >2 for gestational age.

§Atrioventricular valvar regurgitation is graded via color Doppler imaging of ratio of regurgitant jet area to atrial area: <25% is mild and >25% is >mild regurgitation.

¶Ductus venosus flow. If atrial contraction velocity is less than one third of the peak systolic velocity, then there is a mild decrease with atrial contraction.

¶¶Outflow tracts measurements are made at the semilunar valve annular level. RVOTO is defined as anatomic evidence for obstruction, including fibrous or muscular subvalvar pulmonary stenosis, pulmonary valve stenosis, or pulmonary atresia.

Reprinted from Rychik et al<sup>509</sup> with permission from Elsevier. Copyright © 2007, Mosby, Inc.



present. Fetal surgery may be reasonable to consider in select congenital anomalies, including large congenital cystic adenomatoid malformations with signs of hydrops, giant sacrococcygeal teratomas, severe congenital diaphragmatic hernia, and meningocele. The assessment of the cardiac function and fetal circulation with fetal echocardiography may be useful before, during, and after surgical intervention.

#### ***Cystic Adenomatoid Malformation***

Open fetal surgery with resection of large intrathoracic masses can be performed for anomalies such as congenital cystic adenomatoid malformations. Large congenital cystic adenomatoid malformation with early signs of hydrops is a fatal condition, and fetuses with this condition are potential candidates for fetal surgical intervention as a lifesaving intervention. Large congenital cystic adenomatoid malformation disturbs the fetal cardiovascular system through alterations in loading conditions by causing cardiac compression and creation of tamponade-like physiology.<sup>522</sup> Serial fetal echocardiography with Doppler interrogation can identify progressive changes reflecting alterations in ventricular filling and compliance.<sup>523</sup>

#### ***Sacrococcygeal Teratomas***

Giant sacrococcygeal teratoma is a highly vascularized tumor that functions as an arteriovenous malformation leading to massive cardiac volume overload, ventricular dilation, AV valve regurgitation, and heart failure.<sup>181</sup> Assessment of the cardiovascular impact of sacrococcygeal teratomas and determination of prognosis can be performed with serial evaluation of heart size and cardiac output measures via Doppler interrogation of left and right outflow tracts.<sup>524,525</sup> Doppler interrogation of umbilical arterial flow with the finding of diminished or reversed diastolic flow reflecting competitive “steal” from the placenta to the sacrococcygeal teratoma is a marker for poor outcome.<sup>526</sup> Surgical resection and debulking of giant sacrococcygeal teratomas through open fetal surgery or embolization of feeder vasculature through laparoscopic techniques can improve survival.

#### ***Diaphragmatic Hernia***

Laparoscopic techniques have been developed for percutaneous endoscopic tracheal occlusion in the prenatal management of congenital diaphragmatic hernia.<sup>527</sup> Deployment of an occlusive balloon within the fetal trachea may promote lung growth and improve neonatal outcomes.<sup>528</sup> Left ventricular hypoplasia may be associated with congenital diaphragmatic hernias resulting from ventricular compression or diminished filling secondary to pulmonary hypoplasia and decreased pulmonary venous return.<sup>529</sup> Fetal tracheal occlusion does not negatively affect left ventricular function in these patients; however, the potential of this intervention to improve left ventricular filling and mechanics is unclear.<sup>530</sup>

#### ***Open Fetal Surgery***

Surgical repair of CHD before birth may theoretically offer benefits over postnatal repair in select conditions; however, the optimal techniques have not yet been developed, and the proper candidates have not yet been identified. In animal models, it has been noted that cardiac bypass in the fetus results in significant placental dysfunction, in part related to fetal stress and placental vasoconstriction.<sup>531,532</sup> Open fetal surgery for extracardiac conditions affecting the heart such as resection of pericardial teratoma is possible.<sup>533,534</sup> Innovative open fetal surgical procedures that may be lifesaving

to the fetus or may improve postnatal outcomes may be pursued on an investigational basis, but only once the benefits are carefully weighed against the risks to both fetus and mother.

#### ***Cardiovascular Changes During Fetal Surgery***

In a randomized, clinical trial, open fetal surgery for meningocele repair before 26 weeks of gestation was demonstrated to reduce the need for ventricular shunting procedures and to improve motor outcome at 30 months of age compared with conventional postnatal repair.<sup>535</sup> This multicenter, randomized trial functions as a model for answering important questions concerning the benefits and risks of prenatal intervention for a congenital anomaly. Although the anomaly of meningocele has no physiological impact on the fetal cardiovascular system, serial fetal echocardiographic observation of heart function during open fetal surgery for repair provided insight into the response of the fetal heart to prenatal invasive intervention.<sup>536</sup> Intraoperative changes with a decrease in cardiac output, decrease in ventricular function, and development of AV valve regurgitation were common.<sup>537</sup> Maternal anesthesia, the interplay between maternal-placental-fetal hemodynamics, and the stressors of open fetal surgery all likely played a role but are still not completely understood.<sup>538</sup> These observations provide caution and highlight the importance of careful fetal echocardiographic surveillance during and after any invasive fetal procedure.

#### ***Cardiovascular Impact After Fetal Surgical Intervention***

Invasive fetal intervention for extracardiac anomalies may have negative consequences on the cardiovascular system with an impact that is lesion specific.<sup>537</sup> In congenital cystic adenomatoid malformations, surgical mass resection and acute relief of cardiac tamponade may result in acute mismatch in volume with filling impairment and ventricular dysfunction. In sacrococcygeal teratomas, removal of the tumor leads to an acute reduction in preload and sudden imposition of increased afterload after the elimination of the low-vascular-resistance circuit provided by the mass. The sudden imposition of decreased preload and increased afterload on an already stressed heart may lead to ventricular mass-to-volume mismatch, ventricular dysfunction, and death.<sup>537</sup>

## **Perinatal Management and Outcome of Fetuses With CHD**

The prenatal diagnosis and management of fetal CHD have several potential important benefits. In addition to providing time for extensive prenatal counseling and family support, advancements in fetal imaging technology with analysis of interval fetal studies have enabled better prediction of the clinical course in utero and during the circulatory transition that occurs with delivery. This allows specialized planning of deliveries in select cases with the goal of improved fetal and postnatal outcomes. Fetal medicine specialists are now being asked to consider the fetus as a patient and the transition to postnatal life an important part of individualized care.

### **Benefits of Prenatal Diagnosis and Perinatal Management**

#### ***Impact on Morbidity***

The prenatal diagnosis of critical neonatal CHD has been shown to affect neonatal morbidity and, to a lesser extent,

mortality associated with these defects. Infants diagnosed prenatally with CHD who depend on patency of the ductus arteriosus for systemic or pulmonary blood flow have been shown to be less compromised preoperatively than infants in whom the diagnosis is made after birth, with improved arterial pH, improved oxygenation, less myocardial dysfunction, and less end-organ disease such as necrotizing enterocolitis and renal injury.<sup>176,539–544</sup> In infants diagnosed prenatally with HLHS, timely stabilization and initiation of a prostaglandin infusion have been shown to result in fewer neurological sequelae compared with those infants diagnosed postnatally in whom hemodynamic compromise may have occurred before the diagnosis was made.<sup>545</sup> Therefore, it has been proposed that prenatal diagnosis may contribute to improved long-term neurocognitive function and outcome.<sup>544,545</sup> Prenatal diagnosis may also predict the need for emergent postnatal intervention such as balloon atrial septostomy for d-TGA,<sup>546,547</sup> atrial septoplasty for HLHS,<sup>176,548,549</sup> or pacing in CHB,<sup>550</sup> thus improving outcome by allowing more rapid stabilization of the postnatal circulation. Finally, although hospital length of stay has been unaffected by prenatal diagnosis in some settings,<sup>544,551</sup> others report earlier time to surgical intervention and reduced length of hospital stay in neonates diagnosed in utero with critical heart disease who undergo biventricular repair.<sup>545</sup>

### **Impact on Survival**

Despite studies suggesting a reduction in morbidity associated with prenatal diagnosis, studies documenting improved survival in fetuses with CHD are sparse. Improved preoperative survival among prenatally diagnosed infants with d-TGA has been documented,<sup>546</sup> and improved survival has also been shown in a series of infants with a spectrum of lesions associated with a biventricular circulation.<sup>545</sup> An important limitation of such an assessment is that most published investigations have reported the experience of tertiary centers<sup>176,539–545</sup>; thus, the cohorts studied typically represent only neonates who survived to transport. In addition, most studies do not account for deaths that occur before diagnosis. In studies that include necropsy data, prenatal diagnosis has been shown to improve survival in newborns with coarctation of the aorta<sup>542</sup> or d-TGA,<sup>546,552</sup> and a population cohort of all CHD diagnoses excluding ventricular septal defects.<sup>553</sup>

Postoperative survival in CHD patients may be improved with prenatal diagnosis. Infants with a prenatal diagnosis of d-TGA were shown to have improved survival after an arterial switch operation,<sup>546</sup> and infants with HLHS had improved survival after the second-stage surgical palliation in a small cohort.<sup>539</sup> This has not been a consistent observation; several other studies have failed to demonstrate a survival advantage among infants with a prenatal diagnosis for lesions such as d-TGA, congenitally corrected TGA, PA/IVS, TOF with pulmonary atresia, HLHS, heterotaxy syndrome, or double-inlet left ventricle.<sup>176,539–542,545,554–557</sup>

### **In Utero Management**

Prenatal diagnosis of CHD may improve fetal and perinatal outcome associated with intrauterine heart failure or sudden intrauterine demise by guiding the initiation of intrauterine medical therapy and optimization of perinatal management strategies, including early delivery when necessary. As discussed in the

Fetal Therapy for Cardiovascular Conditions Before Birth section, fetuses with tachyarrhythmias, particularly when incessant, occurring early in pregnancy, or in association with CHD, will benefit from the initiation of transplacental medical therapy.<sup>449,491</sup> Although data are limited, fetal autoimmune-mediated myocardial disease, which is associated with death or need for transplantation in 85% of affected fetuses and infants,<sup>170,440,558</sup> may be successfully ameliorated with maternal corticosteroid and IVIG therapy.<sup>439</sup> Finally, fetal transplacental digoxin may improve signs of heart failure in select cases.<sup>465</sup> The potential impact of prenatal diagnosis and management for other conditions associated with the evolution of fetal heart failure and sudden demise, including Ebstein anomaly, TOF with absent pulmonary valve, and other less common lesions, has not, to date, been fully evaluated. Limited patient numbers at any single institution and significant variability in management algorithms from one institution to another contribute to the challenges of documenting improvements in morbidity and mortality.

## **Delivery Planning**

### **Logistical Considerations**

When fetal CHD is found, intrapartum care should be coordinated between obstetric, neonatal, and cardiology services, with specialty teams, including cardiac intensive care, interventional cardiology, electrophysiology, and cardiac surgery, as appropriate. There is evidence that overall neonatal condition and surgical outcomes are improved by delivery in close proximity to a cardiac center with the resources needed to provide medical and surgical interventions for infants with specific major cardiac defects.<sup>145,539,546,554,559</sup> Appropriate planning of delivery location should therefore be made for patients in whom there is a prenatal diagnosis of CHD at risk for postnatal compromise.

Delay of elective delivery until 39 completed weeks of gestation has been shown to improve neonatal outcomes<sup>560</sup>; however, waiting beyond 42 weeks has been shown to be detrimental.<sup>561–563</sup> Similar results have been reported for neonates with CHD, with improved outcomes for every week of gestation added up to 39 weeks.<sup>564,565</sup> These observations are juxtaposed to concerning data from recent studies that have identified a small but significant negative trend in gestational age at delivery in infants with single-ventricle defects when diagnosed prenatally.<sup>544,551,566</sup> Close communication between obstetric and cardiology services is essential in this setting because elective induction for fetuses with CHD before 39 weeks is not recommended unless there are patient-specific obstetric or logistic issues or fetus-specific concerns about well-being.

No randomized trials have evaluated outcome on the basis of route of delivery for infants with severe CHD. The data that are available do not show any inherent advantage to cesarean section over vaginal birth.<sup>567,568</sup> Fetuses with lesions that have significant risk for fetal demise such as severe Ebstein anomaly or CHB with or without CHD may benefit from interval surveillance, although this has not been critically investigated. Interrogation of the fetus for signs of cardiovascular wellness in addition to testing with the BPP or nonstress testing may aid in difficult decisions about delivery of the preterm fetus with compromised physiology, although this has not been studied systematically in the CHD population.

**Delivery Room and Neonatal Care Planning**

Risk assessment for anticipated compromise in the delivery room or during the first few days of life is based largely on postnatal disease-specific clinical experience. However, for some diagnoses, reports in the literature highlighting specific findings on fetal echocardiogram have facilitated more comprehensive planning to prevent the intrapartum hemodynamic compromise that may occur with specific high-risk CHD. Disease-specific delivery room care recommendations for newborns with CHD have been created for neonatologists and are well accepted in clinical practice.<sup>569,570</sup> For many newborns with CHD, no specialized care is needed in the delivery room, and infants can be discharged from the nursery to be seen for follow-up as outpatients. For all others, delivery care planning must define the specialized treatment and follow-up required, the possible need for transport to a specialized cardiac center, the likelihood of neonatal catheter intervention or surgery, or the need for intervention in the delivery room in the small

subset of patients in whom compromise is likely to occur at the time of circulatory transition with cord clamping.

Specialized care plans can be created for delivery room management that are based on cardiac diagnoses and identifiable features noted during the extended fetal cardiac examination. Models of risk assessment that include stratification of patients and specific postnatal care recommendations have been reported.<sup>571,572</sup> In practice, anticipated postnatal level of care should be assigned by the fetal diagnostic team, with concomitant delivery room and neonatal care recommendations made before delivery. Table 19 summarizes risk-stratified level of care assignment and coordinating action plans based on reported algorithms.

**Disease-Specific Recommendations for Transitional Care**

**Transitional Circulation**

Past studies have shown that the fetal diagnosis of CHD prevents the postnatal hemodynamic instability that occurs during

**Table 19. Level of Care Assignment and Coordinating Action Plan**

LOC	Definition	Example CHD	Delivery Recommendations	DR Recommendations
P	CHD in which palliative care is planned	CHD with severe/fatal chromosome abnormality or multisystem disease	Arrange for family support/palliative care services Normal delivery at local hospital	
1	CHD without predicted risk of hemodynamic instability in the DR or first days of life	VSD, AVSD, mild TOF	Arrange cardiology consultation or outpatient evaluation Normal delivery at local hospital	Routine DR care Neonatal evaluation
2	CHD with minimal risk of hemodynamic instability in DR but requiring postnatal catheterization/surgery	Ductal-dependent lesions, including HLHS, critical coarctation, severe AS, IAA, PA/IVS, severe TOF	Consider planned induction usually near term Delivery at hospital with neonatologist and accessible cardiology consultation	Neonatologist in DR Routine DR care, initiate PGE if indicated Transport for catheterization/surgery
3	CHD with likely hemodynamic instability in DR requiring immediate specialty care for stabilization	d-TGA with concerning atrial septum primum (note: it is reasonable to consider all d-TGA fetuses without an ASD at risk) Uncontrolled arrhythmias CHB with heart failure	Planned induction at 38–39 wk; consider C/S if necessary to coordinate services Delivery at hospital that can execute rapid care, including necessary stabilizing/lifesaving procedures	Neonatologist and cardiac specialist in DR, including all necessary equipment Plan for intervention as indicated by diagnosis Plan for urgent transport if indicated
4	CHD with expected hemodynamic instability with placental separation requiring immediate catheterization/surgery in DR to improve chance of survival	HLHS/severely RFO or IAS d-TGA/severely RFO or IAS and abnormal DA Obstructed TAPVR Ebstein anomaly with hydrops TOF with APV and severe airway obstruction Uncontrolled arrhythmias with hydrops CHB with low ventricular rate, EFE, and/or hydrops	C/S in cardiac facility with necessary specialists in the DR usually at 38–39 wk	Specialized cardiac care team in DR Plan for intervention as indicated by diagnosis; may include catheterization, surgery, or ECMO
5	CHD in which cardiac transplantation is planned	HLHS/IAS, CHD including severe Ebstein anomaly, CHD, or cardiomyopathy with severe ventricular dysfunction	List after 35 wk of gestation C/S when heart is available	Specialized cardiac care team in DR

APV indicates absent pulmonary valve; AS, aortic stenosis; ASD, atrial septal defect; AVSD, atrioventricular septal defect; CHB, complete heart block; CHD, congenital heart disease; C/S, cesarean section; d-TGA, transposition of the great arteries, DA, ductus arteriosus; DR, delivery room; ECMO, extracorporeal membrane oxygenation; EFE, endocardial fibroelastosis; HLHS, hypoplastic left heart syndrome; IAA, interrupted aortic arch; IAS, intact atrial septum; LOC, level of care; PA/IVS, pulmonary atresia/intact ventricular septum; PGE, prostaglandin; RFO, restrictive foramen ovale; TAPVR, total anomalous pulmonary venous return; TOF, tetralogy of Fallot; and VSD, ventricular septal defect.

Modified from the Children’s National Level of Care Protocol, Donofrio et al<sup>572</sup> with permission from Elsevier. Copyright © 2012, Elsevier, Inc.



transition at delivery for a variety of high-risk cardiac anomalies.<sup>539,541,543,546,573–575</sup> In general, 2 major systems play a role in a successful fetal-neonatal transition: the circulatory system and the respiratory system. If it is expected that 1 or both of these systems cannot transition normally, then a specialized plan of care is needed. In-utero, oxygenated blood from the placenta reaches the fetus via the umbilical vein. The open fetal shunt pathways of the ductus venosus and the foramen ovale allow this more highly oxygenated blood to stream to the left side of the heart, and the left ventricle then pumps this blood to the systemic circulation. Venous return is directed mostly to the right ventricle, which pumps the deoxygenated blood across the third fetal shunt pathway, the ductus arteriosus, to return to the placenta via the umbilical artery. In the fetus, the placenta is a low-resistance circuit, and the branch pulmonary arteries are a high-resistance circuit, with only  $\approx 10\%$  to  $20\%$  of the combined cardiac output entering the pulmonary arteries during fetal life.<sup>576</sup> With delivery, 2 events occur. First, the fetus is separated from the low-resistance placental circulation with cord clamping. Second, as spontaneous respiration occurs, the pulmonary vessels dilate in response to oxygen. These events lead to an acute increase in systemic vascular resistance, a decrease in pulmonary vascular resistance, an increase in pulmonary blood flow, closure of the foramen ovale as a result of an abrupt increase in left atrial pressure from pulmonary venous return, closure of the ductus arteriosus (usually over 12–72 hours),<sup>577</sup> and change in the circulation from fetoplacental (combined right and left cardiac output supplying the fetus and the placenta) to a circulation in series (cardiac output going first to the lungs and then to the body).

#### **CHD With Minimal Risk During Transition**

Infants with left-to-right shunt lesions such as ventricular septal defects or AVSDs will be stable until the pulmonary resistance decreases enough to create hemodynamic compromise from a significant left-to-right shunt. This usually takes weeks after delivery to occur.<sup>578</sup> Infants with a mild valve abnormality and normal cardiac function are unlikely to display any symptoms in the neonatal period, although progression of valve dysfunction may occur relatively rapidly.<sup>486,579–582</sup> and close follow-up is prudent. For these minimal-risk newborns, no specialized care is recommended in the delivery room.

#### **Structural CHD Requiring Specialized Management**

The diagnostic challenge for fetal specialists is to determine in which fetuses patency of the fetal shunt pathways will be essential for postnatal stability and to ascertain the in utero predictors that will identify which patients will require additional support or intervention to maintain the circulation postnatally. In addition, identifying fetuses in whom cardiac function is impaired, who will be further challenged by the stress of delivery and the transitional circulation, is equally important. Current recommendations for postnatal management based on fetal echocardiogram predictors, including COR and LOE, are summarized in Table 20.

#### **Ductal-Dependent Lesions**

Fetuses with ductal-dependent pulmonary or systemic blood flow require institution of a prostaglandin infusion soon after birth to prevent ductal closure. Because the ductus arteriosus does not close at delivery, these newborns are not expected

to be compromised in the delivery room<sup>569,570,580</sup> and can be stabilized by neonatologists guided by pediatric cardiology input before transfer for surgical intervention. For fetuses with pulmonary blood flow dependent on the ductus arteriosus such as those with critical pulmonary stenosis or atresia, severe tricuspid valve stenosis or atresia without a ventricular septal defect, or severe TOF, reversed shunting (aorta to pulmonary) in the ductus arteriosus in utero<sup>205</sup> and reversed orientation of the ductus arteriosus defined as an inferior angle of the aortic junction of  $<90^\circ$ <sup>583</sup> have been shown to be predictive of the need to maintain ductal patency. For fetuses with ductal-dependent systemic flow such HLHS, critical AS, or interrupted aortic arch, reversed flow across the foramen ovale (left atrium to right atrium) has been shown to be predictive of the need to maintain ductal patency.<sup>205</sup> For these fetuses, delivery at a center with a neonatologist who has access to pediatric cardiology consultation is recommended.

#### **Foramen Ovale-Dependent Lesions**

Fetuses with critical left heart obstruction such as HLHS are dependent on both foramen ovale and ductus arteriosus patency for delivery of pulmonary venous blood to the systemic circulation. Management of these fetuses, who are at significant risk of compromise with foramen ovale restriction or closure, can benefit from coordination of care in the delivery room.<sup>175,176,481,547,572,584,585,588–594</sup> Fetuses with HLHS identified to have a severely restrictive or intact atrial septum are at increased risk for compromise in the delivery room if fetal pulmonary vein flow shows significant reversed flow suggesting severe left atrial hypertension in the third trimester.<sup>175,176,481,549,572</sup> In 2 studies,<sup>176,481</sup> the ratio of pulmonary vein forward to reversed velocity-time integral was used to determine potential need for intervention. These studies suggest that a ratio  $<3$  is predictive of an increased likelihood of needing emergent opening of the atrial septum by catheterization or surgery and therefore should prompt delivery room management to include immediate access to a cardiac team for the procedure if it is indicated. In addition, the use of a maternal hyperoxia challenge test in the third trimester in which 100% O<sub>2</sub> is delivered via nonrebreather facemask to the expectant mother has been shown to predict fetuses with HLHS at risk for delivery room compromise. Lack of pulmonary vasodilation as measured by the calculated Doppler pulsatility index of the branch pulmonary arteries during the hyperoxia challenge predicted fetuses who needed intervention to open the atrial septum at delivery.<sup>482</sup>

Fetuses with d-TGA are dependent on an open foramen ovale for stability at delivery. Fetal echocardiogram features that predict the risk of postnatal closure of the foramen ovale by assessing the anatomy and flow across both the foramen ovale and ductus arteriosus have been reported.<sup>547,585,588,591,592</sup> The foramen ovale was found to be at risk for closure in 1 study<sup>585</sup> if the angle of septum primum was  $<30^\circ$  to the atrial septum, if there was bowing of the septum primum into the left atrium  $>50\%$ , or if there was a lack of normal swinging motion of the septum primum. In another study,<sup>547</sup> a hypermobile septum primum, especially in the presence of an abnormal ductus arteriosus, was shown to be predictive of compromise. Of note, a recent study of high-risk fetuses with CHD found that using the criteria of a tethered or bowing septum primum in d-TGA fetuses did not



**Table 20. Current Recommendations for Fetal Predictors for Delivery Planning**

	Fetal Echocardiographic Finding	Delivery Recommendation	COR/LOE
Ductal-dependent lesions	Ductal-dependent pulmonary circulation: Aorta to pulmonary flow in the DA <sup>205</sup> Reversed orientation of the DA (inferior angle <90°) <sup>583</sup>	No specialized care in delivery room Initiation of prostaglandin E1	I/B I/B
	Ductal-dependent systemic circulation: Left-to-right atrial flow across the foramen ovale <sup>205</sup>		
HLHS with RFO or IAS	Ratio of pulmonary vein forward to reversed velocity-time integral <3 <sup>176</sup> Maternal hyperoxygenation in third trimester with no change in fetal branch pulmonary artery pulsatility index <sup>584</sup>	Plan for possible urgent intervention to decompress left atrium (catheterization-balloon or stent; surgery)	IIa/B
d-TGA	Reported FO findings predictive of restriction: Angle of septum primum <30° to the atrial septum <sup>585</sup> Bowing of septum primum into the left atrium >50% <sup>585</sup> Lack of normal swinging motion of septum primum <sup>585</sup> Hypermobile septum primum <sup>547</sup> (Note: all fetuses with d-TGA and concerning septum primum should be considered at risk <sup>572</sup> )	Plan for urgent balloon atrial septostomy, on site if possible in the delivery room or ICU Initiation of prostaglandin E1	I/B I/B
	Abnormal DA findings <sup>572,585</sup> : Small (low z score) Accelerated forward, bidirectional or reversed diastolic flow	Consider therapy for pulmonary hypertension with abnormal DA flow	IIb/C
TOF with APV	Lung finding suggestive of lobar emphysema (fluid trapping) on MRI <sup>586</sup>	Specialized ventilation	IIb/C
		Consider ECMO	IIb/C
Ebstein anomaly	Hydrops fetalis Uncontrolled arrhythmia	Consider early delivery with measures to decrease pulmonary resistance, treat arrhythmias, and support cardiac output	IIb/C
TAPVR, obstructed	Decompressing vein below the diaphragm Accelerated flow in decompressing vein	Consider ECMO	IIb/C
Tachyarrhythmias	Rapid heart rate Decreased heart function Pericardial effusion/ hydrops fetalis	Consider early delivery if appropriate gestational age	I/C
		Urgent cardioversion or medical therapy in delivery room if possible	I/C
CHB	Decreasing CVP score (to <7) <sup>587</sup> Very low ventricular rate Decreased heart function/EFE Hydrops fetalis	Consider early delivery	IIa/C
		Consider medical chronotrope or temporary pacing in delivery room if possible	IIa/C

CHB indicates complete heart block; COR, classification of recommendation; CVP, cardiovascular profile; d-TGA, transposition of the great arteries; DA, ductus arteriosus; ECMO, extracorporeal membrane oxygenation; EFE, endocardial fibroelastosis; FO, foramen ovale; HLHS, hypoplastic left heart syndrome; IAS, intact atrial septum; ICU, intensive care unit; LOE, level of evidence; MRI, magnetic resonance imaging; RFO, restrictive foramen ovale; TAPVR, total anomalous pulmonary venous return; and TOF with APV, tetralogy of Fallot with absent pulmonary valve.

predict postnatal compromise and need for emergent intervention with an acceptable sensitivity or specificity.<sup>572</sup> In this study, if there were any concerning foramen ovale findings with a ductus arteriosus that was small or had abnormal flow, risk of postnatal compromise and need for urgent balloon atrial septostomy and possible treatment of pulmonary hypertension were high. Given the difficulty in predicting which fetuses with d-TGA will develop foramen ovale restriction and compromise at birth, all fetuses with d-TGA with a concerning septum primum should be delivered in a hospital that can manage the hypoxia and hemodynamic compromise that occur with foramen ovale closure and possible associated pulmonary hypertension. Care should be coordinated so that immediate transfer to a center that can perform a balloon atrial septostomy is possible or, preferably, delivery can occur at a site where the physiological circulatory transition and the catheterization procedure can be managed in either the delivery room or the intensive care unit. In addition,

it is reasonable to recommend that the delivery of all fetuses with d-TGA and no associated atrial septal defects be coordinated at a hospital that can efficiently execute the management of these potentially critically ill newborns, including either planning for the possibility of urgent balloon atrial septostomy or coordinating rapid transport to facilitate urgent intervention

Fetuses with severe right heart obstruction also are dependent on the foramen ovale and ductal patency; however, given the elevation of right atrial pressure in these patients, foramen ovale restriction is rarely observed. Late development of hydrops in the third trimester with foramen ovale restriction has been reported in a small series of patients.<sup>590</sup>

**Fetal Arrhythmias**

Fetuses with tachyarrhythmias or bradyarrhythmias may require intervention in the delivery room, particularly if the delivery is occurring because of impending heart failure, hydrops, or fetal

distress.<sup>440,550,592</sup> Delivery planning that includes medical or electric conversion to sinus rhythm or the initiation of medications for rhythm control in the delivery room is indicated for fetuses with uncontrolled tachycardias. For fetuses with CHB, planned intervention with chronotrope infusion or pacing in the immediate neonatal period has been shown to contribute to survival of affected neonates<sup>440,550</sup> and therefore is reasonable. Deterioration of cardiac function by CVP score, prompting the decision for early delivery and pacing in the delivery room, has been reported but only in a limited number of cases.<sup>587</sup>

### Complex CHD With Heart Failure

Minimal data are available for delivery planning in diseases such as TOF with absent pulmonary valve or severe Ebstein anomaly in which there is heart failure and, in some cases, significant pulmonary comorbidities from bronchial or lung compression or lung hypoplasia. Additional imaging of the airways and lungs with fetal MRI may be considered to assist in risk stratification of fetuses who will have severe airway obstruction or lung disease, including lobar emphysema, that prevents adequate ventilation and oxygenation at birth.<sup>586</sup> Fetal monitoring with BPP or nonstress testing in select high-risk patients may be indicated and play a role in determining the timing of delivery in those with defects at risk for fetal demise as a result of compromised cardiac output such as Ebstein anomaly or CHB with low ventricular rate, endocardial fibroelastosis, or hydrops. The presence of hydrops is an ominous sign. If determined to be caused by heart failure, delivery may be considered if the gestational age is appropriate and the primary pathology is treatable or reversible, with preparations made for the immediate treatment of potential hemodynamic collapse at delivery and for the availability of mechanical cardiac or cardiopulmonary support.

## Recommendations

### Fetal Cardiac Evaluation

1. Referral for fetal cardiac evaluation is indicated for maternal conditions including pregestational DM or DM diagnosed in the first trimester (*Class I; Level of Evidence A*), uncontrolled phenylketonuria (*Class I; Level of Evidence A*), SSA/SSB<sup>+</sup> autoantibodies with a previously affected child (*Class I; Level of Evidence B*), medications including retinoic acid (*Class I; Level of Evidence B*) or NSAIDs used in the third trimester (*Class I; Level of Evidence A*), first-trimester rubella (*Class I; Level of Evidence C*), or an infection with suspicion of fetal myocarditis (*Class I; Level of Evidence C*).
2. Referral for fetal cardiac evaluation is indicated if there is CHD in a first-degree relative of the fetus (maternal, paternal, or sibling) with CHD (*Class I; Level of Evidence B*) or a relative with a disorder with mendelian inheritance that has a CHD association (*Class I; Level of Evidence C*) or if there is a suspected fetal cardiac abnormality identified by obstetric ultrasound (*Class I; Level of Evidence B*), an extracardiac abnormality identified by obstetric ultrasound (*Class I; Level of Evidence B*), a suspected or confirmed chromosome abnormality (*Class I; Level of Evidence C*), fetal tachycardia or bradycardia or frequent or persistent irregular heart rhythm (*Class I; Level of Evidence C*), an increased NT >99% ( $\geq 3.5$  mm) or an increased NT >95% ( $\geq 3$  mm) with abnormal ductus venosus flow (*Class I; Level of Evidence A*), mono-chorionic twinning (*Class I; Level of Evidence A*), or evidence of fetal hydrops or effusions (*Class I; Level of Evidence B*).
3. Referral for fetal cardiac evaluation is reasonable for maternal conditions including SSA/SSB<sup>+</sup> autoantibodies without a previously affected child (*Class IIa; Level of Evidence B*) or medications including angiotensin-converting enzyme inhibitors (*Class IIa; Level of Evidence B*), if the pregnancy is a result of assisted reproduction technology (*Class IIa; Level of Evidence A*), or if there is an increased NT >95% ( $\geq 3.0$  mm) (*Class IIa; Level of Evidence A*).
4. Referral for fetal cardiac evaluation may be considered for maternal medication use including anticonvulsants (*Class IIb; Level of Evidence A*), lithium (*Class IIb; Level of Evidence B*), vitamin A (*Class IIb; Level of Evidence B*), SSRIs (paroxetine only) (*Class IIb; Level of Evidence A*), or NSAIDs used in the first or second trimester (*Class IIb; Level of Evidence B*); if there is CHD in a second-degree relative of the fetus (*Class IIb; Level of Evidence B*); or if there is an abnormality of the umbilical cord, placenta, or intra-abdominal venous anatomy (*Class IIb; Level of Evidence C*).
5. Referral for fetal cardiac evaluation is not indicated for maternal gestational DM with HbA<sub>1c</sub> <6% (*Class III; Level of Evidence B*), maternal medications including SSRIs (other than paroxetine) (*Class III; Level of Evidence A*), vitamin K agonists (although fetal survey is recommended) (*Class III; Level of Evidence B*), maternal infection other than rubella with seroconversion only (*Class III; Level of Evidence C*), or isolated CHD in a relative other than first or second degree (*Class III; Level of Evidence B*).

### Fetal Echocardiogram

6. A fetal echocardiogram should include standard views using both still frame and moving cine clip acquisition of the 4-chamber view sweeping posterior to anterior, left and right ventricular outflow tracts, 3 vessels and trachea view, aortic and ductal arch view, superior and inferior vena cava view (*Class I; Level of Evidence A*), and short-axis and long-axis views (*Class I; Level of Evidence B*).
7. A fetal echocardiogram should include 2D still and cine clips of the atria (including size and anatomy of septum), ventricles (including size with right to left comparison, function, and anatomy of septum), AV valves (comparing size of right to left), semilunar valves (comparing size of right to left), great arteries (including size and position to each other and the trachea), ductal and aortic arches, systemic veins, and pulmonary veins (*Class I; Level of Evidence A*).
8. A fetal echocardiogram should include color Doppler to evaluate the systemic veins (including the superior and inferior vena cava), pulmonary veins, AV valves, atrial and ventricular septae, semilunar valves, ductus arteriosus, aortic arch, and ductus venosus (*Class I; Level of Evidence B*), and pulsed Doppler to evaluate the AV and semilunar valves and the ductus venosus (*Class I; Level of Evidence B/C*).
9. A fetal echocardiogram should include an assessment of heart rate and rhythm with pulsed Doppler, M-mode, or tissue Doppler and a qualitative assessment of cardiac function with the exclusion of cardiomegaly or hydrops fetalis (*Class I; Level of Evidence B*).
10. A fetal echocardiogram should include in specific clinical situations measure of valves using gestational age z scores, measure of the cardiothoracic ratio, detailed rhythm assessment, advanced cardiac function assessment including left and right cardiac output, AV valve inflow for diastolic function, systemic vein Doppler, pulmonary vein Doppler, MPI, isovolumic relaxation and contraction times, shortening fraction, and CVP score (*Class I; Level of Evidence B/C*).
11. It is reasonable to include in a fetal echocardiogram measures of the valves (with comparison of right to left valves) and ventricular length (with comparison of right to left ventricle) and pulsed Doppler of the systemic and pulmonary veins, aortic and ductal arches, and umbilical artery and vein (*Class IIa; Level of Evidence B*).

12. A fetal echocardiogram using pulsed Doppler of the middle cerebral artery or branch pulmonary arteries may be useful in specific clinical situations (*Class IIb; Level of Evidence B/C*).

### Advanced Techniques

13. Advanced techniques that currently are research tools but are reasonable to use in clinical practice for specific indications include cardiac MRI (for assessment of heterotaxy, venous anatomy, and extracardiac anomalies), tissue Doppler (for time interval and rhythm assessment), fetal electrocardiography (for fetal monitoring after rupture of membranes), and fMCG (for assessment of cardiac conduction and rhythm in fetuses with known or suspected conduction system abnormalities) (*Class IIa; Level of Evidence B/C*).

### Extracardiac Assessment

14. Extracardiac assessment in fetuses with known CHD should include genetic counseling with an offer of testing for aneuploidy and a detailed fetal ultrasound anatomy survey (*Class I; Level of Evidence A*).
15. It is reasonable to include extracardiac assessment using fetal brain MRI if a brain abnormality is suspected in fetuses with known CHD or fetal chest/lung MRI to assess lung volume in fetuses with a congenital diaphragmatic hernia (*Class IIa; Level of Evidence B*).
16. It may be reasonable to include extracardiac assessment using fetal brain MRI for cerebral anomaly screening in fetuses with known CHD or fetal chest/lung MRI to assess lung volumes in fetuses with diagnoses in whom there is a suspicion for pulmonary hypoplasia (*Class IIb; Level of Evidence B*).

### Fetal Wellness Assessment

17. Fetal wellness assessment in fetuses with known CHD may be reasonable and can include fetal movement assessment by mother ("kick counts"), nonstress testing beginning in the third trimester for fetuses at risk for hypoxemia or acidosis, and BPP beginning in the third trimester for fetuses at risk for hypoxemia or acidosis (*Class IIb; Level of Evidence C*).

### Fetal Medical Therapy

18. Fetal medical therapy should be offered for fetuses with sustained SVT or VT or sustained tachycardias including multifocal atrial tachycardia, atrial ectopic tachycardia, persistent junctional reciprocating tachycardia, or junctional ectopic tachycardia with average heart rates >200 bpm if the fetus is not near term, and hydropic fetuses with an arrhythmia believed to be the cause of the fetal compromise (*Class I; Level of Evidence A*).
19. Fetal medical therapy with sympathomimetics is reasonable to consider for fetuses with AV block with ventricular rates <55 bpm or AV block at a higher ventricular rate with associated severe CHD or signs of fetal heart failure or hydrops fetalis (*Class IIa; Level of Evidence B*).
20. Fetal medical therapy is reasonable to consider for fetuses with intermittent VT at rates >200 bpm (*Class IIa; Level of Evidence B*).
21. Fetal medical therapy with dexamethasone may be considered for fetuses with immune-mediated second-degree AV block or first-degree AV block with signs of cardiac inflammation (*Class IIb; Level of Evidence B*). Fetal medical therapy with digoxin may be considered for fetuses with signs of heart failure (*Class IIb; Level of Evidence A*).
22. Fetal medical therapy is of no benefit for fetuses with sinus bradycardia, irregular rhythms caused by extrasystolic beats (*Class III; Level of Evidence A*), intermittent SVT without fetal compromise or hydrops, or intermittent VT < 200 bpm (accelerated ventricular rhythm) without

fetal compromise or hydrops fetalis (*Class III; Level of Evidence B/C*).

### Fetal Intervention

23. Fetal catheter intervention may be considered for fetuses with AS with antegrade flow and evolving HLHS; fetuses with AS, severe mitral regurgitation, and restrictive atrial septum; fetuses with HLHS with a severely restrictive or intact atrial septum; or fetuses with PA/IVS (*Class IIb; Level of Evidence B/C*).

### Specialized Delivery Room Care

24. Specialized delivery room care should be planned for fetuses with d-TGA or fetuses with sustained or uncontrolled tachyarrhythmias with heart failure or hydrops fetalis (*Class I; Level of Evidence B/C*).
25. Specialized delivery room care planning is reasonable for fetuses with HLHS with restrictive or intact atrial septum and abnormal pulmonary vein flow (pulmonary vein forward/reversed flow ratio <3) or abnormal hyperoxia test in the third trimester or in fetuses with CHB and low ventricular rate, cardiac dysfunction, or hydrops fetalis (*Class IIa; Level of Evidence B/C*).
26. Specialized delivery room care planning may be considered for fetuses with TOF with absent pulmonary valve or Ebstein anomaly with hydrops fetalis (*Class IIb; Level of Evidence C*).
27. Specialized delivery room care is not needed for fetuses with shunt lesions, most ductal-dependent lesions, or controlled arrhythmias (*Class III; Level of Evidence B/C*).

### Conclusions

In the modern era, it is expected that structural heart disease and arrhythmias will be diagnosed with precise detail in utero. The goal of the fetal cardiologist has now become to understand the fetus as a patient, knowing that the fetal circulation is different from the postnatal circulation, that CHD may progress in utero, and that cardiac function and stability of the cardiovascular system play important roles in fetal wellness. In fetuses at risk for cardiovascular disease, collaboration among all caregivers is essential. This document has been created using what is currently known and practiced in the rapidly advancing and highly specialized field of fetal cardiac care. Further study is needed to determine more precise indications for referral, better diagnostic protocols for the detection of CHD, and standardized treatment strategies to prevent cardiovascular compromise and disease progression. Given the rarity of many conditions, national and international multidisciplinary collaboration is essential as we embrace our role as specialized caregivers for fetuses with cardiovascular disease.

### Acknowledgment

This article is dedicated to the memory of Dr Charles S. Kleinman. Dr Kleinman was slated to be the senior author of this work but died before he could bring the project to fruition. He was a mentor, friend, and colleague of many of the document's authors. In many ways, this document reflects his ideal that, for a fetal cardiologist, the primary issue of importance is the well-being of the patients, both mother and fetus, and he spent his career collaborating with other disciplines to achieve that aim. This document that he envisioned is an attempt to embrace the many disciplines and to provide common standards of practice and treatment to those treating fetuses with cardiovascular disease.

## Disclosures

## Writing Group Disclosures

Writing Group Member	Employment	Research Grant	Other Research Support	Speakers' Bureau/Honoraria	Expert Witness	Ownership Interest	Consultant/Advisory Board	Other
Mary T. Donofrio	Children's National Medical Center	None	None	None	None	None	None	None
Alfred Abuhamad	Eastern Virginia Medical School	None	None	None	None	None	None	None
Joshua A. Copel	Yale University School of Medicine	None	None	None	None	None	None	American Institute of Ultrasound in Medicine*; International Society for Ultrasound in Obstetrics & Gynecology*; Society for Maternal-Fetal Medicine*
Bettina F. Cuneo	Children's Hospital of Colorado	None	None	Philips Medical†	None	None	None	None
Lisa K. Hornberger	University of Alberta	None	None	None	None	None	None	None
James C. Huhta	Pediatrics	None	None	None	None	None	None	None
Richard A. Jonas	Children's National Medical Center	None	None	None	None	None	None	None
Anita Krishnan	Children's National Medical Center	None	None	None	None	None	None	None
Stephanie Lacey	University of Florida	None	None	None	None	None	None	None
Wesley Lee	Baylor College of Medicine/Texas Children's Hospital	GE Healthcare*; Philips Medical*; Siemens Medical*	None	GE Healthcare*	None	None	GE Healthcare*; Philips Medical*; Siemens Medical*	None
Erik C. Michelfelder, Sr	Cincinnati Children's Hospital Medical Center	None	None	None	None	None	None	None
Anita J. Moon-Grady	University of California, San Francisco	None	None	None	None	None	None	None
Gwen R. Rempel	University of Alberta	None	None	None	None	None	None	None
Jack Rychik	University of Pennsylvania/Children's Hospital of Philadelphia	None	None	None	None	None	None	None
Norman H. Silverman	Stanford University	None	None	None	Testified for plaintiff in 2 cases in 2010†	None	AGA Medical†	None
Mark S. Sklansky	University of California	None	None	None	None	None	None	None
Thomas L. Spray	Children's Hospital of Philadelphia	None	None	None	None	None	None	None
Janette F. Strasburger	Medical College of Wisconsin	NIH*	None	None	None	None	None	None
Wayne Tworetzky	Children's Hospital, Boston	None	None	None	None	None	None	None

This table represents the relationships of writing group members that may be perceived as actual or reasonably perceived conflicts of interest as reported on the Disclosure Questionnaire, which all members of the writing group are required to complete and submit. A relationship is considered to be "significant" if (a) the person receives \$10 000 or more during any 12-month period, or 5% or more of the person's gross income; or (b) the person owns 5% or more of the voting stock or share of the entity, or owns \$10 000 or more of the fair market value of the entity. A relationship is considered to be "modest" if it is less than "significant" under the preceding definition.

\*Modest.

†Significant.



## Reviewer Disclosures

Reviewer	Employment	Research Grant	Other Research Support	Speakers' Bureau/Honoraria	Expert Witness	Ownership Interest	Consultant/Advisory Board	Other
Piروز Eghtesady	Washington University	None	None	None	None	None	None	None
Carlen Fifer	University of Michigan	None	None	None	None	None	None	None
Mark Lewin	Children's Hospital and Regional Medical Center	None	None	None	None	None	None	None
Theresa Tacy	Lucile Packard Children's Hospital, Stanford Medical Center	None	None	None	None	None	None	None

This table represents the relationships of reviewers that may be perceived as actual or reasonably perceived conflicts of interest as reported on the Disclosure Questionnaire, which all reviewers are required to complete and submit. A relationship is considered to be "significant" if (a) the person receives \$10 000 or more during any 12-month period, or 5% or more of the person's gross income; or (b) the person owns 5% or more of the voting stock or share of the entity, or owns \$10 000 or more of the fair market value of the entity. A relationship is considered to be "modest" if it is less than "significant" under the preceding definition.

## References

- Ferencz C, Rubin JD, McCarter RJ, Brenner JI, Neill CA, Perry LW, Hepner SI, Downing JW. Congenital heart disease: prevalence at livebirth: the Baltimore-Washington Infant Study. *Am J Epidemiol.* 1985;121:31-36.
- Hoffman JI. Congenital heart disease: incidence and inheritance. *Pediatr Clin North Am.* 1990;37:25-43.
- Tegnander E, Williams W, Johansen OJ, Blaas HG, Eik-Nes SH. Prenatal detection of heart defects in a non-selected population of 30,149 fetuses: detection rates and outcome. *Ultrasound Obstet Gynecol.* 2006;27:252-265.
- Wren C, Richmond S, Donaldson L. Temporal variability in birth prevalence of cardiovascular malformations. *Heart.* 2000;83:414-419.
- Moons P, Sluysmans T, De Wolf D, Massin M, Suys B, Benatar A, Gewillig M. Congenital heart disease in 111 225 births in Belgium: birth prevalence, treatment and survival in the 21st century. *Acta Paediatr.* 2009;98:472-477.
- Rowland TW, Hubbell JP Jr, Nadas AS. Congenital heart disease in infants of diabetic mothers. *J Pediatr.* 1973;83:815-820.
- Lisowski LA, Verheijen PM, Copel JA, Kleinman CS, Wassink S, Visser GH, Meijboom EJ. Congenital heart disease in pregnancies complicated by maternal diabetes mellitus: an international clinical collaboration, literature review, and meta-analysis. *Herz.* 2010;35:19-26.
- Miller E, Hare JW, Cloherty JP, Dunn PJ, Gleason RE, Soeldner JS, Kitzmiller JL. Elevated maternal hemoglobin A1c in early pregnancy and major congenital anomalies in infants of diabetic mothers. *N Engl J Med.* 1981;304:1331-1334.
- Ray JG, O'Brien TE, Chan WS. Preconception care and the risk of congenital anomalies in the offspring of women with diabetes mellitus: a meta-analysis. *QJM.* 2001;94:435-444.
- Lenke RR, Levy HL. Maternal phenylketonuria and hyperphenylalaninemia: an international survey of the outcome of untreated and treated pregnancies. *N Engl J Med.* 1980;303:1202-1208.
- Platt LD, Koch R, Hanley WB, Levy HL, Matalon R, Rouse B, Trefz F, de la Cruz F, Guttler F, Azen C, Friedman EG. The international study of pregnancy outcome in women with maternal phenylketonuria: report of a 12-year study. *Am J Obstet Gynecol.* 2000;182:326-333.
- Koch R, Friedman E, Azen C, Hanley W, Levy H, Matalon R, Rouse B, Trefz F, Waisbren S, Michals-Matalon K, Acosta P, Guttler F, Ullrich K, Platt L, de la Cruz F. The International Collaborative Study of Maternal Phenylketonuria: status report 1998. *Eur J Pediatr.* 2000;159(suppl 2):S156-S160.
- Bruccato A, Frassi M, Franceschini F, Cimaz R, Faden D, Pisoni MP, Muscara M, Vignati G, Stramba-Badiale M, Catelli L, Lojaco A, Cavazzana I, Ghirardello A, Vescovi F, Gambari PF, Doria A, Meroni PL, Tincani A. Risk of congenital complete heart block in newborns of mothers with anti-Ro/SSA antibodies detected by counterimmunoelectrophoresis: a prospective study of 100 women. *Arthritis Rheum.* 2001;44:1832-1835.
- Buyon JP, Hiebert R, Copel J, Craft J, Friedman D, Katholi M, Lee LA, Provost TT, Reichlin M, Rider L, Rupel A, Saleeb S, Weston WL, Skovron ML. Autoimmune-associated congenital heart block: demographics, mortality, morbidity and recurrence rates obtained from a national neonatal lupus registry. *J Am Coll Cardiol.* 1998;31:1658-1666.
- Costedoat-Chalumeau N, Amoura Z, Lupoglazoff JM, Huong DL, Denjoy I, Vauthier D, Sebbouh D, Fain O, Georgin-Lavialle S, Ghillani P, Musset L, Wechsler B, Duhaut P, Piette JC. Outcome of pregnancies in patients with anti-SSA/Ro antibodies: a study of 165 pregnancies, with special focus on electrocardiographic variations in the children and comparison with a control group. *Arthritis Rheum.* 2004;50:3187-3194.
- Friedman DM, Kim MY, Copel JA, Davis C, Phoon CK, Glickstein JS, Buyon JP; PRIDE Investigators. Utility of cardiac monitoring in fetuses at risk for congenital heart block: the PR Interval and Dexamethasone Evaluation (PRIDE) prospective study. *Circulation.* 2008;117:485-493.
- Jaeggi E, Laskin C, Hamilton R, Kingdom J, Silverman E. The importance of the level of maternal anti-Ro/SSA antibodies as a prognostic marker of the development of cardiac neonatal lupus erythematosus: a prospective study of 186 antibody-exposed fetuses and infants. *J Am Coll Cardiol.* 2010;55:2778-2784.
- Spence D, Hornberger L, Hamilton R, Silverman ED. Increased risk of complete congenital heart block in infants born to women with hypothyroidism and anti-Ro and/or anti-La antibodies. *J Rheumatol.* 2006;33:167-170.
- Ambrosi A, Salomonsson S, Eliasson H, Zeffer E, Skog A, Dzikaite V, Bergman G, Fernlund E, Tingstrom J, Theander E, Rydberg A, Skogh T, Ohman A, Lundstrom U, Mellander M, Winqvist O, Foreb M, Ekblom A, Alfredsson L, Kallberg H, Olsson T, Gadler F, Jonzon A, Kockum I, Sonesson SE, Wahren-Herlenius M. Development of heart block in children of SSA/SSB-autoantibody-positive women is associated with maternal age and displays a season-of-birth pattern. *Ann Rheum Dis.* 2012;71:334-340.
- Saleeb S, Copel J, Friedman D, Buyon JP. Comparison of treatment with fluorinated glucocorticoids to the natural history of autoantibody-associated congenital heart block: retrospective review of the research registry for neonatal lupus. *Arthritis Rheum.* 1999;42:2335-2345.
- Matalon S, Schechtman S, Goldzweig G, Ornoy A. The teratogenic effect of carbamazepine: a meta-analysis of 1255 exposures. *Reprod Toxicol.* 2002;16:9-17.
- Jacobson SJ, Ceolin L, Kaur P, Pastuszak A, Einarson T, Koren G, Jones K, Johnson K, Sahn D, Donnenfeld AE, Rieder M, Santelli R. Prospective multicentre study of pregnancy outcome after lithium exposure during first trimester. *Lancet.* 1992;339:530-533.
- Cooper WO, Hernandez-Diaz S, Arbogast PG, Dudley JA, Dyer S, Gideon PS, Hall K, Ray WA. Major congenital malformations after first-trimester exposure to ACE inhibitors. *N Engl J Med.* 2006;354:2443-2451.
- Lammer EJ, Chen DT, Hoar RM, Agnish ND, Benke PJ, Braun JT, Curry CJ, Fernhoff PM, Grix AW Jr, Lott IT, Richard JM, Sun SC. Retinoic acid embryopathy. *N Engl J Med.* 1985;313:837-841.
- Jenkins KJ, Correa A, Feinstein JA, Botto L, Britt AE, Daniels SR, Elixson M, Warnes CA, Webb CL. Noninherited risk factors and congenital cardiovascular defects: current knowledge: a scientific statement from the American Heart Association Council on Cardiovascular Disease in the Young. *Circulation.* 2007;115:2995-3014.
- Bar-Oz B, Einarson T, Einarson A, Boskovic R, O'Brien L, Malm H, Berard A, Koren G. Paroxetine and congenital malformations: meta-analysis and consideration of potential confounding factors. *Clin Ther.* 2007;29:918-926.
- Rothman KJ, Moore LL, Singer MR, Nguyen US, Mannino S, Milunsky A. Teratogenicity of high vitamin A intake. *N Engl J Med.* 1995;333:1369-1373.
- Alwan S, Reefhuis J, Rasmussen SA, Olney RS, Friedman JM; National Birth Defects Prevention Study. Use of selective serotonin-reuptake inhibitors in pregnancy and the risk of birth defects. *N Engl J Med.* 2007;356:2684-2692.

29. Louik C, Lin AE, Werler MM, Hernandez-Diaz S, Mitchell AA. First-trimester use of selective serotonin-reuptake inhibitors and the risk of birth defects. *N Engl J Med*. 2007;356:2675–2683.
30. Lattimore KA, Donn SM, Kaciroti N, Kemper AR, Neal CR Jr, Vazquez DM. Selective serotonin reuptake inhibitor (SSRI) use during pregnancy and effects on the fetus and newborn: a meta-analysis. *J Perinatol*. 2005;25:595–604.
31. Schaefer C, Hannemann D, Meister R, Elefant E, Paulus W, Vial T, Reuvers M, Robert-Gnansia E, Arnon J, De Santis M, Clementi M, Rodriguez-Pinilla E, Dolivo A, Merlob P. Vitamin K antagonists and pregnancy outcome: a multi-centre prospective study. *Thromb Haemost*. 2006;95:949–957.
32. Ericson A, Kallen BA. Nonsteroidal anti-inflammatory drugs in early pregnancy. *Reprod Toxicol*. 2001;15:371–375.
33. Huhta JC, Moise KJ, Fisher DJ, Sharif DS, Wasserstrum N, Martin C. Detection and quantitation of constriction of the fetal ductus arteriosus by Doppler echocardiography. *Circulation*. 1987;75:406–412.
34. Koren G, Florescu A, Costei AM, Boskovic R, Moretti ME. Nonsteroidal antiinflammatory drugs during third trimester and the risk of premature closure of the ductus arteriosus: a meta-analysis. *Ann Pharmacother*. 2006;40:824–829.
35. Botto LD, Lynberg MC, Erickson JD. Congenital heart defects, maternal febrile illness, and multivitamin use: a population-based study. *Epidemiology*. 2001;12:485–490.
36. Stuckey D. Congenital heart defects following maternal rubella during pregnancy. *Br Heart J*. 1956;18:519–522.
37. Bahtiyar MO, Campbell K, Dulay AT, Kontic-Vucinic O, Weeks BP, Friedman AH, Copel JA. Is the rate of congenital heart defects detected by fetal echocardiography among pregnancies conceived by in vitro fertilization really increased? A case-historical control study. *J Ultrasound Med*. 2010;29:917–922.
38. Katalinic A, Rosch C, Ludwig M; German ICSI Follow-Up Study Group. Pregnancy course and outcome after intracytoplasmic sperm injection: a controlled, prospective cohort study. *Fertil Steril*. 2004;81:1604–1616.
39. Rimm AA, Katayama AC, Diaz M, Katayama KP. A meta-analysis of controlled studies comparing major malformation rates in IVF and ICSI infants with naturally conceived children. *J Assist Reprod Genet*. 2004;21:437–443.
40. Rimm AA, Katayama AC, Katayama KP. A meta-analysis of the impact of IVF and ICSI on major malformations after adjusting for the effect of subfertility. *J Assist Reprod Genet*. 2011;28:699–705.
41. Lie RT, Lyngstadaas A, Orstavik KH, Bakketeg LS, Jacobsen G, Tanbo T. Birth defects in children conceived by ICSI compared with children conceived by other IVF-methods: a meta-analysis. *Int J Epidemiol*. 2005;34:696–701.
42. Reefhuis J, Honein MA, Schieve LA, Correa A, Hobbs CA, Rasmussen SA; National Birth Defects Prevention Study. Assisted reproductive technology and major structural birth defects in the United States. *Hum Reprod*. 2009;24:360–366.
43. Hansen M, Kurinczuk JJ, Bower C, Webb S. The risk of major birth defects after intracytoplasmic sperm injection and in vitro fertilization. *N Engl J Med*. 2002;346:725–730.
44. Davies MJ, Moore VM, Willson KJ, Van Essen P, Priest K, Scott H, Haan EA, Chan A. Reproductive technologies and the risk of birth defects. *N Engl J Med*. 2012;366:1803–1813.
45. Burn J, Brennan P, Little J, Holloway S, Coffey R, Somerville J, Dennis NR, Allan L, Arnold R, Deanfield JE, Godman M, Houston A, Keeton B, Oakley C, Scott O, Silove E, Wilkinson J, Pembrey M, Hunter AS. Recurrence risks in offspring of adults with major heart defects: results from first cohort of British collaborative study. *Lancet*. 1998;351:311–316.
46. Oyen N, Poulsen G, Boyd HA, Wohlfahrt J, Jensen PK, Melbye M. Recurrence of congenital heart defects in families. *Circulation*. 2009;120:295–301.
47. Emanuel R, Somerville J, Inns A, Withers R. Evidence of congenital heart disease in the offspring of parents with atrioventricular defects. *Br Heart J*. 1983;49:144–147.
48. Nora JJ, Nora AH. Maternal transmission of congenital heart diseases: new recurrence risk figures and the questions of cytoplasmic inheritance and vulnerability to teratogens. *Am J Cardiol*. 1987;59:459–463.
49. Rose V, Gold RJ, Lindsay G, Allen M. A possible increase in the incidence of congenital heart defects among the offspring of affected parents. *J Am Coll Cardiol*. 1985;6:376–382.
50. Gill HK, Splitt M, Sharland GK, Simpson JM. Patterns of recurrence of congenital heart disease: an analysis of 6,640 consecutive pregnancies evaluated by detailed fetal echocardiography. *J Am Coll Cardiol*. 2003;42:923–929.
51. Fesslova V, Brankovic J, Lalatta F, Villa L, Meli V, Piazza L, Ricci C. Recurrence of congenital heart disease in cases with familial risk screened prenatally by echocardiography. *J Pregnancy*. 2011;2011:368067.
52. Nora JJ, Nora AH. Genetic epidemiology of congenital heart diseases. *Prog Med Genet*. 1983;5:91–137.
53. Hinton RB Jr, Martin LJ, Tabangin ME, Mazwi ML, Cripe LH, Benson DW. Hypoplastic left heart syndrome is heritable. *J Am Coll Cardiol*. 2007;50:1590–1595.
54. Pradat P. Recurrence risk for major congenital heart defects in Sweden: a registry study. *Genet Epidemiol*. 1994;11:131–140.
55. Pierpont ME, Basson CT, Benson DW Jr, Gelb BD, Giglia TM, Goldmuntz E, McGee G, Sable CA, Srivastava D, Webb CL. Genetic basis for congenital heart defects: current knowledge: a scientific statement from the American Heart Association Congenital Cardiac Defects Committee, Council on Cardiovascular Disease in the Young. *Circulation*. 2007;115:3015–3038.
56. McBride KL, Pignatelli R, Lewin M, Ho T, Fernbach S, Menesses A, Lam W, Leal SM, Kaplan N, Schliekelman P, Towbin JA, Belmont JW. Inheritance analysis of congenital left ventricular outflow tract obstruction malformations: segregation, multiplex relative risk, and heritability. *Am J Med Genet A*. 2005;134A:180–186.
57. Copel JA, Kleinman CS. The impact of fetal echocardiography on perinatal outcome. *Ultrasound Med Biol*. 1986;12:327–335.
58. Carvalho JS, Mavrides E, Shinebourne EA, Campbell S, Thilaganathan B. Improving the effectiveness of routine prenatal screening for major congenital heart defects. *Heart*. 2002;88:387–391.
59. Simpson LL. Indications for fetal echocardiography from a tertiary-care obstetric sonography practice. *J Clin Ultrasound*. 2004;32:123–128.
60. Kleinman CS, Donnerstein RL, Jaffe CC, DeVore GR, Weinstein EM, Lynch DC, Talner NS, Berkowitz RL, Hobbins JC. Fetal echocardiography: a tool for evaluation of in utero cardiac arrhythmias and monitoring of in utero therapy: analysis of 71 patients. *Am J Cardiol*. 1983;51:237–243.
61. Allan LD, Anderson RH, Sullivan ID, Campbell S, Holt DW, Tynan M. Evaluation of fetal arrhythmias by echocardiography. *Br Heart J*. 1983;50:240–245.
62. Fouron JC, Fournier A, Proulx F, Lamarche J, Bigras JL, Boutin C, Brassard M, Gamache S. Management of fetal tachyarrhythmia based on superior vena cava/aorta Doppler flow recordings. *Heart*. 2003;89:1211–1216.
63. Carvalho JS, Prefumo F, Ciardelli V, Sairam S, Bhide A, Shinebourne EA. Evaluation of fetal arrhythmias from simultaneous pulsed wave Doppler in pulmonary artery and vein. *Heart*. 2007;93:1448–1453.
64. Jaeggi E, Fouron JC, Fournier A, van Doesburg N, Drblik SP, Proulx F. Ventricular-atrial time interval measured on M mode echocardiography: a determining element in diagnosis, treatment, and prognosis of fetal supra-ventricular tachycardia. *Heart*. 1998;79:582–587.
65. Schmidt KG, Ulmer HE, Silverman NH, Kleinman CS, Copel JA. Perinatal outcome of fetal complete atrioventricular block: a multicenter experience. *J Am Coll Cardiol*. 1991;17:1360–1366.
66. Copel JA, Liang RI, Demasio K, Ozeren S, Kleinman CS. The clinical significance of the irregular fetal heart rhythm. *Am J Obstet Gynecol*. 2000;182:813–817.
67. Fogel M, Copel JA, Cullen MT, Hobbins JC, Kleinman CS. Congenital heart disease and fetal thoracoabdominal anomalies: associations in utero and the importance of cytogenetic analysis. *Am J Perinatol*. 1991;8:411–416.
68. Copel JA, Pilu G, Kleinman CS. Congenital heart disease and extracardiac anomalies: associations and indications for fetal echocardiography. *Am J Obstet Gynecol*. 1986;154:1121–1132.
69. Greenwood RD, Rosenthal A, Nadas AS. Cardiovascular malformations associated with omphalocele. *J Pediatr*. 1974;85:818–821.
70. Greenwood RD, Rosenthal A, Nadas AS. Cardiovascular malformations associated with imperforate anus. *J Pediatr*. 1975;86:576–579.
71. Greenwood RD, Rosenthal A, Nadas AS. Cardiovascular malformations associated with congenital anomalies of the urinary system: observations in a series of 453 infants and children with urinary system malformations. *Clin Pediatr (Phila)*. 1976;15:1101–1104.
72. Greenwood RD, Rosenthal A, Nadas AS. Cardiovascular abnormalities associated with congenital diaphragmatic hernia. *Pediatrics*. 1976;57:92–97.
73. Martinez-Frias ML, Bermejo E, Rodriguez-Pinilla E, Prieto D; ECEMC Working Group. Does single umbilical artery (SUA) predict any type of congenital defect? Clinical-epidemiological analysis of a large consecutive series of malformed infants. *Am J Med Genet A*. 2008;146A:15–25.
74. Tennstedt C, Chaoui R, Korner H, Dietel M. Spectrum of congenital heart defects and extracardiac malformations associated with chromosomal abnormalities: results of a seven year necropsy study. *Heart*. 1999;82:34–39.

75. Hyett J, Moscoso G, Papapanagiotou G, Perdu M, Nicolaides KH. Abnormalities of the heart and great arteries in chromosomally normal fetuses with increased nuchal translucency thickness at 11-13 weeks of gestation. *Ultrasound Obstet Gynecol.* 1996;7:245-250.
76. Papatheodorou SI, Evangelou E, Makrydimas G, Ioannidis JP. First-trimester ductus venosus screening for cardiac defects: a meta-analysis. *BJOG.* 2011;118:1438-1445.
77. Makrydimas G, Sotiriadis A, Ioannidis JP. Screening performance of first-trimester nuchal translucency for major cardiac defects: a meta-analysis. *Am J Obstet Gynecol.* 2003;189:1330-1335.
78. Simpson LL, Malone FD, Bianchi DW, Ball RH, Nyberg DA, Comstock CH, Saade G, Eddleman K, Gross SJ, Dugoff L, Craigo SD, Timor-Tritsch IE, Carr SR, Wolfe HM, Tripp T, D'Alton ME. Nuchal translucency and the risk of congenital heart disease. *Obstet Gynecol.* 2007;109(pt 1):376-383.
79. Ghi T, Huggon IC, Zosmer N, Nicolaides KH. Incidence of major structural cardiac defects associated with increased nuchal translucency but normal karyotype. *Ultrasound Obstet Gynecol.* 2001;18:610-614.
80. Galindo A, Comas C, Martinez JM, Gutierrez-Larraya F, Carrera JM, Puerto B, Borrell A, Mortera C, de la Fuente P. Cardiac defects in chromosomally normal fetuses with increased nuchal translucency at 10-14 weeks of gestation. *J Matern Fetal Neonatal Med.* 2003;13:163-170.
81. Lilja M. Infants with single umbilical artery studied in a national registry, 2: survival and malformations in infants with single umbilical artery. *Paediatr Perinat Epidemiol.* 1992;6:416-422.
82. Weichert J, Hartge D, Germer U, Axt-Flidner R, Gembruch U. Persistent right umbilical vein: a prenatal condition worth mentioning? *Ultrasound Obstet Gynecol.* 2011;37:543-548.
83. Bahtiyar MO, Dulay AT, Weeks BP, Friedman AH, Copel JA. Prevalence of congenital heart defects in monozygotic/diamniotic twin gestations: a systematic literature review. *J Ultrasound Med.* 2007;26:1491-1498.
84. Herberg U, Gross W, Bartmann P, Banek CS, Hecher K, Breuer J. Long term cardiac follow up of severe twin to twin transfusion syndrome after intrauterine laser coagulation. *Heart.* 2006;92:95-100.
85. Kleinman CS, Donnerstein RL, DeVore GR, Jaffe CC, Lynch DC, Berkowitz RL, Talner NS, Hobbins JC. Fetal echocardiography for evaluation of in utero congestive heart failure. *N Engl J Med.* 1982;306:568-575.
86. Machin GA. Differential diagnosis of hydrops fetalis. *Am J Med Genet.* 1981;9:341-350.
87. Moore T. *Maternal-Fetal Medicine: Principles and Practice.* Philadelphia, PA: Saunders; 1999.
88. Ylisen K, Aula P, Stenman UH, Kesaniemi-Kuokkanen T, Teramo K. Risk of minor and major fetal malformations in diabetics with high haemoglobin A1c values in early pregnancy. *Br Med J (Clin Res Ed).* 1984;289:345-346.
89. Shields LE, Gan EA, Murphy HF, Sahn DJ, Moore TR. The prognostic value of hemoglobin A1c in predicting fetal heart disease in diabetic pregnancies. *Obstet Gynecol.* 1993;81:954-957.
90. Hagay Z, Reece A. *Reece and Hobbins: Medicine of the Fetus and Mother.* Philadelphia, PA; JP Lippincott; 1999.
91. Jaeggi ET, Fouron JC, Proulx F. Fetal cardiac performance in uncomplicated and well-controlled maternal type I diabetes. *Ultrasound Obstet Gynecol.* 2001;17:311-315.
92. Levy HL, Waisbren SE. Effects of untreated maternal phenylketonuria and hyperphenylalaninemia on the fetus. *N Engl J Med.* 1983;309:1269-1274.
93. Chameides L, Truex RC, Vetter V, Rashkind WJ, Galioti FM Jr, Noonan JA. Association of maternal systemic lupus erythematosus with congenital complete heart block. *N Engl J Med.* 1977;297:1204-1207.
94. Cuneo BF, Fruitman D, Benson DW, Ngan BY, Liske MR, Wahren-Herlineus M, Ho SY, Jaeggi E. Spontaneous rupture of atrioventricular valve tensor apparatus as late manifestation of anti-Ro/SSA antibody-mediated cardiac disease. *Am J Cardiol.* 2011;107:761-766.
95. Small M, Copel JA. Indications for fetal echocardiography. *Pediatr Cardiol.* 2004;25:210-222.
96. Nii M, Hamilton RM, Fenwick L, Kingdom JC, Roman KS, Jaeggi ET. Assessment of fetal atrioventricular time intervals by tissue Doppler and pulse Doppler echocardiography: normal values and correlation with fetal electrocardiography. *Heart.* 2006;92:1831-1837.
97. Warner JP. Evidence-based psychopharmacology, 3: assessing evidence of harm: what are the teratogenic effects of lithium carbonate? *J Psychopharmacol.* 2000;14:77-80.
98. Moise KJ Jr, Huhta JC, Sharif DS, Ou CN, Kirshon B, Wasserstrum N, Cano L. Indomethacin in the treatment of premature labor: effects on the fetal ductus arteriosus. *N Engl J Med.* 1988;319:327-331.
99. Wright VC, Chang J, Jeng G, Macaluso M; Centers for Disease Control and Prevention (CDC). Assisted reproductive technology surveillance—United States, 2005. *MMWR Surveill Summ.* 2008;57:1-23.
100. Reefhuis J, Honein MA. Maternal age and non-chromosomal birth defects, Atlanta—1968–2000: teenager or thirty-something, who is at risk? *Birth Defects Res A Clin Mol Teratol.* 2004;70:572-579.
101. Koivurova S, Hartikainen AL, Gissler M, Hemminki E, Sovio U, Jarvelin MR. Neonatal outcome and congenital malformations in children born after in-vitro fertilization. *Hum Reprod.* 2002;17:1391-1398.
102. Whittemore R, Wells JA, Castellsague X. A second-generation study of 427 probands with congenital heart defects and their 837 children. *J Am Coll Cardiol.* 1994;23:1459-1467.
103. Cripe L, Andelfinger G, Martin LJ, Shooner K, Benson DW. Bicuspid aortic valve is heritable. *J Am Coll Cardiol.* 2004;44:138-143.
104. Calcagni G, Digilio MC, Sarkozy A, Dallapiccola B, Marino B. Familial recurrence of congenital heart disease: an overview and review of the literature. *Eur J Pediatr.* 2007;166:111-116.
105. Chaoui R, McEwing R. Three cross-sectional planes for fetal color Doppler echocardiography. *Ultrasound Obstet Gynecol.* 2003;21:81-93.
106. Yoo SJ, Lee YH, Kim ES, Ryu HM, Kim MY, Choi HK, Cho KS, Kim A. Three-vessel view of the fetal upper mediastinum: an easy means of detecting abnormalities of the ventricular outflow tracts and great arteries during obstetric screening. *Ultrasound Obstet Gynecol.* 1997;9:173-182.
107. Hofbeck M, Ulmer H, Beinder E, Sieber E, Singer H. Prenatal findings in patients with prolonged QT interval in the neonatal period. *Heart.* 1997;77:198-204.
108. Lin MT, Hsieh FJ, Shyu MK, Lee CN, Wang JK, Wu MH. Postnatal outcome of fetal bradycardia without significant cardiac abnormalities. *Am Heart J.* 2004;147:540-544.
109. Tomek V, Skovranek J, Gebauer RA. Prenatal diagnosis and management of fetal long QT syndrome. *Pediatr Cardiol.* 2009;30:194-196.
110. Greenwood RD, Rosenthal A, Parisi L, Fyler DC, Nadas AS. Extracardiac abnormalities in infants with congenital heart disease. *Pediatrics.* 1975;55:485-492.
111. Gallo P, Nardi F, Marinuzzi V. Congenital extracardiac malformations accompanying congenital heart disease. *G Ital Cardiol.* 1976;6:450-459.
112. Wallgren EI, Landtman B, Rapola J. Extracardiac malformations associated with congenital heart disease. *Eur J Cardiol.* 1978;7:15-24.
113. Miller A, Riehle-Colarusso T, Alverson CJ, Frias JL, Correa A. Congenital heart defects and major structural noncardiac anomalies, Atlanta, Georgia, 1968 to 2005. *J Pediatr.* 2011;159:70-78.e2.
114. Nicolaides KH, Azar G, Byrne D, Mansur C, Marks K. Fetal nuchal translucency: ultrasound screening for chromosomal defects in first trimester of pregnancy. *BMJ.* 1992;304:867-869.
115. Nicolaides KH, Heath V, Cicero S. Increased fetal nuchal translucency at 11-14 weeks. *Prenat Diagn.* 2002;22:308-315.
116. Snijders RJ, Noble P, Sebire N, Souka A, Nicolaides KH. UK multi-centre project on assessment of risk of trisomy 21 by maternal age and fetal nuchal-translucency thickness at 10-14 weeks of gestation: Fetal Medicine Foundation First Trimester Screening Group. *Lancet.* 1998;352:343-346.
117. Haak MC, Twisk JW, Bartelings MM, Gittenberger-de Groot AC, van Vugt JM. Ductus venosus flow velocities in relation to the cardiac defects in first-trimester fetuses with enlarged nuchal translucency. *Am J Obstet Gynecol.* 2003;188:727-733.
118. Huggon IC, Turan O, Allan LD. Doppler assessment of cardiac function at 11-14 weeks' gestation in fetuses with normal and increased nuchal translucency. *Ultrasound Obstet Gynecol.* 2004;24:390-398.
119. Hyett J, Perdu M, Sharland G, Snijders R, Nicolaides KH. Using fetal nuchal translucency to screen for major congenital cardiac defects at 10-14 weeks of gestation: population based cohort study. *BMJ.* 1999;318:81-85.
120. Bahado-Singh RO, Wapner R, Thom E, Zachary J, Platt L, Mahoney MJ, Johnson A, Silver RK, Pergament E, Filkins K, Hogge WA, Wilson RD, Jackson LG; First Trimester Maternal Serum Biochemistry and Fetal Nuchal Translucency Screening Study Group. Elevated first-trimester nuchal translucency increases the risk of congenital heart defects. *Am J Obstet Gynecol.* 2005;192:1357-1361.
121. Westin M, Saltvedt S, Bergman G, Almstrom H, Grunewald C, Valentin L. Is measurement of nuchal translucency thickness a useful screening tool for heart defects? A study of 16,383 fetuses. *Ultrasound Obstet Gynecol.* 2006;27:632-639.
122. Makrydimas G, Sotiriadis A, Huggon IC, Simpson J, Sharland G, Carvalho JS, Daubeney PE, Ioannidis JP. Nuchal translucency and fetal



- cardiac defects: a pooled analysis of major fetal echocardiography centers. *Am J Obstet Gynecol*. 2005;192:89–95.
123. Mavrides E, Cobian-Sanchez F, Tekay A, Moscoco G, Campbell S, Thilaganathan B, Carvalho JS. Limitations of using first-trimester nuchal translucency measurement in routine screening for major congenital heart defects. *Ultrasound Obstet Gynecol*. 2001;17:106–110.
  124. Muller MA, Clur SA, Timmerman E, Bilardo CM. Nuchal translucency measurement and congenital heart defects: modest association in low-risk pregnancies. *Prenat Diagn*. 2007;27:164–169.
  125. Atzei A, Gajewska K, Huggon IC, Allan L, Nicolaides KH. Relationship between nuchal translucency thickness and prevalence of major cardiac defects in fetuses with normal karyotype. *Ultrasound Obstet Gynecol*. 2005;26:154–157.
  126. Bilardo CM, Muller MA, Zikulnig L, Schipper M, Hecher K. Ductus venosus studies in fetuses at high risk for chromosomal or heart abnormalities: relationship with nuchal translucency measurement and fetal outcome. *Ultrasound Obstet Gynecol*. 2001;17:288–294.
  127. Maiz N, Plascencia W, Dagklis T, Faros E, Nicolaides K. Ductus venosus Doppler in fetuses with cardiac defects and increased nuchal translucency thickness. *Ultrasound Obstet Gynecol*. 2008;31:256–260.
  128. Fasouliotis SJ, Achiron R, Kivilevitch Z, Yagel S. The human fetal venous system: normal embryologic, anatomic, and physiologic characteristics and developmental abnormalities. *J Ultrasound Med*. 2002;21:1145–1158.
  129. Jaeggi ET, Fouron JC, Hornberger LK, Proulx F, Oberhansli I, Yoo SJ, Ferment L. Agenesis of the ductus venosus that is associated with extrahepatic umbilical vein drainage: prenatal features and clinical outcome. *Am J Obstet Gynecol*. 2002;187:1031–1037.
  130. Karatza AA, Wolfenden JL, Taylor MJ, Wee L, Fisk NM, Gardiner HM. Influence of twin-twin transfusion syndrome on fetal cardiovascular structure and function: prospective case-control study of 136 monozygotic twin pregnancies. *Heart*. 2002;88:271–277.
  131. AlRais F, Feldstein VA, Srivastava D, Gosnell K, Moon-Grady AJ. Monozygotic twins discordant for congenital heart disease: a referral center's experience and possible pathophysiologic mechanisms. *Prenat Diagn*. 2011;31:978–984.
  132. Lopriore E, Bokenkamp R, Rijlaarsdam M, Sueters M, Vandenbussche FP, Walther FJ. Congenital heart disease in twin-to-twin transfusion syndrome treated with fetoscopic laser surgery. *Congenit Heart Dis*. 2007;2:38–43.
  133. Pruetz JD, Sklansky M, Dettlerich J, Korst LM, Llanes A, Chmait RH. Twin-twin transfusion syndrome treated with laser surgery: postnatal prevalence of congenital heart disease in surviving recipients and donors. *Prenat Diagn*. 2011;31:973–977.
  134. Moon-Grady AJ, Rand L, Lemley B, Gosnell K, Hornberger LK, Lee H. Effect of selective fetoscopic laser photocoagulation therapy for twin-twin transfusion syndrome on pulmonary valve pathology in recipient twins. *Ultrasound Obstet Gynecol*. 2011;37:27–33.
  135. Stumpflen I, Stumpflen A, Wimmer M, Bernaschek G. Effect of detailed fetal echocardiography as part of routine prenatal ultrasonographic screening on detection of congenital heart disease. *Lancet*. 1996;348:854–857.
  136. Yagel S, Weissman A, Rotstein Z, Manor M, Hegesh J, Anteby E, Lipitz S, Achiron R. Congenital heart defects: natural course and in utero development. *Circulation*. 1997;96:550–555.
  137. Ewigman BG, Crane JP, Frigoletto FD, LeFevre ML, Bain RP, McNellis D. Effect of prenatal ultrasound screening on perinatal outcome: RADIUS Study Group. *N Engl J Med*. 1993;329:821–827.
  138. Garne E, Stoll C, Clementi M; Euroscan Group. Evaluation of prenatal diagnosis of congenital heart diseases by ultrasound: experience from 20 European registries. *Ultrasound Obstet Gynecol*. 2001;17:386–391.
  139. Tegnander E, Eik-Nes SH, Johansen OJ, Linker DT. Prenatal detection of heart defects at the routine fetal examination at 18 weeks in a non-selected population. *Ultrasound Obstet Gynecol*. 1995;5:372–380.
  140. Kleinert S. Routine prenatal screening for congenital heart disease. *Lancet*. 1996;348:836.
  141. Tegnander E, Eik-Nes SH, Linker DT. Incorporating the four-chamber view of the fetal heart into the second-trimester routine fetal examination. *Ultrasound Obstet Gynecol*. 1994;4:24–28.
  142. Del Bianco A, Russo S, Lacerenza N, Rinaldi M, Rinaldi G, Nappi L, Greco P. Four chamber view plus three-vessel and trachea view for a complete evaluation of the fetal heart during the second trimester. *J Perinat Med*. 2006;34:309–312.
  143. Kirk JS, Riggs TW, Comstock CH, Lee W, Yang SS, Weinhouse E. Prenatal screening for cardiac anomalies: the value of routine addition of the aortic root to the four-chamber view. *Obstet Gynecol*. 1994;84:427–431.
  144. Marek J, Tomek V, Skovranek J, Povysilova V, Samanek M. Prenatal ultrasound screening of congenital heart disease in an unselected national population: a 21-year experience. *Heart*. 2011;97:124–130.
  145. Friedberg MK, Silverman NH, Moon-Grady AJ, Tong E, Nourse J, Sorenson B, Lee J, Hornberger LK. Prenatal detection of congenital heart disease. *J Pediatr*. 2009;155:26–31, 31.e1.
  146. Sklansky MS, Berman DP, Pruetz JD, Chang RK. Prenatal screening for major congenital heart disease: superiority of outflow tracts over the 4-chamber view. *J Ultrasound Med*. 2009;28:889–899.
  147. Ogge G, Gaglioti P, Maccanti S, Faggiano F, Todros T. Prenatal screening for congenital heart disease with four-chamber and outflow-tract views: a multicenter study. *Ultrasound Obstet Gynecol*. 2006;28:779–784.
  148. Starikov RS, Bsat FA, Knee AB, Tsirka AE, Paris Y, Markenson GR. Utility of fetal echocardiography after normal cardiac imaging findings on detailed fetal anatomic ultrasonography. *J Ultrasound Med*. 2009;28:603–608.
  149. Fetal Echocardiography Task Force; American Institute of Ultrasound in Medicine Clinical Standards Committee; American College of Obstetricians and Gynecologists; Society for Maternal-Fetal Medicine. AIUM practice guideline for the performance of fetal echocardiography. *J Ultrasound Med*. 2013;32:1067–1082.
  150. Lee W, Allan L, Carvalho JS, Chaoui R, Copel J, Devore G, Hecher K, Munoz H, Nelson T, Paladini D, Yagel S; ISUOG Fetal Echocardiography Task Force. ISUOG consensus statement: what constitutes a fetal echocardiogram? *Ultrasound Obstet Gynecol*. 2008;32:239–242.
  151. Rychik J, Ayres N, Cuneo B, Gotteiner N, Hornberger L, Spevak PJ, Van Der Veld M. American Society of Echocardiography guidelines and standards for performance of the fetal echocardiogram. *J Am Soc Echocardiogr*. 2004;17:803–810.
  152. Allan L, Dangel J, Fesslova V, Marek J, Mellander M, Oberhansli I, Oberhoffer R, Sharland G, Simpson J, Sonesson SE; Fetal Cardiology Working Group; Association for European Paediatric Cardiology. Recommendations for the practice of fetal cardiology in Europe. *Cardiol Young*. 2004;14:109–114.
  153. Sklansky M. Current guidelines for fetal echocardiography: time to raise the bar. *J Ultrasound Med*. 2011;30:284–286; author reply 286.
  154. American Institute of Ultrasound in Medicine. AIUM practice guideline for the performance of fetal echocardiography. *J Ultrasound Med*. 2013;32:1067–1082.
  155. Trines J, Hornberger LK. Evolution of heart disease in utero. *Pediatr Cardiol*. 2004;25:287–298.
  156. van Engelen AD, Weijtens O, Brenner JJ, Kleinman CS, Copel JA, Stoutenbeek P, Meijboom EJ. Management outcome and follow-up of fetal tachycardia. *J Am Coll Cardiol*. 1994;24:1371–1375.
  157. Simpson JM, Sharland GK. Fetal tachycardias: management and outcome of 127 consecutive cases. *Heart*. 1998;79:576–581.
  158. Hornberger LK, Sahn DJ, Kleinman CS, Copel JA, Reed KL. Tricuspid valve disease with significant tricuspid insufficiency in the fetus: diagnosis and outcome. *J Am Coll Cardiol*. 1991;17:167–173.
  159. Sharland GK, Chita SK, Allan LD. Tricuspid valve dysplasia or displacement in intrauterine life. *J Am Coll Cardiol*. 1991;17:944–949.
  160. Wertaschnigg D, Jaeggi M, Chitayat D, Shannon P, Ryan G, Thompson M, Yoo SJ, Jaeggi E. Prenatal diagnosis and outcome of absent pulmonary valve syndrome: contemporary single center experience and review of the literature. *Ultrasound Obstet Gynecol*. 2013;41:162–167.
  161. Yamamoto Y, Hornberger LK. Progression of outflow tract obstruction in the fetus. *Early Hum Dev*. 2012;88:279–285.
  162. Loughheed J, Sinclair BG, Fung Kee Fung K, Bigras JL, Ryan G, Smallhorn JF, Hornberger LK. Acquired right ventricular outflow tract obstruction in the recipient twin in twin-twin transfusion syndrome. *J Am Coll Cardiol*. 2001;38:1533–1538.
  163. Hornberger LK, Sanders SP, Sahn DJ, Rice MJ, Spevak PJ, Benacerraf BR, McDonald RW, Colan SD. In utero pulmonary artery and aortic growth and potential for progression of pulmonary outflow tract obstruction in tetralogy of Fallot. *J Am Coll Cardiol*. 1995;25:739–745.
  164. Hornberger LK, Sahn DJ, Kleinman CS, Copel J, Silverman NH. Antenatal diagnosis of coarctation of the aorta: a multicenter experience. *J Am Coll Cardiol*. 1994;23:417–423.
  165. Makikallio K, McElhinney DB, Levine JC, Marx GR, Colan SD, Marshall AC, Lock JE, Marcus EN, Tworetzky W. Fetal aortic valve stenosis and the evolution of hypoplastic left heart syndrome: patient selection for fetal intervention. *Circulation*. 2006;113:1401–1405.
  166. Tworetzky W, McElhinney DB, Marx GR, Benson CB, Brusseau R, Morash D, Wilkins-Haug LE, Lock JE, Marshall AC. In utero valvuloplasty for pulmonary atresia with hypoplastic right ventricle: techniques and outcomes. *Pediatrics*. 2009;124:e510–e518.



167. Pedra SR, Hornberger LK, Leal SM, Taylor GP, Smallhorn JF. Cardiac function assessment in patients with family history of nonhypertrophic cardiomyopathy: a prenatal and postnatal study. *Pediatr Cardiol.* 2005;26:543–552.
168. Pedra SR, Smallhorn JF, Ryan G, Chitayat D, Taylor GP, Khan R, Abdollell M, Hornberger LK. Fetal cardiomyopathies: pathogenic mechanisms, hemodynamic findings, and clinical outcome. *Circulation.* 2002;106:585–591.
169. Sivasankaran S, Sharland GK, Simpson JM. Dilated cardiomyopathy presenting during fetal life. *Cardiol Young.* 2005;15:409–416.
170. Nield LE, Silverman ED, Taylor GP, Smallhorn JF, Mullen JB, Silverman NH, Finley JP, Law YM, Human DG, Seaward PG, Hamilton RM, Hornberger LK. Maternal anti-Ro and anti-La antibody-associated endocardial fibroelastosis. *Circulation.* 2002;105:843–848.
171. Tworetzky W, McElhinney DB, Margossian R, Moon-Grady AJ, Sallee D, Goldmuntz E, van der Velde ME, Silverman NH, Allan LD. Association between cardiac tumors and tuberosus sclerosis in the fetus and neonate. *Am J Cardiol.* 2003;92:487–489.
172. Chao AS, Chao A, Wang TH, Chang YC, Chang YL, Hsieh CC, Lien R, Su WJ. Outcome of antenatally diagnosed cardiac rhabdomyoma: case series and a meta-analysis. *Ultrasound Obstet Gynecol.* 2008;31:289–295.
173. Huhta JC, Cohen AW, Wood DC. Premature constriction of the ductus arteriosus. *J Am Soc Echocardiogr.* 1990;3:30–34.
174. Respondek M, Weil SR, Huhta JC. Fetal echocardiography during indomethacin treatment. *Ultrasound Obstet Gynecol.* 1995;5:86–89.
175. Taketazu M, Barrea C, Smallhorn JF, Wilson GJ, Hornberger LK. Intrauterine pulmonary venous flow and restrictive foramen ovale in fetal hypoplastic left heart syndrome. *J Am Coll Cardiol.* 2004;43:1902–1907.
176. Divanovic A, Hor K, Cnota J, Hirsch R, Kinsel-Ziter M, Michelfelder E. Prediction and perinatal management of severely restrictive atrial septum in fetuses with critical left heart obstruction: clinical experience using pulmonary venous Doppler analysis. *J Thorac Cardiovasc Surg.* 2011;141:988–994.
177. Chintala K, Tian X, Du W, Donoghue D, Rychik J. Fetal pulmonary venous Doppler patterns in hypoplastic left heart syndrome: relationship to atrial septal restriction. *Heart.* 2008;94:1446–1449.
178. Chobot V, Hornberger LK, Hagen-Ansert S, Sahn DJ. Prenatal detection of restrictive foramen ovale. *J Am Soc Echocardiogr.* 1990;3:15–19.
179. Copel JA, Grannum PA, Green JJ, Belanger K, Hanna N, Jaffe CC, Hobbins JC, Kleinman CS. Fetal cardiac output in the isoimmunized pregnancy: a pulsed Doppler-echocardiographic study of patients undergoing intravascular intrauterine transfusion. *Am J Obstet Gynecol.* 1989;161:361–365.
180. Silverman NH, Schmidt KG. Ventricular volume overload in the human fetus: observations from fetal echocardiography. *J Am Soc Echocardiogr.* 1990;3:20–29.
181. Byrne FA, Lee H, Kipps AK, Brook MM, Moon-Grady AJ. Echocardiographic risk stratification of fetuses with sacrococcygeal teratoma and twin-reversed arterial perfusion. *Fetal Diagn Ther.* 2011;30:280–288.
182. Saltvedt S, Almstrom H, Kublickas M, Valentin L, Grunewald C. Detection of malformations in chromosomally normal fetuses by routine ultrasound at 12 or 18 weeks of gestation: a randomised controlled trial in 39,572 pregnancies. *BJOG.* 2006;113:664–674.
183. Syngelaki A, Chelemen T, Dagklis T, Allan L, Nicolaidis KH. Challenges in the diagnosis of fetal non-chromosomal abnormalities at 11–13 weeks. *Prenat Diagn.* 2011;31:90–102.
184. Huggon IC, Ghi T, Cook AC, Zosmer N, Allan LD, Nicolaidis KH. Fetal cardiac abnormalities identified prior to 14 weeks' gestation. *Ultrasound Obstet Gynecol.* 2002;20:22–29.
185. Hyett JA, Perdu M, Sharland GK, Snijders RS, Nicolaidis KH. Increased nuchal translucency at 10–14 weeks of gestation as a marker for major cardiac defects. *Ultrasound Obstet Gynecol.* 1997;10:242–246.
186. Persico N, Moratalla J, Lombardi CM, Zidere V, Allan L, Nicolaidis KH. Fetal echocardiography at 11–13 weeks by transabdominal high-frequency ultrasound. *Ultrasound Obstet Gynecol.* 2011;37:296–301.
187. Moon-Grady A, Shanavaz S, Brook M, Rodriguez H, Hornberger LK. Can a complete fetal echocardiogram be performed at 12 to 16 weeks gestation? *J Am Soc Echocardiogr.* 2012;25:1342–1352.
188. Kurjak A. Are color and pulsed Doppler sonography safe in early pregnancy? *J Perinat Med.* 1999;27:423–430.
189. Barnett SB, Maulik D; International Perinatal Doppler Society. Guidelines and recommendations for safe use of Doppler ultrasound in perinatal applications. *J Matern Fetal Med.* 2001;10:75–84.
190. *Standard for Real-Time Display of Thermal and Mechanical Acoustic Output Indices on Diagnostic Ultrasound Equipment.* Rockville, MD: American Institute of Ultrasound in Medicine; 1992.
191. Food and Drug Administration. *Revised 510(k) Diagnostic Ultrasound Guidance for 1993.* Rockville, MD: Center for Devices and Radiological Health; 1993.
192. Edwards MJ. Hyperthermia and birth defects. *Cornell Vet.* 1993;83:1–7.
193. Shipp TD, Bromley B, Hornberger LK, Nadel A, Benaceraf BR. Levorotation of the fetal cardiac axis: a clue for the presence of congenital heart disease. *Obstet Gynecol.* 1995;85:97–102.
194. Song MS, Hu A, Dyamenahalli U, Chitayat D, Winsor EJ, Ryan G, Smallhorn J, Barrett J, Yoo SJ, Hornberger LK. Extracardiac lesions and chromosomal abnormalities associated with major fetal heart defects: comparison of intrauterine, postnatal and postmortem diagnoses. *Ultrasound Obstet Gynecol.* 2009;33:552–559.
195. Rychik J, Tian ZY, Fogel MA, Joshi V, Rose NC, Jacobs ML. The single ventricle heart in the fetus: accuracy of prenatal diagnosis and outcome. *J Perinatol.* 1997;17:183–188.
196. Tometzki AJ, Suda K, Kohl T, Kovalchin JP, Silverman NH. Accuracy of prenatal echocardiographic diagnosis and prognosis of fetuses with conotruncal anomalies. *J Am Coll Cardiol.* 1999;33:1696–1701.
197. Gottliebson WM, Border WL, Franklin CM, Meyer RA, Michelfelder EC. Accuracy of fetal echocardiography: a cardiac segment-specific analysis. *Ultrasound Obstet Gynecol.* 2006;28:15–21.
198. Taketazu M, Loughheed J, Yoo SJ, Lim JS, Hornberger LK. Spectrum of cardiovascular disease, accuracy of diagnosis, and outcome in fetal heterotaxy syndrome. *Am J Cardiol.* 2006;97:720–724.
199. Stewart PA, Wladimiroff JW. Fetal echocardiography and color Doppler flow imaging: the Rotterdam experience. *Ultrasound Obstet Gynecol.* 1993;3:168–175.
200. Copel JA, Morotti R, Hobbins JC, Kleinman CS. The antenatal diagnosis of congenital heart disease using fetal echocardiography: is color flow mapping necessary? *Obstet Gynecol.* 1991;78:1–8.
201. Gembruch U, Chatterjee MS, Bald R, Redel DA, Hansmann M. Color Doppler flow mapping of fetal heart. *J Perinat Med.* 1991;19:27–32.
202. Comas Gabriel C, Galindo A, Martinez JM, Carrera JM, Gutierrez-Larraya F, de la Fuente P, Puerto B, Borrell A. Early prenatal diagnosis of major cardiac anomalies in a high-risk population. *Prenat Diagn.* 2002;22:586–593.
203. Nadel AS. Addition of color Doppler to the routine obstetric sonographic survey aids in the detection of pulmonic stenosis. *Fetal Diagn Ther.* 2010;28:175–179.
204. Mielke G, Steil E, Kendziorra H, Goelz R. Ductus arteriosus-dependent pulmonary circulation secondary to cardiac malformations in fetal life. *Ultrasound Obstet Gynecol.* 1997;9:25–29.
205. Berning RA, Silverman NH, Villegas M, Sahn DJ, Martin GR, Rice MJ. Reversed shunting across the ductus arteriosus or atrial septum in utero heralds severe congenital heart disease. *J Am Coll Cardiol.* 1996;27:481–486.
206. Seale AN, Ho SY, Shinebourne EA, Carvalho JS. Prenatal identification of the pulmonary arterial supply in tetralogy of Fallot with pulmonary atresia. *Cardiol Young.* 2009;19:185–191.
207. Reed KL, Meijboom EJ, Sahn DJ, Scagnelli SA, Valdes-Cruz LM, Shenker L. Cardiac Doppler flow velocities in human fetuses. *Circulation.* 1986;73:41–46.
208. Choi JY, Noh CI, Yun YS. Study on Doppler waveforms from the fetal cardiovascular system. *Fetal Diagn Ther.* 1991;6:74–83.
209. Mielke G, Benda N. Blood flow velocity waveforms of the fetal pulmonary artery and the ductus arteriosus: reference ranges from 13 weeks to term. *Ultrasound Obstet Gynecol.* 2000;15:213–218.
210. Laudy JA, de Ridder MA, Wladimiroff JW. Doppler velocimetry in branch pulmonary arteries of normal human fetuses during the second half of gestation. *Pediatr Res.* 1997;41:897–901.
211. Fouron JC. The unrecognized physiological and clinical significance of the fetal aortic isthmus. *Ultrasound Obstet Gynecol.* 2003;22:441–447.
212. Paladini D, Palmieri S, Celentano E, Guida F, Salviati M, Morra T, Martinelli P. Pulmonary venous blood flow in the human fetus. *Ultrasound Obstet Gynecol.* 1997;10:27–31.
213. Huisman TW, Stewart PA, Wladimiroff JW, Stijnen T. Flow velocity waveforms in the ductus venosus, umbilical vein and inferior vena cava in normal human fetuses at 12–15 weeks of gestation. *Ultrasound Med Biol.* 1993;19:441–445.
214. Mielke G, Benda N. Cardiac output and central distribution of blood flow in the human fetus. *Circulation.* 2001;103:1662–1668.
215. Valsangiacomo ER, Hornberger LK, Barrea C, Smallhorn JF, Yoo SJ. Partial and total anomalous pulmonary venous connection in the fetus:

- two-dimensional and Doppler echocardiographic findings. *Ultrasound Obstet Gynecol.* 2003;22:257–263.
216. Barrea C, Alkazaleh F, Ryan G, McCrindle BW, Roberts A, Bigras JL, Barrett J, Seaward GP, Smallhorn JF, Hornberger LK. Prenatal cardiovascular manifestations in the twin-to-twin transfusion syndrome recipients and the impact of therapeutic amnioreduction. *Am J Obstet Gynecol.* 2005;192:892–902.
  217. Quartermain MD, Glatz AC, Goldberg DJ, Cohen MS, Elias MD, Tian Z, Rychik J. Pulmonary outflow tract obstruction in the fetus with complex congenital heart disease: predicting the need for neonatal intervention. *Ultrasound Obstet Gynecol.* 2013;41:47–53.
  218. Quartermain MD, Cohen MS, Dominguez TE, Tian Z, Donaghue DD, Rychik J. Left ventricle to right ventricle size discrepancy in the fetus: the presence of critical congenital heart disease can be reliably predicted. *J Am Soc Echocardiogr.* 2009;22:1296–1301.
  219. Allan LD, Sharland GK. The echocardiographic diagnosis of totally anomalous pulmonary venous connection in the fetus. *Heart.* 2001;85:433–437.
  220. Hornberger LK, Benacerraf BR, Bromley BS, Spevak PJ, Sanders SP. Prenatal detection of severe right ventricular outflow tract obstruction: pulmonary stenosis and pulmonary atresia. *J Ultrasound Med.* 1994;13:743–750.
  221. Paternoster DM, Manganelli F, Moroder W, Nicolini U. Prenatal diagnosis of vein of Galen aneurysmal malformations. *Fetal Diagn Ther.* 2003;18:408–411.
  222. Sharland GK, Allan LD. Normal fetal cardiac measurements derived by cross-sectional echocardiography. *Ultrasound Obstet Gynecol.* 1992;2:175–181.
  223. Tan J, Silverman NH, Hoffman JI, Villegas M, Schmidt KG. Cardiac dimensions determined by cross-sectional echocardiography in the normal human fetus from 18 weeks to term. *Am J Cardiol.* 1992;70:1459–1467.
  224. Shapiro I, Degani S, Leibovitz Z, Ohel G, Tal Y, Abinader EG. Fetal cardiac measurements derived by transvaginal and transabdominal cross-sectional echocardiography from 14 weeks of gestation to term. *Ultrasound Obstet Gynecol.* 1998;12:404–418.
  225. Schneider C, McCrindle BW, Carvalho JS, Hornberger LK, McCarthy KP, Daubeney PE. Development of Z-scores for fetal cardiac dimensions from echocardiography. *Ultrasound Obstet Gynecol.* 2005;26:599–605.
  226. Makikallio K, Rasanen J, Makikallio T, Vuolteenaho O, Huhta JC. Human fetal cardiovascular profile score and neonatal outcome in intrauterine growth restriction. *Ultrasound Obstet Gynecol.* 2008;31:48–54.
  227. Bahtiyar MO, Copel JA. Cardiac changes in the intrauterine growth-restricted fetus. *Semin Perinatol.* 2008;32:190–193.
  228. Paladini D, Chita SK, Allan LD. Prenatal measurement of cardiothoracic ratio in evaluation of heart disease. *Arch Dis Child.* 1990;65:20–23.
  229. Awadh AM, Prefumo F, Bland JM, Carvalho JS. Assessment of the intraobserver variability in the measurement of fetal cardiothoracic ratio using ellipse and diameter methods. *Ultrasound Obstet Gynecol.* 2006;28:53–56.
  230. DeVore GR, Siassi B, Platt LD. Fetal echocardiography, IV: M-mode assessment of ventricular size and contractility during the second and third trimesters of pregnancy in the normal fetus. *Am J Obstet Gynecol.* 1984;150:981–988.
  231. Wladimiroff JW, McGhie J. Ultrasonic assessment of cardiovascular geometry and function in the human fetus. *Br J Obstet Gynaecol.* 1981;88:870–875.
  232. Simpson J. Echocardiographic evaluation of cardiac function in the fetus. *Prenat Diagn.* 2004;24:1081–1091.
  233. Van Mieghem T, DeKoninck P, Steenhaut P, Deprest J. Methods for prenatal assessment of fetal cardiac function. *Prenat Diagn.* 2009;29:1193–1203.
  234. Godfrey ME, Messing B, Cohen SM, Valsky DV, Yagel S. Functional assessment of the fetal heart: a review. *Ultrasound Obstet Gynecol.* 2012;39:131–144.
  235. Roman KS, Fouron JC, Nii M, Smallhorn JF, Chaturvedi R, Jaeggi ET. Determinants of outcome in fetal pulmonary valve stenosis or atresia with intact ventricular septum. *Am J Cardiol.* 2007;99:699–703.
  236. McElhinney DB, Marshall AC, Wilkins-Haug LE, Brown DW, Benson CB, Silva V, Marx GR, Mizrahi-Arnaud A, Lock JE, Tworetzky W. Predictors of technical success and postnatal biventricular outcome after in utero aortic valvuloplasty for aortic stenosis with evolving hypoplastic left heart syndrome. *Circulation.* 2009;120:1482–1490.
  237. Moon-Grady AJ, Rand L, Gallardo S, Gosnell K, Lee H, Feldstein VA. Diastolic cardiac pathology and clinical twin-twin transfusion syndrome in monozygotic/diamniotic twins. *Am J Obstet Gynecol.* 2011;205:279.e1–279.e11.
  238. Tsyvian P, Malkin K, Wladimiroff JW. Assessment of mitral A-wave transit time to cardiac outflow tract and isovolumic relaxation time of left ventricle in the appropriate and small-for-gestational-age human fetus. *Ultrasound Med Biol.* 1997;23:187–190.
  239. Raboisson MJ, Fouron JC, Lamoureux J, Leduc L, Grignon A, Proulx F, Gamache S. Early intertwin differences in myocardial performance during the twin-to-twin transfusion syndrome. *Circulation.* 2004;110:3043–3048.
  240. Inamura N, Taketasu M, Smallhorn JF, Hornberger LK. Left ventricular myocardial performance in the fetus with severe tricuspid valve disease and tricuspid insufficiency. *Am J Perinatol.* 2005;22:91–97.
  241. Tsutsumi T, Ishii M, Eto G, Hota M, Kato H. Serial evaluation for myocardial performance in fetuses and neonates using a new Doppler index. *Pediatr Int.* 1999;41:722–727.
  242. Friedman D, Buyon J, Kim M, Glickstein JS. Fetal cardiac function assessed by Doppler myocardial performance index (Tei Index). *Ultrasound Obstet Gynecol.* 2003;21:33–36.
  243. Mori Y, Rice MJ, McDonald RW, Reller MD, Wanitkun S, Harada K, Sahn DJ. Evaluation of systolic and diastolic ventricular performance of the right ventricle in fetuses with ductal constriction using the Doppler Tei index. *Am J Cardiol.* 2001;88:1173–1178.
  244. Huhta JC, Paul JJ. Doppler in fetal heart failure. *Clin Obstet Gynecol.* 2010;53:915–929.
  245. Hofstaetter C, Hansmann M, Eik-Nes SH, Huhta JC, Luther SL. A cardiovascular profile score in the surveillance of fetal hydrops. *J Matern Fetal Neonatal Med.* 2006;19:407–413.
  246. Wieczorek A, Hernandez-Robles J, Ewing L, Leshko J, Luther S, Huhta J. Prediction of outcome of fetal congenital heart disease using a cardiovascular profile score. *Ultrasound Obstet Gynecol.* 2008;31:284–288.
  247. Itsukaichi M, Kikuchi A, Yoshihara K, Serikawa T, Takakuwa K, Tanaka K. Changes in fetal circulation associated with congenital heart disease and their effects on fetal growth. *Fetal Diagn Ther.* 2011;30:219–224.
  248. Donofrio MT, Bremer YA, Schieken RM, Gennings C, Morton LD, Eidem BW, Cetta F, Falkensammer CB, Huhta JC, Kleinman CS. Autoregulation of cerebral blood flow in fetuses with congenital heart disease: the brain sparing effect. *Pediatr Cardiol.* 2003;24:436–443.
  249. Kaltman JR, Di H, Tian Z, Rychik J. Impact of congenital heart disease on cerebrovascular blood flow dynamics in the fetus. *Ultrasound Obstet Gynecol.* 2005;25:32–36.
  250. Hornberger LK, Sahn DJ. Rhythm abnormalities of the fetus. *Heart.* 2007;93:1294–1300.
  251. Strasburger JF, Huhta JC, Carpenter RJ Jr, Garson A Jr, McNamara DG. Doppler echocardiography in the diagnosis and management of persistent fetal arrhythmias. *J Am Coll Cardiol.* 1986;7:1386–1391.
  252. Hornberger LK, Barrea C. Diagnosis, natural history, and outcome of fetal heart disease. *Semin Thorac Cardiovasc Surg Pediatr Card Surg Annu.* 2001;4:229–243.
  253. Hamill N, Yeo L, Romero R, Hassan SS, Myers SA, Mittal P, Kusanovic JP, Balasubramaniam M, Chaiworapongsa T, Vaisbuch E, Espinoza J, Gotsch F, Goncalves LF, Lee W. Fetal cardiac ventricular volume, cardiac output, and ejection fraction determined with 4-dimensional ultrasound using spatiotemporal image correlation and virtual organ computer-aided analysis. *Am J Obstet Gynecol.* 2011;205:76.e71–76.e10.
  254. Michailidis GD, Simpson JM, Karidas C, Economides DL. Detailed three-dimensional fetal echocardiography facilitated by an Internet link. *Ultrasound Obstet Gynecol.* 2001;18:325–328.
  255. Sklansky MS, Nelson TR, Pretorius DH. Three-dimensional fetal echocardiography: gated versus nongated techniques. *J Ultrasound Med.* 1998;17:451–457.
  256. Nelson TR, Pretorius DH, Sklansky M, Hagen-Ansert S. Three-dimensional echocardiographic evaluation of fetal heart anatomy and function: acquisition, analysis, and display. *J Ultrasound Med.* 1996;15:1–9; quiz 11–12.
  257. Deng J, Gardener JE, Rodeck CH, Lees WR. Fetal echocardiography in three and four dimensions. *Ultrasound Med Biol.* 1996;22:979–986.
  258. DeVore GR, Falkensammer P, Sklansky MS, Platt LD. Spatio-temporal image correlation (STIC): new technology for evaluation of the fetal heart. *Ultrasound Obstet Gynecol.* 2003;22:380–387.
  259. Goncalves LF, Lee W, Chaiworapongsa T, Espinoza J, Schoen ML, Falkensammer P, Treadwell M, Romero R. Four-dimensional ultrasonography of the fetal heart with spatiotemporal image correlation. *Am J Obstet Gynecol.* 2003;189:1792–1802.

260. Vinals F, Poblete P, Giuliano A. Spatio-temporal image correlation (STIC): a new tool for the prenatal screening of congenital heart defects. *Ultrasound Obstet Gynecol.* 2003;22:388–394.
261. Gindes L, Hegesh J, Weisz B, Gilboa Y, Achiron R. Three and four dimensional ultrasound: a novel method for evaluating fetal cardiac anomalies. *Prenat Diagn.* 2009;29:645–653.
262. Goncalves LF, Romero R, Espinoza J, Lee W, Treadwell M, Chintala K, Brandl H, Chaiworapongsa T. Four-dimensional ultrasonography of the fetal heart using color Doppler spatiotemporal image correlation. *J Ultrasound Med.* 2004;23:473–481.
263. Bhat AH, Corbett VN, Liu R, Carpenter ND, Liu NW, Wu AM, Hopkins GD, Li X, Sahn DJ. Validation of volume and mass assessments for human fetal heart imaging by 4-dimensional spatiotemporal image correlation echocardiography: in vitro balloon model experiments. *J Ultrasound Med.* 2004;23:1151–1159.
264. Bhat AH, Corbett V, Carpenter N, Liu N, Liu R, Wu A, Hopkins G, Sohaey R, Winkler C, Sahn CS, Sovinsky V, Li X, Sahn DJ. Fetal ventricular mass determination on three-dimensional echocardiography: studies in normal fetuses and validation experiments. *Circulation.* 2004;110:1054–1060.
265. Uittenbogaard LB, Haak MC, Tromp CH, Terwee CB, Van Vugt JM. Reliability of fetal cardiac volumetry using spatiotemporal image correlation: assessment of in-vivo and in-vitro measurements. *Ultrasound Obstet Gynecol.* 2010;36:308–314.
266. Messing B, Cohen SM, Valsky DV, Rosenak D, Hochner-Celnikier D, Savchev S, Yagel S. Fetal cardiac ventricle volumetry in the second half of gestation assessed by 4D ultrasound using STIC combined with inversion mode. *Ultrasound Obstet Gynecol.* 2007;30:142–151.
267. Sklansky MS, Nelson T, Strachan M, Pretorius D. Real-time three-dimensional fetal echocardiography: initial feasibility study. *J Ultrasound Med.* 1999;18:745–752.
268. Xiong Y, Wah YM, Chen M, Leung TY, Lau TK. Real-time three-dimensional echocardiography using a matrix probe with live xPlane imaging of the interventricular septum. *Ultrasound Obstet Gynecol.* 2009;34:534–537.
269. Acar P, Dulac Y, Taktak A, Abadir S. Real-time three-dimensional fetal echocardiography using matrix probe. *Prenat Diagn.* 2005;25:370–375.
270. Sklansky MS, DeVore GR, Wong PC. Real-time 3-dimensional fetal echocardiography with an instantaneous volume-rendered display: early description and pictorial essay. *J Ultrasound Med.* 2004;23:283–289.
271. Acar P, Laskari C, Rhodes J, Pandian N, Warner K, Marx G. Three-dimensional echocardiographic analysis of valve anatomy as a determinant of mitral regurgitation after surgery for atrioventricular septal defects. *Am J Cardiol.* 1999;83:745–749.
272. Marx GR, Fulton DR, Pandian NG, Vogel M, Cao QL, Ludomirsky A, Delabays A, Sugeng L, Klas B. Delineation of site, relative size and dynamic geometry of atrial septal defects by real-time three-dimensional echocardiography. *J Am Coll Cardiol.* 1995;25:482–490.
273. Sklansky M, Miller D, Devore G, Kung G, Pretorius D, Wong P, Chang RK. Prenatal screening for congenital heart disease using real-time three-dimensional echocardiography and a novel “sweep volume” acquisition technique. *Ultrasound Obstet Gynecol.* 2005;25:435–443.
274. Lang RM, Badano LP, Tsang W, Adams DH, Agricola E, Buck T, Faletta FF, Franke A, Hung J, de Isla LP, Kamp O, Kasprzak JD, Lancellotti P, Marwick TH, McCulloch ML, Monaghan MJ, Nihoyannopoulos P, Pandian NG, Pellikka PA, Pepi M, Roberson DA, Sherman SK, Shirali GS, Sugeng L, Ten Cate FJ, Vannan MA, Zamorano JL, Zoghbi WA; American Society of Echocardiography; European Association of Echocardiography. EAE/ASE recommendations for image acquisition and display using three-dimensional echocardiography. *J Am Soc Echocardiogr.* 2011;25:3–46.
275. Chaoui R, Hoffmann J, Heling KS. Three-dimensional (3D) and 4D color Doppler fetal echocardiography using spatio-temporal image correlation (STIC). *Ultrasound Obstet Gynecol.* 2004;23:535–545.
276. Goncalves LF, Espinoza J, Romero R, Kusanovic JP, Swowe B, Nien JK, Erez O, Soto E, Treadwell MC. Four-dimensional ultrasonography of the fetal heart using a novel tomographic ultrasound imaging display. *J Perinat Med.* 2006;34:39–55.
277. Devore GR, Polanko B. Tomographic ultrasound imaging of the fetal heart: a new technique for identifying normal and abnormal cardiac anatomy. *J Ultrasound Med.* 2005;24:1685–1696.
278. Abuhamad A, Falkensammer P, Zhao Y. Automated sonography: defining the spatial relationship of standard diagnostic fetal cardiac planes in the second trimester of pregnancy. *J Ultrasound Med.* 2007;26:501–507.
279. Abuhamad A, Falkensammer P, Reichartseder F, Zhao Y. Automated retrieval of standard diagnostic fetal cardiac ultrasound planes in the second trimester of pregnancy: a prospective evaluation of software. *Ultrasound Obstet Gynecol.* 2008;31:30–36.
280. Uittenbogaard LB, Haak MC, van Vugt JM. Feasibility of automated 3-dimensional fetal cardiac screening in routine ultrasound practice. *J Ultrasound Med.* 2009;28:881–888.
281. Tutschek B, Sahn DJ. Semi-automatic segmentation of fetal cardiac cavities: progress towards an automated fetal echocardiogram. *Ultrasound Obstet Gynecol.* 2008;32:176–180.
282. Rizzo G, Capponi A, Cavicchioni O, Vendola M, Pietrolucci ME, Arzuini D. Application of automated sonography on 4-dimensional volumes of fetuses with transposition of the great arteries. *J Ultrasound Med.* 2008;27:771–776; quiz 777.
283. Yagel S, Benachi A, Bonnet D, Dumez Y, Hochner-Celnikier D, Cohen SM, Valsky DV, Ferment L, Rendinger in fetal cardiac scanning: the intracardiac septa and the coronal atrioventricular valve planes. *Ultrasound Obstet Gynecol.* 2006;28:266–274.
284. Chaoui R, Heling KS. New developments in fetal heart scanning: Three and four-dimensional fetal echocardiography. *Seminars in Fetal and Neonatal Med.* 2005;10:567–577.
285. Adriaanse BM, Tromp CH, Simpson JM, Van Mieghem T, Kist WJ, Kuik DJ, Oepkes D, Van Vugt JM, Haak MC. Interobserver agreement in detailed prenatal diagnosis of congenital heart disease by telemedicine using four-dimensional ultrasound with spatiotemporal image correlation. *Ultrasound Obstet Gynecol.* 2012;39:203–209.
286. Kivelitz DE, Muhler M, Rake A, Scheer I, Chaoui R. MRI of cardiac rhabdomyoma in the fetus. *Eur Radiol.* 2004;14:1513–1516.
287. Fogel MA, Wilson RD, Flake A, Johnson M, Cohen D, McNeal G, Tian ZY, Rychik J. Preliminary investigations into a new method of functional assessment of the fetal heart using a novel application of “real-time” cardiac magnetic resonance imaging. *Fetal Diagn Ther.* 2005;20:475–480.
288. Gorincour G, Bourliere-Najean B, Bonello B, Fraisee A, Philip N, Potier A, Kreitmann B, Petit P. Feasibility of fetal cardiac magnetic resonance imaging: preliminary experience. *Ultrasound Obstet Gynecol.* 2007;29:105–108.
289. Manganaro L, Savelli S, Di Maurizio M, Perrone A, Tesei J, Francioso A, Angeletti M, Coratella F, Irimia D, Fierro F, Ventriglia F, Ballesio L. Potential role of fetal cardiac evaluation with magnetic resonance imaging: preliminary experience. *Prenat Diagn.* 2008;28:148–156.
290. Saleem SN. Feasibility of MRI of the fetal heart with balanced steady-state free precession sequence along fetal body and cardiac planes. *Am J Roentgenol.* 2008;191:1208–1215.
291. Manganaro L, Savelli S, Di Maurizio M, Perrone A, Francioso A, La Barbera L, Totaro P, Fierro F, Tomei A, Coratella F, Giaccotti A, Ballesio L, Ventriglia F. Assessment of congenital heart disease (CHD): is there a role for fetal magnetic resonance imaging (MRI)? *Eur J Radiol.* 2009;72:172–180.
292. Yamamura J, Schnackenburg B, Kooijmann H, Frisch M, Hecher K, Adam G, Wedegartner U. High resolution MR imaging of the fetal heart with cardiac triggering: a feasibility study in the sheep fetus. *Eur Radiol.* 2009;19:2383–2390.
293. Jansz MS, Seed M, van Amerom JF, Wong D, Grosse-Wortmann L, Yoo SJ, Macgowan CK. Metric optimized gating for fetal cardiac MRI. *Magn Reson Med.* 2010;64:1304–1314.
294. Nemeč SF, Brugger PC, Nemeč U, Bettelheim D, Kasprjan G, Amann G, Rimoin DL, Graham JM Jr, Prayer D. Situs anomalies on prenatal MRI. *Eur J Radiol.* 2011;81:e495–e501.
295. Michel SC, Rake A, Keller TM, Huch R, König V, Seifert B, Marinček B, Kubik-Huch RA. Original report: fetal cardiographic monitoring during 1.5-T MR imaging. *AJR Am J Roentgenol.* 2003;180:1159–1164.
296. Baker PN, Johnson IR, Harvey PR, Gowland PA, Mansfield P. A three-year follow-up of children imaged in utero with echo-planar magnetic resonance. *Am J Obstet Gynecol.* 1994;170(pt 1):32–33.
297. Nagueh SF, Appleton CP, Gillebert TC, Marino PN, Oh JK, Smiseth OA, Waggoner AD, Flachskampf FA, Pellikka PA, Evangelista A. Recommendations for the evaluation of left ventricular diastolic function by echocardiography. *J Am Soc Echocardiogr.* 2009;22:107–133.
298. Harada K, Tsuda A, Orino T, Tanaka T, Takada G. Tissue Doppler imaging in the normal fetus. *Int J Cardiol.* 1999;71:227–234.
299. Tutschek B, Zimmermann T, Buck T, Bender HG. Fetal tissue Doppler echocardiography: detection rates of cardiac structures and quantitative assessment of the fetal heart. *Ultrasound Obstet Gynecol.* 2003;21:26–32.
300. Comas M, Crispi F, Gomez O, Puerto B, Figueras F, Gratacos E. Gestational age- and estimated fetal weight-adjusted reference ranges for myocardial tissue Doppler indices at 24–41 weeks’ gestation. *Ultrasound Obstet Gynecol.* 2011;37:57–64.



301. Comas M, Crispi F, Cruz-Martinez R, Martinez JM, Figueras F, Gratacos E. Usefulness of myocardial tissue Doppler vs conventional echocardiography in the evaluation of cardiac dysfunction in early-onset intrauterine growth restriction. *Am J Obstet Gynecol*. 2010;203:45.e1–45.e7.
302. Hatem MA, Zielinsky P, Hatem DM, Niccoloso LH, Manica JL, Piccoli AL, Zanettini J, Oliveira V, Scarpa F, Petracco R. Assessment of diastolic ventricular function in fetuses of diabetic mothers using tissue Doppler. *Cardiol Young*. 2008;18:297–302.
303. Di Naro E, Cromi A, Ghezzi F, Giocolano A, Caringella A, Loverro G. Myocardial dysfunction in fetuses exposed to intraamniotic infection: new insights from tissue Doppler and strain imaging. *Am J Obstet Gynecol*. 2010;203:459e1–459.e7.
304. Divanovic A, Cnota J, Ittenbach R, Tan X, Border W, Crombleholme T, Michelfelder E. Characterization of diastolic dysfunction in twin-twin transfusion syndrome: association between Doppler findings and ventricular hypertrophy. *J Am Soc Echocardiogr*. 2011;24:834–840.
305. Vyas HV, Eidem BW, Cetta F, Acharya G, Huhta J, Roberson D, Cuneo B. Myocardial tissue Doppler velocities in fetuses with hypoplastic left heart syndrome. *Ann Pediatr Card*. 2011;4:129–134.
306. Aoki M, Harada K, Ogawa M, Tanaka T. Quantitative assessment of right ventricular function using doppler tissue imaging in fetuses with and without heart failure. *J Am Soc Echocardiogr*. 2004;17:28–35.
307. Rein AJ, O'Donnell C, Geva T, Nir A, Perles Z, Hashimoto I, Li XK, Sahn DJ. Use of tissue velocity imaging in the diagnosis of fetal cardiac arrhythmias. *Circulation*. 2002;106:1827–1833.
308. Di Salvo G, Russo MG, Paladini D, Pacileo G, Felicetti M, Ricci C, Cardaropoli D, Palma M, Caso P, Calabro R. Quantification of regional left and right ventricular longitudinal function in 75 normal fetuses using ultrasound-based strain rate and strain imaging. *Ultrasound Med Biol*. 2005;31:1159–1162.
309. Perles Z, Nir A, Gavri S, Rein AJ. Assessment of fetal myocardial performance using myocardial deformation analysis. *Am J Cardiol*. 2007;99:993–996.
310. Di Salvo G, Russo MG, Paladini D, Felicetti M, Castaldi B, Tartaglione A, di Pietto L, Ricci C, Morelli C, Pacileo G, Calabro R. Two-dimensional strain to assess regional left and right ventricular longitudinal function in 100 normal fetuses. *Eur J Echocardiogr*. 2008;9:754–756.
311. Ta-Shma A, Perles Z, Gavri S, Golender J, Tarshansky S, Shlichter C, Bar Tov H, Rein AJ. Analysis of segmental and global function of the fetal heart using novel automatic functional imaging. *J Am Soc Echocardiogr*. 2008;21:146–150.
312. Younoszai AK, Saudek DE, Emery SP, Thomas JD. Evaluation of myocardial mechanics in the fetus by velocity vector imaging. *J Am Soc Echocardiogr*. 2008;21:470–474.
313. Barker PC, Houle H, Li JS, Miller S, Herlong JR, Camitta MG. Global longitudinal cardiac strain and strain rate for assessment of fetal cardiac function: novel experience with velocity vector imaging. *Echocardiography*. 2009;26:28–36.
314. Peng QH, Zhou QC, Zeng S, Tian LQ, Zhang M, Tan Y, Pu DR. Evaluation of regional left ventricular longitudinal function in 151 normal fetuses using velocity vector imaging. *Prenat Diagn*. 2009;29:1149–1155.
315. Pu DR, Zhou QC, Zhang M, Peng QH, Zeng S, Xu GQ. Assessment of regional right ventricular longitudinal functions in fetus using velocity vector imaging technology. *Prenat Diagn*. 2010;30:1057–1063.
316. Matsui H, Germanakis I, Kulinskaya E, Gardiner HM. Temporal and spatial performance of vector velocity imaging in the human fetal heart. *Ultrasound Obstet Gynecol*. 2010;37:150–157.
317. Willruth AM, Geipel AK, Berg CT, Fimmers R, Gembruch UG. Comparison of global and regional right and left ventricular longitudinal peak systolic strain, strain rate and velocity in healthy fetuses using a novel feature tracking technique. *J Perinat Med*. 2011;39:549–556.
318. Ishii T, McElhinney DB, Harrild DM, Marcus EN, Sahn DJ, Truong U, Tworetzky W. Circumferential and longitudinal ventricular strain in the normal human fetus. *J Am Soc Echocardiogr*. 2011;25:105–111.
319. Crispi F, Sepulveda-Swatson E, Cruz-Lemini M, Rojas-Benavente J, Garcia-Posada R, Dominguez JM, Sitges M, Bijmens B, Gratacos E. Feasibility and reproducibility of a standard protocol for 2D speckle tracking and tissue doppler-based strain and strain rate analysis of the fetal heart. *Fetal Diagn Ther*. 2012;32:96–108.
320. Mor-Avi V, Lang RM, Badano LP, Belohlavek M, Cardim NM, Derumeaux G, Galderisi M, Marwick T, Nagueh SF, Sengupta PP, Sicari R, Smiseth OA, Smulevitz B, Takeuchi M, Thomas JD, Vannan M, Voigt JU, Zamorano JL. Current and evolving echocardiographic techniques for the quantitative evaluation of cardiac mechanics: ASE/EAE consensus statement on methodology and indications endorsed by the Japanese Society of Echocardiography. *J Am Soc Echocardiogr*. 2011;24:277–313.
321. Gayat E, Ahmad H, Weinert L, Lang RM, Mor-Avi V. Reproducibility and inter-vendor variability of left ventricular deformation measurements by three-dimensional speckle-tracking echocardiography. *J Am Soc Echocardiogr*. 2011;24:878–885.
322. Lorch SM, Ludomirsky A, Singh GK. Maturation and growth-related changes in left ventricular longitudinal strain and strain rate measured by two-dimensional speckle tracking echocardiography in healthy pediatric population. *J Am Soc Echocardiogr*. 2008;21:1207–1215.
323. Koopman LP, Slorach C, Hui W, Manlhiot C, McCrindle BW, Friedberg MK, Jaeggi ET, Mertens L. Comparison between different speckle tracking and color tissue Doppler techniques to measure global and regional myocardial deformation in children. *J Am Soc Echocardiogr*. 2010;23:919–928.
324. Koopman LP, Slorach C, Manlhiot C, McCrindle BW, Jaeggi ET, Mertens L, Friedberg MK. Assessment of myocardial deformation in children using digital imaging and communications in medicine (DICOM) data and vendor independent speckle tracking software. *J Am Soc Echocardiogr*. 2010;24:37–44.
325. Cuneo BF, Strasburger JF, Niksch A, Ovadia M, Wakai RT. An expanded phenotype of maternal SSA/SSB antibody-associated fetal cardiac disease. *J Matern Fetal Neonatal Med*. 2009;22:233–238.
326. Cuneo BF, Strasburger JF, Wakai RT. Magnetocardiography in the evaluation of fetuses at risk for sudden cardiac death before birth. *J Electrocardiol*. 2008;41:116.e1–116.e6.
327. Hall CM, Ward Platt MP. Neonatal flecainide toxicity following supraventricular tachycardia treatment. *Ann Pharmacother*. 2003;37:1343–1344.
328. Menendez T, Achenbach S, Beinder E, Hofbeck M, Klinghammer L, Singer H, Moshage W, Daniel WG. Usefulness of magnetocardiography for the investigation of fetal arrhythmias. *Am J Cardiol*. 2001;88:334–336.
329. Strasburger JF, Wakai RT. Fetal cardiac arrhythmia detection and in utero therapy. *Nat Rev Cardiol*. 2010;7:277–290.
330. Zhao H, Cuneo BF, Strasburger JF, Huhta JC, Gotteiner NL, Wakai RT. Electrophysiological characteristics of fetal atrioventricular block. *J Am Coll Cardiol*. 2008;51:77–84.
331. Zhao H, Strasburger JF, Cuneo BF, Wakai RT. Fetal cardiac repolarization abnormalities. *Am J Cardiol*. 2006;98:491–496.
332. Gardiner HM, Belmar C, Pasquini L, Seale A, Thomas M, Dennes W, Taylor MJ, Kulinskaya E, Wimalasundera R. Fetal ECG: a novel predictor of atrioventricular block in anti-Ro positive pregnancies. *Heart*. 2007;93:1454–1460.
333. Pasquini L, Seale AN, Belmar C, Oseku-Afful S, Thomas MJ, Taylor MJ, Roughton M, Gardiner HM. PR interval: a comparison of electrical and mechanical methods in the fetus. *Early Hum Dev*. 2007;83:231–237.
334. Westerhuis ME, Visser GH, Moons KG, van Beek E, Benders MJ, Bijvoet SM, van Dessel HJ, Drogtop AP, van Geijn HP, Graziosi GC, Groenendaal F, van Lith JM, Nijhuis JG, Oei SG, Oosterbaan HP, Porath MM, Rijnders RJ, Schuitemaker NW, Sopacua LM, van der Tweel I, Wijnenberger LD, Willekes C, Zuihthoff NP, Mol BW, Kwee A. Cardiotocography plus ST analysis of fetal electrocardiogram compared with cardiotocography only for intrapartum monitoring: a randomized controlled trial. *Obstet Gynecol*. 2010;115:1173–1180.
335. Devoe LD. Fetal ECG analysis for intrapartum electronic fetal monitoring: a review. *Clin Obstet Gynecol*. 2011;54:56–65.
336. Velayo C, Sato N, Ito T, Chisaka H, Yaegashi N, Okamura K, Kimura Y. Understanding congenital heart defects through abdominal fetal electrocardiography: case reports and clinical implications. *J Obstet Gynaecol Res*. 2011;37:428–435.
337. Amer-Wahlin I, Hellsten C, Noren H, Hagberg H, Herbst A, Kjellmer I, Lilja H, Lindoff C, Mansson M, Martensson L, Olofsson P, Sundstrom A, Marsal K. Cardiotocography only versus cardiotocography plus ST analysis of fetal electrocardiogram for intrapartum fetal monitoring: a Swedish randomised controlled trial. *Lancet*. 2001;358:534–538.
338. Ojala K, Vaarasmaki M, Makikallio K, Valkama M, Tekay A. A comparison of intrapartum automated fetal electrocardiography and conventional cardiotocography: a randomised controlled study. *BJOG*. 2006;113:419–423.
339. Mensah-Brown NA, Wakai RT, Cheulkar B, Srinivasan S, Strasburger JF. Assessment of left ventricular pre-ejection period in the fetus using simultaneous magnetocardiography and echocardiography. *Fetal Diagn Ther*. 2010;28:167–174.
340. Leuthold A, Wakai RT, Martin CB. Noninvasive in utero assessment of PR and QRS intervals from the fetal magnetocardiogram. *Early Hum Dev*. 1999;54:235–243.



341. Stinstra J, Golbach E, van Leeuwen P, Lange S, Menendez T, Moshage W, Schlessner E, Kaehler C, Horigome H, Shigemitsu S, Peters MJ. Multicentre study of fetal cardiac time intervals using magnetocardiography. *BJOG*. 2002;109:1235–1243.
342. van Leeuwen P, Lange S, Klein A, Geue D, Zhang Y, Krause HJ, Gronemeyer D. Reproducibility and reliability of fetal cardiac time intervals using magnetocardiography. *Physiol Meas*. 2004;25:539–552.
343. Lowery CL, Campbell JQ, Wilson JD, Murphy P, Preissl H, Malak SF, Eswaran H. Noninvasive antepartum recording of fetal S-T segment with a newly developed 151-channel magnetic sensor system. *Am J Obstet Gynecol*. 2003;188:1491–1496.
344. Comani S, Alleva G. Fetal cardiac time intervals estimated on fetal magnetocardiograms: single cycle analysis versus average beat inspection. *Physiol Meas*. 2007;28:49–60.
345. Horigome H, Takahashi MI, Asaka M, Shigemitsu S, Kandori A, Tsukada K. Magnetocardiographic determination of the developmental changes in PQ, QRS and QT intervals in the foetus. *Acta Paediatr*. 2000;89:64–67.
346. Kato Y, Takahashi-Igari M, Inaba T, Sumazaki R, Horigome H. Comparison of PR intervals determined by fetal magnetocardiography and pulsed Doppler echocardiography. *Fetal Diagn Ther*. 2012;32:109–115.
347. Wakai RT, Wang M, Leuthold AC, Martin CB. Foetal magnetocardiogram amplitude oscillations associated with respiratory sinus arrhythmia. *Physiol Meas*. 1995;16:49–54.
348. Cuneo BF, Ovadia M, Strasburger JF, Zhao H, Petropulos T, Schneider J, Wakai RT. Prenatal diagnosis and in utero treatment of torsades de pointes associated with congenital long QT syndrome. *Am J Cardiol*. 2003;91:1395–1398.
349. Hosono T, Shinto M, Chiba Y, Kandori A, Tsukada K. Prenatal diagnosis of fetal complete atrioventricular block with QT prolongation and alternating ventricular pacemakers using multi-channel magnetocardiography and current-arrow maps. *Fetal Diagn Ther*. 2002;17:173–176.
350. Li Z, Strasburger JF, Cuneo BF, Gotteiner NL, Wakai RT. Giant fetal magnetocardiogram P waves in congenital atrioventricular block: a marker of cardiovascular compensation? *Circulation*. 2004;110:2097–2101.
351. Wakai RT, Strasburger JF, Li Z, Deal BJ, Gotteiner NL. Magnetocardiographic rhythm patterns at initiation and termination of fetal supraventricular tachycardia. *Circulation*. 2003;107:307–312.
352. Kahler C, Grimm B, Schlessner E, Schneider A, Schneider U, Nowak H, Vogt L, Seewald HJ. The application of fetal magnetocardiography (FMCG) to investigate fetal arrhythmias and congenital heart defects (CHD). *Prenat Diagn*. 2001;21:176–182.
353. Cuneo BF, Zhao H, Strasburger JF, Ovadia M, Huhta JC, Wakai RT. Atrial and ventricular rate response and patterns of heart rate acceleration during maternal-fetal terbutaline treatment of fetal complete heart block. *Am J Cardiol*. 2007;100:661–665.
354. Wakai RT, Wang M, Martin CB. Spatiotemporal properties of the fetal magnetocardiogram. *Am J Obstet Gynecol*. 1994;170:770–776.
355. Crowe JA, Herbert JM, Huang XB, Reed N, Wolfson MS, Rassi D, Zhuravlev YE, Emery SJ. Sequential recording of the abdominal fetal electrocardiogram and magnetocardiogram. *Physiol Meas*. 1995;16:43–47.
356. Ferencz C, Neill CA, Boughman JA, Rubin JD, Brenner JL, Perry LW. Congenital cardiovascular malformations associated with chromosome abnormalities: an epidemiologic study. *J Pediatr*. 1989;114:79–86.
357. Paladini D, Calabro R, Palmieri S, D'Andrea T. Prenatal diagnosis of congenital heart disease and fetal karyotyping. *Obstet Gynecol*. 1993;81(pt 1):679–682.
358. Copel JA, Cullen M, Green JJ, Mahoney MJ, Hobbins JC, Kleinman CS. The frequency of aneuploidy in prenatally diagnosed congenital heart disease: an indication for fetal karyotyping. *Am J Obstet Gynecol*. 1988;158:409–413.
359. Respondek ML, Binotto CN, Smith S, Donnenfeld A, Weil SR, Huhta JC. Extracardiac anomalies, aneuploidy and growth retardation in 100 consecutive fetal congenital heart defects. *Ultrasound Obstet Gynecol*. 1994;4:272–278.
360. Paladini D, Tartaglione A, Agangi A, Teodoro A, Forleo F, Borghese A, Martinelli P. The association between congenital heart disease and Down syndrome in prenatal life. *Ultrasound Obstet Gynecol*. 2000;15:104–108.
361. Paladini D, Russo M, Teodoro A, Pacileo G, Capozzi G, Martinelli P, Nappi C, Calabro R. Prenatal diagnosis of congenital heart disease in the Naples area during the years 1994–1999: the experience of a joint fetal-pediatric cardiology unit. *Prenat Diagn*. 2002;22:545–552.
362. Berg KA, Clark EB, Astemborski JA, Boughman JA. Prenatal detection of cardiovascular malformations by echocardiography: an indication for cytogenetic evaluation. *Am J Obstet Gynecol*. 1988;159:477–481.
363. Hajdu J, Beke A, Pete B, Orosz NJ, Papp Z. Prenatal diagnosis of the atrioventricular septal defect and its effect on the outcome of the pregnancies [in Hungarian]. *Orv Hetil*. 2005;146:1775–1780.
364. Surerus E, Huggon IC, Allan LD. Turner's syndrome in fetal life. *Ultrasound Obstet Gynecol*. 2003;22:264–267.
365. Allan LD, Sharland GK. Prognosis in fetal tetralogy of Fallot. *Pediatr Cardiol*. 1992;13:1–4.
366. Benn P, Borell A, Chiu R, Cuckle H, Dugoff L, Faas B, Gross S, Johnson J, Maymon R, Norton M, Odibo A, Schielen P, Spencer K, Huang T, Wright D, Yaron Y. Position statement from the Aneuploidy Screening Committee on behalf of the board of the International Society for Prenatal Diagnosis. *Prenat Diagn*. 2013;33:622–629.
367. Jensen TJ, Dzakula Z, Deciu C, van den Boom D, Ehrich M. Detection of microdeletion 22q11.2 in a fetus by next-generation sequencing of maternal plasma. *Clin Chem*. 2012;58:1148–1151.
368. Srinivasan A, Bianchi DW, Huang H, Sehert AJ, Rava RP. Noninvasive detection of fetal subchromosome abnormalities via deep sequencing of maternal plasma. *Am J Hum Genet*. 2013;92:167–176.
369. Xu ZF, Cao L, Ji XQ, Yang C, Zhang JJ, Xu QJ, Zha W, Yang YQ, Lin YS, Chen CH, Liu A, Li L, Lin Y, Yi L. Prenatal genetic study of fetuses with congenital heart diseases [in Chinese]. *Zhonghua Yi Xue Yi Chuan Xue Za Zhi*. 2009;26:128–133.
370. Bellucco FT, Belangero SI, Farah LM, Machado MV, Cruz AP, Lopes LM, Lopes MA, Zugaib M, Cernach MC, Melaragno MI. Investigating 22q11.2 deletion and other chromosomal aberrations in fetuses with heart defects detected by prenatal echocardiography. *Pediatr Cardiol*. 2010;31:1146–1150.
371. Hillman SC, Pretlove S, Coomarasamy A, McMullan DJ, Davison EV, Maher ER, Kilby MD. Additional information from array comparative genomic hybridization technology over conventional karyotyping in prenatal diagnosis: a systematic review and meta-analysis. *Ultrasound Obstet Gynecol*. 2011;37:6–14.
372. Bui TH, Vetro A, Zuffardi O, Shaffer LG. Current controversies in prenatal diagnosis 3: is conventional chromosome analysis necessary in the post-array CGH era? *Prenat Diagn*. 2011;31:235–243.
373. Fiorentino F, Caiazzo F, Napolitano S, Spizzichino L, Bono S, Sessa M, Nuccielli A, Biricik A, Gordon A, Rizzo G, Baldi M. Introducing array comparative genomic hybridization into routine prenatal diagnosis practice: a prospective study on over 1000 consecutive clinical cases. *Prenat Diagn*. 2011;31:1270–1282.
374. ACOG Committee Opinion No. 446: array comparative genomic hybridization in prenatal diagnosis. *Obstet Gynecol*. 2009;114:1161–1163.
375. Baldassarre G, Mussa A, Dotta A, Banaudi E, Forzano S, Marinosci A, Rossi C, Tartaglia M, Silengo M, Ferrero GB. Prenatal features of Noonan syndrome: prevalence and prognostic value. *Prenat Diagn*. 2011;31:949–954.
376. Palomaki GE, Kloza EM, Lambert-Messerlian GM, Haddow JE, Neveux LM, Ehrich M, van den Boom D, Bombard AT, Deciu C, Grody WW, Nelson SF, Canick JA. DNA sequencing of maternal plasma to detect Down syndrome: an international clinical validation study. *Genet Med*. 2011;13:913–920.
377. Palomaki GE, Deciu C, Kloza EM, Lambert-Messerlian GM, Haddow JE, Neveux LM, Ehrich M, van den Boom D, Bombard AT, Grody WW, Nelson SF, Canick JA. DNA sequencing of maternal plasma reliably identifies trisomy 18 and trisomy 13 as well as Down syndrome: an international collaborative study. *Genet Med*. 2012;14:296–305.
378. Verweij EJ, van den Oever JM, de Boer MA, Boon EM, Oepkes D. Diagnostic accuracy of noninvasive detection of fetal trisomy 21 in maternal blood: a systematic review. *Fetal Diagn Ther*. 2012;31:81–86.
379. van den Oever JM, Balkassmi S, Verweij EJ, van Itersom M, Adama van Scheltema PN, Oepkes D, van Lith JM, Hoffer MJ, den Dunnen JT, Bakker E, Boon EM. Single molecule sequencing of free DNA from maternal plasma for noninvasive trisomy 21 detection. *Clin Chem*. 2012;58:699–706.
380. Wimalasundera RC, Gardiner HM. Congenital heart disease and aneuploidy. *Prenat Diagn*. 2004;24:1116–1122.
381. Chaoui R, Korner H, Bommer C, Goldner B, Bierlich A, Bollmann R. Prenatal diagnosis of heart defects and associated chromosomal aberrations [in German]. *Ultraschall Med*. 1999;20:177–184.
382. Paladini D, Rustico M, Todros T, Palmieri S, Gaglioti P, Benettoni A, Russo MG, Chiappa E, D'Ottavio G. Conotruncal anomalies in prenatal life. *Ultrasound Obstet Gynecol*. 1996;8:241–246.
383. Fesslova V, Villa L, Nava S, Boschetto C, Redaelli C, Mannarino S. Spectrum and outcome of atrioventricular septal defect in fetal life. *Cardiol Young*. 2002;12:18–26.

384. Poon LC, Huggon IC, Zidere V, Allan LD. Tetralogy of Fallot in the fetus in the current era. *Ultrasound Obstet Gynecol.* 2007;29:625–627.
385. Volpe P, Paladini D, Marasini M, Buonadonna AL, Russo MG, Caruso G, Marzullo A, Vassallo M, Martinelli P, Gentile M. Common arterial trunk in the fetus: characteristics, associations, and outcome in a multicentre series of 23 cases. *Heart.* 2003;89:1437–1441.
386. Volpe P, Paladini D, Marasini M, Buonadonna AL, Russo MG, Caruso G, Marzullo A, Arciprete P, Martinelli P, Gentile M. Characteristics, associations and outcome of absent pulmonary valve syndrome in the fetus. *Ultrasound Obstet Gynecol.* 2004;24:623–628.
387. Vesel S, Rollings S, Jones A, Callaghan N, Simpson J, Sharland GK. Prenatally diagnosed pulmonary atresia with ventricular septal defect: echocardiography, genetics, associated anomalies and outcome. *Heart.* 2006;92:1501–1505.
388. Zidere V, Tsapakis EG, Huggon IC, Allan LD. Right aortic arch in the fetus. *Ultrasound Obstet Gynecol.* 2006;28:876–881.
389. Ferencz C, Neill CA, Boughman JA, Rubin JD, Brenner JI, Perry LW. Congenital cardiovascular malformations associated with chromosome abnormalities: an epidemiologic study. *J Pediatr.* 1989;114:79–86.
390. Paladini D, Volpe P, Marasini M, Russo MG, Vassallo M, Gentile M, Calabro R. Diagnosis, characterization and outcome of congenitally corrected transposition of the great arteries in the fetus: a multicenter series of 30 cases. *Ultrasound Obstet Gynecol.* 2006;27:281–285.
391. McBride KL, Ware SM. Modifying Mendel: approaches for identification of susceptibility alleles for human cardiovascular malformations. *Circ Cardiovasc Genet.* 2012;5:274–276.
392. American College of Obstetricians and Gynecologists. ACOG Practice Bulletin No. 101: ultrasonography in pregnancy. *Obstet Gynecol.* 2009;113(pt 1):451–461.
393. Medicine SImF. White Paper on Ultrasound Code 76811. 2009. <https://old.smfm.org/attachedfiles/UltrasoundCode76811Revised-Dec272012.pdf>. Accessed March 12, 2014.
394. Glenn OA. MR imaging of the fetal brain. *Pediatr Radiol.* 2010;40:68–81.
395. Limperopoulos C, Tworetzky W, McElhinney DB, Newburger JW, Brown DW, Robertson RL Jr, Guizard N, McGrath E, Geva J, Anness D, Dunbar-Masterson C, Trainor B, Laussen PC, du Plessis AJ. Brain volume and metabolism in fetuses with congenital heart disease: evaluation with quantitative magnetic resonance imaging and spectroscopy. *Circulation.* 2010;121:26–33.
396. Coakley FV, Lopoo JB, Lu Y, Hricak H, Albanese CT, Harrison MR, Filly RA. Normal and hypoplastic fetal lungs: volumetric assessment with prenatal single-shot rapid acquisition with relaxation enhancement MR imaging. *Radiology.* 2000;216:107–111.
397. Gorinour G, Bouvenot J, Mourot MG, Sonigo P, Chaumoitre K, Garel C, Guibaud L, Rypens F, Avni F, Cassart M, Maugey-Laulom B, Bourliere-Najeau B, Brunelle F, Durand C, Eurin D; Groupe Radiopédiatrique de Recherche en Imagerie Foetale (GRRIF). Prenatal prognosis of congenital diaphragmatic hernia using magnetic resonance imaging measurement of fetal lung volume. *Ultrasound Obstet Gynecol.* 2005;26:738–744.
398. Nathan AT, Marino BS, Dominguez T, Tabbutt S, Nicolson S, Donaghue DD, Spray TL, Rychik J. Tricuspid valve dysplasia with severe tricuspid regurgitation: fetal pulmonary artery size predicts lung viability in the presence of small lung volumes. *Fetal Diagn Ther.* 2010;27:101–105.
399. ACOG practice bulletin: antepartum fetal surveillance: Number 9, October 1999 (replaces Technical Bulletin Number 188, January 1994): clinical management guidelines for obstetrician-gynecologists. *Int J Gynaecol Obstet.* 2000;68:175–185.
400. Grant A, Elbourne D, Valentin L, Alexander S. Routine formal fetal movement counting and risk of antepartum late death in normally formed singletons. *Lancet.* 1989;2:345–349.
401. O'Neill E, Thorp J. Antepartum evaluation of the fetus and fetal well being. *Clin Obstet Gynecol.* 2012;55:722–730.
402. Freeman RK, Anderson G, Dorchester W. A prospective multi-institutional study of antepartum fetal heart rate monitoring, I: risk of perinatal mortality and morbidity according to antepartum fetal heart rate test results. *Am J Obstet Gynecol.* 1982;143:771–777.
403. Manning FA. Fetal biophysical profile: a critical appraisal. *Clin Obstet Gynecol.* 2002;45:975–985.
404. Lalor JG, Fawole B, Alfirevic Z, Devane D. Biophysical profile for fetal assessment in high risk pregnancies. *Cochrane Database Syst Rev.* 2008;CD000038.
405. Allan LD, Huggon IC. Counselling following a diagnosis of congenital heart disease. *Prenat Diagn.* 2004;24:1136–1142.
406. Yeu BK, Chalmers R, Shekleton P, Grimwade J, Menaheem S. Fetal cardiac diagnosis and its influence on the pregnancy and newborn: a tertiary centre experience. *Fetal Diagn Ther.* 2008;24:241–245.
407. Chervenak FA, McCullough LB, Brent RL. The perils of the imperfect expectation of the perfect baby. *Am J Obstet Gynecol.* 2010;203:101.e1–101.e5.
408. Menaheem S, Grimwade J. Counselling strategies in the prenatal diagnosis of major heart abnormality. *Heart Lung Circ.* 2004;13:261–265.
409. Menaheem S, Grimwade J. Effective counselling of pre-natal diagnosis of serious heart disease—an aid to maternal bonding? *Fetal Diagn Ther.* 2004;19:470–474.
410. Menaheem S, Grimwade J. Pre-natal counselling: helping couples make decisions following the diagnosis of severe heart disease. *Early Hum Dev.* 2005;81:601–607.
411. Zybiewski SC, Hill EG, Shirali G, Atz A, Forbus G, Gonzalez J, Hlavacek A. Chromosomal anomalies influence parental treatment decisions in relation to prenatally diagnosed congenital heart disease. *Pediatr Cardiol.* 2009;30:1105–1111.
412. Rasiah SV, Ewer AK, Miller P, Wright JG, Barron DJ, Brawn WJ, Kilby MD. Antenatal perspective of hypoplastic left heart syndrome: 5 years on. *Arch Dis Child Fetal Neonatal Ed.* 2008;93:F192–F197.
413. Rychik J, Szwast A, Natarajan S, Quartermain M, Donaghue DD, Combs J, Gaynor JW, Gruber PJ, Spray TL, Bebbington M, Johnson MP. Perinatal and early surgical outcome for the fetus with hypoplastic left heart syndrome: a 5-year single institutional experience. *Ultrasound Obstet Gynecol.* 2010;36:465–470.
414. Ellinger MK, Rempel GR. Parental decision making regarding treatment of hypoplastic left heart syndrome. *Adv Neonatal Care.* 2010;10:316–322; quiz 323–324.
415. Rempel GR, Cender LM, Lynam MJ, Sandor GG, Farquharson D. Parents' perspectives on decision making after antenatal diagnosis of congenital heart disease. *J Obstet Gynecol Neonatal Nurs.* 2004;33:64–70.
416. Jackson C, Cheater FM, Reid I. A systematic review of decision support needs of parents making child health decisions. *Health Expect.* 2008;11:232–251.
417. Ross LF, Frader J. Hypoplastic left heart syndrome: a paradigm case for examining conscientious objection in pediatric practice. *J Pediatr.* 2009;155:12–15.
418. Rosenberg KB, Monk C, Glickstein JS, Levasseur SM, Simpson LL, Kleinman CS, Williams IA. Referral for fetal echocardiography is associated with increased maternal anxiety. *J Psychosom Obstet Gynaecol.* 2010;31:60–69.
419. Sklansky M, Tang A, Levy D, Grossfeld P, Kashani I, Shaughnessy R, Rothman A. Maternal psychological impact of fetal echocardiography. *J Am Soc Echocardiogr.* 2002;15:159–166.
420. Skari H, Malt UF, Bjornland K, Egeland T, Haugen G, Skreden M, Dalholt Bjork M, Bjornstad Ostensen A, Emblem R. Prenatal diagnosis of congenital malformations and parental psychological distress: a prospective longitudinal cohort study. *Prenat Diagn.* 2006;26:1001–1009.
421. Brosig CL, Whitstone BN, Frommelt MA, Frisbee SJ, Leuthner SR. Psychological distress in parents of children with severe congenital heart disease: the impact of prenatal versus postnatal diagnosis. *J Perinatol.* 2007;27:687–692.
422. Skreden M, Skari H, Malt UF, Haugen G, Pripp AH, Faugli A, Emblem R. Long-term parental psychological distress among parents of children with a malformation: a prospective longitudinal study. *Am J Med Genet A.* 2010;152A:2193–2202.
423. Rychik J, Donaghue DD, Levy S, Fajardo C, Combs J, Zhang X, Szwast A, Diamond GS. Maternal psychological stress after prenatal diagnosis of congenital heart disease. *J Pediatr.* 2013;162:302–307.e1.
424. Mulder EJ, Robles de Medina PG, Huizink AC, Van de Bergh BR, Buitelaar JK, Visser GH. Prenatal maternal stress: effects on pregnancy and the (unborn) child. *Early Hum Dev.* 2002;70:3–14.
425. Huizink AC, Robles de Medina PG, Mulder EJ, Visser GH, Buitelaar JK. Stress during pregnancy is associated with developmental outcome in infancy. *J Child Psychol Psychiatry.* 2003;44:810–818.
426. Weinstock M. The potential influence of maternal stress hormones on development and mental health of the offspring. *Brain Behav Immun.* 2005;19:296–308.
427. Maina G, Saracco P, Giolito MR, Danelon D, Bogetto F, Todros T. Impact of maternal psychological distress on fetal weight, prematurity and intrauterine growth retardation. *J Affect Disord.* 2008;111:214–220.
428. de Weerth C, van Hees Y, Buitelaar JK. Prenatal maternal cortisol levels and infant behavior during the first 5 months. *Early Hum Dev.* 2003;74:139–151.

429. Nathanielsz PW, Berghorn KA, Derks JB, Giussani DA, Docherty C, Unno N, Davenport A, Kutzlers M, Koenen S, Visser GH, Nijland MJ. Life before birth: effects of cortisol on future cardiovascular and metabolic function. *Acta Paediatr*. 2003;92:766-772.
430. Sjostrom K, Valentin L, Thelin T, Marsal K. Maternal anxiety in late pregnancy and fetal hemodynamics. *Eur J Obstet Gynecol Reprod Biol*. 1997;74:149-155.
431. Teixeira JM, Fisk NM, Glover V. Association between maternal anxiety in pregnancy and increased uterine artery resistance index: cohort based study. *BMJ*. 1999;318:153-157.
432. Jensen E, Wood CE, Keller-Wood M. Chronic alterations in ovine maternal corticosteroid levels influence uterine blood flow and placental and fetal growth. *Am J Physiol Regul Integr Comp Physiol*. 2005;288:R54-R61.
433. Serra V, Bellver J, Moulden M, Redman CW. Computerized analysis of normal fetal heart rate pattern throughout gestation. *Ultrasound Obstet Gynecol*. 2009;34:74-79.
434. Horigome H, Nagashima M, Sumitomo N, Yoshinaga M, Ushinohama H, Iwamoto M, Shiono J, Ichihashi K, Hasegawa S, Yoshikawa T, Matsunaga T, Goto H, Waki K, Arima M, Takasugi H, Tanaka Y, Tauchi N, Ikoma M, Inamura N, Takahashi H, Shimizu W, Horie M. Clinical characteristics and genetic background of congenital long-QT syndrome diagnosed in fetal, neonatal, and infantile life: a nationwide questionnaire survey in Japan. *Circ Arrhythm Electrophysiol*. 2010;3:10-17.
435. Mitchell J, Cuneo B, Etheridge SP, Horigome H, Weng H, Benson W. Fetal heart rate predictors of long QT syndrome. *Circulation*. 2012;126:2688-2695.
436. Cuneo BF, Strasburger JF, Yu S, Horigome H, Hosono T, Kandori A, Wakai RT. In utero diagnosis of long QT syndrome by magnetocardiography. *Circulation*. 2013;128:2183-2191.
437. Eliasson H, Wahren-Herlenius M, Sonesson SE. Mechanisms in fetal bradyarrhythmia: 65 cases in a single center analyzed by Doppler flow echocardiographic techniques. *Ultrasound Obstet Gynecol*. 2011;37:172-178.
438. Rosenthal D, Druzin M, Chin C, Dubin A. A new therapeutic approach to the fetus with congenital complete heart block: preemptive, targeted therapy with dexamethasone. *Obstet Gynecol*. 1998;92(pt 2):689-691.
439. Trucco SM, Jaeggi E, Cuneo B, Moon-Grady AJ, Silverman E, Silverman N, Hornberger LK. Use of intravenous gamma globulin and corticosteroids in the treatment of maternal autoantibody-mediated cardiomyopathy. *J Am Coll Cardiol*. 2011;57:715-723.
440. Jaeggi ET, Fouron JC, Silverman ED, Ryan G, Smallhorn J, Hornberger LK. Transplacental fetal treatment improves the outcome of prenatally diagnosed complete atrioventricular block without structural heart disease. *Circulation*. 2004;110:1542-1548.
441. Cuneo BF, Lee M, Roberson D, Niksch A, Ovadia M, Parilla BV, Benson DW. A management strategy for fetal immune-mediated atrioventricular block. *J Matern Fetal Neonatal Med*. 2010;23:1400-1405.
442. Friedman DM, Kim MY, Copel JA, Llanos C, Davis C, Buyon JP. Prospective evaluation of fetuses with autoimmune-associated congenital heart block followed in the PR Interval and Dexamethasone Evaluation (PRIDE) Study. *Am J Cardiol*. 2009;103:1102-1106.
443. Buyon JP, Clancy RM, Friedman DM. Cardiac manifestations of neonatal lupus erythematosus: guidelines to management, integrating clues from the bench and bedside. *Nat Clin Pract Rheumatol*. 2009;5:139-148.
444. Eliasson H, Sonesson SE, Sharland G, Granath F, Simpson JM, Carvalho JS, Jicinska H, Tomek V, Dangel J, Zielinsky P, Respondek-Liberska M, Freund MW, Mellander M, Bartrons J, Gardiner HM; Fetal Working Group of the European Association of Pediatric Cardiology. Isolated atrioventricular block in the fetus: a retrospective, multinational, multicenter study of 175 patients. *Circulation*. 2011;124:1919-1926.
445. Skog A, Wahren-Herlenius M, Sundstrom B, Bremme K, Sonesson SE. Outcome and growth of infants fetally exposed to heart block-associated maternal anti-Ro52/SSA autoantibodies. *Pediatrics*. 2008;121:e803-e809.
446. Lopes LM, Tavares GM, Damiano AP, Lopes MA, Aiello VD, Schultz R, Zugaib M. Perinatal outcome of fetal atrioventricular block: one-hundred-sixteen cases from a single institution. *Circulation*. 2008;118:1268-1275.
447. Cuneo BF, Strasburger JF. Management strategy for fetal tachycardia. *Obstet Gynecol*. 2000;96:575-581.
448. Oudijk MA, Michon MM, Kleinman CS, Kapusta L, Stoutenbeek P, Visser GH, Meijboom EJ. Sotalol in the treatment of fetal dysrhythmias. *Circulation*. 2000;101:2721-2726.
449. Jaeggi ET, Carvalho JS, De Groot E, Api O, Clur SA, Rammeloo L, McCrindle BW, Ryan G, Manlhiot C, Blom NA. Comparison of transplacental treatment of fetal supraventricular tachyarrhythmias with digoxin, flecainide, and sotalol: results of a nonrandomized multicenter study. *Circulation*. 2011;124:1747-1754.
450. Shah A, Moon-Grady A, Bhogal N, Collins KK, Tacy T, Brook M, Hornberger LK. Effectiveness of sotalol as first-line therapy for fetal supraventricular tachyarrhythmias. *Am J Cardiol*. 2012;109:1614-1618.
451. Krapp M, Baschat AA, Gembruch U, Geipel A, Germer U. Flecainide in the intrauterine treatment of fetal supraventricular tachycardia. *Ultrasound Obstet Gynecol*. 2002;19:158-164.
452. Ferrer PL. Fetal arrhythmias. In: Deal B, Wolff GS, Gelband H, eds. *Current Concepts in Diagnosis and Treatment of Arrhythmias in Infants and Children*. Armonk, NY: Futura Publishing Company, Inc; 1998:17-63.
453. Strasburger JF, Cuneo BF, Michon MM, Gotteiner NL, Deal BJ, McGregor SN, Oudijk MA, Meijboom EJ, Feinkind L, Hussey M, Parilla BV. Amiodarone therapy for drug-refractory fetal tachycardia. *Circulation*. 2004;109:375-379.
454. Bartalena L, Bogazzi F, Braverman LE, Martino E. Effects of amiodarone administration during pregnancy on neonatal thyroid function and subsequent neurodevelopment. *J Endocrinol Invest*. 2001;24:116-130.
455. Parilla BV, Strasburger JF, Socol ML. Fetal supraventricular tachycardia complicated by hydrops fetalis: a role for direct fetal intramuscular therapy. *Am J Perinatol*. 1996;13:483-486.
456. Hansmann M, Gembruch U, Bald R, Manz M, Redel DA. Fetal tachyarrhythmias: transplacental and direct treatment of the fetus: a report of 60 cases. *Ultrasound Obstet Gynecol*. 1991;1:162-168.
457. Naheed ZJ, Strasburger JF, Deal BJ, Benson DW Jr, Gidding SS. Fetal tachycardia: mechanisms and predictors of hydrops fetalis. *J Am Coll Cardiol*. 1996;27:1736-1740.
458. Lin AE, Alexander ME, Colan SD, Kerr B, Rauen KA, Noonan J, Baffa J, Hopkins E, Sol-Church K, Limongelli G, Digilio MC, Marino B, Innes AM, Aoki Y, Silberbach M, Delrue MA, White SM, Hamilton RM, O'Connor W, Grossfeld PD, Smoot LB, Padera RF, Gripp KW. Clinical, pathological, and molecular analyses of cardiovascular abnormalities in Costello syndrome: a Ras/MAPK pathway syndrome. *Am J Med Genet A*. 2011;155A:486-507.
459. Dubin AM, Cuneo BF, Strasburger JF, Wakai RT, Van Hare GF, Rosenthal DN. Congenital junctional ectopic tachycardia and congenital complete atrioventricular block: a shared etiology? *Heart Rhythm*. 2005;2:313-315.
460. Collins KK, Van Hare GF, Kertesz NJ, Law IH, Bar-Cohen Y, Dubin AM, Etheridge SP, Berul CI, Avari JN, Tuzcu V, Sreeram N, Schaffer MS, Fournier A, Sanatani S, Snyder CS, Smith RT Jr, Arabia L, Hamilton R, Chun T, Liberman L, Kakavand B, Paul T, Tanel RE. Pediatric nonoperative junctional ectopic tachycardia medical management and interventional therapies. *J Am Coll Cardiol*. 2009;53:690-697.
461. Simpson JM, Maxwell D, Rosenthal E, Gill H. Fetal ventricular tachycardia secondary to long QT syndrome treated with maternal intravenous magnesium: case report and review of the literature. *Ultrasound Obstet Gynecol*. 2009;34:475-480.
462. Roberts J, Funai E. Pregnancy related hypertension. In: Creasy R, Resnik R, Iams J, Lockwood C, Moore T, eds. *Creasy & Resnik's Maternal-Fetal Medicine: Principles and Practice*. 6th ed. Philadelphia, PA: Saunders; 2009:651-688.
463. Hui L, Bianchi DW. Prenatal pharmacotherapy for fetal anomalies: a 2011 update. *Prenat Diagn*. 2011;31:735-743.
464. Ebenroth ES, Cordes TM, Darragh RK. Second-line treatment of fetal supraventricular tachycardia using flecainide acetate. *Pediatr Cardiol*. 2001;22:483-487.
465. Patel D, Cuneo B, Viesca R, Rassanan J, Leshko J, Huhta J. Digoxin for the treatment of fetal congestive heart failure with sinus rhythm assessed by cardiovascular profile score. *J Matern Fetal Neonatal Med*. 2008;21:477-482.
466. Newton GE, Tong JH, Schofield AM, Baines AD, Floras JS, Parker JD. Digoxin reduces cardiac sympathetic activity in severe congestive heart failure. *J Am Coll Cardiol*. 1996;28:155-161.
467. Maxwell D, Allan L, Tynan MJ. Balloon dilatation of the aortic valve in the fetus: a report of two cases. *Br Heart J*. 1991;65:256-258.
468. Kohl T, Sharland G, Allan LD, Gembruch U, Chaoui R, Lopes LM, Zielinsky P, Huhta J, Silverman NH. World experience of percutaneous ultrasound-guided balloon valvuloplasty in human fetuses with severe aortic valve obstruction. *Am J Cardiol*. 2000;85:1230-1233.
469. Simpson JM, Sharland GK. Natural history and outcome of aortic stenosis diagnosed prenatally. *Heart*. 1997;77:205-210.
470. Tworetzky W, Wilkins-Haug L, Jennings RW, van der Velde ME, Marshall AC, Marx GR, Colan SD, Benson CB, Lock JE, Perry SB. Balloon



- dilation of severe aortic stenosis in the fetus: potential for prevention of hypoplastic left heart syndrome: candidate selection, technique, and results of successful intervention. *Circulation*. 2004;110:2125–2131.
471. Wilkins-Haug LE, Tworetzky W, Benson CB, Marshall AC, Jennings RW, Lock JE. Factors affecting technical success of fetal aortic valve dilation. *Ultrasound Obstet Gynecol*. 2006;28:47–52.
  472. Marshall AC, Tworetzky W, Bergersen L, McElhinney DB, Benson CB, Jennings RW, Wilkins-Haug LE, Marx GR, Lock JE. Aortic valvuloplasty in the fetus: technical characteristics of successful balloon dilation. *J Pediatr*. 2005;147:535–539.
  473. Arzt W, Wertaschnigg D, Veit I, Klement F, Gitter R, Tulzer G. Intrauterine aortic valvuloplasty in fetuses with critical aortic stenosis: experience and results of 24 procedures. *Ultrasound Obstet Gynecol*. 2011;37:689–695.
  474. Mizrahi-Arnaud A, Tworetzky W, Bulich LA, Wilkins-Haug LE, Marshall AC, Benson CB, Lock JE, McElhinney DB. Pathophysiology, management, and outcomes of fetal hemodynamic instability during prenatal cardiac intervention. *Pediatr Res*. 2007;62:325–330.
  475. Hornberger LK, Sanders SP, Rein AJ, Spevak PJ, Parness IA, Colan SD. Left heart obstructive lesions and left ventricular growth in the mid-trimester fetus: a longitudinal study. *Circulation*. 1995;92:1531–1538.
  476. Hornberger LK, Need L, Benacerraf BR. Development of significant left and right ventricular hypoplasia in the second and third trimester fetus. *J Ultrasound Med*. 1996;15:655–659.
  477. Rychik J, Rome JJ, Collins MH, DeCampi WM, Spray TL. The hypoplastic left heart syndrome with intact atrial septum: atrial morphology, pulmonary vascular histopathology and outcome. *J Am Coll Cardiol*. 1999;34:554–560.
  478. Graziano JN, Heidelberger KP, Ensing GJ, Gomez CA, Ludomirsky A. The influence of a restrictive atrial septal defect on pulmonary vascular morphology in patients with hypoplastic left heart syndrome. *Pediatr Cardiol*. 2002;23:146–151.
  479. Vlahos AP, Lock JE, McElhinney DB, van der Velde ME. Hypoplastic left heart syndrome with intact or highly restrictive atrial septum: outcome after neonatal transcatheter atrial septostomy. *Circulation*. 2004;109:2326–2330.
  480. Glatz JA, Tabbutt S, Gaynor JW, Rome JJ, Montenegro L, Spray TL, Rychik J. Hypoplastic left heart syndrome with atrial level restriction in the era of prenatal diagnosis. *Ann Thorac Surg*. 2007;84:1633–1638.
  481. Michelfelder E, Gomez C, Border W, Gottliebson W, Franklin C. Predictive value of fetal pulmonary venous flow patterns in identifying the need for atrial septoplasty in the newborn with hypoplastic left ventricle. *Circulation*. 2005;112:2974–2979.
  482. Szwast A, Tian Z, McCann M, Donaghue D, Rychik J. Vasoreactive response to maternal hyperoxygenation in the fetus with hypoplastic left heart syndrome. *Circ Cardiovasc Imaging*. 2010;3:172–178.
  483. Marshall AC, Levine J, Morash D, Silva V, Lock JE, Benson CB, Wilkins-Haug LE, McElhinney DB, Tworetzky W. Results of in utero atrial septoplasty in fetuses with hypoplastic left heart syndrome. *Prenat Diagn*. 2008;28:1023–1028.
  484. Selamet Tierney ES, Wald RM, McElhinney DB, Marshall AC, Benson CB, Colan SD, Marcus EN, Marx GR, Levine JC, Wilkins-Haug L, Lock JE, Tworetzky W. Changes in left heart hemodynamics after technically successful in-utero aortic valvuloplasty. *Ultrasound Obstet Gynecol*. 2007;30:715–720.
  485. Marshall AC, van der Velde ME, Tworetzky W, Gomez CA, Wilkins-Haug L, Benson CB, Jennings RW, Lock JE. Creation of an atrial septal defect in utero for fetuses with hypoplastic left heart syndrome and intact or highly restrictive atrial septum. *Circulation*. 2004;110:253–258.
  486. Xu Z, Owens G, Gordon D, Cain C, Ludomirsky A. Noninvasive creation of an atrial septal defect by histotripsy in a canine model. *Circulation*. 2010;121:742–749.
  487. Vogel M, McElhinney DB, Wilkins-Haug LE, Marshall AC, Benson CB, Juraszek AL, Silva V, Lock JE, Marx GR, Tworetzky W. Aortic stenosis and severe mitral regurgitation in the fetus resulting in giant left atrium and hydrops: pathophysiology, outcomes, and preliminary experience with pre-natal cardiac intervention. *J Am Coll Cardiol*. 2011;57:348–355.
  488. Rogers LS, Peterson AL, Gaynor JW, Rome JJ, Weinberg PM, Rychik J. Mitral valve dysplasia syndrome: a unique form of left-sided heart disease. *J Thorac Cardiovasc Surg*. 2011;142:1381–1387.
  489. Salvin JW, McElhinney DB, Colan SD, Gauvreau K, del Nido PJ, Jenkins KJ, Lock JE, Tworetzky W. Fetal tricuspid valve size and growth as predictors of outcome in pulmonary atresia with intact ventricular septum. *Pediatrics*. 2006;118:e415–e420.
  490. Gardiner HM, Belmar C, Tulzer G, Barlow A, Pasquini L, Carvalho JS, Daubeney PE, Rigby ML, Gordon F, Kulinskaya E, Franklin RC. Morphologic and functional predictors of eventual circulation in the fetus with pulmonary atresia or critical pulmonary stenosis with intact septum. *J Am Coll Cardiol*. 2008;51:1299–1308.
  491. Tulzer G, Arzt W, Franklin RC, Loughna PV, Mair R, Gardiner HM. Fetal pulmonary valvuloplasty for critical pulmonary stenosis or atresia with intact septum. *Lancet*. 2002;360:1567–1568.
  492. Denbow ML, Cox P, Taylor M, Hammal DM, Fisk NM. Placental angio-architecture in monochorionic twin pregnancies: relationship to fetal growth, fetofetal transfusion syndrome, and pregnancy outcome. *Am J Obstet Gynecol*. 2000;182:417–426.
  493. Mahieu-Caputo D, Dommergues M, Delezoide AL, Lacoste M, Cai Y, Nancy F, Jolly D, Gonzales M, Dumez Y, Gubler MC. Twin-to-twin transfusion syndrome: role of the fetal renin-angiotensin system. *Am J Pathol*. 2000;156:629–636.
  494. Mahieu-Caputo D, Muller F, Joly D, Gubler MC, Lebidois J, Fermont L, Dumez Y, Dommergues M. Pathogenesis of twin-twin transfusion syndrome: the renin-angiotensin system hypothesis. *Fetal Diagn Ther*. 2001;16:241–244.
  495. De Paeppe ME, Burke S, Luks FI, Pinar H, Singer DB. Demonstration of placental vascular anatomy in monochorionic twin gestations. *Pediatr Dev Pathol*. 2002;5:37–44.
  496. Galea P, Barigye O, Wee L, Jain V, Sullivan M, Fisk NM. The placenta contributes to activation of the renin angiotensin system in twin-twin transfusion syndrome. *Placenta*. 2008;29:734–742.
  497. Mahieu-Caputo D, Meulemans A, Martinovic J, Gubler MC, Delezoide AL, Muller F, Madelenat P, Fisk NM, Dommergues M. Paradoxical activation of the renin-angiotensin system in twin-twin transfusion syndrome: an explanation for cardiovascular disturbances in the recipient. *Pediatr Res*. 2005;58:685–688.
  498. Bajoria R, Ward S, Chatterjee R. Brain natriuretic peptide and endothelin-1 in the pathogenesis of polyhydramnios-oligohydramnios in monochorionic twins. *Am J Obstet Gynecol*. 2003;189:189–194.
  499. Barrea C, Alkazaleh F, Ryan G, McCrindle BW, Roberts A, Bigras JL, Barrett J, Seaward GP, Smallhorn JF, Hornberger LK. Prenatal cardiovascular manifestations in the twin-to-twin transfusion syndrome recipients and the impact of therapeutic amnioreduction. *Am J Obstet Gynecol*. 2005;192:892–902.
  500. Fesslova V, Villa L, Nava S, Mosca F, Nicolini U. Fetal and neonatal echocardiographic findings in twin-twin transfusion syndrome. *Am J Obstet Gynecol*. 1998;179:1056–1062.
  501. Michelfelder E, Gottliebson W, Border W, Kinsel M, Polzin W, Livingston J, Khoury P, Crombleholme T. Early manifestations and spectrum of recipient twin cardiomyopathy in twin-twin transfusion syndrome: relation to Quintero stage. *Ultrasound Obstet Gynecol*. 2007;30:965–971.
  502. Simpson LL, Marx GR, Elkadry EA, D'Alton ME. Cardiac dysfunction in twin-twin transfusion syndrome: a prospective, longitudinal study. *Obstet Gynecol*. 1998;92(pt 2):557–562.
  503. Zosmer N, Bajoria R, Weiner E, Rigby M, Vaughan J, Fisk NM. Clinical and echographic features of in utero cardiac dysfunction in the recipient twin in twin-twin transfusion syndrome. *Br Heart J*. 1994;72:74–79.
  504. Nizard J, Bonnet D, Fermont L, Ville Y. Acquired right heart outflow tract anomaly without systemic hypertension in recipient twins in twin-twin transfusion syndrome. *Ultrasound Obstet Gynecol*. 2001;18:669–672.
  505. Moon-Grady AJ, Rand L, Lemley B, Gosnell K, Hornberger LK, Lee H. Effect of selective fetoscopic laser photocoagulation therapy for twin-twin transfusion syndrome on pulmonary valve pathology in recipient twins. *Ultrasound Obstet Gynecol*. 2011;37:27–33.
  506. Tei C, Ling LH, Hodge DO, Bailey KR, Oh JK, Rodeheffer RJ, Tajik AJ, Seward JB. New index of combined systolic and diastolic myocardial performance: a simple and reproducible measure of cardiac function: a study in normals and dilated cardiomyopathy. *J Cardiol*. 1995;26:357–366.
  507. Quintero RA, Morales WJ, Allen MH, Bornick PW, Johnson PK, Kruger M. Staging of twin-twin transfusion syndrome. *J Perinatol*. 1999;19:550–555.
  508. Habli M, Michelfelder E, Cnota J, Wall D, Polzin W, Lewis D, Lim FY, Crombleholme TM. Prevalence and progression of recipient-twin cardiomyopathy in early-stage twin-twin transfusion syndrome. *Ultrasound Obstet Gynecol*. 2012;39:63–68.
  509. Rychik J, Tian Z, Bebbington M, Xu F, McCann M, Mann S, Wilson RD, Johnson MP. The twin-twin transfusion syndrome: spectrum of cardiovascular abnormality and development of a cardiovascular score to assess severity of disease. *Am J Obstet Gynecol*. 2007;197:392.e1–392.e8.
  510. Crombleholme TM, Shera D, Lee H, Johnson M, D'Alton M, Porter F, Chyu J, Silver R, Abuhamad A, Saade G, Shields L, Kauffman D, Stone J, Albanese CT, Bahado-Singh R, Ball RH, Bilaniuk L, Coleman B, Farmer D, Feldstein V, Harrison MR, Hedrick H, Livingston J,



- Lorenz RP, Miller DA, Norton ME, Polzin WJ, Robinson JN, Rychik J, Sandberg PL, Seri I, Simon E, Simpson LL, Yedigiarova L, Wilson RD, Young B. A prospective, randomized, multicenter trial of amnioreduction vs selective fetoscopic laser photocoagulation for the treatment of severe twin-twin transfusion syndrome. *Am J Obstet Gynecol.* 2007;197:396.e1–396.e9.
511. Shah AD, Border WL, Crombleholme TM, Michelfelder EC. Initial fetal cardiovascular profile score predicts recipient twin outcome in twin-twin transfusion syndrome. *J Am Soc Echocardiogr.* 2008;21:1105–1108.
512. Habli M, Michelfelder E, Cnota J, Wall D, Polzin W, Lewis D, Lim FY, Crombleholme TM. Prevalence and progression of recipient twin cardiomyopathy in early stage twin-twin transfusion syndrome (TTTS). *Ultrasound Obstet Gynecol.* 2012;39:63–68.
513. Harkness UF, Crombleholme TM. Twin-twin transfusion syndrome: where do we go from here? *Semin Perinatol.* 2005;29:296–304.
514. Senat MV, Deprest J, Boulvain M, Paupe A, Winer N, Ville Y. Endoscopic laser surgery versus serial amnioreduction for severe twin-to-twin transfusion syndrome. *N Engl J Med.* 2004;351:136–144.
515. Stirnemann JJ, Nasr B, Proulx F, Essaoui M, Ville Y. Evaluation of the CHOP cardiovascular score as a prognostic predictor of outcome in twin-twin transfusion syndrome after laser coagulation of placental vessels in a prospective cohort. *Ultrasound Obstet Gynecol.* 2010;36:52–57.
516. Van Mieghem T, Klaritsch P, Done E, Gucciardo L, Lewi P, Verhaeghe J, Lewi L, Deprest J. Assessment of fetal cardiac function before and after therapy for twin-to-twin transfusion syndrome. *Am J Obstet Gynecol.* 2009;200:400e1–400.e7.
517. Gratacos E, Van Schoubroeck D, Carreras E, Devlieger R, Roma E, Cabero L, Deprest J. Transient hydropic signs in the donor fetus after fetoscopic laser coagulation in severe twin-twin transfusion syndrome: incidence and clinical relevance. *Ultrasound Obstet Gynecol.* 2002;19:449–453.
518. Van Mieghem T, Martin A, Weber R, Barrea C, Windrim R, Hornberger L, Jaeggi E, Ryan G. Fetal cardiac function in recipient twins undergoing fetoscopic laser ablation of placental anastomoses for stage IV twin-twin transfusion syndrome (TTTS). *Ultrasound Obstet Gynecol.* 2013;42:64–69.
519. Halvorsen CP, Bilock SL, Pilo C, Sonesson SE, Norman M. Childhood cardiac function after twin-to-twin transfusion syndrome: a 10-year follow up. *Acta Paediatr.* 2009;98:1468–1474.
520. Gardiner HM, Taylor MJ, Karatza A, Vanderheyden T, Huber A, Greenwald SE, Fisk NM, Hecher K. Twin-twin transfusion syndrome: the influence of intrauterine laser photocoagulation on arterial distensibility in childhood. *Circulation.* 2003;107:1906–1911.
521. Adzick NS. Open fetal surgery for life-threatening fetal anomalies. *Semin Fetal Neonat Med.* 2009;15:1–8.
522. Szwasz A, Tian Z, McCann M, Donaghue D, Bebbington M, Johnson M, Wilson RD, Rychik J. Impact of altered loading conditions on ventricular performance in fetuses with congenital cystic adenomatoid malformation and twin-twin transfusion syndrome. *Ultrasound Obstet Gynecol.* 2007;30:40–46.
523. Mahle WT, Rychik J, Tian ZY, Cohen MS, Howell LJ, Crombleholme TM, Flake AW, Adzick NS. Echocardiographic evaluation of the fetus with congenital cystic adenomatoid malformation. *Ultrasound Obstet Gynecol.* 2000;16:620–624.
524. Wilson RD, Hedrick H, Flake AW, Johnson MP, Bebbington MW, Mann S, Rychik J, Liechty K, Adzick NS. Sacrococcygeal teratomas: prenatal surveillance, growth and pregnancy outcome. *Fetal Diagn Ther.* 2009;25:15–20.
525. Hedrick HL, Flake AW, Crombleholme TM, Howell LJ, Johnson MP, Wilson RD, Adzick NS. Sacrococcygeal teratoma: prenatal assessment, fetal intervention, and outcome. *J Pediatr Surg.* 2004;39:430–438.
526. Olotoye OO, Johnson MP, Coleman BG, Crombleholme TM, Adzick NS, Flake AW. Abnormal umbilical cord Dopplers may predict impending demise in fetuses with sacrococcygeal teratoma: a report of 2 cases. *Fetal Diagn Ther.* 2003;18:428–431.
527. Deprest J, Gratacos E, Nicolaidis KH; FETO Task Group. Fetoscopic tracheal occlusion (FETO) for severe congenital diaphragmatic hernia: evolution of a technique and preliminary results. *Ultrasound Obstet Gynecol.* 2004;24:121–126.
528. Jani JC, Nicolaidis KH, Gratacos E, Valencia CM, Done E, Martinez JM, Gucciardo L, Cruz R, Deprest JA. Severe diaphragmatic hernia treated by fetal endoscopic tracheal occlusion. *Ultrasound Obstet Gynecol.* 2009;34:304–310.
529. Vogel M, McElhinney DB, Marcus E, Morash D, Jennings RW, Tworetzky W. Significance and outcome of left heart hypoplasia in fetal congenital diaphragmatic hernia. *Ultrasound Obstet Gynecol.* 2010;35:310–317.
530. Van Mieghem T, Gucciardo L, Done E, Van Schoubroeck D, Graatsma EM, Visser GH, Verhaeghe J, Deprest J. Left ventricular cardiac function in fetuses with congenital diaphragmatic hernia and the effect of fetal endoscopic tracheal occlusion. *Ultrasound Obstet Gynecol.* 2009;34:424–429.
531. Hanley FL. Fetal cardiac surgery. *Adv Card Surg.* 1994;5:47–74.
532. Lam CT, Sharma S, Baker RS, Hilshorst J, Lombardi J, Clark KE, Eghtesady P. Fetal stress response to fetal cardiac surgery. *Ann Thorac Surg.* 2008;85:1719–1727.
533. Bruch SW, Adzick NS, Reiss R, Harrison MR. Prenatal therapy for pericardial teratomas. *J Pediatr Surg.* 1997;32:1113–1115.
534. Sydorak RM, Kelly T, Feldstein VA, Sandberg PL, Silverman NH, Harrison MR, Albanese CT. Prenatal resection of a fetal pericardial teratoma. *Fetal Diagn Ther.* 2002;17:281–285.
535. Adzick NS, Thom EA, Spong CY, Brock JW 3rd, Burrows PK, Johnson MP, Howell LJ, Farrell JA, Dabrowiak ME, Sutton LN, Gupta N, Tulipan NB, D'Alton ME, Farmer DL; MOMS Investigators. A randomized trial of prenatal versus postnatal repair of myelomeningocele. *N Engl J Med.* 2011;364:993–1004.
536. Keswani SG, Crombleholme TM, Rychik J, Tian Z, Mackenzie TC, Johnson MP, Wilson RD, Flake AW, Hedrick HL, Howell LJ, Adzick NS. Impact of continuous intraoperative monitoring on outcomes in open fetal surgery. *Fetal Diagn Ther.* 2005;20:316–320.
537. Rychik J, Tian Z, Cohen MS, Ewing SG, Cohen D, Howell LJ, Wilson RD, Johnson MP, Hedrick HL, Flake AW, Crombleholme TM, Adzick NS. Acute cardiovascular effects of fetal surgery in the human. *Circulation.* 2004;110:1549–1556.
538. Tran KM. Anesthesia for fetal surgery. *Semin Fetal Neonatal Med.* 2009;15:40–45.
539. Tworetzky W, McElhinney DB, Reddy VM, Brook MM, Hanley FL, Silverman NH. Improved surgical outcome after fetal diagnosis of hypoplastic left heart syndrome. *Circulation.* 2001;103:1269–1273.
540. Zalfa A, Barker C, Tibby SM, Simpson JM. Prenatal diagnosis of pulmonary atresia: impact on clinical presentation and early outcome. *Arch Dis Child Fetal Neonatal Ed.* 2007;92:F199–F203.
541. Eapen RS, Rowland DG, Franklin WH. Effect of prenatal diagnosis of critical left heart obstruction on perinatal morbidity and mortality. *Am J Perinatol.* 1998;15:237–242.
542. Franklin O, Burch M, Manning N, Sleeman K, Gould S, Archer N. Prenatal diagnosis of coarctation of the aorta improves survival and reduces morbidity. *Heart.* 2002;87:67–69.
543. Kumar RK, Newburger JW, Gauvreau K, Kamenir SA, Hornberger LK. Comparison of outcome when hypoplastic left heart syndrome and transposition of the great arteries are diagnosed prenatally versus when diagnosis of these two conditions is made only postnatally. *Am J Cardiol.* 1999;83:1649–1653.
544. Kipps AK, Feuille C, Azakie A, Hoffman JI, Tabbutt S, Brook MM, Moon-Grady AJ. Prenatal diagnosis of hypoplastic left heart syndrome in current era. *Am J Cardiol.* 2011;108:421–427.
545. Mahle WT, Clancy RR, McGaurn SP, Goin JE, Clark BJ. Impact of prenatal diagnosis on survival and early neurologic morbidity in neonates with the hypoplastic left heart syndrome. *Pediatrics.* 2001;107:1277–1282.
546. Bonnet D, Coltri A, Butera G, Fermont L, Le Bidois J, Kachaner J, Sidi D. Detection of transposition of the great arteries in fetuses reduces neonatal morbidity and mortality. *Circulation.* 1999;99:916–918.
547. Punn R, Silverman NH. Fetal predictors of urgent balloon atrial septostomy in neonates with complete transposition. *J Am Soc Echocardiogr.* 2011;24:425–430.
548. Du Marchie Sarvaas GJ, Trivedi KR, Hornberger LK, Lee KJ, Kirsh JA, Benson LN. Radiofrequency-assisted atrial septoplasty for an intact atrial septum in complex congenital heart disease. *Catheter Cardiovasc Interv.* 2002;56:412–415.
549. Lowenthal A, Kipps AK, Brook MM, Meadows J, Azakie A, Moon-Grady AJ. Prenatal diagnosis of atrial restriction in hypoplastic left heart syndrome is associated with decreased 2-year survival. *Prenat Diagn.* 2012;32:485–490.
550. Glatz AC, Gaynor JW, Rhodes LA, Rychik J, Tanel RE, Vetter VL, Kaltman JR, Nicolson SC, Montenegro L, Shah MJ. Outcome of high-risk neonates with congenital complete heart block paced in the first 24 hours after birth. *J Thorac Cardiovasc Surg.* 2008;136:767–773.
551. Levey A, Glickstein JS, Kleinman CS, Levasseur SM, Chen J, Gersony WM, Williams IA. The impact of prenatal diagnosis of complex congenital heart disease on neonatal outcomes. *Pediatr Cardiol.* 2010;31:587–597.
552. Chantepie A, Schleich JM, Gournay V, Blaysat G, Maragnes P. Preoperative mortality in transposition of the great vessels [in French]. *Arch Pediatr.* 2000;7:34–39.

553. Khoshnood B, De Vigan C, Vodovar V, Goujard J, Lhomme A, Bonnet D, Goffinet F. Trends in prenatal diagnosis, pregnancy termination, and perinatal mortality of newborns with congenital heart disease in France, 1983–2000: a population-based evaluation. *Pediatrics*. 2005;115:95–101.
554. Copel JA, Tan AS, Kleinman CS. Does a prenatal diagnosis of congenital heart disease alter short-term outcome? *Ultrasound Obstet Gynecol*. 1997;10:237–241.
555. Tham EB, Wald R, McElhinney DB, Hirji A, Goff D, Del Nido PJ, Hornberger LK, Nield LE, Tworetzky W. Outcome of fetuses and infants with double inlet single left ventricle. *Am J Cardiol*. 2008;101:1652–1656.
556. Lim JS, McCrindle BW, Smallhorn JF, Golding F, Caldaroni CA, Taketazu M, Jaeggi ET. Clinical features, management, and outcome of children with fetal and postnatal diagnoses of isomerism syndromes. *Circulation*. 2005;112:2454–2461.
557. Wan AW, Jevremovic A, Selamet Tierney ES, McCrindle BW, Dunn E, Manlhiot C, Wald RM, Kingdom JP, Jaeggi ET, Nield LE. Comparison of impact of prenatal versus postnatal diagnosis of congenitally corrected transposition of the great arteries. *Am J Cardiol*. 2009;104:1276–1279.
558. Nield LE, Silverman ED, Smallhorn JF, Taylor GP, Mullen JB, Benson LN, Hornberger LK. Endocardial fibroelastosis associated with maternal anti-Ro and anti-La antibodies in the absence of atrioventricular block. *J Am Coll Cardiol*. 2002;40:796–802.
559. Verheijen PM, Lisowski LA, Stoutenbeek P, Hitchcock JF, Brenner JI, Copel JA, Kleinman CS, Meijboom EJ, Bennink GB. Prenatal diagnosis of congenital heart disease affects preoperative acidosis in the newborn patient. *J Thorac Cardiovasc Surg*. 2001;121:798–803.
560. Tita AT, Landon MB, Spong CY, Lai Y, Leveno KJ, Varner MW, Moawad AH, Caritis SN, Meis PJ, Wapner RJ, Sorokin Y, Miodovnik M, Carpenter M, Peaceman AM, O'Sullivan MJ, Sibai BM, Langer O, Thorp JM, Ramin SM, Mercer BM; Eunice Kennedy Shriver NICHD Maternal-Fetal Medicine Units Network. Timing of elective repeat cesarean delivery at term and neonatal outcomes. *N Engl J Med*. 2009;360:111–120.
561. Hilder L, Costeloe K, Thilaganathan B. Prolonged pregnancy: evaluating gestation-specific risks of fetal and infant mortality. *Br J Obstet Gynaecol*. 1998;105:169–173.
562. Yudkin PL, Wood L, Redman CW. Risk of unexplained stillbirth at different gestational ages. *Lancet*. 1987;1:1192–1194.
563. Rand L, Robinson JN, Economy KE, Norwitz ER. Post-term induction of labor revisited. *Obstet Gynecol*. 2000;96(pt 1):779–783.
564. Cnota JF, Gupta R, Michelfelder EC, Ittenbach RF. Congenital heart disease infant death rates decrease as gestational age advances from 34 to 40 weeks. *J Pediatr*. 2011;159:761–765.
565. Costello JM, Polito A, Brown DW, McElrath TF, Graham DA, Thiagarajan RR, Bacha EA, Allan CK, Cohen JN, Laussen PC. Birth before 39 weeks' gestation is associated with worse outcomes in neonates with heart disease. *Pediatrics*. 2010;126:277–284.
566. Atz AM, Trivison TG, Williams IA, Pearson GD, Laussen PC, Mahle WT, Cook AL, Kirsh JA, Sklansky M, Khaikin S, Goldberg C, Frommelt M, Krawczeski C, Puchalski MD, Jacobs JP, Baffa JM, Rychik J, Ohye RG; Pediatric Heart Network Investigators. Prenatal diagnosis and risk factors for preoperative death in neonates with single right ventricle and systemic outflow obstruction: screening data from the Pediatric Heart Network Single Ventricle Reconstruction Trial. *J Thorac Cardiovasc Surg*. 2010;140:1245–1250.
567. Parry S, Marder SJ. Delivery and obstetrical issues. In: Rychik J, Wernovsky G, ed. *Hypoplastic Left Heart Syndrome*. New York, NY: Springer; 2003:29–37.
568. Peterson AL, Quartermain MD, Ades A, Khalek N, Johnson MP, Rychik J. Impact of mode of delivery on markers of perinatal hemodynamics in infants with hypoplastic left heart syndrome. *J Pediatr*. 2011;159:64–69.
569. Penny DJ, Shekerdemian LS. Management of the neonate with symptomatic congenital heart disease. *Arch Dis Child Fetal Neonatal Ed*. 2001;84:F141–F145.
570. Johnson BA, Ades A. Delivery room and early postnatal management of neonates who have prenatally diagnosed congenital heart disease. *Clin Perinatol*. 2005;32:921–946, ix.
571. Berkley EM, Goens MB, Karr S, Rappaport V. Utility of fetal echocardiography in postnatal management of infants with prenatally diagnosed congenital heart disease. *Prenat Diagn*. 2009;29:654–658.
572. Donofrio MT, Levy RJ, Schuette JJ, Skurow-Todd K, Sten M, Stallings C, Pike J, Krishnan A, Ratnayaka K, Sinha P, du Plessis AJ, Downing DD, Fries MI, Berger JT. Specialized delivery room planning for fetuses with critical congenital heart disease. *Am J Cardiol*. 2012;111:737–747.
573. Verheijen PM, Lisowski LA, Stoutenbeek P, Hitchcock JF, Bennink GB, Meijboom EJ. Lactacidosis in the neonate is minimized by prenatal detection of congenital heart disease. *Ultrasound Obstet Gynecol*. 2002;19:552–555.
574. Fuchs JB, Muller H, Abdul-Khalik H, Harder T, Dudenhausen JW, Henrich W. Immediate and long-term outcomes in children with prenatal diagnosis of selected isolated congenital heart defects. *Ultrasound Obstet Gynecol*. 2007;29:38–43.
575. Jaeggi ET, Sholler GF, Jones OD, Cooper SG. Comparative analysis of pattern, management and outcome of pre- versus postnatally diagnosed major congenital heart disease: a population-based study. *Ultrasound Obstet Gynecol*. 2001;17:380–385.
576. Rasanen J, Wood DC, Weiner S, Ludomirski A, Huhta JC. Role of the pulmonary circulation in the distribution of human fetal cardiac output during the second half of pregnancy. *Circulation*. 1996;94:1068–1073.
577. Lim MK, Hanretty K, Houston AB, Lilley S, Murtagh EP. Intermittent ductal patency in healthy newborn infants: demonstration by colour Doppler flow mapping. *Arch Dis Child*. 1992;67(Spec No):1217–1218.
578. Rudolph AM. *Congenital Diseases of the Heart: Clinical-Physiological Considerations*. Armonk, NY: Future Publishing Co; 2001.
579. Anand R, Mehta AV. Progressive congenital valvular aortic stenosis during infancy: five cases. *Pediatr Cardiol*. 1997;18:35–37.
580. Rowland DG, Hammill WW, Allen HD, Gutgesell HP. Natural course of isolated pulmonary valve stenosis in infants and children utilizing Doppler echocardiography. *Am J Cardiol*. 1997;79:344–349.
581. Gielen H, Daniels O, van Lier H. Natural history of congenital pulmonary valvular stenosis: an echo and Doppler cardiographic study. *Cardiol Young*. 1999;9:129–135.
582. Anagnostou K, Messenger L, Yates R, Kelsall W. Outcome of infants with prenatally diagnosed congenital heart disease delivered outside specialist paediatric cardiac centres. *Arch Dis Child Fetal Neonatal Ed*. 2013;98:F218–F221.
583. Hinton R, Michelfelder E. Significance of reverse orientation of the ductus arteriosus in neonates with pulmonary outflow tract obstruction for early intervention. *Am J Cardiol*. 2006;97:716–719.
584. Szwasz A, Tian Z, McCann M, Donaghue D, Rychik J. Vasoreactive response to maternal hyperoxygenation in the fetus with hypoplastic left heart syndrome. *Circ Cardiovasc Imaging*. 2010;3:172–178.
585. Jouannic JM, Gavard L, Fermont L, Le Bidois J, Parat S, Vouhe PR, Dumez Y, Sidi D, Bonnet D. Sensitivity and specificity of prenatal features of physiological shunts to predict neonatal clinical status in transposition of the great arteries. *Circulation*. 2004;110:1743–1746.
586. Chelliah A, Berger JT, Blask A, Donofrio MT. Clinical utility of magnetic resonance imaging in tetralogy of Fallot with absent pulmonary valve. *Circulation*. 2013;127:757–759.
587. Donofrio MT, Gullquist SD, Mehta ID, Moskowitz WB. Congenital complete heart block: fetal management protocol, review of the literature, and report of the smallest successful pacemaker implantation. *J Perinatol*. 2004;24:112–117.
588. Donofrio MT. Images in cardiovascular medicine: premature closure of the foramen ovale and ductus arteriosus in a fetus with transposition of the great arteries. *Circulation*. 2002;105:e65–e66.
589. Bouchard S, Johnson MP, Flake AW, Howell LJ, Myers LB, Adzick NS, Crombleholme TM. The EXIT procedure: experience and outcome in 31 cases. *J Pediatr Surg*. 2002;37:418–426.
590. Donofrio MT, Bremer YA, Moskowitz WB. Diagnosis and management of restricted or closed foramen ovale in fetuses with congenital heart disease. *Am J Cardiol*. 2004;94:1348–1351.
591. Maeno YV, Kamenir SA, Sinclair B, van der Velde ME, Smallhorn JF, Hornberger LK. Prenatal features of ductus arteriosus constriction and restrictive foramen ovale in d-transposition of the great arteries. *Circulation*. 1999;99:1209–1214.
592. Mirlesse V, Cruz A, Le Bidois J, Diallo P, Fermont L, Kieffer F, Magny JF, Jacquemard F, Levy R, Voyer M, Daffos F. Perinatal management of fetal cardiac anomalies in a specialized obstetric-pediatrics center. *Am J Perinatol*. 2001;18:363–371.
593. Morris LM, Lim FY, Crombleholme TM. Ex utero intrapartum treatment procedure: a peripartum management strategy in particularly challenging cases. *J Pediatr*. 2009;154:126–131.e3.
594. Olivieri L, Ratnayaka K, Levy RJ, Berger J, Wessel D, Donofrio M. Hypoplastic left heart syndrome with intact atrial septum sequelae of left atrial hypertension in utero. *J Am Coll Cardiol*. 2011;57:e369.

# Correction

In the article by Donofrio et al, “Diagnosis and Treatment of Fetal Cardiac Disease: A Scientific Statement From the American Heart Association,” which published online April 24, 2014, and appeared in the May 13, 2014, issue of the journal (*Circulation*. 2014;129:2183–2242), several corrections were needed.

1. On page 2183, the title page, 2 endorsements were added. The endorsements read, “*Endorsed by the American Society of Echocardiography and Pediatric and Congenital Electrophysiology Society.*” The endorsements now read,

*Endorsed by the American Society of Echocardiography and Pediatric and Congenital Electrophysiology Society*

*The American Institute of Ultrasound in Medicine supports the value and findings of the statement.\**

*The Society of Maternal Fetal Medicine supports the statement’s review of the subject matter and believe it is consistent with its existing clinical guidelines.†*

2. On page 2183, 2 paragraphs were added to the footnotes to read,

\*The American Institute of Ultrasound in Medicine (AIUM) has reviewed this statement and acknowledges it as a comprehensive review of the subject of fetal echocardiography. This document does not replace AIUM’s existing practice guideline on fetal echocardiography, which is available on the AIUM Web site or in AIUM’s journal (*J Ultrasound Med*. 2013;32:1067–1082).

†The Society of Maternal Fetal Medicine (SMFM) has reviewed this statement and acknowledges it as a comprehensive review on the subject of fetal echocardiography. This document does not replace SMFM’s existing clinical guidelines, which are available on the SMFM Web site (HYPERLINK "<http://www.smfm.org>).

These corrections have been made to the print version and to the current online version of the article, which is available at <http://circ.ahajournals.org/content/129/21/2183.full.pdf>.