

# UC Irvine

## UC Irvine Previously Published Works

### Title

Quality-of-Life Outcomes Following Endoscopic Resection of Sinonasal Inverted Papilloma.

### Permalink

<https://escholarship.org/uc/item/9fq751jv>

### Journal

The Laryngoscope, 135(2)

### Authors

Abiri, Arash

Hong, Ellen

Dilley, Katelyn

et al.

### Publication Date













2025-02-01

### DOI

10.1002/lary.31725

Peer reviewed

# Quality-of-Life Outcomes Following Endoscopic Resection of Sinonasal Inverted Papilloma

Arash Abiri, PhD ; Ellen M. Hong, BA; Katelyn K. Dilley, BS ; Theodore V. Nguyen, MD ;  
Mandy K. Salmon, MD; Elysia M. Grose, MD ; Siddhant H. Tripathi, MD ; Sanjena Venkatesh, MD ;  
Yohan Kim, MD; Daniel J. Lee, MD; Jennifer E. Douglas, MD ; Jacob G. Eide, MD ;  
Rijul S. Kshirsagar, MD ; Katie M. Phillips, MD; Ahmad R. Sedaghat, MD, PhD ; John M. Lee, MD;  
Charles C.L. Tong, MD ; Nithin D. Adappa, MD; James N. Palmer, MD; Edward C. Kuan, MD, MBA 

**Objectives:** There is growing interest in assessing patient quality of life (QOL) following treatment of sinonasal tumors, including inverted papilloma (IP). We aimed to elucidate the natural history of postoperative QOL outcomes in IP patients treated with surgery.

**Methods:** Cases of sinonasal IP treated surgically at 4 tertiary academic rhinology centers were retrospectively reviewed. SNOT-22 scores were used to evaluate QOL preoperatively and postoperatively (1, 3, 6, 12 months). Repeated-measures ANOVA assessed for differences in mean scores over time. Linear regression identified factors associated with QOL longitudinally.

**Results:** 373 patients were analyzed. Mean preoperative SNOT-22 score was  $20.6 \pm 20.4$ , which decreased to  $16.3 \pm 18.8$  ( $p = 0.041$ ) and  $11.8 \pm 15.0$  ( $p < 0.001$ ) at 1 and 3 months postoperatively, respectively. No further changes in SNOT-22 scores occurred beyond 3 months postoperatively ( $p > 0.05$ ). When analyzed by SNOT-22 subdomains, nasal, sleep, and otologic/facial subdomain scores (all  $p < 0.05$ ) demonstrated improvement at 12-month follow-up compared with preoperative scores; this was not observed for the emotional subdomain score ( $p = 0.800$ ). Recurrent cases were associated with higher long-term SNOT-22 scores ( $\beta = 7.08$ ;  $p = 0.017$ ). Age, sex, degree of dysplasia, prior surgery, primary site, and smoking history did not correlate with symptoms (all  $p > 0.05$ ).

**Conclusions:** QOL outcomes related to IP resection are largely driven by nasal, sleep, and otologic/facial subdomains, though patients appear to experience enduring improvement as early as 3 months postoperatively. Recurrent disease is a major driver of negative QOL.

**Key Words:** endoscopic surgery, inverted papilloma, quality of life, Schneiderian cell papilloma.

**Level of Evidence:** 4

*Laryngoscope*, 135:579–585, 2025

## INTRODUCTION

Inverted papillomas (IP) are benign epithelial wart-like outgrowths of the sinonasal tract that account for 0.5 to 4% of all neoplasms of the sinonasal tract with propensity for recurrence and risk of malignant transformation.<sup>1</sup> Common symptomatology includes unilateral nasal obstruction, epistaxis, rhinorrhea, and obstructive sinusitis.<sup>2,3</sup> In

most cases, IPs are treated through surgical excision, commonly through endoscopic approaches.<sup>4</sup> The best opportunity for control is during initial surgery, and incomplete resection may contribute to recurrence.<sup>1</sup> The development of attachment-oriented excision, which includes identification of the site of attachment, mucosal resection, and cauterization/drilling of underlying bone,

This is an open access article under the terms of the [Creative Commons Attribution-NonCommercial-NoDerivs](https://creativecommons.org/licenses/by-nc-nd/4.0/) License, which permits use and distribution in any medium, provided the original work is properly cited, the use is non-commercial and no modifications or adaptations are made.

From the Department of Otolaryngology–Head and Neck Surgery (A.A., E.M.H., K.K.D., T.V.N., E.C.K.), University of California, Irvine, California, U.S.A.; Department of Otorhinolaryngology–Head and Neck Surgery, Perelman School of Medicine (M.K.S., S.V., Y.K., D.J.L., J.E.D., C.C.L.T., N.D.A., J.N.P.), University of Pennsylvania, Philadelphia, Pennsylvania, U.S.A.; Department of Otolaryngology–Head and Neck Surgery (E.M.G., J.M.L.), University of Toronto, Toronto, Ontario, Canada; Department of Otolaryngology–Head and Neck Surgery (S.H.T., K.M.P., A.R.S.), University of Cincinnati College of Medicine, Cincinnati, Ohio, U.S.A.; Department of Otolaryngology–Head and Neck Surgery (J.G.E.), Henry Ford Health System, Detroit, Michigan, U.S.A.; Department of Head and Neck Surgery (R.S.K.), Kaiser Permanente Redwood City Medical Center, Redwood City, California, U.S.A.; and the Department of Neurological Surgery (E.C.K.), University of California, Irvine, California, U.S.A.

Editor's Note: This Manuscript was accepted for publication on July 31, 2024.

This work was supported in part by the National Institute of General Medical Sciences of the National Institutes of Health under award number T32GM008620.

The authors have no other funding, financial relationships, or conflicts of interest to disclose.

Preliminary versions of this study were presented as a poster at the 6th Congress of European Otorhinolaryngology–Head and Neck Surgery in Milan, Italy, from October 29 through November 2, 2022, and as a podium at the European Rhinologic Society/International Society of Inflammation and Allergy of the Nose Meeting in Sofia, Bulgaria, on June 19, 2023.

Send correspondence to Edward C. Kuan, Department of Otolaryngology–Head and Neck Surgery, University of California, Irvine Medical Center, 101 The City Drive South, Irvine, Orange, CA 92868. Email: [eckuan@uci.edu](mailto:eckuan@uci.edu)

DOI: 10.1002/lary.31725

has resulted in the reduction of recurrence.<sup>1,5,6</sup> Despite benign behavior, IPs may be locally aggressive, and long-term surveillance is indicated.<sup>7</sup>

As the paradigm shifts towards long-term monitoring for disease recurrence, understanding quality of life (QOL) for sinonasal tumors and relevant drivers becomes increasingly important. There have been few investigations on characterizing QOL after IP treatment; however, these have comprised single-institution studies with limited sample sizes and sometimes with combinations of histopathologies.<sup>5,8–11</sup> Additionally, there have been no longitudinal studies to evaluate changes in patient QOL after IP resection, particularly with regard to specific subdomains which drive QOL outcomes. In this study, we explore QOL changes attributed to IP resection from the preoperative to postoperative periods extending to greater than 12 months in a multi-institutional study, with the largest patient population described to date to investigate this topic.

## METHODS

### Study Population

A retrospective chart review of IP cases treated endoscopically spanning from October 1, 2009, to October 31, 2022, was conducted at four tertiary academic rhinology programs (University of California, Irvine, Orange, CA, USA; University of Pennsylvania, Philadelphia, PA, USA; University of Cincinnati, Cincinnati, OH, USA; University of Toronto, Toronto, Ontario, Canada) in accordance with each institution's corresponding Institutional Review Board. Inclusion criteria included any adult patient (age  $\geq 18$  years) diagnosed with sinonasal IP who underwent purely endoscopic resection.

### Study Variables

Independent variables used for analysis included overall patient demographics, site of attachment, laterality, degree of dysplasia in the IP on surgical pathology (e.g., those with malignant transformation were excluded), disease recurrence, clinical symptoms, history of prior/active smoking,<sup>12</sup> history of any prior sinonasal surgery, surgical details (including use of Denker maxillectomy for maxillary tumors, middle turbinate resection, and specific sinuses opened), and postoperative complications including symptomatic epiphora and/or facial/palatal/dental paresthesia (for maxillary sinus primaries) or intraoperative cerebrospinal fluid (CSF) leakage (for frontal, ethmoid, and/or sphenoid sinus primaries). SNOT-22 questionnaires were collected preoperatively and postoperatively at <1 month (immediate-term, IT), 2–3 months (short-term, ST), 6–9 months (mid-term, MT), and >12 months (long-term, LT) following sinus surgery to assess QOL, which was the primary measured outcome. Secondly, SNOT-22 subdomain (nasal, otologic/facial pain, sleep, emotional) scores as validated by Feng et al. were also compared pre- and postoperatively and assessed longitudinally.<sup>13</sup>

### Statistical Analysis

Statistical analyses were performed using R (version 4.2.2; The R Foundation for Statistical Computing) in RStudio (version 2022.12.0). A  $p$ -value of <0.05 was considered statistically significant. Wilcoxon rank-sum tests were used to compare the means of continuous variables. Repeated-measures analysis of variance

(rmANOVA) was performed to analyze differences in QOL scores across surveyed time points. Post-hoc pairwise comparisons were conducted and adjusted using Benjamini and Hochberg correction.<sup>14</sup> Linear regression was performed to identify clinical factors significantly associated with changes in SNOT-22 scores. The dependent variable for linear regression was defined as the difference between the last follow-up postoperative SNOT-22 score and the preoperative SNOT-22 score ( $\Delta$ SNOT = postoperative SNOT-22—preoperative SNOT-22).

## RESULTS

A total of 373 IP patients were analyzed, with 112 (30.0%) females and a mean age of  $59.9 \pm 13.2$  years. Table I lists the demographic and clinical characteristics of this cohort. Overall, 180 (48.6%) patients had IP pedicled in the maxillary sinus, 80 (21.9%) presented with a recurrent case, and 95 (25.6%) exhibited some degree of dysplasia. Most cases were unilateral (83.7%). Surgical resection frequently involved opening the maxillary (89.3%), ethmoid (82.3%), and sphenoid (67.8%) sinuses. Intraoperative CSF leak occurred in 7 (41.2%) frontal, 8 (38.1%) ethmoid, and 2 (9.5%) sphenoid primaries. All intraoperative leaks were successfully repaired with no postoperative CSF leaks reported.

Among all patients ( $N = 373$ ), mean SNOT-22 scores decreased significantly by 3 months postoperatively as compared to preoperative scores ( $p < 0.001$ ). There were no significant differences between ST ( $9.9 \pm 15.1$ ), MT ( $9.4 \pm 15.4$ ), and LT ( $9.4 \pm 15.8$ ) postoperative SNOT-22 scores (all  $p > 0.05$ ; Fig. 1). Repeated-measures ANOVA was then performed on 83 patients for whom SNOT-22 scores were available across all surveyed time points (Table II). For this subset of patients, total preoperative SNOT-22 scores ( $20.6 \pm 20.4$ ) were higher than IT ( $16.3 \pm 18.8$ ;  $p = 0.041$ ), ST ( $11.8 \pm 15.0$ ;  $p < 0.001$ ), MT ( $10.5 \pm 15.2$ ;  $p < 0.001$ ), and LT ( $11.3 \pm 16.3$ ;  $p < 0.001$ ) postoperative scores. Analysis of SNOT-22 subdomain scores using rmANOVA revealed significant long-term improvements in nasal, sleep, and otologic/facial subdomain scores (all  $p < 0.01$ ). Improvements in nasal symptoms were observed within 1 month postoperatively ( $p = 0.031$ ), while sleep ( $p < 0.001$ ) and otologic/facial symptoms ( $p = 0.014$ ) significantly improved by 3 months postoperatively. Nasal, sleep, and otologic/facial subdomain scores improved significantly until 3 months postoperatively (all  $p < 0.05$ ), after which no significant changes were observed in MT and LT surveys (all  $p > 0.05$ ). Emotional subdomain scores did not significantly change following surgery ( $p = 0.492$ ).

Linear regression was performed to identify clinical factors associated with changes in total SNOT-22 scores (Table III). Since ST, MT, and LT SNOT-22 scores were previously found to be similar, MT or, if MT not available, ST scores, were used for calculating  $\Delta$ SNOT in cases where LT scores were not available. Recurrent cases were associated with higher long-term SNOT-22 scores ( $\beta = 7.08$ ;  $p = 0.017$ ). Age, sex, degree of dysplasia, prior sinus surgery, site of attachment, and smoking history did not correlate with long-term symptoms (all  $p > 0.05$ ). Among maxillary sinus IPs, after accounting for prior

Variables	No. (%)
Age (year), Mean ± SD	59.9 ± 13.2
Sex	
Male	261 (70.0)
Female	112 (30.0)
Prior sinus surgery	
No	124 (33.3)
Yes	248 (66.7)
Smoking history	
No	199 (53.6)
Yes	172 (46.4)
Site of attachment	
Maxillary	180 (48.6)
Ethmoid	106 (28.6)
Sphenoid	28 (7.6)
Frontal	34 (9.2)
Nasal cavity	22 (5.9)
Laterality	
Left	164 (44.0)
Right	148 (39.7)
Bilateral	61 (16.4)
Degree of dysplasia	
None	275 (74.3)
Mild	36 (9.7)
Moderate	26 (7.0)
Severe	33 (8.9)
Recurrent case	
No	286 (78.1)
Yes	80 (21.9)
Denker's approach*	
No	139 (66.8)
Yes	69 (33.2)
Maxillary sinus opened	
No	40 (10.7)
Yes	333 (89.3)
Ethmoid sinus opened	
No	66 (17.7)
Yes	307 (82.3)
Sphenoid sinus opened	
No	120 (32.2)
Yes	253 (67.8)
Frontal sinus opened	
No	196 (52.5)
Yes	176 (47.2)
Middle turbinate resection	
No	202 (54.3)
Yes	170 (45.7)
Epiphora*	
No	60 (90.9)
Yes	6 (9.1)

(Continues)

Variables	No. (%)
Facial paresthesia*	
No	45 (68.2)
Yes	21 (31.8)
Intraoperative CSF leak**	
No	151 (89.9)
Yes	17 (10.1)
SNOT-22, Mean ± SD	
Preoperative	18.4 ± 21.4
IT	14.9 ± 17.0
ST	9.9 ± 15.1
MT	9.4 ± 15.4
LT	9.4 ± 15.8
Follow-up (mo), Mean ± SD	44.0 ± 36.2

Not all variables were available for some patients; thus, the percentages reflect the number of patients with available data.

CSF = cerebrospinal fluid; IT = immediate-term; LT = long-term; MT = mid-term; SD = standard deviation; ST = short-term.

\*For maxillary primary site.

\*\*For frontal, ethmoid, and/or sphenoid primary sites.

recurrence, use of endoscopic Denker's approach was not associated with  $\Delta$ SNOT ( $p = 0.832$ ).

## DISCUSSION

In this study, we analyzed QOL after endoscopic tumor resection in the largest longitudinal series of IP patients to date on this topic, with analysis of drivers of QOL. We observed significant improvements in sinonasal-specific QOL (as measured by SNOT-22 score) by the first postoperative visit (<1 month, IT period), which further improved at 3 months (ST) postoperatively with a 46% reduction in SNOT-22 scores. QOL appeared to stabilize 3 months after surgery and remained durable for more than 12 months, with no significant differences in SNOT-22 scores between ST, MT, and LT periods. In the long-term, mean changes in total SNOT-22 scores exceeded the minimal clinically important difference (MCID) of 8.9.<sup>15</sup> Although the average difference between LT and preoperative scores was only 0.4 higher than the MCID, it is important to acknowledge that >25% of our patients presented with very low SNOT-22 scores preoperatively and therefore did not exhibit a measurable change in QOL. Despite such patients lowering the mean change in SNOT-22 scores, we still observed a mean difference greater than the MCID, suggesting that IP resection generally provides a meaningful improvement in QOL. By SNOT-22 subdomain, nasal symptom improvement was seen in the IT period, while both sleep and otologic/facial subdomain improvements were seen in the ST period. While recurrent disease was associated with higher SNOT-22 scores (worse QOL), no other clinical factors significantly affected QOL outcomes.

QOL improvements were most substantial in the ST period, suggesting that the critical recovery period

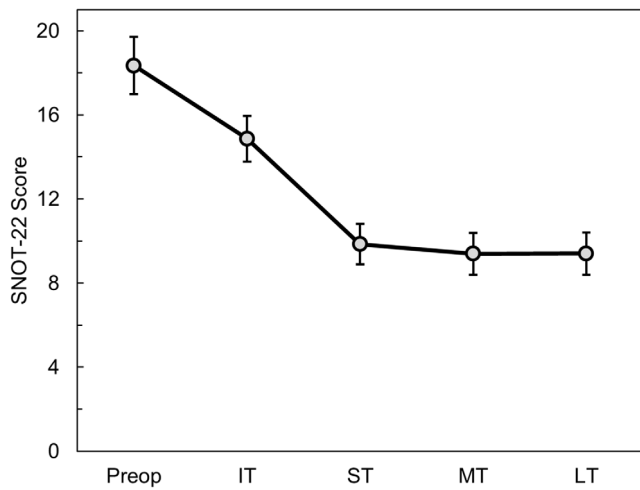


Fig. 1. Average SNOT-22 scores of IP patients preoperatively ( $N = 330$ ) and at IT ( $N = 274$ ), ST ( $N = 240$ ), MT ( $N = 284$ ), and LT ( $N = 285$ ) postoperatively. Error bars represent standard error of the mean. IT = immediate-term; ST = short-term; MT = mid-term; LT = long-term.

primarily occurs within the first 3 months after surgery. This improvement may be attributable to immediate relief due to removal of tumor burden (i.e., improved nasal obstruction), debridement and removal of dressings, remucosalization of denuded bone, and reduction of edema and swelling. As such, this likely represents the expected time period to counsel patients on wound healing. Current reports on the natural history of QOL after IP resection show similar trends. van Samakar and Georgalas found that, in 27 IP patients with a range of 1–10 years for follow-up, the median SNOT-22 score was 12 compared with 9.3 found in healthy populations.<sup>11</sup> In a recent single-institution study of 85 IP patients, Yu et al. reported improvements in total SNOT-22 scores 3 months after surgery.<sup>8</sup> By contrast, Derausseau et al. compared preoperative SNOT-20 scores against those collected at

6 months, 1 year, and 2 years for 32 patients with IP and found a similar trend of postoperative improvement and durability.<sup>10</sup> Recently, Viitasalo et al. used the 15D health-related QOL instrument to prospectively study 52 IP patients' QOL 1 and 2 years after their surgeries.<sup>16</sup> While certain tumor symptoms (e.g., nasal obstruction and epistaxis) improved postoperatively, discomfort scores were higher 1 year postoperatively and patients had experienced surgical complications (e.g., facial paresthesia). Though with some parallels to these findings, which were all conducted at single institutions, the results from the current multi-institutional study both validate prior findings and may potentially be more generalizable because of a more geographically diverse patient population, larger sample size, and representation of different surgical techniques (i.e., multiple surgeons of varying training backgrounds).

On rmANOVA analysis of SNOT-22 subdomains showed that the majority of QOL improvement after IP resection was attributed to reduction in nasal and sleep scores. Nasal and sleep domains are likely most affected by tumor resection due to common presenting symptoms (i.e., nasal obstruction, epistaxis, rhinorrhea, obstructive sinusitis<sup>2</sup>). Given that surgery directly removes the tumor burden and restores nasal and sinus airflow, it naturally follows that nasal and sleep symptoms started improving immediately postoperatively. Moreover, previous literature suggests that further symptomatic improvements can be partly attributed to resolution of intranasal edema, crusting, and nasal discharge.<sup>17</sup> On the contrary, the otologic/facial domain achieved significant improvements at the ST period. This is most likely due to the expected recovery period following resection, where remucosalization occurs over several weeks and debridements and nasal hygiene promote additional wound healing.<sup>16–19</sup> Understanding time intervals for improvement of specific symptoms is helpful for counseling patients as they recover from tumor surgery.

In our cohort, we found that age, sex, previous sinus surgery, smoking history, site of IP attachment

TABLE II.  
Repeated-Measures ANOVA of SNOT-22 Scores from IP Patients ( $N = 83$ ).

SNOT-22 Measure	Preop	IT Postop	ST Postop	MT Postop	LT Postop	$p$
Total	20.6 (16.2–25.0)	16.3 (12.3–20.3)	11.7 (8.5–14.9)	10.5 (7.2–13.8)	11.3 (7.8–14.8)	<0.001*
Nasal	8.7 (7.0–10.4)	6.7 (5.2–8.2)	5.0 (3.6–6.4)	4.3 (3.0–5.6)	5.1 (3.5–6.7)	<0.001*
Sleep	8.6 (6.4–10.8)	6.7 (4.6–8.8)	4.7 (3.1–6.3)	4.2 (2.7–5.7)	4.2 (2.8–5.6)	<0.001*
Otologic/facial	2.5 (1.8–3.2)	2.4 (1.7–3.1)	1.6 (1.0–2.2)	1.4 (0.8–2.0)	1.4 (0.8–2.0)	<0.001*
Emotional	0.7 (0.4–1.1)	0.5 (0.2–0.8)	0.5 (0.2–0.9)	0.5 (0.2–0.9)	0.5 (0.2–0.8)	0.492

Values in parentheses represent 95% confidence intervals.

ANOVA = analysis of variance; IP = inverted papilloma; IT = immediate-term; LT = long-term; MT = mid-term; SNOT-22 = Sinonasal Outcome Test-22; ST = short-term.

\*Statistically significant,  $p < 0.05$ .

TABLE III.  
Linear Regression of the Change of SNOT-22 Scores ( $\Delta$ SNOT) in IP Patients ( $N = 306$ ).

Variables	$\beta$ (95% CI)	$p$ -Value
Age, year	0.09 [-0.10, 0.27]	0.354
Sex		
Male	0 [Reference]	
Female	-0.38 [-5.52, 4.75]	0.884
Prior sinonasal surgery		
No	0 [Reference]	
Yes	-1.66 [-6.67, 3.35]	0.517
Smoking history		
No	0 [Reference]	
Yes	1.55 [-3.26, 6.35]	0.528
Site of attachment		
Maxillary	0 [Reference]	
Ethmoid	-4.34 [-9.99, 1.32]	0.134
Sphenoid	-1.21 [-10.43, 8.02]	0.798
Frontal	6.66 [-1.82, 15.15]	0.125
Nasal cavity	8.72 [-1.09, 18.53]	0.082
Degree of dysplasia	0.55 [-1.76, 2.87]	0.641
Laterality		
Left	0 [Reference]	
Right	-0.43 [-5.60, 4.74]	0.871
Bilateral	1.17 [-5.91, 8.24]	0.747
Recurrent case		
No	0 [Reference]	
Yes	7.08 [1.33, 12.84]	0.017*
Epiphora		
No	0 [Reference]	
Yes	-0.64 [-17.83, 16.55]	0.942
Facial paresthesia		
No	0 [Reference]	
Yes	-7.75 [-18.37, 2.88]	0.159

$\beta$  = regression coefficient; CI = confidence interval; IP = inverted papilloma; SNOT-22 = Sinonasal Outcome Test-22.

\*Statistically significant,  $p < 0.05$ .

(maxillary, ethmoid, sphenoid, frontal, or nasal cavity), degree of dysplasia, tumor laterality, or postoperative complications had no significant effect on QOL prognosis. This suggests that endoscopic surgery is uniformly an effective treatment with overall low morbidity, even with a disease with heterogeneous features. However, we found that patients undergoing recurrent IP resection had worse QOL scores than those with primary IPs. As recurrent IPs have been previously treated, many tumors may have more aggressive anatomic features or extents of involvement (i.e., multifocal involvement), which may require more invasive surgery (e.g., wider margin of resection and treatment of the sinuses), resulting in worse QOL outcomes.<sup>20</sup> This is supported by previous work by Derousseau et al., which reported that the more radical the surgical approach, the greater the disruption of local anatomy, leading to higher SNOT-20 scores.<sup>10</sup> Thus, recurrent disease seems to be a major driver of QOL in IP

patients, possibly due to the need for more extensive treatment. Although a more conservative approach may be considered to facilitate higher QOL, it increases the risk for eventually needing revision surgery, which can lead to worse clinical outcomes in the long-term.<sup>21</sup> In a retrospective cohort of 247 patients with chronic rhinosinusitis, Ayoub *et al.* investigated if there were any differences in QOL outcomes between patients treated more conservatively and those who underwent more extensive surgery that extended beyond the areas of radiographic disease.<sup>22</sup> Similar revision rates and improvements in SNOT-22 were seen in conservative and extensive groups at 6 months. However, patients from a third “concordant” group whose sinusotomies completely correlated with the extent of disease observed on preoperative imaging exhibited significantly lower SNOT-22 scores than either conservative or comprehensive groups at 24 months.<sup>22</sup> This suggests the importance of surgical expertise in developing an individually adapted surgical strategy based on tumor staging and radiologic imaging, rather than a standard procedure, to achieve optimal outcomes for IP resection.

The standard endoscopic approach allows access to sinonasal lesions while avoiding facial scarring from external excisions used in open procedures. However, considerable portions of the maxillary sinus are difficult to visualize and reach through this technique, making it difficult to adequately treat IPs involving this region.<sup>1</sup> Harvey et al. stratified the maxillary sinus into five anatomic zones that were progressively more anterior and lateral from the midline: zone 1, nasal cavity; zone 2, medial to infraorbital nerve (ION); zone 3, lateral to ION; zone 4, anterior maxilla; and zone 5, premaxillary tissue.<sup>23</sup> Zone 3 and above were identified as areas most difficult to reach endoscopically. Techniques have been developed to mitigate the difficulty of maneuverability such as the transseptal approach and septal dislocation.<sup>23,24</sup> More recently, the endoscopic Denker’s approach has been described, which allows for improved exposure of the anterior maxillary sinus without additional dissection of the septum or sublabial incision.<sup>25</sup> However, this procedure includes severing the nasolacrimal duct (NLD), which may cause NLD stenosis resulting in epiphora necessitating dacryocystorhinostomy.<sup>25,26</sup> Other complications include ION damage and alar collapse.<sup>26</sup> Studies examining QOL following endoscopic Denker’s procedure are lacking, and the impacts of the aforementioned complications are not characterized. In our study cohort, we did not find a significant association between the use of Denker’s approach and long-term QOL for patients with maxillary sinus IPs. This suggests that extent of approach may not affect QOL outcomes in IP surgery, as meticulous resection, mucosal preservation technique, and postoperative care may facilitate healing and preserve recovery of function. In 2007, Zhou et al. introduced the endoscopic prelacrimal recess approach, which avoids ablation of the inferior turbinate and the NLD while allowing increased access to the maxillary sinus, albeit to a lesser extent than the endoscopic Denker’s approach.<sup>27,28</sup> Indeed, patients undergoing IP resection via the prelacrimal recess did not report instances of epiphora,

eye crusting, or dry nose due to the preservation of the NLD and the lateral wall of the nasal cavity, maintaining nasal functionality such as humidity and warming.<sup>27,29,30</sup> QOL following this procedure has been examined via SNOT-22 scores; however, Mohankumar et al. did not examine patients undergoing IP resection, and Lin and Chen studied only 9 patients with sinonasal papillomas.<sup>31,32</sup> While NLD stenosis and related complications were not reported by patients, Lin and Chen did not identify a statistically significant improvement in SNOT-22 scores.<sup>32</sup> Overall, improvements in purely endoscopic approaches to IP resection better expose the sinonasal cavity, and future studies in QOL following endoscopic procedures stratifying by technique may aid in surgical decision-making.

Although this is a large multi-institutional cohort study, our results are not without limitations. Firstly, this retrospective analysis of patients relied on chart review, which may not encompass the entirety of patient and tumor characteristics and symptomatology after resection. Patients may not have completed SNOT-22 surveys at all time points due to patient declinations, unscanned forms, or loss to follow-up. Furthermore, SNOT-22 scores are a patient-reported outcome measure, are subjective, and only focus on disease-specific measures without accounting for generic QOL. It is also worth noting that SNOT-22 was originally implemented in assessing chronic rhinosinusitis outcomes and there are technically no validated instruments for evaluating QOL in sinonasal tumors.<sup>15,33</sup> Nonetheless, SNOT-22 scores have been widely used as outcome measures for patients undergoing endoscopic sinus surgery due to similarities in symptomatology between chronic rhinosinusitis and many sinonasal tumors.<sup>9,10,34–38</sup>

## CONCLUSIONS

In this multi-institutional longitudinal study of 373 IP patients, primary surgical resection resulted in significant QOL improvements within 1 month of surgery, which improved in a durable manner at 3 months postoperatively and stabilized across 12 months. QOL outcomes were primarily driven by reductions in nasal, sleep, and otologic/facial symptoms, and recurrent disease portends worse QOL outcomes.

## BIBLIOGRAPHY

- Peng P, Har-El G. Management of inverted papillomas of the nose and paranasal sinuses. *Am J Otolaryngol*. 2006;27(4):233-237. <https://doi.org/10.1016/j.amjoto.2005.11.005>
- von Buchwald C, Bradley PJ. Risks of malignancy in inverted papilloma of the nose and paranasal sinuses. *Curr Opin Otolaryngol Head Neck Surg*. 2007;15(2):95-98. <https://doi.org/10.1097/MOO.0b013e3280803d9b>
- Segal K, Atar E, Mor C, Har-El G, Sidi J. Inverting papilloma of the nose and paranasal sinuses. *Laryngoscope*. 1986;96(4):394-398. <https://doi.org/10.1288/00005537-198604000-00011>
- Reh DD, Lane AP. The role of endoscopic sinus surgery in the management of sinonasal inverted papilloma. *Curr Opin Otolaryngol Head Neck Surg*. 2009;17(1):6-10. <https://doi.org/10.1097/MOO.0b013e32831b9cd1>
- Wu V, Siu J, Yip J, Lee JM. Endoscopic management of maxillary sinus inverted papilloma attachment sites to minimize disease recurrence. *J Otolaryngol—Head Neck Surg*. 2018;47:24. <https://doi.org/10.1186/s40463-018-0271-1>
- Trent MS, Goshtasbi K, Hui L, et al. A systematic review of definitive treatment for inverted papilloma attachment site and associations with recurrence. *Otolaryngol Neck Surg*. 2022;167(3):425-433. <https://doi.org/10.1177/01945998211051975>
- Gupta R, Rady PL, Sikora AG, Tyring SK. The role of human papillomavirus in the pathogenesis of sinonasal inverted papilloma: a narrative review. *Rev Med Virol*. 2021;31(3):e2178. <https://doi.org/10.1002/rmv.2178>
- Yu S, Grose E, Lee DJ, Wu V, Pellarin M, Lee JM. Evaluation of inverted papilloma recurrence rates and factors associated recurrence after endoscopic surgical resection: a retrospective review. *J Otolaryngol—Head Neck Surg*. 2023;52(1):34. <https://doi.org/10.1186/s40463-023-00638-5>
- Deckard NA, Harrow BR, Barnett SL, Batra PS. Comparative analysis of quality-of-life metrics after endoscopic surgery for Sinonasal neoplasms. *Am J Rhinol Allergy*. 2015;29(2):151-155. <https://doi.org/10.2500/ajra.2015.29.4137>
- Derousseau T, Manjunath L, Harrow B, Zhang S, Batra PS. Long-term changes in quality of life after endoscopic resection of sinonasal and skull-base tumors. *Int Forum Allergy Rhinol*. 2015;5(12):1129-1135. <https://doi.org/10.1002/alr.21608>
- van Samkar A, Georgalas C. Long-term quality of life after endoscopic removal of sinonasal inverted papillomas: a 6-year cohort analysis in a tertiary academic hospital. *Eur Arch Otorhinolaryngol*. 2016;273(6):1433-1437. <https://doi.org/10.1007/s00405-015-3751-1>
- Hoehle LP, Phillips KM, Caradonna DS, Gray ST, Sedaghat AR. A contemporary analysis of clinical and demographic factors of chronic rhinosinusitis patients and their association with disease severity. *Ir J Med Sci*. 2018;187(1):215-221. <https://doi.org/10.1007/s11845-017-1639-3>
- Feng AL, Wesely NC, Hoehle LP, et al. A validated model for the 22-item Sino-nasal outcome test subdomain structure in chronic rhinosinusitis. *Int Forum Allergy Rhinol*. 2017;7(12):1140-1148. <https://doi.org/10.1002/alr.22025>
- Lee S, Lee DK. What is the proper way to apply the multiple comparison test? *Korean J Anesthesiol*. 2018;71(5):353-360. <https://doi.org/10.4097/kja.d.18.00242>
- Hopkins C, Gillett S, Slack R, Lund VJ, Browne JP. Psychometric validity of the 22-item Sinonasal outcome test. *Clin Otolaryngol*. 2009;34(5):447-454. <https://doi.org/10.1111/j.1749-4486.2009.01995.x>
- Vaitasalo S, Sintonen H, Lilja M, Hytonen M, Aaltonen LM. Quality of life after operative treatment of sinonasal inverted papilloma—a prospective study. *Rhinology*. 2023;61(1):71-76. <https://doi.org/10.4193/Rhin22.255>
- McCoul ED, Anand VK, Bedrosian JC, Schwartz TH. Endoscopic skull base surgery and its impact on sinonasal-related quality of life. *Int Forum Allergy Rhinol*. 2012;2(2):174-181. <https://doi.org/10.1002/alr.21008>
- Bugten V, Nordgård S, Steinsvåg S. The effects of debridement after endoscopic sinus surgery. *Laryngoscope*. 2006;116(11):2037-2043. <https://doi.org/10.1097/01.mlg.0000241362.06072.83>
- Bernstein JM, Lebowitz RA, Jacobs JB. Initial report on postoperative healing after endoscopic sinus surgery with the microdebrider. *Otolaryngol—Head Neck Surg off J Am Acad Otolaryngol-Head Neck Surg*. 1998;118(6):800-803. [https://doi.org/10.1016/S0194-5998\(98\)70272-4](https://doi.org/10.1016/S0194-5998(98)70272-4)
- Tong CCL, Patel NN, Maina IW, et al. Inverted papilloma with multifocal attachment is associated with increased recurrence. *Int Forum Allergy Rhinol*. 2019;9(8):865-869. <https://doi.org/10.1002/alr.22342>
- Bugter O, Monserez DA, van Zijl FVWJ, Baatenburg de Jong RJ, Hardillo JA. Surgical management of inverted papilloma; a single-center analysis of 247 patients with long follow-up. *J Otolaryngol—Head Neck Surg*. 2017;46:67. <https://doi.org/10.1186/s40463-017-0246-7>
- Ayoub N, Walgama E, Thamboo A, et al. Correlation between extent of sinus surgery, radiographic disease, and postoperative outcomes. *Rhinology*. 2020;58(1):36-44. <https://doi.org/10.4193/Rhin19.213>
- Harvey RJ, Sheehan PO, Debnath NI, Schlosser RJ. Transseptal approach for extended endoscopic resections of the maxilla and infratemporal fossa. *Am J Rhinol Allergy*. 2009;23(4):426-432. <https://doi.org/10.2500/ajra.2009.23.3333>
- Ramakrishnan VR, Suh JD, Chiu AG, Palmer JN. Septal dislocation for endoscopic access of the anterolateral maxillary sinus and infratemporal fossa. *Am J Rhinol Allergy*. 2011;25(2):128-130. <https://doi.org/10.2500/ajra.2011.25.3559>
- Lee JT, Suh JD, Carrau RL, Chu MW, Chiu AG. Endoscopic Denker's approach for resection of lesions involving the anteroinferior maxillary sinus and infratemporal fossa. *Laryngoscope*. 2017;127(3):556-560. <https://doi.org/10.1002/lary.26237>
- McCormick JP, Suh JD, Wang EW, et al. Modified endoscopic Denker's approach for Management of Anterior Maxillary Sinus Tumors: multicenter series of 58 cases. *Am J Rhinol Allergy*. 2022;36(6):763-772. <https://doi.org/10.1177/19458924221110652>
- Zhou B, Han DM, Cui SJ, Huang Q, Wang CS. Intranasal endoscopic prelacrimal recess approach to maxillary sinus. *Chin Med J (Engl)*. 2013;126(7):1276. <https://doi.org/10.3760/cma.j.issn.0366-6999.20121754>
- Li L, London Nyall R, Prevedello DM, Carrau RL. Endoscopic endonasal approach to the pterygopalatine fossa and infratemporal fossa: comparison of the Prelacrimal and Denker's corridors. *Am J Rhinol Allergy*. 2022;36(5):599-606. <https://doi.org/10.1177/19458924221097159>
- Zhou B, Huang Q, Sun J, et al. Resection of inverted papilloma of the maxillary sinus via a Prelacrimal recess approach: a multicenter retrospective analysis of surgical efficacy. *Am J Rhinol Allergy*. 2018;32(6):518-525. <https://doi.org/10.1177/1945892418801243>
- Suzuki M, Nakamura Y, Yokota M, Ozaki S, Murakami S. Modified transnasal endoscopic medial maxillectomy through prelacrimal duct approach. *Laryngoscope*. 2017;127(10):2205-2209. <https://doi.org/10.1002/lary.26529>

31. Mohankumar V, Kannan DS, Narendrakumar V, Kuppuswamy S, Baby AN. A comparative study between endoscopic Prelacrimal approach and middle meatal antrostomy for maxillary sinus pathologies. *Indian J Otolaryngol Head Neck Surg.* 2022;74(1):90-95. <https://doi.org/10.1007/s12070-021-02703-9>
32. Lin YH, Chen WC. Clinical outcome of endonasal endoscopic prelacrimal approach in managing different maxillary pathologies. *PeerJ.* 2020;8:e8331. <https://doi.org/10.7717/peerj.8331>
33. Kuan EC, Wang EW, Adappa ND, et al. International consensus statement on allergy and rhinology: Sinonasal tumors. *Int Forum Allergy Rhinol.* 2024;14(2):149-608. <https://doi.org/10.1002/alr.23262>
34. Chow VJ, Tsetsos N, Poutoglidis A, Georgalas C. Quality of life in sinonasal tumors: an up-to-date review. *Curr Opin Otolaryngol Head Neck Surg.* 2022;30(1):46-57. <https://doi.org/10.1097/MOO.0000000000000774>
35. Rudmik L, Soler ZM, Mace JC, DeConde AS, Schlosser RJ, Smith TL. Using preoperative SNOT-22 score to inform patient decision for endoscopic sinus surgery. *Laryngoscope.* 2015;125(7):1517-1522. <https://doi.org/10.1002/lary.25108>
36. Grimm DR, Beswick DM, Maoz SL, et al. SNOT-22 subdomain outcomes following treatment for sinonasal malignancy: a prospective, multicenter study. *Int Forum Allergy Rhinol.* Published online February 19, 2024; 14(8):1314-1326. <https://doi.org/10.1002/alr.23338>
37. Fleseriu CM, Beswick DM, Maoz SL, et al. Predictive factors for decreased baseline quality of life in patients with sinonasal malignancies. *Int Forum Allergy Rhinol.* 2024;14(4):775-785. <https://doi.org/10.1002/alr.23261>
38. Maoz SL, Wang EW, Hwang PH, et al. Long-term quality of life after treatment in sinonasal malignancy: a prospective, multicenter study. *Int Forum Allergy Rhinol.* 2023;13(11):2030-2042. <https://doi.org/10.1002/alr.23171>