

UCSF

UC San Francisco Previously Published Works

Title

Myocarditis Associated with Immune Checkpoint Inhibitors: An Expert Consensus on Data Gaps and a Call to Action.

Permalink

<https://escholarship.org/uc/item/9fw0z96g>

Journal

The Oncologist, 23(8)

Authors

Neilan, Tomas

Rothenberg, Mace

Amiri-Kordestani, Laleh

et al.

Publication Date

2018-08-01

DOI

10.1634/theoncologist.2018-0157

Peer reviewed

Myocarditis Associated with Immune Checkpoint Inhibitors: An Expert Consensus on Data Gaps and a Call to Action

TOMAS G. NEILAN,^{a,†} MACE L. ROTHENBERG,^{b,†} LALEH AMIRI-KORDESTANI,^c RYAN J. SULLIVAN,^a RICHARD M. STEINGART,^d WILLIAM GREGORY,^b SUBRAMANIAN HARIHARAN,^b TAREK A. HAMMAD,^e JOANN LINDENFELD,^f MARTIN J. MURPHY,^g JAVID J. MOSLEHI,^f
ON BEHALF OF THE CHECKPOINT INHIBITOR SAFETY WORKING GROUP

^aMassachusetts General Hospital, Boston, Massachusetts, USA; ^bPfizer Inc, New York, New York, USA; ^cCenter for Drug Evaluation and Research, U.S. Food and Drug Administration, Silver Spring, Maryland, USA; ^dMemorial Sloan Kettering Cancer Center, New York, New York, USA; ^eEMD Serono Inc, Billerica, Massachusetts, USA; ^fVanderbilt University, Nashville, Tennessee, USA; ^gProject Data Sphere, LLC, Cary, North Carolina, USA

[†]Contributed equally

^{††}The contributions of L.A.-K. represent her opinions and not those of the U.S. Food and Drug Administration.

Disclosures of potential conflicts of interest may be found at the end of this article.

Key Words. Immune checkpoint inhibitor • Immune-related adverse events • Myocarditis • PD-1/PD-L1 inhibitor • Project Data Sphere

ABSTRACT

Immune checkpoint inhibitors (ICIs) have transformed the treatment landscape for cancer. Due to the mechanism of action of ICIs, inflammatory reactions against normal tissue were an anticipated side effect of these agents; these immune-related adverse events have been documented and are typically low grade and manageable. Myocarditis has emerged as an uncommon but potentially life-threatening adverse reaction in patients treated with ICIs. Assessment and characterization of ICI-associated myocarditis is challenging because of its low incidence and protean manifestations. Nevertheless, the seriousness of ICI-associated myocarditis justifies a coordinated effort to increase awareness of this syndrome, identify patients who

may be at risk, and enable early diagnosis and appropriate treatment. The “Checkpoint Inhibitor Safety Working Group,” a multidisciplinary committee of academic, industry, and regulatory partners, convened at a workshop hosted by Project Data Sphere, LLC, on December 15, 2017. This meeting aimed to evaluate the current information on ICI-associated myocarditis, determine methods to collect and share data on this adverse reaction, and establish task forces to close the identified knowledge gaps. In this report, we summarize the workshop findings and proposed steps to address the impact of ICI-associated myocarditis in patients with cancer. *The Oncologist* 2018;23:874–878

INTRODUCTION

Immune checkpoint inhibitors (ICIs) represent an exciting class of drugs that trigger the patient’s immune system to recognize and combat cancer cells [1, 2]. Numerous ICIs, most commonly targeting programmed death-1 (PD-1), its ligand (PD-L1), and cytotoxic T-lymphocyte-associated antigen 4, are approved or in development for various tumor types. Encouraging efficacy outcomes have been observed in a substantial proportion of patients treated with ICIs; however, suppression of important regulators of the immune system can lead to inflammatory reactions, referred to as immune-related adverse events (irAEs), against normal tissue in multiple organs [1]. Immune-related AEs are generally low grade and manageable, especially if recognized early, although severe and sometimes fatal complications with ICIs have been reported [3–5]. Cardiac irAEs appear to occur less frequently than irAEs in other organ systems but can be particularly complex to diagnose and treat [3–5].

Myocarditis has recently emerged as an uncommon adverse reaction in patients administered ICIs, as noted in case reports [6–26], clinical trials [27–30], safety databases [14, 31, 32], and registries [33]. Due to the low incidence of ICI-associated myocarditis, data on presentation, diagnosis, treatment, and outcomes are limited [33, 34]. Nevertheless, preliminary clinical experience indicates ICI-associated myocarditis can be life threatening and therefore warrants efforts to increase awareness, identify patients who may be at risk, facilitate early diagnosis, and develop effective treatments.

The impact of ICI-associated myocarditis is expected to grow as ICIs are evaluated in patients with earlier-stage cancer with a higher likelihood of long-term survival, as well as in combination regimens, which appear to carry an increased risk of myocarditis [14, 33]. In 2015, an estimated 600,000 patients with metastatic cancer in the U.S. were eligible for ICI treatment [35]. This number is anticipated to increase across all

Correspondence: Tomas G. Neilan, M.D., Cardio-Oncology Program and Cardiac MR PET CT Program, Massachusetts General Hospital, 165 Cambridge St., Suite 400, Boston, Massachusetts 02114, USA. Telephone: 617-726-1543; e-mail: tneilan@mgh.harvard.edu Received March 13, 2018; accepted for publication April 19, 2018; published Online First on May 25, 2018. <http://dx.doi.org/10.1634/theoncologist.2018-0157>

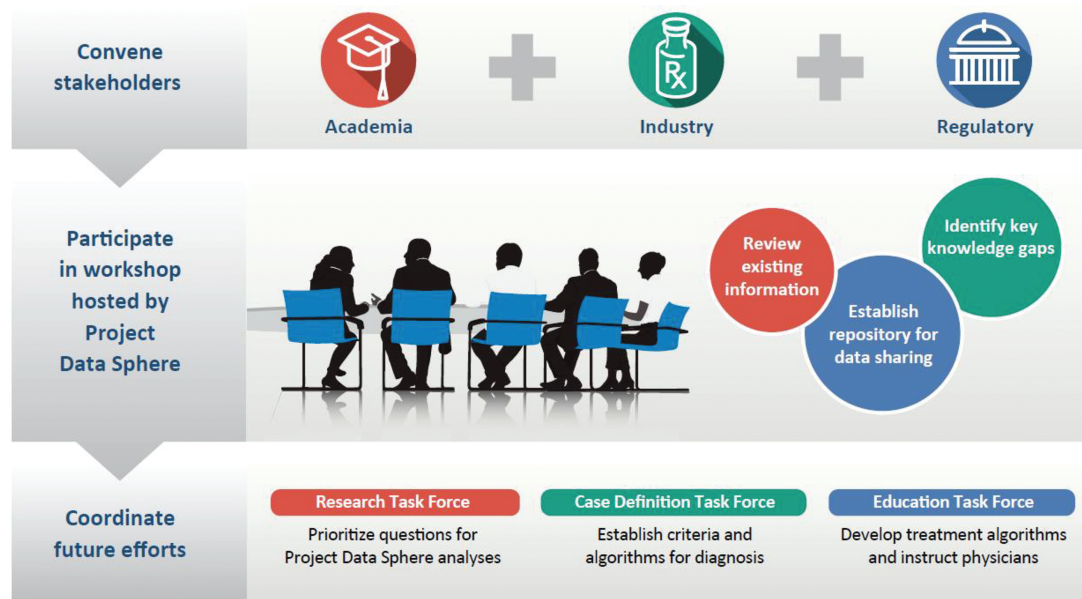


Figure 1. Checkpoint Inhibitor Safety Working Group meeting and goals.

cancer stages; in 2017, there were 940 immuno-oncology agents being tested in 3,042 clinical trials with a target enrollment of 577,076 patients [36].

Evaluation of ICI-associated myocarditis in clinical trials is challenging because the number of patients who develop myocarditis in any single study or group of studies is likely too small to establish risk factors, screening guidelines, diagnostic criteria, or optimal management. Thus, coordinated efforts are urgently needed to better characterize ICI-associated myocarditis. Accordingly, the U.S. Food and Drug Administration (FDA) hosted a public workshop on December 1, 2017, to discuss cardiovascular toxicities in immuno-oncology clinical trials [37].

A multidisciplinary committee assembled on December 15, 2017, for an ICI-associated myocarditis workshop hosted by Project Data Sphere, LLC, an independent, nonprofit initiative of the CEO Roundtable on Cancer's Life Sciences Consortium [38, 39]. Representatives of key stakeholders from academia, industry, and regulatory agencies, including the U.S. and China FDAs and the European Medicines Agency (collectively, the "Checkpoint Inhibitor Safety Working Group"), convened to review the existing, albeit limited, information on ICI-associated myocarditis; identify optimal ways to collect and share data; establish cross-functional teams to develop a case definition, diagnostic work-up, and treatment algorithms; and delineate research priorities (Fig. 1). We report the workshop findings below.

CURRENT KNOWLEDGE

The first specific report of myocarditis during treatment with a PD-1/PD-L1 inhibitor was published in 2014 [27], and a number of cases of ICI-associated myocarditis have been described since [6–26]. In an early analysis of more than 20,000 patients treated with ICIs, either alone or in combination, the incidence of myocarditis was 0.09%; the incidence of fatal myocarditis in this sample was 0.03% [14]. A recent study identified 101 cases of severe ICI-associated myocarditis in the World Health Organization global database of more than 16 million individual case safety reports (VigiBase) [40] and found reporting of cases

increased substantially over time (3 in 2010–2014, 6 in 2015, 15 in 2016, and 76 in 2017) [32]. The true incidence of ICI-associated myocarditis may be underestimated due to the wide range of clinical presentations, challenges in diagnosis, and a general lack of awareness of this condition.

ICI-associated myocarditis appears to be a class effect, and the risk of myocarditis seems to be higher when these drugs are administered in combination regimens [14, 33]. An analysis of a multicenter registry found that combination ICI treatment was more common in patients with ICI-associated myocarditis compared with a random sample of ICI-treated patients without myocarditis (34% vs. 2%; $p < .001$) [33]. This is an important consideration as ICI combinations become a focus of immunotherapy development [36]. To date, most reported cases of myocarditis have occurred in patients receiving single-agent ICI therapy, possibly reflecting the preponderance of clinical trial data and clinical experience with ICIs administered in this manner.

Based on published accounts [6–26, 32, 33] and ~150 cases reviewed at the workshop, the clinical presentation of ICI-associated myocarditis may be quite variable. Manifestations range from nonspecific symptoms that may be erroneously attributed to underlying disease (e.g., fatigue, chest pain, dyspnea) to acute arrhythmias, conduction disorders, clinical heart failure, and sudden death. ICI-associated myocarditis may occur alone or in the setting of irAEs involving other organs [11], especially muscles (myositis) [14, 15, 27, 29, 31, 32].

There are no universally accepted criteria for a diagnosis of ICI-associated myocarditis, but position statements [41] and clinical practice guidelines [42] for myocarditis due to other causes provide benchmarks. Inexpensive and widely available tests used for diagnosing ICI-associated myocarditis include troponin measurements and electrocardiograms [7, 10, 12–15, 19, 20, 22]. However, these tests lack the sensitivity and specificity for a definitive myocarditis diagnosis. Additional standard imaging methods that have been used for the assessment and diagnosis of ICI-associated myocarditis include echocardiography and cardiac magnetic resonance imaging, which may reveal

left-ventricular ejection fraction abnormalities, wall motion abnormalities, myocardial edema, and fibrosis. Even endomyocardial biopsy, currently considered the gold-standard method for diagnosis, has its limitations, as ICI-associated myocarditis may occur as a patchy distribution of T-cell-predominant lymphocytic infiltrate within or adjacent to regions of myocardial necrosis [7, 11, 13, 19, 20, 23], similar to histologic findings in patients with cardiac transplant rejection [14]. Therefore, proper diagnosis of ICI-associated myocarditis may involve a combination of high clinical acumen, biomarkers, cardiac imaging, and endomyocardial biopsy.

Like most irAEs, which typically emerge early in the course of treatment [1], preliminary observations suggest ICI-associated myocarditis generally occurs within 3 months of treatment initiation [7, 9–11, 13–15, 18–20, 22–24]. Management of ICI-associated myocarditis varies in published reports but frequently includes administration of corticosteroids [7, 9–15, 19, 20, 22–26], with outcomes ranging from complete resolution to the occurrence of major adverse cardiac events and/or death.

KEY INFORMATION GAPS

Case Definition

There is currently no standardized definition for ICI-associated myocarditis to enable consistent and reliable diagnosis by clinicians in different settings or in patient populations with diverse cancers and varied disease stages. A case definition is needed to capture these events in a harmonized manner so that data may be pooled and available for more thorough analyses. These would enable a more consistent approach to the detection and treatment of ICI-associated myocarditis that could be built into protocols for prospective evaluation in future clinical trials.

Given the limited available data, a robust case definition of ICI-associated myocarditis cannot be generated at this time. However, as case reports are continually published, this information will be compiled through a collaborative process similar to this workshop with a preliminary case definition shared in 2018 and form the basis for a case definition. Development of a case definition will be an iterative process, with broader definitions applied to initial retrospective analyses, an approach with high sensitivity but low specificity. Subsequent refinement of criteria would occur as more cases are added to increase the specificity to acceptable levels. Due to the high cost and limited availability of some diagnostic tests and/or expertise, it may be necessary to establish one set of criteria with sufficient sensitivity for identifying potential cases of ICI-associated myocarditis and a more extensive set of criteria, with improved specificity, for confirming the diagnosis.

Patients with ICI-associated myocarditis symptoms may first seek care from health care workers unfamiliar with this syndrome (e.g., family or emergency room physicians, internists, or cardiologists whose practices often include a limited number of patients with cancer). Thus, it is important to disseminate a case definition to the broader medical community, in addition to oncologists, and increase patient awareness about specific symptoms that should be reported to their physicians to enable more rapid diagnosis and initiation of treatment.

Monitoring Guidelines

Consensus guidelines for monitoring myocarditis in clinical studies of ICIs are needed. Closer monitoring may be appropriate for trials in the adjuvant or neoadjuvant setting, combination ICI regimens, and coadministration of ICIs with other agents with known cardiovascular toxicities. In large phase III trials, it may be valuable to screen patients for potential risk factors for ICI-associated myocarditis, for example, pre-existing cardiac dysfunction or autoimmune disease, and monitor patients with and without these characteristics for prospective efficacy and safety comparisons.

Risk Factors and Pathogenesis

Although unknown at present, risk factors for ICI-associated myocarditis may include genetic variants associated with innate or adaptive immunity. It may be possible to analyze existing biospecimens from clinical trials to identify potential germline genetic factors and/or circulating biomarkers for the diagnosis and prognosis of ICI-associated myocarditis. Consideration should be given to collection of specific biospecimens in clinical trials for subsequent large-scale genomic and proteomic analyses.

The basic pathophysiology of ICI-associated myocarditis requires further elucidation. Existing data indicate myocarditis is characterized by intense infiltration of T lymphocytes and macrophages [7, 11, 13, 14, 19, 20, 23]. Preliminary evidence suggests common high-frequency T-cell receptor sequences in infiltrates from the cardiac muscle and tumor, raising the possibility of a common (shared) epitope between the tumor and the heart [14]. The rapid onset of myocarditis following ICI treatment suggests the presence of a pre-existing factor and pathway (or pre-autoimmune disease) that is held in check by the targeted pathway. Preclinical models have implicated the PD-1/PD-L1 pathway in the development of myocarditis [43–46], but models for ICI-induced myocarditis specifically are needed to understand the pathogenesis and test potential treatments.

Treatment Algorithms

There is a clear need for a multidisciplinary team of oncologists, cardiologists, and other specialists to develop a standardized approach to the management of ICI-associated myocarditis. Initial recommendations have included consensus guidelines from the Society for Immunotherapy of Cancer Toxicity Management Working Group [4] and the American Society of Clinical Oncology (ASCO) in collaboration with the National Comprehensive Cancer Network (NCCN) [5]. These guidelines recommend consultation with a cardiologist, discontinuation of ICI therapy, and administration of high-dose corticosteroids (e.g., 1 mg/kg methylprednisolone) in cases of confirmed or suspected myocarditis [4, 5], in line with published findings [33]. The ASCO/NCCN panel also suggests that cardiac symptoms be managed per guidelines from the American College of Cardiology and American Heart Association in collaboration with a cardiologist [5]. Both groups acknowledge that due to limited data on ICI-associated myocarditis, their recommendations for management of this adverse reaction are based on anecdotal evidence [4, 5], and treatment guidelines are expected to evolve as more data on ICI-associated myocarditis are reported and assembled. Similar to the approach being used to generate a case definition, efforts are underway by workshop participants to assess published cases of ICI-associated myocarditis and propose management strategies.

CHARTING A PATH FORWARD: A CALL TO ACTION

Data Sharing

To facilitate robust investigations into ICI-associated myocarditis, the Checkpoint Inhibitor Safety Working Group supported the establishment of a single, integrated database of deidentified, patient-level data within Project Data Sphere, with industry sponsors, National Cancer Trial Network organizations, and high-volume cancer centers contributing to this repository. This approach is supported by the U.S. FDA Oncology Center of Excellence for the analysis of uncommon but clinically significant irAEs, including myocarditis [47]. As an open-access, data-sharing platform [39, 48], Project Data Sphere provides researchers with a venue to analyze large clinical datasets of ICI-treated patients that could provide a more accurate estimate of the true incidence of ICI-associated myocarditis, define its clinical characteristics, identify risk factors, and refine diagnostic and treatment algorithms. Future efforts could expand this framework to include ICI-associated myocarditis events observed in patients in the real-world setting.

Formation of Task Forces to Address Information Gaps

The workshop participants prioritized actions to close the information gaps for ICI-associated myocarditis and proposed three working groups to accomplish this: a Research Task Force to identify and prioritize research questions to guide analyses performed on data uploaded to Project Data Sphere; a Case Definition Task Force to establish diagnostic criteria and work-up algorithms; and an Education Task Force to develop treatment algorithms and instruct clinical trial investigators and treating physicians (Fig. 1).

CONCLUSION

ICIs hold tremendous promise for extending the lives of patients with cancer. As ICI use increases rapidly in clinical trial and real-world settings, it is critical to undertake efforts to mitigate the risk of uncommon but life-threatening adverse reactions, including myocarditis. The workshop convened by Project Data Sphere brought together academic, industry, and regulatory partners on short notice to share information, identify knowledge gaps, pose research questions, and initiate development of a case definition and approach to treatment for ICI-associated myocarditis, with the ultimate goal of minimizing the risk of this adverse reaction in patients with cancer who are treated with ICIs.

ACKNOWLEDGMENTS

Financial and organizational support for the December 15, 2017, ICI-associated myocarditis workshop was provided by

Project Data Sphere, LLC; additional financial support was supplied by a grant from the Parker Institute for Cancer Immunotherapy. Medical writing support was provided by Joanna Bloom, Ph.D., of Engage Scientific Solutions, and was funded by Pfizer. We thank Patrick Caubel of Pfizer, Roland Chen of Bristol-Myers Squibb, William Holmes and Mayur Patel of AstraZeneca/MedImmune, Antonio Kwan of Genentech, and Kamal Shah of EMD Serono/Merck for their support in forming the Checkpoint Inhibitor Safety Working Group.

The Checkpoint Inhibitor Safety Working Group includes Hesham Abdullah (AstraZeneca/MedImmune), Laleh Amiri-Kordestani (U.S. Food and Drug Administration), Cecilia Bakker (Pfizer), Chris Boshoff (Pfizer), Charlie Bringham (Pfizer), Samantha Bucktrout (Parker Institute for Cancer Immunotherapy), Kathleen Carlin (Pfizer), Patrick Caubel (Pfizer), Roland Chen (Bristol-Myers Squibb), Kevin Chin (EMD Serono/Merck), Aleksander Chudnovsky (Pfizer), John Davis, Jr. (Pfizer), Jonathan Deutsch (Bristol-Myers Squibb), Rakesh Dixit (AstraZeneca/MedImmune), Christer Gottfridsson (AstraZeneca/MedImmune), William Gregory (Pfizer), Tarek A. Hammad (EMD Serono/Merck), Dave Handelsman (Project Data Sphere), Subramanian Hariharan (Pfizer), William Holmes (AstraZeneca/MedImmune), Peter Honig (Pfizer), Charles Hugh-Jones (Pfizer), Howard Kaufman (Rutgers Cancer Institute of New Jersey), Nasir Khan (Pfizer), David Kozono (Harvard Medical School, Brigham and Women's Hospital, Dana-Farber Cancer Institute), Antonia Kwan (Genentech), Freda C. Lewis-Hall (Pfizer), Sergio Ley-Acosta (Genentech), JoAnn Lindenfeld (Vanderbilt University), Elisabete Michelon (Pfizer), Javid J. Moslehi (Vanderbilt University), Martin J. Murphy (Project Data Sphere), Tomas G. Neilan (Massachusetts General Hospital), Mayur Patel (AstraZeneca/MedImmune), Dejan Pavlovic (AstraZeneca/MedImmune), Francesco Pignatti (European Medicines Agency), Jonathan Potter (Pfizer), David Reese (Amgen), Mace L. Rothenberg (Pfizer), Allan Safferman (Pfizer), Eliza Silvester (Satori Consulting/Pfizer), Richard M. Steingart (Memorial Sloan Kettering Cancer Center), Ryan J. Sullivan (Massachusetts General Hospital), and Ming Zhou (China FDA).

DISCLOSURES

Tomas G. Neilan: Takeda (C/A); **Mace L. Rothenberg:** Pfizer (E); **Ryan J. Sullivan:** Merck, Novartis, Amgen (C/A), Merck, Amgen (RF); **Richard M. Steingart:** Pfizer (Data and safety monitoring board); **William Gregory:** Pfizer (E); **Subramanian Hariharan:** Pfizer (E); **Tarek A. Hammad:** EMD Serono (E); **JoAnn Lindenfeld:** Novartis, Abbott, Edwards, VWave, CVRx, Relypsa, Resmed (C/A), AstraZeneca, Novartis (RF); **Javid J. Moslehi:** Pfizer, Novartis, Bristol-Myers Squibb, Takeda, Regeneron, Daiichi Sankyo, Pharmacyclics (C/A), Pfizer, Bristol-Myers Squibb (RF). The other authors indicated no financial relationships. (C/A) Consulting/advisory relationship; (RF) Research funding; (E) Employment; (ET) Expert testimony; (H) Honoraria received; (OI) Ownership interests; (IP) Intellectual property rights/inventor/patent holder; (SAB) Scientific advisory board

REFERENCES

- Postow MA, Sidlow R, Hellmann MD. Immune-related adverse events associated with immune checkpoint blockade. *N Engl J Med* 2018;378:158–168.
- Boussiotis VA. Molecular and biochemical aspects of the PD-1 checkpoint pathway. *N Engl J Med* 2016;375:1767–1778.
- Rapoport BL, van Eeden R, Sibaud V et al. Supportive care for patients undergoing immunotherapy. *Support Care Cancer* 2017;25:3017–3030.
- Puzanov I, Diab A, Abdallah K et al. Managing toxicities associated with immune checkpoint inhibitors: Consensus recommendations from the Society for Immunotherapy of Cancer (SITC) Toxicity Management Working Group. *J Immunother Cancer* 2017;5:95.
- Brahmer JR, Lacchetti C, Schneider BJ et al. Management of immune-related adverse events in patients treated with immune checkpoint inhibitor therapy: American Society of Clinical Oncology clinical practice guideline. *J Clin Oncol* 2018 [Epub ahead of print].
- Geisler BP, Raad RA, Esaian D et al. Apical ballooning and cardiomyopathy in a melanoma patient treated with ipilimumab: A case of takotsubo-like syndrome. *J Immunother Cancer* 2015;3:4.
- Laubli H, Balmelli C, Bossard M et al. Acute heart failure due to autoimmune myocarditis under pembrolizumab treatment for metastatic melanoma. *J Immunother Cancer* 2015;3:11.

8. Koelzer VH, Rothschild SI, Zihler D et al. Systemic inflammation in a melanoma patient treated with immune checkpoint inhibitors—An autopsy study. *J Immunother Cancer* 2016;4:13.
9. Mehta A, Gupta A, Hannallah F et al. Myocarditis as an immune-related adverse event with ipilimumab/nivolumab combination therapy for metastatic melanoma. *Melanoma Res* 2016;26:319–320.
10. Gibson R, Delaune J, Szady A et al. Suspected autoimmune myocarditis and cardiac conduction abnormalities with nivolumab therapy for non-small cell lung cancer. *BMJ Case Rep* 2016;2016.
11. Heinzerling L, Ott PA, Hodi FS et al. Cardiotoxicity associated with CTLA4 and PD1 blocking immunotherapy. *J Immunother Cancer* 2016;4:50.
12. Semper H, Muehlberg F, Schulz-Menger J et al. Drug-induced myocarditis after nivolumab treatment in a patient with PDL1-negative squamous cell carcinoma of the lung. *Lung Cancer* 2016;99:117–119.
13. Tadokoro T, Keshino E, Makiyama A et al. Acute lymphocytic myocarditis with anti-PD-1 antibody nivolumab. *Circ Heart Fail* 2016;9.
14. Johnson DB, Balko JM, Compton ML et al. Fulminant myocarditis with combination immune checkpoint blockade. *N Engl J Med* 2016;375:1749–1755.
15. Behling J, Kaes J, Munzel T et al. New-onset third-degree atrioventricular block because of autoimmune-induced myositis under treatment with anti-programmed cell death-1 (nivolumab) for metastatic melanoma. *Melanoma Res* 2017;27:155–158.
16. Berg DD, Vaduganathan M, Nohria A et al. Immune-related fulminant myocarditis in a patient receiving ipilimumab therapy for relapsed chronic myelomonocytic leukaemia. *Eur J Heart Fail* 2017;19:682–685.
17. Reuben A, Petaccia de Macedo M, McQuade J et al. Comparative immunologic characterization of autoimmune giant cell myocarditis with ipilimumab. *Oncoimmunology* 2017;6:e1361097.
18. Matson DR, Accola MA, Rehauer WM et al. Fatal myocarditis following treatment with the PD-1 inhibitor nivolumab. *J Forensic Sci* 2018;63:954–957.
19. Fukasawa Y, Sasaki K, Natsume M et al. Nivolumab-induced myocarditis concomitant with myasthenia gravis. *Case Rep Oncol* 2017;10:809–812.
20. Tay RY, Blackley E, McLean C et al. Successful use of equine anti-thymocyte globulin (ATGAM) for fulminant myocarditis secondary to nivolumab therapy. *Br J Cancer* 2017;117:921–924.
21. Arangalage D, Delyon J, Lermuzeaux M et al. Survival after fulminant myocarditis induced by immune-checkpoint inhibitors. *Ann Intern Med* 2017;167:683–684.
22. Chen Q, Huang DS, Zhang LW et al. Fatal myocarditis and rhabdomyolysis induced by nivolumab during the treatment of type B3 thymoma. *Clin Toxicol (Phila)* 2017 [Epub ahead of print].
23. Norwood TG, Westbrook BC, Johnson DB et al. Smoldering myocarditis following immune checkpoint blockade. *J Immunother Cancer* 2017;5:91.
24. Nasr F, El Rassy E, Maalouf G et al. Severe ophthalmoplegia and myocarditis following the administration of pembrolizumab. *Eur J Cancer* 2018;91:171–173.
25. Tajmir-Riahi A, Bergmann T, Schmid M et al. Life-threatening autoimmune cardiomyopathy reproducibly induced in a patient by checkpoint inhibitor therapy. *J Immunother* 2018;41:35–38.
26. Frigeri M, Meyer P, Banfi C et al. Immune checkpoint inhibitor-associated myocarditis: A new challenge for cardiologists. *Can J Cardiol* 2018;34:92.e1–92.e3.
27. Heery CR, Coyne GH, Madan RA et al. Phase I open-label, multiple ascending dose trial of MSB0010718C, an anti-PD-L1 monoclonal antibody, in advanced solid malignancies. *J Clin Oncol* 2014;32(15 suppl):3064a.
28. Eggermont AM, Chiarion-Sileni V, Grob JJ et al. Adjuvant ipilimumab versus placebo after complete resection of high-risk stage III melanoma (EORTC 18071): A randomised, double-blind, phase 3 trial. *Lancet Oncol* 2015;16:522–530.
29. Balar AV, Castellano D, O'Donnell PH et al. First-line pembrolizumab in cisplatin-ineligible patients with locally advanced and unresectable or metastatic urothelial cancer (KEYNOTE-052): A multicentre, single-arm, phase 2 study. *Lancet Oncol* 2017;18:1483–1492.
30. Nghiem PT, Bhatia S, Lipson EJ et al. PD-1 blockade with pembrolizumab in advanced Merkel-cell carcinoma. *N Engl J Med* 2016;374:2542–2552.
31. Suzuki S, Ishikawa N, Konoeda F et al. Nivolumab-related myasthenia gravis with myositis and myocarditis in Japan. *Neurology* 2017;89:1127–1134.
32. Moslehi JJ, Salem JE, Sosman JA et al. Increased reporting of fatal immune checkpoint inhibitor-associated myocarditis. *Lancet* 2018;391:933.
33. Mahmood SS, Fradley MG, Cohen JV et al. Myocarditis in patients treated with immune checkpoint inhibitors. *J Am Coll Cardiol* 2018;71:1755–1764.
34. Escudier M, Cautela J, Malissen N et al. Clinical features, management, and outcomes of immune checkpoint inhibitor-related cardiotoxicity. *Circulation* 2017;136:2085–2087.
35. Andrews A. Treating with checkpoint inhibitors—figure \$1 million per patient. *Am Health Drug Benefits* 2015;8 (Spec Issue):9.
36. Tang J, Shalabi A, Hubbard-Lucey VM. Comprehensive analysis of the clinical immuno-oncology landscape. *Ann Oncol* 2018;29:84–91.
37. U.S. Food and Drug Administration. FDA Public Workshop: Assessment of cardiovascular toxicities in immuno-oncology trials. 2017 (last update: December 1, 2017). Available at <https://www.fda.gov/Drugs/NewsEvents/ucm574741.htm>. Accessed March 8, 2018.
38. Project Data Sphere, LLC. Available at www.ProjectDataSphere.org. Accessed March 12, 2018.
39. Bertagnolli MM, Sartor O, Chabner BA et al. Advantages of a truly open-access data-sharing model. *N Engl J Med* 2017;376:1178–1181.
40. Uppsala Monitoring Centre, WHO Collaborating Centre for International Drug Monitoring. Vigibase. 2018. Available at <https://www.who.int/ucc/vigibase/vigibase/>. Accessed April 2, 2018.
41. Caforio AL, Pankuweit S, Arbustini E et al. Current state of knowledge on aetiology, diagnosis, management, and therapy of myocarditis: A position statement of the European Society of Cardiology Working Group on Myocardial and Pericardial Diseases. *Eur Heart J* 2013;34:2636–2648, 2648a–2648d.
42. Sinagra G, Anzini M, Pereira NL et al. Myocarditis in clinical practice. *Mayo Clin Proc* 2016;91:1256–1266.
43. Seko Y, Yagita H, Okumura K et al. Roles of programmed death-1 (PD-1)/PD-1 ligands pathway in the development of murine acute myocarditis caused by coxsackievirus B3. *Cardiovasc Res* 2007;75:158–167.
44. Lucas JA, Menke J, Rabacal WA et al. Programmed death ligand 1 regulates a critical checkpoint for autoimmune myocarditis and pneumonitis in MRL mice. *J Immunol* 2008;181:2513–2521.
45. Wang J, Okazaki IM, Yoshida T et al. PD-1 deficiency results in the development of fatal myocarditis in MRL mice. *Int Immunol* 2010;22:443–452.
46. Tarrío ML, Grabie N, Bu DX et al. PD-1 protects against inflammation and myocyte damage in T cell-mediated myocarditis. *J Immunol* 2012;188:4876–4884.
47. U.S. Food and Drug Administration, Oncology Center of Excellence. Letter of support for Project Data Sphere, LLC. (last update: April 19, 2017). Available at <https://www.fda.gov/downloads/aboutfda/centersoffices/officeofmedicalproductsandtobacco/ocm/ucm557557.pdf>. Accessed March 12, 2018.
48. Green AK, Reeder-Hayes KE, Corty RW et al. The project data sphere initiative: Accelerating cancer research by sharing data. *The Oncologist* 2015;20:464–e20.