

# UCSF

## UC San Francisco Previously Published Works

### Title

Choroidal Thickness in Multiple Sclerosis: An Optical Coherence Tomography Study

### Permalink

<https://escholarship.org/uc/item/9fw4r700>

### Journal

Journal of Clinical Neurology, 18(3)

### ISSN

1738-6586

### Authors

Masala, Alessandro

Di Mola, Ilaria

Cellerino, Maria

et al.

### Publication Date

2022

### DOI

10.3988/jcn.2022.18.3.334

### Copyright Information

This work is made available under the terms of a Creative Commons Attribution-NonCommercial License, available at <https://creativecommons.org/licenses/by-nc/4.0/>

Peer reviewed



# Choroidal Thickness in Multiple Sclerosis: An Optical Coherence Tomography Study

Alessandro Masala<sup>a,b</sup>

Ilaria Di Mola<sup>a,b</sup>

Maria Cellerino<sup>c</sup>

Valentina Pera<sup>a,b</sup>

Aldo Vagge<sup>a,b</sup>

Antonio Uccelli<sup>b,c</sup>

Cordano Christian<sup>d</sup>

Carlo E Traverso<sup>a,b</sup>

Michele Iester<sup>a,b</sup>

<sup>a</sup>Eye Clinic, Department of Neuroscience, Rehabilitation, Ophthalmology, Genetics, Maternal and Child Health (DiNOGMI), University of Genoa, Genoa, Italy

<sup>b</sup>San Martino IRCCS Policlinic Hospital, Genoa, Italy.

<sup>c</sup>Neurologic Clinic,

Department of Neuroscience, Rehabilitation, Ophthalmology, Genetics, Maternal and Child Health (DiNOGMI) and Center of Excellence

for Biomedical Research (CEBR), University of Genoa, Genoa, Italy

<sup>d</sup>UCSF Weill Institute for Neurosciences, Department of Neurology, University of California, San Francisco, San Francisco, CA, USA

**Background and Purpose** To identify changes in the choroidal thickness (CT) in multiple sclerosis (MS) patients with and without optic neuritis (ON) using enhanced-depth-imaging optical coherence tomography (EDI-OCT).

**Methods** This cross-sectional study included 96 eyes with MS and 28 eyes of healthy controls. All participants underwent an ophthalmologic examination and EDI-OCT scanning (Spectralis, Heidelberg Engineering, Germany) to assess the CT and the retinal nerve fiber layer (RNFL) thickness. MS patients were divided into two groups: 1) with and 2) without a history of ON. The CT was evaluated in the fovea and at six horizontal and six vertical points at 500, 1,000, and 1,500  $\mu\text{m}$  from the fovea. Paired *t*-tests were used to compare the groups, and *p*-value<0.05 was considered as significant.

**Results** At all 13 measurements points, the CT was thicker in MS patients than in the healthy controls and was thinner in eyes with ON than in the contralateral eyes, but these differences were not statistically significant. However, the CT was always larger in all points in eyes with a history of ON than in the control eyes. The RNFL was significantly thinner (*p*<0.05) in both MS and ON eyes than in the control eyes.

**Conclusions** The CT did not differ between MS and control eyes, but it was significantly larger in patients with a history of ON, in whom the RNFL was thinner. Further studies are necessary to establish the possible role of the choroid in MS.

**Keywords** choroidal thickness; optical coherence tomography (OCT); multiple sclerosis; optic neuritis.

## INTRODUCTION

Multiple sclerosis (MS) is an autoimmune disorder that affects the central nervous system, and is characterized by demyelination and neurodegeneration.<sup>1,2</sup> Studies show that this immune-mediated process leads to vascular dysregulation with a high prevalence of vaso-spastic factors.<sup>3</sup> In its most common presentation, MS is characterized by episodes of neurologic dysfunction and relapses, often followed by the progressive accumulation of disability.<sup>4,5</sup>

Several studies of MS patients have identified retinal structural changes using optical coherence tomography (OCT), which is a noninvasive imaging technique used to investigate the retina to assess the retinal nerve fiber layer (RNFL), ganglion cell inner plexiform layer, and inner nuclear layer in patients with or without a clinical history of optic neuritis (ON).<sup>6-17</sup> OCT generates high-resolution images of the retina based on the interference patterns generated by the light reflected by the retinal layers themselves, and can be used to assess the thickness of these layers.

Enhanced-depth-imaging (EDI) OCT (EDI-OCT) provides insight into the layers un-

© This is an Open Access article distributed under the terms of the Creative Commons Attribution Non-Commercial License (<https://creativecommons.org/licenses/by-nc/4.0>) which permits unrestricted non-commercial use, distribution, and reproduction in any medium, provided the original work is properly cited.

**Received** April 16, 2021

**Revised** November 23, 2021

**Accepted** November 24, 2021

### Correspondence

Michele Iester, MD, PhD

Eye Clinic, Department of Neuroscience, Rehabilitation, Ophthalmology, Genetics, Maternal and Child Health (DiNOGMI), University of Genoa,

Viale Benedetto XV, 7,  
Genoa 16132, Italy

**Tel** +39 010 353 7783

**Fax** +39 010 353 8494

**E-mail** iester@unige.it

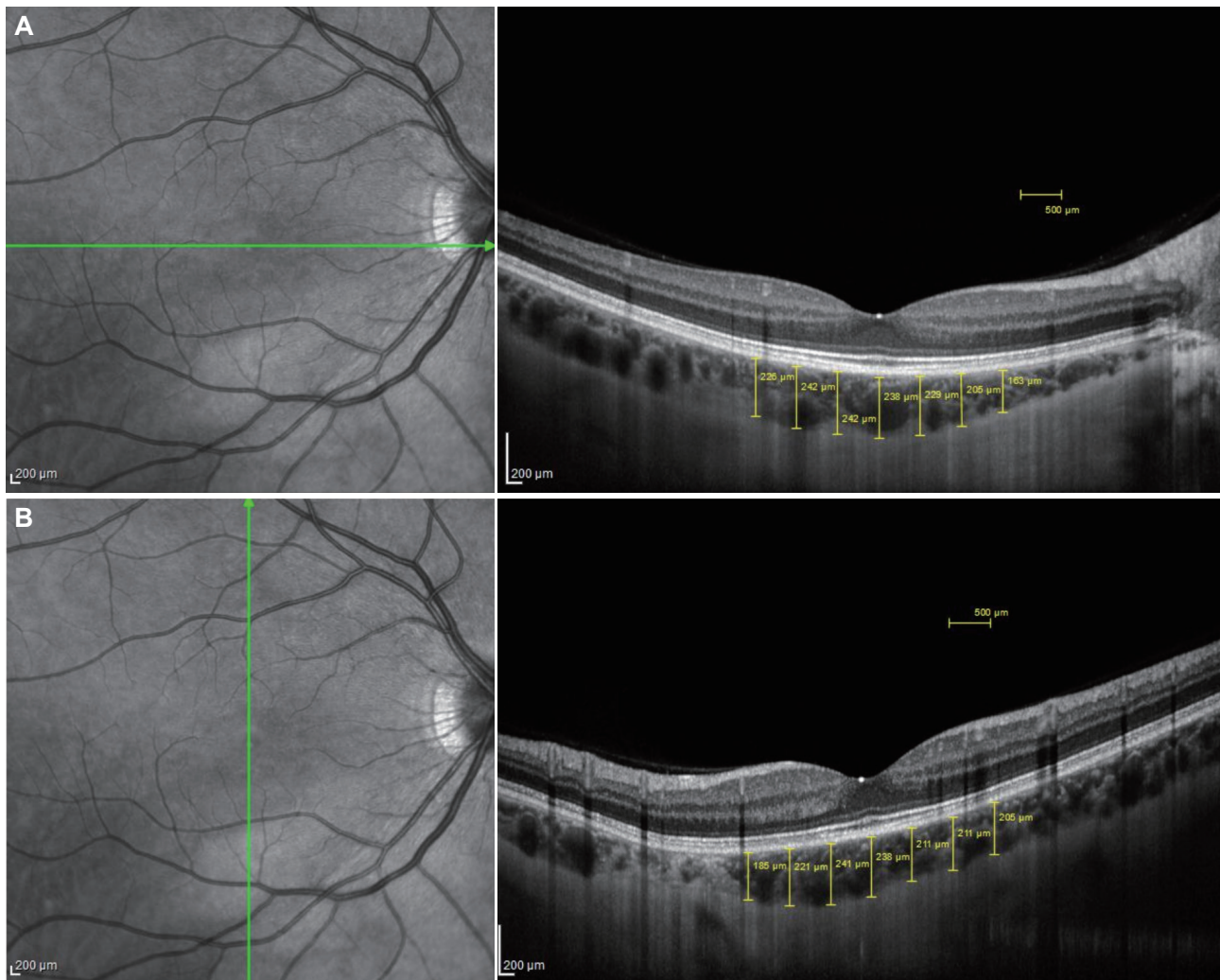
der the retina, and has made it possible to evaluate the aspect of the choroid and its thickness, yielding new research approaches for normal and pathologic choroid processes. A few studies have focused on the choroidal vessels, which could be altered due to the vascular dysregulation associated with MS.<sup>18-20</sup> The present study aimed to measure the choroidal thickness (CT) values in MS patients with and without a clinical history of ON, and compare them with a healthy control group.

## METHODS

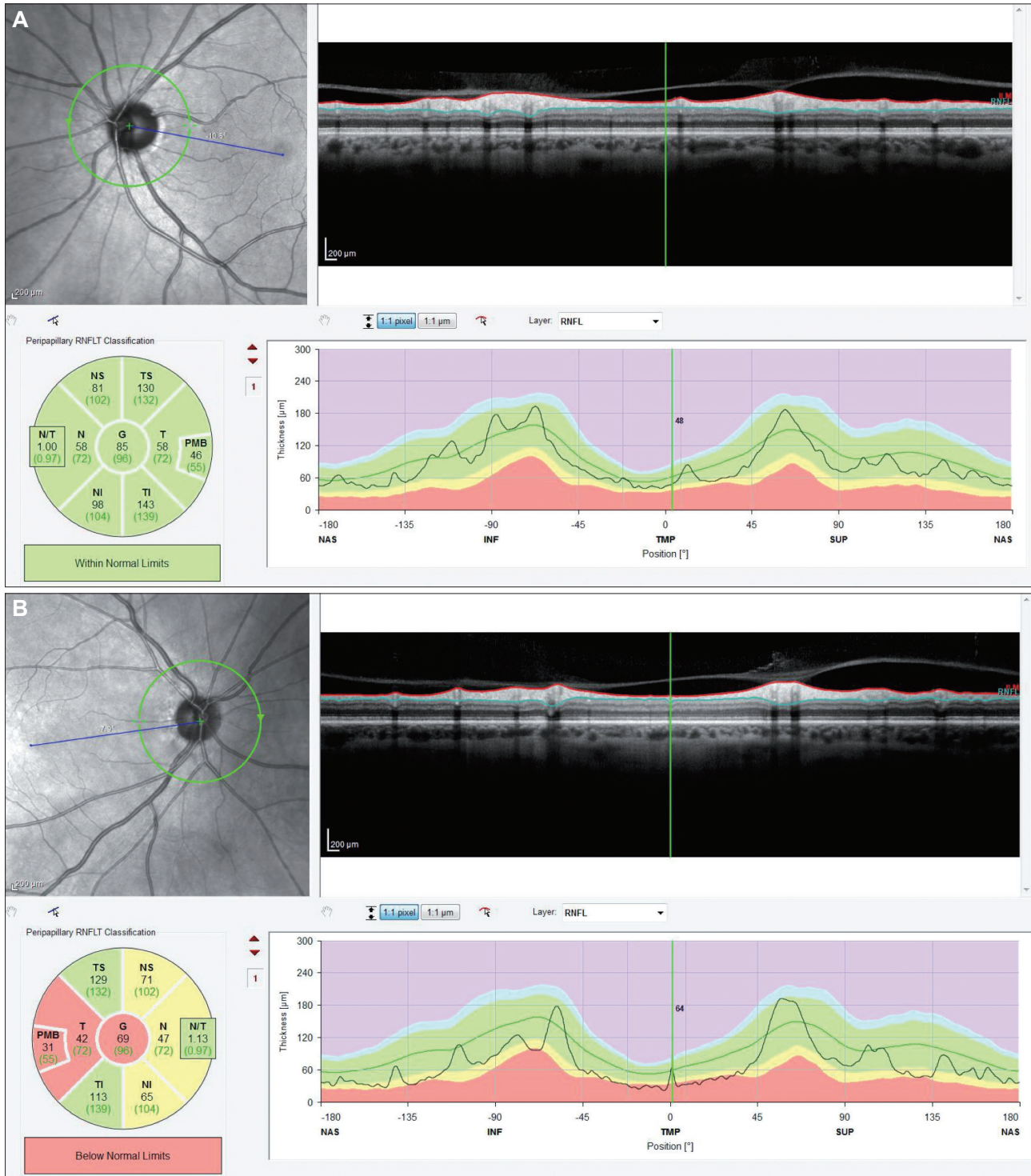
This cross-sectional study included MS patients recruited between November 2016 and March 2017. This study protocol was approved by the appropriate IRB (CER Liguria: 144/2021) and conducted in accordance with the Declaration of Helsinki. All patients submitted informed consents about free to use of the data obtained for clinical purpose.

We included patients with a clinical diagnosis of MS, according to the 2010 McDonald criteria, based on clinical and radiologic findings.<sup>21</sup> Exclusion criteria included symptomatic ON during the 2 months before the OCT assessment, systemic hypertension, diabetes mellitus, other cardiovascular diseases, high myopia or hyperopia with a spherical-equivalent refractive error of  $>5$  or  $<-5$  diopters (D), any retinal or neuro-ophthalmologic disease, a history of intraocular surgery, clinically relevant opacities of the optical media, or low-quality images due to unstable fixation or the presence of a severe cataract.

Patients underwent a complete neurologic assessment and a comprehensive evaluation of physical disability using the Kurtzke Expanded Disability Status Scale (EDSS).<sup>22</sup> Disease duration was defined as the time from the first MS symptom. The MS patients only included those with a history of unilateral ON or without ON. The entire MS group was then divided into two subgroups: 1) with and 2) without a history



**Fig. 1.** Horizontal (A) and vertical (B) macular and choroidal scans with thickness measurements in a right eye. The green line is manually positioned on the fovea, and the yellow lines indicate measurements of the choroidal thickness.



**Fig. 2.** Optical coherence tomography (OCT) print-out. Peripapillary retinal nerve fiber layer (RNFL) thickness measured by optical coherence tomography in a healthy control (A) and a multiple sclerosis patient (B). In both images there is a fundus photo with a green circle which indicates where the measurements have been done (up left); the long image shows an OCT scan of the retina structure along the green circle (up right); in the circle there are the mean values of the RNFL calculated for six sector and globally together with a statistical classification (image A: within normal limits, image B: below normal limits) (down left); the long coloured image is the peripapillary RNFL thickness profile (down right). The three colour represent the normal limit of the measurements (green), the borderline (yellow) and the below normal limits (red). I (INF), inferior; N (NAS), nasal; NI, nasal inferior; NS, nasal superior; N/T, nasal temporal ratio; PMB, papillary-macular bundle; S (SUP), superior; T (TMP), temporal; TI, temporal inferior; TS, temporal-superior.

of ON. Patients included in the study did not have any other systemic comorbidity. The healthy controls were clinic outpatients who had no previous eye disease history, intraocular surgery, glaucomatous optic neuropathy, or history of MS.

All of the patients and controls underwent a comprehensive ocular examination, including autorefractometry, best-corrected visual acuity measurement with Snellen lines, slit-lamp biomicroscopy, intraocular pressure (IOP) measurement, and fundus examination.

### EDI-OCT examination

A single experienced user who was blinded to the clinical diagnosis of the patients performed the EDI-OCT examinations. All subjects were examined with undilated pupils using an EDI system for multimodality diagnostic imaging (wavelength of 870 nm and an EDI scan pattern; Spectralis HRA+ OCT, Heidelberg Engineering, Heidelberg, Germany). Each image represented an average of 100 scans performed using the automatic averaging and eye-tracking features. The macular CT values were measured by selecting horizontal and vertical sections going directly through the center of the fovea. The resultant images were viewed and measured with the supplied Heidelberg Eye Explorer software (version 1.5.12.0, Heidelberg Engineering). The methods used to acquire the images have been reported previously.<sup>23</sup>

Two macular line scans (one horizontal and one vertical) were performed in each eye (Fig. 1), and a circle scan around the optic nerve was used to evaluate the peripapillary RNFL (Fig. 2). The CT was measured manually from the outer portion of the hyperreflective line corresponding to the retinal pigment epithelium to the sclera's inner surface. The CT was manually measured at the fovea (subfoveal area), as well as at 500, 1,000, and 1,500  $\mu\text{m}$  from the fovea vertically (superiorly and inferiorly) and horizontally (temporally and nasally). The choroid was measured by two independent graders (A.M. and V.P.) who were blinded to the diagnosis. If the difference in CT between the two graders was greater than 15% of the mean of the two values, open adjudication was performed with another observer (M.I.). The values of the measurements were compared for each observer and then averaged for analysis. The images were obtained with the best visualization of the border between the choroid and the sclera, known as the choroidal-scleral interface (CSI). If the CSI was not identifiable in the image, additional images were obtained to have the best possible view of the CSI (Fig. 1). The peripapillary RNFL were analyzed globally and in six sectors: nasal, nasal superior, temporal superior, temporal, temporal inferior, and nasal inferior.

### Statistical analysis

Statistical analyses were performed using the SPSS statistical software package (IBM SPSS Statistics version 21, IBM, Armonk, NY, USA). The entire group was divided into two subgroups: 1) healthy control group and 2) patients with MS. The latter subgroup was split into patients 1) with a history of ON (ON group) and 2) without a history of ON (non-ON group). Furthermore, to better analyze the effect of ON on the choroid, MS patients with a monolateral ON history were selected and compared with their contralateral non-ON eyes and with the healthy control group. Descriptive analysis was used to obtain the mean  $\pm$  standard deviation values of all included parameters, and paired *t*-tests were used to compare the groups, with a *p* value  $<0.05$  considered significant.

## RESULTS

The 62 subjects examined were divided into 2 groups: 48 MS patients (33 females and 15 males) and 14 healthy controls (9 females and 5 males). The age in the MS group ranged from 22 to 69 years ( $45 \pm 12$  years), and that in the control group was from 23 to 55 years ( $38 \pm 12$  years). The refractive error was  $-2.25 \pm 1.74$  D in the MS group and  $-1.78 \pm 3.39$  D in the control group. The MS group comprised 39 patients with relapsing-remitting MS, 7 with secondary progressive MS, and 2 with primary progressive MS. The mean duration of the pathology was 11.8 years, and the EDSS score was  $3 \pm 2$ .

The MS group ( $n=96$  eyes) was split into 2 subgroups on the basis of ON history: 25 eyes in the ON group and 71 eyes in the non-ON group. Furthermore, in the ON group, patients with a monocular ON history were selected ( $n=17$  eyes), and the ON eye was compared both with the contralateral eye and with the healthy control group.

At all of the measured points, the mean subfoveal CT was thicker in MS patients than in the control group ( $338 \mu\text{m}$  vs.  $313 \mu\text{m}$ ), but these differences were not statistically significant (Table 1). A similar tendency in the CT was present at 500, 1,000, and 1,500  $\mu\text{m}$  from the fovea both vertically and horizontally. The subfoveal CT was measured twice during the vertical and horizontal scans, which produced the same CT values (Table 1).

The CT did not differ significantly between healthy eyes and either the ON or non-ON group (Table 1). All of the measurements showed that CT was thicker in MS patients than in the control group. However, in the monocular ON subgroup, when each eye with ON history was compared with the contralateral one, the CT was thinner in the ON eye than in the contralateral eye, but the difference was not statistically significant ( $p>0.05$ ) (Table 2). A similar tendency was present at 500, 1,000, and 1,500  $\mu\text{m}$  from the fovea both ver-

**Table 1.** Comparison between healthy controls and multiple sclerosis (MS) patients

	Healthy eyes (1) (n=28)	MS eyes (2) (n=96)	t-test (1 vs. 2)	p	Non-ON MS eyes (3) (n=71)	t-test (1 vs. 3)	p	ON MS eyes (4) (n=25)	t-test (1 vs. 4)	p	t-test (3 vs. 4)	p
Visual acuity (letters)	82.06±5.26	75.16±15.91	1.71	0.089	78.10±11.88	1.3	0.197	67.04±22.07	-2.66	0.011*	-3.12	0.002*
Hsubfoveal (µm)	312.54±7.45	337.65±90.29	-1.34	0.182	331.01±89.18	-0.97	0.334	356.48±92.61	1.91	0.061	1.22	0.227
Hnasal 500 (µm)	297.00±7.97	320.66±85.00	-1.33	0.187	313.83±85.42	-0.912	0.364	339.92±82.43	1.97	0.054	1.32	0.189
Hnasal 1,000 (µm)	281.07±80.78	303.91±83.99	-1.28	0.204	298.92±86.02	-0.945	0.347	318.08±77.82	1.69	0.096	0.98	0.329
Hnasal 1,500 (µm)	253.75±81.62	279.46±84.58	-1.43	0.156	273.96±87.24	-1.056	0.293	295.08±75.99	1.90	0.063	1.08	0.285
Htemporal 500 (µm)	313.39±75.09	327.96±90.04	-0.78	0.437	321.39±88.03	-0.424	0.673	346.60±94.85	1.42	0.162	1.21	0.231
Htemporal 1,000 (µm)	301.18±73.24	323.91±90.87	-1.21	0.228	319.82±87.59	-0.996	0.322	335.52±100.59	1.43	0.158	0.74	0.460
Htemporal 1,500 (µm)	293.39±70.88	314.85±85.15	-1.22	0.227	311.04±78.81	-1.031	0.305	325.68±102.06	1.35	0.183	0.74	0.463
Vsubfoveal (µm)	313.29±69.22	338.42±84.78	-1.43	0.154	335.52±84.74	-1.234	0.22	346.64±86.10	1.56	0.125	0.56	0.576
Vsup 500 (µm)	308.96±66.07	332.09±79.85	-1.40	0.165	328.21±80.46	-1.124	0.264	343.12±78.64	1.72	0.092	0.80	0.425
Vsup 1,000 (µm)	305.46±67.80	323.73±80.12	-1.10	0.275	317.49±81.04	-0.695	0.489	341.44±76.24	1.82	0.075	1.29	0.200
Vsup 1,500 (µm)	311.43±67.18	323.38±77.14	-0.74	0.460	318.11±77.74	-0.4	0.69	338.32±74.92	1.38	0.174	1.13	0.262
Vinf 500 (µm)	312.46±71.22	324.59±84.63	-0.69	0.492	322.60±82.23	-0.574	0.567	330.20±92.64	0.79	0.435	0.38	0.702
Vinf 1,000 (µm)	303.29±78.47	310.92±88.67	-0.41	0.682	306.82±83.67	-0.192	0.848	322.56±102.52	0.77	0.443	0.76	0.448
Vinf 1,500 (µm)	305.43±70.88	304.17±86.01	0.07	0.944	299.06±80.46	0.366	0.715	318.68±100.51	0.56	0.578	0.98	0.329
Global RNFL (µm)	107.46±9.74	90.94±16.96	4.66	<0.001*	96.36±13.49	3.676	<0.001*	78.11±17.73	-7.12	<0.001*	-4.49	<0.001*
Temp RNFL (µm)	79.00±15.07	59.97±17.72	4.81	<0.001*	65.56±16.49	3.413	0.001*	46.74±13.11	-7.48	<0.001*	-4.41	<0.001*
Sup-temp RNFL (µm)	149.73±23.53	130.95±25.30	3.25	0.002*	139.62±19.66	1.941	0.056	110.42±25.75	-5.32	<0.001*	-4.94	<0.001*
Sup-nas RNFL (µm)	115.92±22.83	103.66±23.67	2.25	0.027*	107.62±22.31	1.498	0.139	94.26±24.74	-3.04	0.004*	-2.12	0.038*
Nas RNFL (µm)	74.39±12.11	67.08±16.97	2.00	0.049*	70.71±14.73	1.078	0.285	58.47±19.15	-3.41	0.001*	-2.77	0.007*
Inf-nas RNFL (µm)	121.89±17.41	103.77±22.86	3.63	<0.001*	106.80±21.47	3.047	0.003*	96.58±24.99	-4.01	<0.001*	-1.66	0.103
Inf-temp RNFL (µm)	164.65±13.89	136.89±30.01	4.51	<0.001*	146.82±23.01	3.586	0.001*	113.37±32.05	-7.30	<0.001*	-4.71	<0.001*

Values are presented as mean±standard deviation unless otherwise indicated. Paired t-test is used to compare the groups. Choroidal thickness (CT) was measured at the fovea in horizontal measurements (Hsubfoveal), then at 500, 1,000, and 1,500 mm in the nasal (Hnasal) and temporal (Htemporal) parts; CT was measured at the fovea in vertical measurements (Vsubfoveal), then at 500, 1,000, and 1,500 mm in the superior (Vsup) and inferior (Vinf) parts.

\*Indicates significant differences.  
inf, inferior; nas, nasal; ON, optic neuritis; RNFL, retinal nerve fiber layer; SD, standard deviation; sup, superior; temp, temporal.

**Table 2.** Comparison between eyes in monocular ON multiple sclerosis (MS) patients and healthy controls

	Monolateral ON eyes (n=17)	Contralateral eyes (n=17)	t-test (ON vs. Contralateral)	P	Healthy eyes (n=28)	t-test (ON vs. Healthy)	P
Visual acuity (letters)	72.47±22.43	78.18±19.32	-0.80	0.433	82.06±5.26	1.67	0.106
Hsubfoveal (µm)	394.94±86.29	401.53±98.83	-0.21	0.837	312.54±74.45	-3.39	0.002*
Hnasal 500 (µm)	376.06±74.75	382.06±90.41	-0.21	0.834	297.00±75.97	-3.41	0.001*
Hnasal 1,000 (µm)	351.71±69.47	368.88±82.15	-0.66	0.515	281.07±80.78	-2.99	0.005*
Hnasal 1,500 (µm)	323.35±72.21	341.35±78.35	-0.70	0.491	253.75±81.62	-2.89	0.006*
Htemporal 500 (µm)	385.06±88.48	396.53±97.31	-0.36	0.722	313.39±75.09	-2.90	0.006*
Htemporal 1,000 (µm)	377.24±89.40	399.71±106.77	-0.67	0.511	301.18±73.24	-3.11	0.003*
Htemporal 1,500 (µm)	368.35±89.83	377.71±98.65	-0.29	0.774	293.39±70.88	-3.11	0.003*
Vsubfoveal (µm)	382.12±80.84	392.88±87.63	-0.37	0.712	313.29±69.22	-3.04	0.004*
Vsup 500 (µm)	373.77±76.96	382.12±83.71	-0.30	0.764	308.96±66.07	-3.00	0.005*
Vsup 1,000 (µm)	370.24±75.62	373.77±86.58	-0.13	0.900	305.46±67.80	-2.98	0.005*
Vsup 1,500 (µm)	364.41±76.86	365.65±85.05	-0.04	0.965	311.43±67.18	-2.43	0.019*
Vinf 500 (µm)	369.47±82.84	388.71±86.00	-0.66	0.511	312.46±71.22	-2.45	0.019*
Vinf 1,000 (µm)	362.94±93.23	371.53±82.77	-0.28	0.778	303.29±78.47	-2.30	0.026*
Vinf 1,500 (µm)	357.35±91.73	356.88±79.09	0.02	0.987	305.43±70.88	-2.13	0.039*
Global RNFL (µm)	84.77±14.69	94.39±15.27	-1.64	0.115	107.46±9.74	5.77	<0.001*
Temp RNFL (µm)	50.46±13.41	57.00±14.67	-1.19	0.247	79.00±15.07	5.77	<0.001*
Sup-temp RNFL (µm)	120.62±20.45	138.00±21.57	-2.11	0.046	149.73±23.53	3.80	0.001*
Sup-nas RNFL (µm)	101.15±21.85	108.69±19.63	-0.93	0.364	115.92±22.83	1.93	0.061*
Nas RNFL (µm)	63.92±16.21	70.54±14.88	-1.08	0.289	74.39±12.11	2.27	0.029*
Inf-nas RNFL (µm)	102.92±22.38	111.62±24.82	-0.94	0.358	121.89±17.41	2.91	0.006*
Inf-temp RNFL (µm)	124.85±31.75	143.23±25.69	-1.62	0.118	164.65±13.89	5.48	<0.001*

Values are presented as mean±standard deviation unless otherwise indicated. Paired t-test is used to compare the groups.

\*Indicates significant differences.

inf, inferior; nas, nasal; ON, optic neuritis; RNFL, retinal nerve fiber layer; sup, superior; temp, temporal.

tically and horizontally. In contrast, when these eyes with an ON history were compared with the healthy control group for both CT and RNFL thickness (Table 2), significant differences ( $p < 0.001$ ) were found. In particular, the RNFL was thinner in MS patients than in the controls in all sectors (global:  $91 \mu\text{m}$  vs.  $107 \mu\text{m}$ ) (Table 1), and the RNFL was also significantly thinner ( $p < 0.05$ ) in ON eyes than in healthy control eyes (Tables 1 and 2) in all but one of the sectors. The same tendency was found between the ON and non-ON groups: patients with a history of ON had a thinner RNFL, with the difference being significant in the three temporal sectors.

## DISCUSSION

Since the choroid is a dynamic vascular structure, the CT might represent its vascularity. The CT can change due to several factors, such as age, IOP, blood pressure, refractive errors, and axial length.<sup>24,25</sup> The role of vascular dysregulation in MS is still unclear.<sup>26</sup> Blood flow changes in patients affected by MS have been detected by color Doppler ultrasonography, especially when an episode of ON has occurred.<sup>27</sup> However, few studies have evaluated the condition of the choroid in these patients. Esen et al.<sup>28</sup> used OCT to assess the CT of patients with MS and healthy controls, and observed significant thinning of the vascular layer in the MS patients. Similar findings were obtained using swept-source OCT, with vascular thinning found in MS patients both in the macular and peripapillary areas of the choroid.<sup>29,30</sup> Doğan et al.<sup>6</sup> found no meaningful difference in the CT between patients with MS and healthy controls. However, they found that the CT was larger in patients with ON than in non-ON patients, suggesting that the choroidal layer could be altered due to the inflammation induced by the disease. Also, Yuksel et al.<sup>31</sup> found an increased CT in MS patients.

The present study applied EDI-OCT to MS patients with and without a clinical history of ON and also to age-matched healthy controls to identify any differences in CT. No significant difference was found between MS patients and healthy controls, or between ON and non-ON MS patients. Nevertheless, there was a tendency for a significant difference in CT measurements between ON MS patients and healthy controls. The CT was always larger in MS patients with ON than in both MS patients without ON and healthy controls (Table 1). These data reflect the possible role of inflammation in the physiopathology of axonal damage and choroid vascular alterations. A correlation between alterations in the CT and systemic inflammatory diseases has been reported previously,<sup>32,33</sup> suggesting that the choroid is influenced by inflammation; however, the results were contradictory even in these studies.

Several studies have already identified a strong correlation

between the neurodegenerative damage induced by MS and the thinning of the RNFL in patients affected by MS. In particular, a significant reduction in the RNFL thickness has been found in patients affected by MS relative to healthy controls.<sup>10</sup> The present study found that subjects affected by MS had a significantly thinner ( $p < 0.05$ ) RNFL than did age-matched healthy controls (Tables 1 and 2). Furthermore, MS patients with a clinical history of ON had an even thinner RNFL than those without direct involvement of the optic nerve. Our findings are therefore consistent with the previous studies, reaffirming the value of using OCT to measure the RNFL thickness as a useful marker of MS progression both in patients with clinical and with subclinical retinal damage. Huang-Link et al.<sup>11</sup> showed that even in so-called benign MS, patients without a history of ON can present thinning of the RNFL and the macular ganglion cell layer. Garcia-Martin et al.<sup>34</sup> found that OCT could detect changes in the average thickness of the RNFL when there were no changes in visual acuity, color vision, or visual fields, showing that OCT of the RNFL can detect subclinical neurodegenerative damage. Moreover, they identified a correlation between increased EDSS score and thinning of the RNFL in its temporal and superior quadrants.

Magnetic resonance imaging (MRI) represents the standard examination method for following up MS patients. Even though MRI is a very accurate method for detecting cerebral atrophy, its restricted availability, high cost, and presence of confounders (e.g., hydration status, inflammation) remain essential limitations explaining why MRI is not an ideal examination method. Several studies in recent years have highlighted the potential key role of OCT as a complementary examination method to MRI for assessing MS progression.<sup>35</sup> Furthermore, the CT could be a new parameter to follow, since it can be examined noninvasively and is easy to measure in almost all patients except those with a lack of fixation or involuntary eye movements.

Considering that the eye is the only body location where the condition of axons can be observed directly and noninvasively, monitoring the thinning of the RNFL could allow clinicians to follow the evolution of neurodegeneration in patients.

We acknowledge some limitations of this study. First, the relatively small study population may have restricted the ability to detect significant differences in some of the investigated parameters. Second, there was a discrepancy between the numbers of MS patients and healthy controls. Third, the CT was measured in the macular area but not in the peripapillary area. Fourth, the choroid measurements were made manually, which could have affected their accuracy. This could be improved in the future by using an automated measure-



ment system. Notwithstanding the above limitations, our study also had some significant strengths. Although it was not significant, the CT was always larger in the MS patients than in the healthy controls. The CT difference was significant in the MS patients with a monolateral ON history, confirming the presence of RNFL thinning in MS patients and more so in the ON patients.

In conclusion, the data reported here confirm the role of RNFL evaluations as a biomarker for neurodegeneration in MS and its value as a complementary examination to MRI in following up these patients. Furthermore, changes in the CT have been identified in MS, suggesting that they play a role in systemic inflammatory pathogenesis. However, it needs to be remembered that these CT differences obtained in the present and previous studies could be caused by the dynamic nature of these vessels, which can vary with the age, sex, systemic conditions, and axial length of the eyes of individual patients.<sup>36</sup> Also, Green et al.<sup>37</sup> suggested that OCT could help physician to distinguish inflammation from tissue atrophy in MS patients. Future studies need to clarify the nature and meaning of these modifications.

#### Availability of Data and Material

The datasets generated or analyzed during the study are not publicly available due to the dataset is still under analysis for another study but are available from the corresponding author on reasonable request.

#### ORCID iDs

Alessandro Masala	<a href="https://orcid.org/0000-0002-6424-531X">https://orcid.org/0000-0002-6424-531X</a>
Ilaria Di Mola	<a href="https://orcid.org/0000-0001-6907-7012">https://orcid.org/0000-0001-6907-7012</a>
Maria Cellerino	<a href="https://orcid.org/0000-0002-4359-9872">https://orcid.org/0000-0002-4359-9872</a>
Aldo Vagge	<a href="https://orcid.org/0000-0002-9346-9267">https://orcid.org/0000-0002-9346-9267</a>
Antonio Uccelli	<a href="https://orcid.org/0000-0002-2008-6038">https://orcid.org/0000-0002-2008-6038</a>
Cordano Christian	<a href="https://orcid.org/0000-0002-1413-0442">https://orcid.org/0000-0002-1413-0442</a>
Carlo E Traverso	<a href="https://orcid.org/0000-0002-0510-6651">https://orcid.org/0000-0002-0510-6651</a>
Michele Iester	<a href="https://orcid.org/0000-0002-0524-2637">https://orcid.org/0000-0002-0524-2637</a>

#### Author Contributions

Conceptualization: Michele Iester, Alessandro Masala. Data curation: Michele Iester, Alessandro Masala. Formal analysis: Michele Iester. Investigation: Alessandro Masala, Ilaria Di Mola, Maria Cellerino, Valentina Pera. Methodology: Michele Iester, Alessandro Masala, Valentina Pera. Project administration: Michele Iester, Maria Cellerino. Writing—original draft: Alessandro Masala, Michele Iester, Cordano Christian. Writing—review & editing: Carlo E Traverso, Antonio Uccelli, Aldo Vagge, Michele Iester, Alessandro Masala, Maria Cellerino.

#### Conflicts of Interest

The authors have no potential conflicts of interest to disclose.

#### Funding Statement

This work was developed within the framework of the DINOGMI Department of Excellence of MIUR 2018-2022 (Law 232 of 2016). This work was supported by grant from Italian Ministry of Health-ACC.

## REFERENCES

1. Compston A, Coles A. Multiple sclerosis. *Lancet* 2008;372:1502-1517.

2. Frischer JM, Bramow S, Dal-Bianco A, Lucchinetti CF, Rauschka H, Schmidbauer M, et al. The relation between inflammation and neurodegeneration in multiple sclerosis brains. *Brain* 2009;132:1175-1189.
3. Pache M, Kaiser HJ, Akhalbedashvili N, Lienert C, Dubler B, Kappos L, et al. Extraocular blood flow and endothelin-1 plasma levels in patients with multiple sclerosis. *Eur Neurol* 2003;49:164-168.
4. Kale N. Optic neuritis as an early sign of multiple sclerosis. *Eye Brain* 2016;8:195-202.
5. Toosy AT, Mason DF, Miller DH. Optic neuritis. *Lancet Neurol* 2014;13:83-99.
6. Doğan Ü, Ulaş F, Türkoğlu ŞA, Ögün MN, Ağca S. Eyes are mirror of the brain: comparison of multiple sclerosis patients and healthy controls using OCT. *Int J Neurosci* 2019;129:848-855.
7. Frau J, Fenu G, Signori A, Coghe G, Lorefice L, Barracciu MA, et al. A cross-sectional and longitudinal study evaluating brain volumes, RNFL, and cognitive functions in MS patients and healthy controls. *BMC Neurol* 2018;18:67.
8. Iester M, Cioli F, Uccelli A, Papadia M, Bandini F, Mancardi GL, et al. Retinal nerve fibre layer measurements and optic nerve head analysis in multiple sclerosis patients. *Eye (Lond)* 2009;23:407-412.
9. Iester M, Cordano C, Costa A, D'Alessandro E, Panizzi A, Bisio F, et al. Effectiveness of time domain and spectral domain optical coherence tomograph to evaluate eyes with and without optic neuritis in multiple sclerosis patients. *J Mult Scler* 2016;3:173.
10. Cennamo G, Romano MR, Vecchio EC, Minervino C, Della Guardia C, Velotti N, et al. Anatomical and functional retinal changes in multiple sclerosis. *Eye (Lond)* 2016;30:456-462.
11. Huang-Link YM, Fredrikson M, Link H. Benign multiple sclerosis is associated with reduced thinning of the retinal nerve fiber and ganglion cell layers in non-optic-neuritis eyes. *J Clin Neurol* 2015;11:241-247.
12. Cordano C, Nourbakhsh B, Devereux M, Damotte V, Bennett D, Hauser SL, et al. pRNFL as a marker of disability worsening in the medium/long term in patients with MS. *Neurol Neuroimmunol Neuroinflamm* 2018;6:e533.
13. Caverzasi E, Cordano C, Zhu AH, Zhao C, Bischof A, Kirkish G, et al. Imaging correlates of visual function in multiple sclerosis. *PLoS One* 2020;15:e0235615.
14. Martinez-Lapiscina EH, Arnow S, Wilson JA, Saidha S, Preingerova JL, Oberwahrenbrock T, et al. Retinal thickness measured with optical coherence tomography and risk of disability worsening in multiple sclerosis: a cohort study. *Lancet Neurol* 2016;15:574-584.
15. Petracca M, Cordano C, Cellerino M, Button J, Krieger S, Vancea R, et al. Retinal degeneration in primary-progressive multiple sclerosis: a role for cortical lesions? *Mult Scler* 2017;23:43-50.
16. Cellerino M, Cordano C, Boffa G, Bommarito G, Petracca M, Sbragia E, et al. Relationship between retinal inner nuclear layer, age, and disease activity in progressive MS. *Neurol Neuroimmunol Neuroinflamm* 2019;6:e596.
17. Cordano C, Yiu HH, Oertel FC, Gelfand JM, Hauser SL, Cree BAC, et al. Retinal INL thickness in multiple sclerosis: a mere marker of neurodegeneration? *Ann Neurol* 2021;89:192-193.
18. Konieczka K, Erb C. Diseases potentially related to Flammer syndrome. *EPMA J* 2017;8:327-332.
19. Konieczka K, Koch S, Binggeli T, Schoetzau A, Kesselring J. Multiple sclerosis and primary vascular dysregulation (Flammer syndrome). *EPMA J* 2016;7:13.
20. Flammer J, Pache M, Resink T. Vasospasm, its role in the pathogenesis of diseases with particular reference to the eye. *Prog Retin Eye Res* 2001;20:319-349.
21. Polman CH, Reingold SC, Banwell B, Clanet M, Cohen JA, Filippi M, et al. Diagnostic criteria for multiple sclerosis: 2010 revisions to the McDonald criteria. *Ann Neurol* 2011;69:292-302.
22. Kurtzke JF. A new scale for evaluating disability in multiple sclerosis. *Neurology* 1955;5:580-583.

23. Huang W, Wang W, Gao X, Li X, Li Z, Zhou M, et al. Choroidal thickness in the subtypes of angle closure: an EDI-OCT study. *Invest Ophthalmol Vis Sci* 2013;54:7849-7853.
24. Goharian I, Sehi M. Is there any role for the choroid in glaucoma? *J Glaucoma* 2016;25:452-458.
25. Zhang X, Cole E, Pillar A, Lane M, Waheed N, Adhi M, et al. The effect of change in intraocular pressure on choroidal structure in glaucomatous eyes. *Invest Ophthalmol Vis Sci* 2017;58:3278-3285.
26. Cedola A, Bravin A, Bukreeva I, Fratini M, Pacureanu A, Mittone A, et al. X-ray phase contrast tomography reveals early vascular alterations and neuronal loss in a multiple sclerosis model. *Sci Rep* 2017;7:5890.
27. Modrzejewska M, Karczewicz D, Wilk G. Assessment of blood flow velocity in eyeball arteries in multiple sclerosis patients with past retrobulbar optic neuritis in color Doppler ultrasonography. *Klin Oczna* 2007;109:183-186.
28. Esen E, Sizmaz S, Demir T, Demirkiran M, Unal I, Demircan N. Evaluation of choroidal vascular changes in patients with multiple sclerosis using enhanced depth imaging optical coherence tomography. *Ophthalmologica* 2016;235:65-71.
29. Garcia-Martin E, Jarauta L, Pablo LE, Bambo MP, Ara JR, Martin J, et al. Changes in peripapillary choroidal thickness in patients with multiple sclerosis. *Acta Ophthalmol* 2019;97:e77-e83.
30. Garcia-Martin E, Jarauta L, Vilades E, Ara JR, Martin J, Polo V, et al. Ability of swept-source optical coherence tomography to detect retinal and choroidal changes in patients with multiple sclerosis. *J Ophthalmol* 2018;2018:7361212.
31. Yuksel B, Dogan B, Koctekin B, Atis N, Erdal A, Kurtulus F, et al. Color vision testing versus pattern visual evoked potentials and optical coherence tomography parameters in subclinical optic nerve involvement in multiple sclerosis. *J Clin Neurosci* 2019;61:48-53.
32. Ferreira CS, Beato J, Falcão MS, Brandão E, Falcão-Reis F, Carneiro ÂM. Choroidal thickness in multisystemic autoimmune diseases without ophthalmologic manifestations. *Retina* 2017;37:529-535.
33. Altinkaynak H, Duru N, Uysal BS, Erten Ş, Kürkcüoğlu PZ, Yuksel N, et al. Choroidal thickness in patients with systemic lupus erythematosus analyzed by spectral-domain optical coherence tomography. *Ocul Immunol Inflamm* 2016;24:254-260.
34. Garcia-Martin E, Ara JR, Martin J, Almarcegui C, Dolz I, Vilades E, et al. Retinal and optic nerve degeneration in patients with multiple sclerosis followed up for 5 years. *Ophthalmology* 2017;124:688-696.
35. Gordon-Lipkin E, Calabresi PA. Optical coherence tomography: a quantitative tool to measure neurodegeneration and facilitate testing of novel treatments for tissue protection in multiple sclerosis. *J Neuroimmunol* 2017;15;304:93-96.
36. Kim M, Kim SS, Kwon HJ, Koh HJ, Lee SC. Association between choroidal thickness and ocular perfusion pressure in young, healthy subjects: enhanced depth imaging optical coherence tomography study. *Invest Ophthalmol Vis Sci* 2012;53:7710-7717.
37. Green AJ, McQuaid S, Hauser SL, Allen IV, Lyness R. Ocular pathology in multiple sclerosis: retinal atrophy and inflammation irrespective of disease duration. *Brain* 2010;133:1591-1601.