

UC Davis

Dermatology Online Journal

Title

Acrokeratoelastoidosis

Permalink

<https://escholarship.org/uc/item/9hj2k1xq>

Journal

Dermatology Online Journal, 21(12)

Authors

Mu, Euphemia W
Mir, Adnan
Meehan, Shane A
et al.

Publication Date

2015

DOI

10.5070/D32112029527

Copyright Information

Copyright 2015 by the author(s). This work is made available under the terms of a Creative Commons Attribution-NonCommercial-NoDerivatives License, available at <https://creativecommons.org/licenses/by-nc-nd/4.0/>

Peer reviewed

Case presentation

Acrokeratoelastoidosis

Euphemia W Mu MD, Adnan Mir MD PhD, Shane A Meehan MD and Nathalie Nguyen MD

Dermatology Online Journal 21 (12): 2

New York University School of Medicine

Special Guest Editor: Nicholas A Soter MD

Abstract

Acrokeratoelastoidosis is a rare palmoplantar keratoderma. We report the case of a 32-year old man with multiple keratotic papules and plaques on the peripheral margins of his hands and feet. Histopathologic evaluation showed compact orthokeratosis; Verhoeff van Gieson stain showed thin and fragmented elastic fibers. The differential diagnosis includes focal acral hyperkeratosis, which has a similar presentation but with normal elastic fibers. Treatment of acrokeratoelastoidosis is often disappointing, with minimal response to topical glucocorticoids, keratolytics, retinoids, cryotherapy, and lasers.

Case synopsis

History: A 32-year-old man presented to the Bellevue Hospital Center Dermatology Clinic for evaluation of multiple papules on his hands and feet that appeared over the past year. The affected areas were associated with a mildly pruritic and intermittently burning sensation. The lesions on his hands and feet developed around the same time and were increasing in number. The patient worked part-time as a construction worker and dishwasher and believed that the initial skin eruption occurred after exposures to various occupational chemicals and detergents. There was no history of trauma, hyperhidrosis, or prolonged exposure to the sun. Neither the patient nor his close contacts had a history of similar lesions. The patient was otherwise well with no relevant family or personal medical history. He was treated with urea 40% cream twice daily and clobetasol 0.05% ointment twice daily for three weeks without improvement.

Physical examination: Multiple, 2-to-3-mm, tan, firm papules were clustered along the peripheral margins of the palms and soles.

Laboratory: None.

Histopathology: There is hyperkeratotic compact orthokeratosis. Within the dermis, a Verhoeff-van Gieson stain shows thinning and fragmentation of elastic fibers.

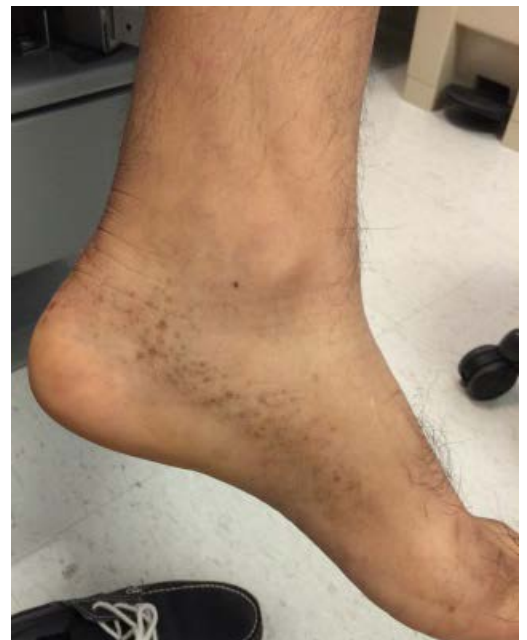

Figure 1. Keratotic papules along sole margin

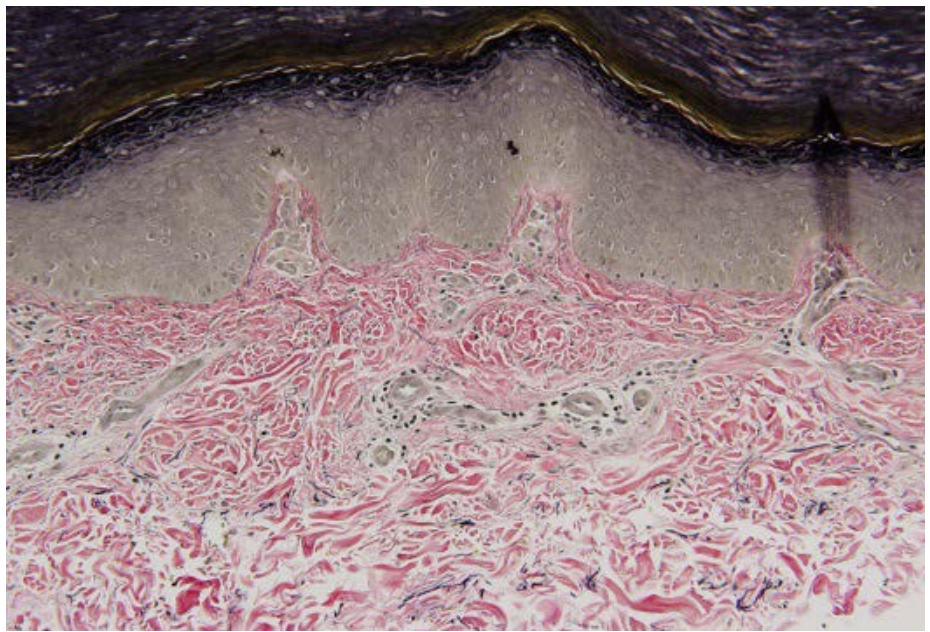
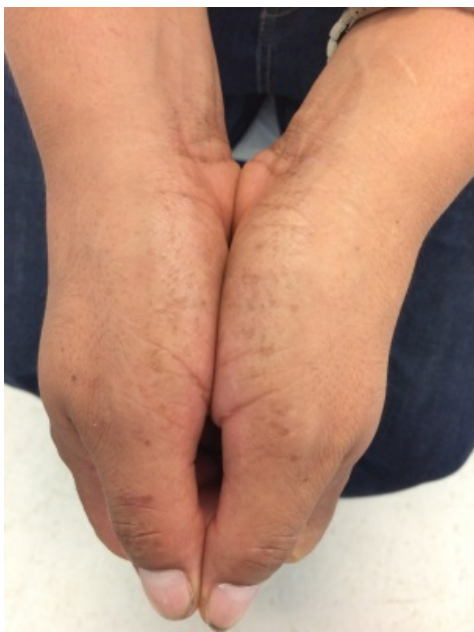

Figure 2. Keratotic papules along palm margin Figure 3. Thinning and fragmentation of elastic fibers

Discussion

Diagnosis: Acrokeratoelastoidosis

COMMENT: Acrokeratoelastoidosis (AKE) is a rare palmoplantar keratoderma that was first described by Oswaldo Gonçalves Costa in 1953 [1, 2]. Clinical characteristics of this condition include keratotic papules and plaques on the lateral margins of the hand and feet that follow the lines of transgredience, with variable association with hyperhidrosis [2]. No correlation with race, age, or gender has been defined [3].

AKE has been linked with both hereditary and sporadic mutations on chromosome 2 [4, 5]. Although the pathogenesis of AKE has yet to be elucidated, some patients report a history of chronic trauma [6]. The characteristic keratotic papules likely are related to the accumulation of excess filaggrin in the granular layer before its incorporation into the protein matrix of mature epidermal keratin [7].

Histopathologic features of AKE include elastorrhexis (fragmentation of elastic fibers), a reduced number of elastic fibers in the dermis [8, 9], acanthosis, orthokeratosis, and epidermal invagination [4]. Despite its name, AKE does not appear to be a disease of elastoidosis (degradation of elastic fibers). Studies using electron microscopy have shown a decrease in fibroblasts within the reticular dermis. Moreover, these depleted fibroblasts contain abnormal granules of elastin fiber precursors. [4].

The differential diagnosis of AKE includes focal acral hyperkeratosis (FAH), keratoelastoidosis marginalis (Ramos and Silva's marginal keratoderma), acrokeratosis verruciformis of Hopf, degenerative collagenous plaques, and punctate palmoplantar keratoderma [4]. Notably, FAH has a nearly identical clinical presentation to AKE but lacks elastorrhexis. Whereas AKE represents a disease of elastic fibers, FAH is more likely a focal disorder of keratinization [10]. The histopathologic abnormalities in FAH are restricted to the epidermis with hyperkeratosis and acanthosis [11]. A Verhoeff van Gieson stain differentiates FAH from AKE as the stain only shows thinning and fragmentation of elastic fibers in AKE [12].

AKE is a chronic disorder, and treatment often proves disappointing [4]. Use of topical glucocorticoids, tretinoin, salicylic acid, and coal tar as well as systemic glucocorticoids, dapsone, antibiotics, and methotrexate have been used with minimal success. Retinoic acid (50 mg/day) has some reported beneficial responses. However, recurrence tends to occur after discontinuation of treatment [6]. Ablative treatments with cryosurgery or laser erbium: yttrium-aluminium-garnet (Er:YAG) have shown little efficacy [13, 14].

References

1. Costa OG. Acrokeratoelastoidosis. *AMA Arch Dermatol Syphilol* 1954; 70: 228
2. Costa OG. Akrokerato-elastoidosis; a hitherto undescribed skin disease. *Dermatologica* 1953; 107: 164
3. de Boer EM., van Dijk E. Acrokeratoelastoidosis: a spectrum of diseases. *Dermatologica* 1985; 171: 8

4. Bogle MA, et al. Acrokeratoelastoidosis. *J Am Acad Dermatol* 2002; 47: 448
5. Greiner J, et al. A linkage study of acrokeratoelastoidosis: possible mapping to chromosome 2. *Hum Genet* 1983; 63: 222-7
6. Costa MC, et al. Case for diagnosis: acrokeratoelastoidosis. *An Bras Dermatol*, 2011; 86: 1222
7. Abulafia J, Vignale RA. Degenerative collagenous plaques of the hands and acrokeratoelastoidosis: pathogenesis and relationship with knuckle pads. *Int J Dermatol* 2000; 39: 424
8. Korc A, et al. Acrokeratoelastoidosis of Costa in North America: a report of two cases. *J Am Acad Dermatol* 1985; 12: 832
9. Highet AS, et al. Acrokeratoelastoidosis. *Br J Dermatol* 1982; 106: 337
10. Erkek E, et al. Focal acral hyperkeratosis: a rare cutaneous disorder within the spectrum of Costa acrokeratoelastoidosis. *Pediatr Dermatol* 2004; 21: 128
11. Dowd PM, et al. Focal acral hyperkeratosis. *Br J Dermatol* 1983; 109: 97
12. Lee SE, Kim SC. Focal acral hyperkeratosis. *Clin Exp Dermatol* 2007; 32: 608
13. Erbil AH, et al, Acrokeratoelastoidosis treated with the erbium:YAG laser. *Clin Exp Dermatol* 2008; 33: 30
14. Meziane M, et al. Acrokeratoelastoidosis. *Dermatol Online J* 2008; 14: 11