

UC Davis

Dermatology Online Journal

Title

Treatment of rosacea with topical ivermectin cream: a series of 34 cases

Permalink

<https://escholarship.org/uc/item/9ks1c48n>

Journal

Dermatology Online Journal, 22(8)

Authors

Mendieta Eckert, Marta

Landa Gundin, Nerea

Publication Date

2016

License

<https://creativecommons.org/licenses/by-nc-nd/4.0/> 4.0

Peer reviewed

Volume 22 Number 8
August 2016

Case Report

Treatment of rosacea with topical ivermectin cream: a series of 34 cases

Marta Mendieta Eckert, Nerea Landa Gundin

Dermatology Online Journal 22 (8): 6

Department of Dermatology, Clínica Dermitek (Bilbao), Spain

Correspondence:

Marta Mendieta Eckert
Paseo Uribitarte 11-12 (Bajo),
48001 Bilbao
Vizcaya
Spain
Tel. +34 65274998 Fax. +34 944010111
Email: mmendieta@dermitek.com

Abstract

Rosacea is a highly prevalent, chronic inflammatory disease. The use of topical ivermectin cream has recently been described in the treatment of rosacea in three clinical trials. We report our experience in a series of 34 patients treated with topical ivermectin cream. The results are a reflection of the reality of clinical practice and the perception of patients of the treatment. We also evaluate the efficacy in cases of mild rosacea and erythematotelangiectatic rosacea which have not been studied in trials.

Keywords: rosacea, topical ivermectin cream, treatment

Introduction

Rosacea is a chronic inflammatory disease of unknown aetiology. Some contributing factors could be: the proliferation of the *Demodex folliculorum* [1]; alterations to the immune response; neurovascular dysfunction; alteration of the epidermal barrier, and bacterial anti-genes. *Demodex folliculorum* (D folliculorum; D brevis) could be an additional factor in the inflammatory response, as well as being a vector of micro-organisms (*Bacillus oleronius*; *Staphylococcus B-haemolytic epidermidis*) either causing, or exacerbating lesions [2-5]. Ivermectin (IVM) might have an effect on rosacea owing to its miticide and anti-inflammatory properties, in addition to its possible antimicrobial properties [6].

It has been postulated that these mechanisms might play a role in the pathogenesis of rosacea on various levels, inhibiting the inflammatory cascade, and reducing the presence of Demodex mites in the skin, which would also reduce exposure to bacterial antigens, which are thought to be related. Topical IVM cream was recently proposed as a new therapeutic option, having been approved for use by the US Food and Drug Administration (FDA) in December 2014 [7, 8]. The following is a report of 34 patients treated with topical IVM cream and the results obtained in terms of efficacy, tolerance, and satisfaction.

Clinical synopses

This is a report of 34 patients with mild to severe rosacea who were treated with topical IVM cream between May 2014 and September 2015. The time of evolution from the diagnosis of rosacea by a dermatologist until the time of treatment with IVM varied from 1 month to 20 years (average 7.7 years; median 6½ years), Table 1.

	Age/ Sex	Type of Rosacea	Degree	Previous Treatments	Response %	Follow-up
1	53 F	ET	Mild	Unknown	0-25	2 m
2	55 M	ET	Mod	Unknown	25-50	2 m
3	67 M	PP	Mod	Topical MDZ and erythromycin; oral minocycline	75-100	5 m
4	30 M	PP	Sev	Oral doxycycline and minocycline	75-100	3 m
5	50 F	PP	Mod	Topical MDZ, erythromycin and brimonidine; oral minocycline	25-50	2 m
6	49 F	ET	Mild	Unknown	25-50	2 m
7	63 F	PP	Mod	Topical MDZ and azelaic acid	50-75	2 m
8	19 F	PP	Mod	Topical MDZ and corticosteroid; oral minocycline	75-100	2 m
9	49 F	PP	Mod	Topical MDZ; oral minocycline; vascular laser	25-50	5 m
10	51 F	PP	Mild	Oral ATB; oral isotretinoin	75-100	2 m
11	53 F	PP	Mild	Topical MDZ and erythromycin; oral doxycycline and minocycline; vascular laser; pulsed light	25-50	3 m
12	50 F	ET	Mild	KTP/ Vbeam vascular laser	75-100	2 m
13	34 F	PP	Mod	Topical MDZ, erythromycin, clindamycin and benzoyl peroxide; oral doxycycline; vascular laser	25-50	4 m
14	50 F	PP	Mod	Topical MDZ; oral minocycline	75-100	3 m
15	35 F	PP	Mild	Unknown	50-75	2 m
16	46 F	PP	Sev	Topical MDZ, erythromycin and brimonidine; oral minocycline and doxycycline; vascular laser	50-75	2 m
17	27 F	PP	Mod	No	50-75	2 m
18	54 F	ET	Mod	No	50-75	3 m
19	48 F	PP	Mild	Topical MDZ, retinol, azelaic acid, hydrocortisone, calcineurin inhibitors and brimonidine; oral doxycycline	0-25	2 m
20	22 F	PP	Sev	Topical MDZ, erythromycin and calcineurin inhibitors; oral minocycline	0-25	2 m
21	52 F	ET	Mild	No	0-25	2 m
22	47 F	PP	Sev	Topical azelaic acid and compounding; oral ATB	75-100	2 m
23	49 F	PP	Sev	Corticosteroid cream; oral ATB	25-50	3 m
24	49 F	PP	Mod	Topical MDZ and erythromycin; oral minocycline, doxycycline and isotretinoin	25-50	2 m
25	53 F	PP	Mild	Topical MDZ and erythromycin; oral minocycline; vascular laser	0-25	2 m
26	42 F	PP	Sev	Oral doxycycline	75-100	2 m
27	59 F	ET	Mod	No	50-75	2 m
28	53 F	ET	Mod	Topical brimonidine; oral minocycline	50-75	2 m
29	55 F	ET	Mild	Topical MDZ; oral minocycline; vascular laser	50-75	2 m
30	45 F	ET	Mild	Unknown	50-75	2 m
31	38 F	PP	Mod	Topical MDZ; oral doxycycline	50-75	2 m
32	51 F	PP	Mod	Topical MDZ; oral doxycycline and minocycline; vascular laser	50-75	2 m
33	16 F	ET	Sev	Topical brimonidine; vascular laser	50-75	2 m
34	28 M	PP	Mod	Topical corticosteroid and compounding	50-75	2 m

F: female; M: male; ET: erythematotelangiectatic rosacea; PP: papulopustular rosacea; Mod: moderate; Sev: severe; MDZ: metronidazole; ATB: antibiotics; m: months.

All patients were treated with topical IVM 1% carbohydrate cream base, which was prescribed once a day at night-time, to be applied in a thin layer without rubbing it in for 2 months. Two dermatologists evaluated clinical improvement in a visual scale (after 4 and 8 weeks) by means of exploration with photographs taken both pre- and post-treatment (Reveal System with

normal, polarized light; Canfield, USA). Results were divided into four levels of clinical improvement: 0-25%; 25-50%; 50-75%; and over 75%.

The responses obtained after 4 weeks were improvements of: 0-25% in 18% of the patients (6/34); 25-50 % in 20% of patients (7/34); 50-75% in 44% of patients (15/34); greater than 75% in 18% of patients (6/34), (Figures 1, 2). Remarkably, improvement was visible within the first 2 weeks.

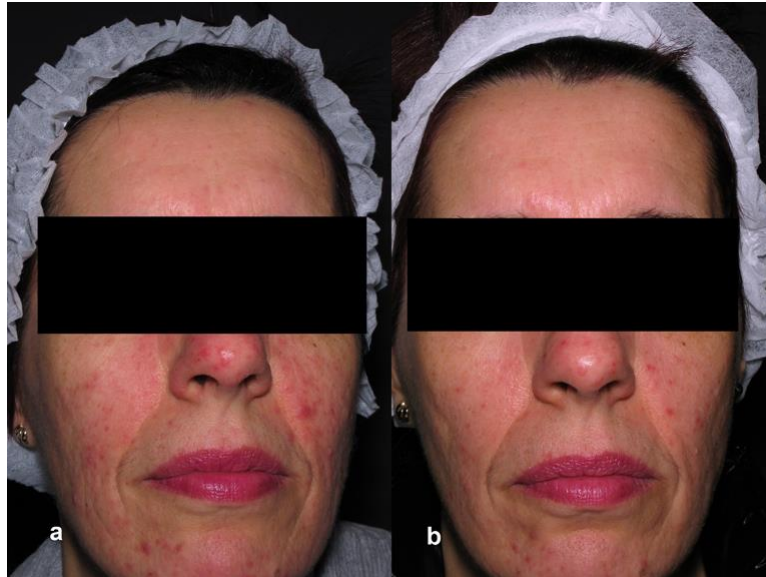


Figure 1. Patient N° 10 with severe papulopustular rosacea (a) with an improvement of 75-100% after 4 weeks (b)

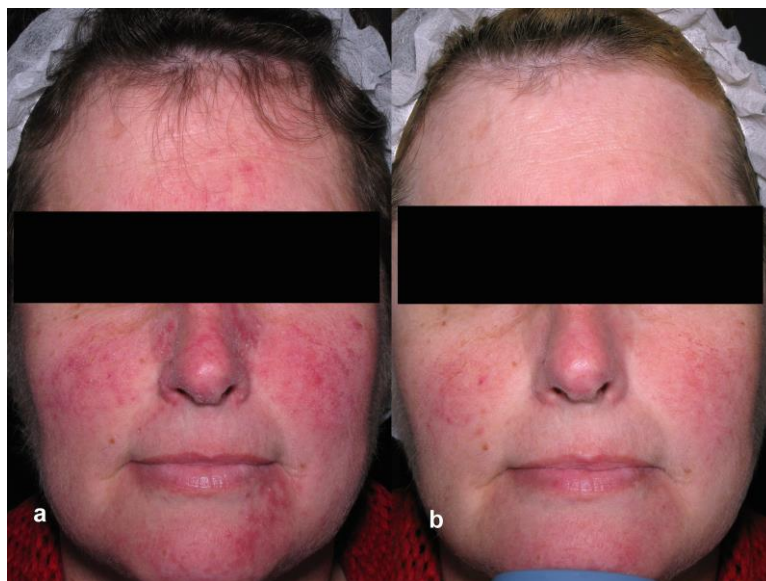


Figure 2. Patient N° 22 with severe papulopustular rosacea (a) with an improvement of 75-100% after 5 weeks (b)

After 8 weeks responses were obtained in 85% of the patients: 25-50% improvement in 23.5% of patients (8/34); 50-75% improvement in 38% of patients (13/34); and greater than 75% improvement in 23.5% of patients (8/34), (Figures 3, 4). Clinical improvement of less than 25% was reported in 15% of patients (5/34), Table 1.

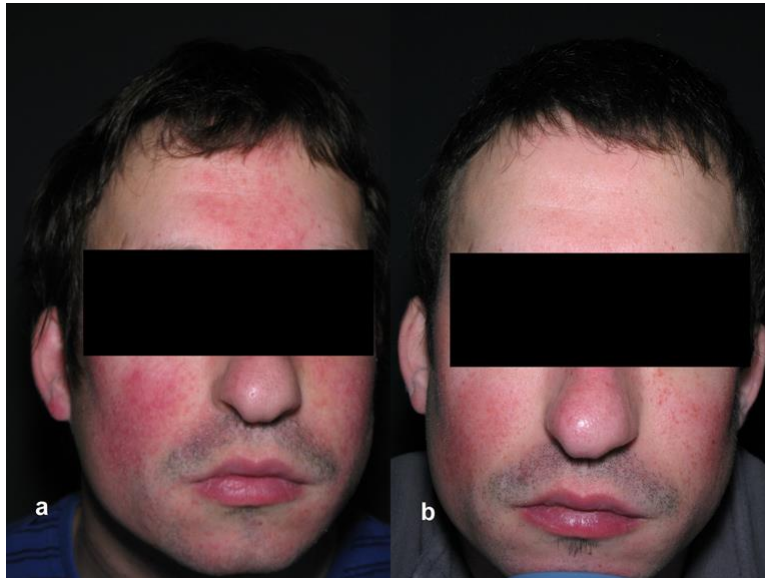


Figure 3. Patient N° 4 with severe papulopustular rosacea (a) with an improvement of 75-100% after 8 weeks (b)

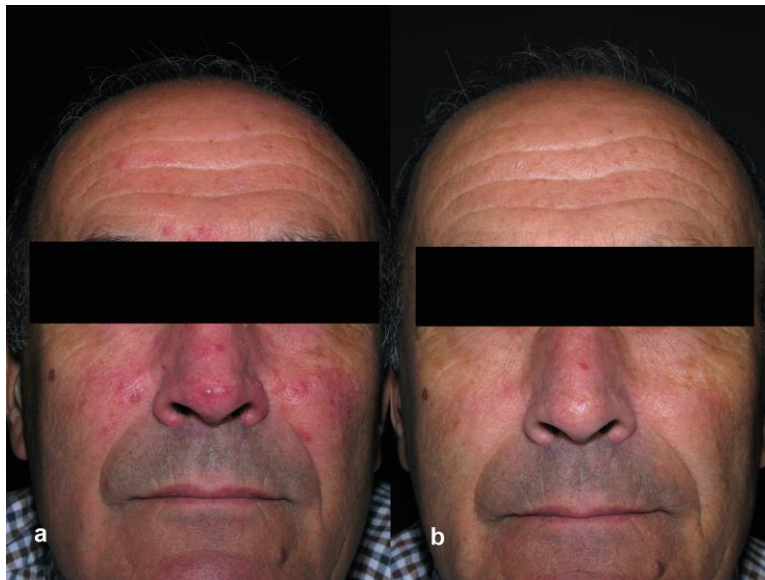


Figure 4. Patient N° 3 with moderate papulopustular rosacea (a) with an improvement of 75-100% after 8 weeks (b)

The best responses were found in patients with moderate to severe rosacea (Figure 5), with improvement being produced in both the vascular component as well as with papulopustular rosacea (Figures 6, 7).

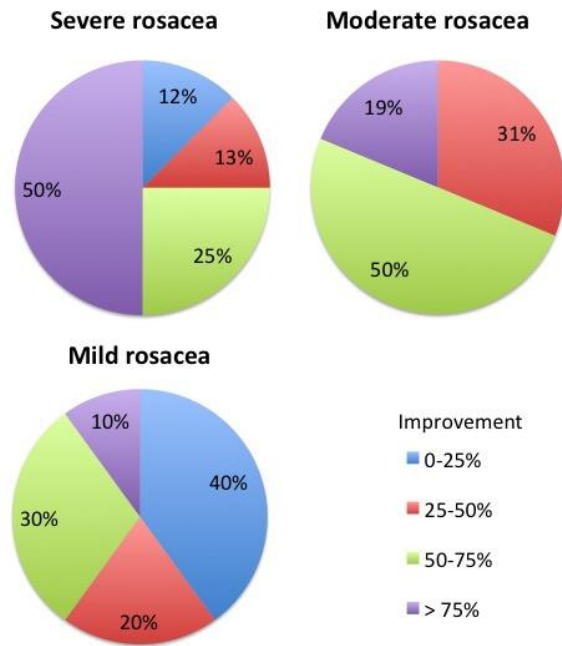


Figure 5. Responses stratified according to the degree of rosacea and expressed as a percentage of the total of number of patients in each group

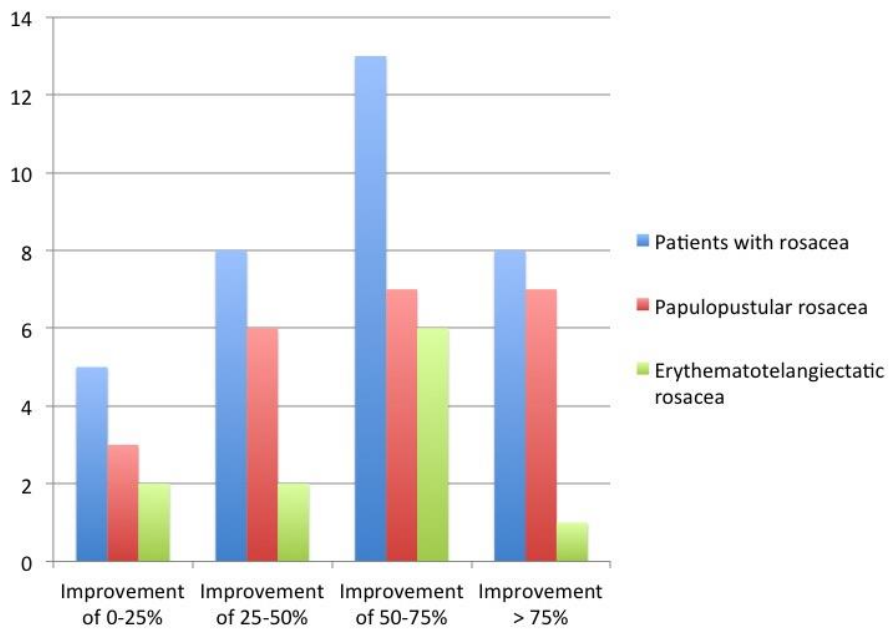


Figure 6. Responses in total numbers in all patients with rosacea and by type of rosacea

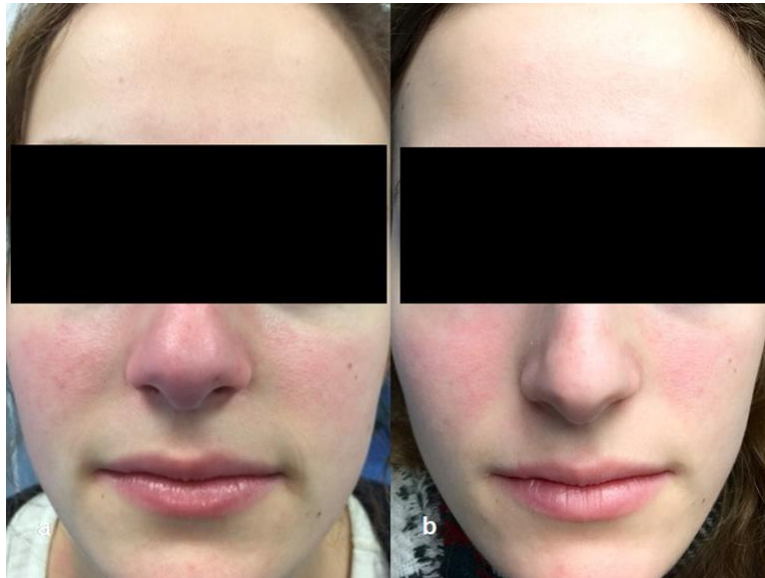

Figure 7. Improvement in the vascular component after 1 month of treatment

Patient N° 20 presented rebound rosacea in the third week following a positive response. This patient presented a unilateral rosacea with early relapses following oral antibiotics and poor response to usual treatments requiring 2 prior biopsies to discard the possibility of cutaneous lupus. Except for this patient, responses were maintained after 2 months of treatment (Fig. 8). No adverse effects were detected except for itching in some cases during the first few days of application.

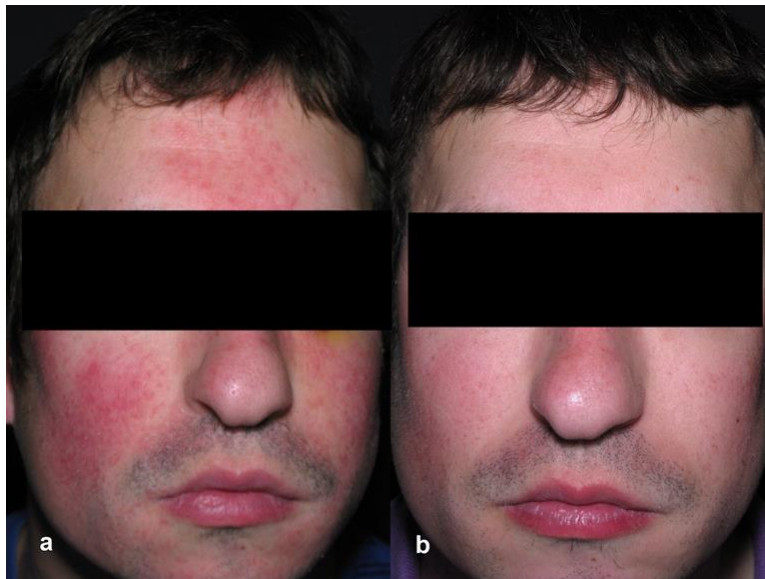

Figure 8. Patient N° 4 after 7 months (b), in ongoing treatment with increased response

Follow-up varied between 2 and 5 months with a median of 2 months. Later treatment was maintained in 9 of the 34 patients with differing dosages. Patients were instructed to apply topical IVM cream 2-3 times per week with the possibility of reinitiating treatment in case of an outbreak with application on a daily basis, and in more serious cases, every 12 hours.

Upon completion of the treatment period, patients were surveyed for the level of satisfaction, being asked to provide an overall score of the results on 5-point scale: 0 = worsening; 1 = no change; 2 = good; 3 = partial improvement; 4 = significant improvement; 5 = excellent. Furthermore, the patients were also asked to evaluate the level of itchiness due to application.

The breakdown of the overall rating by the patients was: '5' (3 patients); '4' (17 patients); '3' (12 patients); '2' (1 patient); and '1' (1 patient). The satisfaction survey found that there were 8 cases of itchiness related to application. With the exception of one patient, who discontinued treatment owing to itchiness, all the patients indicated that the itching had only occurred during the first few days of application; in one patient, the stinging or burning sensation associated with rosacea had actually improved. In general, topical IVM cream was rated positively by 92% of the patients surveyed.

Discussion

Ivermectin is a synthetic derivative of avermectins with a wide spectrum of action against endoparasites and ectoparasites with cutaneous tropism, including Demodex [9]. IVM may either be taken orally or applied topically, and to date has been proven to be effective in numerous dermatological diseases, including pediculosis, scabies [10, 11], and demodicosis [12-15].

The role of Demodex in the pathogenesis of rosacea [1,-5, 16] has led some to propose that IVM could be just as effective in the treatment of rosacea as it is with demodicosis. It is worth noting that there are examples found in literature of successfully treating papulopustular rosacea with oral IVM obtaining early responses [17, 18]. However, the topical use of IVM has been proposed as a new therapeutical agent against rosacea [19-25]. Its efficacy and safety have been demonstrated by means of 2 randomized, double-blind, vehicle-controlled studies at 12 weeks in moderate to severe papulopustular rosacea [26]. In both studies an IGA 0, or almost in 38.4% and 40.1% of the patients was achieved, with significant relevance with regard to the vehicle.

In our series, an improvement greater than 75% was produced in 23%, and 50-75% in 38% respectively. These lower results might be related to greater heterogeneity in our sampling, including not only papulopustular rosacea, but erythematotelangiectatic rosacea as well, and in degrees ranging from mild to severe. Our series shows improvement of over 75% most frequently in the group with papulopustular rosacea compared to erythematotelangiectatic rosacea (30% vs 9% respectively), and in the moderate-to-severe cases (69% vs 40% respectively). Tolerance and the subjective evaluation by our patients are in accordance with the aforementioned studies.

Comparative studies with topical IVM 1% cream were later undertaken against azelaic acid 15% cream and topical metronidazole 0.75% cream [27, 28]. In the case of studies comparing ivermectin and azelaic acid, the safety and tolerance of IVM over 52 weeks presented a lower incidence of adverse effects under observation [27]. The randomized study, investigator-blinded trials against topical metronidazole 0.75 cream compares efficacy and safety with 2 applications daily compared to one application of IVM daily over 16 weeks [28]. In terms of results, the superiority of topical IVM cream is proven with responses after week 3, and an IGA of 0 or almost 0 in 84.9% of the patients, whereas metronidazole obtained 75.4%. Tolerance was greater for IVM with an overall rating by patients of either 'excellent' or 'good'. A 36-week extension of this study showed that IVM cream extended remission of rosacea compared with metronidazole cream [29]. Just as with the previous study of efficacy, when compared to our results, these values are probably greater than those observed in our sampling for the same reasons, or perhaps owing to a shorter follow-up period. In our series, 62% of the patients experienced an improvement of over 50% with similar results obtained in terms of patients' overall rating and speed of action.

It should be noted that topical IVM cream is convenient to use and presents good tolerance along with an absence of resistance [9] with repeated treatments. In our opinion, its use could be considered in treating an outbreak or used as an ongoing therapy. In periods between outbreaks, its use could keep the presence of Demodex mites under control to minimize inflammation and bacterial antigens production implicated in rosacea.

The principal limitations in our series are: the size of the sampling, and the lack of comparison with a vehicle or active ingredient. We do believe, however, that it remains valuable because it reflects the reality of clinical practice in a private dermatological and aesthetics center. Moreover, the study both takes into consideration the perception of the patients themselves regarding the treatment. It demonstrates its efficacy in mild papulopustular cases and erythematotelangiectatic rosacea cases, which has not been analysed in the trials.

Conclusions

In our experience topical IVM cream can be an effective treatment for rosacea. Our series demonstrates better results with moderate to severe papulopustular rosacea as in the cases studied in trials. Nevertheless, we have also observed some response in mild cases of erythematotelangiectatic rosacea as well. Tolerance of ivermectin cream is high and produces quick results. Further studies would be required to determine the results and safety of ivermectin cream treatment. Finally, improved understanding of the causes of rosacea should lead both to a more optimum application of existing treatments and new treatment options.

References

1. Two AM, Wu W, Gallo RL, Hata TR. Rosacea. Part I. Introduction, categorization, histology, pathogenesis, and risk factors. *J Am Acad Dermatol.* 2015; 72: 749-758. [PMID:25890455]
2. Jarmuda S, O'Reilly N, Zaba R, Jakubowicz O, Szkaradkiewicz A, Kavanagh K. Potential role of Demodex mites and bacteria in the induction of rosacea. *J Med Microbiol.* 2012; 61: 1504-1510. [PMID:22933353]
3. O'Reilly N, Menezes N, Kavanagh K. Positive correlation between serum immunoreactivity to Demodex-associated Bacillus proteins and erythematotelangiectatic rosacea. *Br J Dermatol.* 2012; 167: 1032-1036. [PMID:22709541]

4. O'Reilly N, Bergin D, Reeves EP, McElvaney NG, Kavanagh K. Demodex-associated bacterial proteins induce neutrophil activation. *Br J Dermatol.* 2012; 166: 753-760. [PMID:22098186]
5. Casas C, Paul C, Lahfa M, Livideanu B, Lejeune O, Alvarez-Georges S, Saint-Martory C, Degouy A, Mengeaud V, Ginisty H, Durbise E, Schmitt AM, Redouls D. Quantification of Demodex folliculorum by PCR in rosacea and its relationship to skin immune activation. *Exp Dermatol.* 2012; 21: 906-910. [PMID:23171449]
6. Abokwidir M, Fleischer AB. An emerging treatment: topical ivermectin for papulopustular rosacea. *J Dermatol Treat.* 2015; 30: 1-2. [PMID:25424053]
7. Two AM, Wu W, Gallo RL, Hata TR. Rosacea. Part II. Topical and systemic therapies in the treatment of rosacea. *J Am Acad Dermatol.* 2015; 72: 761-770. [PMID:25890456]
8. Gupta G, Daigle D, Gupta AK, Gold LS. Ivermectin 1% cream for rosacea. *Skin Therapy Lett.* 2015; 20 (4): 9-11. [PMID:26382711]
9. Dourmishev AL, Dourmishev LA, Schwartz RA. Ivermectin: pharmacology and application in dermatology. *Int J Dermatol.* 2005; 44: 981-88. [PMID:16409259]
10. Usha V, Gopalakrishnan TV. A comparative study of oral ivermectin and topical permethrin cream in the treatment of scabies. *J Am Acad Dermatol.* 2000; 42: 236-240. [PMID:10642678]
11. González-Canga A, Sahagún-Prieto AM, Díez-Liébana MJ, Fernández-Martínez N, Sierra-Vega M, García-Vieitez JJ. The pharmacokinetics and interactions of ivermectin in humans-a mini-review. *The AAPS Journal.* 2008; 10 (1): 42-46. [PMID:18446504]
12. Clyti E, Nacher M, Sainte-Marie D, Pradinaud R, Couppie P. Ivermectin treatment of three cases of demodicidosis during human immunodeficiency virus infection. *Int J Dermatol.* 2006; 45: 1066-1068. [PMID:16961510]
13. Aquilina C, Viraben R, Sire S. Ivermectin-responsive Demodex infestation during human immunodeficiency virus infection. *Dermatology.* 2002; 205: 394-97. [PMID:12444338]
14. Forstinger C, Kittler H, Binder M. Treatment of rosacea-like demodicidosis with oral ivermectin and topical permethrin cream. *J Am Acad Dermatol.* 1999; 41: 775-777. [PMID:10534645]
15. Salem DA, El-Shazly A, Nabih N, El-Bayoumy Y, Saleh S. Evaluation of the efficacy of oral ivermectin in comparison with ivermectin-metronidazole combined therapy in the treatment of ocular and skin lesions of Demodex folliculorum. *Int J Infect Dis.* 2013; 17 (5): e343-347. [PMID:23294870]
16. Abokwidir M, Fleischer AB Jr. Additional evidence that rosacea pathogenesis may involve demodex: new information from the topical efficacy of ivermectin and praziquantel. *Dermatol Online J.* 2015; 21 (9). [PMID:26437294]
17. Brown M, Hernández-Martín A, Clement A, Colmenero I, Torreló A. Severe demodex folliculorum-associated oculocutaneous rosacea in a girl successfully treated with ivermectin. *JAMA Dermatol.* 2014; 150 (1): 61-63. [PMID:24284904]
18. Allen KJ, Davis CL, Billings SD, Mousdicas N. Recalcitrant papulopustular rosacea in an immunocompetent patient responding to combination therapy with oral ivermectin and topical permethrin. *Cutis* 2007; 80 (2): 149-151. [PMID:17944176]
19. Layton A, Thiboutot D. Emerging therapies in rosacea. *J Am Acad Dermatol.* 2013; 69: s57-65. [PMID:24229638]
20. Moustafa FA, Sandoval LF, Feldman SR. Rosacea: new and emerging treatments. *Drugs* 2014; 74: 1457-1465. [PMID:25154627]
21. Chang BP, Kurian A, Barakin B. Rosacea: an update on medical therapies. *Skin Therapy Lett.* 2014; 19 (3): 1-4. [PMID:25188361]
22. Fallen RS, Gooderham M. Rosacea: update on management and emerging therapies. *Skin Therapy Lett.* 2012; 17 (10): 1-4. [PMID:23223767]
23. Van Zuuren EJ, Fedorowicz Z. Interventions for rosacea: abridged updated Cochrane systemic review including GRADE assessments. *Br J Dermatol.* 2015; 173 (3): 651-662. [PMID:26099423]
24. Ali ST, Alinia H, Feldman SR. The treatment of rosacea with topical ivermectin. *Drugs today (Barc).* 2015; 51 (4): 243-250. [PMID:26020066]
25. Deeks ED. Ivermectin: a review in rosacea. *Am J Clin Dermatol.* 2015; 16 (5): 447-452. [PMID:26254001]
26. Stein L, Kircik L, Fowler J, Tan J, Draelos Z, Fleischer A, Appell M, Steinhoff M, Lynde C, Liu H, Jacovella J. Efficacy and safety of ivermectin 1% cream in treatment of papulopustular rosacea: results of two randomized, double-blind, vehicle-controlled pivotal studies. *J Drugs Dermatol.* 2014; 13 (3): 316-323. [PMID:24595578]
27. Stein L, Kircik L, Fowler J, Jackson JM, Tan J, Draelos Z, Fleischer A, Appell M, Steinhoff M, Lynde C, Sugarman J, Liu H, Jacovella J. Long-term safety of ivermectin 1% cream vs azelaic acid 15% gel in treating inflammatory lesions of rosacea: results of two 40-week controlled, investigator-blinded trials. *J Drugs Dermatol.* 2014; 13 (11): 1380-1386. [PMID:25607706]
28. Taieb A, Ortonne JP, Ruzicka T, Roszkiewicz J, Berth-Jones J, Peirone MH et al. Superiority of ivermectin 1% cream over metronidazole 0.75% cream in treating inflammatory lesions of rosacea: a randomized, investigator-blinded trial. *Br J Dermatol* 2015; 172 (4): 1103-1110. [PMID:25228137]
29. Taieb A, Khemis A, Ruzicka T, Baránska-Rybak W, Berth-Jones J, Schaubert J, Briantais P, Jacovella J, Passeron T. Maintenance of remission following successful treatment of papulopustular rosacea with ivermectin 1% cream vs. metronidazole 0.75% cream: 36-week extension of the ATTRACT randomized study. *J Eur Acad Dermatol Venereol* 2015. [PMID:26691278]