

## A case of perniosis

Euphemia W. Mu, MD, Vitaly Terushkin, MD, Shane A. Meehan, MD, Marie Leger, MD, PhD, Alisa Femia, MD

Ronald O. Perelman Department of Dermatology, NYU School of Medicine, NYU Langone Medical Center

### Abstract

Perniosis is a localized, inflammatory reaction that is characterized by erythematous papules and nodules that often are located on the acral surfaces in young women. The lesions of perniosis are thought to be due to cold-induced vasoconstriction that leads to hypoxemia and inflammation of the vessel wall. Histopathologic and laboratory studies are indicated for patients with suspected perniosis to distinguish between idiopathic perniosis and secondary perniosis. Treatment includes adequate heating and clothing, proper food intake, nifedipine, ultraviolet A1 phototherapy, topical glucocorticoids, and vasodilators.

### Case Presentation

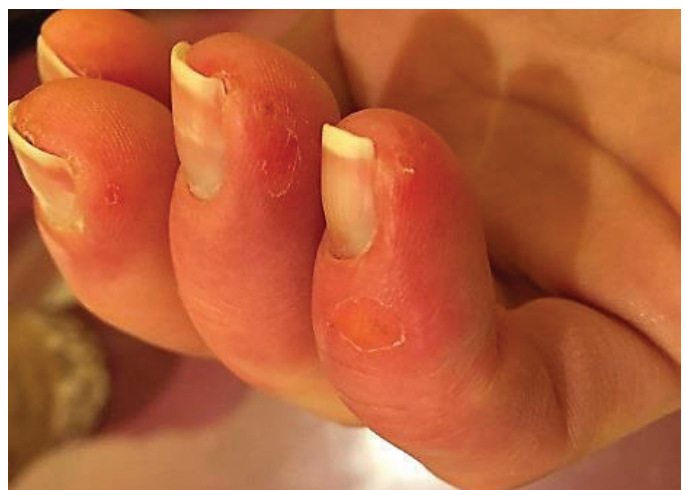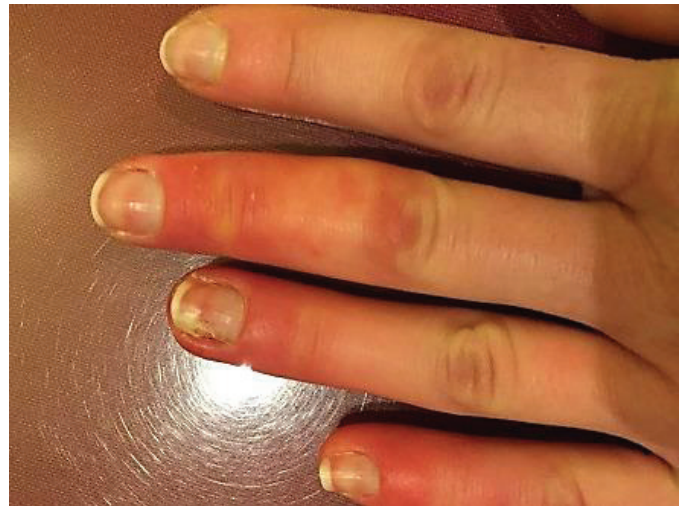**PATIENT:** 22-year-old woman

**DURATION:** Six months

**DISTRIBUTION:** Fingers

**HISTORY:** A 22-year-old woman presented to the Dermatology Consult Service at Tisch Hospital for evaluation of red bumps on her hands. The patient was in her usual state of health until six months prior when she developed swollen, red spots around the fourth digit of the left hand that subsequently spread to involve several of her fingers on both hands. She was evaluated by an outside dermatologist, who performed an incision and drainage of the largest lesion on the fourth digit of the left hand and started the patient on mupirocin and a one-week course of cephalexin then a one-week course of sulfamethoxazole and trimethoprim without improvement. The patient experienced Raynaud's phenomenon that affected

her fingers occasionally over the past several years. She drinks two cups of coffee per day and maintains a regimented diet and exercise routine. She denies fevers, vesicles, discharge from the affected sites, oral lesions other areas of involvement, sick contacts, prior episodes, joint pains, or abdominal pain.

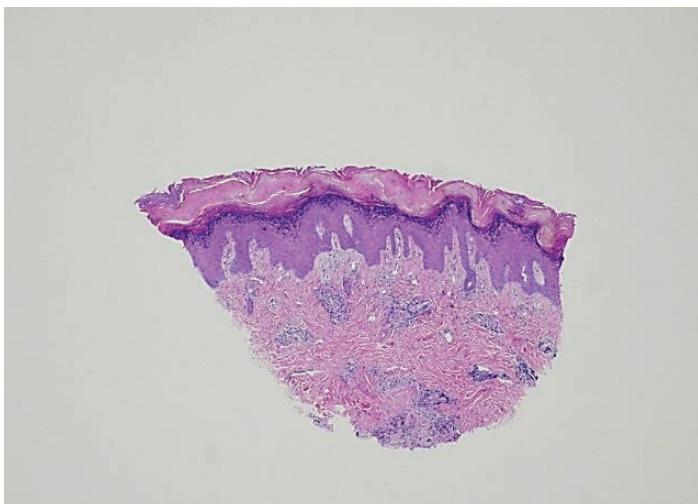


**Figure 1.** Distal phalanges with discrete, erythematous nodules with a background of poorly-circumscribed, erythematous, and edematous patches

**PHYSICAL EXAMINATION:** On the ten distal phalanges were discrete, erythematous nodules with a background of poorly-circumscribed, erythematous, and edematous patches (**Figure 1**). The lesions were mildly tender to palpation.

**LABORATORY DATA:** A complete blood count with differential analysis; a basic metabolic panel; urinalysis; human chorionic gonadotropin; antinuclear, anti-Ro, anti-La, anti-SS, anti-neutrophil cytoplasmic antibodies; lupus anticoagulant panel; beta 2 glycoprotein antibody; cardiolipin antibody; cryoglobulin; cryofibrinogen; zinc; vitamin C; vitamin D; folate; B12; citrullinated peptide antibody; and rheumatoid factor were normal or negative.

**HISTOPATHOLOGY:** There is a superficial and mid dermal perivascular, lymphocytic infiltrate with slight papillary dermal edema. There is acanthosis with hypergranulosis and hyperkeratotic ortho- and parakeratosis (**Figure 2**).



**Figure 2.** Biopsy showing superficial and mid dermal perivascular, lymphocytic infiltrate with slight papillary dermal edema. Acanthosis with hypergranulosis and hyperkeratotic ortho- and parakeratosis is also present

**DIAGNOSIS:** Perniosis / chilblains

## Discussion

Perniosis is a localized, inflammatory reaction that is characterized by erythematous papules and nodules that often occur on the acral surfaces [1]. The condition is most common in young women but can

occur in all ages and both genders. Perniosis is more prevalent among patients who live in cold, damp climates, especially during the late fall and winter [2, 3]. The distinct lesions of perniosis are thought to be due to cold-induced vasoconstriction that leads to hypoxemia and inflammation of the vessel wall [1]. Humidity may contribute as a result of the increased air conductivity of temperature [4]. Exposure to cold can induce perniosis within a few hours, and lesions typically resolve over one to three weeks. Prolonged or repeated exposure to dampness and cold can result in a chronic form of perniosis with waxing and waning lesions [1].

Vascular abnormalities, such as Raynaud's disease, atherosclerosis, and acrocyanosis, can predispose to perniosis [1, 2]. Additional associated conditions include genetics, anorexia nervosa, chronic myelomonocytic leukemias, lupus erythematosus, and macroglobulinemia [4-7]. When secondary to systemic conditions, perniosis can last for several months and is more likely to recur [1]. The differential diagnosis for perniosis includes dyshidrotic eczema, Raynaud's syndrome, septic embolism, embolization, erythromelalgia, impetigo, drug reactions, and herpetic whitlow [1].

Histopathologic and laboratory studies are indicated for patients with suspected perniosis to distinguish between idiopathic perniosis and secondary perniosis. Laboratory studies include a complete blood count, antinuclear antibody titer, basic metabolic profile, cryoglobulin, and cryofibrinogen. Histopathologic features of perniosis include perivascular lymphocytes with endothelial swelling (fluffy edema) and lymphocytes in the vessel wall of the papillary and deep plexus [4, 8]. One study observed histopathologic differences between 21 patients with idiopathic perniosis and 17 patients with perniosis-like lesions in the setting of systemic disease. Changes in idiopathic perniosis included lymphocytic exocytosis around the rete ridges and acrosyringium without interface dermatitis [4]. Vascular injury was observed more commonly in secondary perniosis but was a non-specific finding [4].

A broad array of treatment options has been suggested for the treatment of perniosis, which

suggests a lack of a consistently effective method. Prophylactic recommendations include the use of adequate heating and clothing as well as proper food intake. In one study, use of nifedipine 20 mg three times daily was found to be effective in a six-week, double-blind, placebo-controlled, crossover study of ten patients with severe idiopathic perniosis [9]. Side effects of this medication regimen included hypotension, flushing, headaches, and dizziness. Alternative treatments include ultraviolet A1 phototherapy, topical glucocorticoids, and vasodilators. In severe cases, sympathectomy can be beneficial [10].

## References

1. Goette DK. Chilblains (perniosis). *J Am Acad Dermatol* 1990; 23:257
2. Herman EW, et al. A distinctive variant of pernio: clinical and histopathologic study of nine cases. *Arch Dermatol* 1981;117:26
3. Jacob JR, et al. Chronic pernio: a historical perspective of cold-induced vascular disease. *Arch Intern Med* 1986;146:1589
4. Crowson AN, Magro CM. Idiopathic perniosis and its mimics: a clinical and histological study of 38 cases. *Hum Pathol* 1997;28:478
5. Kelly JW, Dowling JP. Pernio: a possible association with chronic myelomonocytic leukemia. *Arch Dermatol* 1985;121:1048
6. Cribier B, et al. A histologic and immunohistochemical study of chilblains. *J Am Acad Dermatol* 2001;45:924
7. Millard LG, Rowell NR. Chilblain lupus erythematosus (Hutchinson): a clinical and laboratory study of 17 patients. *Br J Dermatol* 1978;98:497
8. Wall LM, Smith NP. Perniosis: a histopathological review. *Clin Exp Dermatol* 1981; 6:263
9. Dowd PM. Nifedipine in the treatment of chilblains. *Br Med J* 1986;293:923
10. Lynn RB. Chilblains. *Surg Gynecol Obstet* 1954;99:720