

UC Davis

Dermatology Online Journal

Title

Erythematous nodule of the ear

Permalink

<https://escholarship.org/uc/item/9m9964rj>

Journal

Dermatology Online Journal, 20(11)

Authors

Thompson, Lauren
Malone, Janine
Schadt, Courtney

Publication Date

2014

DOI

10.5070/D32011024684

Copyright Information

Copyright 2014 by the author(s). This work is made available under the terms of a Creative Commons Attribution-NonCommercial-NoDerivatives License, available at <https://creativecommons.org/licenses/by-nc-nd/4.0/>

Peer reviewed

Photo Vignette

Erythematous nodule of the ear

Lauren Thompson, Janine Malone MD, Courtney Schadt MD

Dermatology Online Journal 20 (11): 14

Division of Dermatology, University of Louisville

Correspondence:

Lauren Thompson, BS
University of Louisville School of Medicine
106 Highwood Drive
Louisville, KY 40206
P: 859.200.8782
lethom11@gmail.com

Abstract

An elderly man with eccrine porocarcinoma of the ear is presented. This rare tumor in an unusual location has the potential for metastasis and local recurrence.

Introduction

This case describes an unusual presentation of eccrine porocarcinoma (EP) on the ear of an elderly patient, a tumor that most often affects the lower extremities [1]. Eccrine porocarcinoma typically presents as a firm, erythematous or violaceous nodule that can rapidly enlarge and ulcerate [2]. It can arise from a preexisting poroma or develop *de novo*. The tumor is diagnosed histologically by cytologic atypia with an advancing margin and basaloid epithelial cells showing ductal differentiation [1]. Eccrine porocarcinoma has been treated by multiple approaches, including Mohs micrographic surgery, which has shown cure rates of between 70-80% [2]. Eccrine porocarcinoma is often misdiagnosed and has the potential for metastasis to local lymphatics and distant organs, in addition to recurrence after excision. Although the lower extremities are most frequently affected, an adnexal neoplasm, such as EP, should be considered in the differential diagnosis in a patient with a rapidly enlarging hemorrhagic lesion on any site.

Keywords: Eccrine porocarcinoma

Case synopsis

An elderly man presented to the clinic for initial evaluation of a nodule on the helix of his right ear. It had been present for 5 months with recent rapid enlargement and bleeding in the weeks prior to his evaluation. He had no other systemic complaints. Physical exam revealed a 2cm hemorrhagic, friable, erythematous nodule on his right superior helix (Figure 1). No similar lesions were found on skin examination and he had no associated cervical or facial lymphadenopathy. A shave biopsy was obtained for histopathologic examination (Figure 2, 3, and 4).

The histopathologic pattern was that of a poorly-differentiated, focally infiltrative tumor with basaloid morphology. Hematoxylin-eosin stain demonstrated the salient features of EP including malignant cytology, ductal formation, and comedo necrosis. The tumor was immunopositive for epithelial markers including epithelial membrane antigen (EMA) and focally immunopositive for S100 protein. The patient was subsequently treated with Mohs micrographic surgical excision.

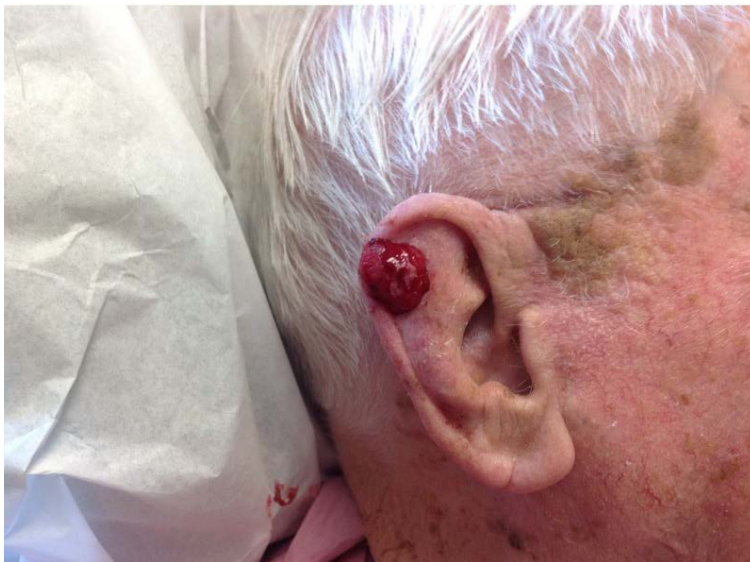

Figure 1. Photograph of the hemorrhagic nodule on the patient's right ear

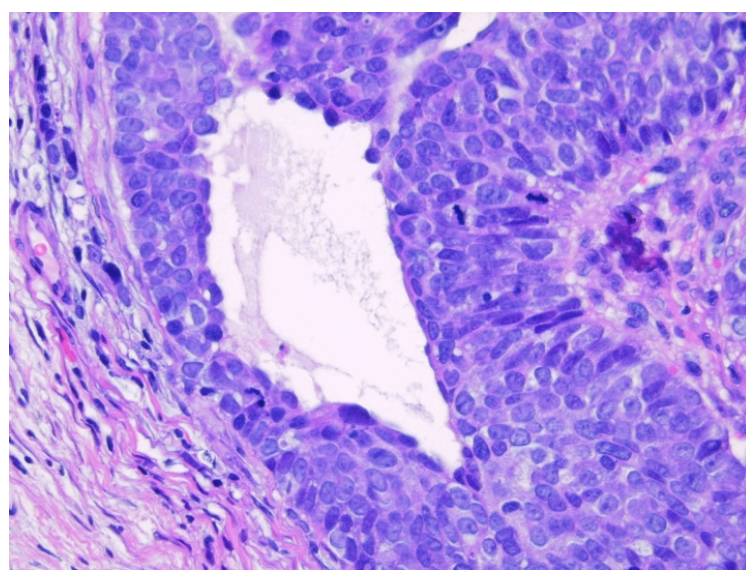
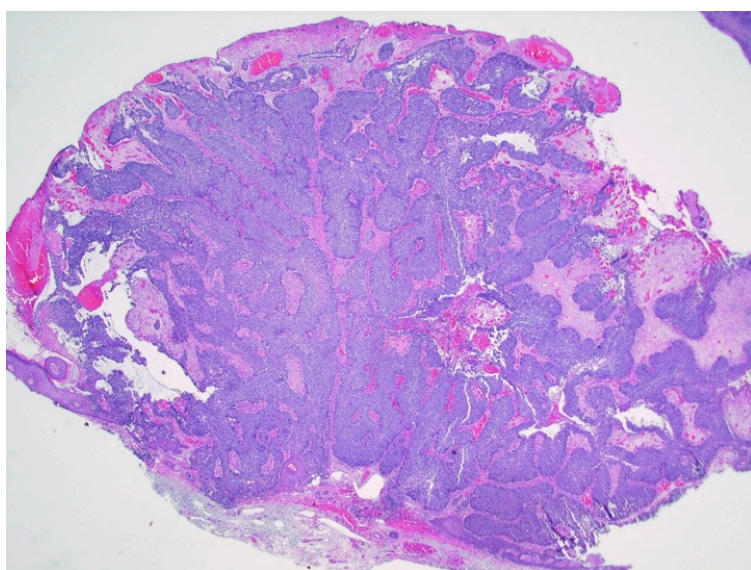


Figure 2. Histological image of the ulcerated polypoid tumor nodule (shave biopsy, hematoxylin-eosin, original magnification x20)

Figure 3. Uniformly atypical malignant tumor cells with mitotic figures and duct formation (original magnification x400)

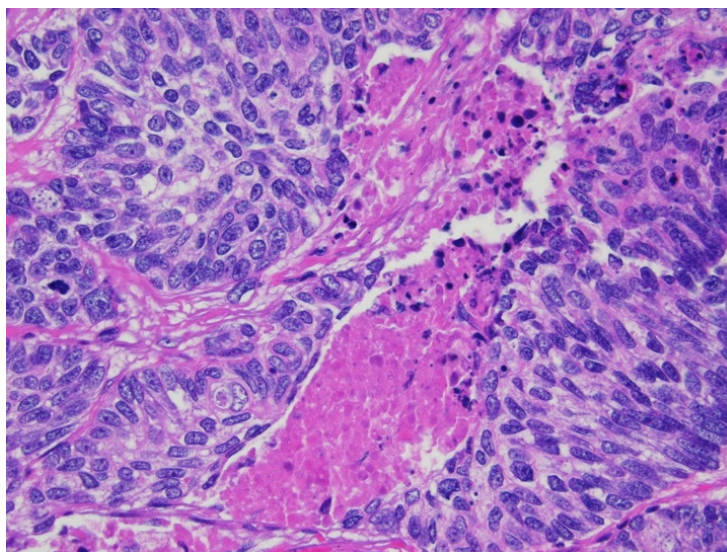


Figure 4. Comedo necrosis (original magnification x400)

Discussion

Eccrine porocarcinoma is a rare cancer of the eccrine sweat glands. It is believed to arise from the intraepithelial ductal portion of the eccrine gland and constitutes as few as 0.005-0.01% of all cutaneous cancers [1]. It typically presents in elderly patients with an average age of 73 and is seen slightly more often in women [1]. Eccrine porocarcinoma is most commonly seen on the lower extremities (44%), followed by the trunk (24%), and the head (18%) [1]. Although uncommon, these tumors have also been reported on the vulva and scrotum as well [3,4].

Eccrine porocarcinoma usually presents as an asymptomatic firm nodule that is erythematous or violaceous, as seen in our patient [2]. About 18% of EP arise from a benign preexisting poroma, but they can also develop *de novo* [1,5]. Malignant transformation can be suspected in cases of spontaneous bleeding, sudden pain or itching, ulceration, or rapid growth [5]. The lesion is typically noticed over a long course of time (up to 50 years), but it has also been documented to transform rapidly over the course of a few months [1, 6]. As this is a rare cutaneous cancer, it can be confused with more common, similar appearing growths such as squamous cell carcinoma, seborrheic keratosis, basal cell carcinoma, and pyogenic granuloma.

Making the histologic diagnosis can be difficult, as a variety of patterns have been documented. Some reports note misdiagnoses of the original primary EP until a later local recurrence or metastasis is found [1,7]. The histologic diagnosis is based on cytologic atypia with an advancing margin and poromatous basaloid epithelial cells showing ductal differentiation [1]. As opposed to the typical infiltrative border, a variant has been documented with striking pleomorphic epithelial cells and a pushing border that resembles bowenoid dysplasia [1]. Bowenoid dysplasia can be excluded by the presence of ducts lined by tumor cells within the lesion [1]. Immunohistochemistry can aid in diagnosis and stains for EMA, carcinoembryonic antigen (CEA), and S-100 protein have been useful in the diagnosis [8].

Eccrine porocarcinoma has the potential to spread to lymph nodes, metastasize to distant organs, and recur locally after excision. Survival times for metastatic EP is thought to be between 5-24 months [5]. The number of mitoses, tumor depth, and presence of lymphovascular space invasion are associated with worse outcomes. Cellular necrosis and tumor size have been shown to have no significant impact on prognosis. An infiltrative margin is associated with more local recurrence in comparison to a broader margin [1].

Eccrine porocarcinoma has been treated by multiple approaches including electrocautery, simple excision, wide excision, and Mohs micrographic surgery [2]. Mohs micrographic surgery is currently considered the preferred treatment for primary EPC with cure rates of about 70-80% [2]. It allows visualization of the entire margin as an aid in removing the tumor. Chemotherapy and radiation have been attempted to treat primary and metastatic EP with little success [2].

Elderly patients presenting with an erythematous or violaceous tumor nodule involving the lower extremity, trunk, or face should have the lesion histologically examined with a clinical differential diagnosis including unusual adnexal malignancies such as EP. As this is a rare, often misdiagnosed cancer with the possibility for local invasion and metastasis, early identification and complete excision are essential.

References

1. Robson A, Greene J, Ansari N, Kim B, Seed PT, McKee PH, Calonje E. Eccrine porocarcinoma (malignant eccrine poroma): a clinicopathologic study of 69 cases. *Am J Surg Pathol*. 2001;25(6):710-720. [PMID:11395548]
2. Brown CW, Dy LC. Eccrine porocarcinoma. *Dermatol Ther*. 2008;21(6):433-438. doi:10.1111/j.1529-8019.2008.00243.x. [PMID:19076620]
3. Adegboyega PA. Eccrine porocarcinoma of the vulva: a case report and review of literature. *Int. J Gynecol Pathol*. 2011;30(1):95-100. doi:10.1097/PGP.0b013e3181ea11b1. [PMID:21131825]
4. Choi CM, Cho HR, Lew BL, Sim WY. Eccrine porocarcinoma presenting with unusual clinical manifestations: a case report and review of the literature. *Ann Dermatol*. 2011;23(Suppl 1):S79-83. doi:10.5021/ad.2011.23.S1.S79. [PMID:22028580]
5. Sawaya JL, Khachemoune A. Poroma: a review of eccrine, apocrine, and malignant forms [published online April 2, 2014]. *Int J Dermatol*. doi:10.1111/ijd.12448. [PMID:24697501]
6. Jeon SP, Kang SJ, Jung SJ. Rapidly growing eccrine porocarcinoma of the face in a pregnant woman. *J Craniofac Surg*. 2014;25(2):715-717. doi:10.1097/01.scs.0000436739.52418.97. [PMID:24621740]
7. Huet P, Dandurand M, Pignodel C, Guillot B. Metastasizing eccrine porocarcinoma: report of a case and review of the literature. *J Am Acad Dermatol*. 1996;35(5 Pt. 2):860-864. [PMID:8912607]
8. Kurisu Y, Tsuji M, Yasuda E, Shibayama Y. A case of eccrine porocarcinoma: usefulness of immunostain for s-100 protein in the diagnoses of recurrent and metastatic dedifferentiated lesions. *Ann of Dermatol*. 2013;25(3):348-351. doi:10.5021/ad.2013.25.3.348. [PMID:24003279]

