Title
Cryogen Spray Cooling and Pulsed Dye Laser Treatment of Cutaneous Hemangiomas

Journal
Annals of Plastic Surgery, 46(6)

ISSN
0148-7043

Authors
Chang, Cheng-Jen
Kelly, Kristen M
Nelson, J Stuart

Publication Date
2001-06-01

DOI
10.1097/00000637-200106000-00001

Cryogen Spray Cooling and Pulsed Dye Laser Treatment of Cutaneous Hemangiomas

Cheng-Jen Chang, MD*
Kristen M. Kelly, MD†
J. Stuart Nelson, MD, PhD†‡

When a cryogen spurt is applied to the skin surface for tens of milliseconds, cooling remains localized in the epidermis, leaving the temperature of deeper hemangioma vessels unchanged. The objective of this study was to compare the efficacy and safety of noncooled laser treatment (NC-LT) vs. cryogen spray cooling plus laser treatment (CSC-LT) for cutaneous hemangiomas in a large series of patients. A retrospective review was conducted of 164 patients treated with the pulsed dye laser (λ = 585 nm; $\tau\rho$ = 450 μsec) over an 8-year period. Eighty-two patients received NC-LT using light doses of 5.5 to 8 J per square centimeter. Subsequently, 82 patients received CSC-LT using light doses of 9 to 10 J per square centimeter. The primary efficacy measure was quantitative assessment of improvements in lesional volume, texture, and color. Safety was evaluated for each treatment group by monitoring for adverse effects. Based on chi-squared analysis, there were clinical and significant differences in the number of treatments (p = 0.001), and improvement in volume (p = 0.008) and texture (p = 0.001) of the CSC-LT group compared with the NC-LT group. Permanent adverse effects were not observed in either group. In conclusion, CSC permitted the use of higher incident light doses for treatment of cutaneous hemangiomas, resulting in fewer treatments required and better improvement in lesional volume and texture.

Chang C-J, Kelly KM, Nelson JS. Cryogen spray cooling and pulsed dye laser treatment of cutaneous hemangiomas. Ann Plast Surg 2001;46:577–583

From the *Department of Plastic and Reconstructive Surgery, Chang Gung Memorial Hospital, Chang Gung University, Taipei, Taiwan; and the Beckman Laser Institute and Medical Clinic, the Departments of †Dermatology and ‡Surgery, University of California, Irvine, CA.

Received Nov 10, 2000. Accepted for publication Nov 30, 2000.

Address correspondence and reprint requests to Dr Nelson, Beckman Laser Institute and Medical Clinic, University of California, Irvine, 1002 Health Sciences Road East, Irvine, CA 92612.

Hemangioma of infancy is a common birthmark that presents the plastic surgeon with one of the most difficult therapeutic dilemmas in medicine. Typically, hemangiomas appear a few days to weeks after birth. Initially, lesions may be small red spots or nodules. Subsequent proliferation during the first year of life may lead to a large and/or disfiguring birthmark.

Traditional conservative management of hemangiomas is based on the assumption that these birthmarks will involute spontaneously by the age of 3 to 7 years.[1,2] However, symptomatic problems such as ulceration, infection, bleeding, obstruction of a vital organ, or psychosocial factors may be indications for urgent medical intervention.[3,4] A variety of modalities including carbon dioxide snow, liquid nitrogen,[5] and radiation therapy have been used for treatment of hemangiomas.[6] Steroid therapy has been advocated for palliation of symptomatic hemangiomas.[7] Surgical intervention is limited primarily to patients in whom function is impaired.

Apfelberg and colleagues[8] and Hobby[9] first reported using the argon laser (λ = 488 and 514 nm) for treatment of hemangiomas in early infancy. However, because of the relatively shallow penetration of argon laser light, the therapeutic effect was limited to superficial lesions. The KTP laser, with a wavelength of 532 nm, is an alternative choice in some circumstances.

For thick hemangiomas, the Nd:YAG laser has been shown to be effective because of the deep penetration of 1,064-nm light.[10–12] More recently, the Nd:YAG laser has been used for intralesional photocoagulation.[13–15]

Although the use of lasers for the treatment of hemangiomas has resulted in some success, there is a substantial risk of nonspecific, thermally induced damage to the epidermis and papillary dermis.[16] To decrease this risk, clinicians have used the flash lamp-pumped pulsed dye laser (PDL; λ = 575–600 nm), which emits light that is absorbed preferentially by hemoglobin (the major chromophore in blood) in the cutaneous vessels.[17–19] Radiant energy is converted to heat, causing thermal damage and thrombosis in the target vessels while minimizing absorption in the epidermis. However, the epidermis is not spared completely because of the partial absorption of energy by melanin, which presents an optical

barrier through which light must pass to reach the underlying blood vessels. Absorption of laser energy by melanin causes localized heating in the epidermis, which may, if not controlled, produce permanent complications such as hypertrophic scarring. Furthermore, epidermal melanin reduces the light dose reaching the blood vessels, thereby decreasing the amount of heat produced in the targeted hemangioma and leading to suboptimal improvement of the lesion.

Skin cooling can be used to minimize further epidermal injury. Ice or chilled water has been used in conjunction with laser irradiation.[20–22] However, computed temperature distributions after sustained cooling with these modalities show that in addition to cooling the epidermis, the temperature of subjacent blood vessels is also reduced.[23] Thermal energy removed to protect the epidermis from injury is offset by the additional laser energy required to heat blood vessels to a sufficiently high temperature for destruction.

Spatially selective photocoagulation is the term used to describe the concept of providing epidermal protection while still achieving thermal injury in the upper dermis. In 1994, Nelson and associates[24] described a novel and efficient method of achieving spatially selective photocoagulation with "dynamic" or cryogen spray cooling (CSC). When a cryogen spurt is applied to the skin surface for an appropriately short period of time (on the order of tens of milliseconds), cooling remains localized in the epidermis, leaving the temperature of deeper blood vessels unchanged.[25–27]

We compare the efficacy and safety of noncooled laser treatment (NC-LT) vs. CSC-LT for cutaneous hemangiomas in a large series of patients. The primary efficacy measure was the quantitative assessment of improvements in volume, texture, and color of the NC-LT treatment group compared, on a blinded basis, with the CSC-LT group. Safety was evaluated for each treatment group by monitoring for adverse effects.

Patients and Methods

A retrospective review was conducted of 164 patients with 168 cutaneous hemangiomas treated with the PDL (λ = 585 nm; $\tau\rho$ = 450 μsec) over an 8-year period (January 1991–January 1999). Subject age ranged between 1 month and 43 years (average age, 2 years 11 months). There were 118 female and 46 male patients (an approximate ratio of 2.6:1), all of whom were Asian. All patients received laser treatment with periods ranging from 3 months to 3 years 11 months (mean, 24 months). All were followed for a minimum of 1 year after their last treatment.

Treatments were performed using the Candela (Wayland, MA) model SPTL-1b flash lamp-pumped PDL (λ = 585 nm; $\tau\rho$ = 450 μsec). During January 1991 to June 1995, 82 patients received NC-LT using light doses of 5.5 to 8 J per square centimeter. For the subsequent period of July 1995 to January 1999, 82 patients received CSC-LT using light doses of 9 to 10 J per square centimeter. Laser energy was delivered to the skin through an optical fiber and lens, which focused the beam onto a 7-mm-diameter spot on the hemangioma.

For the CSC-LT group, 1, 1, 1, 2-tetrafluoroethane $C_2H_2F_4$ (R134a; ICE KLEA, Wilmington DE; boiling point = −26.2°C)—an environmentally compatible, nontoxic, nonflammable, Food and Drug Administration-approved refrigerant—was used as the cryogen. Cryogen spurts (τ_c = 50 msec) were sprayed onto the hemangioma through an electronically controlled solenoid valve positioned approximately 10 mm from the skin surface. The spurt covered a nearly circular 10-mm-diameter area. The duration of cryogen spurt (50 msec), and the delay between cryogen delivery and laser illumination (10 msec) were controlled by a programmable digital delay generator.

Each patient was evaluated by chart review. Information regarding the following variables was extracted: age, gender, anatomic location, involved area of hemangioma, complications noted at time of consultation, number of treatments, hemangioma texture and color, and improvement after laser therapy. All pre- and posttreatment photographs were taken under standardized conditions for film, light source, and exposure.

Clinical outcomes were assessed by three plastic surgeons knowledgeable of and experienced in laser treatment, but not involved previously in the study. On a blinded basis, each evaluator was given pre- and posttreatment photographs of each

Table 1. Complications at First Consultation

Complication	NC-LT Group (N = 82)	CSC-LT Group (N = 82)	Total (N = 164)
Obstruction of orifices	30	36	66
Ulceration	5	2	7
Bleeding	3	0	3
Infection	1	0	1
Pain	1	1	2
Total	40	39	79

$\chi^2 = 5.819$, $p = 0.213$.
NC-LT = noncooled laser treatment; CSC-LT = cryogen spray cooling and laser treatment.

Table 2. Number of PDL Treatments in 164 Patients With Cutaneous Hemangiomas

	No. of Treatments						
Group	1	2	3	4	5	6	Total
NC-LT, N (%)	30 (36.59)	21 (25.61)	18 (21.95)	5 (6.10)	8 (9.76)	0 (0)	82 (100)
CSC-LT, N (%)	63 (76.83)	15 (18.29)	2 (2.44)	1 (1.22)	0 (0)	1 (1.22)	82 (100)
No. of patients	93	36	20	6	8	1	164

$\chi^2 = 37.176$, $p = 0.001$.
NC-LT = noncooled laser treatment; CSC-LT = cryogen spray cooling and laser treatment.

patient's lesion. The primary efficacy measure was the quantitative assessment of improvements in lesional volume, texture, and color. The outcomes were evaluated on the following scale: 1, poor (0–25% improvement); 2, fair (26–50% improvement); 3, good (51–75% improvement); and 4, excellent (76–100% improvement). Results for each of the three parameters (volume, texture, and color) of the NC-LT treatment group were compared with the CSC-LT group. Differences between the mean scores for both groups were determined, and a chi-squared analysis was performed.

Results

Information regarding the variables of age, gender, anatomic location, hemangioma volume, and complications at first consultation was obtained for statistical comparison. The mean ages for the NC-LT and CSC-LT groups were 2.5 years and 3.4 years respectively. The male-to-female ratios for the corresponding groups were 22:60 and 24:58 respectively. The majority of hemangiomas (N = 126) were found on the head and neck (74.3%), with 16 lesions (9.8%) on the trunk, 17 lesions (10.4%) on the extremities, and only 9 lesions (5.5%) in the genital area. Hemangioma volumes for the NC-LT and CSC-LT groups ranged from 1 to 400 cm^2 and 1 to 500 cm^2 with averages of 14.5 cm^2 and 16.0 cm^2 respectively. Complications at first consultation (Table 1) involved obstruction of orifices in 66 patients (40.2%). Ulceration was seen in 7 patients (4.3%), and 3 patients (1.8%) gave a history of bleeding. Infection occurred in 1 patient (0.6%) and was secondary to previous ulceration. Two patients (1.2%) had persistent pain resulting from massive ulceration. The two treatment groups exhibited nonsignificant differences with regard to patient age ($p = 0.3352$), gender ($p = 0.861$), hemangioma volume ($p = 0.2454$), and number of complications at first consultation ($\chi^2 = 5.819$, $p = 0.213$).

The number of PDL treatments for the NC-LT and CSC-LT groups are listed in Table 2. The mean number of PDL treatments for the corresponding groups were 2.27 and 1.33 respectively. This difference was significant ($\chi^2 = 37.176$, $p = 0.001$), and indicates that improvement was greater in the CSC-LT group, and thus fewer treatments were required.

The final outcomes and comparison of the NC-LT and CSC-LT groups for each of the three efficacy parameters are summarized in Table 3 and Figures 1 and 2). All patients achieved good or excellent improvement in volume reduction,

Table 3. Response in Lesion Volume Reduction, Texture, and Color by Treatment Group

Response Parameter	Mean Score NC-LT Group	Mean Score CSC-LT Group	*p*-Value
Volume	3.84	3.96	0.008, significant
Texture	3.57	3.90	0.001, significant
Color	3.98	4.00	0.155, not significant

NC-LT = noncooled laser treatment; CSC-LT = cryogen spray cooling and laser treatment.

*Fig 1. A 3-month-old Asian boy with extensive hemangioma on the face. (*A*) View before laser treatment. (*B*) View 4 months after two treatments with cryogen spray cooling and the pulsed dye laser using an energy density of 9 J per square centimeter. The result was evaluated as an excellent response.*

texture, and color. The mean response scores were 3.84 and 3.96 for the NC-LT treatment group compared with the CSC-LT treatment group respectively, indicating enhanced volume reduction in the CSC-LT group. This difference was significant (χ^2 = 6.926, p = 0.008). For the quantitative assessment of texture improvement, the mean response scores were 3.57 and 3.90 for the two groups respectively, indicating an enhanced response in the CSC-LT group. This difference was also significant (χ^2 score = 22.978, p = 0.001). For the quantitative assessment of color improvement of NC-LT compared with CSC-LT, the mean response scores were 3.98 and 4.00 respectively. These data indicate an enhanced clinical response in the CSC-LT group but this was not significant (χ^2 = 2.025, p = 0.155). No permanent adverse effects were reported in either group.

Discussion

The clinical objective in the laser treatment of patients with cutaneous hemangiomas is to maximize thermal damage to targeted blood vessels

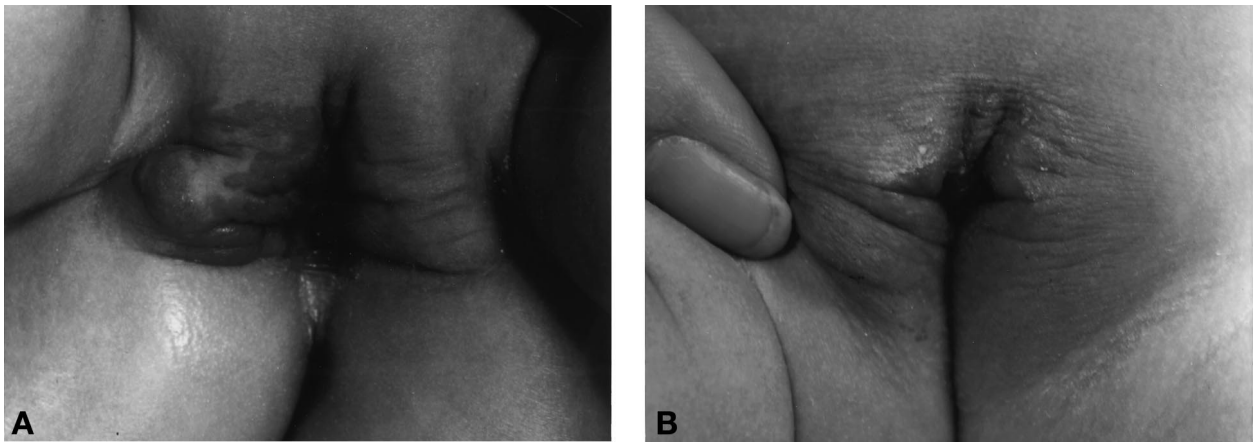

*Fig 2. A 4-month-old Asian girl with obstructive hemangioma of her genital area. (*A*) View before laser treatment. (*B*) View 6 months after two treatments with cryogen spray cooling and the pulsed dye laser using an energy density of 9 J per square centimeter. The result was evaluated as an excellent response.*

while minimizing nonspecific injury to the overlying epidermis. A potential technique to achieve this objective is to cool selectively the most superficial layers of the skin. To be used successfully in combination with laser treatment of these lesions, any cooling modality must adhere to two constraints: Cooling must produce a rapid, substantial reduction in skin surface temperature, and it must provide a spatially selective epidermal temperature reduction, leaving the temperature of the deeper blood vessels unchanged.

In patients with cutaneous hemangiomas undergoing laser treatment, optimal clinical results should be obtained when the ratio of heat generated in the blood vessels is high compared with that in the epidermis. When the skin surface temperature exceeds 70°C immediately after pulsed laser exposure (<1 msec), epidermal necrosis results. CSC permits safe and effective treatment of cutaneous hemangiomas by raising the threshold for epidermal damage.[28] During CSC, the skin surface temperature is reduced as a result of supplying latent heat to the liquid cryogen droplets that strike the skin. The maximum surface temperature achieved immediately after laser exposure is lower on CSC-LT sites compared with NC-LT sites (in some cases by as much as 40°C). After laser irradiation, cryogen remaining on the skin continues to evaporate and remove residual heat. As a result, the temperature of the postirradiated epidermis decreases more rapidly on the CSC-LT sites compared with the NC-LT sites. Cooling remains localized to the epidermis, whereas the temperature of the hemangioma vessels, located at a depth of more than 250 μm, remains unchanged. The time delay before the cold front produced by CSC reaches the most superficial layer (250 μm) of hemangioma vessels is on the order of 100 msec. Therefore, in the current study we chose a cryogen spurt duration of 50 msec to permit selective photothermolysis of hemangioma blood vessels.

Results of our study demonstrate that CSC in conjunction with PDL therapy allows the use of higher light doses to achieve, in fewer treatments, more rapid and complete involution of cutaneous hemangiomas. Based on chi-squared analysis, there were clinical and significant differences in the number of treatments ($p = 0.001$), and improvements in lesional volume ($p = 0.008$) and texture ($p = 0.001$) of the CSC-LT group compared with the NC-LT group.

The quantitative assessment of color improvement of the NC-LT group compared with the CSC-LT group was not significant ($\chi^2 = 2.025$, $p = 0.155$). This may be the result of limited influence of the PDL on the deepest vessels of the hemangioma. Lastly, and most importantly, despite the higher fluences, there were no adverse effects reported in the CSC-LT group.

Conclusion

Our clinical study demonstrates the feasibility of selective epidermal cooling while achieving pho-

tothermolysis of blood vessels during pulsed laser treatment of cutaneous hemangiomas. Currently, all patients are treated with CSC spurt durations and light doses based on the clinical judgment of the physician without taking variations in the biophysical, structural, optical, and thermal properties of human skin and hemangiomas into consideration. Ideally, these parameters should be determined individually for each patient based on knowledge of vessel depth and distribution, and work is currently underway in our laboratory to achieve this goal. In addition, several key technical issues need to be addressed in regard to the development of the cooling device: (1) distance between the valve and skin surface, (2) boiling point of the cryogen, (3) velocity of the cryogen before striking the skin surface, (4) orientation of the valve with respect to the skin surface, (5) the maximal depth that cryogen can reach, and (6) delay between cryogen delivery and laser irradiation. Evaluation of these issues may optimize further CSC for use during laser treatment of cutaneous hemangiomas and other indications.

The authors acknowledge gratefully the support of Robert L. Newcomb, PhD, Director of the Center for Statistical Consulting at the University of California, Irvine, who performed the statistical analysis.

The methodology described in this manuscript is contained within U.S. patent no. 5,814, 040—Apparatus and Method for Dynamic Cooling of Biological Tissue for Thermal Mediated Surgery, awarded to J. Stuart Nelson, MD, PhD, Thomas E. Milner, PhD, and Lars O. Svaasand, PhD, and assigned to the Regents of the University of California.

This project was supported by research grants awarded from the Institute of Arthritis and Musculoskeletal and Skin Diseases (AR-43419) at the National Institutes of Health and Chang Gung Memorial Hospital (CMRP-606, CMRP 812). Institutional support from the National Institutes of Health, Office of Naval Research, Department of Energy, and the Beckman Laser Institute and Medical Center endowment is also gratefully acknowledged.

References

1 Bowers RE, Graham EA, Omlinson KM. The natural history of the strawberry nevus. Arch Dermatol 1960;82:667–680
2 Mulliken JB, Glowacki J. Hemangiomas and vascular malformations in infants and children: a classification based on endothelial characteristics. Plast Reconstr Surg 1982; 69(3):412–422
3 Cohen A. Hemangiomas in infancy and childhood. Pediatr Ann 1987;16:17–26
4 Rebeiz E, April MM, Bohigian RK, Shapahay SM. Nd-YAG laser treatment of venous malformations of the head and neck: an update. Otolaryngol Head Neck Surg 1991;105(5): 655–661
5 Goldwyn RM, Rosoff CB. Cryosurgery for large hemangiomas in adults. Plast Reconstr Surg 1969;43(6):605–611
6 Achauer BM, Vander Kam VM. Strawberry hemangioma of infancy: early definitive treatment with an argon laser. Plast Reconstr Surg 1991;88(3):486–489
7 Sasaki GH, Pang CY, Wittliff JL. Pathogenesis and treatment of infant skin strawberry hemangiomas: clinical and in vitro studies of hormonal effects. Plast Reconstr Surg 1984;73(3):359–370
8 Apfelberg DB, Maser MR, Lash H. Argon laser management of cutaneous vascular deformities. West J Med 1976; 124(2):99–101
9 Hobby LW. Further evaluation of the potential of argon laser in the treatment of strawberry hemangiomas. Plast Reconstr Surg 1983;71(4):481–489
10 Rosenfield H, Sherman R. Treatment of cutaneous and deep vascular lesions with Nd:YAG laser. Lasers Surg Med 1986;6(1):20–23
11 Apfelberg DB, Maser MR, White DN, et al. Benefits of contact and noncontact YAG laser for periorbital hemangiomas. Ann Plast Surg. 1990;24(5):397–408
12 Werner AJ, Lippert BM, Hoffmann P, Rudert H. Nd:YAG laser therapy of voluminous hemangiomas and vascular malformation. Adv Otorhinolaryngol 1995;49:75–80
13 Apfelberg DB. Intralesional laser photocoagulation–steroids as an adjunct to surgery for massive hemangiomas and vascular malformations. Ann Plast Surg. 1995;35(2): 144–148
14 Achauer BM, Chang CJ, Vander Kam VM, Boyko A. Intralesional photocoagulation of periorbital hemangiomas. Plast Reconstr Surg 1999;103(1):11–16
15 Chang CJ, Fisher DM, Chen YR. Intralesional photocoagulation of vascular anomalies of the tongue. Br J Plast Surg 1999;52(3):178–181
16 Achauer BM, Vander Kam VM. Capillary hemangioma (strawberry mark) of infancy: comparison of argon and Nd:YAG laser treatment. Plast Reconstr Surg 1989;84(1): 60–69
17 Ashinoff R, Geronemus RG. Flashlamp-pumped pulsed dye laser for port wine stains in infancy: earlier versus later treatment. J Am Acad Dermatol 1991;24(3):467–472
18 Nelson JS, Applebaum J. Clinical management of port wine stain in infants and young children using the flashlamp-pumped dye laser. Clin Pediatr 1990;29(9):503–508
19 Nelson JS. Selective photothermolysis and removal of cutaneous vasculopathies by pulsed laser. Plast Reconstr Surg 1991;88(4):723–731
20 Gilchrest BA, Rosen S, Noe JM. Chilling port wine stains improves the response to argon laser therapy. Plast Reconstr Surg 1982;69(2):278–283
21 Dreno B, Patrice T, Litoux P, Barriere H. The benefit of chilling in argon laser treatment of port wine stains. Plast Reconstr Surg 1985;75(1):42–45
22 Chess C, Chess Q. Cool laser optics treatment of large telangiectasia of the lower extremities. J Dermatol Surg Oncol 1993;19(1):74–80
23 Anvari B, Milner TE, Tanenbaum BS, et al. Dynamic epidermal cooling in conjunction with laser treatment of port wine stains: theoretical and preliminary clinical evaluations. Lasers Med Sci 1995;10:105–112
24 Nelson JS, Milner TE, Anvari B, et al. Dynamic cooling of the epidermis during laser port wine stain therapy. Lasers Surg Med 1994;6S:48
25 Nelson JS, Milner TE, Anvari B, et al. Dynamic epidermal cooling during pulsed laser treatment of port wine

stain—a new methodology with preliminary clinical evaluation. Arch Dermatol 1995;131(6):695–700
26 Nelson JS, Milner TE, Anvari B, et al. Dynamic epidermal cooling in conjunction with laser-induced photothermolysis of port wine stain blood vessels. Lasers Surg Med 1996;19(2):224–229
27 Waldorf HA, Alster TS, McMillan K, et al. Effect of dynamic cooling on 585 nm pulsed dye laser treatment of port wine stain birthmarks. Dermatol Surg 1997;23(8): 657–662
28 Chang CJ, Nelson JS. Cryogen spray cooling and higher fluence pulsed dye laser treatment improve port-wine stain clearance while minimizing epidermal damage. Dermatol Surg 1999;25(10):767–772