

# UC Irvine

## UC Irvine Previously Published Works

### Title

Fractionated ablative carbon dioxide laser treatment of steatocystoma multiplex

### Permalink

<https://escholarship.org/uc/item/9n74p88r>

### Journal

Journal of Cosmetic and Laser Therapy, 18(7)

### ISSN

1476-4172

### Authors

Kassira, Sama  
Korta, Dorota Z  
de Feraudy, Sebastien  
[et al.](#)

### Publication Date

2016-10-02

### DOI

10.1080/14764172.2016.1188212

Peer reviewed



Published in final edited form as:

*J Cosmet Laser Ther.* 2016 November ; 18(7): 364–366. doi:10.1080/14764172.2016.1188212.

## Fractionated Ablative Carbon Dioxide Laser Treatment of Steatocystoma Multiplex

Sama Kassira<sup>1</sup>, Dorota Z. Korta, MD, PhD<sup>2</sup>, Sebastien de Feraudy, MD, PhD, and Christopher B. Zachary, FRCP<sup>2</sup>

<sup>1</sup>University of Alabama School of Medicine, Birmingham, AL

<sup>2</sup>Department of Dermatology, University of California Irvine, Irvine, CA

### Abstract

Steatocystoma multiplex is a well-recognized condition in which subjects develop dermal cysts generally inherited in an autosomal dominant fashion, though these can occur sporadically. This case report describes the successful treatment of a 51-year-old woman with steatocystomata limited to the face, who after two treatments with a fractionated ablative carbon dioxide laser remained free of cysts for 3 years. We conclude that this treatment should be considered as an efficient and effective treatment option for patients with steatocystoma multiplex.

### Keywords

Steatocystoma; fractionated; laser; Fraxel

### Introduction

Steatocystoma multiplex (SM) is an uncommon condition in which dermal cysts most often arise on the chest but may also occur on the abdomen, upper arms, armpits and, as in this case report, the face. Facial SM subjects are more likely to have cosmetic concerns than in those whose dermal cysts occur in less aesthetically sensitive areas. While SM is generally inherited in an autosomal dominant fashion, steatocystomas can occur sporadically, with both males and females being affected equally (1). Steatocystomata are thought to arise from an abnormal lining of the sebaceous duct, and onset at puberty is common and likely due to hormonal stimulus of the pilosebaceous unit (1,2). The cysts are generally small (2–4mm) somewhat firm bumps, which contain an oily, yellow liquid, and can occasionally contain one or more hairs. Some may become inflamed and heal with scarring (3).

This case report describes the successful treatment of a 51-year-old woman with the sporadic form of SM limited to the face, who after two treatments with a fractionated ablative carbon dioxide laser remained free of cysts for 3 years. We conclude that this treatment should be considered as an efficient and effective treatment option for patients with steatocystoma.

## Case Report

A 51-year old Caucasian female presented to the dermatology clinic complaining of numerous bumps on her face, present since early adolescence. Prior to presentation, she had undergone multiple treatments for these cosmetically bothersome lesions including oral tetracycline, cryotherapy, and various topical agents such as salicylic acid, glycolic acid washes, benzoyl peroxide, and tretinoin 0.05% cream. None of these treatments provided any satisfactory improvement. There were no significant underlying medical problems, no relevant medications, and no known drug allergies. No family members had similar lesions.

Physical examination revealed multiple yellow-white papules scattered over the face, particularly concentrated on the forehead and bilateral temples (Figure 1a).

Biopsy was performed of a representative lesion, and histopathology revealed keratin debris found within a dermal cystic structure. A characteristic cuticle was observed within the cyst. These findings confirmed the diagnosis of steatocystoma multiplex (Figure 2).

The patient understood that this condition posed no real medical issues, but wanted treatment for cosmetic reasons. Given the extent of the lesions and the patient's desire for minimal scarring and low downtime, we elected to perform a test treatment with the Fraxel re:pair® fractionated ablative CO<sub>2</sub> laser limited to the right temple. After appropriate consent, the area was thoroughly washed, and rendered anesthetic with topical 23/7% lidocaine/tetracaine. A 6cm<sup>2</sup> area was then treated with the fractionated ablative CO<sub>2</sub> laser with the following settings: 70 mJ, 70% coverage, 8 passes, though only 6 passes were actually delivered, with a total energy of 0.25 kJ. Immediately after treatment, topical fluocinonide 0.05% ointment was applied. Healing was uneventful except that over the subsequent two weeks, the patient reported spontaneous expression of yellow-white contents from the SM papules, and a total disappearance of these after approximately 4 weeks.

Given the excellent result of the test treatment, two further treatments were given at 4 and 8 months over the entire face using similar parameters. She experienced significant cosmetic improvement, which was persistent at 3-year follow-up (Figure 1b).

## Discussion

SM is an uncommon benign condition presenting with multiple dermal papules. These are often 2–4 mm in diameter, but can grow if unchecked to form 2cm or larger cysts (2). The familial form of SM is associated with a keratin 17 gene mutation (4). Keratin 17 is a type 1 cytokeratin, which is involved in the assembly of intermediate keratin filaments (2). The gene for keratin 17 is located on chromosome 17 (2). Recently, a specific causation mutation for this gene on Exon 1 (R94C) has been discovered in a Chinese SM pedigree, and not found in unaffected controls (4). The presence of keratin 17 in sebaceous glands and the increase of sebaceous glands during puberty may explain the average age of onset in SM in early adulthood (5).

SM has multiple associations with other dermatologic conditions and systemic diseases, including ichthyosis, pachyonychia congenita type 2, hypothyroidism, hidradenitis

suppurativa, and some forms of lichen planus (6). Pachyonychia congenita type 2 exhibits the same keratin 17 mutations as SM. Rare associations have also been found with pilar cysts, preauricular sinuses, natal teeth, and trichoblastomas (5).

The diagnosis of SM requires exclusion of several differential diagnoses. Specifically, it is important to exclude vellus hair cysts, milia, follicular infundibula tumors, and epidermal inclusion cysts, as the clinical presentation of these conditions may be very similar to steatocystomata. Under histopathological examination, epidermal inclusion cysts and vellus hair cysts do not exhibit sebaceous glands within the cyst wall, which is characteristic of steatocystomata (2). Milia are often found in the superficial dermis and exhibit very small cysts. Follicular infundibulum tumors display a plate-like dermal pattern with many small, thin connections to the epidermis (7). Steatocystoma contain cellular debris and exhibit connections to the epidermis, but often these connections are a few straight epithelial cords rather than the multiple small connections seen in tumors of the follicular infundibulum (2).

Although benign, those affected with SM often experience significant psychological distress due to cosmetic reasons, leading them to seek treatment. This is especially common when patients present with SM cysts on the face, as was the case with our patient.

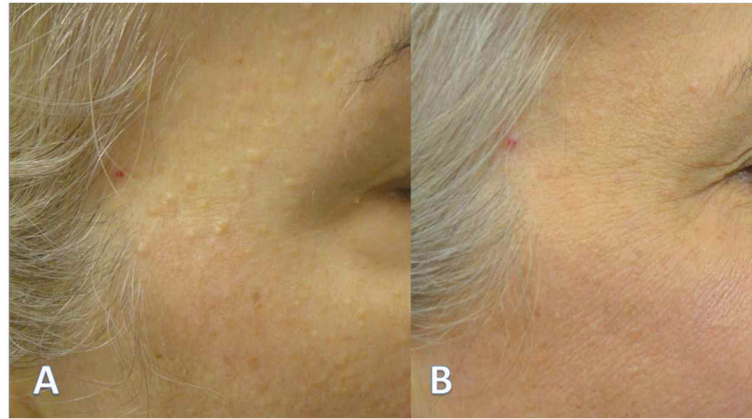Multiple treatments for SM have been attempted. Earlier treatments included cryotherapy, aspiration, or excision, but these were often complicated by scarring (5). Furthermore, cryotherapy and aspiration do not remove the cyst wall and are therefore often associated with recurrence (5). Incision of steatocystoma with a radiofrequency device or surgical blade incision with removal using a vein hook have both been successful without recurrence or scarring, but these methods require treatment to each singular cyst and therefore are very time consuming to perform (8,9). Finally, oral isotretinoin has also been utilized as a treatment for the suppurative form of SM (10–14) with good cosmetic result, but adverse reactions such as worsening in the size and number of cysts have been reported (12,13).

More recently, SM has been successfully treated in case studies with the fractionated 1450nm diode laser, the fractionated erbium: yttrium-aluminum-garnet (Er:YAG) laser, and the non-fractionated CO<sub>2</sub> lasers (15–17). The CO<sub>2</sub> and Er:YAG lasers have also been utilized to create a punctum for manual expiration of cyst contents, with no scarring or recurrence at 2 year follow up (16,17).

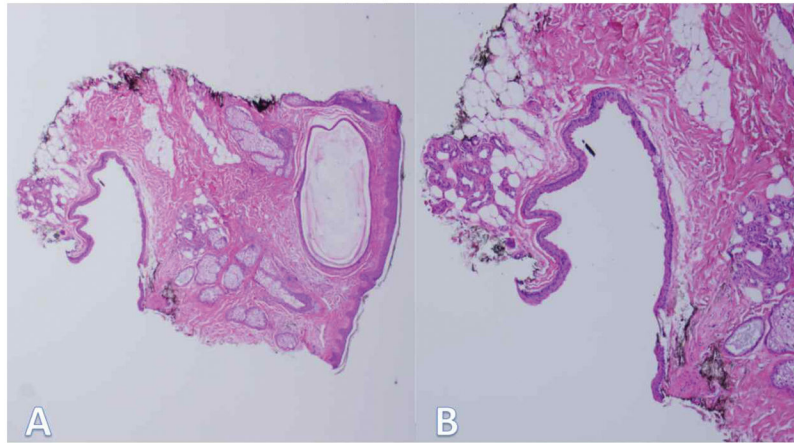
Treatment with the fractionated ablative CO<sub>2</sub> laser is attractive because it offers decreased recovery times and decreased pain when compared to unfractionated ablative CO<sub>2</sub> lasers (18). Furthermore, compared to non-laser treatment modalities, treatment of SM with fractionated ablative CO<sub>2</sub> is less time consuming, and, at least in our case, carried a reduced risk of scarring. This case report describes the successful treatment of SM with no recurrence after a three-year follow up. The normal expectation might be that these would indeed recur given that the SM cyst walls were not actually removed with this treatment. Understanding this phenomenon might require one to propose that the instigating hormonal factor during puberty is actually required for initialization of these cysts, similar to the cysts associated with acne vulgaris.

## References

1. Bakkour W, Madan V. Carbon dioxide laser perforation and extirpation of steatocystoma multiplex. *Dermatol Surg.* 2014; 40(6):658–62. 2014/05/24 ed. [PubMed: 24852470]
2. Kamra HT, Gadgil PA, Ovhal AG, Narkhede RR. Steatocystoma multiplex-a rare genetic disorder: a case report and review of the literature. *J Clin Diagn Res.* 2013; 7(1):166–8. 2013/03/02 ed. [PubMed: 23449619]
3. Hansen KK, Troy JL, Fairley JA. Multiple papules of the scalp and forehead. Steatocystoma multiplex (facial papular variant). *Arch Dermatol.* 1995; 131(7):835, 838. 1995/07/01 ed. [PubMed: 7611805]
4. Liu Q, Wu W, Lu J, Wang P, Qiao F. Steatocystoma multiplex is associated with the R94C mutation in the KRT17 gene. *Mol Med Rep.* 2015 Oct; 12(4):5072–6. [PubMed: 26165312]
5. Gordon Spratt EA, Kaplan J, Patel RR, Kamino H, Ramachandran SM. Steatocystoma. *Dermatol Online J.* 2013; 19(12):20721. 2013/12/25 ed. [PubMed: 24365012]
6. Kim SJ, Park HJ, Oh ST, Lee JY, Cho BK. A case of steatocystoma multiplex limited to the scalp. *Ann Dermatol.* 2009; 21(1):106–9. 2009/02/01 ed. [PubMed: 20548872]
7. Cheng AC-C, Chang Y-L, Wu Y-Y, Hu S-L, Chuan M-T. Multiple tumors of the follicular infundibulum. *Dermatol Surg.* 2004 Sep; 30(9):1246–8. [PubMed: 15355370]
8. Choudhary S, Koley S, Salodkar A. A modified surgical technique for steatocystoma multiplex. *J Cutan Aesthet Surg.* 2010; 3(1):25–8. 2010/07/08 ed. [PubMed: 20606990]
9. Lee SJ, Choe YS, Park BC, Lee WJ, Kim do W. The vein hook successfully used for eradication of steatocystoma multiplex. *Dermatol Surg.* 2007; 33(1):82–4. 2007/01/12 ed. [PubMed: 17214684]
10. Apaydin R, Bilen N, Bayramgürler D, Ba da F, Harova G, Dökmeci S. Steatocystoma multiplex suppurativum: oral isotretinoin treatment combined with cryotherapy. *Australas J Dermatol.* 2000 May; 41(2):98–100. [PubMed: 10812703]
11. Moritz DL, Silverman RA. Steatocystoma multiplex treated with isotretinoin: a delayed response. *Cutis.* 1988 Nov; 42(5):437–9. [PubMed: 3197445]
12. Rosen BL, Brodtkin RH. Isotretinoin in the treatment of steatocystoma multiplex: a possible adverse reaction. *Cutis.* 1986 Feb.37(2):115, 120. [PubMed: 3456886]
13. Schwartz JL, Goldsmith LA. Steatocystoma multiplex suppurativum: treatment with isotretinoin. *Cutis.* 1984 Aug; 34(2):149–50. 153. [PubMed: 6592069]
14. Statham BN, Cunliffe WJ. The treatment of steatocystoma multiplex suppurativum with isotretinoin. *Br J Dermatol.* 1984 Aug.111(2):246. [PubMed: 6590088]
15. Moody MN, Landau JM, Goldberg LH, Friedman PM. 1,450-nm diode laser in combination with the 1550-nm fractionated erbium-doped fiber laser for the treatment of steatocystoma multiplex: a case report. *Dermatol Surg.* 2012; 38(7 Pt 1):1104–6. 2012/04/11 ed. [PubMed: 22487444]
16. Mumcuoglu CT, Gurel MS, Kiremitci U, Erdemir AV, Karakoca Y, Hutten O. Er: yag laser therapy for steatocystoma multiplex. *Indian J Dermatol.* 2010; 55(3):300–1. 2010/11/11 ed. [PubMed: 21063535]
17. Rossi R, Cappugi P, Battini M, Mavilia L, Campolmi P. CO2 laser therapy in a case of steatocystoma multiplex with prominent nodules on the face and neck. *Int J Dermatol.* 2003; 42(4):302–4. 2003/04/16 ed. [PubMed: 12694500]
18. Preissig J, Hamilton K, Markus R. Current Laser Resurfacing Technologies: A Review that Delves Beneath the Surface. *Semin Plast Surg.* 2012 Aug; 26(3):109–16. [PubMed: 23904818]



**Figure 1.**  
a) Steatocystoma of the face prior to treatment b) Cosmetically satisfactory results at 3-year follow-up after 2 treatments with Fraxel re:pair® CO<sub>2</sub> ablative fractionated laser.



**Figure 2.**

a) H&E XXX magnification. A punch biopsy demonstrates keratin debris found within a dermal cystic structure, consistent with steatocystoma. b) H&E XX magnification.