

UCSF

UC San Francisco Previously Published Works

Title

Hemodynamic assessment of transitioning from parenteral prostacyclin to selexipag in pediatric pulmonary hypertension.

Permalink

<https://escholarship.org/uc/item/9n7924zk>

Journal

Pulmonary Circulation, 12(4)

ISSN

2045-8932

Authors

Colglazier, Elizabeth
Stevens, Leah
Parker, Claire
[et al.](#)

Publication Date


2022-10-01

DOI

10.1002/pul2.12159

Peer reviewed

Hemodynamic assessment of transitioning from parenteral prostacyclin to selexipag in pediatric pulmonary hypertension

Elizabeth Colglazier¹ | Leah Stevens¹ | Claire Parker¹ |
Hythem M. Nawaytou¹ | Elena K. Amin¹ | Jasmine Becerra¹ |
Martina Steurer¹ | Jeffrey R. Fineman MD^{1,2} 

¹Department of Pediatrics, UCSF Benioff Children's Hospital, San Francisco, California, USA

²UCSF Cardiovascular Research Institute, San Francisco, California, USA

Correspondence

Jeffrey R. Fineman, MD, Department of Pediatrics, UCSF Benioff Children's Hospital, 550 16th St, 5th Floor, San Francisco, CA 94143, USA.
Email: jeff.fineman@ucsf.edu

Funding information

None

Abstract

Despite the increase in therapeutic options, parenteral prostacyclins remain the cornerstone in the medical management of pulmonary arterial hypertension (PAH). While the use of parenteral prostacyclins in pediatric patients is well documented, less is known about alternative drug delivery methods such as enteral administration. Given that parenteral routes of prostacyclin administration (IV or SC) are invariably accompanied by complicated logistics and lifestyle compromises, enteral prostacyclin administration represents an attractive treatment option. Selexipag (Uptravi®) was approved for adults PAH in 2015. There is limited data on the hemodynamic efficacy of transitioning from parenteral prostacyclins to selexipag, particularly in the pediatric population. We report 11 pediatric PAH patients who underwent this transition, in which 10 had complete cardiac catheterization data before and following the transition to selexipag. All patients/families reported an improvement in quality of life, and the transitions occurred without adverse effects. However, 3 of the 11 (27%) did not tolerate the transition; two for worsening hemodynamics, and one for acute right ventricular failure in the setting of an intercurrent illness. In addition, the transition to selexipag was associated with a modest increase in pulmonary vascular resistance index (6/10) and decrease in cardiac index (6/10) in some patients. Selexipag use in pediatric PAH represents a significant addition to our therapeutic arsenal, and its use provides a meaningful improvement in quality of life compared with other prostacyclin formulations. However, when goals of care include aggressive disease management, a decision between improved quality of life and possible adverse outcomes must be considered, and its substitution should include cautious, close, long-term follow-up.

KEYWORDS

prostacyclin, pulmonary hypertension, pulmonary vascular disease, selexipag

This is an open access article under the terms of the Creative Commons Attribution-NonCommercial License, which permits use, distribution and reproduction in any medium, provided the original work is properly cited and is not used for commercial purposes.

© 2022 The Authors. *Pulmonary Circulation* published by John Wiley & Sons Ltd on behalf of Pulmonary Vascular Research Institute.

INTRODUCTION

Recent advances in the recognition and treatment of pediatric pulmonary vascular disease have resulted in improved outcomes for this vulnerable patient population.¹ For example, before 1995, and the introduction of prostacyclin therapy for pulmonary arterial hypertension (PAH), the median survival for idiopathic pulmonary hypertension was 2.8 years, with a 3-year survival of 48%.² With the development of advanced pulmonary vascular therapies that now include phosphodiesterase 5 inhibitors (PDE5i) and endothelin receptor antagonists (ERA), more recent pediatric data using an aggressive therapeutic approach, demonstrates a markedly improved survival (1-year survival of 100%; 3-year survival of 87%).³ However, parenteral prostacyclins remain the cornerstone in the medical management of PAH and remain the only therapeutic modality to have shown an improvement in long-term survival with PAH.^{4,5} While there is a significant body of literature and clinical experience surrounding the use of parenteral prostacyclins in pediatric patients, less is known about alternative drug delivery methods such as enteral administration.⁶ Given that parenteral routes of prostacyclin administration (IV, SC, or inhaled) are invariably accompanied by complicated logistics as well as lifestyle compromises, enteral prostacyclin administration represents an attractive treatment option. For example, site pain, which at times can be intolerable, is a well-documented side effect of SC treprostinil.^{7,8} Although the intravenous delivery of treprostinil intravenously avoids site pain, it carries the risk of potentially life-threatening complications including malposition, thrombus, and infection associated with the presence of a central venous catheter. Inhaled prostacyclins require frequent administration and delivery through a designated and costly inhalation system. These issues may be particularly challenging in infants, children, and adolescents.

In contrast to epoprostenol and treprostinil, which are prostacyclin analogs, selexipag is a selective non-prostanoid prostacyclin receptor (IP) agonist which has no activity at the EP₃ receptor, a receptor that is thought to contribute to vasoconstriction.^{9,10} Following large, randomized trials in adult PAH that demonstrated a significant decrease in mortality and PAH complications, selexipag (Upravi®) was approved for the treatment of adults with PAH in 2015.^{9,10} Despite its increasing use in both the adult and pediatric PAH populations, there is limited data on the hemodynamic efficacy of transitioning from parenteral prostacyclins to selexipag, particularly in the pediatric population.^{11–20} Therefore, the objective of this study was to characterize the hemodynamic changes associated with transitioning from parenteral prostacyclins to enteral selexipag in children. To this end, we retrospectively collected hemodynamic

data from 11 children who had undergone a transition from parenteral prostacyclin ($n = 7$ SC treprostinil; $n = 1$ IV treprostinil; and $n = 3$ inhaled tyvaso) to enteral selexipag from October 2016 to May 2022.

METHODS

This is a retrospective chart review study. All patients cared for by the UCSF Pediatric Pulmonary Service between October 2016 to May 2022 who had undergone a transition from either continuous or inhaled prostacyclin therapy to selexipag were identified ($N = 17$). Six patients were excluded due to inadequate follow-up hemodynamic data.

The remaining 11 patients underwent a transition from parenteral (SC, IV, or inhaled) treprostinil therapy to selexipag with the intent of improving quality of life while still pursuing aggressive medical management. These patients are described in our statistical analyses. One of these 11 patients had clinical and echo evidence of acute right ventricular (RV) failure during an intercurrent illness 1 month after transitioning. Given her tenuous clinical status, she did not undergo cardiac catheterization before re-initiation of tyvaso.

Transitions

Nine of our 11 total patients were transitioned from treprostinil to selexipag as outpatients with weekly increases in selexipag doses ranging from 50 to 200 mcg twice daily, while inhaled or parenteral treprostinil doses were simultaneously decreased. One patient underwent a similar protocol as an inpatient, and one underwent a previously described rapid transition from IV treprostinil to selexipag over 5–7 days while in the hospital.²¹

Baseline characteristics were described using mean and standard deviation. A variety of hemodynamic data (pulmonary vascular resistance indexed [PVRI], mean pulmonary arterial pressure [MPAP], transpulmonary gradient [TPG, the mean pulmonary arterial pressure minus the left atrial or pulmonary capillary wedge pressure], and cardiac index [CI]), B-type natriuretic factor (BNP), WHO functional class (FC), and 6-min walk test (6MWT), were compared by paired *t*-tests between the following time points: (a) before initiation of parenteral prostacyclin, (b) on parenteral prostacyclin therapy before transitioning to selexipag, and (c) on oral selexipag following a transition off parenteral prostacyclin therapy. A *p* value of <0.05 was considered statistically significant.

All 11 reported patients were simultaneously treated with a PDE-5 inhibitor, and 10/11 were treated with an

ERA. There were no changes to these drugs during the transition and evaluation period.

Failure to tolerate the transition to selexipag was defined as clinical and/or hemodynamic deterioration that led to re-initiation of pretransition parenteral prostacyclin therapy. However, deterioration that did not lead to re-initiation of parenteral prostacyclin therapy during the follow-up period is also reported.

The study was approved by the UCSF Institutional Review Board with waiver of consent.

RESULTS

Eleven patients underwent a transition from continuous (SC/IV) treprostinil therapy to selexipag with the intent of improving quality of life while still pursuing aggressive medical management (Table 1). Transitions in this group were undertaken for improved quality of life in the setting of either adequate disease control ($n = 9$) or intolerance of continuous therapy ($n = 2$). Seven of the patients were female (73%); the mean age at presentation with PAH was 8 years; and all were WHO Group 1 (100%). Before transition the mean duration of treprostinil therapy was 20 months, and tyvaso therapy was 51 months. The mean duration of selexipag therapy at evaluation was 9 months.

Figure 1 describes the hemodynamic changes in the 11-patient cohort that was undergoing aggressive medical management. All patients had hemodynamic evaluations before and after treprostinil initiation; 10/11 also had hemodynamic evaluations after the transition from parenteral to enteral therapy. As seen in Figure 1, initiation of treprostinil therapy resulted in a significant decrease in indexed PVRI (from 12.4 ± 6.8 to 5.9 ± 1.9 woods units (WU), $p < 0.05$) (Figure 1a) and mean branch pulmonary arterial pressure (mPAP) (from 53.3 ± 15.5 to 37.8 ± 10.8 mmHg, $p < 0.05$) (Figure 1b). This was associated with a decrease in TPG (from 42.5 ± 16 to 26.9 ± 7.7 , $p < 0.05$) (Figure 1c). The increase in CI (from 3.3 ± 1.0 to 3.8 ± 1.0 l/min/m²) did not reach statistical significance ($p = 0.30$) (Figure 1d). Following transitioning to selexipag ($n = 10$) there were modest, but nonsignificant increases in PVRI to 7.3 ± 2.6 WU ($p = 0.07$). On average, mPAP to 41.8 ± 12.7 mmHg ($p = 0.50$), TPG to 30.6 ± 10.5 ($p = 0.17$), and CI (3.8 ± 1.0 to 3.8 ± 0.9 l/min/m²) did not change. However, PVRI increased in 6 of the 10 patients, mPAP increased in 5 of the 10 patients, TPG increased in 7 of 10 patients, and CI decreased in 6 of 10 patients (Figure 1). Mean B-type natriuretic factor (BNP) decreased with initiation of continuous prostacyclin therapy (from 408.1 ± 99 to 35.6 ± 32 pg/ml, $p < 0.05$, $n = 9$). Following

TABLE 1 Patient demographics

Demographics	All patients ($n = 11$)
Sex, male, n (%)	4 (27)
Age at diagnosis (years)	
Median	10
Interquartile range	14
PH WHO group classification, n (%)	
PH Group 1	11 (100)
PH Group 2	0 (0)
PH Group 3	0 (0)
PH Group 4	0 (0)
Remodulin dosing (ng/kg/min)	
Median	79.5
Interquartile range	29
Tyvaso dosing (mcg)	
Median	48
Interquartile range	N/A ^a
Selexipag dosing (mcg)	
Median	1600
Interquartile range	800
Duration of remodulin ^b (months)	
Median	19
Interquartile range	11.95
Duration of tyvaso ^b (months)	
Median	48.6
Interquartile range	N/A ^a
Duration of selexipag ^c (months)	
Median	9.95
Interquartile range	4.5

^aSample size too small.

^bAt time of pre-selexipag catheterization.

^cAt time of first post-selexipag catheterization.

the transition to selexipag there was a modest but nonsignificant increase in BNP to 86.1 ± 25 pg/ml ($p = 0.44$). Functional class remained I-II in the majority of the cohort. Three patients had 6MWT before and after the transition to selexipag, which were unchanged. Importantly, there were no significant differences in baseline pulmonary vascular hemodynamics between the 60% of patients in which vascular hemodynamics worsened with the transition compared with the 40% of patients in which there were no changes.

Three of these 11 patients (27%) failed the transition and required re-initiation of parenteral therapy. Two had been on

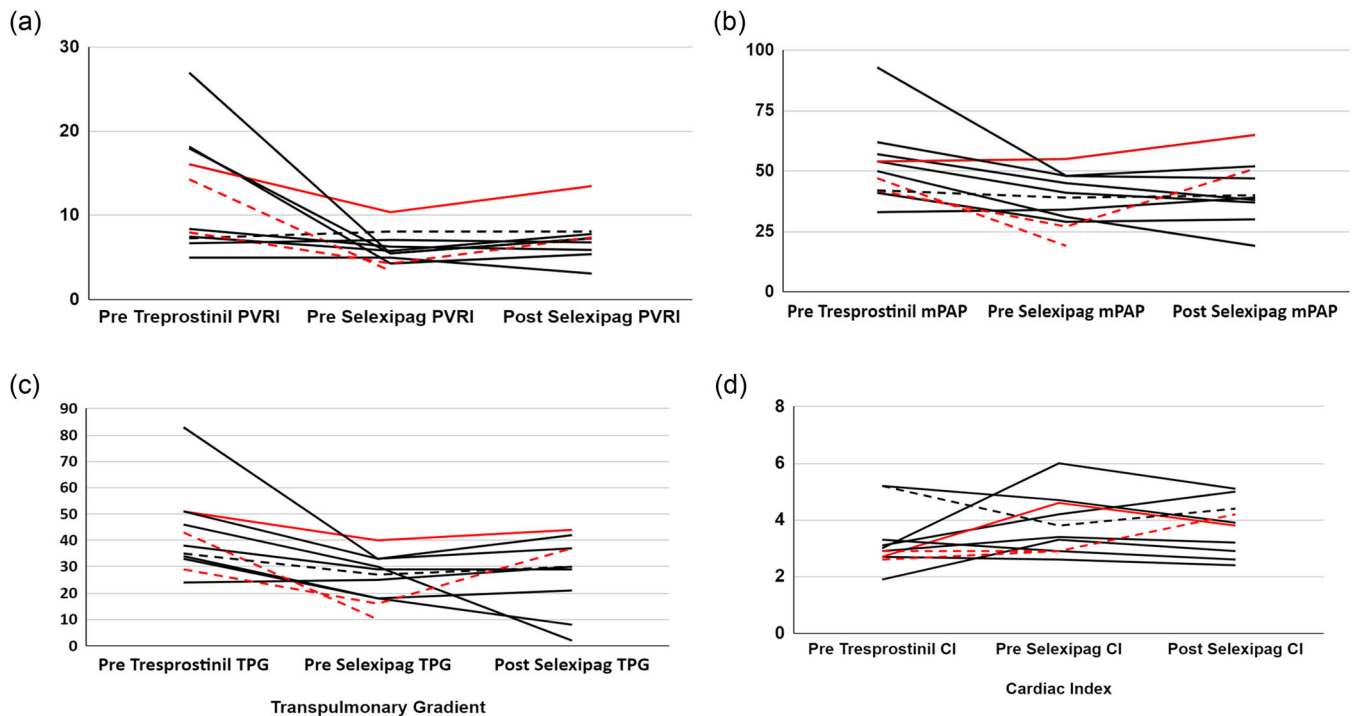


FIGURE 1 Changes in indexed pulmonary vascular resistance (PVRI, a), mean pulmonary arterial pressure (mPAP, b), transpulmonary gradient (TPG, c), and cardiac index (CI, d), before initiation of a prostacyclin, on parenteral (continuous or inhaled) prostacyclin therapy, and on oral selexipag following a transition off continuous or inhaled prostacyclin therapy. Solid lines ($n = 8$) indicate those that transitioned from SC/IV Treprostinil. Dashed lines ($n = 3$) indicate those that transitioned from inhaled tyvaso. Red lines indicate a failed transition.

inhaled treprostinil before the transition to selexipag, and one was on SC treprostinil. Two patients failed for worsening PAH (an increase in PVRI, mPAP, and TPG) (Figure 1). Clinical worsening was demonstrated in one of these patients as an increase in FC from II to III. One patient failed for acute RV failure in the setting of an intercurrent viral illness one month following the selexipag transition. Due to the clinical and echo evidence of acute RV failure, cardiac catheterization data was not obtained in this patient before re-initiation of tyvaso. Re-initiation of parenteral therapy resulted in improvement in two of the three patients. The third patient, after transient improvement, suffered from progression of his complex arterial and venous disease and died.

There were no reported adverse effects during the transitions. All patients and/or their families reported a quality-of-life preference for the oral selexipag therapy over their previous prostacyclin delivery (continuous SC, IV, or intermittent inhaled).

DISCUSSION

With the expansion of advanced therapies, the lifespan of PAH patients has improved dramatically. As such, PAH is more commonly transitioned into a chronic disease in which

quality of life issues have become more paramount. Historically, the targeted therapeutic cascade associated with the most disturbance of day-to-day life has been the prostacyclin cascade, which has necessitated either continuous SC or IV infusions or frequent inhaled deliveries. Thus, an enteral prostacyclin alternative has been met with great enthusiasm. However, detailed hemodynamic characterization of the transition from continuous or inhaled prostacyclin therapy to enteral therapy, particularly in the pediatric population is lacking. We report 11 pediatric PAH patients who underwent this transition, in which 10 had complete cardiac catheterization data before and following the transition to selexipag. As a group, the patients had nonstatistically significant changes in hemodynamics after the transition. However, pulmonary vascular hemodynamics worsened in ~60% of patients, and 3 of the 11 (27%) did not tolerate the transition; two for worsening hemodynamics, and one for acute RV failure in the setting of an intercurrent illness. Thus, such transitions require close follow-up, and should not be performed without careful consideration of quality of life issues versus the risk of potential adverse outcomes.

Available data are limited by the small number of patients, lack of hemodynamic confirmation, long-term follow-up, and sparse pediatric data.^{12–20} The largest series to date is presented by Frost et al. In this series the

authors present 34 adult patients that underwent a transition from inhaled treprostinil to oral selexipag with successful transition in 32 patients (94%) as assessed by changes in functional class, BNP, and 6MWT over a 16-week period. No hemodynamic assessments were made, and these patients were long-term survivors with a mean time from diagnosis to transition of 8 years.¹⁷ Yanaka et al. reported a series of eight adult patients transitioned from IV epoprostenol to oral selexipag in which hemodynamic assessments were made by cardiac catheterizations. In this series, similar to the Frost series, BNP and 6MWT remained stable. However, mPAP and PVR increased in ~25% of the patients, and CI significantly declined in the entire group, voicing concern for close clinical and hemodynamic follow-up.¹² Importantly, Holthaus et al. also noted a decrease in CI in 3 of the 5 adult patients that underwent transition from parenteral prostacyclin to oral selexipag.¹⁹ Therefore, it is noteworthy that in this current pediatric series, we also demonstrate an increase in pulmonary vascular hemodynamics in ~60% of patients and a decrease in CI in 6 of the 10 patients that transitioned from parenteral treprostinil to selexipag in those that underwent a transition while pursuing aggressive medical management. In addition, since the hemodynamic worsening was only associated with an increase in functional class in one patient, these data emphasize the importance of invasive versus noninvasive evaluation.

A few limitations of this study are noteworthy including the retrospective nature of the investigation and the small sample size. In addition, it should be stressed that the relatively short duration of follow-up (~10 months) is a significant limitation, particularly since a subset that remained on selexipag did have worsening pulmonary vascular hemodynamics. Lastly, the contribution of advancing pulmonary vascular disease to any of the hemodynamic changes that occurred during the transition period cannot be excluded. However, these data represent a significant addition to the current literature in that it represents the first pediatric case series documenting the hemodynamic consequences of a transition from either continuous SC/IV or intermittent inhaled prostacyclin therapy to oral selexipag. The actual transitions from parenteral prostacyclins to selexipag were performed safely without adverse effects. In addition, and as a group, changes in clinical parameters and hemodynamics were nonstatistically significant at initial follow-up evaluation. However, the transition failed in 27%, requiring re-initiation of continuous or inhaled prostacyclin therapy, and PVRI increased in several patients. Selexipag use in pediatric PAH represents a significant addition to our therapeutic arsenal, and its use provides a meaningful improvement in quality-of-life compared with other prostacyclin formulations. However, emerging data suggest that

aggressive therapy that obtains significant hemodynamic improvement, results in improved outcomes.^{3,22-24} Thus, when goals of care include aggressive disease management, transitions from parenteral prostanoids should not be routinely recommended, and involve a decision between improved quality of life and possible hemodynamic deterioration with adverse outcomes. Importantly, data is emerging that may guide these important transitional decisions.²² For example, in a small number of pediatric patients Douwes et al. demonstrated that discontinuation of parenteral prostanoids is associated with favorable outcomes if the mPAP was ≤ 35 mmHg and/or the PVRI was ≤ 4.4 woods units at the time of discontinuation.²² However, currently, when transitioning is performed, cautious, close, and long-term follow-up to evaluate for rapid and, possibly, gradual worsening in pulmonary vascular disease and/or RV function is warranted.

AUTHOR CONTRIBUTIONS

All authors have made substantial contributions to the conception of the work; revising the work critically for important intellectual content; have approved the final version to be published; and agree to be accountable for all aspects of the work in ensuring that questions related to the accuracy or integrity of any part of the work are appropriately investigated and resolved.

ACKNOWLEDGMENT

No funding supported this report.

CONFLICT OF INTEREST

The authors declare no conflict of interest.

ETHICS STATEMENT

This work was performed under an Institutional IRB approval.

ORCID

Jeffrey R. Fineman  <https://orcid.org/0000-0001-9740-405X>

REFERENCES

1. Abman SH, Ivy DD, Archer SL, Wilson K. Executive summary of the American Heart Association and American Thoracic Society Joint Guidelines for pediatric pulmonary hypertension. *Am J Respir Crit Care Med.* 2016;194(7):898-906.
2. D'Alonzo GE, Barst RJ, Ayres SM, Bergofsky EH, Brundage BH, Detre KM, Fishman AP, Goldring RM, Groves BM, Kernis JT, Levy PS, Pietra GG, Reid LM, Reeves JT, Rich S, Vreim CE, Williams GW, Wu M. Survival in patients with primary pulmonary hypertension. Results from a national prospective registry. *Ann Intern Med.* 1991;115(5):343-9.
3. Haarman MG, Lévy M, Roofthoof MTR, Douwes JM, Vissia-Kazemier TR, Szezepanski I, Berger RMF, Bonnet D. Upfront

- triple combination therapy in severe paediatric pulmonary arterial hypertension. *Eur Respir J.* 2021;57(1):2001120.
4. Siehr SL, Dunbar Ivy D, Miller-Reed K, Ogawa M, Rosenthal DN, Feinstein JA. Children with pulmonary arterial hypertension and prostanoid therapy: long-term hemodynamics. *J Heart Lung Transplant.* 2013;32(5):546–52.
 5. Barst RJ, Rubin LJ, Long WA, McGoon MD, Rich S, Badesch DB, Groves BM, Tapson VF, Bourge RC, Brundage BH, Koerner SK, Langleben D, Keller CA, Murali S, Uretsky BF, Clayton LM, Jöbsis MM, Blackburn SD, Shortino D, Crow JW. A comparison of continuous intravenous epoprostenol (prostacyclin) with conventional therapy for primary pulmonary hypertension. *N Engl J Med.* 1996;334:296–301.
 6. Farhat N, Lador F, Beghetti M. Diagnosis and treatment of pediatric pulmonary arterial hypertension. *Expert Rev Cardiovasc Ther.* 2019;17(3):161–75.
 7. Levy M, Del Cerro MJ, Nadaud S, Vadlamudi K, Colglazier E, Fineman J, Bonnet D, Adatia I. Safety, efficacy and management of subcutaneous treprostinil infusions in the treatment of severe pediatric pulmonary hypertension. *Int J Cardiol.* 2018;264:153–157.
 8. Simonneau G, Barst RJ, Galie N, Naeije R, Rich S, Bourge RC, Keogh A, Oudiz R, Frost A, Blackburn SD, Crow JW, Rubin LJ. Continuous subcutaneous infusion of treprostinil, a prostacyclin analogue, in patients with pulmonary arterial hypertension: a double-blind, randomized, placebo-controlled trial. *Am J Respir Crit Care Med.* 2002;165(6):800–804.
 9. Coghlan JG, Picken C, Clapp LH. Selexipag in the management of pulmonary arterial hypertension: an update. *Drug Healthc Patient Saf.* 2019;11:55–64.
 10. Sitbon O, Channick R, Chin KM, Frey A, Gaine S, Galiè N, Ghofrani HA, Hoeper MM, Lang IM, Preiss R, Rubin LJ, Di Scala L, Tapson V, Adzerikho I, Liu J, Moiseeva O, Zeng X, Simonneau G, McLaughlin VV. Selexipag for the treatment of pulmonary arterial hypertension. *N Engl J Med.* 2015;373:2522–33.
 11. Hansmann G, Meinel K, Bukova M, Chouvarine P, Wählander H, Koestenberger M. Selexipag for the treatment of children with pulmonary arterial hypertension: first multicenter experience in drug safety and efficacy. *J Heart Lung Transplant.* 2020;39:695–706.
 12. Yanaka K, Guillien A, Soumagne T, Benet J, Piliero N, Picard F, Pison C, Sitbon O, Bouvaist H, Degano B. Transition from intravenous epoprostenol to selexipag in pulmonary arterial hypertension: a word of caution. *Eur Respir J.* 2020;55:1902418.
 13. Tamura Y, Furukawa A, Tamura Y, Yamada K, Taniguchi H, Fukuda K, Kawamura A, Satoh T. Long-term safety of a structured transition protocol from parenteral prostanoids to selexipag in pulmonary arterial hypertension. *Pulm Circ.* 2022;12:1–4.
 14. Lafuente-Romero A, Rodriguez Ogando A. Selexipag use for paediatric pulmonary hypertension: a single centre report focussed on congenital heart disease patients. *Cardiol Young.* 2021;31:1513–15.
 15. Aldweib N, Verlinden NJ, Kassis-George H, Raina A. Transition from parenteral prostacyclins to selexipag: safety and feasibility in selected patients. *Pulm Circ.* 2021;11(3):1–5.
 16. Takatsuki S, Nakayama T, Shimizu Y, Kawai R, Matsuura H. Clinical efficacy and safety of selexipag in children and young adults with idiopathic and heritable pulmonary arterial hypertension. *Cardiol Young.* 2022;1–5. Epub 2020 Dec 7. <https://doi.org/10.1017/S1047951122000415>
 17. Frost A, Janmohamed M, Fritz JS, McConnell JW, Poch D, Fortin TA, Miller CE, Chin KM, Fisher M, Eggert M, McEvoy C, Benza RL, Farber HW, Kim NH, Pfister T, Shiraga Y, McLaughlin V. Safety and tolerability of transition from inhaled treprostinil to oral selexipag in pulmonary arterial hypertension: results from the TRANSIT-1 study. *J Heart Lung Transplant.* 2019;38:43–50.
 18. Fanous SM, Janmohamed M. Transition from treprostinil to selexipag in patients with pulmonary arterial hypertension: case series. *Am J Health Syst Pharm.* 2018;75:1877–81.
 19. Holthaus N, Prins K, Rose L, Prisco S, Pritzker M, Thenappan T. EXPRESS: transition from parental prostacyclin to selexipag: a case series of five pulmonary arterial hypertension patients. *Pulm Circ.* 2019;9:2045894019862167.
 20. Lázaro Salvador M, Escribano Subías P, Rodriguez Padial L, Lázaro Salvador M, Escribano Subías P, Rodriguez Padial L. Right heart catheterization further confirms successful transition from parenteral prostanoid to oral selexipag. *Arch Bronconeumol.* 2019;55(7):393–394.
 21. Colglazier E, Ng AJ, Parker C, Nawaytou H, Fineman JR. Safety and tolerability of a rapid transition from intravenous treprostinil to oral selexipag in three adolescent patients with pulmonary arterial hypertension. *J Pediatr Pharmacol Ther.* 2021;26(5):512–516.
 22. Douwes JM, Zijlstra WMH, Rosenzweig EB, Ploegstra MJ, Krishnan US, Haarman MG, Roofthoof MTR, Postmus D, Hillege HL, Ivy DD, Berger RMF. Parenteral prostanoids in pediatric pulmonary arterial hypertension: start early, dose high, combine. *Ann Am Thorac Soc.* 2022;19(2):227–37.
 23. Tella JB, Kulik TJ, McSweeney JE, Sleeper LA, Lu M, Mullen MP. Prostanoids in pediatric pulmonary hypertension: clinical response, time-to-effect, and dose-response. *Pulm Circ.* 2022;10(4):2045894020944858.
 24. Boucly A, Savale L, Jaïs X, Bauer F, Bergot E, Bertoletti L, Beurnier A, Bourdin A, Bouvaist H, Bulifon S, Chabanne C, Chaouat A, Cottin V, Dauphin C, Degano B, De Groote P, Favrolt N, Feng Y, Horeau-Langlard D, Jevnikar M, Jutant EM, Liang Z, Magro P, Mauran P, Mocerri P, Mornex JF, Palat S, Parent F, Picard F, Pichon J, Poubeau P, Prévot G, Renard S, Reynaud-Gaubert M, Riou M, Roblot P, Sanchez O, Seferian A, Tromeur C, Weatherald J, Simonneau G, Montani D, Humbert M, Sitbon O. Association between initial treatment strategy and long-term survival in pulmonary arterial hypertension. *Am J Respir Crit Care Med.* 2021;204(7):842–54.

How to cite this article: Colglazier E, Stevens L, Parker C, Nawaytou HM, Amin EK, Becerra J, Steurer M, Fineman JR. Hemodynamic assessment of transitioning from parenteral prostacyclin to selexipag in pediatric pulmonary hypertension. *Pulm Circ.* 2022;e12159. <https://doi.org/10.1002/pul2.12159>