

UC Irvine

UC Irvine Previously Published Works

Title

Canalplasty for Exostoses With Maximal Skin Preservation With Temporoparietal Fascia Grafting and Use of Bone Wax for Skin Flap Protection: A Retrospective Case Series.

Permalink

<https://escholarship.org/uc/item/9ns1z1q7>

Journal

The Annals of otology, rhinology, and laryngology, 124(12)

ISSN

0003-4894

Authors

Moss, William J
Lin, Harrison W
Cueva, Roberto A

Publication Date


2015-12-01

DOI

10.1177/0003489415595238

Peer reviewed

Canalplasty for Exostoses With Maximal Skin Preservation With Temporoparietal Fascia Grafting and Use of Bone Wax for Skin Flap Protection: A Retrospective Case Series

Annals of Otolaryngology, Rhinology & Laryngology
2015, Vol. 124(12) 978–986
© The Author(s) 2015
Reprints and permissions:
sagepub.com/journalsPermissions.nav
DOI: 10.1177/0003489415595238
aor.sagepub.com


William J. Moss, MD¹, Harrison W. Lin, MD², and Roberto A. Cueva, MD³

Abstract

Background: External auditory canal exostoses are benign, bony overgrowths that arise in patients who experience chronic cold water exposure. While considerable advancement has been made in canalplasty techniques in recent decades, many patients continue to experience prolonged healing periods and recurrent stenosis following surgery.

Objective: To perform a retrospective outcomes analysis of our experience with a skin-preserving canalplasty technique with temporoparietal fascia grafting and use of bone wax for skin flap protection.

Study Design: Retrospective review.

Subjects and Methods: Thirty-four patients (41 ears) underwent canalplasty from 2008 to 2014 at a tertiary referral center. Primary outcome measures included rates of prolonged healing and restenosis, need for revision surgery, and audiometric results. Rates of intraoperative and postoperative complications were also tabulated.

Results: No patient experienced recurrent stenosis or required a revision surgery within the follow-up period. All but one patient (97%) achieved complete healing within 8 weeks. Minimal intraoperative complications were found. Statistically significant improvements in air pure tone averages and air-bone gaps were achieved.

Conclusion: The proposed technique is a safe and effective method of canalplasty for exostoses that imparts accelerated wound healing and minimizes the rate of recurrent stenosis.

Keywords

exostoses, canalplasty, skin preservation

Introduction

External auditory canal exostoses are lamellated, bony growths that arise in patients who habitually participate in cold water or wind activities.¹ Colloquially known as “surfer’s ear,” this disorder is thought to be provoked by evaporative cooling.^{2,3} Not to be confused with external auditory canal osteomas, this disorder is more commonly bilateral and manifests as multiple, broad-based outgrowths. Most patients with this anomaly do not require surgical intervention. However, those with more advanced disease can experience uncomfortable water trapping that may predispose to recurrent and oftentimes severe otitis externa. For those with severe or obliterative disease, conductive hearing loss can result. For these symptomatic patients, a variety of transcanal, endaural, and postauricular canalplasty techniques have been described with increasingly lower rates of intraoperative complications. Postoperatively, however, many of these patients experience prolonged healing,

recurrent stenosis, and, not uncommonly, require revision procedures. In an effort to promote more optimal soft tissue healing, we describe a postauricular canalplasty technique with maximal preservation of the native canal skin, temporoparietal (false) fascia grafting, and use of bone wax for skin flap protection. We present both a detailed description

¹Division of Otolaryngology—Head and Neck Surgery, University of California, San Diego, California, USA

²Department of Otolaryngology—Head and Neck Surgery, University of California, Irvine, California, USA

³Department of Otolaryngology—Head and Neck Surgery, Southern California Permanente Medical Group, San Diego, California, USA

Corresponding Author:

Roberto A. Cueva, Department of Otolaryngology—Head and Neck Surgery, Southern California Permanente Medical Group, 5893 Copley Drive, San Diego, CA 92111, USA.
Email: Roberto.A.Cueva@kp.org

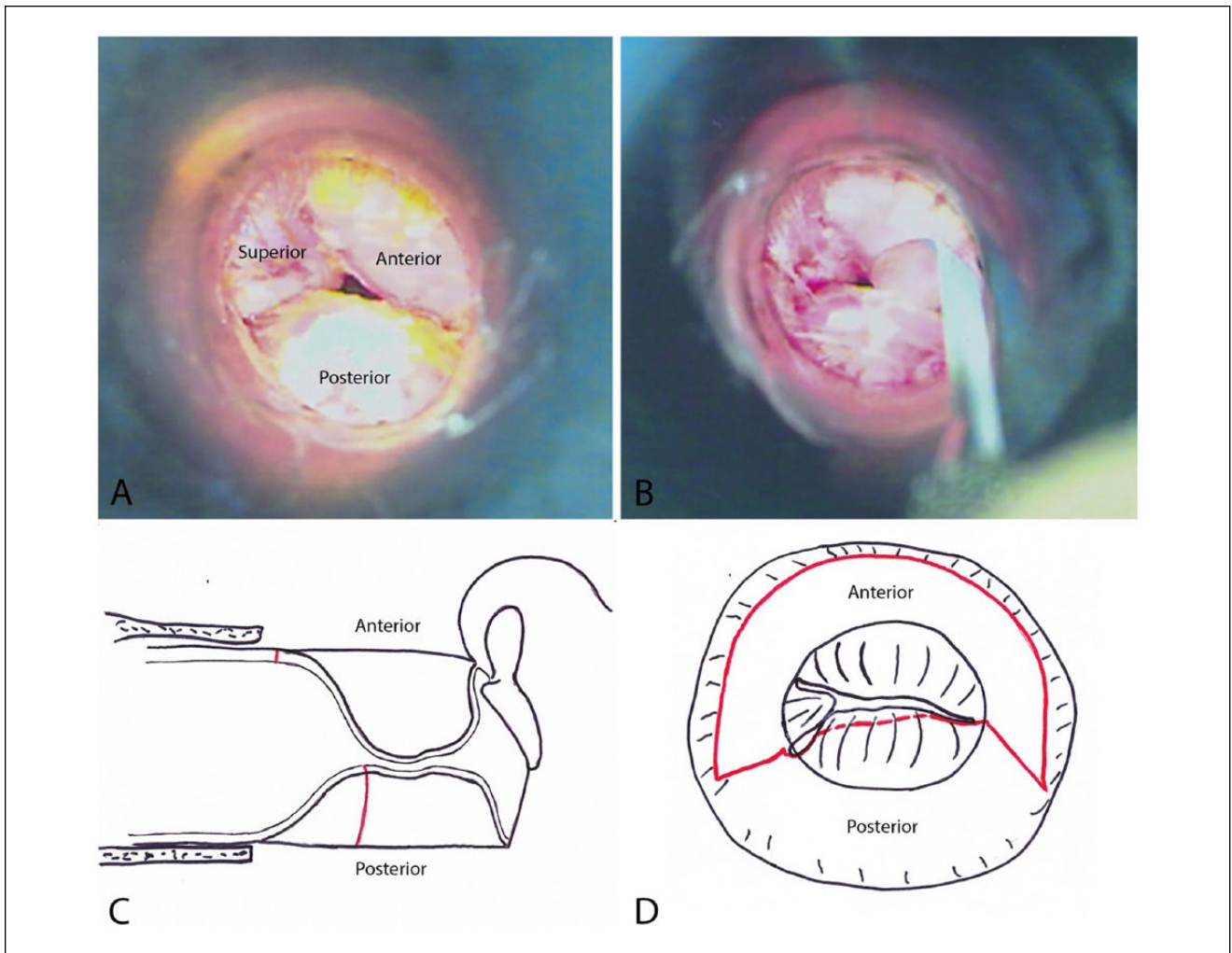


Figure 1. Transcanal view and canal incisions.

(A) Transcanal view of a case of severe exostoses in the right ear, with typical superior, anterior, and posterior exostoses. (B) A beaver blade is used to make a transcanal incision over the posterior exostosis as far medially as possible. (C) Drawing of a sagittal view of the ear canal and middle ear, demonstrating the staggered placement of the anterior and posterior canal skin incisions. (D) Drawing of a transcanal view of the anterior (red solid line) and posterior (red dotted line) canal skin incisions.

of the surgical technique with images as well as retrospective outcomes data.

Materials and Methods

Surgical Technique

Under general anesthesia and standard sterile preparations, the ear canal is inspected under the operating microscope (Figure 1A). After local injection, a 72-Beaver blade is used to make an incision as far medial as possible along the posterior exostosis from the 6-o'clock position in the floor of the canal up to the tympanosquamous suture line (Figure 1B-D). A 57-Beaver blade is then used to make radial incisions from medial to lateral along the tympanosquamous

suture line and floor of the canal. The flap is slightly back elevated. Next, the postauricular incision is made, the plane of the temporoparietal fascia is identified, and a 3 × 3 cm piece is harvested and set on a block to dry. A T-shaped periosteal incision is made and periosteal flaps are elevated posteriorly, superiorly, and anteriorly. The spine of Henle and ear canal are identified anteriorly. Under the microscope, the skin flap can be elevated out of the posterior ear canal. The ear canal flap and ear are held forward with a Weitlaner retractor (Figure 2). Drilling is then commenced with a 4-cutting burr under constant suction irrigation, taking care to visualize the level of the native ear canal. Drilling proceeds from lateral to medial, starting at the spine of Henle. The drilling is continued with sequentially smaller burrs converting to diamond burrs for more medial work.

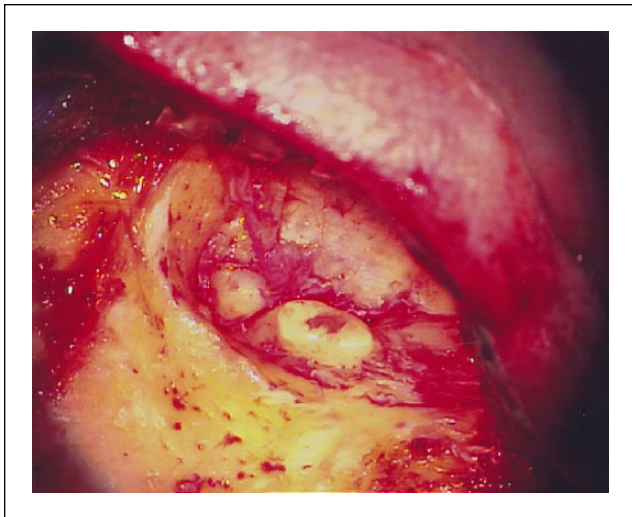


Figure 2. A postauricular incision is made and the auricle and posterior canal skin flap is elevated and retracted anteriorly, exposing the posterior and superior exostoses. Note that the anterior canal wall skin is still in place.

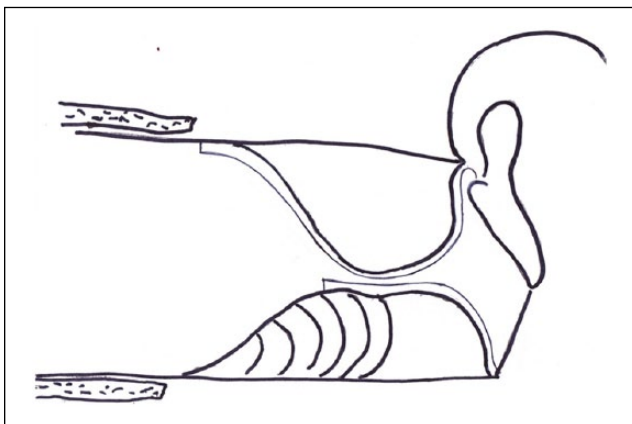


Figure 3. Drawing demonstrating the drilling technique used to remove the exostoses.

Beginning laterally at the spine of Henle, the exostosis is drilled away in the plane of the native canal. The skin edge is undercut, leaving a thin layer of bone to protect the medially based skin flap. The thin chip of bone can then be carefully dissected free from the skin using a sickle knife.

Care is taken to avoid drilling on the skin of the medial side of the exostosis by exclusively drilling peripherally along the axis of the ear canal, rather than centrally (Figure 3). A sickle knife (or Rosen needle, joint knife, or stapes curette) is used to carefully elevate the remnant, eggshell-thin bone of the exostosis off the medial canal skin. Both the posterior and superior exostoses are drilled down to the level of the native canal in this fashion (Figure 4A). Replacement of the posterior and superior medially based skin flaps onto the canal wall allows for identification and visualization of the tympanic membrane (Figure 4B).

Next, an incision in the anterior ear canal through skin and a small amount of cartilage at the level of the bony and cartilaginous junction is made with a 57-Beaver blade. A Lancet knife is used to elevate this medially based skin flap, which is then placed onto the posterior canal wall (Figure 4C). A long strip of bone wax is hand-fashioned to fit into the canal to cover and protect this anterior skin flap while allowing for adequate exposure of and working space to address the anterior exostosis (Figure 4D). The anterior canal is then drilled down in a similar fashion, starting with a 4-cutting burr and sequentially down-sizing down to a 1-diamond burr. Once the anterior canal bone has been adequately removed to provide an unobstructed view of the anterior tympanic sulcus, the eggshell of bone is elevated from the medially based skin flap and removed (Figure 5). Any other area(s) of medial bony overhang is then addressed with a size-appropriate drill or curette.

Next, the bone wax is removed (Figure 6A) and the medially based anterior skin flap is replaced into its native position. It is then sutured anteriorly to the lateral canal skin and cartilage with 3 interrupted 5-0 chromic sutures (Figure 6B). The pressed and dried temporoparietal fascia is then cut into 2 triangular pieces (Figure 7A) and each is used to line the defects in skin coverage along the superior and inferior ear canal (Figures 7B and 8A). Small relaxing incisions can be made in the medial canal skin to allow for the skin flaps to lay flat. Once all flaps are in good position (Figure 8B), the medial canal is filled with bacitracin ointment. The laterally based posterior canal wall skin flap is then brought back into the ear canal. The mastoid periosteum and deep subcutaneous layer of the postauricular wound are then closed with simple interrupted 3-0 Vicryl sutures. The ear canal is then visualized under the operating microscope and the posterior canal wall skin flap is carefully positioned atop of the fascial grafts. The remainder of the ear canal is then filled with bacitracin ointment, and the postauricular incision is dressed with bacitracin ointment, Telfa, and plastic cup dressings. The patient is discharged home on the same day.

Data Collection

A retrospective chart review was undertaken for all patients who underwent canalplasty from 2008 to 2014 with the senior author (RAC) at a tertiary referral center in San Diego, California. Primary indications for this procedure were water trapping, recurrent otitis externa, and conductive hearing loss. No exclusions were made based on age, sex, severity of exostoses, or history of prior canalplasty. Basic demographic data as well as preoperative and postoperative audiologic data were collected for each patient. The audiologic data collected comprised the air PTA (pure tone average), SRT (speech reception threshold), and ABG (air-bone gap) and were recorded in dB (decibels). PTAs and

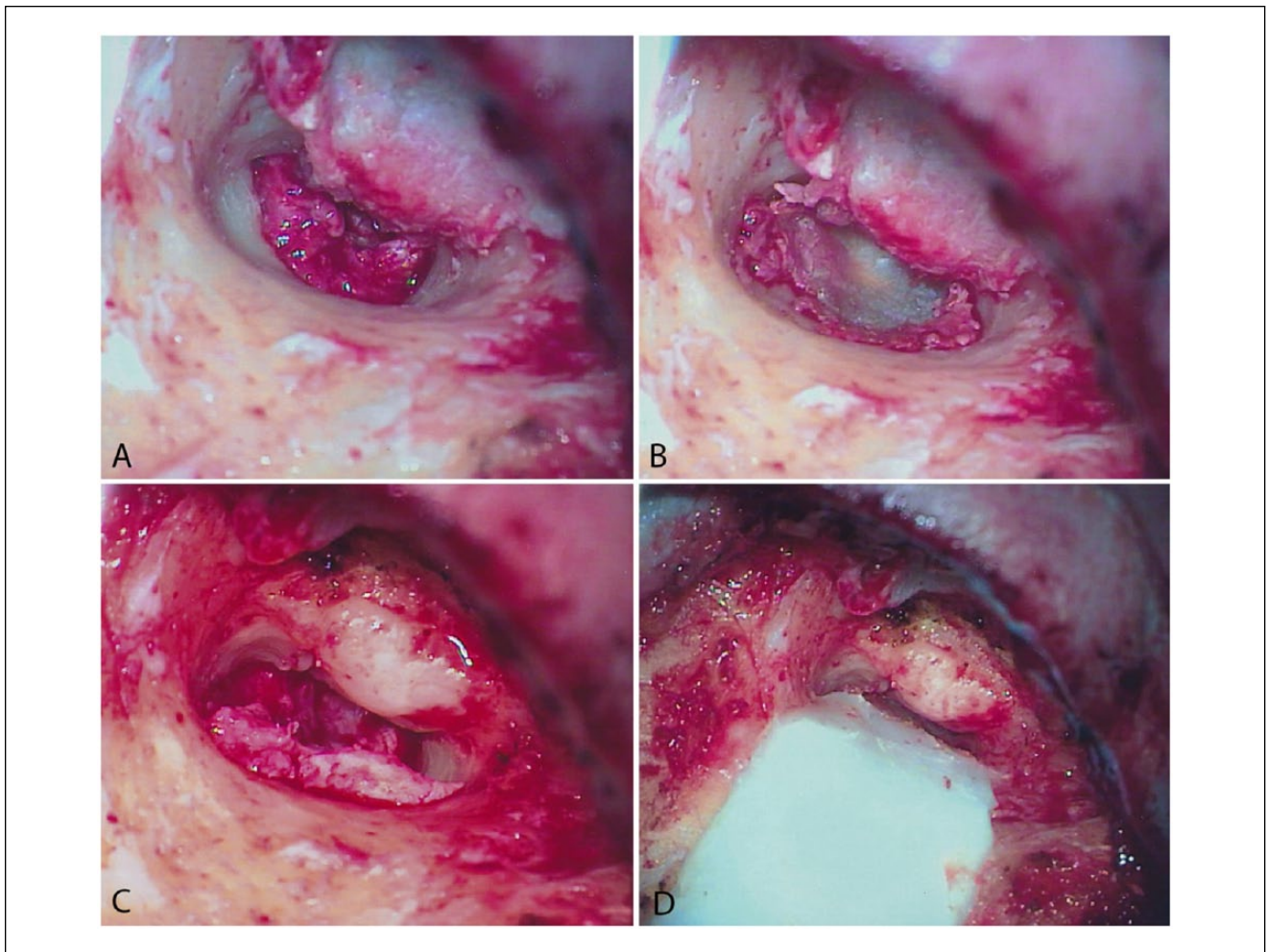


Figure 4. Canal skin preservation.

(A) The posterior and superior exostoses are removed. The posterior medially based skin flap, tucked medially over the tympanic membrane, is preserved. (B) The posterior medial skin flap is placed onto the posterior wall of the ear canal, revealing the tympanic membrane. (C) The anterior canal skin incision is made laterally and through skin and cartilage, and the medially based anterior skin flap is elevated to expose the anterior exostosis. (D) Bone wax is molded into a thin strip used to cover and protect the anterior canal wall skin flap and pressed onto the posterior wall of the canal.

ABGs were calculated as an average of 0.5, 1, 2, and 3 kHz. Preoperative and postoperative audiologic metrics were compiled, averaged, and compared. Exclusions were made if both preoperative and postoperative data were not available. Exostoses severity was assessed intraoperatively via a standardized severity score and tabulated. Intraoperative and postoperative complications were compiled. Intraoperative complications included tympanic membrane (TM) perforation, facial nerve injury, temporomandibular joint (TMJ) injury, and inadvertent entry into the mastoid air cells. Postoperative complications included sensorineural hearing loss (SNHL), facial weakness, wound infection, prolonged healing, and restenosis. SNHL was defined as a 15-dB loss (worsening) in hearing at any one or more frequencies. Prolonged healing was defined as an external auditory canal not completely healed by 8 weeks postoperatively. Last,

canal stenosis was defined as a chronic, persistent meatal narrowing or scar of any severity.

Ethical Considerations

This retrospective review was approved by the Southern California Permanente Medical Group Institutional Review Board (IRB #10384).

Statistical Analysis

Data entry and statistical analysis was completed with Microsoft Excel (Microsoft Corporation, Redmond, VA, USA). Continuous variables were compared with a 2-tailed, Student's *t* test, and *P* values of less than or equal to .05 were considered to be statistically significant.

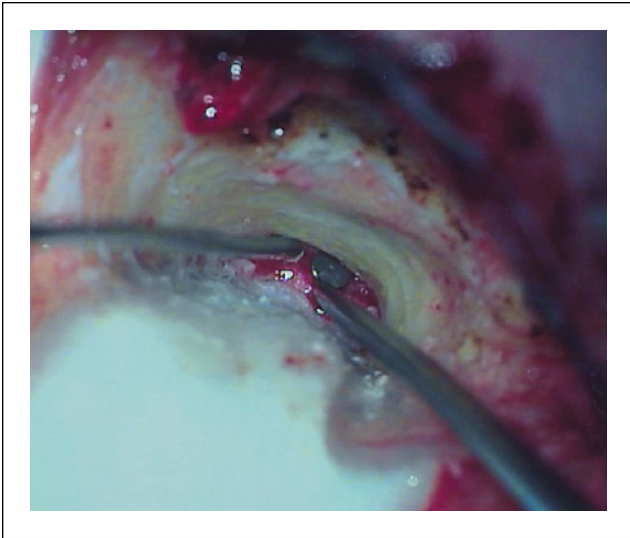


Figure 5. As drilling proceeds medially toward the tympanic membrane, the skin flap is gently elevated from the underlying exostosis with a round knife. Note the excellent exposure and visualization of the anterior canal wall, allowing for minimal temporomandibular joint exposure risk.

Results

A total of 34 patients were included in the clinical review, and their demographic data are shown in Table 1. All patients were male surfers, average age 49.7 years (range 26-65 years). Seven of the 34 patients had bilateral, staged canalplasties, thus giving data for a total of 41 operated ears. Of these 41 cases, 25 were performed on right ears and 16 on left ears. Thirty-five of these cases were primary canalplasties and 6 were revisions in patients previously operated on by other surgeons. Table 2 shows the exostoses severity of the 41 operated ears. Thirty-nine of the 41 ears were rated as severe (>66% EAC obstruction) with 37 of these 39 having greater than 90% obstruction.

Audiologic Results

The preoperative and postoperative audiologic data are shown in Table 3. Statistically significant improvements were achieved for both the air PTA and ABG ($P = .05$ and $.04$, respectively). A nonsignificant trend for an improved SRT was found ($P = .06$). Of note, 2 patients had persistent ABGs of 40 and 30 dB following surgery and were recommended to undergo middle ear exploration. One of these patients proceeded with this recommendation, ultimately underwent stapedectomy, and experienced full closure of the ABG. The second patient declined further intervention. Three patients experienced a SNHL postoperatively. Each instance involved frequencies only above 3 kHz and ranged from 15 to 20 dB.

Intraoperative Complications

Intraoperative complications were minimal (Table 4). One patient experienced a 1-mm TM perforation. Another patient's case was complicated by inadvertent entry into the mastoid air cells. Both of these injuries healed spontaneously and without sequelae prior to the first follow-up visit at 3 weeks.

Postoperative Complications

Of the 41 cases, one patient was lost to follow-up, yielding postoperative data for 40 operated ears (Table 4). Average follow-up was 35 weeks and ranged from a minimum of 3 weeks to a maximum of 270 weeks. The most common postoperative complication was EAC edema, which occurred in 6 patients (15%). In each case, this swelling was addressed with otowick placement and antibiotic-steroid drops to prevent chronic stenosis. Wound infection was the second most common complication and occurred in 5 patients (13%). These infections included otitis externa as well as cellulitis at the postauricular incision. Each case was mild and was resolved with a course of oral or topical antibiotics. Three patients (8%) had a postoperative seroma at the postauricular incision, and each of these was successfully relieved with an in-office needle aspiration. Prolonged healing (defined as a lack of a completely epithelialized external auditory canal at 8 weeks postoperatively) occurred in only one patient. This patient had moderate canal edema and a small area of granulation that were fully resolved at 9 weeks. No patient experienced postoperative exposed bone, chronic canal stenosis, or required revision surgery of any kind within the follow-up period.

Discussion

This case series features a predominance of middle-aged, male surfers, similar to several other prior series. Also similar to other recent postauricular canalplasty series, we have shown an acceptably low rate of intraoperative complications (5% overall).³⁻⁵ We attribute this in large part to the improved visualization of critical structures with this approach. With severe or obliterative exostoses, we believe that the transcanal technique can be more challenging in this regard.

We find that our audiometric data compares favorably with that of recent series.³⁻⁶ Statistically significant improvements in the PTA and ABG were demonstrated as well as a nonsignificant trend for improved SRT ($P = .06$). SNHL occurred at a rate of 8% and is attributed to noise and vibration injury from the drilling process. Each instance involved the higher frequencies (above 3 kHz) and had minimal clinical impact on the patients.

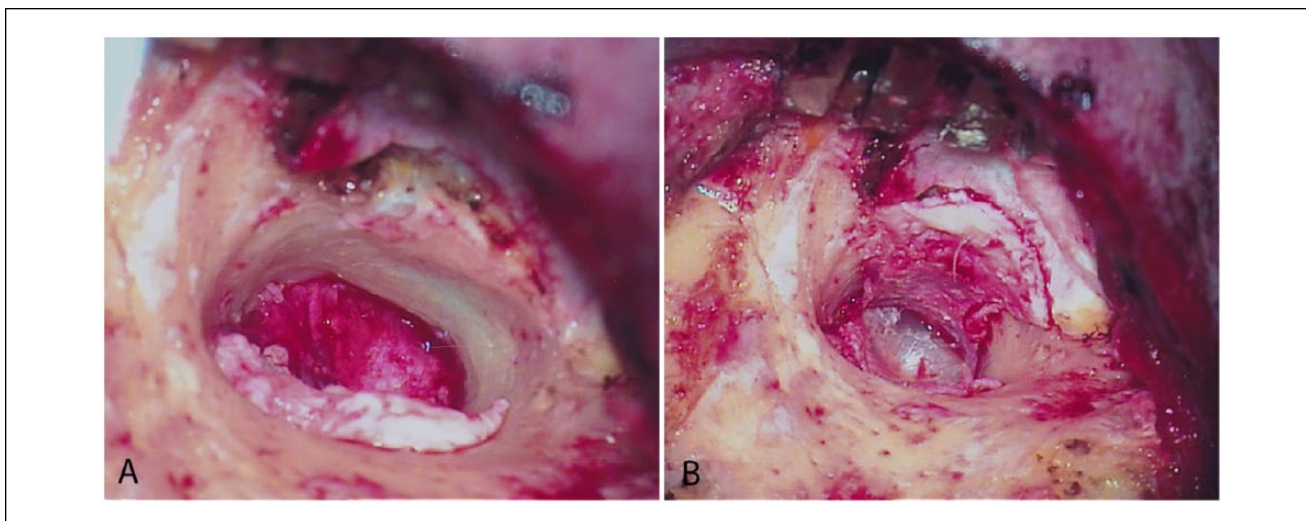


Figure 6. (A) The anterior canal wall exostosis has been removed, along with the bone wax protecting the anterior canal wall skin flap. (B) The anterior canal wall skin flap has been replaced onto the anterior canal wall and secured to the lateral canal skin with chromic sutures, providing a full view of the tympanic membrane. Note the resulting canal bone exposure superiorly and inferiorly.

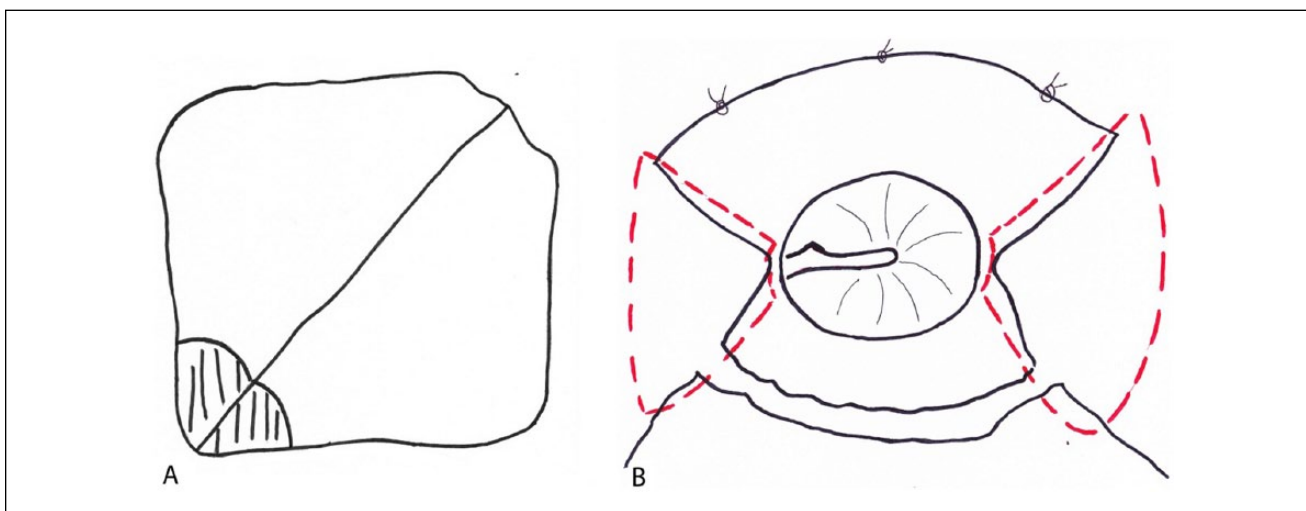


Figure 7. Temporoparietal fascia cutting and placement.

(A) The harvested, pressed, and dried temporoparietal fascia is cut into 2 triangular pieces, with one corner removed with a curvilinear cut to accommodate the tympanic ring. (B) The 2 pieces of fascia (red dotted lines) are placed to cover the exposed bone superiorly and inferiorly in an underlay fashion relative to the anterior and posterior skin flaps. Anteriorly, the skin flap is sutured to the lateral skin using interrupted 5-0 fast-absorbing chromic sutures.

We believe the greatest benefit of our technique to be accelerated wound healing and the avoidance of recurrent canal stenosis (Figure 9). The external canals of exostoses patients are commonly chronically infected and are thus predisposed to postoperative healing difficulties. As such, minimizing trauma to the native external canal skin during surgery and preserving its integrity and vasculature are of the utmost importance. Most experienced canalplasty surgeons are likely familiar with the excess granulation and

subsequent scarring that can develop in the postoperative period. Often these are the consequences of exposed bone and excessively traumatized canal skin. By using bone wax to protect and secure the anterior canal skin flap, we have found it easier to eliminate soft tissue trauma during the drilling process. This allows for maximal preservation of the native canal skin, which is essential to achieve sufficient coverage of the bony canal. A variety of materials have been used to protect the anterior canal flap during the drilling of

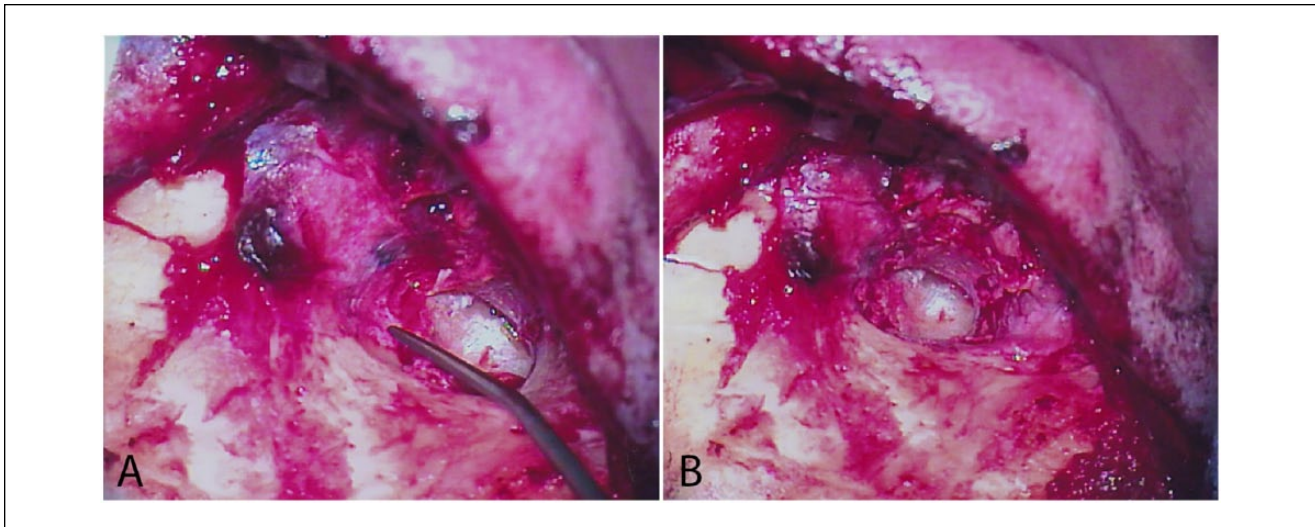


Figure 8. (A) The cut piece of fascia is placed superiorly to cover the area of exposed bone. (B) Following the placement of the fascia to cover the area of exposed bone inferiorly, the medial ear canal can be filled with antibiotic ointment, and closure can begin.

Table 1. Demographic Data.

Number of patients: 34
Male vs female: 34 vs 0 (100% vs 0%)
Surfer vs nonsurfer: 34 vs 0 (100% vs 0%)
Average age: 49.7 years (range = 26-65)
Number of ears operated: 41
Right vs left ear: 25 vs 16 (61% vs 39%)
Primary vs revision surgery: 35 vs 6 (85% vs 15%)

Table 2. Exostoses Severity (No. = 41).

Grade	Percentage Obstructed	No. (%)
0 (normal)	0	0 (0)
1 (minimal)	<33	0 (0)
2 (moderate)	33-66	2 (5)
3 (severe)	>66	39 (95) ^a

^aOf the 39 ears graded as severe, 37 had obstruction of greater than 90%.

exostoses, including foil from suture packs and silastic.^{4,7-9} We have found that these relatively bulkier and more rigid materials can impart an obstructed view of the operative field and are frequently displaced with contact from the burr, which may result in additional trauma to the skin flaps. Burr contact with the bone wax does not cause this displacement.

After the drilling is completed and the canal flaps are laid into position, relaxing incisions are made to allow the skin to lie flat onto the medial canal bone. The anterior canal skin flap is sutured to the lateral skin to achieve more

secure coverage of the underlying bone. In nearly all cases, there will be coverage defects superiorly and inferiorly, and many surgeons would elect to use split thickness skin grafts in these situations.^{4,9} Our use of temporoparietal fascia grafting in these instances provides comparable soft tissue coverage while avoiding potential morbidity at the skin graft harvest site, and is believed to facilitate the regrowth of native ear canal skin. This preserves the pattern of natural, lateral migration of the external auditory canal skin from the umbo outward.¹⁰ Grafted skin does not have this migratory property and would thus impede the cycling of ear canal skin, promote the accumulation of skin and cerumen, and potentially lead to obstruction and infection. With these measures, we have been able to achieve a completely healed external canal at a faster rate than other series.^{4,8} Additionally, we have been able to avoid restenosis and the need for revision surgery of any kind in all cases within our follow-up period. Rates of restenosis have been quoted as high as 10% in recent series.⁵ Subsequent interventions for this complication are not infrequent and our 0% rate of revision surgery compares favorably with other series in this regard.^{3,4,6,7} A technique that may assist with prevention of restenosis is our use of otowicks with topical antibiotic-steroid drop therapy in patients with postoperative canal swelling (occurred in 15% of patients). Additionally, all patients are strongly admonished to wear ear plugs when surfing to reduce the amount of cold water entering the ear canal to prevent recurrence of the exostoses.

A recent series from Hetzler¹¹ from 2007 has similarly shown very impressive rates of healing following canalplasty for exostoses. In this retrospective series of 221 ears, an average healing time of 3.5 weeks was achieved. Of note, this study implemented a transcanal approach that

Table 3. Audiologic Data (dB)^a.

Audiologic Metric	Preoperative Mean (SD)	Postoperative Mean (SD)	Change (SD)	P Value ^b
PTA (no. = 30) ^c	22.81 (18.63)	17.21 (15.28)	-5.61 (15.10)	.05
SRT (no. = 27)	23.52 (18.39)	17.63 (15.95)	-5.89 (15.63)	.06
ABG (no. = 28) ^d	7.92 (13.96)	3.27 (9.26)	-4.67 (11.46)	.04

Abbreviations: PTA, air pure tone average; SRT, speech reception threshold; ABG, air-bone gap; SD, standard deviation.

^aThe variations in "no." between audiologic metrics are due to exclusion of ears without both preoperative and postoperative measurements of a given metric.

^bCalculated with type I Student's *t* test, paired, 2-tailed.

^cPTA taken as an average of 0.5, 1, 2, and 3 kHz thresholds.

^dABG taken as an average of 0.5, 1, 2, and 3 kHz gaps.

Table 4. Complications.

Intraoperative complications (no. = 41)	
Facial nerve injury	0 (0%)
TM perforation	1 (2%)
TMJ injury	0 (0%)
Mastoid air cell entry	1 (2%)
Postoperative complications (no. = 40) ^a	
SNHL ^b	3 (8%)
Facial paralysis	0 (0%)
TM lateralization	0 (0%)
Chronic myringitis	0 (0%)
Wound infection	5 (13%)
Hematoma/seroma	3 (8%)
Canal swelling ^c	6 (15%)
Prolonged healing ^d	1 (3%)
Exposed bone	0 (0%)
Canal stenosis ^e	0 (0%)
Revision surgery required	0 (0%)

Abbreviations: TM, tympanic membrane; TMJ, temporomandibular joint; SNHL, sensorineural hearing loss.

^aOne patient failed to have an in-person follow-up and was excluded; mean follow-up time was 35 weeks, minimum 3, maximum 270, standard deviation 52.

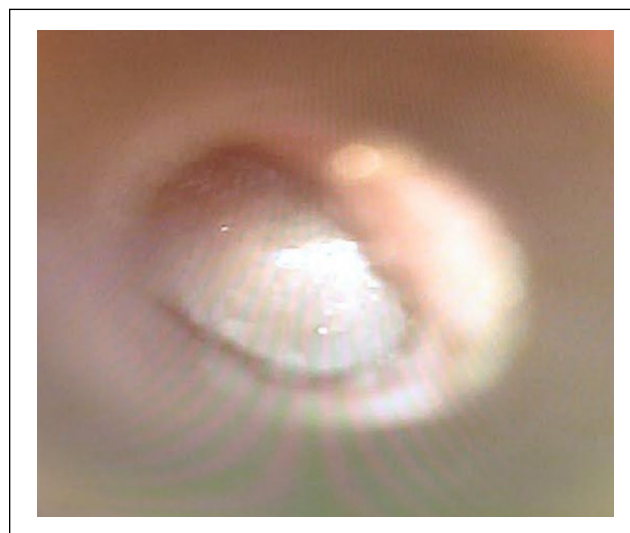
^bSNHL defined as a 15-dB loss for any one frequency; all 3 patients had SNHL above 3 kHz.

^cDefined as canal edema requiring otowick placement.

^dDefined as wound problems such as infection, granulation, or adhesions not resolved by 8 weeks postoperatively.

^eDefined as a chronic, unresolving meatal stenosis or scar of any severity.

afforded less soft tissue manipulation overall in comparison to postauricular approaches. As stated previously, however, many authors feel that the transcanal approach can be more hazardous due to obscured landmarks, as evidenced by a rate of tympanic membrane injury of 13.6% in their review. A more recent study from Barrett and colleagues¹² in 2015 reported a rate of tympanic membrane injury of 5.4% with an endaural approach. Although a significant improvement relative to the Hetzler series, this rate is much higher in comparison to that achieved with a postauricular approach.^{3,4}

**Figure 9.** In-office view of the postoperative results at 3 weeks.

Perhaps the most salient complications of our series are the rates of infection and seroma of 13% and 8%, respectively. While these rates relatively high compared with many other otologic procedures, each instance was mild and responded to minimal intervention. We attribute this in part to the oftentimes diseased and chronically infected external canal skin that is found in exostoses patients. Other series have quoted similar and even higher rates of infection.^{5,12} Other drawbacks of our study include the limitations inherent in any retrospective study as well as the relatively small sample size in comparison with other recent case series.

Conclusion

We have described a postauricular canalplasty technique using bone wax to protect the canal skin that allows for maximal epithelial preservation during the drilling process. Our use of temporoparietal fascia grafting obviates the need for split thickness skin grafting and is believed to promote healing and preserve the natural behavior of the external canal skin. This technique is safe to perform and has low

rates of intraoperative complications. Postoperatively, patients benefit from accelerated wound healing and a low incidence of restenosis.

Declaration of Conflicting Interests

The author(s) declared no potential conflicts of interest with respect to the research, authorship, and/or publication of this article.

Funding

The author(s) received no financial support for the research, authorship, and/or publication of this article.

References

1. Sheehy J. Osteoma of the external auditory canal. *Laryngoscope*. 1958;68:1667-1673.
2. Seftel D. Ear canal hyperostosis—surfer's ear. *Arch Otolaryngol*. 1977;103:58-60.
3. King JF, Kinney AC, Iacobellis SF 2nd, et al. Laterality of exostosis in surfers due to evaporative cooling effect. *Otol Neurotol*. 2010;31:345-351.
4. House J, Wilkinson E. External auditory exostoses: evaluation and treatment. *Otolaryngol Head Neck Surg*. 2008;138:672-678.
5. Van Spronsen E, Ebbens FA, Mirck PG, van Wettum CH, van der Baan S. Canalplasty: the technique and the analysis of its results. *Am J Otolaryngol*. 2013;34:439-444.
6. Vasama J. Surgery for external auditory canal exostoses: a report of 182 operations. *ORL J Otorhinolaryngol Relat Spec*. 2003;65:189-192.
7. Sanna M, Russo A, Khrais T, Jain Y, Augurio AM. Canalplasty for severe external auditory meatus exostoses. *J Laryngol Otol*. 2004;118:607-611.
8. Lavy J, Fagan P. Canalplasty: review of 100 cases. *J Laryngol Otol*. 2001;115:270-273.
9. Myers EN, ed. *Operative Otolaryngology Head and Neck Surgery*. 2nd ed. Philadelphia, PA: Saunders Elsevier; 2008.
10. Alberti P. Epithelial migration on the tympanic membrane. *J Laryngol Otol*. 1964;78:808-830.
11. Hetzler D. Osteotome technique for removal of symptomatic ear canal exostoses. *Laryngoscope*. 2007;117:1-14.
12. Barrett G, Ronan N, Cowan E, Flanagan P. To drill or to chisel? A long-term follow-up study of 92 exostectomy procedures in the UK. *Laryngoscope*. 2015;125:453-456.