

UC Irvine

UC Irvine Previously Published Works

Title

Digital fluorescent imaging System for quantitative analysis of facial sebum production

Permalink

<https://escholarship.org/uc/item/9pd822hb>

Journal

Progress in Biomedical Optics and Imaging - Proceedings of SPIE, 6424

ISSN

1605-7422

ISBN

9780819465375

Authors

Han, B
Jung, B
Choi, EH
et al.

Publication Date

2007-08-31

DOI

10.1117/12.699787

License

<https://creativecommons.org/licenses/by/4.0/> 4.0

Peer reviewed

Digital fluorescent imaging System for quantitative analysis of facial sebum production

Byungkwan Han¹, Byungjo Jung^{1,2*}, Eung-Ho Choi³, and J. Stuart Nelson⁴

¹Department of Biomedical Engineering, Yonsei University, Wonju, Korea

²Institute of Medical Engineering Yonsei University, Wonju, Korea

³Department of Dermatology, Yonsei University Wonju College of Medicine, Korea

⁴Beckman Laser Institute, University of California, Irvine, CA 92612

ABSTRACT

Current methods for analysis of sebum excretion have limitations, such as irreproducible results in repeatable measurements due to the point measurement method, user-dependent artifact due to contact measurement or qualitative evaluation of the image, and long measurement time. A UV-induced fluorescent digital imaging system was developed to acquire facial images so that the distribution of sebum excretion on the face could be analyzed. The imaging system consisted of a constant UV-A light source, digital color camera, and head-positioning device. We describe the system characterization for acquisition of a fluorescent facial image and the image analysis method. The imaging modality provided uniform light distribution on the facial mannequin model and presented a discernible color fluorescent image. Valuable parameters of sebum excretion were obtained after image analysis. The imaging system, which provides a non-contact method, was proven to be a useful tool to evaluate sebum excretion and to characterize the pattern of sebum excretion. When compared to conventional “Wood’s lamp” and “Sebutape” methods that provide similar parameters for sebum excretion, the method described herein is simpler and more reliable to evaluate the dynamics of sebum excretion in nearly real-time.

Keywords: fluorescent facial image; UV-A; digital imaging; sebum

1. INTRODUCTION

Sebum secreted from sebaceous glands is an oily substance predominantly containing squalene, wax esters, and triglycerides, as well as a small amount of cholesterol esters, and possibly some free cholesterol.¹ The variation of such biological components causes skin disorders related to sebum.² Therefore, the measurement of sebum excretion is important for investigation of the pathophysiology of skin disorders (e.g., acne and some hormonal disorders) and their response to therapy.¹⁻⁴

The amount of sebum excretions varies individually depending on age,¹ skin type (normal, dry, or oily skin),^{5,6} and anatomical site (forehead, nose, cheek, or chin) of skin.^{5,6} In the infundibulum, sebum is contaminated with bacterial hydrolases which convert some of the triglycerides to free fatty acid on the skin surface.^{1,4} A remarkable source of fluorescence in facial area is porphyrins produced by bacteria observed within skin pores.⁷

The earliest collection technique of sebum excretion is a funnel method using neutral solvent to extract lipid, in which the collected sebum was evaluated by gravimetry or high-performance thin-layer chromatography and densitometry.^{4,9} Later, the “Sebutape” method using a lipid-absorbing polymeric film was developed to overcome the cumbersome experimental procedures for collection and evaluation of sebum excretion. The “Sebutape” image was analyzed with computer-aided image analysis methods to acquire useful sebum information, such as patterns of follicular sebum excretion, percentage of area covered by sebum spots, density of spots, their maximum area and mean area.^{4,10} Most recently, the “Sebumeter,” which utilizes a photometric technique, was introduced for sebum excretion measurement by providing the amount of sebum ($\mu\text{g}/\text{cm}^2$) within a fast sampling period (~30 seconds).⁴ It uses a matted plastic film (64 mm²) for lipid sampling and measure the increase transparency of a rough film surface after application of lipids. The transparency of the plastic film is measured by a photometric method. The degree of transparency of the film is expressed on a scale from 0 through 500. The transparency is finally transformed into the amount of sebum.⁴

The described methods provide regional information on sebum excretion or use off-line analysis methods. Therefore, they are of limited use to determine sebum distribution in real-time. The Wood's lamp method, invented in 1903, is an invaluable tool because some biological molecules composed of sebum can be easily detected in broader skin area.⁷ The method uses UV-A (wavelength: 320-380 nm) light to induce skin fluorescence in the visible spectral range. Until now, it has been used just for qualitative evaluation of skin condition by taking images or observing skin fluorescence with the naked eye.^{7,11} Therefore, the evaluation of a skin disease/disorder was fairly subjective.

For clinical applications, the current methods have still limitations, such as unpredictable results in repeatable measurements due to the point measurement method, user-dependent error due to contact measurement or qualitative evaluation of the image, and long measurement time.⁴ In this study, we propose an imaging modality for analysis of facial sebum distribution. A UV-induced fluorescent digital imaging system was developed for real-time image acquisition and analysis of facial sebum distribution. The imaging system overcomes several of the aforementioned limitations and artifacts of current methods. The imaging system easily acquires a facial fluorescent image. Various image analysis methods are applied to the fluorescent facial image in order to obtain sebum-related parameters (pattern of follicular sebum excretion, percent of area covered by sebum spots, mean area and diameter of the sebum spots, and the number of sebum spots), which are useful for the evaluation of a skin disease/disorder.

2. MATERIALS AND METHODS

2.1 Digital fluorescent imaging system

Figure 1 shows the developed imaging system. Four UV-A lamps, which are also called "Wood's Lamp" or "black light," were employed as light sources to induce facial skin fluorescence. A digital color camera was centered between the lamps to provide uniform light distribution on the face. The facial fluorescent image was acquired with a digital color camera (Coolpix 8400, Nikon, Tokyo, Japan) operated in manual mode. To ensure optimal facial fluorescent image acquisition, a custom-built head-positioning device was centered between the four UV-A lamps and placed within the working distance (21.6 cm) of the UV-A lamps, resulting in uniform light distribution on the subject's face. The entire system was integrated into an imaging box surrounded by a black curtain to provide a dark environment.




Fig. 1. UV-A induced facial fluorescent imaging system consisting of a color digital camera, four UV-A lamps, and head-positioning device which are integrated into an imaging box.

2.2 Light Distribution Test

The spectrum of the UV-A lamp was measured with an optical spectrometer (Triax 550, Horiba, New Jersey, USA) in order to verify the spectral range and safety of the light source. Human facial skin was modeled using a mannequin

model, in which fluorescent patches were placed on the mannequin face [Fig. 4(a)]. The light distribution was determined by computing the coefficient of variation (CV) of fluorescent patches in the T-zone (forehead, nose, and chin) and U-zone (both cheeks).³ The CV was calculated as follows:

$$CV(\%) = [\sigma/\mu] \times 100 \quad (1)$$

where μ and σ are the mean and standard deviation of the selected fluorescent patches, respectively. A lower CV indicates better uniform light distribution on the face.

2.3 Acquisition of Fluorescent Facial Image

A UV-A induced fluorescent image was acquired from a subject. The subject's head was placed on the head-positioning device and the view angle¹² set to 0° with respect to the camera optical axis in order to obtain front facial image. A reference fluorescent patch ($1 \times 1 \text{ cm}^2$) was placed onto the subject's forehead for area calibration in image analysis. The number of pixels (104×104) of the reference fluorescent patch was used for area calibration in image analysis. The power of UV-A light source was experimentally measured with a UV solarmeter (Model 5.0, Mat Science Tech Co., Ltd., Seoul, Korea) and determined to be 0.6 mW/cm^2 in facial area.

2.4 Image Analysis

The forehead, cheek, and chin area have relatively planar surface when imaged at the view angle of 0° . However, the nose area has curvature surface causing non-uniform illumination. Therefore, the nose area may cause errors in image analysis depending on the sebum parameters (for example, sebum pattern, density) analyzed. Herein, the curvature effect in nose area was not considered because such issue can be further minimized by using optimal view angle for the area of interest.¹² Therefore, the image analysis was performed without considering the optimal view angle in the selected area.

Clinically important parameters related to sebum excretion were computed with the image processing procedure illustrated in Fig. 2. Sebum spots are detected with a threshold based on a 255 gray levels scale. Finally, various image analysis methods were applied to the processed image to extract sebum parameters. The parameters include the following values^{3,7,13}: percent area covered by the sebum spot indicating total sebum output; number of sebum spots indicating secreting sebaceous follicles; patterns of follicular sebum excretion taking into account the number and shape of the sebum spots; and size distribution of spots indicating differences in secretion activity between follicles. Such parameters were automatically computed with laboratory built "MathLab" codes. Even though the image analysis methods are not described in detail herein, they will be provided in a future study.

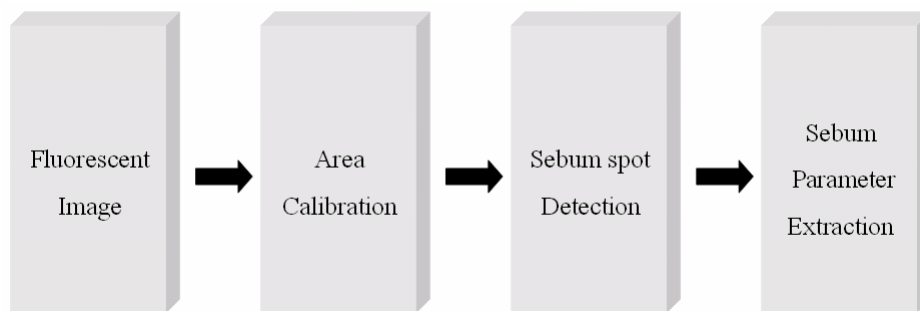


Fig. 2. Schematic diagram of image analysis procedure. The area calibration of the fluorescent image is first performed and sebum spots are basically detected with edge detection algorithm.

3. RESULTS

3.1 Light Distribution Test

Figure 3 shows the measured spectrum (320-380 nm) of the UV-A lamp used as a light source. It is well known that this spectral range is safe for human skin application. Using the selected camera parameters and light source, the uniformity of the light distribution was investigated by analyzing the intensity distribution of fluorescent patches placed on the mannequin's face. Figures 4 (a) and (b) show the white light and fluorescent images, respectively, of fluorescent patches placed on the mannequin's face. The camera setting for fluorescent facial imaging, respectively, was changed to avoid saturation of fluorescent patches. The fluorescent patches representing T-zone (patch numbers: 1-18) and U-zone (patch numbers: 19-28) were sequentially numbered. The CV on the T-zone was slightly higher as compared to the U-zone. However, both cases presented a mean error of 4.3 % in light distribution which is negligible in analysis.

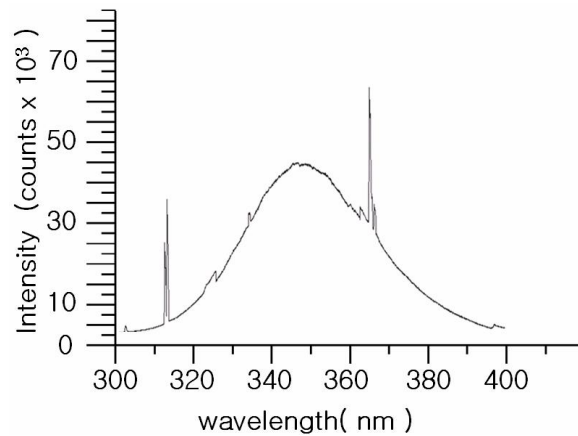


Fig. 3. Optical spectrum (320-380 nm) of the UV-A lamp. It has spectral range which is safe for human skin application.

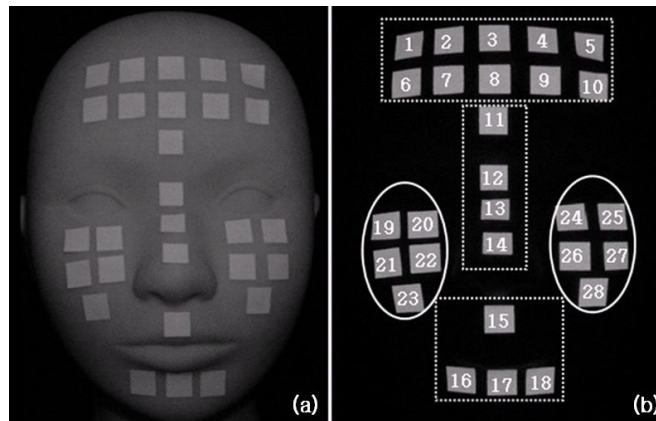


Fig. 4. Investigation of the uniformity of the light distribution. Fluorescent patches were placed on the T-zone (square-dotted line) and U-zone (solid-circle line) of the mannequin facial model. (a) White light image and (b) fluorescent image of fluorescent patches placed on the mannequin facial model.

3.2 In vivo Facial Fluorescent Image Analysis

Before taking the fluorescent facial image [Fig. 5 (b)], a routine digital color image [Fig. 5 (a)] was taken with the same camera using the internal flash while the subject was in the imaging box. Four different facial regions (mid-forehead, nose, left-cheek and right-cheek) were clipped from the subject's entire facial fluorescent image in order to calculate

sebum related parameters (the percent area, mean area and diameter, and number of sebum spots). The results are summarized in Table 1. The qualitative information, such as the patterns and the size distribution of the sebum spots, are presented in Fig. 6.

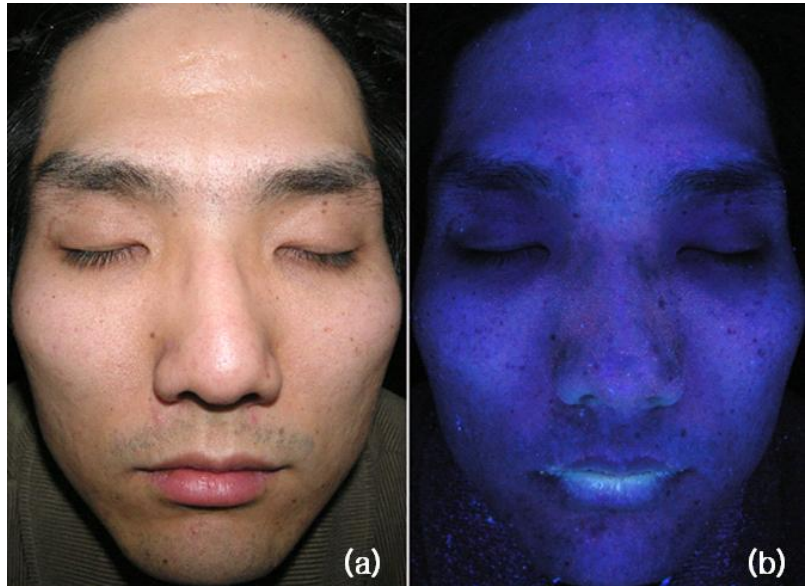

Fig. 5. (a) Routine color image and (b) fluorescent image of a human face. The sun damage blotches are clearly observed in the fluorescent image while they are not discernible in the routine digital color image.

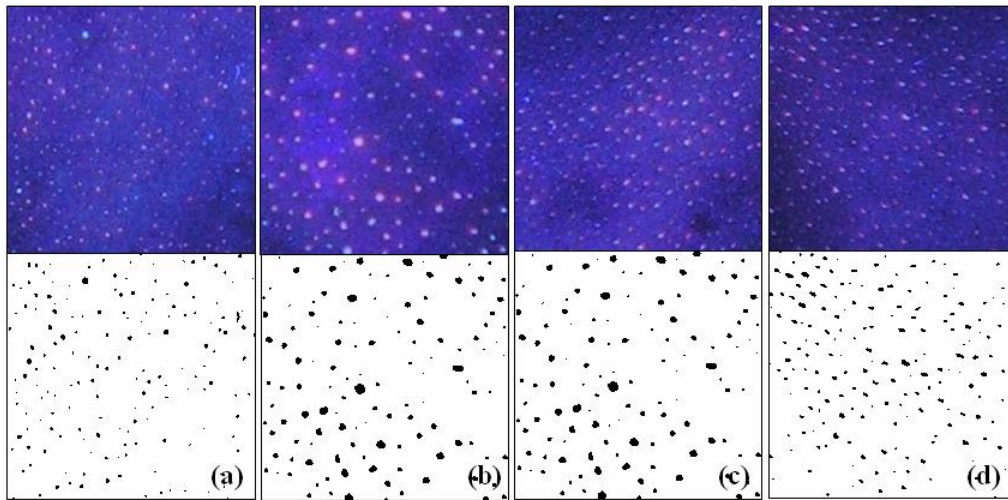


Fig. 6. Fluorescent images (upper) and processed pattern image (lower) of sebum excretion on (a) mid-forehead, (b) nose, (c) left-cheek and (d) right-cheek. The upper images were used to compute the information of sebum excretion in Table 1.

Parameters	Mid-forehead	Nose	Left-cheek	Right-cheek
Total pixel number	208 × 208	208 × 208	208 × 208	208 × 208
Total area (cm ²)	4 (2×2)	4 (2×2)	4 (2×2)	4 (2×2)
Sebum area (cm ²)	0.0708	0.1482	0.106	0.1123
Percent sebum area (%)	1.7705	3.7052	2.6489	2.8083
Number of sebum spots	169	125	172	186
Mean area of sebum spots (cm ²)	4.19×10 ⁻⁴	11.86×10 ⁻⁴	6.16×10 ⁻⁴	6.04×10 ⁻⁴
Mean diameter of sebum spots (cm)	2.316×10 ⁻⁴	1.186×10 ⁻⁴	2.801×10 ⁻⁴	2.773×10 ⁻⁴

Table 1. Sebum-related parameters computed from the facial fluorescent image of a human subject [Fig. 6].

4. DISCUSSION

The T- and U-zone on the face presented slightly different light distributions due to the working distance of light. The mid-forehead and nose that resulted in similar light distributions are closer to the light source as compared to the mid-cheek and chin which resulted in similar light distributions. Such results can affect the fluorescent image analysis because fluorescent intensity is dependent upon incident light intensity. Therefore, fluorescent image analysis has to be carefully performed when comparing the severity of skin lesions using fluorescent images. In addition, image acquisition conditions, such as camera setting, constant light source, and imaging configuration, have to be maintained during the therapeutic period for a constant and reliable comparison of therapeutic outcome for the skin disorder/disease.

Color images in dermatology have been routinely used as an important diagnostic tool to determine therapeutic outcome. However, it has limitations in clinical diagnosis due to poor functional information of the image modality. A fluorescent image [Fig. 5 (b)] provides functional information for skin conditions which cannot be detected in a routine color image [Fig. 5 (a)]. The red, white, and yellow colored sebum spots in figure 5 (b) and 6 are due to excessive skin oil, inflammation, and oil that is not pH balanced and may be bacteriostatic, respectively.^{7,8} In addition, sun damaged areas appear as diffuse gray to black blotches and are clearly observed in the fluorescent image while they are not discernible in the routine digital color image (Fig. 5). In the analysis of fluorescent image, it is important to sure that the measured signal is caused only by the substances of interest (in this case, sebum) without any influence by other chemical compounds. A good source of interesting artifacts is observed on the lips of figure 5 (b) as a result of foods and drinks the volunteer consumed. Many things of foods and drinks can fluoresce and the residue on the lips might show up on a fluorescent image. Herein, we did not consider the fluorescence on the lips because of no sebaceous glands in the anatomical site.

The imaging modality when compared to the “Sebutape” method, has the advantage of non-contact image acquisition, nearly real-time image analysis, and continuous monitoring of sebum excretion. In addition, the fluorescent imaging method provides the information of the sebum parameters (total percent area, density, number, size distribution of sebum spots, and patterns of follicular sebum excretion) for the entire facial area, while the “Sebutape” presents regional information of about 2.5 × 2 cm². In order to evaluate the sebum excretion, the “Sebutape” method takes approximately 1 hour for collection and analysis of sebum excretion.¹³ The same parameters (Table 1) acquired from “Sebutape” can be evaluated in nearly real-time by applying the image analysis methods to the fluorescent image. For clinical application, the sebum information may play important roles in studying acne because its development is closely related to seborrhea and the suppression of sebum production is a powerful therapeutic principle for acne management.¹⁻³ Morphological patterns of sebum excretion are also useful qualitatively in defining pattern variations over time. For example, Piérard *et al.* defined five different patterns: infantile, pubertal, adult, acne, and aging.¹⁶ In a future study, the condition of sebum

excretion will be classified by fluorescent colors utilizing the color image analysis method. In addition, other skin disorders related to pigmentation and inflammation will be analyzed with various image analysis methods.

5. CONCLUSION

In conclusion, the fluorescent digital imaging system is a useful, easy, and non-contact method to evaluate sebum excretion and to characterize the pattern of sebum distribution. Various image analysis methods were applied to the fluorescent image to obtain parameters for sebum excretion. When compared to conventional methods that provide similar parameters for sebum excretion, our approach is a simpler and more reliable way to evaluate the dynamics of sebum excretion in nearly real-time.

6. ACKNOWLEDGMENT

This research was supported by Regional Research Center Program which was conducted by the Ministry of Commerce, Industry and Energy of the Korean Government. JSN was supported by the following grants from the National Institutes of Health (AR47751 and EB 2495).

REFERENCES

1. C. C. Zouboulis. "Acne and sebaceous gland function," *Clin. Dermatol.* 22, 306-366 (2004).
2. C. C. Zouboulis, A. Eady, M. Philpott, L. A. Goldsmith, C. Orfanos, W. C. Cunliffe, R. Rosenfield R., "What is the pathogenesis of acne?," *Exp. Dermatol.* 14, 143-152 (2005).
3. S-W. Youn, E.-S. Park., D-H. Lee, C-H. Huh, K-C. Park, "Does facial sebum excretion really affect the development of acne?," *Br.J.Dermatol.* 153, 919-924 (2005).
4. P. Clarys, A. Barel. "Quantitative evaluation of skin surface lipids," *Clin. Dermatol.* 13, 307-321 (1995).
5. S. W. Youn, S. J. Kim, I. A. Hwang, K. C. Park, "Evaluation of facial skin type by sebum secretion: discrepancies between subjective descriptions and sebum secretion," *Skin Res. Technol.* 8, 168-172 (2002).
6. S. W. Youn, J. I. Na, S. Y. Choi, C. H. Huh, K. C. Park, "Regional and seasonal variation in facial sebum secretions: a proposal for the definition of combination skin type," *Skin Res. Technol.* 11, 189-195 (2005).
7. P. Asawanonda, C.R. Taylor, "Wood's light in dermatology," *Int. J. Dermatol.* 38, 801-807 (1999).
8. Meeks Engineering, see <http://www.atlantacamera.com/pictures.html> (2006)
9. G. E. Piérard, C. Piérard-Franchimont, R. Marks, M. Paye, V. Rogiers, "EEMCO guidance for the in vivo assessment of skin greasiness," *Skin Pharmacol. Appl. Skin Physiol.* 13, 372-389 (2000).
10. A. Pagnoni, T. Stoudemayer, A. M. Kligman, "Use of sebutape assessed by image analysis to measure sebaceous gland activity," Chap. 8 in *Bioengineering of the Skin: Skin Surface Imaging and Analysis*, K-P. Wilhelm, P. Elsner, E. Berardesca, and H. I. Maibach, Eds., pp. 105-111, CRC press, New York (1997).
11. J. Niamtu III, "Digitally processed ultraviolet images: A convenient affordable, reproducible means of illustrating ultraviolet clinical examination," *Dermatol. Surg.* 27, 1039-1042 (2001).
12. B. Jung, B. Choi, Y. Shin, A. J. Durkin, J. S. Nelson, "Determination of optimal view angles for quantitative facial image analysis," *J. Biomed. Opt.* 10, 024002 (2005).
13. P. Elsner, "Sebum," Chap. 8 in *Bioengineering of the Skin: Methods and Instrumentation*, E. Berardesca, P. Elsner, K-P. Wilhelm, H. I. Maibach, Eds., pp. 81-89, CRC press, New York (1995).
14. D.H. Suh, T. E. Kwon, J. L. Youn, "Change of comedonal cytokines and sebum secretion after UV irradiation in acne patients," *Eur. J. Dermatol.* 12, 139-144 (2002).
15. S. E. Mudiyansele, M. Hamburger, P. Elsner, J. J. Thiele, "Ultraviolet A induces generation of squalene monohydroperoxide isomers in human sebum and skin surface lipids In Vitro and In Vivo," *J. Invest. Dermatol.* 120, 915-922 (2003).
16. G. E. Piérard, C. Piérard-Franchimont, T. Lé, C. Lapière C, "Patterns of follicular sebum excretion rate during lifetime," *Arch. Dermatol. Res.* 279, S104-S107 (1987).