

UCSF

UC San Francisco Previously Published Works

Title

Variable disruption of a syntactic processing network in primary progressive aphasia.

Permalink

<https://escholarship.org/uc/item/9q5506dw>

Journal

Brain, 139(11)

ISSN

0006-8950

Authors

Wilson, Stephen M
DeMarco, Andrew T
Henry, Maya L
[et al.](#)

Publication Date

2016-11-01

DOI

10.1093/brain/aww218

Peer reviewed

Variable disruption of a syntactic processing network in primary progressive aphasia

Stephen M. Wilson,^{1,2*} Andrew T. DeMarco,¹ Maya L. Henry,^{3,4} Benno Gesierich,³ Miranda Babiak,³ Bruce L. Miller³ and Maria Luisa Gorno-Tempini³

Syntactic processing deficits are highly variable in individuals with primary progressive aphasia. Damage to left inferior frontal cortex has been associated with syntactic deficits in primary progressive aphasia in a number of structural and functional neuroimaging studies. However, a contrasting picture of a broader syntactic network has emerged from neuropsychological studies in other aphasic cohorts, and functional imaging studies in healthy controls. To reconcile these findings, we used functional magnetic resonance imaging to investigate the functional neuroanatomy of syntactic comprehension in 51 individuals with primary progressive aphasia, composed of all clinical variants and a range of degrees of syntactic processing impairment. We used trial-by-trial reaction time as a proxy for syntactic processing load, to determine which regions were modulated by syntactic processing in each patient, and how the set of regions recruited was related to whether syntactic processing was ultimately successful or unsuccessful. Relationships between functional abnormalities and patterns of cortical atrophy were also investigated. We found that the individual degree of syntactic comprehension impairment was predicted by left frontal atrophy, but also by functional disruption of a broader syntactic processing network, comprising left posterior frontal cortex, left posterior temporal cortex, and the left intraparietal sulcus and adjacent regions. These regions were modulated by syntactic processing in healthy controls and in patients with primary progressive aphasia with relatively spared syntax, but they were modulated to a lesser extent or not at all in primary progressive aphasia patients whose syntax was relatively impaired. Our findings suggest that syntactic comprehension deficits in primary progressive aphasia reflect not only structural and functional changes in left frontal cortex, but also disruption of a wider syntactic processing network.

1 Department of Speech, Language, and Hearing Sciences, University of Arizona, Tucson, AZ, USA

2 Department of Neurology, University of Arizona, Tucson, AZ, USA

3 Department of Neurology, University of California, San Francisco, CA, USA

4 Department of Communication Sciences and Disorders, University of Texas, Austin, TX, USA

*Present address: Department of Hearing and Speech Sciences, Vanderbilt University Medical Center, Nashville, TN, USA

Correspondence to: Stephen M. Wilson,
Department of Hearing and Speech Sciences,
Vanderbilt University Medical Center,
MCE 8310, 1215 21st Ave S,
Nashville, TN 37232, USA
E-mail: stephen.m.wilson@vanderbilt.edu

Keywords: primary progressive aphasia; syntax; reaction time; functional MRI; voxel-based morphometry

Abbreviations: BOLD = blood oxygen level-dependent; PPA = primary progressive aphasia

Introduction

Primary progressive aphasia (PPA) is a clinical syndrome in which neurodegeneration of dominant hemisphere language regions leads to progressive language deficits, with relative sparing of other cognitive functions (Mesulam *et al.*, 2014). There is considerable variability in the distribution of cortical atrophy in PPA, and patterns of language deficits vary accordingly, since they reflect the underlying distribution of atrophy. In particular, three clinical variants of PPA—non-fluent/agrammatic, semantic and logopenic—are recognized (Gorno-Tempini *et al.*, 2004, 2011), but even within each variant, individual patients differ in terms of their specific patterns of atrophy and language deficits (Wilson *et al.*, 2010*b*).

Syntactic processing refers to the implicit construction and manipulation of abstract hierarchical structures that specify the relationships between the words and morphemes that make up sentences. Both the comprehension and the production of sentences depend on syntactic processing. Like other domains of language function, syntactic processing deficits are highly variable in individuals with PPA. Some patients are capable of producing only nouns in isolation; other patients exhibit agrammatic or paragrammatic features to different degrees; while still other patients' grammars are essentially intact, despite profound deficits in other language domains (Warrington *et al.*, 1975; Hodges and Patterson, 1996; Patterson *et al.*, 2006; Meteyard and Patterson, 2009; Wilson *et al.*, 2010*b*; see Wilson *et al.*, 2012 for review). Deficits in the comprehension and production of syntactic structures are highly correlated in PPA (Wilson *et al.*, 2011), suggesting that these deficits usually reflect damage to core syntactic processes rather than peripheral mechanisms.

Damage to left inferior frontal cortex has been associated with syntactic deficits in PPA in a number of structural and functional neuroimaging studies. Voxel-based morphometry and cortical thinning studies have shown that atrophy of left frontal regions is predictive of syntactic deficits in comprehension (Amici *et al.*, 2007; Peelle *et al.*, 2008; Sapolsky *et al.*, 2010; Wilson *et al.*, 2011) and production (Gunawardena *et al.*, 2010; Wilson *et al.*, 2010*b*, 2011; Rogalski *et al.*, 2011; DeLeon *et al.*, 2012). Functional MRI studies have shown that left inferior frontal cortex is not only atrophic, but is also functionally abnormal: in non-fluent/agrammatic variant PPA, left inferior frontal cortex is not modulated by syntactic complexity as it is in healthy controls (Wilson *et al.*, 2010*a*; see also Cooke *et al.*, 2003). Conversely, in patients with semantic variant PPA, in whom syntactic processing is largely spared, there is normal modulation by syntactic complexity in this region (Wilson *et al.*, 2014). Dorsal white matter pathways that connect left frontal cortex to posterior temporal and parietal regions have also been implicated in syntactic deficits: microstructural damage to these pathways—the superior longitudinal fasciculus including its arcuate component—

is associated with impaired syntactic comprehension and production (Wilson *et al.*, 2011).

While these studies generally suggest that syntactic deficits in PPA are associated with atrophy and dysfunction of left inferior frontal cortex, a contrasting picture of a broader syntactic network has emerged from neuropsychological studies in other aphasic cohorts, and functional imaging studies in healthy controls. Infarction confined to left inferior frontal cortex does not generally lead to protracted agrammatism (Mohr, 1976; Baldo and Dronkers, 2006). While some lesion–symptom mapping studies have linked left frontal damage to syntactic deficits (Dronkers *et al.*, 2004; Newhart *et al.*, 2012; Teichmann *et al.*, 2015), these same studies have also implicated temporal (Dronkers *et al.*, 2004) or parietal (Newhart *et al.*, 2012) regions, while other researchers have reported only temporal or temporo-parietal lesion correlates of syntactic deficits (Leff *et al.*, 2009; Thothathiri *et al.*, 2012; Magnusdottir *et al.*, 2013), or have contended that there is individual variability in a range of perisylvian and even extrasylvian regions important for syntactic function (Caplan *et al.*, 1996, 2007, 2015). Many functional imaging studies have shown that left inferior frontal cortex is sensitive to syntactic complexity (Stromswold *et al.*, 1996), but more recent studies have demonstrated that not only frontal but also posterior temporal regions are robustly modulated by syntactic complexity (Friederici *et al.*, 2009; Snijders *et al.*, 2009; Wilson *et al.*, 2010*a*; Pallier *et al.*, 2011; Blank *et al.*, 2016).

Are syntactic deficits in PPA related to damage and dysfunction of left frontal cortex, or to dysfunction of a broader syntactic network? To address this question, we used functional MRI to investigate the functional neuroanatomy of syntactic processing in a comprehension task in a large cohort of individuals with PPA, composed of all clinical variants and a wide range of degrees of syntactic processing impairment. To determine which regions were modulated by syntactic processing in each patient, we used trial-by-trial reaction time as a proxy for syntactic processing load, and then examined how the set of regions that each individual recruited was related to whether syntactic comprehension was ultimately successful or unsuccessful. We then investigated relationships between functional abnormalities and patterns of cortical atrophy.

Materials and methods

Participants

Structural and functional imaging data were successfully acquired from 51 patients with PPA and 24 healthy age-matched control participants over a 4-year period. Patients and age-matched controls were recruited through the Memory and Aging Center at the University of California, San Francisco (UCSF). All participants gave written informed consent, and the study was approved by the institutional

review boards at UCSF and the University of Arizona. Patients and controls received a comprehensive multidisciplinary evaluation including neurological history and examination, neuropsychological testing, and neuroimaging.

Patients were diagnosed with PPA based on recent guidelines (Gorno-Tempini *et al.*, 2011). A diagnosis of PPA required progressive deterioration of speech and/or language functions, and that deficits be largely restricted to speech and/or language for at least 2 years. Neuroimaging results were not used for diagnostic purposes, but only to rule out other causes of focal brain damage. Although syntactic deficits may also be observed in patients with other neurodegenerative syndromes such as behavioural variant frontotemporal degeneration (Pelle *et al.*, 2008; Charles *et al.*, 2014) and Alzheimer's disease (Grossman and Rhee, 2001), we did not include these patients, because their language deficits have been shown to often be secondary to deficits in other domains such as working memory or executive function, which would complicate interpretation.

Additional inclusion criteria were fluency in English, and a Mini-Mental State Examination score of at least 15 (Folstein *et al.*, 1975). A total of 57 patients met these criteria and were scanned, but six patients were excluded: four because they requested that the scanning session be stopped before the functional run was complete, one for excessive head motion that could not be corrected, and one for failing to respond on ~35% of trials. All analyses were based on the remaining 51 patients.

There were 17 patients with non-fluent/agrammatic variant PPA (eight of whom were included in Wilson *et al.*, 2010a), 20 patients with semantic variant PPA (all of whom were included in Wilson *et al.*, 2014), 12 patients with logopenic variant PPA (none of whom have been reported previously), and two patients who met criteria for PPA but did not meet criteria for any variant (these patients have not been reported previously).

There were 24 control participants (all of whom were included in Wilson *et al.*, 2010a and Wilson *et al.*, 2014), who were recruited from the same communities as the patients, and were confirmed to be normal based on a comprehensive multidisciplinary evaluation.

Demographic, clinical, and neuropsychological characteristics for all included participants are provided in Table 1. There were no significant differences between patients and controls in age, sex, handedness or education.

Structural images from an additional 50 age-matched controls were used to create a template for intersubject normalization and voxel-based morphometry.

Experimental design

The design of the functional MRI study has been described in detail previously (Wilson *et al.*, 2010a), so only a brief summary is presented here. Participants were scanned with functional MRI as they performed an auditory sentence-to-picture matching task. Each trial began with the presentation of two pictures: a target and a foil, one on the left and one on the right of the screen. One second later, a sentence was presented auditorily that matched one of the two pictures. Participants selected the matching picture at any point by pressing one of two buttons with their right hand.

There were seven conditions, which differed in the syntactic processing required as well as in length (Table 2). In two

conditions (Short Lexical, Long Lexical), the correct response could be determined based on lexical information alone, as the foil pictures involved different lexical items than the target pictures. In two more conditions (Short Active, Long Easy), the foil pictures contained the same lexical items as the target pictures, so it was necessary to attend to syntactic structures to determine the correct response, but the syntactic structures involved were canonical: elements were arranged in configurations that are prototypical in English. The final three conditions (Short Passive, Long Medium, Long Hard) also required processing of syntactic structures to determine the correct response, but now the structures involved were non-canonical: elements were displaced from their prototypical positions. Within each length category (short or long), all conditions were matched for length, for lexical content, and for the point at which the sentence disambiguated between the target and foil pictures. To keep lexical demands to a minimum, all sentences were constructed using just two high-frequency nouns (boy, girl), one of seven high-frequency verbs (push, pull, kiss, kick, chase, wash, hug), and for the long sentences, one of three high-frequency colour adjectives (red, green, blue). It was important to minimize lexical demands because patients with semantic PPA often have severe lexical deficits.

The total duration of the functional sequence was 15 min 40 s. There were three blocks per condition, for a total of 21 blocks, presented in random order. Each block was 28 s in length and contained four equally spaced trials, and there were 16 s rest periods between blocks and at the beginning and end of the experiment. In previous studies based on this experimental task (and subsets of the present group of patients), our primary analyses were based on the block design (Wilson *et al.*, 2010a, 2014). In this study, to account for the wide range of performance in our PPA cohort, the data were analysed only as an event-related design, fitting response variables to the four individual trials within each block, as described in more detail below. The intertrial interval of 7 s was sufficiently long to permit an event-related analysis.

Prior to scanning, participants were trained on the task. They were then scanned on a Siemens 3T Trio scanner. T₁-weighted anatomical images and T₂*-weighted blood oxygen level-dependent (BOLD) echo-planar images (repetition time = 2000 ms; 470 volumes; whole brain coverage) were acquired using standard sequences as described previously (Wilson *et al.*, 2010a). Auditory stimuli were presented via headphones, visual stimuli were presented via a monitor that was viewed via a mirror, and button presses were recorded.

Analysis of behavioural data

Accuracy on the syntactic comprehension task was quantified as the percentage of trials on which a correct response was provided. Reaction times were measured from the onset of the first word in the sentence that disambiguated the target picture from the foil, and were calculated including correct and incorrect trials (but not trials on which no response was provided).

Analysis of functional imaging data

The functional data were visually inspected and volumes where there was excessive head motion (visible interleaving artefact) or other artefacts were replaced with interpolated data prior to

Table 1 Demographic, clinical and neuropsychological characteristics of PPA patients and controls

	PPA	Control
Demographic		
Age	65.0 ± 7.8	66.8 ± 4.2
Sex (M/F)	27/24	7/17
Handedness (R/L)	42/9	22/2
Education (years)	16.7 ± 2.6	17.2 ± 2
Clinical		
Mini-Mental State Examination (30)	25.5 ± 3.6*	29.3 ± 0.8
Clinical Dementia Rating	0.63 ± 0.25	N/A
Age at disease onset	60.5 ± 7.9	N/A
Years from first symptom	4.4 ± 3.1	N/A
Language production		
Confrontation naming (BNT, 15)	8.7 ± 4.5*	14.5 ± 0.7
Phonemic fluency (D words in 1 min)	7.4 ± 4.5 ^{a,b}	17.6 ± 4.1
Semantic fluency (Animals in 1 min)	8.5 ± 4.6 ^{a,b}	23.8 ± 4.3
Speech fluency (WAB, 10)	7.7 ± 2.2*	10.0 ± 0.0 ^a
Apraxia of speech rating (MSE, 7)	1.1 ± 1.9	N/A
Dysarthria rating (MSE, 7)	0.9 ± 1.9	N/A
Repetition (WAB, 100)	86.7 ± 10.3 ^{a,b}	99.5 ± 0.9 ^a
Language comprehension		
Auditory word recognition (PPVT, 16)	12.2 ± 4.1*	15.7 ± 0.7
Sequential commands (WAB, 80)	72.8 ± 9.1*	80.0 ± 0.0 ^a
Semantic knowledge (PPT-P, 52)	46.0 ± 6.0*	51.8 ± 0.4 ^a
Visuospatial function		
Modified Rey-Osterrieth copy (17)	15.0 ± 1.7	15.0 ± 1.1
Visual memory		
Modified Rey-Osterrieth delayed copy (17)	8.1 ± 3.6*	11.7 ± 2.3
Verbal memory		
CVLT-MS Trials 1–4 (40)	18.1 ± 8.0*	28.7 ± 3.1
CVLT-MS 30 s free recall (10)	4.4 ± 2.8*	7.9 ± 1.6
CVLT-MS 10 min free recall (10)	3.4 ± 2.9*	7.3 ± 1.6
Executive function		
Digit span backwards	4.1 ± 1.5*	5.6 ± 1.2
Modified Trail making test (lines per min)	18.3 ± 11.2*	37.8 ± 12.6
Calculation (WAB, 5)	4.3 ± 1.0*	4.8 ± 0.4

Values are means ± standard deviation. Variables were compared between patients and controls using Welch's *t*-tests where appropriate, the Wilcoxon signed-rank test for measures with floor or ceiling effects, and Fisher's exact test for discrete variables. *Significantly impaired relative to controls, $P < 0.05$.

^aData from Gorno-Tempini *et al.* (2004) as present control group was not tested on these variables.

^bTwo non-fluent/agrammatic patients were excluded from these variables due to being mute.

BNT = Boston Naming Test; WAB = Western Aphasia Battery; MSE = Motor Speech Evaluation; PPVT = Peabody Picture Vocabulary Test; PPT-P = Pyramids and Palm Trees–Pictures; CVLT-MS = California Verbal Learning Test–Mental Status.

See Kramer *et al.* (2003) for detailed description of neuropsychological testing procedures and Gorno-Tempini *et al.* (2004) for detailed description of language testing procedures.

preprocessing, and later excluded from model fitting. The mean number of volumes excluded was 20.7 ± 27.7 in patients with PPA and 11.5 ± 15.9 in controls [not significant (n.s.)]. The functional imaging data were preprocessed with standard methods in AFNI (Cox, 1996): the data were corrected for slice timing differences, realigned to account for head movement, smoothed with a Gaussian kernel of 8 mm full-width at half-maximum, high pass filtered (cut-off = 100 s) and

detrended (Legendre polynomials of order up to and including 2). Independent component analysis was then carried out using the FSL tool *melodic* (Beckmann and Smith, 2004), generating 30 components. Noise components were manually identified with reference to published criteria (Kelly *et al.*, 2010), and removed using *fsl_regfilt*. The mean number of components removed was 9.0 ± 2.1 in patients with PPA and 9.0 ± 2.4 in controls (n.s.).

The functional MRI data were analysed with a whole-brain general linear model using the *fmrilm* procedure from FMRISTAT (Worsley *et al.*, 2002). Reaction time was used as a proxy for allocation of syntactic processing resources. Reaction time was measured from the onset of the first word in the sentence that disambiguated the target from the foil, under the assumption that more syntactic processing took place on trials with longer reaction times (Taylor *et al.*, 2014). This approach enabled a direct comparison of the regions that patients and controls recruited to perform the task, despite individual and group differences in performance. The four trials within each block were modelled as separate events with duration of 4 s each, convolved with a haemodynamic response function consisting of a gamma density function (delay $5.4 \text{ s} \pm 5.2 \text{ s}$; no post-stimulus undershoot). Short and long trials were modelled with separate explanatory variables, each of which was parametrically modulated by another variable coding reaction time for that trial. Reaction time was demeaned based on the mean of all short or long trials, clipped at 1.5 standard deviations (SD) from the mean, then demeaned again. Both correct and incorrect trials were included, to identify regions recruited for syntactic processing regardless of whether that processing was successful. Trials on which there was no response were not included; they were modelled with a separate explanatory variable of no interest. Additional covariates of no interest were included to reduce error variance: three translation and three rotation parameters (saved during realignment), BOLD signal time courses from a white matter region of interest and a CSF region of interest, the whole brain global signal, and three cubic spline temporal trends. The main contrast of interest was BOLD signal change per second of reaction time, which was averaged across the short and long parametric variables. The purpose of this contrast was to identify regions modulated by syntactic complexity. A second contrast of interest was the main effect of the task, again averaged across the short and long variables. This contrast identified regions involved in sentence comprehension in general, along with non-linguistic functions related to the task, such as visual, auditory, motor and executive processes.

Random effects analyses were carried out on contrast images from individual participants, which were normalized to Montreal Neurological Institute (MNI) space by applying transformations derived from the structural images (see below). All statistical maps were thresholded at voxelwise $P < 0.005$, and then corrected for multiple comparisons at $P < 0.05$ based on cluster extent according to Gaussian random field theory implemented in SPM5 (Worsley *et al.*, 1996).

Analysis of structural imaging data

The T_1 -weighted structural images were bias-corrected, segmented into grey matter, white matter and CSF, and initially normalized to MNI space using the unified segmentation

Table 2 Sentence structures and foils in the seven conditions

Condition	Sentence example	Foil picture
Short Lexical	The boy is hugging the girl	Different action (e.g. pulling)
Short Active	The girl is kissing the boy	Agent and patient reversed
Short Passive ^a	The boy is kicked by the girl	Agent and patient reversed
Long Lexical	The girl who is green is pushing the boy The boy is kissing the girl who is red	Different action (e.g. chasing) Different coloured patient (e.g. green girl)
Long Easy	The girl is pulling the boy who is red The boy who is red is chasing the girl	Colour assigned to wrong participant Agent and patient reversed
Long Medium ^a	The girl who is washed by the boy is green The girl who the boy is hugging is red	Colour assigned to wrong participant Agent and patient reversed
Long Hard ^a	The boy who the girl is pushed by is blue The girl who the boy is kissed by is green	Agent and patient reversed Colour assigned to wrong participant

^aNon-canonical structures.

Note that this table is identical to Table 2 in Wilson *et al.* (2014). See Wilson *et al.* (2010a) for a more detailed description and linguistic analysis of the stimuli.

algorithm in SPM5 (Ashburner and Friston, 2005). More anatomically precise intersubject registration was then performed with the Diffeomorphic Anatomical Registration Through Exponentiated Lie algebra (DARTEL) toolbox (Ashburner, 2007) by warping each participant's image to a template created from the 50 additional control participants. Grey matter and white matter probability maps were scaled by Jacobians, smoothed with a Gaussian kernel of 12 mm full-width at half-maximum, then summed together to obtain a map of brain parenchyma (Wilson *et al.*, 2010b).

Voxel-based morphometry was used to identify regions where volume loss was predictive of syntactic deficits. Voxelwise correlations of parenchymal volume with overall syntactic comprehension accuracy were calculated in the 51 patients with PPA, with age, sex and total intracranial volume included as covariates. The resulting *t* map was thresholded at voxelwise $P < 0.005$, then corrected for multiple comparisons at $P < 0.05$ based on cluster size with respect to 1000 permutations in which behavioural scores were randomly reassigned (Wilson *et al.*, 2010b).

Results

Descriptive overview

Patients with PPA were highly variable in their performance on the syntactic comprehension task. Accuracy ranged from 52.4% to 91.7% correct, with a mean of $76.9\% \pm 11.9\%$, compared to $92.8\% \pm 3.1\%$ in controls.

Syntactic processing deficits in PPA are graded rather than binary, and accuracy on the syntactic processing task will be treated as a continuous variable in most of the analyses in this study. But first, a median split half analysis was carried out, to present an intuitive overview of the general patterns of accuracy, reaction time, and brain regions modulated by syntactic processing, in patients with relatively spared or relatively impaired syntactic comprehension. A split half analysis is not optimal for statistical analysis, hence this section is descriptive. Inferential statistical analyses will be reported in subsequent sections.

A median split yielded 26 patients in the 'impaired' group (accuracy 52.4% to 77.4%), and 25 in the 'spared' group (accuracy 79.8% to 91.7%). Accuracy and reaction time were plotted as a function of sentence structure (syntactic complexity and length) for controls, for the relatively spared patients, and for the relatively impaired patients (Fig. 1A and B). The relatively spared patients with PPA were almost as accurate as controls, whereas the relatively impaired patients were less accurate and performed increasingly poorly as syntactic complexity increased. Reaction times were shortest in controls, longer in the relatively spared patients, and longer still in the relatively impaired patients, but similar patterns as a function of condition were seen in each case, with slower responses as syntactic complexity increased.

To identify brain regions involved in syntactic processing, the parametric modulation of BOLD signal by trial-by-trial reaction time was mapped, as a proxy for extent of syntactic processing. The regions modulated by syntactic processing were similar in controls and in patients whose syntax was relatively spared (Fig. 1C). In both of these groups, regions modulated by syntactic processing included, in the left hemisphere, the posterior inferior frontal gyrus, precentral gyrus, anterior insula, presupplementary motor area, intraparietal sulcus and adjacent regions, posterior superior temporal sulcus, posterior middle temporal gyrus, middle occipital gyrus, and thalamus. In the right hemisphere, the same regions were modulated to a lesser extent, with the exception of the posterior superior temporal sulcus and posterior middle temporal gyrus, which were not modulated in the right hemisphere.

In contrast, in the patients whose syntax was relatively impaired, a much less extensive network was modulated by syntactic processing (Fig. 1C). The regions modulated by syntactic processing in this group included the left posterior inferior frontal gyrus, left precentral gyrus, left and right supplementary motor area, left and right anterior insula and left intraparietal sulcus, but all of these regions were modulated less than they were in the patients with

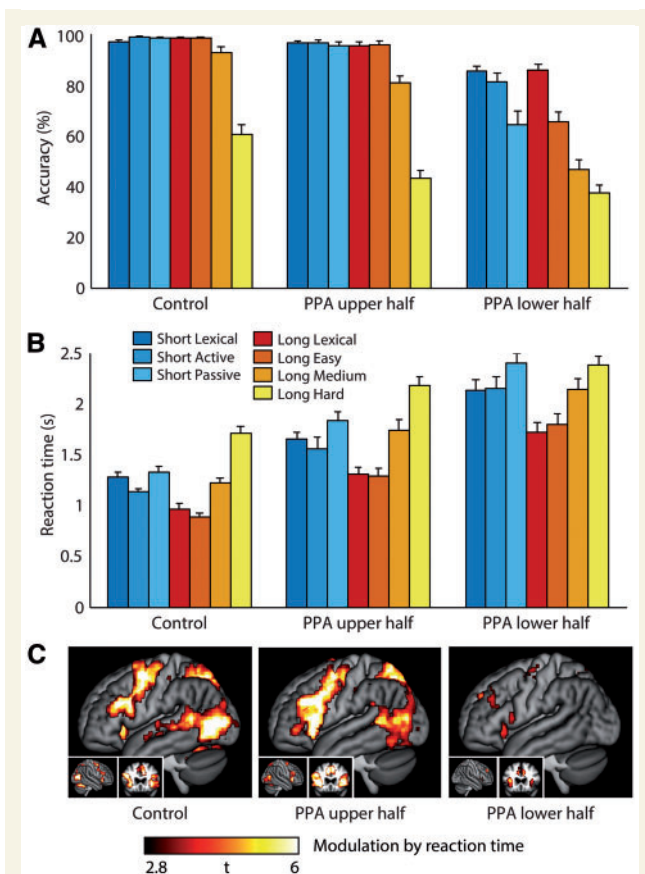


Figure 1 Descriptive median split half analysis. **(A)** Accuracy on the syntactic processing task as a function of condition (sentence structure/length) in healthy controls, patients with PPA with relatively spared syntax, and patients with PPA with relatively impaired syntax. **(B)** Reaction time as a function of condition in healthy controls, patients with PPA with relatively spared syntax, and patients with PPA with relatively impaired syntax. **(C)** Modulation of BOLD signal by reaction time, a proxy for extent of syntactic processing, in healthy controls, patients with PPA with relatively spared syntax, and patients with PPA with relatively impaired syntax. $P < 0.05$ corrected for multiple comparisons.

relatively spared syntax, and less than they were in the controls.

Functional imaging correlates of accuracy on the syntactic comprehension task

To quantify this apparent difference in regions recruited for syntactic processing between patients in whom syntax was relatively impaired or relatively spared, a voxelwise correlation map was computed in the 51 patients with PPA, between individual effect size maps of modulation by reaction time, and overall accuracy on the syntactic task (Fig. 2A and Table 3).

This correlation analysis revealed three regions that were statistically significant after correction for multiple

comparisons: (i) the left posterior inferior frontal gyrus and adjacent anterior insula, inferior frontal sulcus, and ventral precentral gyrus and sulcus; (ii) the left posterior superior temporal sulcus, middle temporal gyrus, and middle occipital gyrus; and (iii) the left intraparietal sulcus and adjacent areas. These three regions were modulated by syntactic processing more in patients with PPA who were more accurate on the task (Fig. 2B, D and F). In healthy controls, these regions were all modulated by syntactic processing, but the extent of modulation was not related to individual differences in accuracy (which were modest) (Fig. 2B, D and F). No region showed the opposite pattern of increased modulation by syntactic complexity in patients who were less accurate on the task.

All three regions described were activated for the syntactic processing task relative to the resting baseline in patients with PPA and healthy controls (Fig. 2C, E and G). There was no relationship in any region in either group between BOLD signal change relative to the resting baseline and accuracy. In the temporal and parietal regions, there was no difference between mean signal change in patients with PPA and controls [temporal $t(59.54) = 0.84$, $P = 0.40$; parietal $t(72.44) = 0.54$, $P = 0.59$]. In the frontal region, signal change was greater in the PPA group ($0.47\% \pm 0.27\%$) than controls ($0.27\% \pm 0.15\%$) [$t(69.77) = 3.96$, $P < 0.001$], but most patients with PPA were still in the control range. This demonstrates that the abnormal lack of modulation by syntactic processing in the impaired patients is quite specific: it is not that the regions in question show no activation at all, but rather, that they do not show additional activation on trials requiring more syntactic processing.

Although the three regions described above were the only statistically significant regions where modulation was correlated with accuracy, at a lower threshold, a similar pattern was seen throughout the network of regions that were modulated by syntactic processing in healthy controls (Fig. 2H).

Correlates of accuracy and reaction time measures

Because our functional imaging analyses depend on the relationship between accuracy and trial-to-trial variability in reaction times, it is important to investigate how accuracy and reaction times were related to each other and to other measures in order to clarify the interpretation of the imaging findings.

Patients with PPA were less accurate ($76.9\% \pm 11.9\%$) than controls ($92.8\% \pm 3.1\%$) [$t(62.59) = 8.91$, $P < 0.001$], and also responded more slowly (1882 ± 443 ms) than controls (1219 ± 174 ms) [$t(71.50) = 9.28$, $P < 0.001$] (Fig. 3A). Accuracy and reaction time were negatively correlated in patients with PPA ($r = -0.61$, $P < 0.001$) but not in controls ($r = -0.28$, $P = 0.19$). Patients who performed more accurately

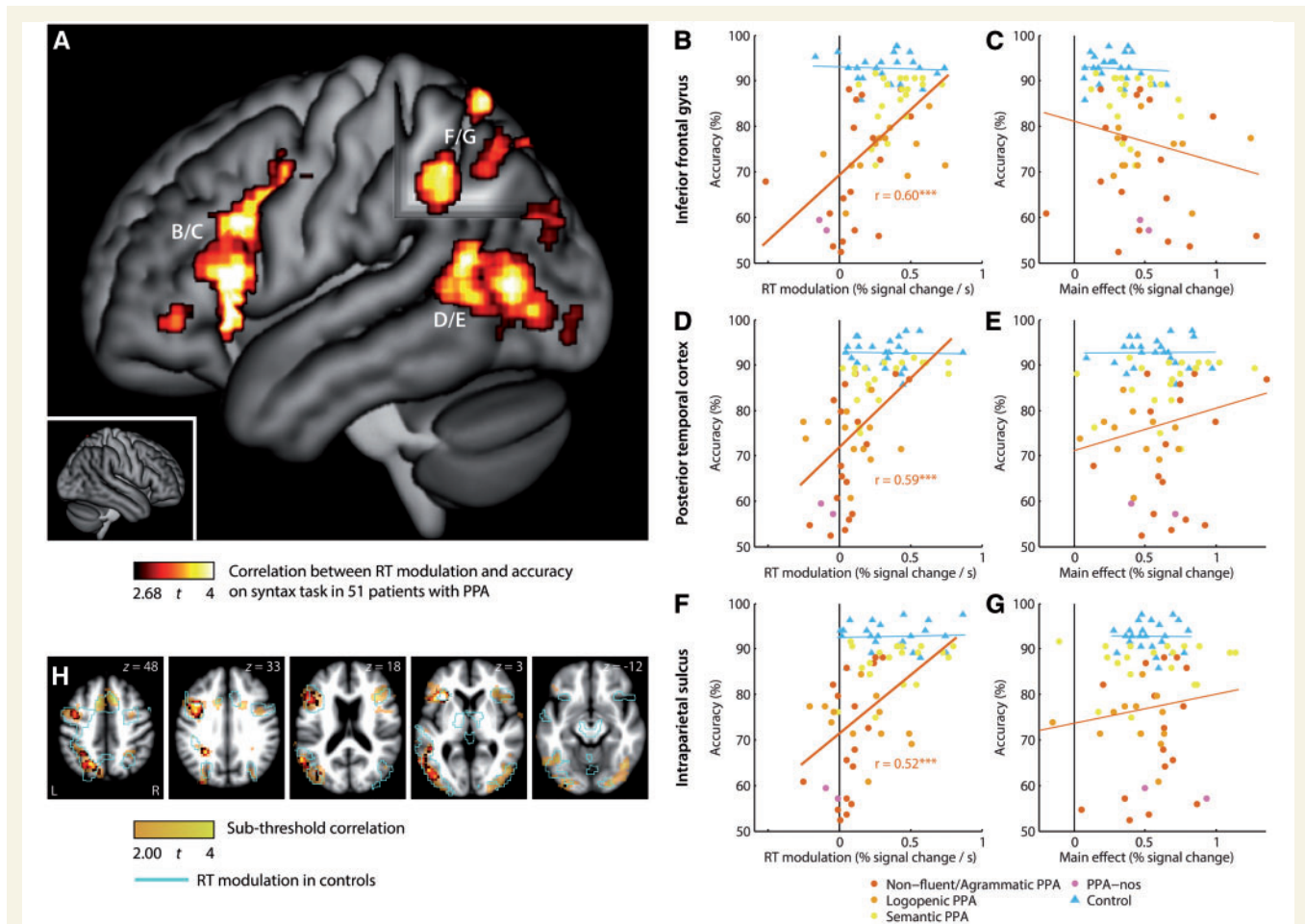


Figure 2 Functional correlates of syntactic performance. (A) Whole-brain correlation between modulation of BOLD signal by reaction time (syntactic processing), and overall accuracy on the syntactic task. $P < 0.05$ corrected for multiple comparisons. Correlations between modulation of signal by reaction time and accuracy are shown for the left frontal (B), left temporal (D) and left parietal (F) regions. Correlations between signal change relative to rest and accuracy are also shown for the left frontal (C), left temporal (E) and left parietal (G) regions. PPA variant diagnoses, and controls, are indicated by colour. Models were fit separately for all patients with PPA, and for controls. (H) At a lower threshold, there were trends for many of the regions modulated by syntactic processing in controls to show less modulation by syntactic processing in patients who performed less well. RT = reaction time.

Table 3 Statistical details of neuroimaging analyses

Brain regions	MNI coordinates			Extent (mm ³)	Max t	P
	x	y	z			
Functional MRI: correlation between reaction time modulation and accuracy on syntax task in PPA patients						
Left posterior inferior frontal gyrus (pars opercularis and triangularis), anterior insula, posterior inferior frontal sulcus, ventral precentral gyrus and sulcus	-42	16	20	18 576	5.04	<0.001
Left posterior superior temporal sulcus, middle temporal gyrus, middle occipital gyrus	-49	-70	10	10 480	4.19	<0.001
Left intraparietal sulcus and superior parietal lobule	-24	-59	49	6064	4.21	0.005
Voxel-based morphometry: correlation between tissue volume and accuracy on syntax task in PPA patients						
Entire left frontal lobe except for ventromedial regions, adjacent left parietal white matter, adjacent right superior frontal gyrus	-26	13	32	202 216	6.97	0.003

MNI coordinates for clusters are centres of mass.

responded more quickly. This significant correlation is important because it raises the possibility that the differences between brain regions modulated by syntactic processing as a function of accuracy might reflect poorer fitting of the parametric model in less accurate patients, whose mean response times tended to be longer. Therefore, the functional imaging analysis was repeated, but instead of using a stipulated event duration of 4 s in each participant, the event duration for each individual was set to their own mean reaction time (measured from the onset of the sentence, not the disambiguation point). In this ancillary analysis, the same three frontal, temporal and parietal regions that were reported in the primary analysis were again statistically significant, along with additional less extensive significant clusters of activation in the left supplementary motor area and the right inferior frontal gyrus. This analysis shows that the imaging findings described above are unlikely to represent an artefact of longer mean reaction times in patients who performed less accurately.

Next, performance was compared on canonical and non-canonical syntactic structures, the latter of which require more syntactic processing (Fig. 3B). Both patients with PPA and controls performed less accurately and more slowly on non-canonical conditions. The drop-off in accuracy was greater in patients with PPA ($26.8\% \pm 11.8\%$) than in controls ($14.5\% \pm 6.9\%$) [$t(69.13) = 5.68$, $P < 0.001$], which was expected, as structures involving more syntactic processing will be more susceptible to syntactic deficits. The extent of slowdown on non-canonical structures did not differ between patients with PPA (412 ± 282 ms) and controls (354 ± 145 ms) [$t(72.30) = 1.17$, $P = 0.25$]. There was no relationship between drop-off in accuracy and slowdown of reaction times in either patients with PPA ($r = -0.20$, $P = 0.16$) or controls ($r = -0.18$, $P = 0.41$).

However, there was a significant correlation between slowdown of reaction times on non-canonical conditions and overall accuracy in PPA ($r = 0.46$, $P < 0.001$) but not in controls ($r = -0.34$, $P = 0.10$) (Fig. 3C). Patients who slowed down more on non-canonical conditions performed more accurately overall. This is important because it suggests that the distribution of reaction times across trials is less principled in the patients whose syntax is more impaired. Whereas all controls, and most patients with PPA, took more time to respond on non-canonical trials, which require more syntactic processing, the most impaired patients may not have been sufficiently sensitive to grammatical structure to strategically devote more time to processing non-canonical structures.

Next, the distribution of trial-to-trial variability (i.e. the standard deviation of reaction times within an individual) and its relationship to overall accuracy was plotted (Fig. 3D). Trial-to-trial variability was greater in patients with PPA (806 ± 134 ms) than in controls (611 ± 106 ms) [$t(56.06) = 6.82$, $P < 0.001$]. Trial-to-trial variability was somewhat greater in patients who performed less accurately, however this correlation just escaped significance

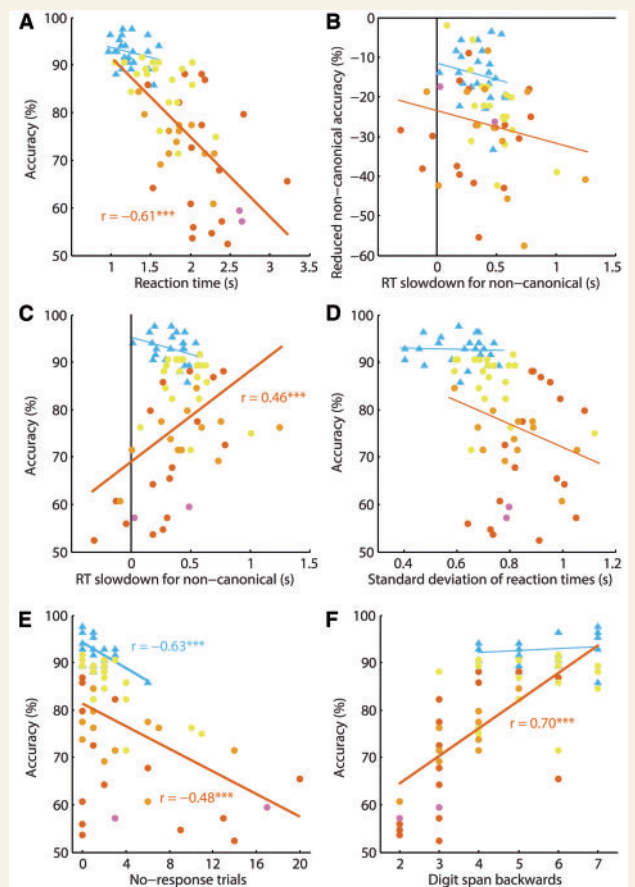


Figure 3 Relationships of accuracy and reaction times to each other and to other measures. (A) Correlation between reaction time and accuracy. (B) Correlation between slow down in reaction time for non-canonical sentences relative to canonical sentences, and decrease in accuracy for non-canonical sentences relative to canonical sentences. (C) Correlation between slow down in reaction time for non-canonical sentences relative to canonical sentences, and overall accuracy. (D) Correlation between variability in reaction times (standard deviation) and accuracy. (E) Correlation between number of no-response trials and accuracy. (F) Correlation between digit span backwards (a measure of verbal working memory) and accuracy. PPA variant diagnoses, and controls, are indicated by colour (Fig. 2). Models were fit separately for all patients with PPA, and for controls. RT = reaction time.

($r = -0.27$, $P = 0.052$). There was no correlation in controls ($r = -0.04$, $P = 0.86$). These findings show that the reduction in regions modulated by syntactic processing in more impaired patients cannot be attributed to a lack of variance in reaction times on which the analysis depends.

Then, the relationship between the total number of trials on which no response was provided, and overall accuracy, was plotted (Fig. 3E). There were more no-response trials in patients with PPA (3.7 ± 4.8) than in controls (1.1 ± 1.4) [$t(65.46) = 3.52$, $P = 0.001$]. There were significant negative correlations between number of no-response trials and accuracy in both patients with PPA ($r = -0.48$, $P < 0.001$) and in controls ($r = -0.63$, $P = 0.001$). Because

of the uneven distribution of these no-response trials, which were excluded from analysis, the functional imaging analysis was repeated, but instead of excluding no-response trials, they were included with a fixed nominal reaction time of 5 s. In this ancillary analysis, the same three frontal, temporal and parietal regions that were reported in the primary analysis were again statistically significant, along with additional less extensive significant clusters of activation in the left supplementary motor area, right inferior frontal gyrus and right intraparietal sulcus. This analysis shows that the imaging findings described above are unlikely to represent an artefact of no-response trials being excluded from analysis.

Finally, to investigate the possibility that the findings were attributable to differences in verbal working memory, which are known to be associated with variability in syntactic comprehension in neurodegenerative patients (Amici *et al.*, 2007), the relationship between digit span backwards and overall accuracy was plotted (Fig. 3F). Digit span backwards is a well-established measure of verbal working memory. Digit span backwards was shorter in patients with PPA (4.1 + 1.5) than in controls (5.6 + 1.2) [$t(53.12) = 4.53$, $P < 0.001$]. There was a significant correlation between digit span backwards and overall accuracy in patients with PPA ($r = 0.70$, $P < 0.001$) but not in controls ($r = 0.16$, $P = 0.47$). To determine whether the correlations between modulation and accuracy shown in Fig. 2A could be explained by verbal working memory deficits, digit span backwards was included as a covariate in each of these three activated regions. In each region, modulation by syntactic processing continued to predict overall accuracy after controlling for digit span backwards (frontal partial $r = 0.54$, $P < 0.001$; temporal partial $r = 0.41$, $P < 0.003$; parietal partial $r = 0.52$, $P = 0.006$). This shows that the extent of modulation by syntactic complexity was associated with overall accuracy on the syntactic comprehension task even after taking into account verbal working memory deficits, so the findings are not an artefact of differences in verbal working memory.

Impact of atrophy on functional imaging measures

Voxel-based morphometry showed that parenchymal volume loss throughout almost the entire left frontal lobe, and extending to the white matter underlying the parietal lobe, was associated with reduced accuracy on the syntactic processing task, with the strongest correlation observed in the left inferior frontal sulcus (Fig. 4A and Table 3).

To investigate the relationship between frontal atrophy and patterns of functional activation, a voxelwise correlation was computed between inferior frontal atrophy (in the region where $t > 4$ in the voxel-based morphometry analysis) and modulation of BOLD signal change by syntactic processing (Fig. 4B). This analysis showed that left frontal atrophy was predictive of reduced modulation of

signal change by syntactic processing in the same three left hemisphere regions that were shown above to be significantly associated with task performance. In other words, the greater the left frontal atrophy, the less these frontal, temporal and parietal regions were modulated by syntactic processing.

Could the correlations between modulation and accuracy shown in Fig. 2A be explained by atrophy in the frontal, temporal or parietal regions themselves? Parenchymal volume was positively correlated with functional modulation by syntactic processing in the frontal region ($r = 0.54$, $P < 0.001$) and the parietal region ($r = 0.48$, $P < 0.001$), and marginally so in the temporal region ($r = 0.28$, $P = 0.051$) (Fig. 4C, E and G). However, in each region, modulation by syntactic processing continued to predict accuracy after controlling for parenchymal volume (frontal partial $r = 0.39$, $P = 0.005$; temporal partial $r = 0.58$, $P < 0.001$; parietal partial $r = 0.44$, $P = 0.001$) (Fig. 4D, F and H). This shows that the extent of functional modulation by syntactic processing predicts accuracy above and beyond the contribution of atrophy in each region.

Finally, the relative contributions of atrophy and functional modulation by syntactic processing in all three key regions were investigated, using a stepwise regression procedure (backward, Bayesian information criterion, JMP version 12.0.1). The dependent variable was overall syntactic accuracy, and there were six independent variables, comprising atrophy and functional modulation measures from left frontal, temporal and parietal regions of interest. The stepwise regression procedure yielded a model explaining 53.9% of the variance, retaining three independent variables: parenchymal volume in the frontal region [$F(1,47) = 8.867$, $P = 0.005$], functional modulation in the frontal region [$F(1,47) = 3.827$, $P = 0.056$], and functional modulation in the temporal region [$F(1,47) = 4.661$, $P = 0.036$].

Discussion

The overall goal of this study was to determine whether syntactic deficits in PPA are related to damage and dysfunction of left frontal cortex, or to dysfunction of a broader syntactic network. We found that in a large, diverse group of individuals with PPA, the individual degree of syntactic comprehension impairment was predicted by left frontal atrophy, but also by functional disruption of a broader syntactic processing network, comprising left posterior frontal cortex, left posterior temporal cortex, and the left intraparietal sulcus and adjacent areas. These regions were modulated by syntactic processing in healthy controls and in patients with PPA with relatively spared syntax, but they were modulated to a lesser extent or not at all in patients with PPA with relatively impaired syntax. Our findings provide strong support for the idea that syntactic comprehension depends on a network of left-lateralized perisylvian regions (Dronkers *et al.*, 2004; Caplan *et al.*, 2007;

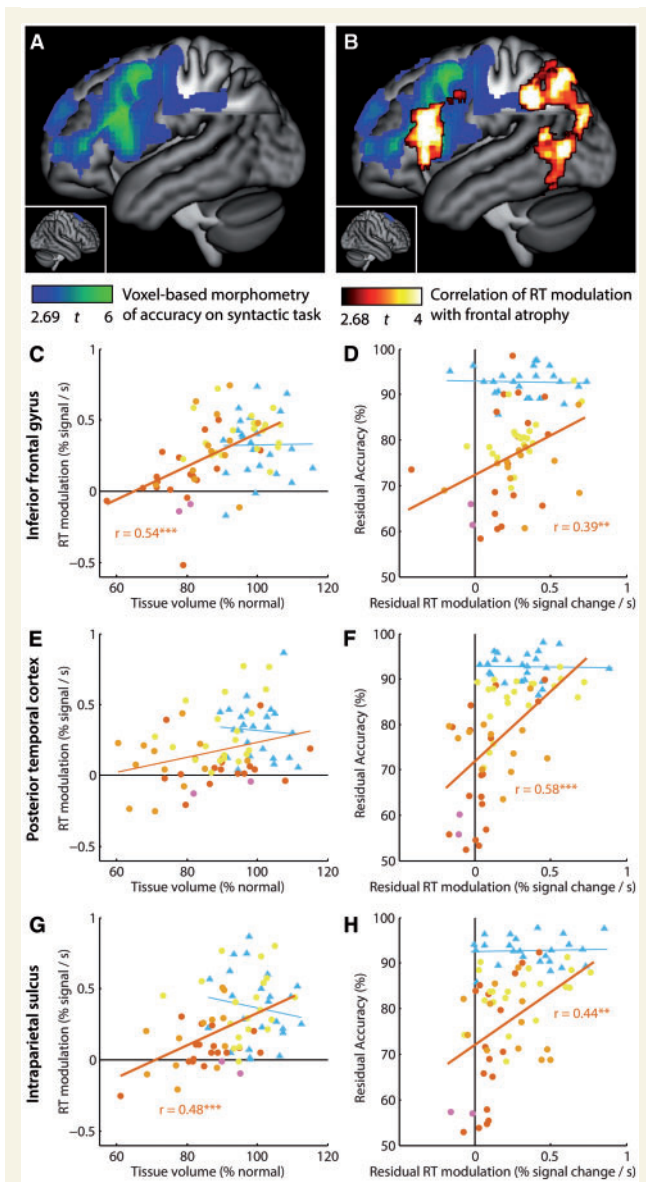


Figure 4 Cortical atrophy, functional measures, and syntactic processing. (A) Regions where parenchymal volume loss was associated with deficits on the syntactic task. (B) Shown in hot colours are regions where the modulation of BOLD signal by reaction time (proxy for syntactic processing) was correlated with left frontal atrophy. Blue-green colours as in A. (C, E and G) Correlations between tissue volume and modulation of signal by reaction time in the three activated regions from Fig. 2. (D, F and H) Partial correlations between the signal modulations and accuracy, after accounting for tissue volume, in these same regions. PPA variant diagnoses, and controls, are indicated by colour (Fig. 2). Models were fit separately for all patients with PPA, and for controls. RT = reaction time.

that took place on each trial. We took this approach because of the dramatic differences between individuals in performance on the syntactic comprehension task, which would make it challenging to interpret straightforward contrasts between conditions defined based on syntactic structure (i.e. length, syntactic complexity), when accuracy and reaction times differed between conditions in ways that were systematically related to degree of syntactic impairment.

Reaction time is widely used in cognitive psychology as a key outcome variable from which processing differences between conditions or groups can be inferred. In functional imaging, it has been established that haemodynamic responses increase with duration of stimulation (Boynton *et al.*, 1996) and with time on task (Honey *et al.*, 2000; Binder *et al.*, 2005), yet in cognitive neuroscience research, reaction time is more often treated as a potential confound (Binder *et al.*, 2005; Yarkoni *et al.*, 2009; Graves *et al.*, 2010; Crittenden and Duncan, 2014) than as a potential source of information (Taylor *et al.*, 2014). Yet the regions that are modulated by stimulus duration or time on task are specific: not all regions are modulated, only those involved in perceptual, cognitive or other processes related to the task at hand. For instance, reaction time was shown to be correlated with haemodynamic signal in the amygdala in an implicit association test in which reaction time variability reflected differences in emotional processing load (Phelps *et al.*, 2000), and different language regions have been shown to correlate with reaction times depending on which language domain(s) are implicated in the task (Wilson *et al.*, 2009b; Taylor *et al.*, 2013). Accordingly, examining brain regions where BOLD signal is correlated with reaction time is a potentially powerful method of identifying regions that are differentially recruited as a function of extent of task-related processing, which can then be inferred to be important for task-related processes (Taylor *et al.*, 2014).

The regions identified in this way may be specifically linguistic in their roles, or they may be important for other cognitive processes that are involved in the syntactic processing task. In particular, a set of brain regions have been shown to be implicated a wide variety of goal-directed behaviours; we refer to these as ‘multiple demand’ regions (Duncan and Owen, 2000; Duncan, 2010; Fedorenko *et al.*, 2013). The multiple demand areas are bilateral and include regions in prefrontal cortex, in particular the inferior frontal sulcus, anterior insula and frontal operculum, areas in and around the intraparietal sulcus, and the pre-supplementary motor area and dorsal anterior cingulate cortex (Duncan, 2010). Language comprehension involves an interplay between regions that are specifically important for linguistic processing, and multiple demand regions (Fedorenko *et al.*, 2011, 2012, 2013; Fedorenko, 2014; Fedorenko and Thompson-Schill, 2014).

Of the regions that we observed to be functionally disrupted in patients with impaired syntax, the left posterior superior temporal region is unquestionably a language

Friederici, 2012; Bornkessel-Schlesewsky and Schlesewsky, 2013; Fedorenko and Thompson-Schill, 2014; Blank *et al.*, 2016).

In this study, variability in trial-by-trial reaction times was used as a proxy for the extent of syntactic processing

region, not a multiple demand region. The area around the left intraparietal sulcus is part of the multiple demand network; this region is often implicated in behaviours requiring piecemeal, serial, processing (Owen *et al.*, 2005; Wilson *et al.*, 2009a), which would be consistent with its recruitment for syntactic processing. Left inferior frontal cortex includes language-related as well as multiple demand regions (Fedorenko *et al.*, 2012). The language-related region is localized to the lateral pars opercularis and triangularis, whereas the inferior frontal sulcus and anterior insula have more domain-general roles. All of these regions were functionally disrupted in patients with impaired syntax. It is noteworthy that while the multiple demand network is bilateral (Duncan, 2010), we observed significant functional disruption only of left hemisphere regions. This suggests that the multiple demand network is not monolithic and that left-lateralized components play a relatively greater role in language.

In future research, it would be informative to have patients perform a non-linguistic task in addition to a syntactic task. We would hypothesize that language-specific regions (i.e. the left posterior superior temporal region and the left lateral pars opercularis and triangularis) would be modulated by reaction time only on the linguistic task, whereas multiple demand regions (i.e. the intraparietal sulcus, inferior frontal sulcus, and anterior insula) would be modulated by reaction time on both linguistic and non-linguistic tasks.

Is the network dysfunction we observed a direct consequence of structural damage to left frontal cortex, or is PPA in fact characterized by inherent functional abnormalities in a wider network of regions that may or may not be atrophic? While our study cannot definitely answer this important question, the former possibility finds support in the correlation between frontal atrophy and voxelwise modulation by syntactic processing (Fig. 4B), which yielded a very similar map to the correlation between modulation by syntactic processing and accuracy (Fig. 2A). On the other hand, modulation of the left posterior temporal region by syntactic processing made a significant contribution to predicting accuracy on the comprehension task even when left frontal parenchymal volume was included in the model, suggesting that left frontal atrophy cannot fully account for syntactic deficits. Furthermore, stroke patients with damage confined to the left inferior frontal lobe do not show long term syntactic deficits (Mohr, 1976; Baldo and Dronkers, 2006), which suggests that structural damage alone to this region is not sufficient to lead to the degree of impaired syntactic processing apparent in some patients with PPA. Taken together, these arguments suggest that while the left frontal atrophy and wider network dysfunction probably reflect a single underlying disease process, it is unlikely that the network dysfunction follows directly and inevitably from the structural damage to the left frontal lobe.

In this study, we did not separate patients with PPA according to which of the three recognized clinical variants

they were diagnosed with (Gorno-Tempini *et al.*, 2004, 2011). We did indicate variant diagnoses in all scatter plots by means of colour coding data points, but this information did not enter into any of the analyses. We took this approach because the focus of our study was to understand the neural correlates of variability in syntactic deficits, and variability in this domain occurs within variants as well as across variants (Thompson *et al.*, 1997, 2012; Patterson *et al.*, 2006; Bright *et al.*, 2008; Wilson *et al.*, 2010b, 2011, 2012). Variability within each variant may reflect stage of disease progression as well as different underlying distributions of cortical damage or differences in pathological substrates.

Conclusion

The findings of this study show that syntactic comprehension deficits in PPA are associated not only with atrophy of left frontal cortex, but also with dysfunction in a wider syntactic processing network comprising left posterior frontal cortex, left posterior temporal cortex, and the left intraparietal sulcus and adjacent regions.

Acknowledgements

We thank Nina Dronkers for helpful discussions, Jenny Ogar for patient testing, Laura Calverley for drawing the stimulus pictures, Max Besbris, Paul Keselman, Lara Stables and Maria Luisa Mandelli for assistance with functional imaging, Julia Fisher for statistical consulting, Matthew Growdon, Jung Jang, Michael Neylan and Henry Rodriguez for administrative assistance, all of the members of the UCSF Memory and Aging Center who contributed to patient evaluation and care, and the patients, caregivers and volunteers for their participation in our research.

Funding

This research was supported in part by the National Institutes of Health (NIDCD R03 DC010878, NIDCD R01 DC013270, NINDS R01 NS050915, NIA P50 AG023501, NIA P01 AG019724).

References

- Amici S, Brambati SM, Wilkins DP, Ogar J, Dronkers NL, Miller BL, *et al.* Anatomical correlates of sentence comprehension and verbal working memory in neurodegenerative disease. *J Neurosci* 2007; 27: 6282–90.
- Ashburner J. A fast diffeomorphic image registration algorithm. *Neuroimage* 2007; 38: 95–113.
- Ashburner J, Friston KJ. Unified segmentation. *Neuroimage* 2005; 26: 839–51.

- Baldo JV, Dronkers NF. The role of inferior parietal and inferior frontal cortex in working memory. *Neuropsychology* 2006; 20: 529–38.
- Beckmann CF, Smith SM. Probabilistic independent component analysis for functional magnetic resonance imaging. *IEEE Trans Med Imaging* 2004; 23: 137–52.
- Binder JR, Medler DA, Desai R, Conant LL, Liebenthal E. Some neurophysiological constraints on models of word naming. *Neuroimage* 2005; 27: 677–93.
- Blank I, Balewski Z, Mahowald K, Fedorenko E. Syntactic processing is distributed across the language system. *Neuroimage* 2016; 127: 307–23.
- Bornkessel-Schlesewsky I, Schlewsky M. Reconciling time, space and function: a new dorsal-ventral stream model of sentence comprehension. *Brain Lang* 2013; 125: 60–76.
- Boynton GM, Engel SA, Glover GH, Heeger DJ. Linear systems analysis of functional magnetic resonance imaging in human V1. *J Neurosci* 1996; 16: 4207–21.
- Bright P, Moss HE, Stamatakis EA, Tyler LK. Longitudinal studies of semantic dementia: the relationship between structural and functional changes over time. *Neuropsychologia* 2008; 46: 2177–88.
- Caplan D, Hildebrandt N, Makris N. Location of lesions in stroke patients with deficits in syntactic processing in sentence comprehension. *Brain* 1996; 119: 933–49.
- Caplan D, Michaud J, Hufford R, Makris N. Deficit-lesion correlations in syntactic comprehension in aphasia. *Brain Lang* 2015; 152: 14–27.
- Caplan D, Waters G, Kennedy D, Alpert N, Makris N, Dede G, et al. A study of syntactic processing in aphasia II: neurological aspects. *Brain Lang* 2007; 101: 151–77.
- Charles D, Olm C, Powers J, Ash S, Irwin DJ, McMillan CT, et al. Grammatical comprehension deficits in non-fluent/agrammatic primary progressive aphasia. *J Neurol Neurosurg Psychiatr* 2014; 85: 249–56.
- Cooke A, DeVita C, Gee J, Alsop D, Detre J, Chen W, Grossman M. Neural basis for sentence comprehension deficits in frontotemporal dementia. *Brain Lang* 2003; 85: 211–21.
- Cox RW. AFNI: software for analysis and visualization of functional magnetic resonance neuroimages. *Comput Biomed Res* 1996; 29: 162–73.
- Crittenden BM, Duncan J. Task difficulty manipulation reveals multiple demand activity but no frontal lobe hierarchy. *Cereb Cortex* 2014; 24: 532–40.
- DeLeon J, Gesierich B, Besbris M, Ogar J, Henry ML, Miller BL, et al. Elicitation of specific syntactic structures in primary progressive aphasia. *Brain Lang* 2012; 123: 183–90.
- Dronkers NF, Wilkins DP, Van Valin RD Jr, Redfern BB, Jaeger JJ. Lesion analysis of the brain areas involved in language comprehension. *Cognition* 2004; 92: 145–77.
- Duncan J. The multiple-demand (MD) system of the primate brain: mental programs for intelligent behaviour. *Trends Cogn Sci* 2010; 14: 172–79.
- Duncan J, Owen AM. Common regions of the human frontal lobe recruited by diverse cognitive demands. *Trends Neurosci* 2000; 23: 475–83.
- Fedorenko E. The role of domain-general cognitive control in language comprehension. *Front Psychol* 2014; 5: 335.
- Fedorenko E, Behr MK, Kanwisher N. Functional specificity for high-level linguistic processing in the human brain. *Proc Natl Acad Sci USA* 2011; 108: 16428–33.
- Fedorenko E, Duncan J, Kanwisher N. Language-selective and domain-general regions lie side by side within Broca's area. *Curr Biol* 2012; 22: 2059–62.
- Fedorenko E, Duncan J, Kanwisher N. Broad domain generality in focal regions of frontal and parietal cortex. *Proc Natl Acad Sci USA* 2013; 110: 16616–21.
- Fedorenko E, Thompson-Schill SL. Reworking the language network. *Trends Cogn Sci* 2014; 18: 120–6.
- Folstein MF, Folstein SE, McHugh PR. "Mini-mental state": a practical method for grading the cognitive state of patients for the clinician. *J Psychiatr Res* 1975; 12: 189–98.
- Friederici AD. The cortical language circuit: from auditory perception to sentence comprehension. *Trends Cogn Sci* 2012; 16: 262–8.
- Friederici AD, Makuuchi M, Bahlmann J. The role of the posterior superior temporal cortex in sentence comprehension. *Neuroreport* 2009; 20: 563–8.
- Gorno-Tempini ML, Dronkers NF, Rankin KP, Ogar JM, Phengrasamy L, Rosen HJ, et al. Cognition and anatomy in three variants of primary progressive aphasia. *Ann Neurol* 2004; 55: 335–46.
- Gorno-Tempini ML, Hillis AE, Weintraub S, Kertesz A, Mendez M, Cappa SF, et al. Classification of primary progressive aphasia and its variants. *Neurology* 2011; 76: 1006–14.
- Graves WW, Desai R, Humphries C, Seidenberg MS, Binder JR. Neural systems for reading aloud: a multiparametric approach. *Cereb Cortex* 2010; 20: 1799–815.
- Grossman M, Rhee J. Cognitive resources during sentence processing in Alzheimer's disease. *Neuropsychologia* 2001; 39: 1419–31.
- Gunawardena D, Ash S, McMillan C, Avants B, Gee J, Grossman M. Why are patients with progressive nonfluent aphasia nonfluent? *Neurology* 2010; 75: 588–94.
- Hodges JR, Patterson K. Nonfluent progressive aphasia and semantic dementia: a comparative neuropsychological study. *J Int Neuropsychol Soc* 1996; 2: 511–24.
- Honey GD, Bullmore ET, Sharma T. Prolonged reaction time to a verbal working memory task predicts increased power of posterior parietal cortical activation. *Neuroimage* 2000; 12: 495–503.
- Kelly RE Jr, Alexopoulos GS, Wang Z, Gunning FM, Murphy CF, Morimoto SS, et al. Visual inspection of independent components: defining a procedure for artifact removal from fMRI data. *J Neurosci Methods* 2010; 189: 233–45.
- Kramer JH, Jurik J, Sha SJ, Rankin KP, Rosen HJ, Johnson JK, et al. Distinctive neuropsychological patterns in frontotemporal dementia, semantic dementia, and Alzheimer disease. *Cogn Behav Neurol* 2003; 16: 211–8.
- Leff AP, Schofield TM, Crinion JT, Seghier ML, Grogan A, Green DW, et al. The left superior temporal gyrus is a shared substrate for auditory short-term memory and speech comprehension: evidence from 210 patients with stroke. *Brain* 2009; 132: 3401–10.
- Magnusdottir S, Fillmore P, den Ouden DB, Hjaltason H, Rorden C, Kjartansson O, et al. Damage to left anterior temporal cortex predicts impairment of complex syntactic processing: a lesion-symptom mapping study. *Hum Brain Mapp* 2013; 34: 2715–23.
- Mesulam M-M, Rogalski EJ, Wieneke C, Hurley RS, Geula C, Bigio EH, et al. Primary progressive aphasia and the evolving neurology of the language network. *Nat Rev Neurol* 2014; 10: 554–69.
- Meteyard L, Patterson K. The relation between content and structure in language production: an analysis of speech errors in semantic dementia. *Brain Lang* 2009; 110: 121–34.
- Mohr JP. Broca's area and Broca's aphasia. In: Whitaker H, Whitaker H, editors. *Studies in neurolinguistics*. New York: Academic Press; 1976. p. 201–33.
- Newhart M, Trupe LA, Gomez Y, Cloutman L, Molitoris JJ, Davis C, et al. Asyntactic comprehension, working memory, and acute ischemia in Broca's area versus angular gyrus. *Cortex* 2012; 48: 1288–97.
- Owen AM, McMillan KM, Laird AR, Bullmore E. N-back working memory paradigm: a meta-analysis of normative functional neuroimaging studies. *Hum Brain Mapp* 2005; 25: 46–59.
- Pallier C, Devauchelle AD, Dehaene S. Cortical representation of the constituent structure of sentences. *Proc Natl Acad Sci USA* 2011; 108: 2522–7.
- Patterson K, Graham N, Ralph MAL, Hodges J. Progressive non-fluent aphasia is not a progressive form of non-fluent (post-stroke) aphasia. *Aphasiology* 2006; 20: 1018–34.

- Pelle JE, Troiani V, Gee J, Moore P, McMillan C, Vesely L, et al. Sentence comprehension and voxel-based morphometry in progressive nonfluent aphasia, semantic dementia, and nonaphasic frontotemporal dementia. *J Neurolinguistics* 2008; 21: 418–32.
- Phelps EA, O'Connor KJ, Cunningham WA, Funayama ES, Gatenby JC, Gore JC, et al. Performance on indirect measures of race evaluation predicts amygdala activation. *J Cogn Neurosci* 2000; 12: 729–38.
- Rogalski E, Cobia D, Harrison TM, Wieneke C, Thompson CK, Weintraub S, et al. Anatomy of language impairments in primary progressive aphasia. *J Neurosci* 2011; 31: 3344–50.
- Sapolsky D, Bakkour A, Negreira A, Nalipinski P, Weintraub S, Mesulam MM, et al. Cortical neuroanatomic correlates of symptom severity in primary progressive aphasia. *Neurology* 2010; 75: 358–66.
- Snijders TM, Vosse T, Kempen G, Van Berkum JJ, Petersson KM, Hagoort P. Retrieval and unification of syntactic structure in sentence comprehension: an fMRI study using word-category ambiguity. *Cereb Cortex* 2009; 19: 1493–503.
- Stromswold K, Caplan D, Alpert N, Rauch S. Localization of syntactic comprehension by positron emission tomography. *Brain Lang* 1996; 52: 452–73.
- Taylor JSH, Rastle K, Davis MH. Can cognitive models explain brain activation during word and pseudoword reading? A meta-analysis of 36 neuroimaging studies. *Psychol Bull* 2013; 139: 766–91.
- Taylor JSH, Rastle K, Davis MH. Interpreting response time effects in functional imaging studies. *Neuroimage* 2014; 99: 419–33.
- Teichmann M, Rosso C, Martini J-B, Bloch I, Brugieres P, Duffau H, et al. A cortical-subcortical syntax pathway linking Broca's area and the striatum. *Hum Brain Mapp* 2015; 36: 2270–83.
- Thompson CK, Ballard KJ, Tait ME, Weintraub S, Mesulam M-M. Patterns of language decline in non-fluent primary progressive aphasia. *Aphasiology* 1997; 11: 297–321.
- Thompson CK, Cho S, Hsu C-J, Wieneke C, Rademaker A, Weitner BB, et al. Dissociations between fluency and agrammatism in primary progressive aphasia. *Aphasiology* 2012; 26: 20–43.
- Thothathiri M, Kimberg DY, Schwartz MF. The neural basis of reversible sentence comprehension: evidence from voxel-based lesion symptom mapping in aphasia. *J Cogn Neurosci* 2012; 24: 212–22.
- Warrington EK. The selective impairment of semantic memory. *Q J Exp Psychol* 1975; 27: 635–57.
- Wilson SM, Brambati SM, Henry RG, Handwerker DA, Agosta F, Miller BL, et al. The neural basis of surface dyslexia in semantic dementia. *Brain* 2009a; 132: 71–86.
- Wilson SM, DeMarco AT, Henry ML, Gesierich B, Babiak M, Mandelli ML, et al. What role does the anterior temporal lobe play in sentence-level processing? Neural correlates of syntactic processing in semantic variant primary progressive aphasia. *J Cogn Neurosci* 2014; 26: 970–85.
- Wilson SM, Dronkers NF, Ogar JM, Jang J, Growdon ME, Agosta F, et al. Neural correlates of syntactic processing in the nonfluent variant of primary progressive aphasia. *J Neurosci* 2010a; 30: 16845–54.
- Wilson SM, Galantucci S, Tartaglia MC, Gorno-Tempini ML. The neural basis of syntactic deficits in primary progressive aphasia. *Brain Lang* 2012; 122: 190–8.
- Wilson SM, Galantucci S, Tartaglia MC, Rising K, Patterson DK, Henry ML, et al. Syntactic processing depends on dorsal language tracts. *Neuron* 2011; 72: 397–403.
- Wilson SM, Henry ML, Besbris M, Ogar JM, Dronkers NF, Jarrold W, et al. Connected speech production in three variants of primary progressive aphasia. *Brain* 2010b; 133: 2069–88.
- Wilson SM, Isenberg AL, Hickok G. Neural correlates of word production stages delineated by parametric modulation of psycholinguistic variables. *Hum Brain Mapp* 2009b; 30: 3596–608.
- Worsley KJ, Liao CH, Aston J, Petre V, Duncan GH, Morales F, et al. A general statistical analysis for fMRI data. *Neuroimage* 2002; 15: 1–15.
- Worsley KJ, Marrett S, Neelin P, Vandal AC, Friston KJ, Evans AC, et al. A unified statistical approach for determining significant signals in images of cerebral activation. *Hum Brain Mapp* 1996; 4: 58–73.
- Yarkoni T, Barch DM, Gray JR, Conturo TE, Braver TS. BOLD correlates of trial-by-trial reaction time variability in gray and white matter: a multi-study fMRI analysis. *PLoS One* 2009; 4: e4257.