

UC Irvine

UC Irvine Previously Published Works

Title

2477: Biofilms in wounds: Detection, individualizing treatment and monitoring response to therapy (Abstract)

Permalink

<https://escholarship.org/uc/item/9qk979zr>

Journal

Journal of Clinical and Translational Science, 1(S1)

ISSN

2059-8661

Authors

Wilder-Smith, Petra

Ajdaharian, Janet

Golabgir Anbarani, Afarin

et al.

Publication Date

2017-09-01

DOI

10.1017/cts.2017.233

Copyright Information

This work is made available under the terms of a Creative Commons Attribution License, available at <https://creativecommons.org/licenses/by/4.0/>

Peer reviewed



Published in final edited form as:

Lasers Surg Med. 2014 September ; 46(7): 546–552. doi:10.1002/lsm.22265.

Multimodality Imaging of the Effects of a Novel Dentifrice on Oral Biofilm

Janet Ajdaharian, BA, BS¹, Mohammad Dadkhah, BS¹, Sara Sabokpey, BS¹, John Biren-Fetz, BS¹, Na Eun Chung, BS¹, Cherie Wink, BS, RDH^{1,2}, and Petra Wilder-Smith, DDS, PhD^{1,*}

¹Beckman Laser Institute, University of California, Irvine, California 92612

²School of Dental Hygiene, Concorde Career College, Garden Grove, California 92840

Abstract

Objective—Oral biofilm formation and progression on the surface of the tooth can lead to advanced oral disease such as gingivitis. The purpose of this randomized, controlled, double-blinded study was to evaluate the effects of a novel dental gel on oral plaque biofilm using multimodal imaging techniques.

Materials and Methods—Twenty-five subjects with moderate gingival inflammation (Löe and Silness Gingival Index = 2) and pocket depths <4 were randomly assigned to brush twice daily for 21 days with the test or the control dental gel. In vivo multimodality *in situ* imaging was performed over a 3-week period using *in vivo* Optical Coherence Tomography (OCT) and Non-Linear Optical microscopy (NLOM). Plaque levels, gingival inflammation and gingival bleeding were also charted on days 0, 7, 14, and 21 using standard clinical indices.

Results—After 3 weeks, OCT and NLOM images showed a macroscopic break-up of the plaque layer and smaller, fragmented residual deposits in the test group with no apparent changes in the pellicle. Biofilm was also reduced in the control group, but to a lesser degree with regard to thickness, continuity and surface area. Paralleling these imaging results, clinical indices were significantly improved in both groups ($P < 0.05$) and significantly lower in the test group ($P < 0.05$).

Conclusion—Both dental gels reduced oral biofilm with the test gel showing greater efficacy ($P < 0.05$) as determined by clinical and imaging parameters.

Keywords

plaque; gingival inflammation; dental gel; nonlinear optical microscopy; optical coherence tomography; biofilm

© 2014 Wiley Periodicals, Inc.

*Correspondence to: Petra Wilder-Smith, DDS, PhD, Associate Professor and Director of Dentistry, Beckman Laser Institute, University of California at Irvine, 1002 Health Sciences Rd East, Irvine, CA 92612. pwsmith@uci.edu.

Conflict of Interest Disclosures: All authors have completed and submitted the ICMJE Form for Disclosure of Potential Conflicts of Interest and have disclosed the following: We confirm that there are no conflicts of interest for any of the authors of this article.

INTRODUCTION

A recent publication evaluating data from the National Health and Nutrition Examination Survey (NHANES) found that 47% of adults in the US suffer from periodontitis, the progressed disease of gingivitis [1]. The initiation of gingival inflammation and subsequent destruction of periodontal tissues has been found to originate from oral biofilm [2]. Biofilm consists of a group of microorganisms embedded in an extracellular polysaccharide matrix that are attached to the tooth surface [3] and are more generally known as plaque. Biofilms, which are tightly adherent to oral surfaces, are a major cause of progressive periodontal diseases [4]. The most common method of biofilm control is through the use of dentifrices, usually in conjunction with physical tooth brushing [5]. Engaging in effective oral hygiene practices can eliminate microbial plaque accumulation and eventually lead to the reduction of gingival inflammation [6]. On the contrary, deviation from continuous plaque control results in the re-emergence of inflammation [7].

Mechanical plaque control is not adequately practiced by most individuals, despite its essential role in the prevention of gingivitis and periodontitis [8–10]. Professional cleaning is only accessible to a small fraction of the world's population, therefore, improvements in the approach to plaque control are essential to prevent and control extensive periodontal disease. Accordingly, a multitude of novel dental gel formulations are being explored for their ability to remove oral biofilm and to prevent its reaccumulation [9,11,12].

In addition to primary interventions such as tooth brushing, a wide range of adjunct measures have been investigated for their ability to control oral plaque. Mouth rinses that contain chlorhexidine preparations can be beneficial for plaque control; however, their side effects prevent long-term usage [13]. Dentifrices containing triclosan copolymer can improve oral biofilm accumulation; however, in some studies exceptional short-term benefits were counteracted by lack of any lasting benefits [14]. Moreover, there is a continuing discussion about the potentially undesirable effects of long-term triclosan usage that include allergic sensitization [15], endocrine function disruption [16], and resistance to antibiotics [17].

Cations such as calcium and iron, which are bound by activated edathamil, are essential to biofilm formation and microbial growth. The metal-binding activated edathamil has the capability to inhibit the establishment of oral biofilm by disrupting surface adherence through interference with calcium and iron-binding processes [18]. The dental gel investigated in this study contains a 2.6% proprietary formulation of activated edathamil combined with the carrier and permeability enhancer methyl sulfonyl methane (MSM). The formulation combines Generally Regarded as Safe (GRAS) and natural ingredients as defined by the FDA. The test dentifrice is a commercially available OTC dental gel.

Several optical imaging modalities offer the opportunity for noncontact *in situ* surface and subsurface characterization of the oral cavity.

- A. **Optical Coherence Tomography (OCT)** is a noninvasive, high-resolution optical imaging modality that uses near-infrared light reflected from an object to provide sub-surface (1.5–2.5mm) images without ionizing radiation [19]. OCT imaging

allows real-time video rate imaging speed, simultaneous OCT and CCD imaging channels, 3D volumetric imaging and surface profiling capability. The imaging system has approximately 8–15 μm depth and 20 μm lateral resolution; penetration depth approximates 1.5–2mm.

- B. 3-D *in vivo* Nonlinear Optical Microscopy imaging (NLOM) OCT can be combined with *in vivo* NLOM generating high-resolution imaging of specific tissue components and fluorescence using many wavelengths of light [20,21]. Using a custom-built imaging probe attached to a tabletop imaging system we are able to image undisturbed biofilm at high-resolution.

The goal of this randomized, controlled, double-blinded study was to investigate *in vivo* the effects of a novel dentifrice on dental biofilm and gingival health through Optical Coherence Tomography (OCT) and Non-Linear Optical Microscopy (NLOM) as well as conventional clinical indices. Effects on biofilm were measured using OCT, NLOM, and the Plaque Index (Turesky Modification of Quigley-Hein Index) (P.I.). Gingival health was quantified using the conventional gold standards, the Gingival Index (Löe and Silness) (G.I.), and the marginal Sulcus Bleeding Index (mSBI).

MATERIALS AND METHODS

This project was performed in full compliance with University of California at Irvine IRB-approved protocol #2002–2805. Written informed consent was obtained from all participants in this study. Subjects were recruited by means of IRB-approved advertisements, flyers, notices, and media. In addition, the study was posted on clinicaltrials.gov and the UCI student health center.

Subjects

Twenty-five subjects, who were all students at UCI, ranging in age from 19 to 31 years old (mean age of 23 years, 13 female, 12 male) with mild to moderate gingival inflammation (Löe and Silness Gingival Index ≥ 2) [22,23] and pocket depths ≥ 4 were enrolled in this prospective, randomized, controlled, double-blinded study. Subjects were recruited only if they fulfilled the inclusion and exclusion criteria cited above. The volunteer patients also had to have undergone dental prophylaxis within a period of 6–10 weeks before study enrollment, be nonsmokers, not pregnant, nonlactating and in a state of good general health.

Clinical Protocol

No professional dental cleaning was performed immediately before or during the trial in order to avoid the influence this would have on the data gathered and to sustain the type of dental gel used as the only variable. Subjects were randomly assigned to brush twice daily for 21 days with either the test dental gel (2.6% Livionex[®] Dental Gel, Los Gatos, CA), or the control gel (Colgate Total[®], Colgate-Palmolive, Piscataway NJ). A standard Oral B ProFlex[®] toothbrush was provided to each volunteer and subjects were trained in standard sulcular brushing technique. Subjects brushed their teeth 2 hours prior to each visit and refrained from eating from that time onwards until after their visit. Noncontact *in vivo* imaging was performed on Days 0 and 21 prior to any probing of the oral cavity to obtain

low- and high-resolution surface and subsurface images of the dental plaque. Optical Coherence Tomography (OCT) imaging was performed for all subjects; three subjects were randomly selected from each group for 3-D *in vivo* Non-Linear Optical Microscopy (NLOM) imaging. Plaque levels (Turesky Modification of Quigley-Hein Index) [24] (P.I.), gingival inflammation (Löe and Silness Gingival Index) [23] (G.I.), and marginal Sulcus Bleeding Index (mSBI) [25] were recorded. A standardized pressure sensitive probe (Florida Probe) with 20 g probing force was used to measure probing depth. No other clinical data were recorded per UCI IRB# 2002–2805.

A single blinded, precalibrated periodontist with more than 20 years of clinical experience assessed the condition of each patient, recording all three clinical indices: Plaque Index, Gingival Index, and marginal Sulcus Bleeding Index. The clinical data were collected with the subject in a dental chair, under conventional dental office lighting. He was precalibrated by charting all three clinical indices used in this study in 25 patients not associated with this study until his scores were at >92% agreement with those charted by two other experienced periodontists.

Imaging

The following standardized locations were imaged on days 0 and 21: 1mm apical to the gingival margin at the mid-buccal point on the (a) upper right central incisor, (b) upper left first molar, (c) lower left central incisor, and (d) lower right first molar. All imaging was performed on natural, unrestored tooth surfaces. A flexible imaging probe covered with a disposable sterile sheath was used in noncontact mode to acquire the images. This approach was previously developed and validated in *ex vivo* studies [20].

OCT measurements were performed using the commercially available Niris[®] OCT console and imaging probe, (Imalux Corporation, Cleveland, OH), which allows realtime video rate imaging speed, simultaneous OCT and CCD imaging channels, 3D volumetric imaging and surface profiling capability. The imaging system has approximately 8–15 μm depth and 20 μm lateral resolution; penetration depth approximates 1.5–2 μm . The imaging location and angle were standardized to ensure accurate colocalization at subsequent imaging events. NLOM of the dental biofilm was performed using a custom-built imaging probe attached to a tabletop imaging system.

Saliva was collected from each subject at the beginning of each visit by simple expectoration into a sterile collection tube. Plaque Test (Ivoclar Vivadent Inc., Amherst, NY) and Coolblue (Coolblue[®], Pfizer, New York, NY) dyes were used as optical contrast agents during fluorescence imaging with NLOM. Each disclosing agent was mixed with saliva at a 1:100 volume ratio and applied using an eye-dropper from 2mm above the tooth surface to avoid any possible disturbance of the biofilm layer.

RESULTS

Subjects

The study population consisted of student volunteers at UCI. As the required levels of gingival inflammation and oral hygiene were moderate, recruitment was easily completed.

Imaging Data

Representative *in vivo* OCT images from one subject in each group are shown in Figure 1. At study outset, a thick, continuous layer of plaque up to 3 mm in depth covers the tooth surface and gingival margin in both subjects (Fig. 1A and B on Day 0). Extending throughout the entire visible gingival pocket, the interface between the plaque and underlying dental structures appears seamless throughout the baseline images. Tooth enamel and dentin are visible. After 3 weeks of control gel use, considerable reduction in plaque presence is apparent vs. Day 0 (Fig. 1A RHS). Residual, somewhat fragmented biofilm is visible within the gingival pocket while the tooth and gingival surfaces appear free of biofilm. In Figure 1B extensive elimination of surface biofilm is also apparent after 3 weeks of test gel usage. Again, tooth and gingival surfaces appear free of plaque. A thin patch of residual, less dense and more loosely connected biofilm remains visible in the gingival pocket. The enamel appears wider in this image because an oblique optical section was used to reveal the small deposit of biofilm.

Higher resolution NLOM images acquired at the gingival margin of upper left central incisors are shown in Figure 2. In a 3-D reconstructed top view image acquired from a subject after 3 weeks of control gel usage (Fig. 2A, top), the blue signal from the tooth surface shows horseshoe-shaped enamel rods. An overlying pink signal originating from the salivary pellicle is visible and a superimposed red signal from bacterial plaque is apparent in a fairly uniform, but patchy distribution across the entire sample area. A vertical optical section of the upper 3-D image confirms the presence of thin but continuous bacterial plaque and underlying pellicle on the tooth surface (Fig. 2A, right). Figure 2B depicts images from a subject acquired after 3 weeks of test dental gel use. In the left image, a 3-D reconstructed top view clearly shows the blue signal from the enamel (Fig. 2B, left). The pink signal from the pellicle is again visible, and considerably less covered by the red signal emanating from bacterial plaque than in Figure 2A. This finding is confirmed by a vertical optical section of Fig. 2B, left as shown in (Fig. 2B, right), showing unaltered pellicle but fragmented and thinner bacterial plaque on the enamel surface.

Clinical Data

Data are summarized in Figure 3. In summary, clinical indices at study outset were comparable between the control and test group. Over the next 21 days Plaque Index, marginal Sulcus Bleeding Index and Gingival Index diminished progressively, showing a significant improvement in each group at Day 21 versus Day 0 ($P<0.05$). Overall, the test group showed significantly lower values for all indices vs. the control group at the end of the 21-day study ($P<0.05$).

DISCUSSION

At study outset, all subjects manifested a moderate level of plaque and gingival inflammation based on the study recruitment exclusion and inclusion criteria. On Day 21 (study conclusion), both treatment groups demonstrated a substantial decrease in plaque levels and gingival inflammation as evidenced by the conventional clinical indices for plaque and gingival health. This observation was not surprising. Initially, the subjects

involved in this study demonstrated poor oral hygiene, and the rapid improvement in the oral health may be due to motivation by the prospect of weekly oral exams, in addition to the knowledge that they were enrolled in a study to identify the effects of a novel dental gel. With the exception of initial poor oral hygiene, these subjects were young and in excellent general health. Over the 21-day study period, their oral health improved quickly and markedly.

The initial hypothesis that the new dental gel formulation may provide improved plaque control was supported by the significantly lower plaque indices measured in the test group versus the control gel group on Day 21. Previous studies have demonstrated effective plaque inhibition by activated edathamil [18,26]. In an *in situ* examination of biofilm structure and metabolic activity, activated edathamil was the most effective of four agents tested to affect the cell membrane integrity of all bacterial organisms of biofilms on uncoated surfaces [27]. Some other publications describe an inadequate antiplaque effect of the chelating agent, attributed to its lack of penetration into the biofilm layer [28]. The carrier and permeability enhancer MSM was integrated into the test dental gel formulation used in this study to address this potential issue [29]. Clinical evidence of the observed antiplaque effect was supported by a unique, novel, multimodality imaging approach which permitted noncontact surface and subsurface mapping and characterization of biofilm presence, distribution and microarchitecture. Imaging data confirmed plaque removal by both dental gels, documenting superior plaque control by the test gel without apparent damage to the underlying pellicle.

The status of the underlying pellicle after use of any antiplaque intervention is an important issue, especially when the agent is intended for daily use. Since it is the interface between teeth and the oral environment, the pellicle plays a key role in the maintenance of oral health by regulating processes including lubrication, demineralization, and remineralization in addition to shaping the composition of early microbial flora adhering to tooth surfaces. In this study, an intact pellicle was mapped using NLOM in both subject groups. An additional study to determine any potential effects of the new formulation on enamel demineralization and mineralization, identified no adverse effects on enamel microstructure (in press).

OCT is an emergent, high-resolution imaging technology that has been used to image the microstructure of the tooth surface and its underlying components. The resolution capabilities of OCT allow noncontact imaging of microbial colonies and the microstructure that develops in these biofilms. OCT is practical for its ability to image 3-D microstructures at high-resolutions in real-time. In this way, biofilm accumulation can be imaged and analyzed during any period of inhabitation on the tooth structures and thereby improve characterization of biofilm structure and function. A study that imaged biofilm development inoculated on a glass flow cell found that OCT's imaging depth capabilities allowed it to be an excellent imaging technique when compared to prominent imaging approaches such as *ex vivo* Fluorescence Microscopy and Confocal Scanning Laser Microscopy [30]. The *in vivo* results found in this study correlate with an *ex vivo* OCT study [31] which was able to image and assess rapid oral biofilm attachment and growth.

The use of dentrifice in conjunction with physical tooth brushing is the established method for biofilm control. However, research has shown that a combination of antimicrobial

treatment and mechanical removal is necessary to prevent the survival and re-emergence of biofilm [32]. In this study, the test gel used in conjunction with tooth brushing was shown to inhibit re-establishment of dental biofilm and advancement of plaque formation. It is unclear to what extent superior plaque control was the primary cause for the considerable improvement in gingival inflammation observed in the subjects using the test gel, and to what extent the anti-inflammatory effect of the gel formulation [33–35] drove the improvement in gingival health. Further studies are necessary to obtain a more refined understanding of this issue.

CONCLUSION

In this clinical study, a novel dental gel achieved excellent plaque control and reduced gingival inflammation over a period of three weeks. Clinical indices as well as a novel *in vivo* imaging approach mapped its antiplaque effects and confirmed the persistence of the enamel pellicle.

Acknowledgments

We gratefully acknowledge funding for this research from: NIH P41EB015890 (LAMMP); National Institutes of Health (NIH) 1R21DA031571-01; Livionex Inc R03-EB014852. We thank Corwin Evans, DDS, MS, for assistance with clinical standardization and scoring. We would like to thank ASLMS for their support through a 2013 travel grant.

Contract grant sponsor: National Institutes of Health (NIH); Contract grant number: P41EB015890; Contract grant sponsor: National Institutes of Health (NIH); Contract grant number: 1R21DA031571-01; Contract grant sponsor: Livionex Inc.; Contract grant number: R03-EB014852.

REFERENCES

1. Eke PI, Dye BA, Wei L, Thornton-Evans GO, Genco RJ, Beck J, Douglass G, Page R. Prevalence of periodontitis in adults in the United States: 2009 and 2010. *J Dent Res.* 2012; 91(10):914–920. [PubMed: 22935673]
2. Haffajee AD, Socransky SS. Microbial etiological agents of destructive periodontal diseases. *Periodontol* 2000. 1994; 5:78–111. [PubMed: 9673164]
3. Bowen WH, Koo H. Biology of *Streptococcus mutans*-derived glucosyltransferases: Role in extracellular matrix formation of cariogenic biofilms. *Caries Res.* 2011; 45:69–86. [PubMed: 21346355]
4. Jeon JG, Rosalen PL, Falsetta ML, Koo H. Natural products in caries research: Current (limited) knowledge, challenges and future perspective. *Caries Res.* 2011; 45:243–263. [PubMed: 21576957]
5. Sanz M, Serrano J, Iniesta M, Santa Cruz I, Herrera D, van Loveren C. Toothpastes. *Monogr Oral Sci Basel Karger.* 2013; 23:27–44.
6. Theilade E, Wright WH, Jensen SB, Løe H. Experimental gingivitis in man. II. A longitudinal clinical and bacteriological investigation. *J Periodontal Res.* 1996; 1:1–13. [PubMed: 4224181]
7. Axelsson P, Lindhe J. The significance of maintenance care in the treatment of periodontal disease. *J Clin Periodontol.* 1981; 8(4):281–294. [PubMed: 6947992]
8. Morris AJ, Steele J, White DA. The oral cleanliness and periodontal health of UK adults in 1998. *Br Dent J.* 2001; 191(4):186–192. [PubMed: 11551090]
9. Nogueira-Filho GR, Toledo S. Effect of three dentifrices containing triclosan and various additives. An experimental gingivitis study. *J Clin Periodontol.* 2000; 27(7):494–498. [PubMed: 10914890]
10. Van der Weijden GA, Hioe KP. A systematic review of the effectiveness of self-performed mechanical plaque removal in adults with gingivitis using a manual toothbrush. *J Clin Periodontol.* 2005; 32(S):6214–6228.

11. Yates R, Jenkins S, Newcombe R, Wade W, Moran J, Addy M. A 6-month home usage trial of a 1% chlorhexidine toothpaste (1). Effects on plaque, gingivitis, calculus and toothstaining. *J Clin Periodontol.* 1993; 20(2):130–138. [PubMed: 8436632]
12. Madlena M, Banoczy J, Gotz G, Marton S, Kaan M, Nagy G. Effects of amine and stannous fluorides on plaque accumulation and gingival health in orthodontic patients treated with fixed appliances: A pilot study. *Oral Health Dent Manag.* 2012; 11(2):57–61. [PubMed: 22692271]
13. Van Strydonck DAC, Slot DE, Van der Velden U, Van der Weijden F. Effect of a chlorhexidine mouthrinse on plaque, gingival inflammation and staining in gingivitis patients: a systematic review. *J Clin Periodontol.* 2012; 39:1042–1055. [PubMed: 22957711]
14. Bogren A, Teles RP, Torresyap G, Haffajee AD, Socransky SS, Wennstrom JL. Clinical and microbiologic changes associated with the combined use of a powered toothbrush and a triclosan/copolymer dentifrice: A 3-year prospective study. *J Periodontol.* 2007; 78(9):1708–1717. [PubMed: 17760540]
15. Raut SA, Angus RA. Triclosan has endocrine-disrupting effects in male western mosquitofish, *Gambusia affinis*. *Environ Toxicol Chem.* 2010; 29(6):1287–1291. [PubMed: 20821571]
16. Dodson RE, Nishioka M, Standley LJ, Perovich LJ, Brody JG, Rudel RA. Endocrine disruptors and asthma-associated chemicals in consumer products. *Environ Health Perspect.* 2012; 120(7):935–943. [PubMed: 22398195]
17. Yazdankhah SP, Scheie AA, Højby EA, Lunestad BT, Heir E, Fotland TØ, Naterstad K, Kruse H. Triclosan and antimicrobial resistance in bacteria: An overview. *Microb Drug Resist.* 2006; 12(2):83–90. [PubMed: 16922622]
18. Fang X, Keutgen XM, Jiang Y, Sherertz R, Hachem R. The role of chelators in preventing biofilm formation and catheter-related bloodstream infections. *Curr Opin Infect Dis.* 2008; 21(4):385–392. [PubMed: 18594291]
19. Colston BW, Everett MJ, Da Silva LB, Otis LL, Stroeve P, Nathel H. Imaging of hard- and soft-tissue structure in the oral cavity by optical coherence tomography. *Applied Optics.* 1998; 37(16):3582–3585. [PubMed: 18273327]
20. Baek J-H, Krasieva T, Tang H, Ahn Y, Chang K, Vu D, Chen Z, Wilder-Smith P. Optical approach to the salivary pellicle. *J Biomed Opt.* 2009; 14(4):044001. [PubMed: 19725713]
21. Sumen C, Mempel TR, Mazo IB, von Andrian UH. Intravital microscopy: Visualizing immunity in context. *Immunity.* 2004; 21(3):315–329. [PubMed: 15357943]
22. Løe H. The gingival index, the plaque index and the retention index systems. *J Periodontol.* 1967; 38(6):610–616. [PubMed: 5237684]
23. Løe H, Silness J. Periodontal disease in pregnancy. *Acta Odontologica Scandinavica.* 1963; 21:533–551. [PubMed: 14121956]
24. Turesky S, Gilmore ND, Glickman I. Reduced plaque formation by the chloromethyl analogue of vitamin C. *J Periodontol.* 1970; 41:41–43. [PubMed: 5264376]
25. Newbrun. Indices to measure gingival bleeding. *J Periodontol.* 1996; 67:555–561.
26. Chang Y, Gu W, McLandsborough L. Low concentration of ethylenediaminetetraacetic acid (EDTA) affects biofilm formation of *Listeria monocytogenes* by inhibiting its initial adherence. *Food Microbiol.* 2011; 29(1):10–17. [PubMed: 22029913]
27. Chávez de Paz LE, Bergenholtz G, Svensäter G. The effects of antimicrobials on endodontic biofilm bacteria. *J Endod.* 2010; 36:70–77. [PubMed: 20003938]
28. Bryce G, O'Donnell D, Ready D, Ng YL, Pratten J, Gulabivala K. Contemporary root canal irrigants are able to disrupt and eradicate single- and dual-species biofilms. *J Endod.* 2009; 35(9):1243–1248. [PubMed: 19720223]
29. Zhang M, Wong IG, Gin JB, Ansari NH. Assessment of methylsulfonylethane as a permeability enhancer for regional EDTA chelation therapy. *Drug Delivery.* 2009; 16(5):243–248. [PubMed: 19538004]
30. Xi C, Marks D, Boppart SA, Schlachter S, Luo W. High-resolution three-dimensional imaging of biofilm development using optical coherence tomography. *J Biomed Opt.* 2006; 11(3):34001. [PubMed: 16822051]

31. Lenton P, Rudney J, Chen R, Fok A, Aparicio C, Jones RS. Imaging in vivo secondary caries and ex vivo dental biofilms using cross-polarization optical coherence tomography. *Dent Mater.* 2012; 13(7):792–800. [PubMed: 22578989]
32. Fraud S, Maillard J-Y, Denyer SP, Kaminski MA, Hanlon GW. A simulated oral hygiene model to determine the efficacy of repeated exposure of amine oxide on the viability of *Streptococcus mutans* biofilms. *Eur J Oral Sc.* 2007; 115:71–76. [PubMed: 17305719]
33. Ansari NH, Campbell G, Xiao TL, Zhang M. Amelioration of oxidation-induced toxicity in human lens epithelial cells, diabetic rat lens by EDTA. *ARVO.* 2006:E-2434.
34. Ansari NH, Campbell G, Shoeb M, Xiao TL, Zhang M. Inhibition of endotoxin-induced uveitis by a metal chelator. *ARVO.* 2007:E-5156.
35. Zhang M, Shoeb M, Liu P, Xiao T, Hogan D, Wong IG, Campbell GA, Ansari NH. Topical metal chelation therapy ameliorates oxidation-induced toxicity in diabetic cataract. *J Toxicol Environ Health A.* 2011; 74(6):380–391. [PubMed: 21271438]

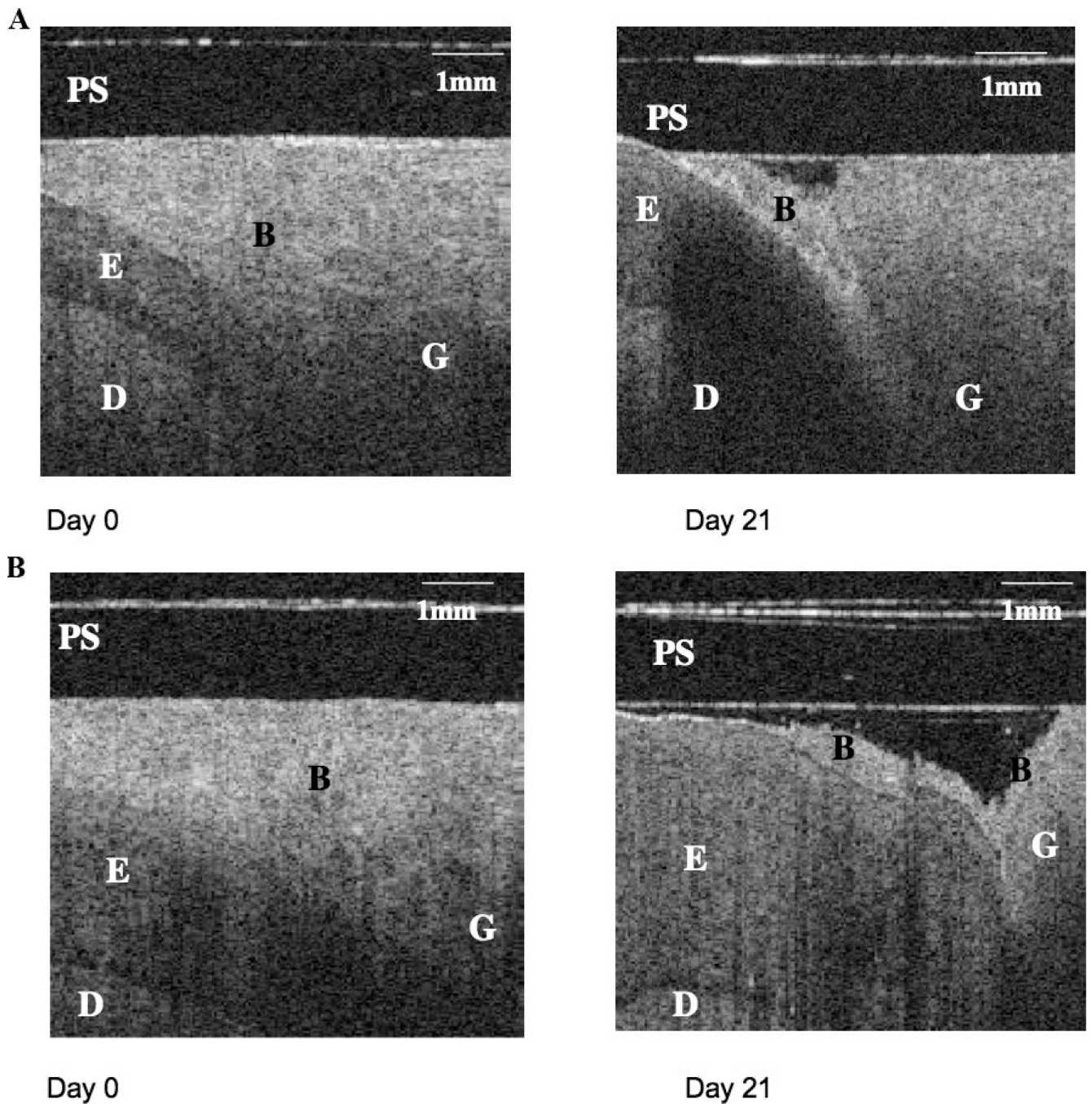


Fig. 1. Representative *in vivo* OCT images from one subject in each group. PS, probe sheath; B, biofilm; G, gingiva; E, enamel; D, dentin. **A:** Representative OCT images of subject in control gel group. At study outset a thick plaque layer covering the gingival and enamel surface is clearly visible. Considerable elimination of surface biofilm is apparent after 3 weeks of control gel usage with residual plaque visible at the enamel margin and inside the gingival pocket. **B:** Representative OCT images of subject in test gel group. At study outset a thick plaque layer covering the gingival and enamel surface is clearly visible. After 3 weeks

of test gel usage extensive elimination of surface biofilm is apparent. A thin patch of residual biofilm remains at the gingival margin. The enamel appears wider in this image because an oblique optical section was used to reveal the small deposit of biofilm, which was not visible at the usual imaging angle.

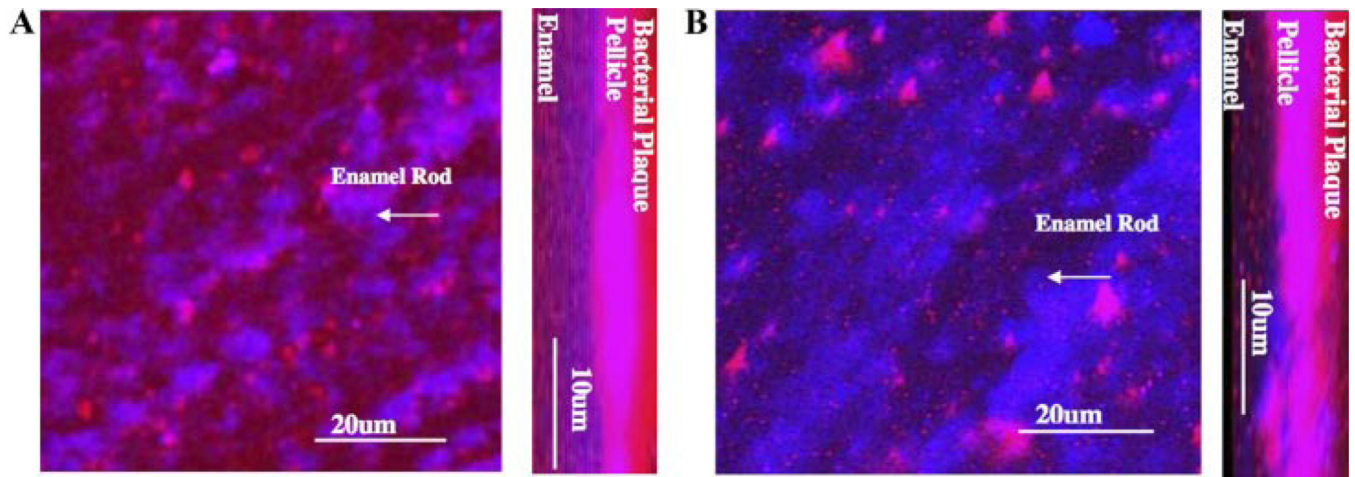


Fig. 2.

In vivo NLOM of oral plaque at gingival margin of the upper central left incisor. Subjects had brushed their teeth 2× daily with control (**A**) or test (**B**) toothpaste for 3 weeks. Fluorescein (Sigma-Aldrich Corp, St. Louis, MO) and Coolblue (Coolblue1, Ffizer, New York, NY) dyes were used as optical contrast agents during fluorescence imaging with NLOM. Left (**A**): 3-D reconstructed top view image. Enamel rods are clearly visible. Blue signal originates from tooth and saliva; pink signal originates from salivary pellicle and red signal is from bacterial plaque. The enamel is covered by a continuous layer of biofilm, with the blue signal from the enamel penetrating through the biofilm signal in a patchy fashion. Right (**A**): Vertical optical section of 3-D image. This lateral view confirms the presence of a solid and homogeneous film of bacterial plaque and underlying pellicle on the tooth surface. Representative biofilm on tooth surface in subject using test toothpaste for 3 weeks. Left (**B**): 3-D reconstructed top view image. Enamel rods are clearly visible in this 3-D reconstructed top view image. More blue signal from enamel and less overlying red signal from bacterial plaque are visible indicating the presence of less plaque than in **A**. Right (**B**): Vertical optical section of 3-D image. This lateral view confirms the presence of pellicle and less bacterial plaque on the tooth surface than in **A**. Especially on the right hand side of the image the red signal from plaque is reduced and considerably less dense than in **A**.

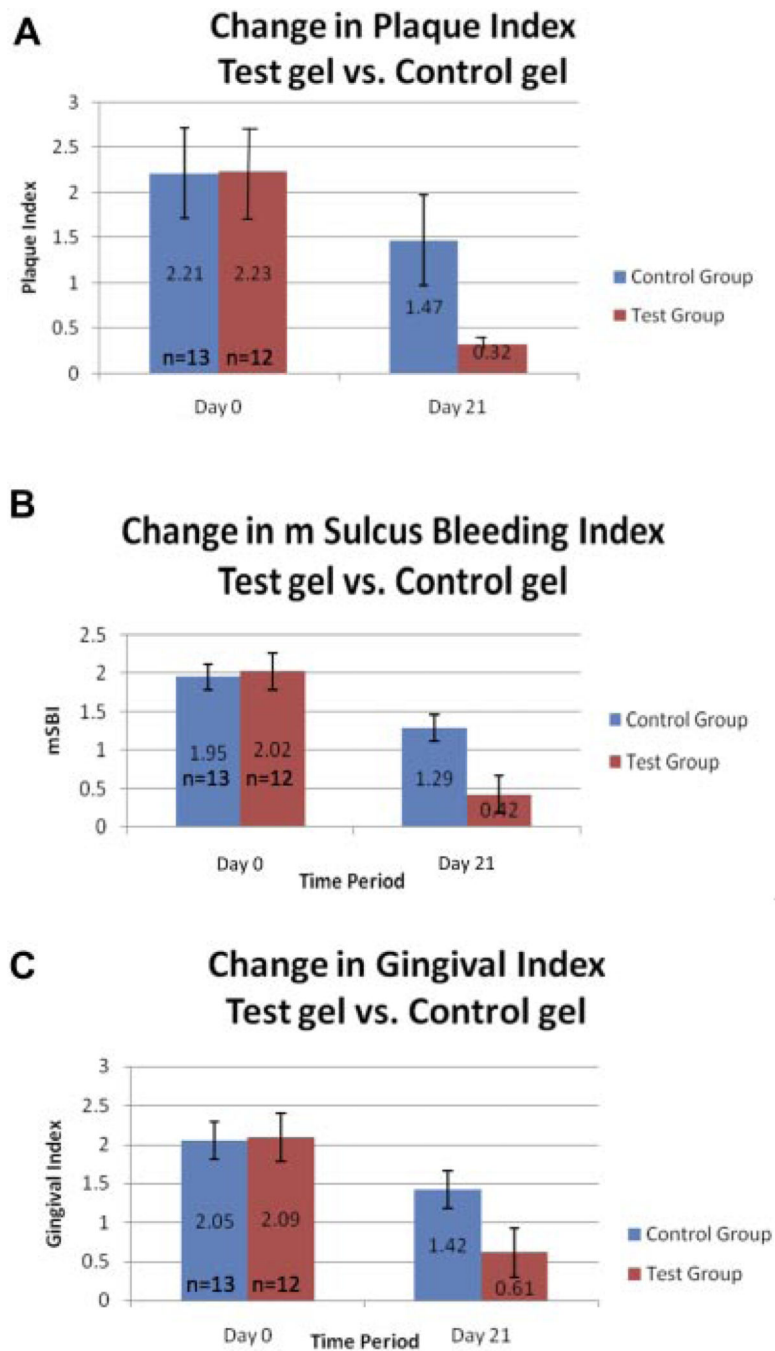


Fig. 3. Clinical indices. **A:** Clinical P.I. on Day 0 and Day 21. **B:** Clinical mSBI on Day 0 and Day 21. **C:** Clinical G.I. on Day 0 and Day 21.