

**UCSF**

**UC San Francisco Electronic Theses and Dissertations**

**Title**

Condylar changes in anterior open bite patients after orthodontic treatment -- a CBCT evaluation

**Permalink**

<https://escholarship.org/uc/item/9sf7p1r8>

**Author**

Lin, Yi

**Publication Date**

2023

Peer reviewed|Thesis/dissertation

Condylar changes in anterior open bite patients after orthodontic treatment -- a CBCT evaluation

by  
Yi Lin

THESIS

Submitted in partial satisfaction of the requirements for degree of  
MASTER OF SCIENCE

in

Oral and Craniofacial Sciences

in the

GRADUATE DIVISION

of the

UNIVERSITY OF CALIFORNIA, SAN FRANCISCO

Approved:

DocuSigned by:

*Mona Bajestan*

2981A760204B4B2...

Mona Bajestan

Chair

DocuSigned by:

*Christina Hong*

DocuSigned by:  
451...

Christina Hong

*Rumpa Ganguly*

389A1F702D854A7...

Rumpa Ganguly

Committee Members



# **Condylar changes in anterior open bite patients after orthodontic treatment -- a CBCT evaluation**

**Yi Lin**

## **Abstract**

**Introduction:** Anterior open bite (AOB) is a type of malocclusion that exhibit no anterior guidance resulting in a lack of occlusal equilibrium in static and dynamic aspects, which could induce more stress for the temporomandibular joint (TMJ) than a normal occlusion. However, the effect of orthodontic treatment to obtain anterior guidance for patients with AOB on TMJ condyle remained poorly studied. This study aims to analyze the condylar changes in AOB patients by comparing their CBCT data pre- and post-orthodontic treatment.

**Methods:** The 108 AOB patients underwent orthodontic treatment included had cone-beam computed tomography (CBCT) scans taken before orthodontic (T1) and after orthodontic treatment (T2). We divided them into 3 different severity groups (Mild, Moderate, and Severe) and 3 different treatment modalities groups (ALN, FFA, and Sx). Measurements were conducted using InVivo 6 for the condylar joint space, depth of fossa, condylar position, and condylar dimension. Pre-treatment and post-treatment three-dimensional (3D) volume of bilateral condylar head were calculated, and the representative 3D models were superimposed using voxel-based registration on the mandibular stable region.

**Results:** After orthodontic treatment for AOB, the condyles tend to seat more posteriorly and superiorly for about 0.17-0.21mm and 0.09-0.12mm respectively; the depth of fossa increased 0.22mm on the right side; the asymmetry of the condylar position improved; the condylar width increased for 0.44mm; the condylar height increased for 0.40mm; and the

3D condylar volume increased for 98.29 mm<sup>3</sup>. Teenage AOB patients have significant condylar changes (joint space, laterolateral condylar position, height, width, and 3D volume) after treatment while adult patients generally do not experience many changes except for the surgical patients. As patient ages, the dimensional and volumetric changes after treatment decreased. Surgical patients experienced the most volumetric increase after treatment of AOB. There is no difference in the amount of condylar changes between AOB treatment with ALN and FFA.

Conclusions: Our results shows that orthodontic treatment for AOB overall does not predispose patients to the risk of condylar resorption or dysfunction. The joint space changes are small, however, the direction of these changes in teenage patients may warrant closer examination and consideration in treatment planning. As AOB patients age, the amount of condylar changes decrease with no much significant changes in adult non-surgical patients. Surgical AOB patients may experience more condylar positive remodeling after treatment compared to the non-surgical patients.

# Table of Contents

## 1. Introduction

1.1 Anterior Open Bite (AOB)	1
Demographic characteristics	
Relation to TMJ	
Treatment for AOB	
1.2 Temporomandibular joint disorders (TMDs)	2
Functional remodeling and adaptive changes	
Imaging Diagnosis of TMD	
Correlation between AOB and TMDs	

## 2. Central Hypothesis

## 3. Specific Aims

## 4. Materials and Methods

4.1 Sample size calculation and patient selection	6
4.2 Sample collection and classification	7
4.3 CBCT reconstruction and orientation	8
4.4 Landmarks and 3D measurements	9
4.5 3D volumetric calculation and superimposition	10
4.6 Statistical analysis	13

## 5. Results

5.1 General characteristics	14
5.2 Condylar joint space	14
5.3 Depth of Fossa	16

5.4 Condylar position	16
5.5 Condylar dimension	18
5.6 Condylar 3D volume	19
<b>6. Discussion</b>	21
<b>7. Conclusion</b>	25
<b>8. References</b>	26

## List of Figures

<b>Figure 1</b>	33
Photographic Openbite Severity Index (POSI)	
<b>Figure 2</b>	33
Head Orientation using InVivo 6	
<b>Figure 3</b>	34
Measurement of LLCP and ACA from the axial view	
<b>Figure 4</b>	34
The automatic conjugation of condylar width, length, and height	
<b>Figure 5</b>	35
The data distribution of condylar joint space and PS/AS ratio	
<b>Figure 6</b>	35
The general changes of the TMJ joint spaces before and after treatment	
<b>Figure 7</b>	36
Condylar joint space changes in the Adult and Teen groups	
<b>Figure 8</b>	36
Condylar joint space changes in the Female and Male groups	
<b>Figure 9</b>	36
Condylar joint space changes in different severity groups	
<b>Figure 10</b>	37
LLCP between left and right side in different groups before and after treatment	
<b>Figure 11</b>	37
The correlation between age and the dimensional changes	



<b>Figure 12</b>	38
3D volumetric changes of the condylar head in the Teen and Adult groups	
<b>Figure 13</b>	39
The correlation between 3D volumetric changes and age	
<b>Figure 14</b>	39
Condylar 3D superimposition of the average patients in the Teen group	
<b>Figure 15</b>	40
Condylar 3D superimposition of the average patients in the adult group	

## List of Tables

<b>Table 1</b>	41
----------------	----

Landmarks used for automatic 3D TMJ measurements.

<b>Table 2</b>	41
----------------	----

Sample size per group.

<b>Table 3</b>	42
----------------	----

Mean value of general joint space changes after orthodontic treatment.

<b>Table 4</b>	42
----------------	----

Condylar positional symmetry before and after treatment.

<b>Table 5</b>	42
----------------	----

Laterolateral condylar position in different genders at pre- and post-orthodontic treatment.

## **1. Introduction**

### *1.1 Anterior Open Bite (AOB)*

Anterior open bite (AOB) is characterized by the absence of vertical overlap of the anterior teeth. The prevalence of AOB has been reported to range from 0.6% to 16.5%, depending on age and race, and approximately 17% in orthodontic patients with skeletal malocclusions<sup>1</sup>. The etiology of AOB is multifactorial, including unfavorable growth patterns, digit-sucking habits, enlarged lymphatic tissue, intracapsular TMJ deformations, neurologic problems such as cerebral palsy, and skeletal growth abnormalities. It can impair the speech, swallowing, mastication and esthetics, thus creating unfavorable conditions for normal social life<sup>2</sup>.

Tanne et al. revealed that approximately 50% of open bite patients presented at least one symptom or sign of Temporomandibular disorders (TMDs)<sup>3</sup>. This may be due to the fact that these patients with open bite exhibit no anterior guidance resulting in a lack of occlusal equilibrium in static and dynamic aspects, which could induce more stress for the TMJ than a normal occlusion. Arnett et al.<sup>4</sup> suggested that TMJ loading, if excessive, alters the host adaptive capacity for bone remodeling. Studies from Terada et al. demonstrated that open bite patients with TMDs exhibited more prominent vertical discrepancy than those without TMDs, which suggests the association between the onset of TMDs and skeletal discrepancy as well as occlusal one particularly in the vertical direction.

The treatment of AOB varies from an early intervention of habit to orthognathic surgery. While surgical correction has typically been recommended to adults with severe open bites, recent case reports have illustrated successful correction of significant open bites in adults using other techniques, including aligners, multiloop edgewise archwire (MEAW) with

elastics, and TADs. In surgical cases, Le Fort I impaction and maxillary advancement as well as mandibular advancement/setback are routinely performed for patients with skeletal open bite. Zupnik et al.<sup>5</sup> and Gomes et al.<sup>6</sup> have demonstrated that the 3D condylar displacement happened after surgical correction for open bite patients.

### *1.2 Temporomandibular Joint Disorders (TMDs)*

TMD are a range of disorders which include the intra-articular joint disorders, degenerative joint disorder and subluxation. They can be diagnosed according to the diagnostic criteria for temporomandibular disorders (DC/TMD), which includes the imaging approaches such as magnetic resonance imaging (MRI) and computerized tomography (CT)<sup>7</sup>. Multiple imaging techniques were implemented for the diagnosis of TMD. The limitations of traditional two-dimensional (2D) imaging methods such as panoramic radiograph, cephalometric radiograph, transcranial X-ray, and arthrography have become increasingly apparent in recent years as they cannot provide accurate assessment of the morphology and spatial relationships of the TMJ osseous components. Advancements in medical imaging technology have led to the widespread adoption of 3D imaging techniques such as CT and MRI, which offer superior visualization of the complex structures involved in TMD pathology. CT or CBCT is mainly used to detect the bony changes of TMJ while MRT was used to evaluate the disc position and articular cartilage alteration<sup>8</sup>.

It has long been a controversial topic that orthodontic treatment in achieving functional a balanced and functional occlusion will cause positive changes in TMJ and eliminate TMD symptom. So far, there is no evidence for a cause-effect relationship between orthodontic treatment and TMD<sup>9</sup>, however, a lot of studies reported TMJ changes after orthodontic treatment including the condylar positional changes and morphological changes in glenoid

fossa and/or condylar head<sup>10-19</sup>. Most of these studies were focusing on orthodontic treatment involving sagittal correction using Herbst appliance<sup>11,12</sup>, Twin Block appliances<sup>17</sup>, Class II or Class III elastics<sup>18,19</sup>, maxillary protraction with Facemask<sup>15,16</sup> or Bollard plate<sup>14</sup>, surgical treatment for skeletal Class II or Class III malocclusion<sup>10,13</sup>, etc. The TMJ reaction to transverse correction with rapid palatal expander was also studied<sup>20,21</sup>. Nevertheless, fewer research embarks on the effect of orthodontic correction in vertical discrepancy on TMJ, which only includes patients went through surgical correction for skeletal open bite<sup>5,6</sup>.

While some case reports showed no or few condylar changes after the orthodontic treatment of patients with AOB<sup>22</sup>, others like Tanaka et al. have reported the adaptive remodeling of the condyle after comprehensive orthodontic treatment<sup>3,23</sup>. In addition, Sasaguri et al.<sup>24</sup> reported condylar remodeling in a patient with rheumatoid arthritis 4 years post-retention. Functional remodeling of the TMJ bony structures is characterized by morphological adaptation, invariable ramus height, and stable occlusions. Treatment for AOB is usually accompanied with counterclockwise rotation of the mandible, which may cause condylar reposition and joint space changes. It would be reasonable to assume that these changes, in conjunction with optimal occlusal support, may lead to biomechanical equilibrium in the TMJ. However, the effect of orthodontic treatment for patients with AOB on TMJ condyle remained poorly studied. Therefore, this project aims to analyze the condylar changes in AOB patients by comparing their CBCT data pre- and post-orthodontic treatment.

## **2. Central Hypothesis**

We hypothesize that there will be specific condylar changes among patients with AOB before and after orthodontic treatment.

### **3. Specific Aims**

Our first aim is to assess the condylar positional changes after orthodontic correction of AOB. Our second aim is to assess the condylar volumetric changes after orthodontic correction of AOB.

## 4. Materials and Methods

### 4.1 Sample size calculation and patient selection

#### 4.1.1 Sample size calculation

To estimate sample size and considering a clinically significant difference between the 2 timepoints of 1 SD, the sample size will be calculated given 80% power to detect this difference at a significance level of 0.05. And the minimal detectable effect was set as 0.2mm.

#### 4.1.2 Case selection

(1) Inclusion criteria:

- (a) One or more incisors with no vertical overlap. The remaining incisors may have incisor overlap but could not contact teeth in the opposing arch.
- (b) At least one posterior contact between maxillary and mandibular teeth to verify the presence of open bite, as seen on sagittal CBCT cross-sectional slices.
- (c) Preoperative and postoperative CBCT scans of sufficient quality
- (d) Initial and final cephalometric radiograph taken
- (e) Initial intraoral frontal photo or study model or digital intraoral scan taken prior to the beginning of the treatment
- (f) Patient is in permanent dentition

(2) Exclusion criteria:

- (a) Craniofacial syndromes
- (b) Systemic degenerative conditions
- (c) Previous TMJ surgery



- (d) Previous arthroscopy, arthrocentesis, or viscosupplementation
- (e) Patients originally are missing more than 1 posterior tooth without restoration
- (f) Patients that achieved positive overbite by merely habit intervention without comprehensive orthodontic treatment
- (g) The anterior open bite was not fully corrected according to the final records

#### *4.2 Sample collection and classification*

This is a retrospective cohort study. The protocol will be submitted to the institutional review board at the University of California, San Francisco for approval. Records for this study will be selected from all patients who consecutively treated in the Division of Orthodontics at the University of California, San Francisco from January 2007 to November 2021 according to the inclusion criteria and exclusion criteria.

All CBCT scans were taken with a CS9300 Cone Beam 3D Imaging System (Carestream Dental, Atlanta, Ga) set at 85 kV(p), 4.0 mA, 6.4-second scan time, 17 × 11 cm field of view, and voxel size of 0.250 mm. For cephalometric X-ray, all films were taken with Instrumentarium® Orthopantomograph OP100® (Instrumentarium Imaging, Tuusula, Finland), with a magnification of 9.8% and scanned at 300 dpi (U Max Power Look 1100; Techville Inc., Dallas, TX). Study models were fabricated according to the ABO standard. Intraoral scannings were performed with iTero (Align Technology, San Jose, California). All the records collected at the initial time point will be determined as T1 while the records collected at the final time point immediately after treatment will be determined as T2.

### *AOB Severity Index*

With the initial data collected, patients were categorized and scored by the severity of anterior open bite (Fig. 1)<sup>1</sup>. The categories are:

- (1) 1 or 2 maxillary (Mx) lateral incisors without vertical overlap (but both Mx central incisors have vertical overlap)
- (2) 1 Mx central incisor without vertical overlap (the other Mx central has vertical overlap)
- (3) 2 Mx central incisors without vertical overlap (at least one Mx lateral has vertical overlap)
- (4) All four Mx incisors without vertical overlap
- (5) All anterior teeth without overlap (canine to canine)
- (6) Category 5, plus at least one premolar without vertical overlap

### *Treatment Modalities*

The treatment modalities were divided into four mutually exclusive categories:

- (1) ALN: Aligners (patients recommended fixed appliances or orthognathic surgery were excluded)
- (2) FFA: Full Fixed appliances (patients could also have been recommended aligners, but patients recommended orthognathic surgery were excluded)
- (3) SX: Orthognathic surgery (patients could also have been recommended aligners, fixed appliances, and/or TADs)

### *4.3 CBCT reconstruction and head orientation*

The scanned data were exported in DICOM format and imported into InVivo 6 software to reconstruct 3D images for further analysis. The head positions will be standardized

according to the Frankfort, coronal, axial, and sagittal planes. The Frankfort plane will be oriented horizontally; the coronal and axial planes will be positioned, respectively, tangentially to the posterior and inferior border of the external acoustic meatus, simultaneously at the right and left sides; and the sagittal plane will be positioned passing through the internasal suture and anterior nasal spine (Fig. 2).

#### *4.4 Landmarks and 3D measurements*

Based on the head orientation, Landmarks in Table 1 will be placed for the left and right sides using InVivo 6.

From the sagittal image, the following linear measurements will be automatically calculated after the position of landmarks.

- (1) Anterior joint space (AS): the shortest distance between the most anterior point of the condyle and the posterior wall of the articular tubercle.
- (2) Superior joint space (SS): the shortest distance between the most superior point of the condyle and the deepest point of the mandibular fossa.
- (3) Posterior joint space (PS): the shortest distance between the most posterior point of the condyle and the posterior wall of the mandibular fossa.
- (4) Depth of the mandibular fossa: distance between the deepest point of the mandibular fossa and the plane formed by the most inferior point of the articular tubercle to the most inferior point of the auditory meatus.

According to the above measurement, the anterior-posterior condyle-fossa relation will be expressed as PS/AS (Pullinger and Hollender).

From the axial image, the following measurements will be made (Fig. 3):

- (1) Laterolateral condylar position (LLCP): the distance between Center of Condyles (CC) and the mid-sagittal plane (MSP)
- (2) Axial condylar angle (ACA): the angle formed by the intersection of the line passing through CC and the LCo landmarks with the MSP.)

From the coronal image, the following measurements will be made:

- (1) Coronal condylar angle (CCA): the angle formed by the intersection of the line connecting CC and the LCo with the MSP.

For the condylar dimension, the following measurements will be automatically calculated (Fig. 4):

- (1) Condylar width: Distance from LCo to MCo.
- (2) Condylar length: Distance from ACo to PCo.
- (3) Condylar height: Distance from SCo perpendicular to R-tan-P.

#### *4.5 3D volumetric calculation and superimposition*

- (1) Conversion and De-identification. Converts the individual slices of the scan sequence from DICOM format (Digital Imaging and Communications in Medicine) into a single-file de-identified image format known as GIPL (Guys Image Processing Lab).
- (2) Downsizing. The CBCT images will be reformatted to 0.5-mm isotropic voxel size for the segmentation of the anatomic structures of interest using the Downsize Image module in 3D Slicer (version 4.11.0, [www.slicer.org](http://www.slicer.org)).
- (3) Orientation. Slicer CMF will be then employed to perform head orientation of surface models generated following an automated thresholding algorithm to

generate full-skull models by means of the intensity segmenter and model maker modules. The transforms module will then be used to align the Frankfort horizontal, midsagittal, and transporionic planes to match the axial, sagittal, and coronal planes of the skull surface model. After alignment of 3 planes, translate the skull superiorly to match the horizontal plane with A point and posteriorly to match the coronal planes with the posterior margin of the frontal process of the zygomatic bone. This is to ensure the whole mandible is within the region of interest.

(4) Segmentation. The 3D volumetric models of the mandible will be subsequently segmented by outlining the cortical threshold and edge attraction using a semiautomatic procedure in ITK-SNAP (version 3.8.0; open-source software, <http://www.itksnap.org>). The constructed image was then manually checked slice by slice in all planes of space to clean and correct any errors that may have occurred during the automatic segmentation process. These refined mandibular segmentations will be converted subsequently into 3D surface models using the model maker module within 3D Slicer to produce the surface models.

(5) Landmarking. Manual landmark identification will then occur with 3 open windows of ITK-SNAP to visualize in 3D space. The axial, coronal, and sagittal views of the original gray scale images recreated by multiplanar reconstruction, and the 3D volumetric model will be used in landmark placement. 2 landmarks (Sig, sigmoid notch; Cr, the tip of the coronoid process, painbrush, round, 5, label 2) will be placed on each side of the mandible using

another active label in ITK-SNAP to differentiate it from the previous segmentation.

- (6) Cropping. The previous segmentation including the mandible and landmarks will then be identified and exported individually using the Surface Model (Model maker) in 3D Slicer. Both models will be then reloaded to 3D slicer and differentiated with different colors (Red for LMs in Model Module). The condylar head of each side will be cropped based on a plane covering the Sig and Cr on the targeted side along with the Cr or Sig on the opposite side using the Easy Clip Module in 3D slicer. The model of left and right condyles will be saved subsequently, followed by transformation from Model to Segmentation using the Mesh to Label Map Module with the reference of previous segmentation without landmarks.
- (7) Volumetric calculation. The segmentation of condylar heads will then be loaded to ITK-SNAP to allow the volumetric calculation using the volumes and statistics tool. The 3D volume of the condylar heads in  $\text{mm}^3$  will be obtained subsequently.
- (8) Superimposition. Manual approximation of T1 CBCTs and segmentations onto the T0 mandible will be performed by means of cross-sectional views in all 3 planes of space, in 3D Slicer CMF using the transforms module. Regions of interest (masks) on the T1 mandibular segmentations will be then identified on the approximate T1 segmentations in ITK-SNAP. The masks are used to define the stable regions of superimposition for the mandibular body voxel-based image registration. The stable regions will be cropped horizontally below the B

point and coronally frontal to the anterior ramus in ITK-SNAP using a 3D toolbar. A fully-automated voxel-based growing mandibular superimposition will then be performed using the growing registration module in 3D Slicer CMF Registration to generate a matrix that allowed for subsequent superimposition of the T1 mandibular surface models onto the original T0 mandibular surface model. Condylar changes subsequently could be visualized by semi-transparency overlays of the T0 and T1 mandibular surface models.

#### *4.6 Statistical Analysis*

Records from ten patients will be randomly selected to measure inter- and intra-rater reliability by two investigators. Each measurement will be automatically calculated, and then 2 weeks later, repeat the procedures. Both inter- and intra-rater reliability will be determined using intraclass correlations coefficient.

Data analysis will be performed with Excel (Microsoft, version 16.13.1, Redmond, Wash). Means and standard deviations will be calculated for all subjects. The paired Student t test will be used to compare the difference between T1 and T2. Difference among groups of severity and treatment modalities will be analyzed by ANOVA or Standard t test. The correlation between age to changes will be calculated using linear regression analysis. And the correlation between severity/treatment modality and condylar changes will be analyzed by Spearman correlation.

## **5. Results**

### **5.1 General characteristics**

#### *Sample size*

The minimal sample size calculated based on the minimum detectable effect being 0.2mm is 30.

#### *Demographic characteristics*

After inclusion and exclusion, 108 patients were included with a mean age 19.8yo and standard deviation of 7.7 yo. The age range is 10-58 yo. 62 of them are male patients while 46 of them are females.

#### *Sample size per groups*

The groups based on severity index were combined to yield a larger sample size per group: Mild (severity index 1-2), Moderate (severity index 3-4), Severe (severity index 5-6). The sample size per groups is shown in Table 2.

#### *Inter-rater and Intra-rater reliability.*

The Intra-rater reliability calculated is over 89% and the Inter-rater reliability of the measurements are 87.7%-95%.

### **5.2 Condylar joint space**

#### *Distribution of the data*

The joint space distribution is shown in Fig. 5. The median of the joint space is 2.39mm and PS/AS ratio is 0.95. The inter-quartile range of the joint space is from 1.94-2.89mm with the PS/AS ratio being 0.73-1.2. The superior joint space is more variably distributed compared to the posterior and anterior joint space.



### *General Changes*

In general, we noted that the posterior space decreased significantly after treatment for 0.17mm on the left side and 0.21mm on the right side averagely. The superior joint also decreased but in a less amount for 0.12mm on the left and 0.09mm on the right, while the anterior joint space does not show any significant changes after treatment. The PS/AS unsurprisingly also shows a significant decrease for 0.06 on the left and 0.09 on the right (Fig. 6, Table 3). The result indicates that after orthodontic treatment, both condyles seated slightly more posteriorly and superiorly.

### *Adult VS Teen*

In the adult group, only the right side posterior joint space has a significant decrease after treatment for 0.16mm. However, in the teen group, both PS and PS/AS ratio have a significant decrease for 0.27mm and 0.26mm for the PS left side and right side respectively and 0.10 for the PS/AS ratio on the right side (Fig. 7). This indicates that teenagers are more susceptible to joint space changes after treatment compared to adults.

### *Female VS Male*

When compare the changes in female and male patients separately, the significant difference is mainly among female with similar amount of changes to the general result (Fig. 8). Basically, after orthodontic treatment, female AOB patients are more likely to experience joint space changes than male patients. In contrast, male patients did not show significant joint space changes following orthodontic treatment.

### *Severity*

The decrease in the posterior and superior joint space as well as the PS/AS ratio is significant in only the severe open bite group while not in the mild or moderate group with

over 0.30mm, which is larger than the general average value (Fig. 9). The spearman correlation analysis shows that the coefficient between the severity index and the number of changes in PS/AS ratio is about -0.24 for the right side and -0.23 for the left side, which indicates a moderate correlation. Therefore, the severity of anterior open bite will affect the amount of joint space changes after orthodontic treatment.

#### *Treatment modalities*

For the effect of treatment modalities, the significant changes were observed in the surgery group, which have 0.25mm decrease in PS, 0.17mm decrease in SS and 0.12 decrease in the PS/AS ratio. While for the FFA group, PS decreased for 0.21mm averagely. The ALN group, however, does not have significant different before and after treatment in any joint space. We also performed an AVONA analysis of T2-T1 among all three groups with no significant result, which means that there were no statistically significant differences in the changes observed among these 3 groups receiving different treatment modalities.

### **5.3 Depth of Fossa**

Overall, the average depth of fossa measure to be 10.08mm for T1 and 10.2mm for T2, with a significant increase observed between them on the right side only for 0.22mm averagely, in the teen group for 0.32mm, and in the male group for 0.36 mm averagely. For the severity and treatment modality, no significant difference was observed in the mild group or the ALN group. And there is no correlation or significant difference detected among groups.

### **5.4 Condylar position**

For condylar position, we compared the left side and the right side for symmetrical analysis. And the result (Table 4) shows that at T1, while both ACA and CCA did not show a

significant difference between the left and right sides, only LLCPC exhibited a significant difference between the left and right sides; At T2, there was no significant difference found between the left and right sides in any of the variables. Therefore, the condylar position potentially become more symmetrical after treatment.

For the subgroup, as Fig. 10 shows, adult patients have a statistically significant difference between the left and right sides both at T1 and T2 meaning the asymmetric condylar position does not change after treatment in this patient group. However, in teenage patients with AOB, the difference was only significant at T1 but at T2, which indicate an improvement of asymmetry after treatment. At both T1 and T2, there was a statistically significant difference between the left and right sides in adult patients with AOB. However, in teenage patients with AOB, the difference was only significant at T1. From Table 5, we also noticed that at both T1 and T2, there was no statistically significant difference between the left and right sides in male patients. However, in female patients, the difference was only significant at T1.

In the mild AOB group, the difference of LLCPC between L and R sides are not statistically significant at both T1 and T2. In the moderate and severe AOB groups, there are significant difference of LLCPC between L and R sides at T1, while the differences become not statistically significant at T2.

In the ALN and Sx group, the difference of LLCPC between L and R sides are not statistically significant at both T1 and T2. In the FFA groups, there are significant difference of LLCPC between L and R sides at T1, while the differences become not statistically significant at T2.

After treatment, female teenage patients showed a greater change towards the right side (R changes > L changes) of the mandible, with outward rotation of the right condyle.

After treatment, male teenage patients showed a greater change towards the right side of the mandible, with outward rotation of the left condyle. In adult male patients, the mandible moved towards the right side with medial inclination of the right condyle.

## **5.5 Condylar dimension**

### *General Changes*

No significant difference was observed between the left and right condylar dimensions. The condylar width and height have significant changes after treatment, with an increase of 0.44 mm and 0.40 mm respectively.

### *Adult VS Teen*

Both adult and teen patients have a significant change of condylar height and width after treatment. Condylar width significantly increases more in the teen group compared to the adult group, which is 0.25mm in adult and 0.65mm in teenager. While their changes in condylar height are not significantly different, which is 0.36mm in adult and 0.43mm in teen.

Since the dimensional changes are also significant in the adult group, which is not detected in the previous variables, we also analyzed the adult patients only receiving different treatment modalities. And it shows that the increase in condylar width and condylar height are significant in the FFA and surgery groups while not in the ALN group. Also, the surgery group in adult patients showed the largest increase in both condylar width and height., which is 0.36mm in width and 0.68mm in height.

### *Condylar width changes-Age correlation*

It was observed a significant difference in the amount changes between the Adult and Teen groups. We removed the outlier which is the patient that is 58 years old in our patient pool. Although the square R of the equation is only 0.1034 meaning that it doesn't fit the data

very well, the correlation coefficient is -0.3216 with a p value under 0.001, which indicates a moderate negative correlation between patient's age and the amount of condylar width changes. Also based on the scatter plot, we can see that most patients have an increase condylar width verse decrease after treatment (Fig. 11).

## **5.6 Condylar 3D volume**

### *Teen*

Both male and female teenage patients showed a significant increase in condylar volume after treatment. The increase in male teenage patients was approximately twice that of female teenage patients. Before treatment, male teen patients have a similar range of condylar volume to female teen patients. After treatment, a wider range of condylar volume was observed in male patients (Fig. 12).

### *Adult*

The adult group, however, has a less amount of increase, which are not statistically significant in either the female or the male group. Similar to the male teen patients, male adult patients also has a wider range of condylar volume compared to female adult patients (Fig. 12).

### *3D volumetric changes-Age correlation*

The linear regression analysis shows a moderate negative correlation with a p value under 0.001, which mean there is a moderate negative correlation between the age of AOB patients and the increase in condylar volume after orthodontic treatment. The left- and right-side condyle in different colors are basically overlapped. Another interesting finding is that patient under 20 has a more positive changes in general, while for patients over 20, the

number of patients undergoing positive changes is similar to the amount of the ones that have negative changes (Fig. 13).

### *Severity*

The Spearman correlation does not show any correlation between the severity index and the amount volumetric changes of the condyles.

### *Treatment modalities*

Overall, the condylar volume increased in all 3 groups after treatment, with 45.79 mm<sup>3</sup> in the ALN group, 69.72 mm<sup>3</sup> in the FFA group and 182.76 mm<sup>3</sup> in the Sx group. Only patients in the Sx groups have significant volumetric changes after treatment, which is about 2-3 times higher than the other 2 groups. The difference of volumetric changes between the ALN and FFA groups is not statistically significant.

### *Superimposition*

The visualization of the average 3D condylar changes is displayed in Figure 14 and Figure 15. The average condylar volume in the Teen group is 2038.82 mm<sup>3</sup> with an average increase of 145.89 mm<sup>3</sup> after orthodontic treatment. We can observe from the colormap and superimposition that the in the Teen group, the condylar head mostly grow upwards, backwards, and laterally. In adult patients, the average condylar volume is 2366.21 mm<sup>3</sup> with an average increase of 31.36 mm<sup>3</sup> which is very minimal.

## 6. Discussion

This study shows a general decrease in PS and SS after orthodontic correction of anterior open bite. This is similar to other studies focusing on other patient groups. Alhammadi et al.<sup>25</sup> also reported an increase in AS and a decrease in PS following maxillary first premolar extraction and incisor retraction in skeletal CI II patients, however, in a much bigger amount like 2-3mm. Other articles also mentioned the concerns in the changes of condylar position, particularly in the posterior direction, which may lead to disc displacement in TMD patients<sup>26</sup>. This is aligned with the finding of Chen et al. published in 2022<sup>27</sup> as they noticed that condyles were positioned more posteriorly with increasing age, and the condylar position was more posterior in the open bite patients than in the crossbite patients. Rohan et al also found a larger anterior space in the hyperdivergent group compared to normodivergent and hypodivergent groups<sup>28</sup>. Therefore, it's reasonable to assume that AOB patients who are usually hyperdivergent has condyles seated more posteriorly and the changes with orthodontic treatment may partly be due to the normal change with increasing age as it's too small to be clinically significant. However, closer examination during the treatment may be warranted.

We also found that female patients are more susceptible to joint space changes, while male patients didn't experience significant joint space changes after orthodontic treatment. This is different from the finding of Zahra et al.<sup>29</sup> as they found no significant differences in the P/A ratio between the sexes. However, their samples are normal function individuals which is highly not aligned with our patient's population in this study.

We also found that the more severe the AOB, the higher chances the condyles will move more posteriorly (PS decreased for about 0.34mm, ~14% decrease) after treatment. And

different treatment modalities (ALN, FFA, SX) do not affect the joint space changes after treatment. Bella et al. also found that cephalometric comparison of anterior open bite correction and changes in the mandibular plane angle associated with use of clear aligners and fixed appliances did not demonstrate statistically significant differences in adult hyperdivergent patients<sup>30</sup>. Gomes et al. also conclude in his article in 2018 that the condyles moved backward in skeletal AOB patients after CMMA<sup>6</sup>. They also noticed a medial and superior condylar translation after orthognathic surgery. And usually, the more severe the open bite, the more counterclockwise rotation of the mandible is involved in the treatment, that's probably why we observe more posterior movement in the severe AOB group.

For the depth of fossa, we mainly found the increase changes on the right side for 0.22mm averagely. Also, Teenage and Male patients tend to have increased depth of glenoid fossa after orthodontic treatment, with increments of 0.32mm and 0.36mm, respectively. The changes of fossa depth are not correlated to the severity of AOB or the treatment modalities. Unlike our study that found a slight increase in the depth of fossa, Ballesteros et al. found that it was significantly reduced with an increase in age in adult male<sup>31</sup>. That is because aging may have caused the flattening of the superior part of the condyle and erosion of the articular tubercle<sup>32</sup>. Other studies also found the depth being lower in Class III patient, followed by Class II and lastly the Class I patients<sup>33,34</sup>. Again, no studies were found based on the vertical dimension of the malocclusion. Whether or not the change of depth of fossa is still controversial. Parknahad et al. have found that the depth of fossa is significantly higher in patient with TMD than in the control group<sup>35</sup>. However, Derwich et al. found no significant differences in morphology of glenoid fossa including the depth between both of the TMJs groups with and without reciprocal clicking<sup>36</sup>.



For joint position in AOB patient, we found that the condylar position was deviated to the left side for about 0.71 mm with no mandibular rotational asymmetry. This is especially true in the moderate (1.19mm) and severe (1.22mm) AOB groups and in female patients (0.64mm). Good thing is that the condylar position become relatively symmetrical after orthodontic treatment, which means they mostly move towards the right sides after treatment. Both female and male patients have the mandible move to the right sides in accompany with lateral rotation of right condyle in female patients and left condyle in male teenager patients as well as medial inclination of the male adult patients. The asymmetry of mandibular position improved with treatment in teen patients, however, not quite so in adult patients. Betul et al. in 2023 have reported a positive correlation between inward rotation or medial rotation of the condyle (decrease ACA) and condyle remodeling after BSSO in CI III patients, independent of the apposition and resorption pattern, which we did not find in our study<sup>37</sup>. An asymmetry of condylar angle might cause TMD symptoms which we generally do not find in our patient pool in this study. Park et al. also found a decreased condylar axial angle in their study of condylar modeling after orthognathic surgery. They reported a mean decrease in the condylar axial angle of 5.7<sup>38</sup>. A change in the condylar axial angle may also result from condylar resorption from the superior aspect of the condyle. A smaller condylar axial angle may be a specific characteristic of ICR reported by Iwasa and Tanaka<sup>39</sup>. And we did not find any significant changes in the condylar axial angle before and after treatment, which could be a good thing to know as it indicates that orthodontic treatment does not predispose our AOB patient to further condylar resorption with orthodontic treatment.

Lastly as mentioned before, we found that the condylar volume overall increase after orthodontic treatment mainly in height (0.40 mm) and width (0.44 mm) of the condylar head

both in the Adult and Teen group. However, adult patients do not experience significant 3D volumetric change before and after treatment except in the Surgery group. The age of AOB patients has a moderate negative correlation with the changes in condylar width and 3D volume. Patients under 20 years old have a higher chance of condylar growth after treatment. The severity of AOB, however, does not affect the amount of dimensional or volumetric changes. Surgical patients have a higher volumetric increase which is about 3 times of the FFA group, and 4 times of the ALN group.

Patients treated with FFA and ALN does not have a significant difference in condylar volumetric changes. The condylar head mostly grows upwards, backwards, and laterally after treatment. Most of the changes we found are increase in dimension and volume, which is a positive trend as. Both Kristensen et al.<sup>40</sup> and Iwasa et al.<sup>39</sup> have found a reduced condylar width and height in ICR patients. Seon et al. also found that condylar width decreased significantly in patient with TMJ disc displacement<sup>41</sup>. On the other hand. Park et al.<sup>38</sup> and R J da Silva et al.<sup>42</sup> found a reduction in mean condylar volume after Orthognathic surgery in Cl II patients. In our study thought, the surgical patients of AOB may or may not have a component of the correction for Cl II or Cl III, but the overall trend is an increase in condylar volume.

## **7. Conclusion**

Overall, orthodontic treatment for AOB does not predispose patients to the risk of condylar resorption or dysfunction. The joint space changes are small, however, the direction of these changes in teenage patients may warrant closer examination and consideration in treatment planning. As AOB patients age, the amount of condylar changes decrease with no much significant changes in adult non-surgical patients. Surgical AOB patients may experience more condylar positive remodeling after treatment compared to the non-surgical patients.

## 8. References

1. Huang G, Baltuck C, Funkhouser E, et al. The National Dental Practice-Based Research Network Adult Anterior Open Bite Study: Treatment recommendations and their association with patient and practitioner characteristics. *Am J Orthod Dentofacial Orthop.* 2019;156(3):312-325. doi:10.1016/j.ajodo.2019.05.005
2. Tavares CAE, Allgayer S. Open bite in adult patients. *Dent Press J Orthod.* 2019;24(5):69-78. doi:10.1590/2177-6709.24.5.069-078.bbo
3. Tanaka E, Tanaka M, Watanabe M, Del Pozo R, Tanne K. Influences of occlusal and skeletal discrepancies on biomechanical environment in the TMJ during maximum clenching: an analytic approach with the finite element method. *J Oral Rehabil.* 2001;28(9):888-894. doi:10.1046/j.1365-2842.2001.00763.x
4. Arnett GW, Milam SB, Gottesman L. Progressive mandibular retrusion—idiopathic condylar resorption. Part II. *Am J Orthod Dentofacial Orthop.* 1996;110(2):117-127. doi:10.1016/S0889-5406(96)70099-9
5. Zupnik JT, Ioshida M, Yatabe M, et al. Three-dimensional analysis of condylar changes in surgical correction for open bite patients with skeletal class II and class III malocclusions. *Int J Oral Maxillofac Surg.* 2019;48(6):739-745. doi:10.1016/j.ijom.2019.01.004
6. Gomes LR, Soares Cevidanes LH, Gomes MR, et al. Three-dimensional quantitative assessment of surgical stability and condylar displacement changes after counterclockwise maxillomandibular advancement surgery: Effect of simultaneous articular disc repositioning. *Am J Orthod Dentofac Orthop Off Publ Am Assoc Orthod Its Const Soc Am Board Orthod.* 2018;154(2):221-233. doi:10.1016/j.ajodo.2017.10.030

7. Schiffman E, Ohrbach R, Truelove E, et al. Diagnostic Criteria for Temporomandibular Disorders (DC/TMD) for Clinical and Research Applications: recommendations of the International RDC/TMD Consortium Network\* and Orofacial Pain Special Interest Group†. *J Oral Facial Pain Headache*. 2014;28(1):6-27. doi:10.11607/jop.1151
8. Barghan S, Tetradis S, Mallya S. Application of cone beam computed tomography for assessment of the temporomandibular joints: CBCT of the TMJ. *Aust Dent J*. 2012;57:109-118. doi:10.1111/j.1834-7819.2011.01663.x
9. Fernandez-Gonzalez F, Canigral A, Lopez-Caballo J, et al. Influence of orthodontic treatment on temporomandibular disorders. A systematic review. *J Clin Exp Dent*. Published online 2015:e320-e327. doi:10.4317/jced.52037
10. Chen S, Lei J, Wang X, Fu K yuan, Farzad P, Yi B. Short- and Long-Term Changes of Condylar Position After Bilateral Sagittal Split Ramus Osteotomy for Mandibular Advancement in Combination With Le Fort I Osteotomy Evaluated by Cone-Beam Computed Tomography. *J Oral Maxillofac Surg*. 2013;71(11):1956-1966. doi:10.1016/j.joms.2013.06.213
11. Wei RY, Atresh A, Ruellas A, et al. Three-dimensional condylar changes from Herbst appliance and multibracket treatment: A comparison with matched Class II elastics. *Am J Orthod Dentofacial Orthop*. 2020;158(4):505-517.e6. doi:10.1016/j.ajodo.2019.09.011
12. Atresh A, Cevidanes LHS, Yatabe M, et al. Three-dimensional treatment outcomes in Class II patients with different vertical facial patterns treated with the Herbst appliance. *Am J Orthod Dentofacial Orthop*. 2018;154(2):238-248.e1. doi:10.1016/j.ajodo.2017.11.037

13. Xi T, van Luijn R, Baan F, et al. Three-dimensional analysis of condylar remodeling and skeletal relapse following bimaxillary surgery: A 2-year follow-up study. *J Cranio-Maxillofac Surg*. 2017;45(8):1311-1318. doi:10.1016/j.jcms.2017.06.006
14. Fakharian M, Bardideh E, Abtahi M. Skeletal Class III malocclusion treatment using mandibular and maxillary skeletal anchorage and intermaxillary elastics: a case report. *Dent Press J Orthod*. 2019;24(5):52-59. doi:10.1590/2177-6709.24.5.052-059.oar
15. Huang X, Cen X, Liu J. Effect of protraction facemask on the temporomandibular joint: a systematic review. *BMC Oral Health*. 2018;18(1):38. doi:10.1186/s12903-018-0503-9
16. Lee H, Son WS, Kwak C, et al. Three-dimensional changes in the temporomandibular joint after maxillary protraction in children with skeletal Class III malocclusion. *J Oral Sci*. 2016;58(4):501-508. doi:10.2334/josnusd.16-0251
17. Hameed Mohamed MA, Abdallah KF, Hussein FA. Three-Dimensional Assessment of Mandibular Condylar Volume and Position Subsequent to Twin Block Functional Therapy of Skeletal Class II Malocclusion Accompanied by Low-Level Laser Therapy. *Dent J*. 2020;8(4):115. doi:10.3390/dj8040115
18. Liu H, Xi X, Liu D. *Three-Dimensional Mandibular Changes Associated with Class II Elastics and Extractions Treatment in Adult Patients*. In Review; 2021. doi:10.21203/rs.3.rs-400695/v1
19. Gurbanov V, Bas B, Öz AA. Evaluation of Stresses on Temporomandibular Joint in the Use of Class II and III Orthodontic Elastics: A Three-Dimensional Finite Element Study. *J Oral Maxillofac Surg*. 2020;78(5):705-716. doi:10.1016/j.joms.2019.11.022

20. Melgaço CA, Neto JC, Jurach EM, Nojima M da CG, Nojima LI. Immediate changes in condylar position after rapid maxillary expansion. *Am J Orthod Dentofacial Orthop.* 2014;145(6):771-779. doi:10.1016/j.ajodo.2014.01.024
21. Hesse KL, Årtun J, Joondeph DR, Kennedy DB. Changes in condylar position and occlusion associated with maxillary expansion for correction of functional unilateral posterior crossbite. *Am J Orthod Dentofacial Orthop.* 1997;111(4):410-418. doi:10.1016/S0889-5406(97)80023-6
22. Moon D, Park JH, Lee GH. Orthodontic treatment for a patient with anterior open bite and severe condylar resorption. *Am J Orthod Dentofacial Orthop.* 2020;157(3):392-407.e2. doi:10.1016/j.ajodo.2018.10.030
23. Tanaka E, Kikuchi K, Sasaki A, Tanne K. An adult case of TMJ osteoarthritis treated with splint therapy and the subsequent orthodontic occlusal reconstruction: Adaptive change of the condyle during the treatment. *Am J Orthod Dentofacial Orthop.* 2000;118(5):566-571. doi:10.1067/mod.2000.93966
24. Sasaguri K, Ishizaki-Takeuchi R, Kuramae S, Tanaka EM, Sakurai T, Sato S. The Temporomandibular Joint in a Rheumatoid Arthritis Patient after Orthodontic Treatment. *Angle Orthod.* 2009;79(4):804-811. doi:10.2319/040708-201.1
25. Alhammadi MS, Fayed MS, Labib A. Three-dimensional assessment of condylar position and joint spaces after maxillary first premolar extraction in skeletal Class II malocclusion. *Orthod Craniofac Res.* 2017;20(2):71-78. doi:10.1111/ocr.12141
26. Ikeda K, Kawamura A. Disc displacement and changes in condylar position. *Dentomaxillofacial Radiol.* 2013;42(3):84227642. doi:10.1259/dmfr/84227642

27. Chen Y, Wang J, Li Y, et al. Age-related variations in position and morphology of the temporomandibular joint in individuals with anterior openbite and crossbite: a multi-cross-sectional comparative study. *BMC Oral Health*. 2022;22(1):200. doi:10.1186/s12903-022-02236-9
28. Diwakar R, Bucci R, Kaushik A, et al. Three-Dimensional Assessment of Temporomandibular Joint Morphology and Facial Asymmetry in Individuals with Different Vertical Skeletal Growth Patterns. *Int J Environ Res Public Health*. 2023;20(2):1437. doi:10.3390/ijerph20021437
29. Dalili Z, Khaki N, Kia S, Salamat F. Assessing joint space and condylar position in the people with normal function of temporomandibular joint with cone-beam computed tomography. *Dent Res J*. 2012;9(5):607. doi:10.4103/1735-3327.104881
30. Garnett BS, Mahood K, Nguyen M, et al. Cephalometric comparison of adult anterior open bite treatment using clear aligners and fixed appliances. *Angle Orthod*. 2019;89(1):3-9. doi:10.2319/010418-4.1
31. Ballesteros Acuña LE, Ramirez Aristeguieta LM, Muñoz Mantilla G. Mandibular Fossa Depth Variations: Relation to Age and Dental State. *Int J Morphol*. 2011;29(4):1189-1194. doi:10.4067/S0717-95022011000400020
32. Yun JM, Choi YJ, Woo SH, Lee UL. Temporomandibular joint morphology in Korean using cone-beam computed tomography: influence of age and gender. *Maxillofac Plast Reconstr Surg*. 2021;43(1):21. doi:10.1186/s40902-021-00307-5
33. Arieta-Miranda JM, Silva-Valencia M, Flores-Mir C, Paredes-Sampen NA, Arriola-Guillen LE. Spatial analysis of condyle position according to sagittal skeletal relationship,



assessed by cone beam computed tomography. *Prog Orthod.* 2013;14(1):36.  
doi:10.1186/2196-1042-14-36

34. Song J, Cheng M, Qian Y, Chu F. Cone-beam CT evaluation of temporomandibular joint in permanent dentition according to Angle's classification. *Oral Radiol.* 2020;36(3):261-266.  
doi:10.1007/s11282-019-00403-3

35. Paknahad M, Shahidi S, Akhlaghian M, Abolvardi M. Is Mandibular Fossa Morphology and Articular Eminence Inclination Associated with Temporomandibular Dysfunction? *J Dent Shiraz Iran.* 2016;17(2):134-141.

36. Derwich M, Mitus-Kenig M, Pawlowska E. Morphology of the Temporomandibular Joints Regarding the Presence of Osteoarthritic Changes. *Int J Environ Res Public Health.* 2020;17(8):2923. doi:10.3390/ijerph17082923

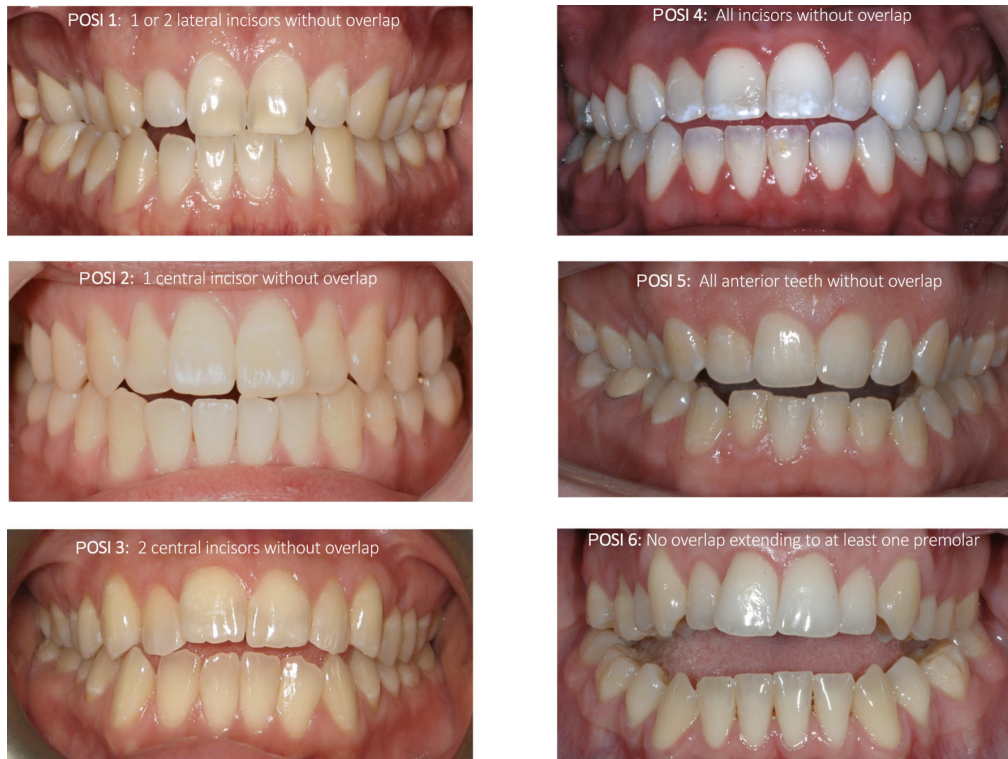37. Gulcek BN, Ozbilen EO, Biren S. Changes in the condylar head after orthognathic surgery in Class III patients: a retrospective three-dimensional study. *Angle Orthod.* 2023;93(2):168-175. doi:10.2319/052922-394.1

38. Park SB, Yang YM, Kim YI, Cho BH, Jung YH, Hwang DS. Effect of Bimaxillary Surgery on Adaptive Condylar Head Remodeling: Metric Analysis and Image Interpretation Using Cone-Beam Computed Tomography Volume Superimposition. *J Oral Maxillofac Surg.* 2012;70(8):1951-1959. doi:10.1016/j.joms.2011.08.017

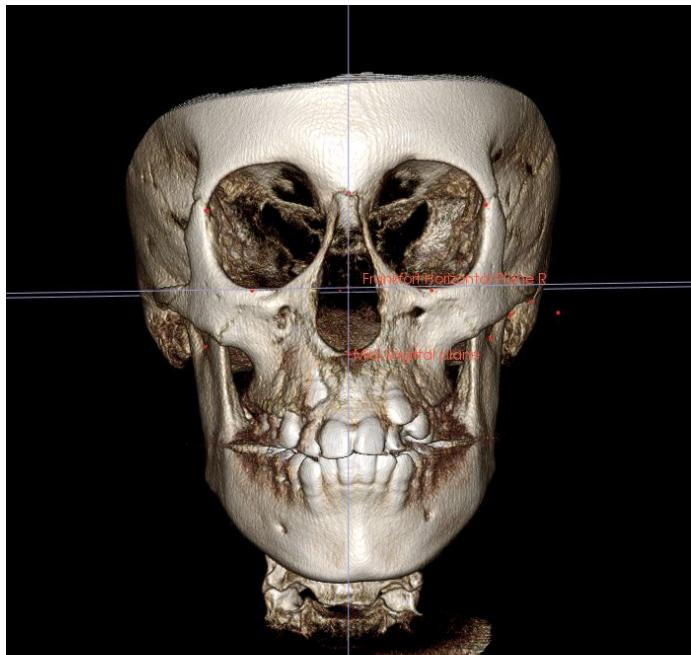
39. Iwasa A, Tanaka E. Signs, Symptoms, and Morphological Features of Idiopathic Condylar Resorption in Orthodontic Patients: A Survey-Based Study. *J Clin Med.* 2022;11(6):1552. doi:10.3390/jcm11061552

40. Kristensen KD, Schmidt B, Stoustrup P, Pedersen TK. Idiopathic condylar resorptions: 3-dimensional condylar bony deformation, signs and symptoms. *Am J Orthod Dentofacial Orthop.* 2017;152(2):214-223. doi:10.1016/j.ajodo.2016.12.020
41. Seo BY, An JS, Chang MS, Huh KH, Ahn SJ. Changes in condylar dimensions in temporomandibular joints with disk displacement. *Oral Surg Oral Med Oral Pathol Oral Radiol.* 2020;129(1):72-79. doi:10.1016/j.oooo.2019.04.010
42. da Silva RJ, Valadares Souza CV, Souza GA, et al. Changes in condylar volume and joint spaces after orthognathic surgery. *Int J Oral Maxillofac Surg.* 2018;47(4):511-517. doi:10.1016/j.ijom.2017.10.012

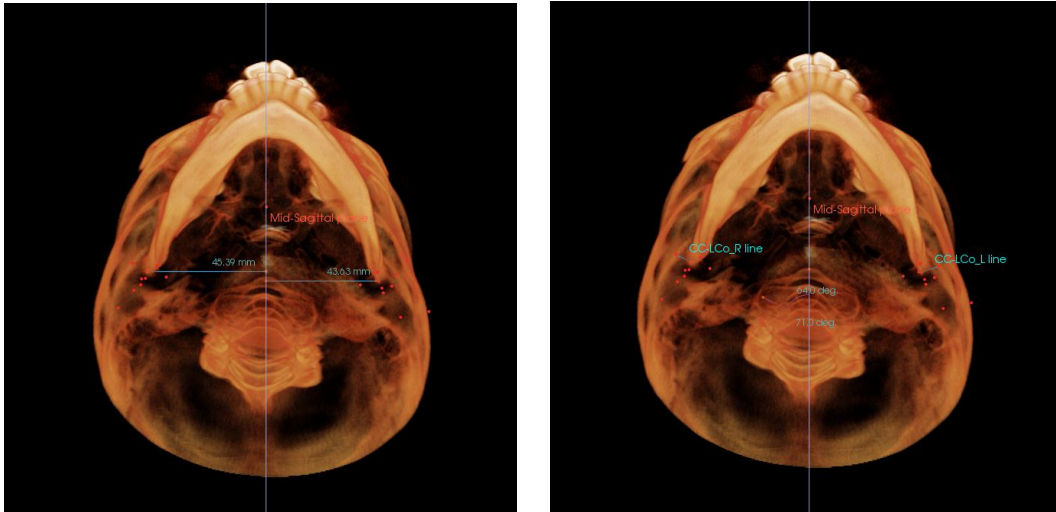
## Figures



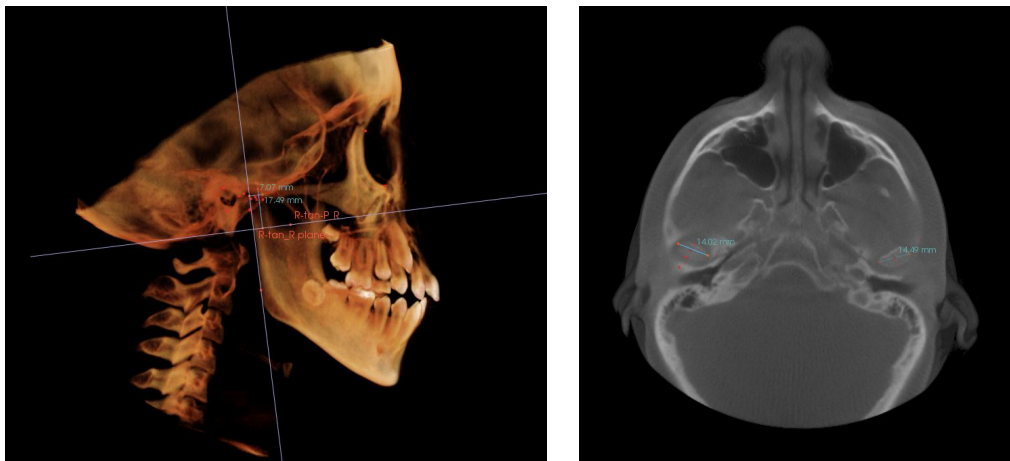
**Figure 1.** Photographic Openbite Severity Index (POSI) (With Courtesy to Huang G et al.<sup>1</sup>)



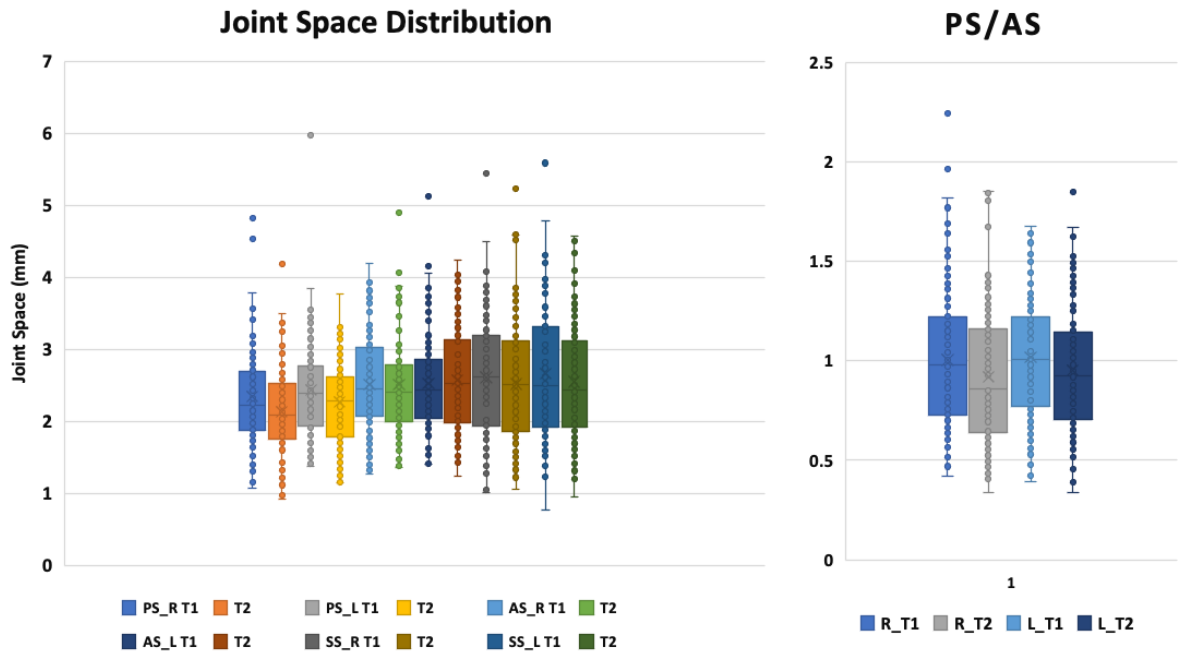
**Figure 2.** Head Orientation using InVivo 6.



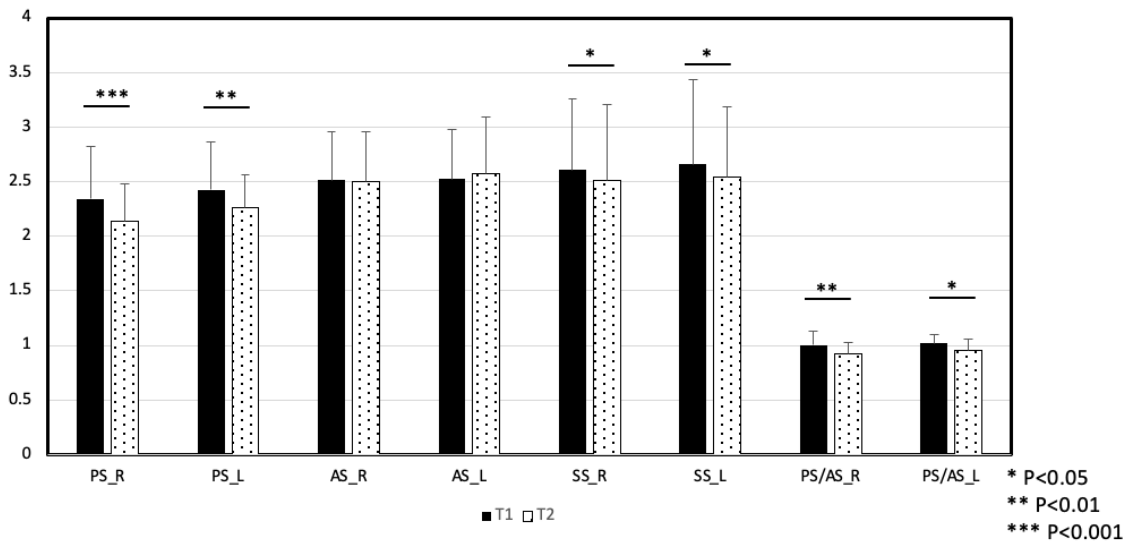
**Figure 3.** Measurement of LLCP and ACA from the axial view.



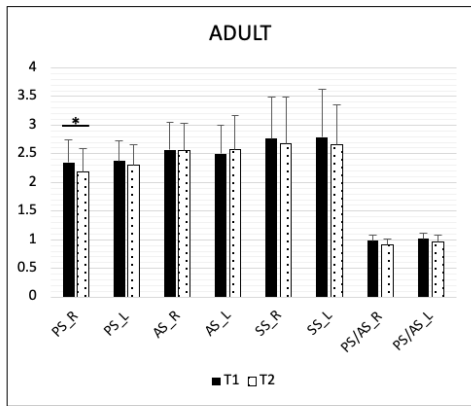
**Figure 4.** The automatic conjugation of condylar width, length, and height.



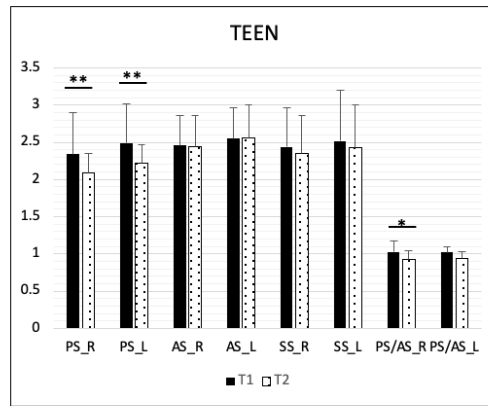
**Figure 5.** The data distribution of condylar joint space and PS/AS ratio.



**Figure 6.** The general changes of the TMJ joint spaces before and after treatment.



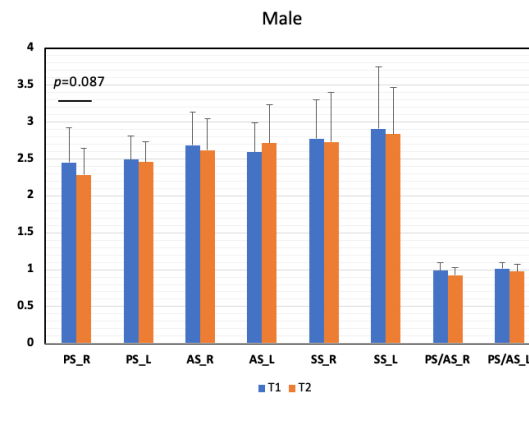
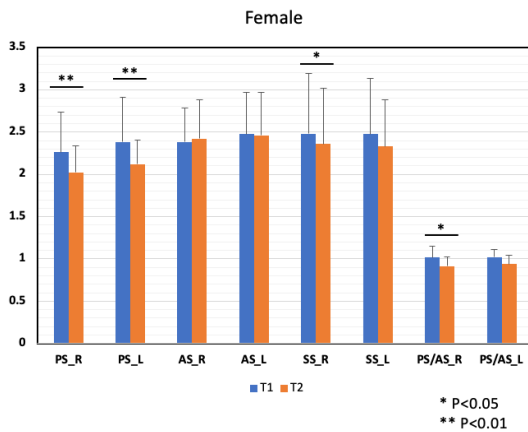
Average changes:  
 • PS\_R: -0.16mm



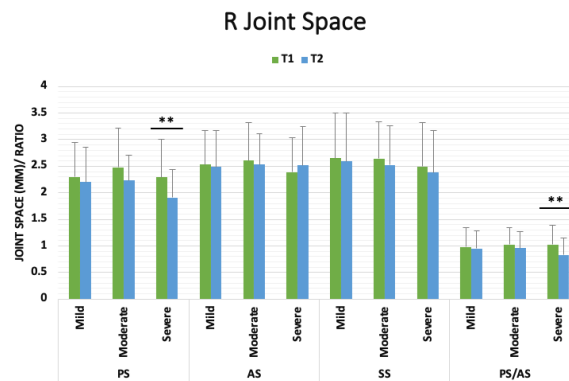
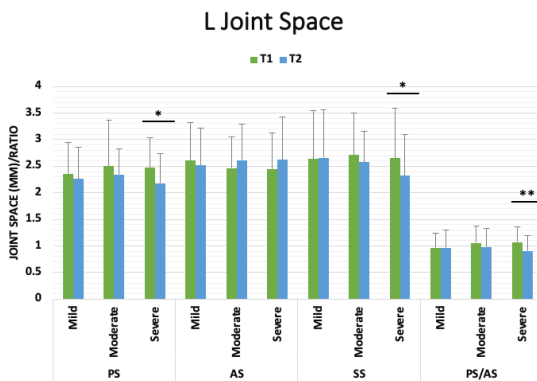
Average changes:  
 • PS\_R: -0.26mm  
 • PS\_L: -0.27mm  
 • PS/AS\_R: -0.10

\* P<0.05  
 \*\* P<0.01

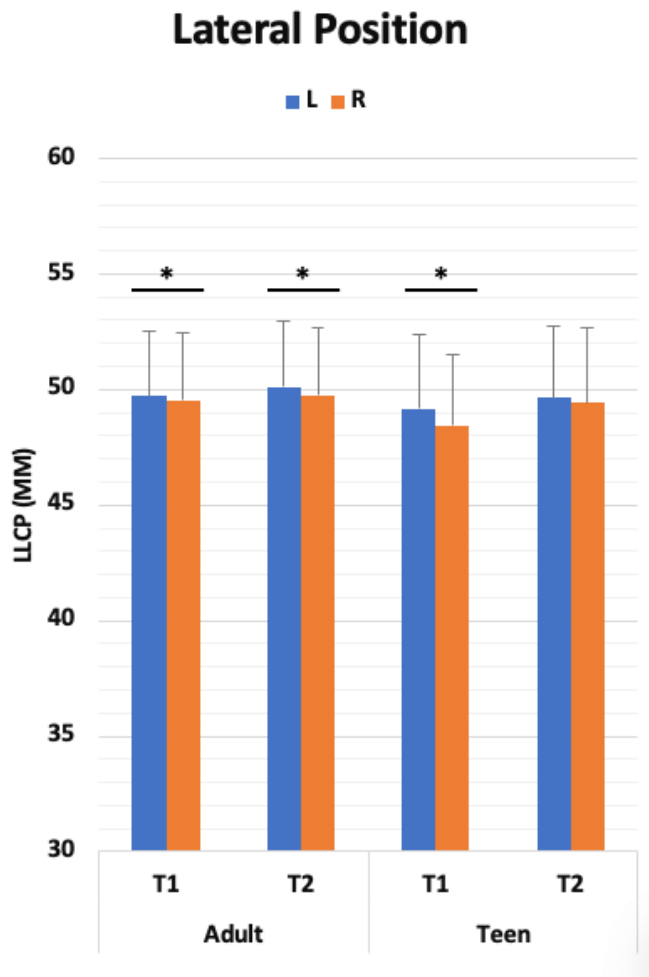
**Figure 7.** Condylar joint space changes in the Adult and Teen groups



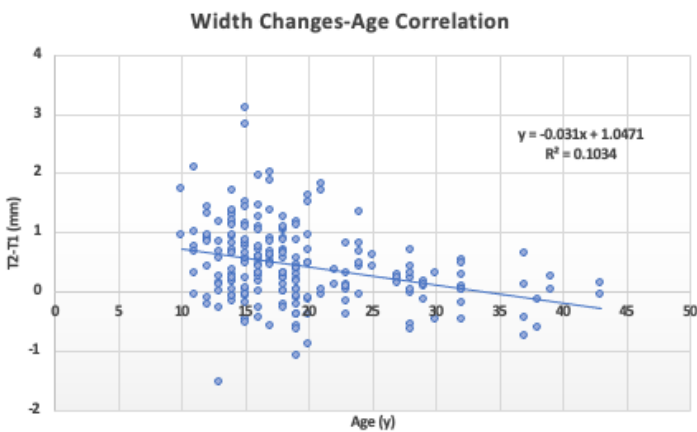
**Figure 8.** Condylar joint space changes in the Female and Male groups



**Figure 9.** Condylar joint space changes in different severity groups



**Figure 10.** LLCP between left and right side in different groups before and after treatment.



**Figure 11.** The correlation between age and the dimensional changes.

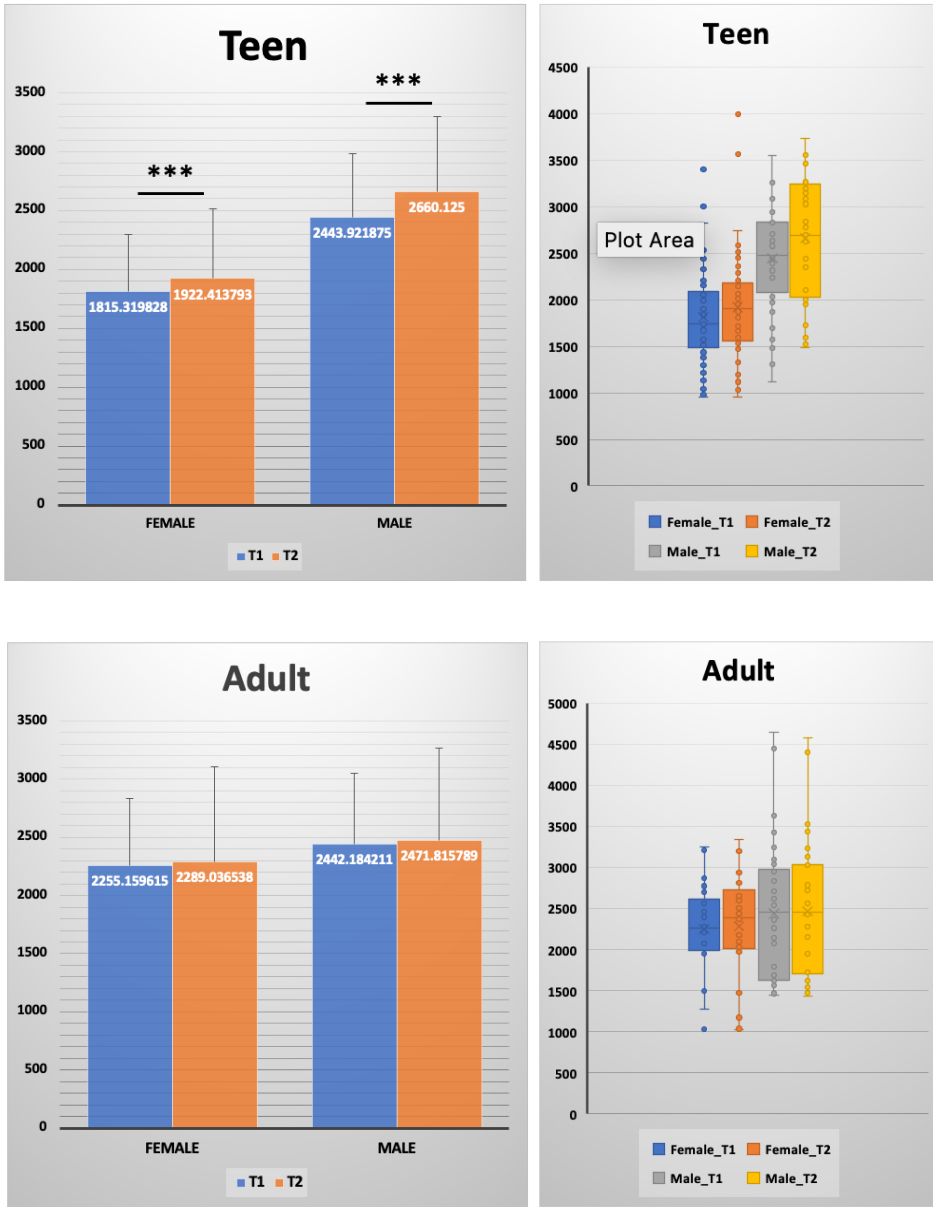
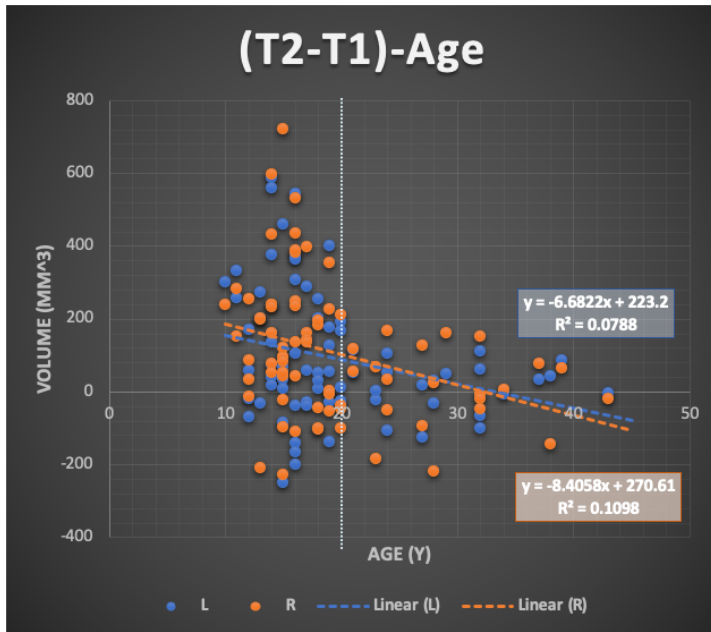
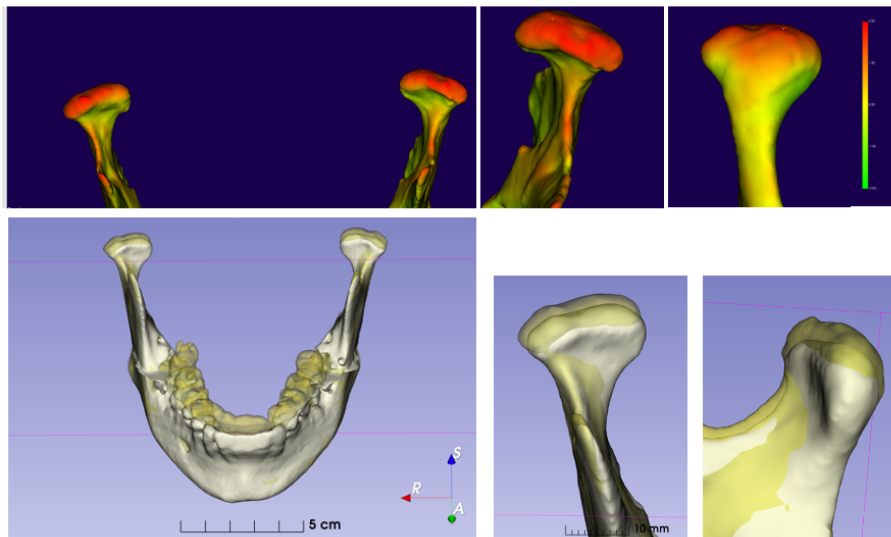


Figure 12. 3D volumetric changes of the condylar head in the Teen and Adult groups.

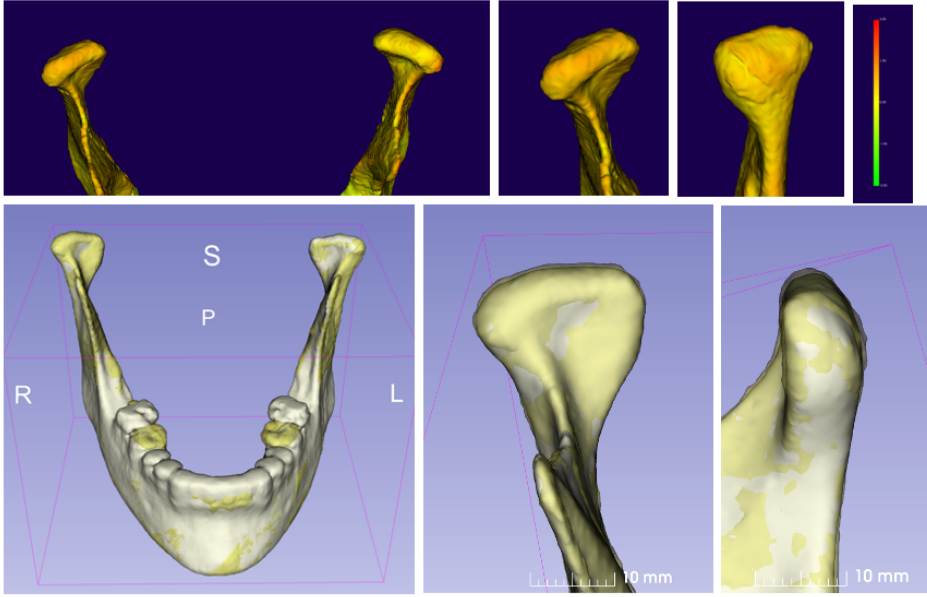




**Figure 13.** The correlation between 3D volumetric changes and age.



**Figure 14.** Condylar 3D superimposition of the average patients in the Teen group.



**Figure 15.** Condylar 3D superimposition of the average patients in the adult group.

**Table 1.** Landmarks used for automatic 3D TMJ measurements.

Landmarks	Definition
ArT	The most inferior point of the articular tubercle
EAM	The most inferior point of the auditory meatus.
Fo	The most deepest point of the glenoid fossa
PCo	The most posterior point of the condylar head
ACo	The most anterior point of the condylar head
SCo	The most superior point of the condylar head
PFo	The posterior wall of the articular tubercle
AFo	The anterior wall of the articular tubercle
SFo	The superior wall of the articular tubercle
LCo	The most lateral point of the condylar head
MCo	The most medial point of the condylar head
$\frac{1}{2}$ (LCo-MCo)	The midpoint of the lateromedial width of the condyle
$\frac{1}{2}$ (PCo-ACo)	The midpoint of the anteroposterior width of the condyle
Center of the Condyles (CC)	The midpoint of $\frac{1}{2}$ (PCo-ACo) and $\frac{1}{2}$ (LCo-MCo)
P	The posterior border of the condyle
R	The posterior border of the mandibular ramus
Sig	The deepest point of the sigmoid notch

**Table 2.** Sample size per group.

	Mild	Moderate	Severe	Total
<18y	25	13	14	52
≥18y	25	16	15	56
Total	50	29	29	108

ALN	FFA	SX	Total
15	60	33	108

**Table 3.** Mean value of general joint space changes after orthodontic treatment

Mean (mm)	PS_R	PS_L	AS_R	AS_L	SS_R	SS_L	PS/AS_R	PS/AS_L
T1	2.34	2.43	2.51	2.53	2.61	2.66	1.00	1.02
T2	2.13	2.26	2.51	2.57	2.52	2.55	0.92	0.95
T2-T1	-0.21	-0.17	-0.01	0.04	-0.09	-0.12	-0.09	-0.06
P-Value	<0.001	0.006	0.892	0.393	0.035	0.042	0.006	0.035

**Table 4.** Condylar positional symmetry before and after treatment.

Variables	T1				T2			
	R	L	Difference (R-L)	p-Value	R	L	Difference (R-L)	p-Value
LLCP (mm)	48.96	49.67	-0.71	0.005	49.55	50.09	-0.54	NS
ACA (°)	66.63	66.61	0.02	NS	66.91	67.33	-0.42	NS
CCA (°)	75.32	75.02	0.30	NS	74.51	75.16	-0.65	NS

Note: NS, Not significant (P > 0.05).  
LLCP, laterolateral condylar position; ACA, axial condylar angle; CCA, coronal condylar angle.  
Value are Mean

**Table 5.** Laterolateral condylar position in different genders at pre- and post-orthodontic treatment.

LLCP	T1				T2			
	R	L	Difference (R-L)	p-Value	R	L	Difference (R-L)	p-Value
Female	47.92	48.56	-0.64	0.031	48.55	48.66	-0.11	NS
Male	50.49	50.68	-0.18	NS	51.02	51.56	-0.54	NS

Note: NS, not significant (P > 0.05).

## Publishing Agreement

It is the policy of the University to encourage open access and broad distribution of all theses, dissertations, and manuscripts. The Graduate Division will facilitate the distribution of UCSF theses, dissertations, and manuscripts to the UCSF Library for open access and distribution. UCSF will make such theses, dissertations, and manuscripts accessible to the public and will take reasonable steps to preserve these works in perpetuity.

I hereby grant the non-exclusive, perpetual right to The Regents of the University of California to reproduce, publicly display, distribute, preserve, and publish copies of my thesis, dissertation, or manuscript in any form or media, now existing or later derived, including access online for teaching, research, and public service purposes.

DocuSigned by:  
  
682CAFEF5A4F4B9... Author Signature

5/29/2023  
Date