

UCLA

UCLA Previously Published Works

Title

Incidence of thrombus formation on the CardioSEAL and the Amplatzer interatrial closure devices

Permalink

<https://escholarship.org/uc/item/9sw9810n>

Journal

The American Journal of Cardiology, 93(4)

ISSN

0002-9149

Authors

Anzai, Hitoshi
Child, John
Natterson, Barbara
[et al.](#)

Publication Date

2004-02-01

DOI

10.1016/j.amjcard.2003.10.036

Copyright Information

This work is made available under the terms of a Creative Commons Attribution License, available at <https://creativecommons.org/licenses/by/4.0/>

Peer reviewed

Incidence of Thrombus Formation on the CardioSEAL and the Amplatzer Interatrial Closure Devices

Hitoshi Anzai, MD, John Child, MD, Barbara Natterson, MD, Janine Krivokapich, MD, Michael C. Fishbein, MD, Vicki K. Chan, BS, and Jonathan M. Tobis, MD

Transcatheter closure for atrial septal defect (ASD) and patent foramen ovale (PFO) is a promising alternative to surgical closure or anticoagulant therapy. A potential complication is thrombus formation on the device after implantation. From February 2001 to June 2003, 66 patients with atrial communication were treated successfully with the Amplatzer device (16 septal and 20 PFO occluders) or the CardioSEAL device (30). Patients were discharged on antiplatelet medication (aspirin and clopidogrel) and/or anticoagulation. Fifty patients (76%) had transesophageal echocardiography (TEE) 1 month after device implantation (28 ± 10 days). No patient experienced a thromboembolic episode during follow-up. TEE revealed that thrombus formation occurred more

frequently on the CardioSEAL device (5 of 23 patients; 22%) than on the Amplatzer device (0 of 27 patients; 0%) ($p = 0.02$). Although thrombus disappeared or markedly diminished after additional anticoagulation therapy in 3 patients, 1 patient had surgical explantation of the device due to progressive increase in the size of thrombus with hypermobility despite intensive anticoagulation therapy. There was no variable associated with the presence of thrombus formation on the occluder other than the use of the CardioSEAL device. One month after insertion, the CardioSEAL device is more likely to have thrombus present than the Amplatzer device. ©2004 by Excerpta Medica, Inc.

(Am J Cardiol 2004;93:426–431)

Several transcatheter closure devices for interatrial communications (secundum atrial septal defect [ASD] and patent foramen ovale [PFO]) have been developed,¹ but only the CardioSEAL device (Nitinol Medical Technologies, Inc., Boston, Massachusetts) and the Amplatzer device (AGA Medical Corporation, Golden Valley, Minnesota) are currently available in the United States. Although the performance and safety of these devices appear to be reliable, certain risks and complications remain. Thrombus formation on the device, which could lead to systemic embolization,^{2,3} is 1 of the major concerns with these implants. This study describes the incidence of thrombus formation on these devices detected by transesophageal echocardiography (TEE) 1 month after implantation.

METHODS

Patient population: From February 2001 to June 2003, 66 consecutive adult patients underwent transcatheter closure of an interatrial communication using the CardioSEAL or the Amplatzer device. Indications for PFO closure included the presence of spontaneous or provokable (with Valsalva maneuver) right to left shunt confirmed by a contrast study using agitated saline during TEE, and (1) a history of ≥ 1 cryptogenic stroke or transient ischemic attack, or (2) the presence of systemic hypoxemia that was partially attributable to right to left

shunt at the atrial level. Indications for ASD closure included: (1) the presence of a large left to right shunt (Qp/Qs ratio >1.5) and an enlarged right-sided cardiac chamber detected by echocardiography, with or without symptoms, or (2) a history of ≥ 1 cryptogenic stroke or transient ischemic attack.

Before treatment, the benefits and risks associated with transcatheter closure compared with other treatment options (anticoagulation or surgical closure) were explained. Patients were permitted to receive a PFO closure device only after consenting to the institutional review board protocol for use of these devices under the Humanitarian Device Exemption guideline.

Device descriptions: The Amplatzer occluder device is a self-expandable, double-disk device with a connecting waist made from a Nitinol wire mesh (0.004 to 0.0075 in). Dacron patches are sewn within each disk and the connecting waist, which serve to occlude blood flow through the device.⁴ The Amplatzer septal occluder device is available in sizes measured by the diameter of the connecting waist, ranging from 4 to 40 mm. The Amplatzer PFO occluder device comes in only 2 sizes, 25 and 35 mm, which describe the diameter of the larger right atrial disk. The CardioSEAL device is also a self-expanding device, which consists of 2 square “umbrellas” made by Dacron cloth that are attached to each other in the center.⁵ Each umbrella is supported by 4 nitinol spring arms radiating from the center of the device. The CardioSEAL device sizes, measured by the length of the diagonal of an umbrella, are 17, 23, 28, 33, and 40 mm.

Patients with ASD were treated with the Amplatzer septal occluder. When treating patients with a PFO, either the Amplatzer PFO occluder or the Cardio-

From the University of California, Los Angeles, Center for Health Sciences, Los Angeles, California. Manuscript received July 2, 2003; revised manuscript received and accepted October 10, 2003.

Address for reprints: Jonathan M. Tobis, MD, 10833 Le Conte Avenue, Room BL-394 CHS, Los Angeles, California 90095-1717. E-mail: jtobis@mednet.ucla.edu.

Age (yrs)	47 ± 14
Women	44 (67%)
Baseline disease	
PFO alone	48 (73%)
ASD alone	9 (14%)
PFO and ASD	4 (6%)
Fenestrated septum and PFO	5 (8%)
Atrial septal aneurysm	21 (32%)
Concomitant heart disease	
Dilated cardiomyopathy	2 (3%)
Ebstein's anomaly	2 (3%)
Transposition of great arteries	1 (2%)
Coagulation disorder	5 (8%)
Indication	
Large left to right shunt	13 (20%)
Paradoxical embolization	48 (73%)
Hypoxemia	5 (8%)

	Amplatzer (n = 36)	CardioSEAL (n = 30)
Aspirin and clopidogrel	28	22
Aspirin alone	1	0
Warfarin alone	5	1
Aspirin and warfarin	0	2
Clopidogrel and warfarin	1	0
Aspirin, clopidogrel, and warfarin	1	5

No statistical difference between the 2 groups.

	Amplatzer			CardioSEAL (n = 23)	p Value
	Septal Occluder (n = 14)	PFO Occluder (n = 13)	Total (n = 27)		
Residual shunt (small*)	6 (43%)	3 (23%)	9 (33%)	5 (22%)	0.36
Thrombus formation	0	0	0	5 (22%)	0.02
Device deformation	0	0	0	2 (9%)	0.21

*Small: color Doppler jet <2 mm through the defect or the presence of 3 to 9 microbubbles in the left atrium by contrast injection.

SEAL was chosen at the discretion of the operator. The CardioSEAL device became available first in our institution in February 2001 and was the only device available until November 2002 when the Amplatzer PFO occluder was approved.

Procedure: Patients were usually given aspirin (81 to 325 mg/day) and clopidogrel (75 mg/day) a few days before the procedure. When a patient had been taking warfarin, warfarin was discontinued 4 days before the procedure. The initial 5 consecutive patients had the procedure performed under general anesthesia with endotracheal intubation due to concerns about aspiration during prolonged TEE performance in the supine position. However, the procedures subsequent to August 2001 were performed without general anesthesia. TEE was used to guide the procedure to ensure that the device was optimally placed. Heparin was routinely administered at the start of the

procedure to achieve an activated clotting time of >250 seconds. Two patients had a history of suspected heparin-induced thrombocytopenia; therefore, argatroban was used for anticoagulation during the procedure instead of heparin.

Follow-up evaluation: Patients were usually discharged on aspirin (325 mg/day) and clopidogrel (75 mg/day). Amoxicillin was prescribed before dental work to prevent bacterial endocarditis. Warfarin use, in addition to antiplatelet therapy, was determined by the patient's concomitant disease, such as a hypercoagulation disorder, deep venous thrombosis, or pulmonary embolism. Patients were followed clinically and TEE was performed at 1 month after implantation.

Definitions of echocardiographic findings: The presence of a residual shunt at follow-up TEE examination was determined by color flow Doppler for left to right shunt⁶ and by agitated saline contrast injection into an antecubital vein for the presence of right to left shunt.⁷ These residual shunts were categorized as follows: (1) color flow Doppler, none: no color disturbances through the defect; small: color Doppler jet <2 mm through the defect; moderate to large: >2 mm through the defect; and (2) contrast injection, none: no microbubbles in the left atrium after injection of agitated saline; small: presence of 3 to 9 microbubbles in the left atrium; moderate: 10 to 30 microbubbles in the left atrium; and large: >30 microbubbles in the left atrium.

The diagnostic criteria for atrial septal aneurysm were a base width of >15 mm and septal excursion of >10 mm into the right or left atrium or bilateral excursions of >10 mm.⁸

The presence of thrombus on the device during follow-up was defined as a new hypoechogenic nonplanar, partially mobile structure.

Statistical analysis: Continuous variables were analyzed using *t* tests and dichotomous variables were analyzed using chi-square tests or Fisher's exact tests. Continuous variables are expressed as mean ± SD and dichotomous variables are expressed

as a frequency percentage. A *p* value of <0.05 was considered statistically significant.

RESULTS

Patient population: Sixty-six consecutive adult patients underwent transcatheter closure therapy of interatrial communications. The closure devices were successfully deployed in all 66 patients. Baseline demographics of the patients are shown in Table 1. Forty-four of the 66 patients (67%) were women; mean age was 47 ± 14 years (range 17 to 77). Most of the patients (n = 48) had a PFO alone (73%). There were morphologic variations of the ASD, including 5 fenestrated septums. An atrial septal aneurysm was found in 21 patients (32%). There were 5 patients who had concomitant heart disease (2 with dilated cardiomyopathy, 2 with Ebstein's anomaly, and 1 with transposition of the great arteries). Five patients were

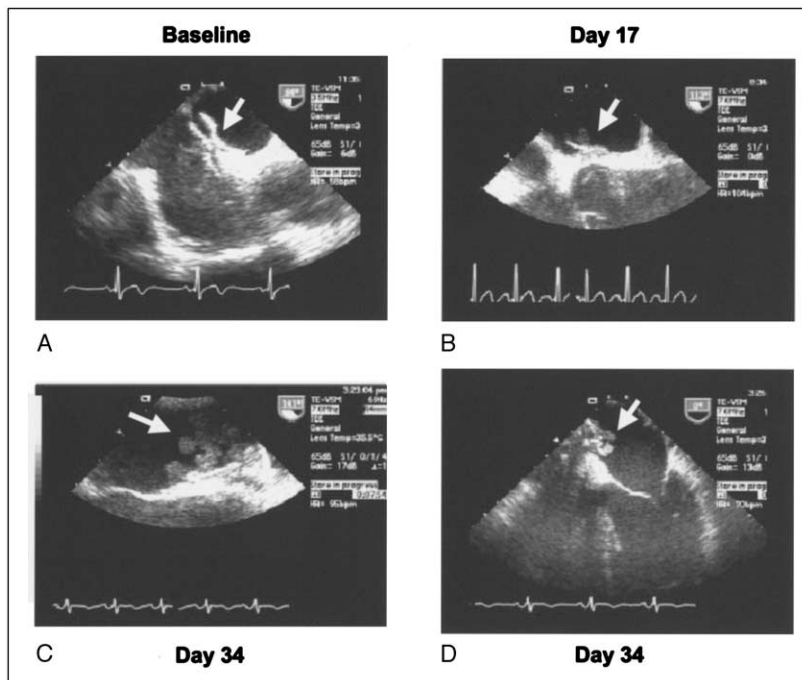


FIGURE 1. Serial TEE findings in a 32-year-old man with a PFO treated with a CardioSEAL device. (A) The CardioSEAL device was well seated on the atrial septum after implantation (arrow). The patient was given aspirin (81 mg/day) and clopidogrel (75 mg/day). (B) Seventeen days later, a TEE examination revealed an 8 × 8 mm hypo-echogenic lobular and mobile mass on the left atrial side of the device (arrow). The patient was asymptomatic and warfarin was initiated in addition to antiplatelet medication. (C and D) Two weeks later, a repeat TEE examination showed the mass to be enlarged dramatically with multiple lobulated mobile structures (arrows).




FIGURE 2. The patient was sent to surgery and the CardioSEAL was explanted. (A) Intraoperative finding of the CardioSEAL. A polypoid tissue mass was adherent to the left atrial side of the device (arrow). (B) Macroscopic examination of the detached mass. The tissue was composed of a round basal part (arrowhead) attached to the device with polypoid structures extending outward (arrows). The tissue had a mixture of white fibrous tissue and fresh red thrombus.

TABLE 4 Risk Factors for Thrombus Formation on the Device

	Without Thrombus (n = 45)	With Thrombus (n = 5)	p Value
CardioSEAL use	18 (40%)	5 (100%)	0.02
Device size (mm)	32 ± 6	28 ± 4	0.22
Transseptal approach	9 (20%)	2 (40%)	0.30
PFO	30 (67%)	5 (100%)	0.31
Residual shunt	13 (29%)	0	0.57
Post-warfarin use	11 (24%)	0	0.63
Atrial septal aneurysm	13 (29%)	2 (40%)	0.65
Women	31 (69%)	3 (60%)	0.96
Age (yrs)	46 ± 13	46 ± 12	>0.99
Coagulation disorder	3 (7%)	0	

found to have a hypercoagulable state consisting of anticardiolipin antibodies (1), factor VIII elevation (1), prothrombin 20210A variant (1), protein C deficiency (1), and protein S deficiency (1). The indication for closure consisted of ischemic cerebral events due to presumed paradoxical embolization in 48 patients (73%), large left to right shunt in 13 patients with ASDs (20%), and arterial hypoxemia due to right to left shunt in 5 patients (4 chronic arterial hypoxemia and 1 platypnea orthodeoxia) (8%).

Procedural results: The devices were successfully deployed in all patients. The CardioSEAL device was used in 30 patients (45%), the Amplatzer septal occluder device in 16 patients (24%), and the Amplatzer PFO occluder device in 20 patients (30%). Two patients had 2 CardioSEAL devices implanted during the same procedure. One of these 2 patients presented with a large atrial septal aneurysm and a long PFO and the other patient had a fenestrated septum with 3 separate shunts. All procedures were performed with TEE guidance, ex-

cept 1 in which the patient was not able to tolerate the TEE probe. Intracardiac echocardiographic imaging was used instead of TEE.⁹ A transseptal puncture technique was used in 11 patients (17%)¹⁰ because the PFO was long or there was a large atrial septal aneurysm.

Follow-up TEE results: Patients were treated with several antithrombotic regimens after implantation, but there was no difference in treatment between patients who received the CardioSEAL or the Amplatzer device (Table 2).

Fifty of 66 patients (76%) were evaluated by TEE at 28 ± 10 days (range 7 to 47) after implantation. Follow-up TEE was not scheduled in the initial 4 patients. Six patients were not able to have follow-up TEE because of their unstable health conditions. One patient could not tolerate the TEE examination. One patient died because of severe underlying disease (pulmonary embolism, myocardial infarction, and multiple embolic cerebral infarctions) before the follow-up TEE. The other 4 patients have not undergone follow-up TEE examination yet. Table 3 outlines the TEE findings at 1 month after implantation between the CardioSEAL and the Amplatzer devices. The incidence of a small residual shunt did not differ between the CardioSEAL and the Amplatzer devices (22% vs 33%, p = 0.36). All residual shunts were small (color Doppler jet <2 mm through the defect or the presence of 3 to 9 microbubbles in the left atrium by contrast injection).

The Amplatzer device had no deformation, such as

TABLE 5 Previous Reports of Thrombus Formation on Septal Occlusion Devices

Author	No. and Device	Baseline Disorder	Time of Follow-up TEE	Antithrombotic Medication Postimplantation	Incidence of Thrombus	Outcome of Thrombus
Sievert et al ¹⁶	139 ASDOS	ASD or PFO	1–4 wks	Warfarin or aspirin	9 (6%)	1 Cerebral embolization 1 Surgically explanted 7 Resolved without symptoms All resolved without symptoms
Sievert et al ¹⁷	37 CardioSEAL 57 Amplatzer 26 Sideris buttoned 11 ASDOS 19 Angel Wings 98 PFO Star 33 Helex	PFO	2 wks–6 mon	Aspirin or Warfarin or aspirin + clopidogrel	7 (2.5%) 1 Angel Wings 1 ASDOS 1 CardioSEAL 4 PFO Star	All resolved without symptoms
Krumsdorf et al ⁶	12 CardioSEAL 16 Amplatzer 26 Sideris buttoned 3 Angel Wings 25 PFO Star 7 Helex	ASD or PFO with ASA	First 4 wks	Aspirin + clopidogrel	3 (6%) 3 PFO Star	1 TIA 2 Resolved without symptoms
La Rosee ¹⁸	22 ASDOS	ASD or PFO	3 d–4 wks	Warfarin	6 (27%)	All resolved without symptoms
Franke ¹⁹	32 CardioSEAL 4 ASDOS 2 Amplatzer	ASD or PFO	1–6 mon	Warfarin or aspirin + clopidogrel	5 (13%)	1 Surgically explanted 4 Resolved without symptoms

ASA = atrial septal aneurysm; ASD = atrial septal defect; ASDOS = ASD Occlusion System (Sulger-Osyпка, Germany); TIA = transient ischemic attack.

a cobra-like structure.¹¹ However, there were 2 CardioSEAL devices with abnormal positions of the arms. On these devices, 1 of the 4 spring arms was in an abnormal position, perpendicular to the plane of the cloth sheet. One of these occurred on the left atrial side and 1 in the right atrium. Dislodgement or erosion was not observed with either device.

Incidence of thrombus: Thrombus formation was detected on the device in 5 of 50 patients (10%). However, all of the patients with thrombus received the CardioSEAL device. No patient who received the Amplatzer device had thrombus on the device (5 of 23 patients, 22% vs 0 of 27 patients, 0%, $p = 0.02$) (Table 3). The size of thrombus ranged from 5 to 8 mm at the first follow-up TEE examination. Thrombus was attached on the left atrial side in 4 patients and on the right atrial side in 1 patient. The thrombus was mobile in 3 patients. In 3 of 5 patients with thrombus formation on the device, the thrombus resolved after anticoagulation therapy with warfarin. One patient did not have a repeat TEE examination. In 1 patient, the CardioSEAL device was surgically removed because of continuous growth of thrombus on the device despite initiation of intensive anticoagulation therapy (Figures 1 and 2). No patient developed a thromboembolic episode during the 2.5-year follow-up period, including those patients with thrombus formation on the device.

Predictors for thrombus formation on the device: An analysis of risk factors for thrombus formation on the device is shown in Table 4. Use of the CardioSEAL device was the only variable associated with the presence of thrombus formation on the device ($p = 0.02$).

DISCUSSION

Although results from recent reports are encouraging,^{12–14} there remain several possible complications

related to transcatheter closure of interatrial communications. These include air embolism, device embolization, atrial perforation, device malposition, residual shunt, device arm fracture, arrhythmia, infection, and thrombus formation on the device. Although most of these complications are caused by technical problems and may be solved by refinements of the device and implantation technique, thrombus formation on the device is still a major concern because it may result in embolic events and recurrent neurologic deficits.^{2,15}

A summary of previous reports^{6,16–19} describing thrombus formation on these devices is listed in Table 5. The incidence of thrombus in these studies varied between 3% and 27%. Our results were comparable in terms of the incidence of thrombus formation on the device, the tendency for thrombus to resolve subsequently, and the observation that no thrombus has been reported on the Amplatzer device. Although the shape and structure of these devices are different, there is no obvious reason why there should be a difference in thrombus or scar formation. The Amplatzer device consists of Nitinol metal with smooth rounded disks. The polyester fabric of the Amplatzer is sewn inside the meshed disks; in the CardioSEAL device, the fabric is directly exposed to blood (Figure 3). The structure and composition could affect the process of endothelialization on the 2 devices. Endothelialization and scar tissue formation on the implanted device is necessary to obtain complete closure of the atrial communication and is believed to be necessary to prevent thrombus formation. Although animal studies show sufficient cell proliferation covering the device 4 weeks after implantation, in human hearts the detailed time course of endothelialization is not known.^{20,21} Another potential reason might be




FIGURE 3. (A) The CardioSEAL is composed of 2 square sheets of polyester fabric each attached to 4 nitinol springs. There is a central pin that connects to a delivery cable. The CardioSEAL device is available in sizes from 17 to 34 mm measured at the diagonal of the fabric sheet. **(B)** The Amplatzer PFO occluder device consists of 2 circular discs made from nitinol that spring back into the disc shape when released from the introducing sheath. There is a thin wafer of polyester fabric within each disc to promote the seal and eventual fibrosis. Although both devices consist of polyester fabric and nitinol springs, the configuration and relative amount of these materials differs greatly between the 2 devices.

different antithrombotic regimens after implantation or unknown underlying hypercoagulation disorders, including aspirin resistance.²² Warfarin is known to have a procoagulant effect during initiation,²³ and there is 1 report that has suggested that anticoagulation with warfarin after implantation has a tendency toward a higher rate of thrombus on the device compared with antiplatelet therapy.¹⁹ However, in our study, all 5 patients who experienced thrombus formation did not have warfarin initially after implantation.

Previous reports document that most recurrent neurologic events after percutaneous closure of PFO occurred within the first year after device implantation.^{12,24–26} This has been ascribed to incomplete closure of the PFO. Several reports indicate a close association between the recurrence of embolic events and a residual shunt.^{25,27} It has also been reported that there is a gradual reduction of the residual shunt after implantation associated with the healing process.^{28,29} However, there are patients without a residual shunt who have recurrent neurologic symptoms.³⁰ It is possible in these cases that thrombus formed on the left side of the device, producing embolic events before the device surface was completely endothelialized. These TEE observations may be visualizing a part of the natural healing process, in which thrombus evolves into a fibrous scar. The finding of hypoechogenic structures on the device does not necessarily imply that embolization is imminent; these may resolve with time, with or without anticoagulation therapy. However, the mobile polypoid structure seen in Figure 1 may carry a higher risk of embolization. The primary distinction of this report is that none of these hypoechogenic structures suggestive of thrombus was seen on the Amplatzer devices.

1. Rao PS. Summary and comparison of atrial septal defect closure devices. *Curr Interv Cardiol Rep* 2000; 2:367–376.
2. Khatchaturov G, Kalangos A, Anwar A, Urban P, De Moerloose P, Friedli B, Faidutti B. Massive thromboembolism due to transcatheter ASD closure with ASDOS device. *J Invasive Cardiol* 1999;11:743–745.
3. Bohm J, Bittigau K, Kohler F, Baumann G, Konertz W. Surgical removal of atrial septal defect occlusion system-devices. *Eur J Cardiothorac Surg* 1997;12: 869–872.
4. Harper RW, Mottram PM, McGaw DJ. Closure of secundum atrial septal defects with the Amplatzer septal occluder device: techniques and problems. *Cathet Cardiovasc Intervent* 2002;57:508–524.
5. Latson LA. The CardioSEAL device: history, techniques, results. *J Interv Cardiol* 1998;11:501–505.
6. Krumsdorf U, Keppeler P, Horvath K, Zadan E, Schrader R, Sievert H. Catheter closure of atrial septal defects and patent foramen ovale in patients with an atrial septal aneurysm using different devices. *J Interv Cardiol* 2001;14:49–55.
7. Mas JL, Arquizan C, Lamy C, Zuber M, Cabanes L, Derumeaux G, Coste J. Patent Foramen Ovale and Atrial Septal Aneurysm Study Group. Recurrent cerebrovascular events associated with patent foramen ovale, atrial septal aneurysm, or both. *N Engl J Med* 2001;345:1740–1746.
8. Olivares-Reyes A, Chan S, Lazar EJ, Bandlamudi K, Narla V, Ong K. Atrial septal aneurysm: a new classification in two hundred five adults. *J Am Soc Echocardiogr* 1997;10:644–656.
9. Bartel T, Konorza T, Arjumand J, Ebradlidze T, Eggebrecht H, Caspari G, Neudorf U, Erbel R. Intracardiac echocardiography is superior to conventional monitoring for guiding device closure of interatrial communications. *Circulation* 2003;107:795–797.
10. Ruiz CE, Alboliras ET, Pophal SG. The puncture technique: a new method for transcatheter closure of patent foramen ovale. *Catheter Cardiovasc Interv* 2001;53:369–372.
11. Mazic U, Gavora P, Masura J. “Cobra-like” deformation of an Amplatzer septal occluder. *Pediatr Cardiol* 2001;22:253–254.
12. Martin F, Sanchez PL, Doherty E, Colon-Hernandez PJ, Delgado G, Inglessis I, Scott N, Hung J, King ME, Buonanno F, et al. Percutaneous transcatheter closure of patent foramen ovale in patients with paradoxical embolism. *Pediatr Cardiol* 2001;22:253–254.
13. Bruch L, Parsi A, Grad MO, Rux S, Burmeister T, Krebs H, Kleber FX. Transcatheter closure of interatrial communications for secondary prevention of paradoxical embolism: single-center experience. *Circulation* 2002;105:2845–2848.
14. Chessa M, Carminati M, Butera G, Bini RM, Drago M, Rosti L, Giamberti A, Pome G, Bossone E, Frigiola A. Early and late complications associated with transcatheter occlusion of secundum atrial septal defect. *J Am Coll Cardiol* 2002;39:1061–1065.
15. Nkomo VT, Theuma P, Mani CV, Chandrasekaran K, Miller FA, Schaff HV, Petty GW, Miller TD. Patent foramen ovale transcatheter closure device thrombosis. *Mayo Clin Proc* 2001;76:1057–1061.
16. Sievert H, Babic UU, Hausdorf G, Schneider M, Hopp HW, Pfeiffer D, Pfisterer M, Friedli B, Urban P. Transcatheter closure of atrial septal defect and patent foramen ovale with ASDOS device (a multi-institutional European trial). *Am J Cardiol* 1998;82:1405–1413.
17. Sievert H, Horvath K, Zadan E, Krumsdorf U, Fach A, Merle H, Scherer D, Schrader R, Spies H, Nowak B, Lissmann-Jensen H. Patent foramen ovale closure in patients with transient ischemia attack/stroke. *J Interv Cardiol* 2001;14:261–266.
18. La Rosee K, Deutsch HJ, Schnabel P, Schneider CA, Burkhard-Meier C, Hopp HW. Thrombus formation after transcatheter closure of atrial septal defect. *Am J Cardiol* 1999;84:356–359.
19. Franke A, Kuhl HP, Muhler EG, Nussbaum J, Visser L, Lepper W, Hanrath P. Frequency of occluder-related atrial thrombi despite different prophylactic therapy after transcatheter closure of a patent foramen ovale (abstr). *Eur Heart J* 2000;21:25.
20. Lock JE, Rome JJ, Davis R, Van Praagh S, Perry SB, Van Praagh R, Keane JF. Transcatheter closure of atrial septal defects. Experimental studies. *Circulation* 1989;79:1091–1099.
21. Sharafuddin MJ, Gu X, Titus JL, Urness M, Cervera-Ceballos JJ, Amplatz K. Transvenous closure of secundum atrial septal defects: preliminary results with a new self-expanding nitinol prosthesis in a swine model. *Circulation* 1997;95: 2162–2168.
22. Gum PA, Kottke-Marchant K, Welsh PA, White J, Topol EJ. A prospective, blinded determination of the natural history of aspirin resistance among stable patients with cardiovascular disease. *J Am Coll Cardiol* 2003;41:961–965.

23. Freedman JE, Adelman B. Pharmacology of heparin and oral anticoagulants. In: Loscalzo J, Schafer AI, eds. *Thrombosis and Hemorrhage*. Boston: Blackwell Scientific, 1994:1155–1171.
24. Braun MU, Fassbender D, Schoen SP, Haass M, Schraeder R, Scholtz W, Strasser RH. Transcatheter closure of patent foramen ovale in patients with cerebral ischemia. *J Am Coll Cardiol* 2002;39:2019–2025.
25. Windecker S, Wahl A, Chatterjee T, Garachemani A, Eberli FR, Seiler C, Meier B. Percutaneous closure of patent foramen ovale in patients with paradoxical embolism: long-term risk of recurrent thromboembolic events. *Circulation* 2000;101:893–898.
26. Meier B, Lock JE. Contemporary management of patent foramen ovale. *Circulation* 2003;107:5–9.
27. Wahl A, Meier B, Haxel B, Nedeltchev K, Arnold M, Eicher E, Sturzenegger M, Seiler C, Mattle HP, Windecker S. Prognosis after percutaneous closure of patent foramen ovale for paradoxical embolism. *Neurology* 2001;57:1330–1332.
28. Omeish A, Hijazi ZM. Transcatheter closure of atrial septal defects in children & adults using the Amplatzer Septal Occluder. *J Interv Cardiol* 2001; 14:37–44.
29. Rao PS, Berger F, Rey C, Haddad J, Meier B, Walsh KP, Chandar JS, Lloyd TR, de Lezo JS, Zamora R, Sideris EB. Results of transvenous occlusion of secundum atrial septal defects with the fourth generation buttoned device: comparison with first, second and third generation devices. International Buttoned Device Trial Group. *J Am Coll Cardiol* 2000;36:583–592.
30. Braun MU, Fassbender D, Schoen SP, Haass M, Schraeder R, Scholtz W, Strasser RH. Transcatheter closure of patent foramen ovale in patients with cerebral ischemia. *J Am Coll Cardiol* 2002;39:2019–2025.