

UC Irvine

UC Irvine Previously Published Works

Title

Curved adjustable fiberoptic laser for endoscopic cholesteatoma surgery.

Permalink

<https://escholarship.org/uc/item/9sx0v8j0>

Journal

Otology & neurotology : official publication of the American Otological Society, American Neurotology Society [and] European Academy of Otology and Neurotology, 36(1)

ISSN

1531-7129

Authors

Yau, Amy Y
Mahboubi, Hossein
Maducdoc, Marlon
[et al.](#)

Publication Date

2015

DOI

10.1097/mao.0000000000000527

Peer reviewed

Curved Adjustable Fiberoptic Laser for Endoscopic Cholesteatoma Surgery

*Amy Y. Yau, *Hossein Mahboubi, *Marlon Maducdoc, *Yaser Ghavami,
and *†Hamid R. Djalilian

*Division of Neurotology and Skull Base Surgery, Department of Otolaryngology–Head and Neck Surgery, and
†Department of Biomedical Engineering, University of California, Irvine, California, U.S.A.

Objective: To determine whether endoscopic cholesteatoma removal can be performed efficiently and safely using a curved fiberoptic-based laser.

Background: Angled instruments are required in endoscopic ear surgery to access recesses of the middle ear without extra drilling. Lasers are effective at ablating visible and microscopic cholesteatoma matrix and removing granulation tissue.

Study Design: Retrospective case review from 2006 to 2013.

Setting: Single tertiary care center.

Patients: Patients who underwent cholesteatoma surgery with otoendoscopy.

Intervention: Residual cholesteatoma that could not be reached by conventional microinstruments was identified using an endoscope. This residual cholesteatoma was ablated in a contactless manner using a fiberoptic-based curved laser carrier with an argon laser. The

laser tip through the carrier probe has a 45-degree curve, and the length of the tip is adjustable, allowing it to be used in recesses or around corners, such as in the sinus tympani, around the stapes suprastructure, in the oval window, or in the Eustachian tube orifice.

Main Outcome Measures: Presence or absence of residual cholesteatoma after laser ablation and complications.

Results: In 7 cases, the fiberoptic curved laser was used to ablate cholesteatoma completely with no injury to surrounding structures and with no evidence of recidivism with a mean follow-up period of 19 months. There were no cases of sensorineural hearing loss or perilymphatic fistula.

Conclusion: The curved laser probe allows for precise removal of cholesteatoma endoscopically. **Key Words:** Cholesteatoma—Endoscope—Fiberoptic—Laser.

Otol Neurotol 36:61–64, 2015.

Endoscopic otologic surgery has been gaining popularity over the last 2 decades. Otoendoscopy has been recognized as an alternative method of removing cholesteatoma from the tympanic cavity proper and the attic (1). Several authors, including the International Working Group on Endoscopic Ear Surgery, recommend the use of the endoscope in removing certain cholesteatomas via a transcanal tympanoplasty method without the need for a mastoidectomy (2–4). Other authors advocate the use of

the otoendoscope as an adjunct tool in addition to traditional mastoidectomy and microsurgery to remove cholesteatoma in the middle ear (5–10).

The otoendoscope allows for visualization around the corners in the middle ear and mastoid. Angled picks and forceps are required in endoscopic ear surgery to access recesses of the middle ear without extra drilling. Despite this, the scutum and bony rim of the medial external auditory canal are often required to be removed by drills or bone curette (2–4). New angled instruments have been designed for endoscopic cholesteatoma surgery (11); however, these instruments may not be able to reach around tight corners or remove or ablate cholesteatoma while maintaining a clear, blood-free visual field in a one-handed format. Lasers have been verified as tools that are effective at ablating visible and microscopic cholesteatoma matrix and removing granulation tissue (12,13). New fiberoptic laser cables and slim carriers for the laser fiber provide the surgeon the ability to perform certain otologic surgeries in a blood-free field with one hand only. We present the novel use of a curved, adjustable fiberoptic-based laser carrier for endoscopic otologic surgery that is able to reach around corners and ablate cholesteatoma. We aimed to determine

Address correspondence and reprint requests to Hamid R. Djalilian, M.D., Division of Neurotology and Skull Base Surgery, Department of Otolaryngology–Head and Neck Surgery, University of California, Irvine, Otolaryngology-5386, 19182 Jamboree Road, Irvine, CA 92697; E-mail: hdjalili@uci.edu

Primary author and presenter of abstract: Amy Y. Yau, M.D., Department of Otolaryngology–Head and Neck Surgery, University of California, Irvine, Otolaryngology-5386, 19182 Jamboree Road, Irvine, CA 92697 Email: yyau@uci.edu

Institutional Review Board Status: Approved.

This study has been presented as a poster at the 2014 American Otological Society Spring Meeting at Combined Otolaryngology Spring Meetings, May 2014.

The authors disclose no conflicts of interest.

Supplemental digital content is available in the text.

whether endoscopic cholesteatoma removal could be performed efficiently and safely using a curved fiberoptic-based laser.

MATERIALS AND METHODS

A retrospective review was performed of patients who underwent endoscopic-assisted removal of cholesteatoma between 2006 and 2013. Demographic data, location and extent of cholesteatoma, and postoperative course were recorded. Institutional review board from the University of California, Irvine, was obtained. All surgical cases were performed by the senior author.

Surgical Technique

Traditional microsurgery for cholesteatoma removal was first performed. The tympanomeatal flap was raised, followed by mastoidectomy if necessary, either in a partial canal wall down (atticotomy) or a canal wall up fashion. The type of mastoidectomy, if performed, was dictated by the extent and location of cholesteatoma spread. If the cholesteatoma involved the mastoid, past the antrum, a mastoidectomy was performed. An atticotomy or inside-out mastoidectomy was performed for patients with contracted mastoids with cholesteatoma involvement. After cholesteatoma that was visible and accessible with microscopy was removed, a 30-degree 2.6-mm rigid otoendoscope (Karl Storz, El Segundo, CA, USA) was used to evaluate the middle ear and mastoid cavity for any residual cholesteatoma. With endoscopic assistance, cholesteatoma was first attempted to be removed using a combination of curved suction and angled microdissectors. After this, the otoendoscope was used to reevaluate the space to verify complete removal.

In cases where the curved suction and instruments were not able to reach or remove the residual cholesteatoma, the Iridex Adjustable and Intuitive Endo Ocular Probe (14573T; Iridex, Mountain View, CA, USA) was used in endoscopic-assisted cholesteatoma surgery. This probe was originally designed for retina surgery but can be used in otologic surgery as well and is compatible with multiple laser systems. Additionally, the laser was used in cases where the residual cholesteatoma was near critical and delicate structures, such as the stapes superstructure, as the use of bulky angled suction or dissectors would not be feasible. The fiberoptic-based laser carrier is handheld and has an adjustable slider control that can be ordered as either finger-control or thumb-control to control the length of the fiber that extends outside of the carrier (Fig. 1). The tip of the laser through the handle has a 45-degree curve. The laser handheld carrier works with a number of different laser fiber gauges, and the laser fiber itself comes in 3 sizes: 20-, 23-, and 25-gauge. The laser fiber and carrier was used with the Iridex argon laser light source (Oculight TX Green, Iridex, Mountain View, CA, USA) at a setting of 1 W and pulsed duration of 100 ms on and 100 ms off. The angled endoscope was used for visualization during the laser-assisted cholesteatoma removal and to ensure that all




FIG. 1. Curved laser hand piece with fiberoptic laser fiber.

cholesteatoma was removed. Ossiculoplasty, if necessary, and tympanoplasty were then performed in traditional manner.

Postoperatively, the patients were examined and monitored in clinic periodically for healing, recurrence of cholesteatoma, audiologic results, and postoperative complications. The evaluation for residual disease was performed by routine binocular examination and imaging. MRI with nonecho planar diffusion-weighted imaging (DWI) half-Fourier acquisition single-shot turbo spin echo (HASTE) sequence at 12, 24, and 36 months was used to help evaluate for residual cholesteatoma.

RESULTS

Of the 287 patients undergoing cholesteatoma surgery in our institution between 2006 and 2013, seven patients (1 female and 6 male subjects) underwent surgery, assisted by the curved argon laser in the manner that was described above (Table 1). The mean age was 24 (range, 6–48). The preoperative average air-bone gap (ABG) was 26.3 dB (range, 0–40). Tympanoplasty and canal wall up mastoidectomy was performed in 3 patients each, whereas 1 patient required an atticotomy (Table 1). The most common location of cholesteatoma that required curved laser removal was in and around the stapes superstructure, followed by in the anterior epitympanic recess (Table 2). In all cases, the cholesteatoma was ablated completely with no injury to surrounding structures. There were no cases of unintentional ossicular discontinuity, facial nerve weakness, perilymphatic fistula (PLF), or cerebrospinal fluid leak because of this procedure. There were no cases of sensorineural hearing loss. There was no evidence of residual or recurrent cholesteatoma with an average follow-up period of 19 months (range, 5–38 mo).

DISCUSSION

Endoscopic ablation of cholesteatoma was performed in 7 cases with no injury to surrounding structures. A mean follow-up of 19 months did not reveal any recidivism. These findings suggest that a curved fiberoptic argon laser on an adjustable handheld carrier may safely ablate cholesteatoma from the middle ear and mastoid in a contactless manner during otoendoscopic surgery. Cholesteatomas in these regions required the curved laser removal, either because they were in areas of a recess as in 9 of 16 instances (56%, anterior tympanic recess, Eustachian tube orifice, sinus tympani, oval window, and tegmen) or because the cholesteatoma was closely associated with delicate structures and required contactless removal (44%, stapes superstructure, malleus, and incus). The use of angled otoendoscopes and laser in the sinus tympani has improved the visualization of cholesteatoma and minimized residual cholesteatoma in this area (Fig. 2; see Video, Supplemental Digital Content, <http://links.lww.com/MAO/A252> which shows the use of the curved laser in ablating cholesteatoma endoscopically in the sinus tympani of a right ear).

In the authors' experience, the laser must not be directly aimed at the bone for an extended period as this will cause bony injury. Lasering should be halted immediately

TABLE 1. Demographics, distribution of surgery types, and location of cholesteatoma in patients undergoing endoscopic cholesteatoma surgery with the curved laser

| # | Sex | Age | Follow-up (mo) | Side | Surgical technique | Associated procedures | Location of cholesteatoma | Location of laser assisted removal |
|------|-----|-----|----------------|------|---|----------------------------------|---|------------------------------------|
| 1 | F | 11 | 38 | R | Tympanoplasty | Congenital cholesteatoma removal | Attic, FN, malleus, incus, SS, tensor tendon, tegmen mastoideum and tympani | Tegmen mastoideum and tympani |
| 2 | M | 6 | 36 | L | Revision tympanoplasty with ICW mastoidectomy | OCR: incus interposition | AE, ETO, malleus, incus, SS, tensor tendon | AE, ETO, incus, SS |
| 3 | M | 22 | 35 | L | Tympanoplasty | | Attic, SS, ST | SS, ST |
| 4 | M | 14 | 9 | R | Tympanoplasty with partial CWD mastoidectomy | | Attic, AE, malleus, incus, tegmen tympani | AE, malleus |
| 5 | M | 37 | 7 | R | Tympanoplasty with ICW mastoidectomy | OCR: hydroxylapatite | Attic, SS, incus | SS, incus |
| 6 | M | 27 | 6 | L | Tympanoplasty | OCR: mastoid cortex graft | Attic, CP, FN, OW, SS | OW, SS |
| 7 | M | 48 | 5 | R | Revision tympanoplasty with ICW mastoidectomy | OCR: hydroxylapatite | AE, ETO, FN, incus, stapes footplate, tensor tendon | AE, ETO |
| Mean | | 24 | 19 | | | | | |

F indicates female; M, male; R, right; L, left; ICW, intact canal wall; OCR, ossicular chain reconstruction; AE, anterior epitympanic recess; CP, cochleariform process; ETO, Eustachian tube orifice; FN, facial nerve-tympanic segment; SS, stapes suprastructure; ST, sinus tympani.

once charring of bone is seen. A PLF is possible when lasering the footplate. On the footplate, it is best, however, to remove gross disease with instruments and then use the laser in a defocused fashion to ablate microscopic disease. In addition, reducing the power of the laser to 500 mW would reduce the chance of PLF. Lasering a dehiscent footplate is not recommended. In the current study, the laser was most frequently used to ablate cholesteatoma from the stapes superstructure. The laser was able to ablate cholesteatoma in a contactless manner from the stapes without ossicular discontinuity, PLF, or facial nerve injury. Bony injury is possible with the laser.

In our cohort, no residual cholesteatoma has been identified through routine binocular examination and MRI with a maximal follow-up period of 38 months. Given the recent introduction of this laser carrier, our follow-up period is short (mean, 19 mo). We recognize that these are preliminary results and that cholesteatoma is considered a life-long disease (14). Future studies will allow for a larger sample size and will report long-term recidivism rates with the curved laser and otoendoscopy. The authors plan to continue to use the curved laser in the

removal of cholesteatoma endoscopically. We recognize that the laser and laser hand piece adds an additional cost to cholesteatoma surgery and that not every cholesteatoma case requires laser or otoendoscopy. However, in multiple studies (2–10) including a recent review (1), otoendoscopy, whether used as an adjunct to conventional microsurgery or independent of the microscope, can decrease recidivism rates. In certain cases, where the cholesteatoma involves a deep recess or is in contact with delicate bony structures, the curved laser can help with removal atraumatically when the use of a straight laser would not allow for ablation.

Otoendoscopy, especially with angled endoscopes, provides improved lighting and line of site into the middle ear and mastoid cavity and allows cholesteatoma in recesses of the middle ear to be visualized (1,11). Angled microinstruments with otoendoscopy can be used to remove cholesteatoma from these deep recesses in a safe, atraumatic, and one-handed manner. Several companies, including Karl Storz, have worked with the members of International Working Group on Endoscopic Ear Surgery

TABLE 2. Location of cholesteatoma ablated by curved laser and otoendoscopy

| Location | n |
|-----------------------------|----|
| Stapes superstructure | 4 |
| Anterior epitympanic recess | 3 |
| Lateral to incus | 2 |
| Eustachian tube orifice | 2 |
| Tegmen mastoideum | 1 |
| Tegmen tympani | 1 |
| Sinus tympani | 1 |
| Oval window | 1 |
| Malleus | 1 |
| Total | 16 |

Total is greater than 7 as cholesteatoma may have been found in multiple locations.

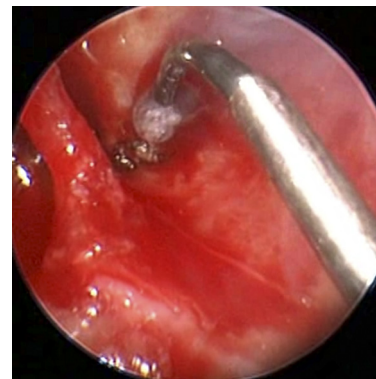

FIG. 2. The use of the curved laser in the sinus tympani (right ear) to ablate cholesteatoma as visualized with a 30-degree, 2.6-mm rigid otoendoscope.

to create angled microinstruments for cholesteatoma surgery. Some have incorporated suction to the tips of the angled picks and elevators to help with removal of cholesteatoma in a bloody field (11). When instruments are unable to reach an area, laser can be used to ablate residual cholesteatoma. Lasers have been used in middle ear surgery for tissue removal in a contactless and hemostatic manner (11–13). These studies have advocated for the use of lasers for removing microscopic foci of cholesteatoma and for ablating granulation tissue and mucosal bands in the middle ear. Flexible laser fibers with handheld carriers allow for cholesteatoma removal without significant bony removal. The use of lasers in endoscopic cholesteatoma surgery has been encouraged (11); however, this is the first report of a curved laser carrier to ablate cholesteatoma effectively.

Most microscopes allow for the placement of an inline filter to block the laser from reaching the eyes of the surgeon. This allows the surgeon to operate without laser safety goggles. However, in otoendoscopic laser surgery, safety goggles must be worn. We generally wear the safety glasses (orange-colored in the case of the argon laser) lower on the nose, similar to reading glasses (Fig. 3). This allows for blocking of the laser light, while allowing the surgeon to look at the monitor above the glasses without an orange discoloration.

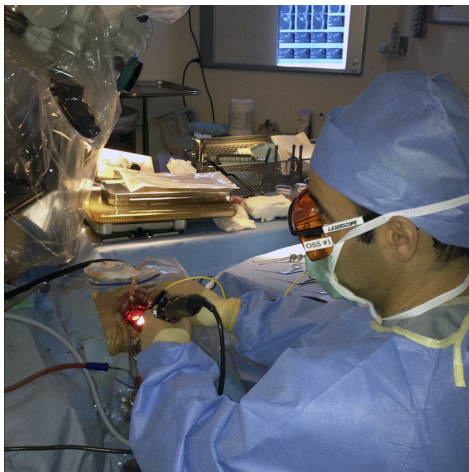


FIG. 3. Wearing laser safety goggles lower on the nose while ablating cholesteatoma endoscopically with the curved laser.

CONCLUSION

The curved laser probe allows for precise removal of cholesteatoma endoscopically. No perioperative complications or no recidivistic cholesteatoma was noted in our series of 7 cases with a follow-up period of up to 19 months. This technique may be a useful adjunct in the treatment of cholesteatomas, and it allows the surgeon to operate around corners and ablate cholesteatoma in a contactless fashion.

REFERENCES

1. Lima Tde O, Araújo TF, Soares LC, Testa JR. The impact of endoscopy on the treatment of cholesteatomas. *Braz J Otorhinolaryngol* 2013;79:505–11.
2. Migirov L, Shapira Y, Horowitz Z, Wolf M. Exclusive endoscopic ear surgery for acquired cholesteatoma: preliminary results. *Otol Neurotol* 2011;32:433–6.
3. Tarabichi M, Nogueira JF, Marchioni D, Presutti L, Pothier DD, Ayache S. Transcanal endoscopic management of cholesteatoma. *Otolaryngol Clin North Am* 2013;46:107–30.
4. Marchioni D, Villari D, Mattioli F, Alicandri-Ciuffelli M, Piccinini A, Presutti L. Endoscopic management of attic cholesteatoma: a single-institution experience. *Otolaryngol Clin North Am* 2013; 46:201–9.
5. Thomassin JM, Korchia D, Doris JM. Endoscopic-guided otosurgery in the prevention of residual cholesteatomas. *Laryngoscope* 1993;103:939–43.
6. Yung MW. The use of middle ear endoscopy: has residual cholesteatoma been eliminated? *J Laryngol Otol* 2001;115:958–61.
7. Badr-el-Dine M. Value of ear endoscopy in cholesteatoma surgery. *Otol Neurotol* 2002;23:631–5.
8. El-Meselaty K, Badr-El-Dine M, Mandour M, Mourad M, Darweesh R. Endoscope affects decision making in cholesteatoma surgery. *Otolaryngol Head Neck Surg* 2003;129:490–6.
9. Ayache S, Tramier B, Strunski V. Otoendoscopy in cholesteatoma surgery of the middle ear: what benefits can be expected? *Otol Neurotol* 2008;29:1085–90.
10. Barakate M, Bottrill I. Combined approach tympanoplasty for cholesteatoma: impact of middle-ear endoscopy. *J Laryngol Otol* 2008;122:120–4.
11. Badr-El-Dine M, James AL, Panetti G, Marchioni D, Presutti L, Nogueira JF. Instrumentation and technologies in endoscopic ear surgery. *Otolaryngol Clin North Am* 2013;46:211–25.
12. Saeed SR, Jackler RK. Lasers in surgery for chronic ear disease. *Otolaryngol Clin North Am* 1996;29:245–56.
13. Hamilton JW. Systematic preservation of the ossicular chain in cholesteatoma surgery using a fiber-guided laser. *Otol Neurotol* 2010;31:1104–8.
14. Kuo CL, Shiao AS, Liao WH, Ho CY, Lien CF. How long is long enough to follow up children after cholesteatoma surgery? A 29-year study. *Laryngoscope* 2012;122:2568–73.