

UCSF

UC San Francisco Previously Published Works

Title

Fetal Unguarded Mitral Valve Orifice, Aortic Atresia, and Severe Left Heart Enlargement

Permalink

<https://escholarship.org/uc/item/9tf5r4sb>

Journal

JACC Case Reports, 3(2)

ISSN

2666-0849

Authors

Howley, Lisa W
Strasburger, Janette
Maleszewski, Joseph J
[et al.](#)

Publication Date

2021-02-01

DOI

10.1016/j.jaccas.2020.11.020

Peer reviewed



HHS Public Access

Author manuscript

JACC Case Rep. Author manuscript; available in PMC 2021 May 25.

Published in final edited form as:

JACC Case Rep. 2021 February ; 3(2): 206–211. doi:10.1016/j.jaccas.2020.11.020.

Fetal Unguarded Mitral Valve Orifice, Aortic Atresia, and Severe Left Heart Enlargement

Lisa W. Howley, MD^{a,b}, Janette Strasburger, MD^c, Joseph J. Maleszewski, MD^d, Saul Snowise, MD^b, Amy Lund, CNP^{a,b}, Andrew Schneider, MD^a, Robroy MacIver, MD^e, Erik Edens, MD^a, Stephanie Eyerly-Webb, PHD^b, Norman H. Silverman, MD, DSC(MED)^f

^aDivision of Cardiology, Department of Pediatrics, The Children's Heart Clinic, Children's Minnesota, Minneapolis, Minnesota, USA

^bMidwest Fetal Care Center, Children's Minnesota, Minneapolis, Minnesota, USA

^cDivision of Cardiology, Department of Pediatrics, Children's Hospital of Wisconsin, Milwaukee, Wisconsin, USA

^dDepartment of Laboratory Medicine and Pathology, Mayo Clinic, Rochester, Minnesota, USA

^eDivision of Cardiac Surgery, The Children's Heart Clinic, Children's Minnesota, Minneapolis, Minnesota, USA

^fDivision of Cardiology, Department of Pediatrics, University of California, San Francisco, California, USA

Abstract

Unguarded mitral valve orifice is a rare disease with only 7 described cases in the literature. We describe the first known case of unguarded mitral valve orifice with normal segmental cardiac anatomy, severe left ventricular dilatation and dysfunction, aortic atresia, and atrial flutter. (**Level of Difficulty: Advanced.**)

Keywords

aortic atresia; atrial flutter; congenital heart defect; fetal; heart malformation; unguarded mitral valve orifice

A 27-year-old gravida 3, para 1 mother presented at 21 4/7 weeks gestation (weeks) with suspected fetal congenital heart disease. Her prenatal ultrasound showed cardiomegaly and difficulty visualizing the outflow tracts. Family history was negative. The family declined genetic testing.

This is an open access article under the CC BY-NC-ND license (<http://creativecommons.org/licenses/by-nc-nd/4.0/>).

ADDRESS FOR CORRESPONDENCE: Dr. Lisa W. Howley, Fetal Cardiology Program, Division of Cardiology, The Children's Heart Clinic, Children's Minnesota, 2530 Chicago Avenue S, Suite 500, Minneapolis, Minnesota 55404, USA. lhowley@chc-pa.org.

The authors attest they are in compliance with human studies committees and animal welfare regulations of the authors' institutions and Food and Drug Administration guidelines, including patient consent where appropriate. For more information, visit the Author Center.

APPENDIX For a supplemental video, please see the online version of this paper.

A fetal echocardiogram demonstrated a cardiothoracic ratio of 67% with notable left heart enlargement and normal atrioventricular (AV) and ventriculoarterial (VA) connections. No mitral valvar (MV) tissue could be seen with unrestrictive to-and-fro flow across the left AV junction (Figure 1A). The left ventricular (LV) myocardium was thin-walled (Figure 1B) with severely reduced function. Right-sided cardiac anatomy appeared morphologically and functionally normal. The ventricular septum was intact. Aortic atresia (AA) was present. Severe aortic arch hypoplasia was observed (Figure 1C). A left-to-right atrial level shunt was unrestrictive.

At 30 6/7 weeks, the fetus presented with 2:1 atrial flutter (AF) (Figure 2, Video 1) and scant ascites and transplacental therapy (sotalol 160 mg orally twice a day and flecainide 100 mg orally twice a day) was initiated. Fetal ventricular rate control was achieved (150 to 160 beats/min) with ascites resolution, but return to normal sinus rhythm was not accomplished.

The fetus remained in rate-controlled AF until 37 4/7 weeks when the mother presented with decreased fetal movement. Fetal echocardiogram demonstrated fetal AF with 1:1 AV conduction with a ventricular rate of 288 beats/min, ascites, and a pericardial effusion (Figure 3) and delivery was recommended.

DIFFERENTIAL DIAGNOSIS

The differential diagnosis included Ebstein anomaly of the MV or congenitally unguarded MV orifice.

INVESTIGATIONS

The patient was referred to the University of Wisconsin Biomagnetism Laboratory at 34 5/7 weeks for a fetal magnetocardiography. Fetal magnetocardiography demonstrated incessant fetal AF with predominant 2:1 AV conduction with brief periods of 1:1 conduction and associated ventricular rates between 250 and 268 beats/min (Figures 2B and 2C).

Following death of the patient, an autopsy was performed (Figure 4).

MEDICAL MANAGEMENT AND INTERVENTIONS

Before delivery, the pediatric cardiology and cardiac surgical teams discussed post-natal management options, including a Norwood procedure and left-sided Starnes surgical approach (1) and orthotopic heart transplantation (OHT). Given the markedly dilated left heart structures and persistent arrhythmia, significant doubt was raised regarding long-term success of a single ventricle palliation pathway. Post-natal primary OHT was determined to be the preferred approach.

Baby was delivered via cesarean section at 37 6/7 weeks, weighing 2,880 g with Apgar of 8 and 8 at 1 and 5 min, respectively. Following delivery, the neonate was intubated and started on intravenous prostaglandin therapy for systemic ductal dependence. He was started on intravenous procainamide therapy for AF and transferred to the cardiovascular intensive care unit. On admission, vital signs included: heart rate 138 beats/min, blood pressure 65/30 mm

Hg, and oxygen saturation 85% while receiving fraction of inspired oxygen 50%. The baby had a normal appearance with a hyperdynamic precordium and an audible gallop. Within 12 h of delivery, the neonate developed worsening respiratory status and rising lactic acidosis and he was electively taken to the cardiovascular operating room and placed on central venoarterial extracorporeal membrane oxygenation with the addition of bilateral pulmonary artery band placement. He was listed status 1A for OHT.

Successful cardioversion was achieved and the baby maintained clinical stability on venoarterial extracorporeal membrane oxygenation awaiting OHT until day of life 26 when he had an acute episode of bradycardia, hypotension, and eventual asystole. On examination his pupils were fixed and dilated and a sonographic examination demonstrated cardiac standstill. The family elected to withdraw support and consented to an autopsy.

Autopsy findings confirmed concordant AV and VA connections with congenital absence of the MV, associated with marked left atrial and aneurysmal LV dilatation (Figure 4). Histologically, the LV myocardium was markedly attenuated (thinning to 0.1 cm). An LV trabecular network was visualized without papillary muscles. AA was confirmed with normal coronary artery ostia.

DISCUSSION

Congenital unguarding of the MV orifice is an exceptionally rare cardiac malformation wherein the left AV junction is completely devoid of leaflet tissue, allowing for unrestrictive flow across the left AV junction. We report the second case of congenitally unguarded MV orifice in the setting of concordant AV and VA connections and AA (2), and the first with marked enlargement of left-sided heart structures, AF, and confirmatory autopsy findings. Four of the previous 7 reports of congenitally unguarded MV orifice were associated with a mirror image atrial arrangement, AV discordance, double-outlet right ventricle, and pulmonary stenosis/atresia (3–6). Banerji et al. (7) described unguarding of the MV orifice in the setting of usual atrial arrangement, but with discordant AV connections, double-outlet right ventricle, and pulmonary atresia. Most recently, Subramanian et al. (8) described unguarding of the MV orifice with usual atrial arrangement and AV connections, double-outlet right ventricle with aortic arch interruption, LV hypoplasia, and an intact ventricular septum. In all cases, the morphologic LV was noted to be thin-walled and poorly contractile.

Disruption of normal MV development may result in this valve deformation. We speculate that the early MV incompetence altered normal LV development, resulting in a severely thinned, aneurysmal LV appearance and development of AA. An alternate hypothesis is that of a primary derangement in LV myocardial development, disrupting MV formation and resulting in severe valve incompetence. Understanding the embryologic etiology through detailed study has not been possible.

The finding of AA has been reported in all cases of unguarded MV in the setting of normal segmental cardiac anatomy (2). AA in the setting of an unguarded MV mirrors that of pulmonary atresia, which has been frequently reported in the setting of fetal unguarded tricuspid valve (9). We postulate that severe regurgitation of an unguarded AV valve results

in ipsilateral arterial valvar atresia caused by the inefficient, and eventually absent, antegrade flow across the respective arterial valve.

Fetal AF has not been previously described in the setting of unguarded MV orifice. Likely this arrhythmia is secondary to the severely dilated and dysfunctional left-sided chambers; however, abnormal arrhythmogenic myocardium resulting from an early developmental derangement cannot be excluded. Fetal magnetocardiography was useful because identification of intermittent 1:1 AV conduction prompted heightened surveillance through the pregnancy.

CONCLUSIONS

Our report describes an unusual case of a prenatally discovered, exceedingly rare unguarded MV orifice in conjunction with an aneurysmally dilated LV, AA, and longstanding AF.

Supplementary Material

Refer to Web version on PubMed Central for supplementary material.

FUNDING SUPPORT AND AUTHOR DISCLOSURES

Dr. Strasburger is supported by grant NIH RO1HL143485. All other authors have reported that they have no relationships relevant to the contents of this paper to disclose.

ABBREVIATIONS AND ACRONYMS

AA	aortic atresia
AF	atrial flutter
AV	atrioventricular
LV	left ventricle
MV	mitral valve
OHT	orthotopic heart transplant
VA	ventriculoarterial

REFERENCES

1. Nakata T, Fujimoto Y, Hirose K, Tosaka Y, Ide Y, Sakamoto K. Norwood procedure combined with the Starnes procedure. *Ann Thorac Surg* 2008;86: 1378–80. [PubMed: 18805206]
2. Su JA, Ho J, Wong PC. Unguarded mitral orifice associated with hypoplastic left heart syndrome. *Cardiol Young* 2015;25:1002–5. [PubMed: 25058691]
3. Earing MG, Edwards WD, Puga FJ, Cabalka AK. Unguarded mitral orifice associated with discordant atrioventricular connection, double-outlet right ventricle, and pulmonary atresia. *Pediatr Cardiol* 2003;24:490–2. [PubMed: 14627321]
4. Hwang MS, Chang YS, Chu JJ, Lin WS, Su WJ. A potential new constellation of defects: unguarded mitral orifice associated with double-outlet right ventricle (I, D, D) and pulmonary atresia/stenosis. *Int J Cardiol* 2011;148:354–7. [PubMed: 20598383]

5. Kishi K, Katayama H, Ozaki N, et al. Fatal cardiac anomaly of unguarded mitral orifice with asplenia syndrome. *J Cardiol Cases* 2017;15:6–9. [PubMed: 30524572]
6. Yasukochi S, Satomi G, Park I, Ando M, Momma K. Unguarded mitral orifice, mirror-imaged atrial arrangement, and discordant atrioventricular connections. *Cardiol Young* 1999;9: 478–83. [PubMed: 10535827]
7. Banerji N, Krishna MR, Kumar RK, Anderson RH. Caught-off guard: unguarded mitral valve orifice in usual atrial arrangement with discordant atrioventricular connections and pulmonary atresia. *Ann Pediatr Cardiol* 2020;13:84–6. [PubMed: 32030042]
8. Subramanian A, Bharath AP, Jayaranganath M. Unguarded left atrioventricular orifice: an unusual cause of hypoplastic left ventricle and double-outlet right ventricle with intact ventricular septum. *Ann Pediatr Cardiol* 2019;12:153–5. [PubMed: 31143045]
9. Kumar Vikraman S, Chandra V, Balakrishnan B, Jaiman S, Batra M, Kannoly G. Unguarded tricuspid orifice: a rare cause of fetal right atrial dilatation with characteristic color doppler sign. Case report with review of literature. *J Clin Ultrasound* 2017; 45:370–4. [PubMed: 27753109]

LEARNING OBJECTIVES

- To recognize the varied origins of hypoplastic left heart syndrome.
- To understand the spectrum of mitral valve abnormalities that can occur in fetal development.
- To recognize that unguarded mitral valve orifice can occur in the heart with concordant cardiac connections.

Author Manuscript

Author Manuscript

Author Manuscript

Author Manuscript

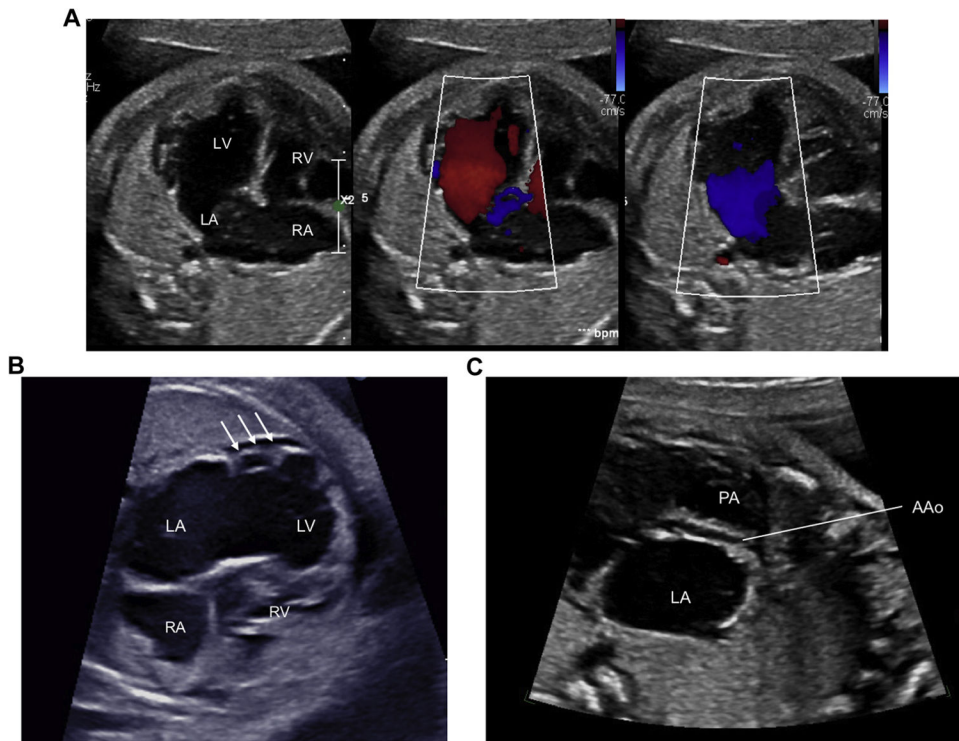


FIGURE 1. Fetal Echocardiographic Findings

(A) Apical 4-chamber image of the fetal heart with unrestricted to-and-fro flow across the left atrioventricular junction. (B) Thin, aneurysmal appearance of the left ventricle (LV) lateral wall (**arrows**). (C) Sagittal view demonstrating a hypoplastic ascending aorta arising from the LV. AAo = ascending aorta; LA = left atrium; PA = pulmonary artery; RA = right atrium; RV = right ventricle.

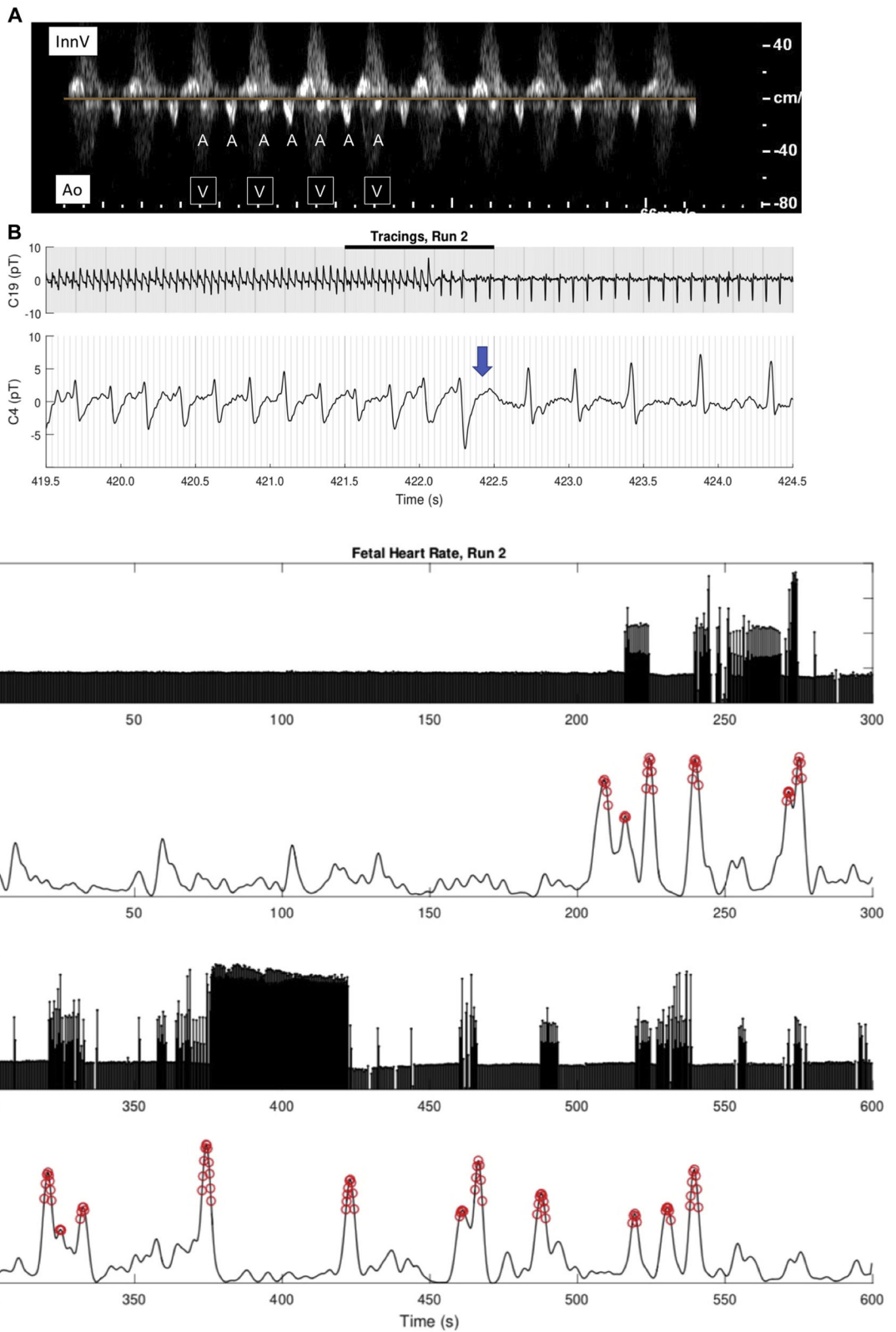


FIGURE 2. Fetal Atrial Flutter Assessment

(A) Simultaneous pulsed Doppler sampling of the innominate vein and aorta demonstrating atrial flutter with 2:1 AV conduction. The atrial rate is regular (A-A interval = 150 ms) and the R-R interval is 300 ms. (B) Fetal magnetocardiogram rhythm strip demonstrating atrial flutter with transition from 1:1 to 2:1 AV conduction (**blue arrow**). (C) Fetal magnetocardiogram heart rate trend and actogram demonstrating transition of atrial flutter from predominantly 2:1 to 1:1 AV conduction associated with fetal movement (**red circles**). Ao = aorta; AV = atrioventricular; InnV = innominate vein.

Author Manuscript

Author Manuscript

Author Manuscript

Author Manuscript

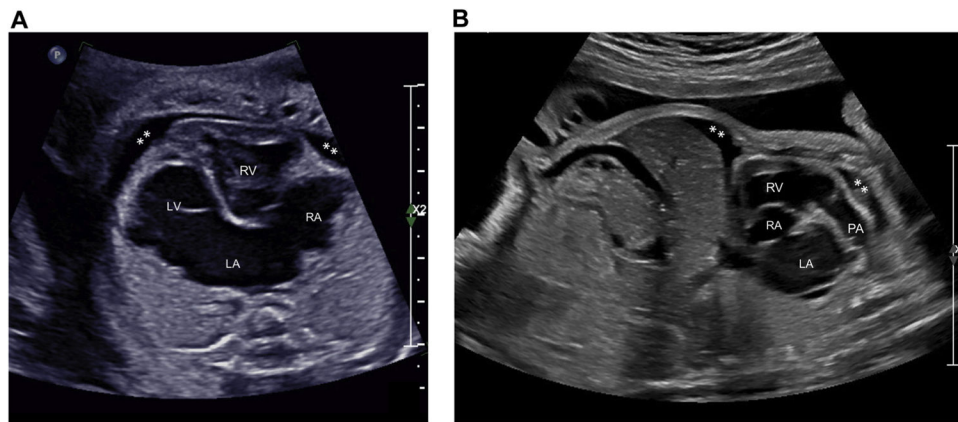
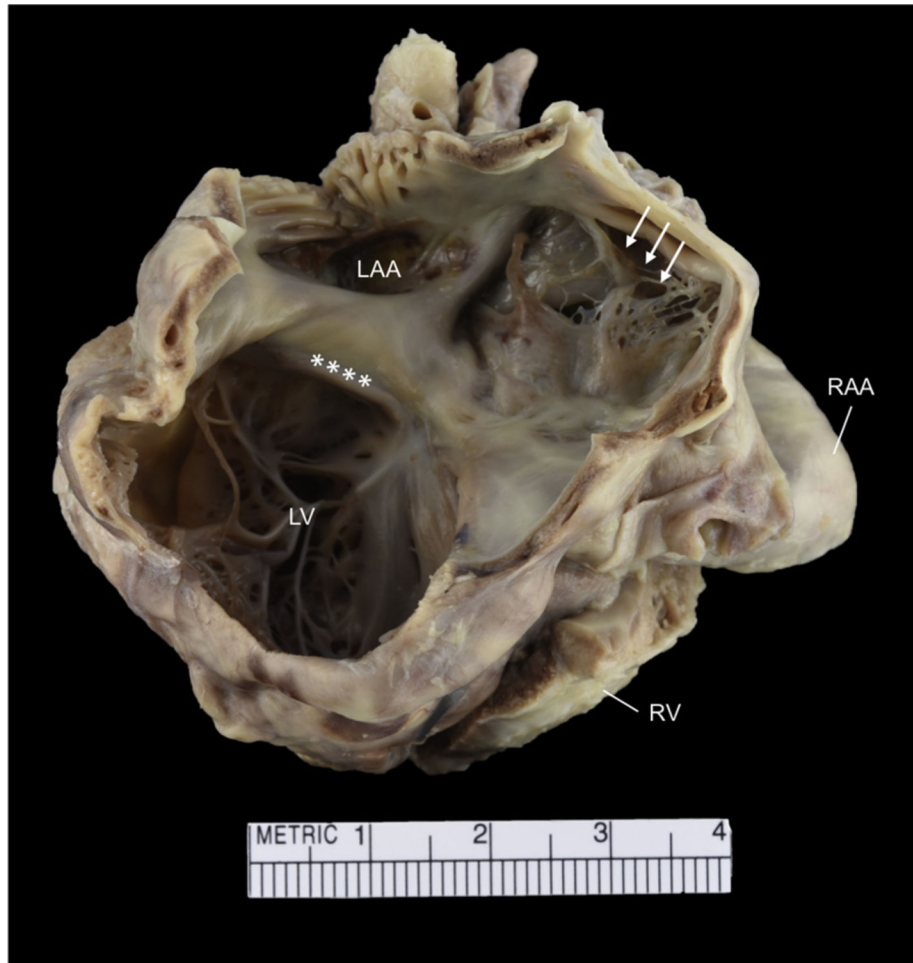


FIGURE 3. Fetal Hydrops Evaluation

(A) Apical 4-chamber image of the fetal heart demonstrating a small pericardial effusion (asterisks). (B) Sagittal view of the fetal body demonstrating ascites and small anterior pericardial effusion (asterisks). Abbreviations as in Figure 1.

**FIGURE 4. Autopsy**

Gross autopsy specimen exhibiting left AV junction with an unguarded mitral valve orifice (**asterisks**). The atrial septum is fenestrated and web-like in appearance (**arrows**). LAA = left atrial appendage; RAA = right atrial appendage; other abbreviations as in Figures 1 and 2.