

# UC Irvine

## UC Irvine Previously Published Works

### Title

Seeing invisible light: 2-photon microperimetry to measure visual function

### Permalink

<https://escholarship.org/uc/item/9tg5h6v9>

### Authors

Mehta, Urmi

Palczewska, Grazyna

Lin, Ken Y

et al.

### Publication Date

2022-12-01

### DOI


10.1016/j.ajoc.2022.101724

### Copyright Information

This work is made available under the terms of a Creative Commons Attribution-NonCommercial-NoDerivatives License, available at

<https://creativecommons.org/licenses/by-nc-nd/4.0/>

Peer reviewed



# Seeing invisible light: 2-photon microperimetry to measure visual function

Urmi Mehta<sup>a,b</sup>, Grazyna Palczewska<sup>a,c</sup>, Ken Y. Lin<sup>a</sup>, Andrew W. Browne<sup>a,d,e,\*</sup>

<sup>a</sup> Gavin Herbert Eye Institute, Department of Ophthalmology, University of California-Irvine, Irvine, CA, 92617, USA

<sup>b</sup> Western University of Health Sciences, Pomona, CA, 91766, USA

<sup>c</sup> Polgenix Inc., Department of Medical Devices, Cleveland, OH, 44106, USA

<sup>d</sup> Institute for Clinical and Translational Sciences, University of California-Irvine, Irvine, CA, 92617, USA

<sup>e</sup> Department of Biomedical Engineering, University of California-Irvine, Irvine, CA, 92617, USA

## ARTICLE INFO

### Keywords:

Two-photon microperimetry  
cataracts  
Visual sensitivity

## ABSTRACT

**Purpose:** The accuracy of conventional visual function tests, which emit visible light, decreases in patients with corneal scars, cataracts, and vitreous hemorrhages. In contrast, infrared (IR) light exhibits greater tissue penetration than visible light and is less susceptible to optical opacities. We therefore compared conventional visual function tests against infrared 2-photon microperimetry (2PM-IR) in a subject with a brunescens nuclear sclerotic and posterior subcapsular cataract before and after cataract surgery.

**Methods:** Testing using infrared light microperimetry from a novel device (2PM-IR), visible light microperimetry from a novel device (2PM-Vis), conventional microperimetry, and the cone contrast threshold (CCT) test were performed before and after cataract surgery.

**Results:** Retinal sensitivity assessed using 2PM-IR, 2PM-Vis, and cMP improved by 3.4 dB, 17.4 dB, and 18 dB, respectively. Cone contrast threshold testing improved for the S-cone, M-cone, and L-cone by 111, 14, and 30.

**Conclusions and Importance:** 2PM-IR, unlike conventional visual function tests, showed minimal variability in retinal sensitivity before and after surgery. Thus, IR visual stimulation may provide a more accurate means of measuring neurosensory retinal function by circumventing optical media opacities, aiding in the diagnosis of early macular disease.

## 1. Introduction

Cataracts are the leading cause of reversible vision loss worldwide.<sup>1</sup> By attenuating (scattering) light entering the eye, cataracts reduce visual acuity, color vision, and contrast sensitivity while increasing glare and worsening visual field loss.<sup>2</sup> Eye care providers rely upon visual function tests to measure changes in vision, which are confounded by media opacities<sup>2–5</sup> like cataracts. Cataracts coincide with other common age-related diseases such as age-related macular degeneration (AMD) and glaucoma. Precision in isolating and quantifying neurosensory retinal function is therefore diminished by cataracts. Based on the study by Cocce et al., no visual function tests were able to distinguish the earliest stages of AMD from normal age-matched eyes.<sup>6</sup>

IR light has greater transmittance into the aged eye than visible light.<sup>7</sup> Two-photon (2P) technologies prevail in the basic sciences where conventional fluorescence microscopy using short wavelength light to stimulate fluorescence has been partially supplanted by 2P microscopes in which ultrafast pulsed infrared lasers introduce 2 photons of infrared

light to a small focal volume to stimulate fluorescence much like conventional fluorescence microscopes using UV and visible light. Recent innovations in 2P technology have demonstrated that pulsed IR light can initiate phototransduction by inducing photoisomerization of 11-*cis*-retinylidene<sup>8</sup> nested in visual pigments. Therefore, 2P IR light can stimulate human vision.

While IR light has long enabled medical imaging of the ocular fundus, this report demonstrates the inaugural clinical use of 2PM-IR to measure neurosensory retinal function before and after cataract surgery. 2PM-IR is a novel device that uses a pulsed IR light at 1045 nm<sup>9</sup> to stimulate vision.

## 2. Materials and methods

This study received Institutional Review Board approval from the University of California, Irvine and was conducted in accordance with the Declaration of Helsinki and HIPAA regulations. Informed written consent was obtained from the patient.

\* Corresponding author. University of California-Irvine School of Medicine, 850 Health Sciences Rd, Irvine, CA, 92697, USA.

E-mail addresses: [urmimehta321@gmail.com](mailto:urmimehta321@gmail.com) (U. Mehta), [gpalczew@uci.edu](mailto:gpalczew@uci.edu) (G. Palczewska), [linky@uci.edu](mailto:linky@uci.edu) (K.Y. Lin), [abrowne1@uci.edu](mailto:abrowne1@uci.edu) (A.W. Browne).

<https://doi.org/10.1016/j.ajoc.2022.101724>

Received 15 July 2020; Received in revised form 27 September 2022; Accepted 10 October 2022

Available online 13 October 2022

2451-9936/© 2022 The Authors. Published by Elsevier Inc. This is an open access article under the CC BY-NC-ND license (<http://creativecommons.org/licenses/by-nc-nd/4.0/>).

### 3. Baseline evaluation

A 51-year-old male presented to the Gavin Herbert Eye Institute with gradual painless vision loss of the left eye over the preceding 2 months with a reduction in best corrected visual acuity (BCVA) at distance from 20/25 to 20/70. Slit lamp exam showed a dense brunescent and posterior subcapsular cataract (Fig. 1). Medical history revealed a branch retinal arterial occlusion of the left eye at the age of 19 and borderline glaucoma. The patient was subjectively dependent on his left eye after losing vision in his right eye secondary to CMV retinitis with a stable pseudophakic vision of 20/40. There was no history of prior surgeries or trauma to the left eye.

Given his monocular vision status, he was scheduled for expedited cataract surgery using a clear monofocal intraocular lens (ZCB00, Abbott Medical Optics Santa Ana, CA) during the COVID19 pandemic.

### 4. Functional testing

Neurosensory retinal function was assessed 3 weeks before and 1 week after cataract surgery. All testing was completed on the same day. The same order of testing was employed before and after cataract extraction. The 2-photon microperimeter (2PM) presented either a visible light green stimulus (2PM-Vis) at 522.5 nm or stimulated vision using a 1045 nm pulsed infrared light source (2PM-IR) under scotopic conditions. Only foveal sensitivity using one central stimulus was assessed. As described by Wei et al., a stimulus pattern formed by either two-photon infrared or visible light was projected onto the retina.<sup>9</sup> Test subjects were asked to adjust the intensity of the stimulus by scrolling either up or down on a computer mouse, which would either increase or decrease the intensity of the stimulus entering the eye.<sup>9</sup> When the visibility threshold was reached and the subject could no longer see the stimulus, the subject was asked to click on the mouse, thereby recording the threshold power that could be detected.<sup>9</sup> The same procedure was performed four more times, and an average threshold sensitivity for all five replicate tests was calculated.<sup>9</sup> Conventional microperimetry (cMP, Nidek MP-3, San Jose, CA) assessed macular sensitivity using a Goldmann III stimuli over an intensity range from 0 to 34 dB under mesopic conditions. Although multiple stimuli across the macula were tested, only the foveal sensitivity was included in our assessment. Cone contrast threshold (CCT) testing measured color and contrast vision (ColorDx CCT HD, Konan Medical Irvine CA) under photopic conditions. The device selectively stimulates retinal L-, M-, and S-cones by projecting Landolt C optotypes in either decreasing or increasing steps of cone contrast against a gray background.<sup>10</sup>

### 5. Results

BCVA at distance was 20/25 at the patient's 1-week post-op visit. Visual function improved by a similar amount for both visible spectrum microperimetry assays, with 18 dB for conventional microperimetry and 17.4 dB for 2PM-Vis. 2PM-IR demonstrated a 3.4 dB change in neurosensory retinal sensitivity, which is approximately 20% of the change seen with visible spectrum microperimetry. Preop and postop standard deviations were 1.9 dB and 0.7 dB for 2PM-Vis and 0.4 dB and 0.7 dB for

2PM-IR, respectively. CCT scores for 3 cone classes and retinal sensitivities measured on three microperimetry devices demonstrated a statistically significant improvement after cataract surgery (Fig. 2).

Optical imaging of the retinal fundus demonstrates the ability for light outside the eye to pass through the optical media, reflect on the retinal fundus, and return through the optical media to the camera sensor (Fig. 3). Infrared imaging at two wavelengths (750 and 840 nm) demonstrated retained image features when features in color photography were lost in the context of PSC (Fig. 3). All imaging modalities demonstrate improved image clarity after cataract surgery.

### 6. Discussion

This is the first report using 2PM-IR *in vivo* that shows minimal changes in neurosensory retinal function after the removal of a visually significant cataract. Our patient presented with a brunescent nuclear sclerotic and posterior subcapsular cataract of the left eye. Conventional visual function testing before and after cataract surgery were largely dependent upon the presence or absence of media opacities.

Prior studies by Ruminski et al. comparing 2PM-Vis and 2PM-IR performance using human donor lenses found decreased absorbance and increased transmission of IR light.<sup>8</sup> This report corroborates their findings *in vivo* by demonstrating less variability in retinal sensitivity testing before and after cataract surgery using 2PM-IR than conventional visible spectrum assays.

2PM-IR demonstrated a 3.4 dB increase in neurosensory retinal function. This may result from modest IR absorption by the cataractous lens, which is approximately 4 mm thicker than a pseudophakic implant. While we have not observed testing noise in young healthy subjects tested and retested on the 2PM instrument, we cannot rule out testing noise as a source of change. This study highlights the limitations of conventional visual function tests used in all clinical trials to accurately measure retinal function in the presence of a media opacity.

### 7. Conclusion

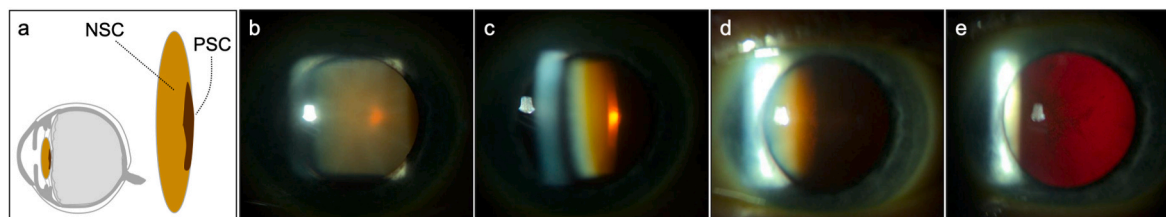
The ability to diagnose and monitor function of the neurosensory retina in the presence of media opacities can be achieved with greater reliability and accuracy by using IR light. 2PM-IR may emerge as an adjunct to conventional vision testing to mitigate the effect of media opacity and help discriminate heretofore indistinguishable changes in visual function in early common blinding diseases like AMD.

### Patient consent

The patient consented to publication of the case in writing and orally.

### Funding

Research to Prevent Blindness unrestricted grant to UCI Department of Ophthalmology; National Institute of Health Mentored Career Development Award (KL2) 5KL2TR001416-02.



**Fig. 1.** Diagram of cataract with NSC and PSC (a). Brunescent nuclear sclerosis is highlighted *in vivo* by broad illumination (b), and slit beam illumination of the lens nucleus (c). PSC is revealed by slit beam illumination of the lens posterior capsule (d), and retroillumination (e).

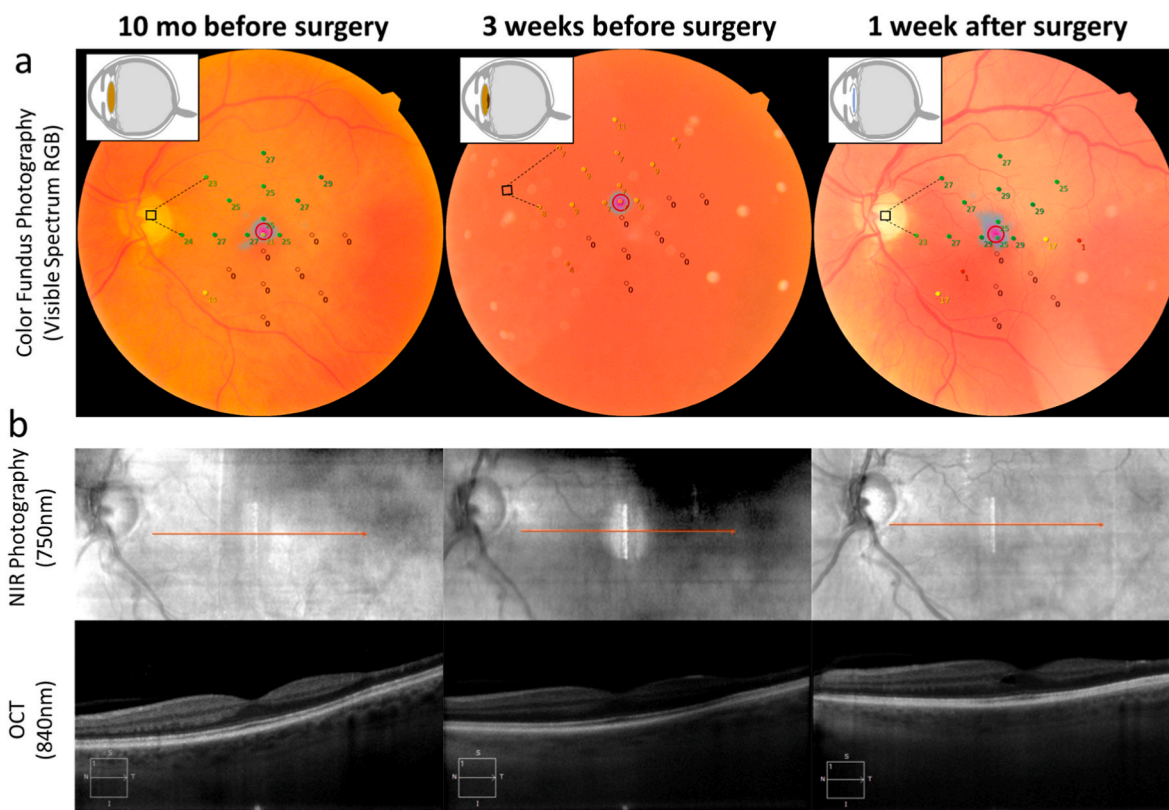
## a) Change in Cone Contrast Thresholds

	Pre	Post	Change
<b>Blue</b>	0	99	<b>99</b>
<b>Green</b>	25	39	<b>14</b>
<b>Red</b>	54	84	<b>30</b>

## b) Change in Microperimetry

Conventional MP	18 dB
2PM-Vis	17.4 dB
2PM-IR	3.4 dB

**Fig. 2.** Changes in visual function testing before and after cataract surgery. CCT scores before and after cataract surgery for the cone contrast threshold (CCT) test. (a) A normal score is greater than 90. Changes in foveal sensitivity for three different microperimetry assays (b).



**Fig. 3.** Changes in multimodal imaging acquired with NSC alone 10-months prior to surgery, with both NSC and PSC 3-weeks prior to surgery, and pseudophakia 1-week after cataract surgery. (a) Color fundus photographs (visible spectrum composed of red, green and blue channels). (b) Infrared imaging by NIR fundus photography (750 nm) and OCT b-scan (840 nm) demonstrate preserved visible anatomy at all stages of cataract. Nuclear sclerotic cataract (NSC); posterior sub-capsular cataract (PSC); near infrared (NIR); optical coherence tomography (OCT). (For interpretation of the references to color in this figure legend, the reader is referred to the Web version of this article.)

### Authorship

All authors attest that they meet the current ICMJE criteria for Authorship.

### Intellectual property

We confirm that we have given due consideration to the protection of intellectual property associated with this work and that there are no impediments to publication, including the timing of publication, with respect to intellectual property. In so doing we confirm that we have

followed the regulations of our institutions concerning intellectual property.

### Research ethics

We further confirm that any aspect of the work covered in this manuscript that has involved human patients has been conducted with the ethical approval of all relevant bodies and that such approvals are acknowledged within the manuscript.

IRB approval was obtained (required for studies and series of 3 or more cases).

Written consent to publish potentially identifying information, such as details or the case and photographs, was obtained from the patient(s) or their legal guardian(s).

### Contact with the editorial office

This author submitted this manuscript using his/her account in EVISE.

We understand that this Corresponding Author is the sole contact for the Editorial process (including EVISE and direct communications with the office). He/she is responsible for communicating with the other authors about progress, submissions of revisions and final approval of proofs.

We confirm that the email address shown below is accessible by the Corresponding Author, is the address to which Corresponding Author's EVISE account is linked, and has been configured to accept email from the editorial office of American Journal of Ophthalmology Case Reports: [abrowne1@uci.edu](mailto:abrowne1@uci.edu).

### Declaration of competing interest

Grazyna Palczewska is an employee of Polgenix, Inc. The following

authors have no financial disclosures: UM, KYN, AWB.

### Acknowledgements

The authors would like to thank Dr. Krzysztof Palcowski for use of the 2PM. The authors would also like to thank Carl Zeiss Meditec for loan of ophthalmic testing devices used to verify ophthalmic health in human subjects and Konan medical for an unrestricted donation of ColorDX.

### References

1. Lam D, Rao SK, Ratna V, et al. *Cataract Nat Rev Dis Prim.* 2015;1, 15014.
2. Brown NA. The morphology of cataract and visual performance. *Eye.* 1993;7(Pt 1): 63–67.
3. Fujikawa M, Muraki S, Niwa Y, Ohji M. Evaluation of clinical validity of the Rabin cone contrast test in normal phakic or pseudophakic eyes and severely dichromatic eyes. *Acta Ophthalmol.* 2018;96(2):e164–e167.
4. Palkovits S, Hirschschall N, Georgiev S, Leisser C, Findl O. Effect of cataract extraction on retinal sensitivity measurements. *Ophthalmic Res.* 2021;64:10–14. <https://doi.org/10.1159/000507450>.
5. Richter-Mueksch S, Sacu S, Weingessel B, Vecsei-Marlovits VP, Schmidt-Erfurth U. The influence of cortical, nuclear, subcortical posterior, and mixed cataract on the results of microperimetry. *Eye.* 2011;25(10):1317–1321.
6. Cocce KJ, Stinnett SS, Luhmann UFO, et al. Visual function metrics in early and intermediate dry age-related macular degeneration for use as clinical trial endpoints. *Am J Ophthalmol.* 2018;189:127–138.
7. Boettner EA, Wolter JR. Transmission of the ocular media. *Investig Ophthalmol Vis Sci.* 1962;1(6):776–783.
8. Ruminski D, Palczewska G, Nowakowski M, et al. Two-photon microperimetry: sensitivity of human photoreceptors to infrared light. *Biomed Opt Express.* 2019;10(9):4551–4567.
9. Wei A, et al. Two-photon microperimetry: a media opacity-independent retinal function assay. *Transl Vis Sci Technol.* 2021;10(2), 11–11.
10. Konan Medical. ColorDxCCT-HD fundamentals. Available at: August 20, 2022 <https://konanmedical.com/colordx-ccthd-fundamentals/>.