

Timely Use of Venous-Arterial ECMO to Treat Congenital Pediatric Junctional Ectopic Tachycardia: A Case Report

Journal of Investigative Medicine High Impact Case Reports
Volume 9: 1–5
© 2021 American Federation for Medical Research
DOI: 10.1177/23247096211034045
journals.sagepub.com/home/hic


Jordan Mudery, MD¹, Joanne P. Starr, MD²,
Anjan Batra, MD^{1,2}, and Robert B. Kelly, MD^{1,2} 

Abstract

Supraventricular tachycardia is the most common tachyarrhythmia in pediatrics. Although postoperative junctional ectopic tachycardia (JET) is a known complication of congenital heart surgery that is typically transient, congenital JET is rare and requires aggressive treatment to maintain hemodynamic stability. We describe the case of a 3-month-old, previously healthy female who presented with heart failure and cardiogenic shock secondary to congenital JET for whom extracorporeal membrane oxygenation (ECMO) provided time for selection of effective therapy. Adenosine, cardioversion, and transesophageal pacing were unsuccessful, and her echocardiogram demonstrated bilateral atrial dilation and severe left ventricular systolic dysfunction. Approximately 8 hours after presentation, venous-arterial ECMO was commenced allowing for successful treatment with amiodarone. Her electrocardiogram demonstrated atrioventricular dissociation consistent with JET. She was successfully decannulated from ECMO after 6 days. Her discharge echocardiogram showed normal ventricular function, and she had no significant ECMO sequelae. This case demonstrates the value of early ECMO initiation for cardiovascular support in pediatric patients with a life-threatening arrhythmia and in cardiogenic shock. ECMO support can allow for full diagnostic and therapeutic decisions to effectively reverse the consequences of uncontrolled arrhythmias unrelated to surgical complications.

Keywords

junctional ectopic tachycardia, extracorporeal membrane oxygenation, heart failure, pediatrics, shock

Introduction

Junctional ectopic tachycardia (JET) is a tachyarrhythmia originating in or proximal to the atrioventricular junction and atrioventricular canal. Postoperative JET is a known complication of congenital heart surgery that is typically transient. Congenital JET is a lesser-known tachyarrhythmia, is typically refractory to treatment, and has a significant mortality. A death rate as high as 35% has been reported.¹ We describe the case of a 3-month-old, previously healthy female with heart failure and cardiogenic shock secondary to congenital JET for whom extracorporeal membrane oxygenation (ECMO) provided time for selection of effective therapy. This case demonstrates the value of early ECMO initiation for cardiovascular support in pediatric patients with a life-threatening arrhythmia and in cardiogenic shock. Our hospital's institutional review board waives approval for de-identified case reports, and the patient's parent provided written consent for publication.

Illustrative Case

Presentation

A 3-month-old healthy female without significant medical history was brought to the emergency department at a tertiary care children's hospital with a chief complaint of lethargy. Two days prior to presentation the infant was inconsolable with decreased oral intake and vomiting. There were no fevers, cough, or diarrhea. She was born full term via normal spontaneous vaginal delivery with an unremarkable prenatal

¹University of California, Irvine, CA, USA

²Children's Hospital of Orange County, Orange, CA, USA

Received May 10, 2021. Revised June 26, 2021. Accepted July 1, 2021.

Corresponding Author:

Robert B. Kelly, MD, Division of Critical Care, Children's Hospital of Orange County, 1201 West, La Veta Avenue, Orange, CA 92868, USA.
Email: rkelly@choc.org



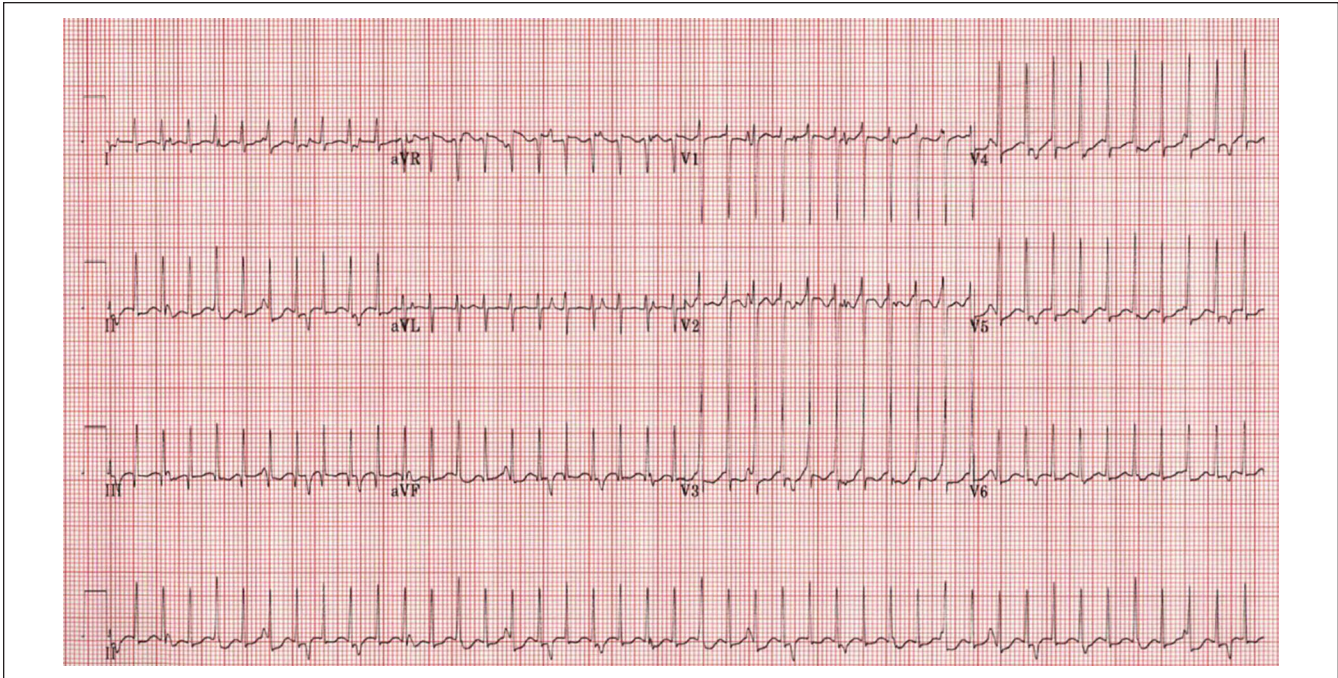


Figure 1. Electrocardiogram performed approximately 6 hours after cannulation for extracorporeal membrane oxygenation. The electrocardiogram demonstrates atrioventricular dissociation consistent with junctional ectopic tachycardia.

history. The patient had been gaining weight and meeting appropriate developmental milestones.

On presentation, the infant was ill-appearing and lethargic with no response to venipuncture. Her initial vital signs were a temperature of 36.9 °C, a heart rate of 160 beats per minute (BPM), a respiratory rate of 68 breaths per minute, and an oxygen saturation of 99% in room air. Six minutes later, her vital signs were a heart rate of 269 BPM, a respiratory rate of 79 breaths per minute, a blood pressure of 108/88 mm Hg, and an oxygen saturation of 100% in room air. Her blood glucose was 20 mg/dL, which was corrected with intravenous 10% dextrose without improvement in her clinical status. Her venous blood gas was remarkable for a pH of 7.25 and a lactate of 11.72 mmol/L. Her troponin was 1.44 ng/mL, and her brain natriuretic peptide was >5000 pg/mL. She had significant coagulopathy evidenced by a prothrombin time of 57.1 seconds, an international normalized ratio of 6.75, an activated partial thromboplastin time of 146.5 seconds, and a D-dimer of >20.0 µg/mL. A rhythm strip demonstrated an intermittent tachycardia of 270 BPM. Electrocardiograms confirmed the presence of both wide- and narrow-complex tachycardias with heart rates between 250 and 270 BPM.

Treatment

The patient was intubated and given 0.1 mg/kg of intravenous adenosine for presumed supraventricular tachycardia without resolution. Electrical cardioversion was attempted with 1 and 2 J/kg without conversion to a normal sinus

rhythm, and she remained tachycardic with a heart rate of 250 BPM. She became hypotensive to as low as 30/20 mm Hg. She was started on an epinephrine infusion and transferred to the cardiovascular intensive care unit.

Additional doses of intravenous adenosine (up to 0.5 mg/kg) and transesophageal overdrive pacing were ineffective. Her echocardiogram demonstrated bilateral atrial dilation and diminished function of both ventricles, with a left ventricular ejection fraction of 18%. As she became more hypotensive and acidotic, the decision was made to cannulate the patient for venous-arterial ECMO to support the patient while an accurate diagnosis could be made and effective treatment of her dysrhythmia initiated. ECMO flow commenced approximately 8 hours after presentation via the right internal jugular vein and right carotid artery with a 12-French venous cannula and an 8-French arterial cannula (Medtronic DLP), respectively, and supported with 80 mL/kg/min (0.45 L/min) of ECMO flow (Getinge Rotaflow), 0.3 L/min of sweep gas flow, and 0.60 fraction of inspired oxygen using a Quadrox-iD Pediatric oxygenator (Getinge). Her perfusion and acidosis improved shortly after ECMO initiation. An electrocardiogram performed approximately 6 hours after cannulation for ECMO demonstrated atrioventricular dissociation consistent with junctional ectopic tachycardia (Figure 1).

To maintain adequate blood pressure during her resuscitation, the patient required epinephrine (0.3 µg/kg/min) and vasopressin (0.6 milliunits/kg/min) infusions but was transitioned to a milrinone (0.75 µg/kg/hour) infusion on day 1 of

hospitalization. For rhythm control, she was given a 15 mg/kg dose of intravenous amiodarone, followed by an amiodarone infusion (20 µg/kg/min), also on hospital day 1. A calcium chloride infusion was also started (5 mg/kg/h). This controlled her heart rate in a range of 100 to 110 BPM. Repeat electrocardiograms demonstrated atrial-ventricular disassociation consistent with a diagnosis of JET.

Telemetry continued to show intermittent periods of an irregular JET at rates of 160 to 205 BPM. Persistent rhythm control was established on hospital day 4 with an improved heart rate ranging from 107 to 158 BPM on subsequent electrocardiograms. Echocardiograms continued to demonstrate severely diminished systolic function until hospital day 6 when borderline ventricular dilation and mildly diminished systolic function were seen. She was decannulated from ECMO on hospital day 6 and extubated on hospital day 9. Electrocardiograms and echocardiograms throughout the rest of her admission demonstrated a controlled rhythm and improving systolic function. Her amiodarone and milrinone infusions were discontinued, and she was started on oral amiodarone (5 mg/kg/day), enalapril (2.4 mg/kg/day), and furosemide (2 mg/kg/day) on hospital day 10. Amiodarone was increased (6.4 mg/kg/day) and propranolol (2 mg/kg/day) added on hospital day 26, the day of discharge. She was discharged on this medication regimen to be weaned as an outpatient.

On day 16 of hospitalization, the patient had an episode of right upper and lower extremity shaking. A sluggish left pupil was noted. The seizure activity was stopped with 1 dose of lorazepam (0.1 mg/kg), and she was loaded with levetiracetam (20 mg/kg). A brain magnetic resonance imaging scan showed a punctate hemorrhage in the left occipital lobe, but no acute infarction. An electroencephalogram showed left posterior slowing consistent with the punctate left occipital hemorrhage. She was started on maintenance levetiracetam (30 mg/kg/day) and did not have any further seizure activity.

Clinical Outcome and Follow-up

At the time of discharge, she continued to have a junctional rhythm with brief intermittent periods of normal sinus rhythm. Her final echocardiogram demonstrated normal ventricular size and systolic function. She had a thorough evaluation to identify possible causes. A 180k Oligonucleotide-SNP International Standards for Cytogenomic Array whole genome oligonucleotide array was performed which did not detect abnormalities. An approximately 11.6 Mb total loss of heterozygosity was noted that was interpreted as likely benign and not thought to be contributing to the patient's clinical picture. No definitive causative metabolic disorder was identified after interpreting various laboratory studies, including acylcarnitine profile, carnitine (total, free, and esters), plasma amino acid profile, ketones, urine organic acids, urine acylglycine profile, ammonia, and lactic acid.

Likewise, no definitive causative infectious disease was identified after interpreting various laboratory studies for HIV 1/2, rapid plasma reagin, cytomegalovirus, hepatitis B, hepatitis C, Epstein-Barr virus, toxoplasma, enterovirus, adenovirus, influenza A, influenza B, respiratory syncytial virus, parainfluenza 1, parainfluenza 2, parainfluenza 3, and human metapneumovirus, as well as viral, urine, respiratory, and blood cultures.

At her 6-month outpatient follow-up visit, she was continued on amiodarone, enalapril, and propranolol. She had remained asymptomatic, and her electrocardiogram demonstrated a normal sinus rhythm (Figure 2). Her echocardiogram demonstrated normal ventricular size and function. She was growing and developing normally (Figure 3).

Discussion

Supraventricular tachycardia is generally treated with pharmacologic or electrical cardioversion without physiologic deterioration. Congenital JET is consistently harder to treat as these patients respond poorly to antiarrhythmic medications.² Best results appear to be associated with amiodarone usage as the primary antiarrhythmic, with or without adjunct therapy.^{2,3}

Amiodarone administration can be associated with significant risks, notably hypotension, bradycardia, ventricular tachycardia, and torsades de pointes.⁴ Furthermore, amiodarone use in patients with heart failure requires close monitoring, as these potential side effects can further worsen an already decompensating patient. For our case, the hemodynamic support provided by ECMO allowed for adequate, aggressive treatment of the patient's arrhythmia without concern for further decompensation.

Radiofrequency or cryoablation has been utilized for JET, but with considerable morbidity, such as recurrent JET and secondary atrioventricular block requiring pacemaker placement.² With so few cases and limited information in the literature, there is no established treatment algorithm for patients presenting in cardiogenic shock secondary to congenital JET.

Given the difficulties in diagnosing and treating congenital JET, devising a rescue plan for clinically decompensating patients who do not respond to initial treatment is paramount. In our case, the patient did not respond to initial pharmacological treatment, electrical cardioversion, or pacing. ECMO has been used for multiple patients with various tachyarrhythmias and has been established as a lifesaving option in patients with intractable arrhythmias, including postoperative JET.⁵

Darst and Kaufman⁶ reported a similar case of a 2-month-old patient presenting in cardiogenic shock secondary to congenital JET requiring 3 days of ECMO support with dopamine (5 µg/kg/min), milrinone (0.5 µg/kg/min), and epinephrine (0.01 µg/kg/min) while adequate rhythm control was established with amiodarone (0.015 µg/kg/min) and esmolol (250 µg/kg/min). We provide our case as evidence

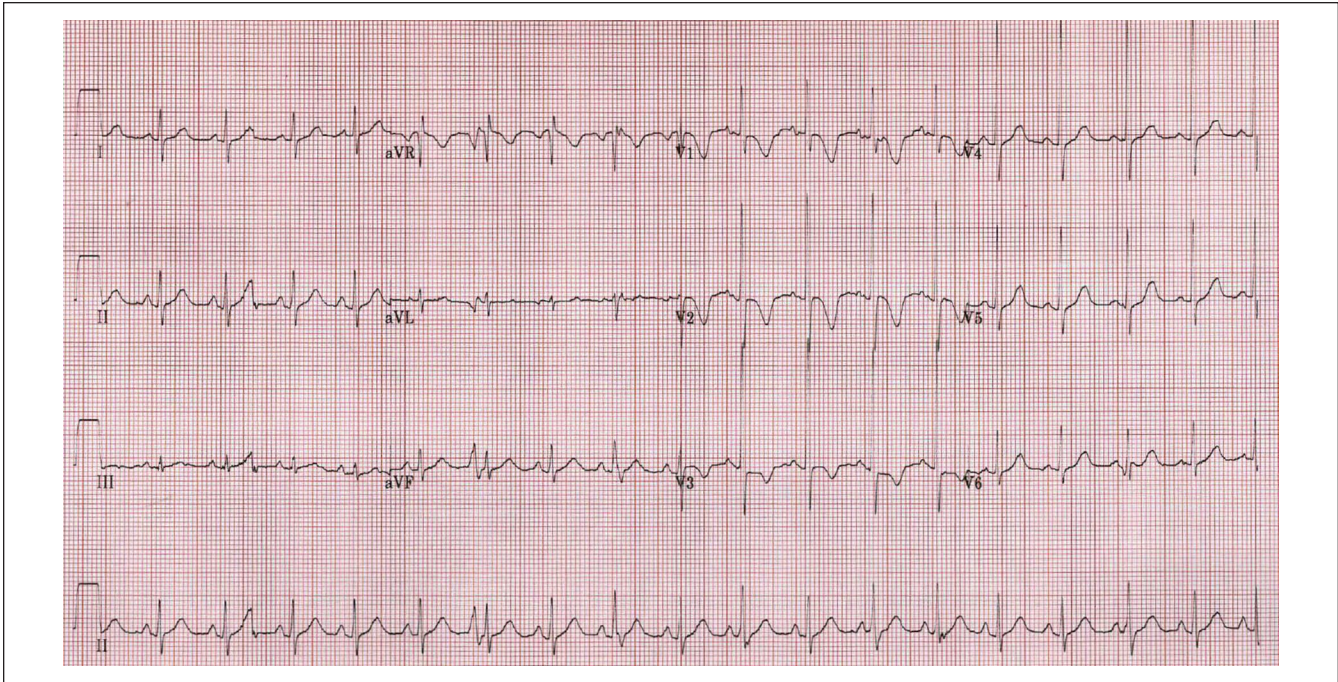


Figure 2. Electrocardiogram performed at a 6-month outpatient follow-up visit. The electrocardiogram demonstrates a normal sinus rhythm without atrioventricular dissociation.

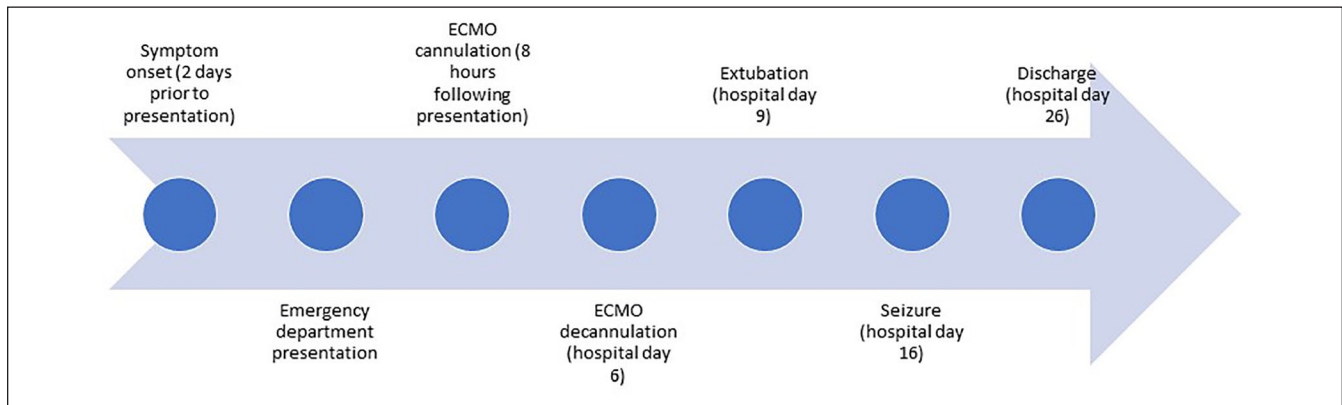


Figure 3. Patient care timeline.

that patients presenting with more significant cardiac failure secondary to congenital JET have ample time for titration and escalation of medical management when supported by ECMO. Our patient required higher levels of hemodynamic support and 6 days of ECMO and still achieved an excellent outcome.

Placing patients on ECMO support is not without risk of significant morbidity and mortality. Complications associated with ECMO cannulation and support include infection, bleeding, and thromboembolic events.⁷ ECMO, however, should be considered an option in life-threatening cases where the cause is potentially reversible, such as in the case of an arrhythmia. Prompt discussion with an ECMO center for clinically

decompensating patients is warranted in these situations to weigh the benefits and risks and to arrange rapid transfer.

Conclusion

We use this case and information available in the literature to recommend prompt consultation with or transfer to an ECMO center early on in the clinical course for pediatric patients with a life-threatening arrhythmia such as JET. In this report, the prompt decision to initiate ECMO was critical to the patient's successful outcome and likely avoided a cardiac arrest. We recommend early consideration of ECMO as a rescue modality when treating a patient with cardiogenic shock

secondary to a cardiac arrhythmia, especially one suspicious for congenital JET. ECMO can allow for further diagnostic evaluation and treatment to establish rhythm control.

Author's Note

This case report was presented in abstract form at the Society of Critical Care Medicine's 49th Critical Care Congress on February 17, 2020, and subsequently published in abstract form (Mudery J, Starr J, Batra AJ, Kelly R. Timely use of venoarterial ECMO to treat congenital pediatric junctional ectopic tachycardia. *Crit Care Med.* 2020;48(1):61 (Abstract 156). doi:10.1097/01.ccm.0000618984.38002.2).

Acknowledgments

We thank Danny Lam, ECLS Co-Coordinator, for assistance in preparing this article.

Author Contributions

JM: Drafted the initial manuscript version and reviewed the current literature.

JPS: Edited the manuscript critically for important intellectual content and provided ECMO expertise.

AB: Edited the manuscript critically for important intellectual content and provided electrophysiology expertise.

RBK: Identified the case report for submission, assisted in drafting the initial manuscript version, and revised the manuscript critically for important intellectual content.

All authors read and approved the final manuscript and are accountable for all aspects of the work.

Declaration of Conflicting Interests

The author(s) declared no potential conflicts of interest with respect to the research, authorship, and/or publication of this article

Funding

The author(s) received no financial support for the research, authorship, and/or publication of this article.

Ethics Approval

Children's Hospital of Orange County's Institutional Review Board waives approval for de-identified case reports.

Informed Consent

The patient's parent provided written consent for publication.

ORCID iD

Robert B. Kelly  <https://orcid.org/0000-0002-7825-8728>

References

1. Villain E, Vetter VL, Garcia JM, Herre J, Cifarelli A, Garson A Jr. Evolving concepts in the management of congenital junctional ectopic tachycardia. A multicenter study. *Circulation.* 1990;81:1544-1549.
2. Collins KK, Van Hare GF, Kertesz NJ, et al. Pediatric nonpost-operative junctional ectopic tachycardia medical management and interventional therapies. *J Am Coll Cardiol.* 2009;53:690-697.
3. Kylat RI, Samson RA. Junctional ectopic tachycardia in infants and children. *J Arrhythm.* 2019;36:59-66.
4. Florek JB, Girzadas D. *Amiodarone*. StatPearls Publishing. Published 2020. Accessed November 23, 2020. <https://www.ncbi.nlm.nih.gov/books/NBK482154/>
5. Dyamenahalli U, Tuzcu V, Fontenot E, et al. Extracorporeal membrane oxygenation support for intractable primary arrhythmias and complete congenital heart block in newborns and infants: short-term and medium-term outcomes. *Pediatr Crit Care Med.* 2012;13:47-52.
6. Darst JR, Kaufman J. Case report: an infant with congenital junctional ectopic tachycardia requiring extracorporeal mechanical oxygenation. *Curr Opin Pediatr.* 2007;19:597-600.
7. Hervey-Jumper SL, Annich GM, Yancon AR, Garton HJL, Muraszko KM, Maher CO. Neurological complications of extracorporeal membrane oxygenation in children. *J Neurosurg Pediatr.* 2011;7:338-344.