

UC Berkeley

UC Berkeley Previously Published Works

Title

Ardipithecus ramidus and the evolution of the human cranial base

Permalink

<https://escholarship.org/uc/item/9v63j059>

Journal

Proceedings of the National Academy of Sciences of the United States of America,
111(3)

ISSN

0027-8424

Authors

Kimbel, William H
Suwa, Gen
Asfaw, Berhane
et al.

Publication Date

2014-01-21

DOI

10.1073/pnas.1322639111

Peer reviewed

Ardipithecus ramidus and the evolution of the human cranial base

William H. Kimbel^{a,1}, Gen Suwa^b, Berhane Asfaw^c, Yoel Rak^{a,d}, and Tim D. White^{e,1}

^aInstitute of Human Origins and School of Human Evolution and Social Change, Arizona State University, Tempe, AZ 85287; ^bThe University Museum, University of Tokyo, Bunkyo-ku, Tokyo 113-0033, Japan; ^cRift Valley Research Service, Addis Ababa, Ethiopia; ^dDepartment of Anatomy and Anthropology, Sackler School of Medicine, Tel Aviv University, 69978 Ramat Aviv, Israel; and ^eDepartment of Integrative Biology, Human Evolution Research Center, University of California, Berkeley, CA 94720

Contributed by Tim D. White, December 5, 2013 (sent for review October 14, 2013)

The early Pliocene African hominoid *Ardipithecus ramidus* was diagnosed as a having a unique phylogenetic relationship with the *Australopithecus* + *Homo* clade based on nonhoning canine teeth, a foreshortened cranial base, and postcranial characters related to facultative bipedality. However, pedal and pelvic traits indicating substantial arboreality have raised arguments that this taxon may instead be an example of parallel evolution of human-like traits among apes around the time of the chimpanzee–human split. Here we investigated the basicranial morphology of *Ar. ramidus* for additional clues to its phylogenetic position with reference to African apes, humans, and *Australopithecus*. Besides a relatively anterior foramen magnum, humans differ from apes in the lateral shift of the carotid foramina, mediolateral abbreviation of the lateral tympanic, and a shortened, trapezoidal basioccipital element. These traits reflect a relative broadening of the central basicranium, a derived condition associated with changes in tympanic shape and the extent of its contact with the petrous. *Ar. ramidus* shares with *Australopithecus* each of these human-like modifications. We used the preserved morphology of ARA-VP 1/500 to estimate the missing basicranial length, drawing on consistent proportional relationships in apes and humans. *Ar. ramidus* is confirmed to have a relatively short basicranium, as in *Australopithecus* and *Homo*. Reorganization of the central cranial base is among the earliest morphological markers of the *Ardipithecus* + *Australopithecus* + *Homo* clade.

human origins | fossil record | skull | occipital bone | temporal bone

As the confluence of the neural, locomotor, and masticatory systems, the cranial base has been the site of profound structural change in human evolution. The modern human basicranium differs from that of our closest living relatives, the great apes, in numerous aspects of shape and morphological detail (1–4). In humans, the foramen magnum and occipital condyles are more anteriorly located, the midline basicranial axis is relatively short anteroposteriorly and strongly “flexed” internally, and the bilateral structures marking vascular and neural pathways through the central part of the base are more widely separated. This organization alters the relationships between the petrous and tympanic parts of the temporal bone. These phylogenetically derived features are already seen in the earliest known skulls of *Australopithecus*, ca. 3.0–3.4 Ma (5, 6).

The cranium of *Ardipithecus ramidus*, an early Pliocene (4.4 Ma) hominoid from Ethiopia, was shown to have a relatively anterior foramen magnum on a short basicranium, corroborating evidence of nonhoning canine teeth and terrestrial bipedality for phylogenetic attribution of this taxon. These sets of derived characters are shared uniquely with the *Australopithecus* + *Homo* clade (7–10). At the same time, pelvic and pedal characters indicate that *Ar. ramidus* also retained considerable arboreal capabilities (11–14). Despite the evidence for a unique phylogenetic relationship with the *Australopithecus* + *Homo* clade, it has been argued that *Ar. ramidus* may be an example of putatively widespread parallel evolution (homoplasy) of human-like traits among great apes around the time of the split between the chimpanzee and human lineages (15–17).

We report here results of a metrical and morphological study of the *Ar. ramidus* basicranium as another test of its hypothesized phylogenetic affinity with *Australopithecus* and *Homo*. We analyzed the length and breadth of the external cranial base and the structural relationship between the petrous and tympanic elements of the temporal bone in *Ar. ramidus*, *Australopithecus* (including *Paranthropus* of some authors), and mixed-sex samples of extant African hominoid (*Gorilla gorilla*, *Pan troglodytes*, *Pan paniscus*) and modern human skulls (*SI Text, Note 1*). The finding of additional shared basicranial modifications would support the hypothesis of phylogenetic affinity and weaken the alternative hypothesis of homoplasy as an explanation for human-like basicranial morphology. The outcome has important implications for understanding the functional-adaptive foundations of basicranial evolution in *Australopithecus* and *Homo*.

The best-preserved basicranial specimen of *Ar. ramidus*, ARA-VP 1/500, comprises two nonarticulating temporo-occipital portions spanning the skull’s midline. This preservation permits reconstruction of distances between bilateral landmarks, including the carotid canal and the lateral margins of the tympanic elements (7, 10) (Fig. 1 and *SI Text, Note 2*). The petrous elements are incomplete but their articulation with the tympanics is preserved. The margin of the foramen magnum includes the anterior midline point (*basion*), constituting the posterior end of the external basicranial length. The specimen is insufficiently complete to permit direct measurement of external cranial base length, from *basion* forward to *hormion* (the posterior midline point of the vomer’s intersection with the basisphenoid). Suwa et al. (10) estimated the position of the *foramen ovale* to reconstruct the anterior terminus of a relatively

Significance

The Pliocene (4.4 Ma) hominoid species *Ardipithecus ramidus* has been linked phylogenetically to the *Australopithecus* + *Homo* clade by nonhoning canines, a short basicranium, and postcranial features related to bipedality. However, aspects of the foot and pelvis indicative of arboreal locomotion have raised arguments that this taxon may instead exemplify parallel evolution of human-like traits among apes around the time of the chimpanzee–human split. Our investigation of the basicranium shows that *Ar. ramidus* shares with *Australopithecus* and *Homo* a relatively short, broad central cranial base and related modifications of the tympanic, petrous, and basioccipital elements. These similarities support the proposed relationship of *Ar. ramidus* to *Australopithecus* + *Homo*. Reorganization of the central basicranium is among the earliest morphological attributes of this group.

Author contributions: W.H.K. and G.S. designed and performed research; W.H.K., G.S., B.A., Y.R., and T.D.W. analyzed data and wrote the paper.

The authors declare no conflict of interest.

¹To whom correspondence may be addressed. E-mail: wkimbel.iho@asu.edu or timwhite@berkeley.edu.

This article contains supporting information online at www.pnas.org/lookup/suppl/doi:10.1073/pnas.1322639111/-DCSupplemental.




Fig. 1. Basal view of *Ar. ramidus* cranium ARA-VP 1/500. Dotted line indicates midline. cf, carotid foramen; ba, basion, the midline point on the anterior margin of foramen magnum. At natural size, the distance between the centers of the carotid foramina is 50.3 cm.

short basicranial length in ARA-VP 1/500. Here, we present results of evaluations of cranial base breadths and previously unpublished estimates of cranial base length for ARA-VP 1/500 using a different methodology that allows more comprehensive comparisons between of *Ar. ramidus* and *Australopithecus*. All measurements were size-standardized by the external basicranial breadth, the distance spanning the base between the indentations just above the external auditory openings (biauricular breadth), which can be measured on ARA-VP 1/500.

Results

Relative bicarotid breadth, which expresses the mediolateral span of the central basicranium, separates—without sample overlap—the narrow base of the great apes from the wide base of modern humans. In the great ape samples the bicarotid breadth constitutes (on average) 35–39% of external basicranial breadth, whereas in our modern human sample the bicarotid breadth constitutes ~49% of external basicranial breadth (Fig. 2 and Dataset S1). Our sample of nine *Australopithecus* crania, with a mean value of 43.6%, is intermediate, overlapping the ends of both the ape and human distributions (Student *t* tests are significant for all ape vs. human, *Australopithecus* vs. human, and *Australopithecus* vs. ape comparisons) (Fig. S1). Within the *Australopithecus* sample, the “robust” species *Australopithecus boisei* and *Australopithecus robustus* tend to have the largest bicarotid distances, as previously found by Dean and Wood (3). The external cranial base breadth of ARA-VP 1/500 (110 mm) approximates the average value for our sample of chimpanzee females (Dataset S1), yet its relative bicarotid breadth value (45.7%) falls in the upper part of the *Australopithecus* range, and just within the range of our modern human sample. Thus, with *Australopithecus*, *Ar. ramidus* shows a relative broadening of the center of the cranial base, a condition otherwise documented only in modern humans among extant hominoids.

It is expected that as the carotid canal shifted laterally, the tympanic length (measured from lateral margin to carotid foramen) would diminish concomitantly. This finding is indeed the

case (Fig. 3 and Dataset S1). The human cranial base features a mediolaterally shorter tympanic element (approximately 18% of biauricular breadth) than the apes’ (28–32%), and *Australopithecus* again falls intermediate between the two (24%; as before, all Student *t* test results are significant) (Fig. S1). Within *Australopithecus*,

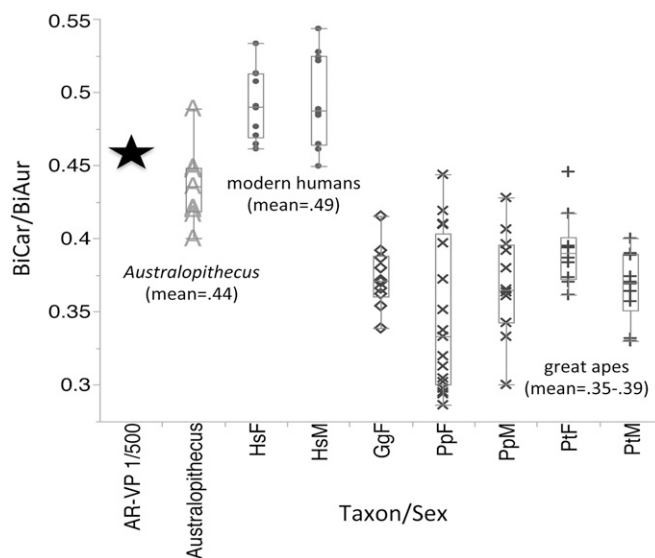


Fig. 2. Box-and-whisker plot of relative bicarotid breadth. Horizontal line within box is the median; lower and upper ends of the box represent the first and third quartiles, respectively; and the ends of the whiskers represent $\pm 1.5 \times$ interquartile range. x-axis abbreviations: HsF, *Homo sapiens* female ($n = 10$); HsM, *Homo sapiens* male ($n = 10$); GgF, *Gorilla gorilla* female ($n = 10$); PTF, *Pan troglodytes* female ($n = 10$); PtM, *Pan troglodytes* male ($n = 10$); PpF, *Pan paniscus* female ($n = 17$); PpM, *Pan paniscus*, male ($n = 12$). Individual fossil specimen and comparative sample data are provided in Dataset S1.

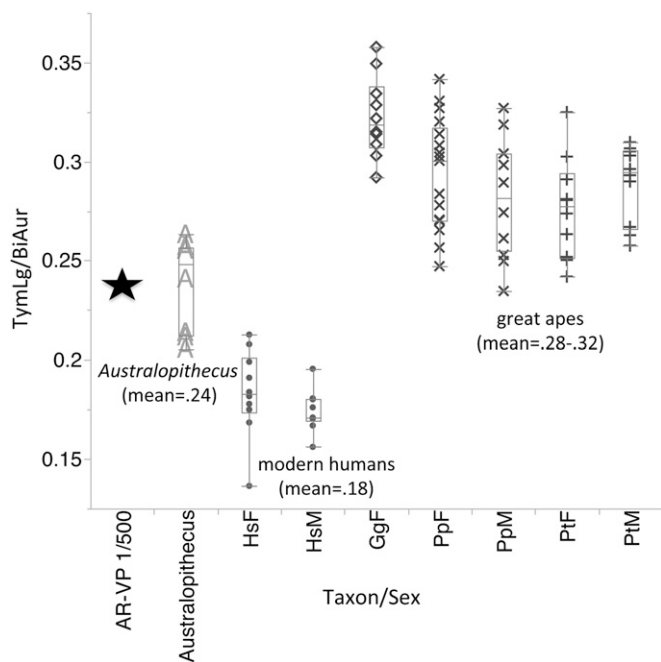


Fig. 3. Box-and-whisker plot of relative tympanic length. See Fig. 2 legend for explanation.

the longest tympanics belong to *Au. boisei* and *Au. robustus* crania, but this is because of a secondary elongation of the tympanic at its lateral margin, which often results in the tympanic projecting farther laterally than any other structure on the base. Despite this projection, the lateral shift of the carotid foramina in these species

yields a much shorter relative tympanic length than in the great majority of apes. The ARA-VP 1/500 value (24%) is identical to the *Australopithecus* mean, which is matched by no ape cranium in our sample.

These metrical changes modify the relationship between the tympanic and petrous elements of the temporal bone. As the tympanic extends medially in the generalized hominoid configuration (Fig. 4A and Fig. S2), including that of orangutans and gibbons, it bends sharply anteriorly to terminate in a prominent projection (the eustachian process) that forms the bony floor of the cartilaginous eustachian tube lateral to the petrous element. Here it frequently anchors the origins of *levator veli palatini* and *tensor veli palatini* muscles (18). The tympanic rarely extends medially past the carotid foramen to any significant degree, and so leaves the basal surface of the petrous almost completely uncovered. In humans (Fig. 4B), the homologous anatomy is quite different. Here, the eustachian process extends the tympanic's long axis medially, often well past the laterally shifted carotid foramen, where it overlaps some 30–40% of the petrous element's length. In place of the anteriorly projecting eustachian process observed in the apes, a prominent posterior angle of the sphenoid bone (bearing the sphenoid spine) abuts the petrous laterally and makes a substantial contribution to the entoglenoid process of the temporal squama, bounding the mandibular fossa medially. Crania of *Australopithecus* species show the human pattern (Fig. 4C and D), despite well-documented variation in the details of glenoid region morphology (3, 5). Although the petrous in ARA-VP 1/500 is broken (Fig. 5), the preserved portion is completely covered by the tympanic, which terminates well medial to the carotid foramen in an abraded but prominent eustachian process. The eustachian process is variably developed in *Australopithecus*, suggesting that the *tensor veli palatini* muscle had not migrated as far laterally as in later *Homo* (18). As the original differential diagnosis of *Ar. ramidus* noted, ARA-VP 1/

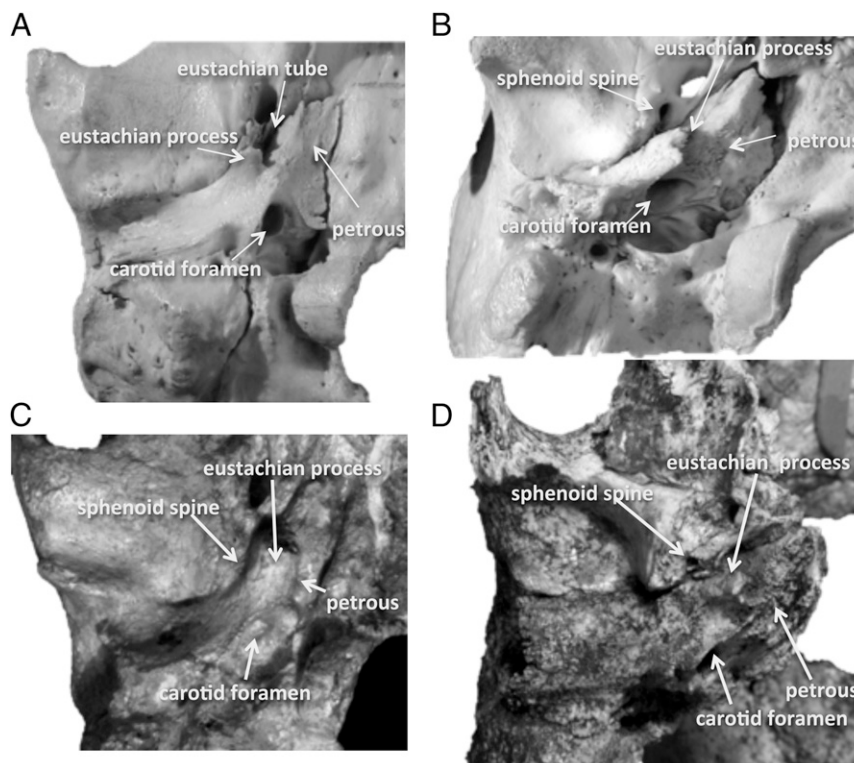


Fig. 4. Anatomy of the tympanic/petrous relationship *Pan*, *Homo*, and *Australopithecus*: (A) chimpanzee, (B) modern human, (C) *Australopithecus africanus* (Sts 5), (D) *Australopithecus robustus* (DNH 7). See additional specimens in Fig. S2.

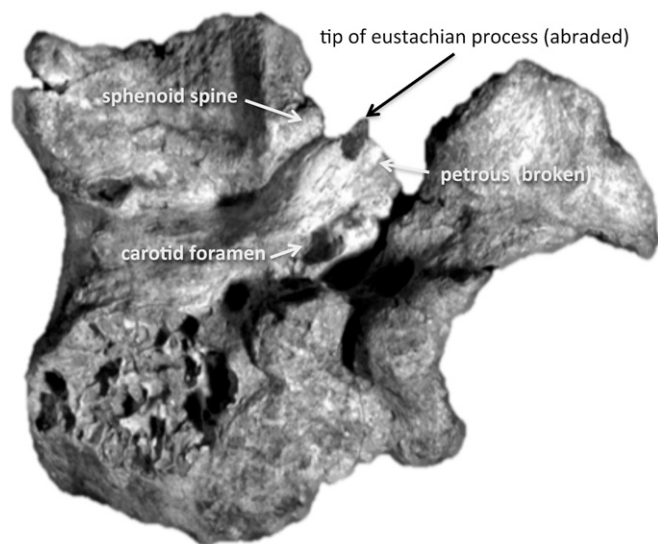


Fig. 5. Anatomy of the tympanic/petrous relationship: *Ardipithecus ramidus* specimen ARA-VP 1/500, image reversed for ease of comparison with Fig. 4. Note tip of eustachian process is darkened by abrasion of surface bone.

500 is distinguished from extant apes by “the carotid foramen placed posteromedial to tympanic angle” (7), reflecting the lateral shift of the foramen with the broadening of the central basicranium. In ARA-VP 1/500, a developed posterior angle of the sphenoid is also evident (Fig. 5). In all of these respects, *Ar. ramidus* conforms to the pattern shared by both modern humans and *Australopithecus*.

To estimate external cranial base length (*basion-hormion*) in ARA-VP 1/500, we reconstructed the length of the missing segment anterior to the fossae for the mandibular condyle’s articulation with the cranial base (*SI Text, Note 3*). For our comparative samples of chimpanzee, gorilla, and human crania, we calculated the ratio between the distance from *basion* to a line connecting the summits of the entoglenoid processes at the medial end of the mandibular fossae (“*basion-bientoglenoid* length,” which can be directly measured on ARA-VP 1/500), and *basion-hormion* length. The sample mean ratios varied over a narrow range, from 0.61 in human females to 0.56 in chimpanzee males, but within each sample, the values distributed widely and their ranges broadly overlapped (*Dataset S2*). We substituted a range of these values in the ratio for ARA-VP 1/500 to solve for the total *basion-hormion* length (*SI Text, Note 3*). The results, when adjusted for the biauricular cranial size standard, completely encompass the short relative basicranial lengths of the modern human sample and the two *Australopithecus* crania (Sts 5, Sts 19) preserved well enough to be included in this part of the analysis (Fig. 6). All but one estimate (-2 SDs below the male chimpanzee mean) fall well below the relatively large relative cranial base lengths of the great ape samples. As we noted previously (10), despite its slightly more anterior foramen magnum (19, 20), the bonobo (*P. paniscus*) does not have a relatively shorter external cranial base than the other African great apes. ARA-VP 1/500 is confirmed by these results to have a relatively short basicranium, which is shared only with *Homo* and *Australopithecus* among hominoids.

The broad, short basicranium is associated with other changes in the cranial base that can be inferred for *Ar. ramidus*. In *Australopithecus* and *Homo* the shape of the basioccipital element, which spans most of the external basicranial length, is an anteroposteriorly abbreviated trapezoid, much wider immediately in front of the foramen magnum than further anteriorly (at the level of the spheno-occipital synchondrosis). Because of the

posteriorly divergent margins of the basioccipital element, the openings of the hypoglossal canals, located just anterolateral to the foramen magnum, are similarly far apart on the base. In contrast, in the apes (and many other primates) the basioccipital is more rectangular, reflecting the proportional differences in the basicranium of these species. In ARA-VP 1/500, the basioccipital does not preserve its synchondrosal articulation with the sphenoid bone anteriorly, but the short, trapezoidal outline of the element is obvious (as it is also on the otherwise poorly preserved basicranium of a second adult *Ar. ramidus* individual, ARA-VP 6/500) (10). The *Ar. ramidus* basioccipital shape and lateral placement of the hypoglossal canal are strikingly similar to the configuration in *Australopithecus afarensis* (Fig. 7). Both ARA-VP 1/500 and ARA-VP 6/500 basioccipitals also share with many *Australopithecus* and *Homo* crania relatively weak topography of the prevertebral muscle (*rectus capitis anterior* and *longus capitis*) insertion sites, in contrast to the deep concavities and anterolaterally situated prominences commonly seen in *Pan* and *Gorilla* (10, 18).

The basioccipital’s lateral margins mirror the orientation of the adjacent petrous element on the external cranial base. In *Australopithecus* and *Homo*, the posteriorly divergent margins of the short, trapezoidal basioccipital reflect the diagonal path of each petrous across the base (thus, the left and right petrous bones form a relatively wide posterior angle with one another); in contrast, the parallel margins of the long basioccipital of the apes match the more anterior–posterior orientation of the petrous externally (and thus, a much more acute angle is formed between the two). Although about half of the petrous is missing in ARA-VP 1/500, its full extent can be visualized using the preserved outlines of the basioccipital. Again, there is no doubt that its similarity lies with the diagonally oriented petrous of the *Australopithecus* + *Homo* clade.

Discussion

As previously demonstrated by Suwa et al. (10), using a different method to estimate basicranial length (*SI Text, Note 3*), the ARA-VP 1/500 paratype cranium of *Ar. ramidus* is shown here to have an anteroposteriorly short cranial base. Suwa et al. (10) also inferred from the orientation of the basioccipital element that the ARA-VP 1/500 cranial base axis was ventrally flexed, as in *Australopithecus* and *Homo*, based on a composite reconstruction

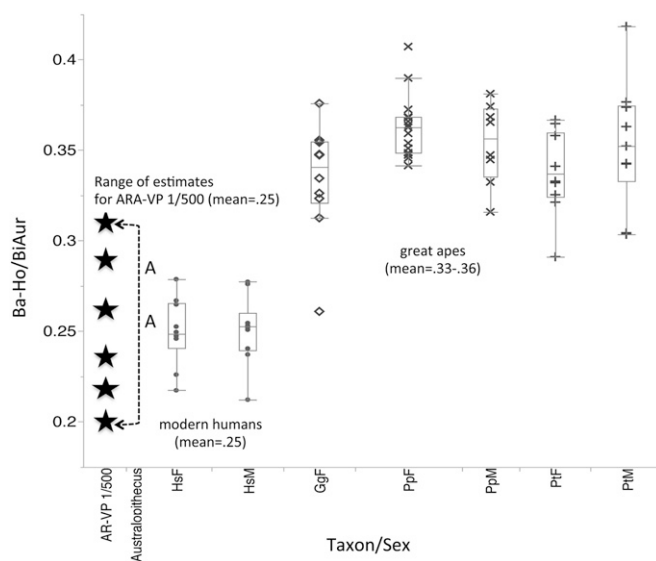


Fig. 6. Box-and-whisker plot of relative length of the external basicranium. Then range of estimated values for ARA-VP 1/500 is shown at left (main text and *SI Text, Note 3*). See Fig. 2 legend for explanation.

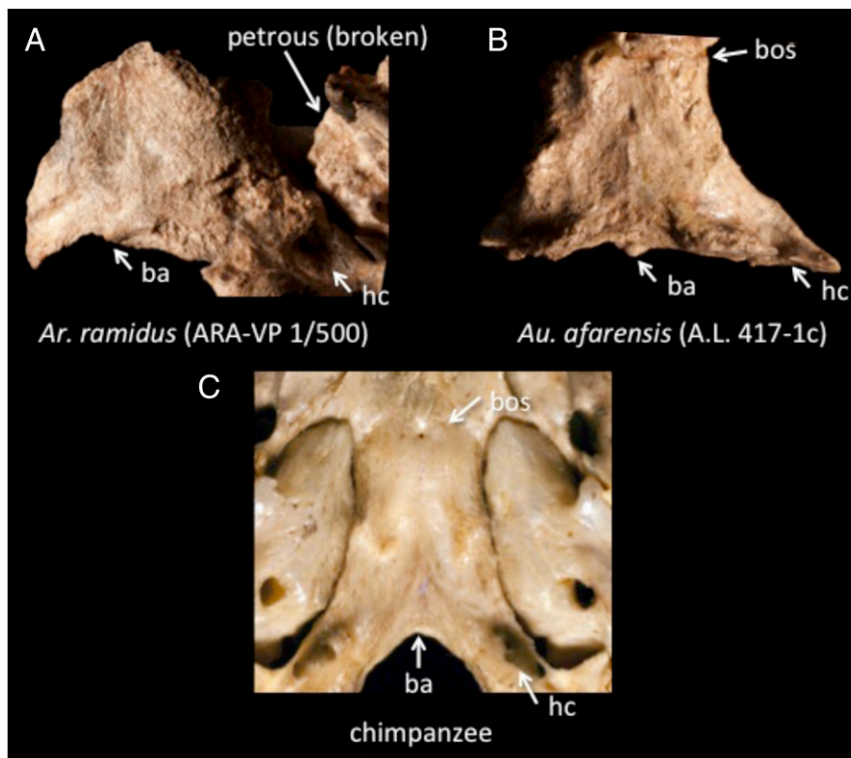


Fig. 7. Comparison of basioccipital morphology in (A) *Ardipithecus ramidus*, ARA-VP 1/500; (B) *Australopithecus afarensis*, A.L. 417-1c; and (C) chimpanzee. ba, basion; bos, basioccipital synchondrosis; hc, hypoglossal canal.

that joined a slightly scaled-down but otherwise unmodified ARA-VP 1/500 to the face and braincase of a second adult individual (ARA-VP 6/500). When combined with our data showing that ARA-VP 1/500 also possesses a broad central basicranium and a consequently abbreviated tympanic element, a pattern emerges that is fundamentally like that of *Australopithecus* and derived in the direction of modern humans. The phylogenetically derived overlap of the tympanic and the petrous elements of the temporal bone, the prominent posterior sphenoid angle, and the inferred diagonal orientation of the petrous on the external basicranium, strongly reinforce this pattern of affinity.

The derived anatomy of the *Ar. ramidus* cranial base is so pervasive and detailed that we find it difficult to agree with the suggestion that it just as likely reflects homoplastic similarity to, rather than true kinship with, the *Australopithecus* + *Homo* clade (15, 17). Indirect support for this view comes from the skulls of primates that are frequently cited as examples of parallel evolution of human-like cranial base morphology. For example, whereas the foramen magnum of the neurocranially “pedomorphic” bonobo (*P. pansicus*) skull tends to be located slightly more anterior than in the chimpanzee (19–21), its external base is relatively just as long and narrow as in the other African apes, and none of the derived tympanic and petrous anatomy is present (Fig. S2). Similarly, in the squirrel monkey (*Saimiri* spp.) the foramen magnum is centrally located on the basicranium. However, this condition is linked to the effects of a dramatic posterior elongation of the occipital lobe of the telencephalon in this small-bodied, relatively large-brained platyrrhine (19, 22). Anterior to its foramen magnum, the base is very long and unflexed, as in most other primates (2, 23). In these cases, sufficiently close inspection of the larger anatomical context reveals the logical basis for identifying homoplasy as the most likely explanation for the observed similarity (e.g., via scaling effects of small body size in *Saimiri*).

The phylogenetically derived central cranial base configuration of the *Ar. ramidus* cranium presents a strong contrast with the primitive anatomy of other parts of the skull, including some of the more peripheral parts of the base, such as the glenoid region of the temporal bone, with its flat mandibular fossa and small-caliber tympanic tube (7, 10). A similar distinction in phylogenetic signal is seen in the earliest known *Australopithecus* crania. For example, in *Au. afarensis*, the cranial base is relatively short, with an anterior foramen magnum, and internally flexed. However, the nuchal plane of the occipital bone, anchoring the neck muscle insertions at the posterior end of the cranium, often rises steeply to a high position on the back of the braincase in an apelike manner (6). Within and among species of *Australopithecus* and early *Homo* there is considerable variation in the bony morphology of the nuchal and glenoid regions, including differences between “robust” and “nonrobust” species of *Australopithecus* (3, 5). However, this variation appears to be unlinked to the morphology of the central basicranium, the derived configuration of which, as described here, was apparently fixed early in the clade’s evolutionary history (3, 6, 10, 24–26).

From the modern human perspective, we can see that at least 4 million y of dramatic evolution of the skull (and the soft tissues it encloses and supports) did not affect the fundamental structure of the central basicranium. Later modifications affected the anterior and lateral cranial base, spanning the anterior and middle cranial fossae on which the frontal and temporal lobes of the cerebrum sit. This strongly mosaic pattern of anatomical change highlights the suggestion that basicranial evolution in humans has been constrained in relative length and internal flexion to avoid “occlud[ing] the airway and disturb[ing] the functional relationships in the masticatory apparatus” (24).

The crania of *Ardipithecus* and *Australopithecus* show that in relative length and midsagittal flexion, a condition closely approaching that of modern humans, was already present in the Pliocene. On the other hand, our data show that between

Australopithecus and modern humans, there has been a secondary increase in the breadth of the central base (as seen in the increased relative distance between larger carotid foramina). This finding most likely reflects, in part, the absolute brain enlargement that subsequently occurred in the *Homo* lineage, with fewer apparent constraints on the mediolateral expansion of the base than on changes along its anteroposterior axis. The lateral shift of the upper pharyngeal muscle attachments from the tympanic and petrous (in the apes) to the sphenoid (in modern humans) (18) may be related to this secondary expansion in basicranial breadth. Expansion of the middle cranial fossa and the lateral part of the anterior cranial fossa in *Homo* apparently postdated midsagittal flexion of the base, affecting both endocranial and facial structure (25, 27). This pattern of change is consistent with the hypothesis of developmental modularity in the evolutionary emergence of human cranial base form (27).

The forward migration of the foramen magnum and the craniovertebral articulation at the adjacent occipital condyles is associated with both the reduced anteroposterior length and expanded mediolateral breadth of the basicranium in *Ardipithecus*, *Australopithecus*, and *Homo*. The long history of debate

over the ultimate cause of this shift in human evolution divides opinion among relative enlargement or restructuring of the brain (2, 4, 26, 28–30), brain restructuring interacting with facial/pharyngeal development (2, 10), or the acquisition of orthograde posture and bipedal locomotion (6, 19, 26, 31–33). The appearance of human-like basicranial anatomy in *Ar. ramidus*, a species with an ape-size brain whose locomotion bridged the gap between arboreal quadrumanal clambering and terrestrial bipedality, affords an opportunity to refocus research on the etiology of these evolutionary changes in human skull structure.

ACKNOWLEDGMENTS. We thank the Authority for Research and Conservation of Cultural Heritage (Ethiopian Ministry of Culture and Tourism) and the staff of the National Museum of Ethiopia, Addis Ababa, for facilitating access to the fossil collections in their care; the staffs of the Cleveland Museum of Natural History, the Musée Royal de Afrique Centrale, Tervuren, and the Archaeological Research Institute, Arizona State University, for access to great ape and human skeletal collections; Jason Massey and Kieran McNulty for generously sharing their bonobo craniometrics; Halszka Glowacka for assisting with data collection; Halszka Glowacka and Terry Ritzman for helpful discussions; and Christopher Dean and an anonymous referee for constructive reviews of the manuscript.

- Weidenreich F (1943) The skull of *Sinanthropus pekinensis*: A comparative study of a primitive hominid skull. *Palaentol Sin*, New Ser D, 10.
- Biegert J (1957) Der Formwandel des Primatenschädels und seine Beziehungen zur ontogenetischen Entwicklung und den phylogenetischen Spezialisierungen der Kopforgane. *Gegenbaurs Morphol Jahrb* 98:77–199.
- Dean MC, Wood BA (1982) Basicranial anatomy of Plio-Pleistocene hominids from East and South Africa. *Am J Phys Anthropol* 59(2):157–174.
- Lieberman DE, Ross CF, Ravosa MJ (2000) The primate cranial base: Ontogeny, function, and integration. *Am J Phys Anthropol* 43(Suppl 31):117–169.
- Kimbel WH, Rak Y, Johanson DC (2004) *The Skull of Australopithecus afarensis* (Oxford Univ Press, New York).
- Kimbel WH, Rak Y (2010) The cranial base of *Australopithecus afarensis*: New insights from the female skull. *Philos Trans R Soc Lond B Biol Sci* 365(1556):3365–3376.
- White TD, Suwa G, Asfaw B (1994) *Australopithecus ramidus*, a new species of early hominid from Aramis, Ethiopia. *Nature* 371(6495):306–312.
- White TD, Suwa G, Asfaw B (1995) *Australopithecus ramidus*, a new species of early hominid from Aramis, Ethiopia. *Nature* 375(6526), 88, Corrigendum for *Nature* 371(6495): 306–312.
- White TD, et al. (2006) Asa Issie, Aramis and the origin of *Australopithecus*. *Nature* 440(7086):883–889.
- Suwa G, et al. (2009) The *Ardipithecus ramidus* skull and its implications for hominid origins. *Science* 326(5949):e1–e7.
- Lovejoy CO, Latimer B, Suwa G, Asfaw B, White TD (2009) Combining prehension and propulsion: the foot of *Ardipithecus ramidus*. *Science* 326(5949):e1–e8.
- Lovejoy CO, Simpson SW, White TD, Asfaw B, Suwa G (2009) Careful climbing in the Miocene: The forelimbs of *Ardipithecus ramidus* and humans are primitive. *Science* 326(5949):e1–e8.
- Lovejoy CO, Suwa G, Simpson SW, Matternes JH, White TD (2009) The great divides: *Ardipithecus ramidus* reveals the postcrania of our last common ancestors with African apes. *Science* 326(5949):100–106.
- Lovejoy CO, Suwa G, Spurlock L, Asfaw B, White TD (2009) The pelvis and femur of *Ardipithecus ramidus*: The emergence of upright walking. *Science* 326(5949):e1–e6.
- Harrison T (2010) Anthropology. Apes among the tangled branches of human origins. *Science* 327(5965):532–534.
- Sarmiento EE (2010) Comment on the paleobiology and classification of *Ardipithecus ramidus*. *Science* 328(5982):1105–, author reply 1105.
- Wood BA, Harrison T (2011) The evolutionary context of the first hominins. *Nature* 470(7334):347–352.
- Dean MC (1985) Comparative myology of the hominoid cranial base. II. The muscles of the prevertebral and upper pharyngeal region. *Folia Primatol (Basel)* 44(1):40–51.
- Schultz AH (1955) The position of the occipital condyles and of the face relative to the skull base in primates. *Am J Phys Anthropol* 13(1):97–120.
- Luboga SA, Wood BA (1990) Position and orientation of the foramen magnum in higher primates. *Am J Phys Anthropol* 81(1):67–76.
- Lieberman DE, Carlo J, Ponce de León M, Zollikofer CP (2007) A geometric morphometric analysis of heterochrony in the cranium of chimpanzees and bonobos. *J Hum Evol* 52(6):647–662.
- Hershkovitz P (1977) *Living New World Monkeys (Platyrrhini)* (Univ of Chicago Press, Chicago), Vol 1.
- Hofer HO (1969) The evolution of the brain of primates: Its influence on the form of the skull. *Ann N Y Acad Sci* 167:341–356.
- Ross CF, Henneberg M (1995) Basicranial flexion, relative brain size, and facial kyphosis in *Homo sapiens* and some fossil hominids. *Am J Phys Anthropol* 98(4):575–593.
- Baba H, et al. (2003) *Homo erectus* calvarium from the Pleistocene of Java. *Science* 299(5611):1384–1388.
- Spoor F (1997) Basicranial architecture and relative brain size of Sts 5 (*Australopithecus africanus*) and other Plio-Pleistocene hominids. *S Afr J Sci* 93:182–186.
- Bastir M, Rosas A (2009) Mosaic evolution of the basicranium in *Homo* and its relation to modular development. *Evol Biol* 36(1):57–70.
- Bolk L (1909) On the position and displacement of the foramen magnum in the primates. *Verh Akad Wet Amst* 12:362–377.
- Dabelow A (1931) Über Korrelationen in der phylogenetischen Entwicklung der Schädelform II. Beziehungen zwischen Gehirn und Schädelbasisform bei den Mammalieren. *Gegenbaurs Morphol Jahrb* 67:84–133.
- Strait DS, Ross CF (1999) Kinematic data on primate head and neck posture: Implications for the evolution of basicranial flexion and an evaluation of registration planes used in paleoanthropology. *Am J Phys Anthropol* 108(2):205–222.
- Weidenreich F (1941) The brain and its role in the phylogenetic transformation of the human skull. *Trans Amer Phil Soc* 31:320–442.
- Moss ML (1961) Rotation of the otic capsule in bipedal rats. *Am J Phys Anthropol* 19(3):301–307.
- Russo GA, Kirk EC (2013) Foramen magnum position in bipedal mammals. *J Hum Evol* 65(5):656–670.