


# The Remarkables

Endocrine Abnormalities in Art

The Remarkables Endocrine Abnormalities in Art

Carol Z. Clark  
Orlo H. Clark, MD

Carol Z. Clark  
Orlo H. Clark, MD



How do changing notions of beauty and ugliness affect attitudes toward physical deformities? To what extent was the birth of a dwarf, a giant or a hirsute child thought to reflect the depraved imagination of the mother and classify her child as a monster or freak of nature? *The Remarkables: Endocrine Abnormalities in Art* addresses these questions and others in the context of medical, social, intellectual, and art history from antiquity to the twentieth century in Western Europe. In five chapters the authors review endocrine abnormalities whose physical, and sometimes mental, signs appear in European paintings and sculpture: diffuse and disfiguring goiter, Graves' disease, thyroid cancer, disorders of the pituitary, adrenal and parathyroid glands, and the gonads. Each chapter includes a detailed discussion of the medical history of the disorders: the etiology, epidemiology, and history of treatment followed by a discussion of pertinent examples of art presented thematically to reflect the influence of geography, religion, social politics, cultural traditions, and aesthetic theories on each artist's representation of endocrine disease. The book's comparative study examines the development of empirical knowledge and scientific discovery that inspired parallel experimentation in both medicine and art. With their focus on the important intersection of the two disciplines throughout history, the authors consider a variety of paintings that demonstrate the artist's skill of observation manifested in accurate illustrations of disease. Although neither artists nor physicians understood the causes and manifestations of endocrine disease until the late nineteenth century, the book's examples document that artists were often the more astute observers of the "human condition."



# **The Remarkables**

**Endocrine Abnormalities in Art**

---

## Perspectives in Medical Humanities

Perspectives in Medical Humanities publishes scholarship produced or reviewed under the auspices of the University of California Medical Humanities Consortium, a multi-campus collaborative of faculty, students and trainees in the humanities, medicine, and health sciences. Our series invites scholars from the humanities and health care professions to share narratives and analysis on health, healing, and the contexts of our beliefs and practices that impact biomedical inquiry.

---

## General Editor

Brian Dolan, PhD, Professor of Social Medicine and Medical Humanities,  
University of California, San Francisco (UCSF)

---

## Forthcoming Titles

*Paths to Innovation: Discovering Recombinant DNA, Oncogenes, and Prions  
In One Medical School, Over One Decade*

By Henry Bourne (Fall, 2011)

*Clowns and Jokers Can Heal Us: Comedy and Medicine*

By Albert Howard Carter III (Fall, 2011)

*Health Citizenship: Essays in Social Medicine and Biomedical Politics*

By Dorothy Porter (Fall, 2011)

*Darwin and the Emotions: Mind, Medicine and the Arts*

Edited by Angeliqe Richardson and Brian Dolan (Fall, 2012)



---

[www.medicalhumanities.ucsf.edu](http://www.medicalhumanities.ucsf.edu)

---

[brian.dolan@ucsf.edu](mailto:brian.dolan@ucsf.edu)

---

This series is made possible by the generous support of the Dean of the School of Medicine at UCSF, the Center for Humanities and Health Sciences at UCSF, and a Multi-Campus Research Program grant from the University of California Office of the President.

# **The Remarkables**

**Endocrine Abnormalities in Art**

**Carol Z. Clark**

**Orlo H. Clark, MD**

First published in 2011

by UC Medical Humanities Consortium and distributed by UC Press.

BERKELEY — LOS ANGELES — LONDON

© 2011

University of California

Medical Humanities Consortium

3333 California Street, Suite 485

San Francisco, CA 94143-0850

Designed and typeset by Eduardo de Ugarte

---

Library of Congress Control Number: 2011930921

ISBN 978-0-9834639-0-0

Printed in China

# Contents

---

Acknowledgments		I
Introduction to <i>The Remarkables: Endocrine Abnormalities in Art</i>		3
<hr/>		
<b>Chapter 1</b>	<b>THE GOITER BEAUTIFUL: PURITY, SENSUALITY, FERTILITY</b>	<b>10</b>
	Introduction	11
	History of thyroid disease and goiter, its etiology and epidemiology, the association of the full rounded neck with beauty, sensuality, fertility, and maternity	16
	The goiter beautiful in art	23
<hr/>		
<b>Chapter 2</b>	<b>THE GOITER GROTESQUE: POWER, TREACHERY, OR HUMBLENESS?</b>	<b>62</b>
	Introduction	63
	Etiology and treatment of disfiguring (surgical) goiter, Graves' disease, and cretinism	64
	The development of thyroid surgery and treatment of thyroid cancer	69
	The goiter grotesque in art	72
<hr/>		
<b>Chapter 3</b>	<b>LITTLE PEOPLE: FASCINATION OR EXPLOITATION?</b>	<b>90</b>
	Introduction	91
	Types of dwarfism; pituitary dysfunction and other etiologies	92
	History of diagnosis and treatment of dwarfism	94
	Little people in mythology, art, and history	97

<b>Chapter 4</b>	<b>GIANTS AND ACROMEGALICS: STIGMA OR STATURE?</b>	<b>124</b>
	Introduction	125
	Causes of gigantism and acromegaly	126
	Medical history and treatment of gigantism and acromegaly	127
	Giants in mythology, art, and history	129
<b>Chapter 5</b>	<b>“AN EXCESS OF SEED”: ENDOCRINE DISORDERS OF THE SEX GLANDS, ADRENAL GLANDS, AND PARATHYROID GLANDS</b>	<b>148</b>
	Introduction	149
	Sexual disorders controlled by the endocrine glands	150
	Attitudes toward sexual ambiguity in religion, medicine, and history	152
	Medical history and etiology of sexual disorders	154
	Disorders of the adrenal glands and parathyroid glands	157
	The gonads, adrenal glands, and parathyroid glands in art	160
List of Illustrations		176
Bibliography		184
End Notes		191
Glossary of Medical Terms		206
Index		212





**“The power of art is the power of  
unsettling surprise.”**

— Simon Schama, *The Power of Art*

This book is dedicated to our children Catharine, Emilie, and Andrew and to their families, who have taught us about art in myriad and wonderful ways.

## Acknowledgments

We are grateful to our professional institutions, the University of California San Francisco Medical School and the Crystal Springs Uplands School, Hillsborough, CA for their generous support of sabbatical leaves that enabled us to begin this project in 1997 and continue our research in 2004. The support of Orlo's colleagues has inspired us to pursue

our research in the midst of busy schedules: UCSF Dept. of Surgery, Dr. Nancy Ascher, Chair; UCSF Endocrine Surgery colleagues: Doctors Quan Yang Duh, Wen Shen, and Jessica Gosnell; and numerous colleagues in professional organizations: International Association of Endocrine Surgeons, American Association of Endocrine Surgeons, Pacific Coast Surgical Association, and American Thyroid Association.

We are grateful to the following institutions and organizations for arranging invited lectures on the subject of Endocrine Abnormalities in Art: the University of California, San Francisco, Dept. of Surgery (2005); University of Calgary, Calgary, Alberta, Canada (2005); the Phoenix Surgical Society (2006); the British Association of Endocrine Surgeons

(2006); Johns Hopkins University, Dept. of Surgery, Baltimore, Maryland (2007); University of British Columbia, Vancouver, B.C., Canada (2007); Postgraduate Course in Endocrinology and Endocrine Surgery, Cesme, Turkey (2009); The Bay Area History of Medicine Club, San Francisco, California (with Carol Clark) (2010); the University of Utrecht, Netherlands (2010).

Special thanks to librarians Gloria Won and Gail Sorrough at the Fishbon/UCSF Mt. Zion Hospital library, to the librarians and staff at the Wellcome Library, London and at the Ashmolean Museum archives, Oxford, and to head librarian Maria Conforti at the History of Medicine Library, University of Rome, Sapienza, Rome, Italy for their aid in locating sources and providing pleasant spaces

to accommodate our research. We are grateful to Dept. of Surgery administrative assistant Joy Oson at UCSF/ Mt. Zion, Dept. of Surgery for her technical help and efficient printing of manuscripts.

We are especially grateful to Dr. Brian Dolan, Professor and Vice-Chair of the UCSF Department of Anthropology, History & Social Medicine and Director, UC Medical Humanities Consortium for inviting us to include our book in the Consortium series. We thank him for his careful management of the publishing process and support of our project. We thank Doctors Melvin Grumbach and Felix Conte of the UCSF Dept. of Pediatrics for generously offering their expertise in the field of pediatric endocrinology.

We are indebted to Professor Sebastiano Filetti of the University of Rome, Sapienza for his encouragement and help with accessing research facilities and archives in Rome, and to Dr. Menno Vriens, University of Utrecht, Netherlands for help in securing image permissions in the Netherlands.

We wish to acknowledge fiction writer Joel Ben Izzy and Springer/Humana Press editor Richard Lansing for reading and commenting on our manuscript. Thanks also to Carol's professional colleagues at Crystal Springs Uplands School, Helen Harper and Steve Weislogel, for their encouragement and suggestions for images; and to members of Carol's writing group Alison Draper, Liz Greenberg and Dildar Pisani, who helped to critique part of our manuscript.



## Introduction

The title for our book *The Remarkables: Endocrine Abnormalities in Art* alludes to the intersection of scientific and aesthetic sensibilities that began to link the seemingly unrelated disciplines of medicine and visual art in Renaissance Europe. The concept of medicine as art, the physician as artist, or the artist as scientist is not as contradictory as it would seem. As artists and physicians in Renaissance Europe became more aware of the human body, its anatomy and functions, they began to challenge established precepts and directly or indirectly influenced each other, often with remarkable results.

Given the large number of Renaissance and Baroque paintings whose human figures appear to have signs of endocrine disease, we can recognize a developing pattern in European art that reflects artists' accurate depictions of anatomical detail and their knowledge of human anatomy. This development is not surprising when one considers the growing importance of science in the fifteenth through seventeenth centuries. Historian Katharine Park argues that contrary to the assumption that there was "a deep hostility between humanists and

physicians, ... the interests of doctors and humanists began to converge"<sup>1</sup> in early Renaissance Italy, for example, and "the decades around 1400 saw a lively dialogue between students and teachers at the studio and professional amateur humanists outside" (Park 223). The anatomical theater was the place where physicians and artists worked together, even sharing cadavers for their research.

Anatomical dissection was a relatively new concept in the early seventeenth century when the great anatomy theaters of Padova, Leiden and Bologna were created. Built to resemble Greek and Roman theaters, with the dissection table at the base of several rows of tiered seating, anatomy theaters were also the center of action in the medical sciences.<sup>2</sup> Similar to the anatomy theater was the artist's studio in which art students gathered around the "master" much as medical students gathered around the anatomist in a theatrical setting. In both settings fascination with the structure and functions of the human body led to recognition of physical abnormalities in human anatomy and physiology, among them those related to the endocrine glands.

Even with our twenty-first century's emphasis on specialization in medicine and surgery, the link between artists and medical scientists persists. A New York Times article dated April 17, 2006 reported that medical students at Mt. Sinai Medical School in New York City were required to enroll in an art appreciation course in order to augment the "observational abilities" needed for thorough and accurate examination of patients.<sup>3</sup> Other schools such as Cornell, Stanford and Yale have instituted similar programs (Kennedy). Recently an administrator at a well known art museum in New York told us a similar story about courses for police academy students as well as medical students. Although the general public might be skeptical about the perceived connections between scientific

or forensic analysis and the viewing of art, Renaissance thinkers might have embraced such a concept quite naturally.

The representation of physical abnormalities in art actually preceded the use of anatomical dissection theaters. We have discovered examples of physical signs of endocrine disease in works dating from Greek, Etruscan and early Roman sculpture and painting. Similar signs appear again in numerous paintings dating from the early Italian Renaissance (1400's) through the Baroque period (1600's). These works along with medical manuscripts from the same eras document a growing awareness of physical abnormalities while also revealing changing aesthetic, religious and social attitudes. Such attitudes must have influenced the choices made by artists and scientists.

Recognition and depiction of physical abnormalities in painting and sculpture may have happened by chance or may have been influenced by an artist's interest in the use of naturalistic detail. Since it was often practical for an artist to use the same model for a variety of subjects, whether religious, classical or secular, the same anatomical features appear frequently within an artist's oeuvre, thus enabling the viewer to recognize the abnormality represented. The artists' reasons for representing anatomical abnormalities such as diffuse or disfiguring goiters, cretinism, dwarfism, gigantism and other rare manifestations of endocrine disease were most likely diverse. Their choices may have reflected both prag-

matic and aesthetic interests as well as a fascination with science and curiosity about "the other" or those remarkable individuals marginalized by society.

Examined side by side, medical theories and practices and artistic renderings of human subjects reflect the continually evolving attempts to define the parameters of what it means to be human or "normal" within the context of societal structure in a given period of history. Both scientists and artists followed the practice of negative definition—in other words, defining humanity by what it is not. Any perceived physical or mental aberration that fell outside of accepted parameters was relegated to the category of "the other" or the "abnormal." In the most positive sense, such aberrations were thought to be fantastic or exotic. In the most negative sense, they were considered monstrosities, *terata* or freaks of nature. To the religious minded, physical or mental aberrations were thought to be a deity's punishment for immoral behavior, inappropriate thoughts or lack of faith. To those in positions of political power, they were sometimes perceived as a threat and at other times as mere curiosities enhancing a ruler's collection of valuable and exotic possessions.

Among the medical abnormalities that attracted the interest of both scientists and artists are the physical and mental manifestations of endocrine disease, the focus of a medical specialty not established until the twentieth century. Such observations led to extensive speculation, investigation and experimentation from the time of Aristotle

(384–322 BCE) and Galen (130–201 CE) to the present. The terms endocrine, endocrinology and hormone were not used, however, until the early twentieth century because the unusual nature of the ductless or endocrine glands made the concepts those terms represent difficult to identify or understand. An endocrine gland is defined as an organ that secretes a hormone that is carried via the blood stream to act at a distant site within the body. The term endocrine derives from the Greek adverb *endon*, meaning within, and the Greek verb *krino*, meaning to separate or sift, thus leading to our modern understanding of the remote functions of all endocrine glands. The term hormone was first used in 1905 by Ernest Henry Starling (1866–1927) and is derived from the Greek verb *hormao*, meaning to put into quick motion, excite or arouse.

Because of their inherent remoteness, the functions of most endocrine glands were misunderstood by scientists until the late nineteenth century when the etiology and physical manifestations of endocrine disease were gradually revealed through persistent experimentation and observation of changes following removal of specific endocrine glands. Accurate scientific observation of physiological functions as well as anatomy and pathology were especially important to the early discoveries that now enable endocrinologists and endocrine surgeons to make accurate diagnoses and provide effective treatment. Disorders such as hypothyroidism, hyperthyroidism, diabetes mellitus, adrenal hypo or hyper function—once

lethal medical conditions—can now be effectively treated.

Like artists, medical scientists depend on the discoveries enabled by a carefully trained eye. And like artists, medical scientists such as the sixteenth century Vesalius and Paracelsus have often risked criticism for challenging established practices. Among the most astute scientific observers of physical manifestations of endocrine abnormalities were the sixteenth century French surgeon Ambroise Paré, the eighteenth century British surgeon John Hunter and the nineteenth century Swiss surgeon Theodore Kocher. These surgeons learned about endocrine disease through observation, dissection and experimentation on animals and humans. As surgical scientists, they often challenged accepted medical practices in their quest for knowledge. They were unwilling to accept the dogma of their medical colleagues who were usually considered more scholarly because of their classical education in Latin and Greek and their foundation in ancient medical theories such as those of Galen.

Similarly, Renaissance and Baroque artists such as Piero della Francesca, Botticelli, da Vinci, Il Sodoma, Raphael, Caravaggio, Artemisia Gentileschi, Rubens, Ribera, Velasquez and Goya challenged the Renaissance value of beauty in symmetry and the idealization of the human figure. Some of their works illustrate the more obvious anatomical manifestations of endocrine disease undoubtedly rendered without the artists' understanding of the causes or subtle

consequences of the abnormality. The majority of these artists' paintings depict diffuse, nodular or greatly enlarged goiters, but there are also paintings of figures with signs of cretinism, the bulging eyes (exophthalmos) and other signs of Graves' disease, dwarfism, gigantism, sexual ambiguity, Addison's disease and other abnormalities. These works of art provide a record of endocrine disorders in a time when medical scientists knew little or nothing about such diseases. Despite a parallel trajectory in the disciplines of art and medicine toward an increasingly sophisticated understanding of the human body, for many years, artists proved to be more astute observers than their medical and surgical peers.

Much earlier than the work of these Renaissance and Baroque artists, ancient Egyptian, Greek and Roman sculptors and painters also represented endocrine abnormalities, sometimes in the form of votive figures, renderings of mythological characters or in realistic portraiture. Although some of their subjects were derived from fantasy, the artists often rendered the physical manifestations of endocrine disease with anatomical accuracy.

The great Italian anatomists and illustrators such as Andreas Vesalius (1514–64) and Fabricius ab Acquapendente (1537–1619) were as well known for the artistic nature of their anatomical illustrations as they were for their scientific accuracy. Doubt about the origin of some of Vesalius' illustrations, for example, raises "the question of who was more

important, artist or anatomist."<sup>4</sup> Some Renaissance artists actually arrived at their own theories about endocrine disease by observing human anatomy. Leonardo da Vinci was one of the first to illustrate the thyroid gland, and Michelangelo, who depicted both goiter and exophthalmos in some of the human figures in his paintings, proposed a theory about the etiology of goiter formation.<sup>5</sup> Although the conclusions of Michelangelo and da Vinci were scientifically inaccurate, their paintings as well as those of many other Renaissance artists include accurate illustrations of endocrine diseases.

The artists' reasons for including such illustrations of endocrine disease invite speculation. For example, we do not know whether artists such as Piero della Francesca, Botticelli, Artemisia Gentileschi, Caravaggio and others consciously chose models with goiters or used models who coincidentally happened to have goiters. Certainly the prevalence of endemic goiter in specific regions such as Piedmont, Tuscany and Umbria where Renaissance and Baroque artists were working may have provided models with goiters or the features of cretinism common to those areas. Because the manifestations of goiter were visible to the naked eye but the causes unknown, the artist's careful eye may have led him or her to make aesthetic classifications, associating smooth or diffuse goiters with the western notion of beauty in symmetry and the disfiguring goiters with ugliness in asymmetry. Moral as well as aesthetic

associations may have coupled severe disfigurement with negative character traits such as stupidity, deception or evil.

In the case of more dramatic and easily identifiable endocrine anomalies such as cretinism, dwarfism and gigantism, the artist's fascination with "the other" is especially apparent. Painters such as Paolo Veronese, Orazio Gentileschi, Jusepe Ribera and Diego Velasquez seem to have been as motivated by the contrast between the "normal" and the "abnormal" as they were by representing the human condition in myriad ways. Indeed, the more physically obvious the signs of endocrine disease, the more such artists seem to have been fascinated with extremes.

Among the many works of art we have examined for their depiction of endocrine abnormalities, the representation of goiter has figured most prominently. Disorders of the thyroid are noticeable because the thyroid gland is superficially located in the anterior lower neck whereas the other traditional endocrine glands are more deeply situated: for example, the pituitary in the head, the parathyroid in the deep neck, the adrenal glands in the retro-peritoneum. The fact that it is relatively easy to recognize the smooth, rounded goiter caused by thyroid enlargement, especially during adolescence or pregnancy in a young woman, may explain why so many Renaissance artists painted women with smooth diffuse goiters that artists and viewers probably considered a sign of beauty.<sup>6</sup> Similarly, artists may have observed

people with large disfiguring goiters when they were working in inland or mountainous regions where iodine deficiency caused endemic goiter, especially among peasants who may not have had the opportunity to travel to other regions where there was sufficient iodine in the soil and water.

History tells us that those persons with overtly large disfiguring goiters, especially those with accompanying mental abnormalities such as cretinism, were often ostracized from society, whereas giants and dwarfs, who had more obvious physical manifestations of pituitary or other endocrine gland dysfunction, were usually more severely marginalized and classified as sub-human, animalistic or monstrous. Exploited by those in power, they were frequently collected and displayed in the courts of Europe and sometimes exhibited at freak shows. We know that artists such as Veronese and Velasquez had some contact with the court dwarfs they represented in their paintings, but we know little about artists' access to actual giants. Although examples of mythological and biblical giants abound in Renaissance and Baroque paintings, most of the portraits suggest an imagined rather than actual abnormality caused by pituitary disease, in other words, a magnification of a "normal" human.

Representations in art of hirsutism (excessive body hair) and sexual ambiguity in males and females were often used to convey a didactic or satirical message to the viewer, frequently associating such aberrations with moral deficiency or freakery or both. In early Renaissance paintings, for example, the devil and his messengers are frequently represented as hirsute creatures. Other endocrine disorders such as adrenal disease (Cushing's syndrome, pheochromocytoma, Addison's disease) and hyperparathyroidism were only rarely captured by the painter's brush because the physical manifestations of these diseases are usually much more subtle than those of thyroid or pituitary disease. These diseases often resulted in a profound illness and premature death.

Apart from their evident powers of observation, whether artists attempted to paint realistically or actually exaggerated the details they may have observed in their models is a question for debate. In his painting of *The Transfiguration* (see **Figure 2-13**, p. 83 in **Chapter 2**), for example, Raphael faithfully represented so many signs of probable familial Graves' disease that we can only conclude he painted his subjects from life. It would be unlikely for Raphael to have imagined such a constellation of clinical manifestations often present in patients with Graves' disease, which can include the presence of goiter, exophthalmos, and gynecomastia. Similarly, some artists focused on physical abnormalities from which they themselves suffered. In his paintings that included self-portraiture Piero della Francesca repre-



sented himself with a thyroglossal duct cyst, and Michelangelo made a sketch of himself with a large goiter. Toulouse Lautrec included his own dwarfish figure in several drawings. Whatever the reasons for depicting such signs of endocrine abnormalities in their work, it remains certain that artists observed these signs in their subjects, sometimes well in advance of medical scientists who tended to rely on theoretical rather than empirical methods of diagnosis. As an interest in anatomical accuracy began to influence aesthetic choices, the faithful rendering of a multinodular goiter or an achondroplastic dwarf's enlarged head and short limbs became more common in European paintings. Sometimes, too, such abnormalities were useful to the artists of symbolic works in which an endocrine abnormality, often exaggerated, provides a metaphorical or symbolic statement that has little to do with literal representation.

Of particular interest in our research have been the social, moral, religious and aesthetic implications of the artists' choices. How did changing notions of beauty and ugliness affect an artist's representation of endocrine disease? Did artists assign moral values to some endocrine abnormalities, for example, associating smooth goiters with purity or fertility and disfiguring goiters with treachery or deception? Do the numerous examples of sensually appealing young female figures with diffuse goiters reflect an erotic association between the smooth diffuse goiter and other erogenous zones such as the breasts? To what extent did changes in fashion and

taste dictate artists' choices in representing endocrine disease in their paintings? Did the gradual acceptance of the artists' use of the working class and peasants as models for paintings allow for greater representation of endocrine diseases that may have been more common among these populations? Did religious tradition associate certain signs of endocrine disease with damnation and therefore influence an artist's rendering of those condemned to ignominy? Did artists consciously choose male models with gynecomastia and other ambiguous secondary sex characteristics to represent androgynous or asexual religious or mythological figures such as angels, Cupid, Adonis or Apollo? Were dwarfs and giants classified according to the extremity of their size? Did eighteenth century political caricaturists associate physical disfigurement such as that caused by some endocrine diseases with political corruption?

In our discussion of paintings we address these questions and others concerning the delicate balance between an artist's vision, the medical knowledge available to him or her and the extent to which a knowledge of historicism applies to the artist's work. We have examined the history of medical science within social and art historical contexts. Why, for example, were there so many centuries of medical "dark ages" in which religious beliefs and superstitions rather than scientific observation determined medical diagnosis and treatment? Why were medical scientists as late as the sixteenth century reluctant to advance beyond the theories of

medical anatomy and treatment of disease purported by Aristotle and Galen, avoiding the opportunity for evidence-based practices? Why was the church so influential in the decisions made by medical doctors? Why were medical theorists averse to testing their often brilliant theories with experimental procedures? To what extent were discoveries such as those of Paré and Hunter dependent on bold and risky experimentation that even defied the civil and criminal laws of the time? We know that little progress was made before the use of anatomical dissection of cadavers in the sixteenth century. Until the discovery of anesthesia and antisepsis in the mid nineteenth century surgical science was slow to advance because of the pain, suffering and often premature death associated with surgery, but what other obstacles continued to obfuscate scientific understanding of endocrine disease? How did seemingly primitive practices such as organotherapy that often bordered on charlatanism actually contribute to effective treatment of endocrine disease?

Finally, considering the powerful influence of each historical period's *gestalt* and the intellectual cross fertilization of the sciences and the humanities, to what extent are artistic vision and medical knowledge interdependent in the history of both disciplines? As an artist who often incorporated historical references in his paintings, Rembrandt must have perceived a transition concurrent with the scientific revolution in northern Europe in which "a shift in emphasis from speculation to experimentation" (Lyons and

Petrocelli 427) enabled Rembrandt and other seventeenth century artists to make use of the serious work of anatomists.<sup>7</sup> Rembrandt's famous painting of *The Anatomy Lesson* (The Hague, Netherlands, Maritshuis Museum) is an example of that "shift." In the painting the figure of Dr. Tulp the anatomist looks toward an unidentified viewer as he displays the dissection of a cadaver's arm for the students and physicians who have gathered around the dissecting table. Replace the clamp with a paintbrush, and the figure of the anatomist becomes that of an artist. Or imagine the anatomist as lead actor on the stage, the operating room his theater.

Paintings such as Rembrandt's reflect the historical importance of medical dissection or autopsy as a public spectacle. Similar to paintings of anatomical dissection, another popular category of seventeenth century art was the subject of the artist's studio. Such paintings often use a composition analogous to that of *The Anatomy Lesson* with the artist/teacher demonstrating technique for the students and artists gathered around him.

Despite these indications of scientific advances in the understanding of the human body for both physicians and artists, superstitions still influenced the classification of individuals with physical or mental disorders. In the various texts we have examined, the terms monstrosity, *terata* and freakery have figured in discussions of diseases that marginalize the afflicted in western society. As French literary scholar Marie-Hélène Huet reports in

her study of the female imagination and *terata* in western art, Aristotle defined monsters as "offspring" characterized by "their lack of resemblance to their parents."<sup>8</sup> Even liberated thinkers in the Renaissance such as Paré attributed the conception of a monster to the imagination of the mother. According to art historian Barry Wind, although the Roman Pliny and others of the ancient world embraced "the panoply of diversity, ranging from androgynes to umbrella-footed tribesmen, from bearded women to dwarfs," the victims of such anomalies were still accorded less than human status in the societies in which they lived.<sup>9</sup>

Thus, an artist's use of realistic anatomical detail provokes the viewer to question the artist's motive. For example, by placing peasant figures with disfiguring thyroid nodules in the foreground of paintings on religious subjects, was the Italian Baroque painter Caravaggio consciously mocking the church and its tendency toward elitism? Or was he attempting to humanize the image of the religious faithful to include a wide spectrum of social classes? Despite the advances made during the scientific revolution seventeenth century secular paintings and later works influenced by the Enlightenment continued to represent victims of endocrine disease by contrasting those victims to what was considered "normal."

Interest in the physical manifestations of endocrine disease appeared in the popular press of nineteenth century Britain. In 1820 the British writer

James Caulfield published a series of engravings and stories depicting felons and other remarkable characters provoking curiosity in the public. Among the *Remarkable Persons* to which the title of his four volume collection alludes are those he describes as follows:

Very different are the multitude who are noticed only as instances of the deviation of nature, such as giants, dwarfs, strong men, personal deformity, &c. In like manner are distinguished those persons who have lived to an extraordinary age; others, as empirics and quacks, buffoons, prize-fighters, and adventurers, serve but to fill up the class of *Remarkable Characters*; and if eccentricity of manners characterizes another description of persons, that very eccentricity entitles them to a place in the present work.<sup>10</sup>

Many of the engravings in Caulfield's volumes were executed by the famous British caricaturist Cruikshank, who also illustrated the novels of Charles Dickens. Although less salacious than the material of our modern tabloids, Caulfield's collection of *Remarkable Persons* calls attention to the same physical abnormalities that drew audiences to freak shows in the nineteenth and twentieth centuries. In our contemporary world, we also have myriad ways of defining, exoticizing or denigrating the "other" in our societies, implying what is "normal" by defining what it is not—obesity, physical deformity, and identification by certain economic, racial, ethnic, or social categories—to name a few.

Our book includes numerous examples of European physicians and artists who have contributed to an understanding of endocrine disease and the remarkable characteristics of the glands that function remotely. Even before endocrine diseases were given names, they puzzled and fascinated scientists and artists throughout time. The *Remarkables* are those individuals whose physical and sometimes mental manifestations of endocrine disease produce ambiguous responses, depending on the time and place in which they are regarded. They are remarkable for their adaptation to “normal” society as well as for the differences that separate them from the same society. Remarkable, too, is the intricate endocrine system that explains how, for example, the pituitary or “master” gland can produce thyroid stimulating hormone and other hormones that directly lead to the symptoms of thyroid disease or other endocrine diseases. However complex and remote the relationship between endocrine cause and effect may seem, the manifestations of endocrine disorders continue to be remarkable to physicians and most certainly to those who suffer from endocrine disease. In our view the painters who represented such diseases were remarkable for their scientifically accurate and precise observations of human anatomy and pathology. They were no less remarkable than the physicians who, also by accurate observation, trial and error, eventually learned the etiology and mechanisms responsible for endocrine disorders.



## Chapter 1

## The Goiter Beautiful: Purity, Sensuality, Fertility

### Introduction

In the history of European portrait and narrative paintings featuring female figures, a variety of aesthetic choices provides the viewer with a glimpse into the ways artists perceive their subject matter. During the early Renaissance in Italy, many artists began to use live models whose images were rendered in formal portraits. Others created female figures from their imaginations. Whatever the source of human images in painting and sculpture, traditional concepts of female beauty changed according to the time and region in which the artist worked.

A comparison of five female figures featured in works from ancient Rome to Victorian England reveals a changing perception of female beauty over a period of 1600 years. For example, a second century CE Roman pavement mosaic includes the domestic portrait of a woman with prominent eyes and youthful curls in a frontal pose common to mosaics from this period. What distinguishes this portrait from other Roman portraits executed in a similar style is the

#### Figure 1-17, facing page

Sandro Botticelli, *La Primavera* (1481–82, Florence, Uffizi Galleria) (see p. 37)

figure's full rounded neck, an important attribute of the subject's feminine identity. More demure and less direct than the subject of the Roman portrait, the figure of *St. Catherine of Alexandria* in Vittore Crivelli's portrait (1494) of the saint, suggests the idealization of youth and purity in a painting that also draws attention to the young saint's full rounded neck. With contrasting boldness, the full neck and voluptuous décolletage of Rubens's red haired Delilah in *Samson and Delilah* (1609) displays overt eroticism. More subtly sensual, Botticelli's Three Graces from *La Primavera* (1477–78) and the subject of Rossetti's portrait *A Daydream* (1878) also



**Figure 1-35**

Vittore Crivelli, *St Catherine of Alexandria* (1491, Oxford, Ashmolean Museum) (see p. 51)



reveal the full rounded necks of young, romanticized female figures.<sup>11</sup>

What do these women have in common as the subjects of paintings created within the larger context of Western European culture? On the surface, each painting attracts the viewer to its subject's beauty, grace, and youth. Some of the renderings of female figures reflect notions of female purity and religious piety. Others exude confidence and power, some a subtle sensuality disguised as romantic innocence. The artist's use of composition and color and attention to specific details of hair and clothing may reflect the culture of the time and place in which the artist worked. In the history of western civilization standards of female or male beauty are as capricious as modern fashion. Angular noses and high cheek bones; rounded, plump cheeks; round or almond-shaped eyes, thin or bold eyebrows; a dimpled chin—facial features that artists accentuate in pleasing combinations—change with the aesthetic preferences of time and region. One aspect of the figures' female beauty remains a constant in these paintings: the full rounded neck, an early indicator of an enlarged thyroid gland or diffuse goiter frequently found in females and generally not found in males.

---

**Figure 1-20**

Dante Gabriel Rossetti, *The Day Dream* (1880, London, Victoria and Albert Museum)  
(see p. 38)



**Figure 1-1**

Hans Holbein the Younger, *Adam and Eve*  
(1527, Basel, Switzerland, Kunstmuseum)

This prominent anatomical feature in paintings of women hides the sternocleidomastoid muscles and Adam's apple more visible in portraits of males. Hans Holbein the Younger's *Adam and Eve* (Figure 1-1, 1527, Basel, Switzerland, Kunstmuseum) is a good example of the difference between male and female anatomy of the neck. In the painting, the strong sternocleidomastoid muscles and prominent thyroid cartilage (or Adam's apple) of Adam's neck create a significant contrast with the smooth rounded neck of Eve. More unusual are those paintings in which the artist depicts a male figure's full rounded neck rather than the more typical angular and muscular features found in many portraits of men. In paintings with classical, religious or secular themes the full rounded neck imbues the subject of a portrait

or scene with an individual identity that transcends the legendary or historical figure she or he represents.

The prevalence of the full rounded neck in female images from a wide spectrum of paintings in both northern and southern Europe and throughout history leads one to question the artist's intention. Were Botticelli, Rubens, and the numerous other painters who draw attention to the full rounded neck aware of the underlying thyroid gland or other endocrine disorders that such an anatomical detail indicates? Most likely not.

The large number of Renaissance and Baroque paintings that portray women, and sometimes men, with diffuse goiters, however, suggests that artists did recognize and often accurately represent the physical

manifestations of thyroid disease. Practicality demanded efficiency and if the same model could be used for a variety of subjects, so much the better. Thus the same anatomical features in a particular model might have been repeated in numerous paintings. When several paintings in an artist's oeuvre feature the same model, the variety of poses enables the viewer to determine whether the figure's neck swelling is, in fact, an example of thyroid disease or just a fat neck. If a female figure in a painting is shown to have a physical condition such as diffuse goiter, indicating possible hypo- or hyperthyroidism, the viewer may question the artist's reasons for representing this anatomical feature.

Considering the absence of knowledge of the anatomy and function of endocrine glands in general and the

thyroid gland in particular until the late nineteenth century, it is unlikely that artists before 1900 were conscious of displaying a subject's goiter as such. Only a few Renaissance artists such as Leonardo da Vinci and Michelangelo revealed an awareness of the thyroid gland's anatomy in their sketches and drawings. The large number and variety of paintings in which goiters are visible, however, indicates that many artists observed their models' swollen necks and attempted to represent the neck's anomalies as an anatomical feature of the human form. In many paintings, the slightly enlarged thyroid gland appears to be a sign of beauty. It is also evident that the female figures in the paintings we discuss in this chapter appear to have diffuse rather than nodular goiters with palpable thyroid nodules manifested in noticeable neck masses. Both diffuse and enlarged multinodular goiters (caused by mostly benign but sometimes malignant thyroid nodules) are examples of thyroid disorders that were particularly common to specific inland or mountainous regions of iodine deficiency in Europe where Renaissance painting flourished: Italy, Spain, the Netherlands, Flanders, and Germany.

---

**Figure 1-5**

Leonardo da Vinci, *Madonna and Child* (1473, Munich, Alte Pinakothek) (see p. 26)





Did artists' models in these countries coincidentally have endemic goiters caused by iodine deficiency and thus have enlarged thyroid glands? The numerous paintings by Tuscan and Umbrian artists of women with goiters would suggest that many of the models had endemic goiter and artists were painting what they saw with a high degree of anatomical realism.<sup>12</sup> Or were the models chosen for their beauty, imagined or real, one feature of which was the fully rounded neck? Since not all painters working in the same region and time period feature the full rounded neck in their female figures, one questions whether this detail was emphasized consciously, whether the aesthetic standard varied from artist to artist, or whether the choice was made simply by chance. If an artist such as Botticelli or Caravaggio used the same model with a full rounded neck and this figure was also shown to be a beautiful woman, we might conclude that the artist, and subsequently the viewer, came to associate the full rounded neck with female beauty.

One also questions the artists' emphasis on the full rounded neck in male figures, mostly in religious paintings of angels and saints. Is the full rounded neck in both female and male figures associated with gentleness and holiness as well as beauty? If the neck's symbolism derives from multiple associations, to what extent is beauty defined as a quality of purity and innocence, martyrdom or sacrifice? If these qualities are included in the definition, how do we reconcile them with those paintings that empha-

size the sensual, even erotic, nature of the human figure with a full rounded neck? From many examples, especially those from the Baroque period and later, one might question whether a woman's full rounded neck was considered part of an erogenous zone that included the breasts.

#### Figure 1-4

Andrea del Verocchio and assistant (Lorenzo di Credi), *Virgin and Child with Two Angels* (1470–80, London, National Gallery) (see p. 26)



As late as the latter half of the nineteenth century through the early twentieth century, as realism gave way to a more abstract rendering of subject matter, artists continued to represent the full rounded neck in paintings of women. To the twenty-first century viewer this prominent anatomical feature may not be as aesthetically pleasing as it might have been in the fifteenth and sixteenth centuries. It is possible, however, to recognize patterns that link the appearance of a woman's small diffuse goiter with the aesthetic, cultural, social, and moral or religious values expressed in these works. In this chapter we will attempt to answer some of the questions provoked by the recognition of such patterns as we examine the history of thyroid disease and the rich array of examples from European paintings of women and men with evidence of diffuse goiters. In **Chapter 2**, we will examine the contrast between artists' representations of the full and often aesthetically pleasing rounded neck and those with more dramatically diffuse or nodular enlargement to which we refer as "goiter grotesque."

---

### History of thyroid disease and goiter, its etiology and epidemiology, the association of the full rounded neck with beauty, youth, fertility, and maternity

---

The normal thyroid gland is shield like or butterfly like in shape and is situated in the anterior neck with the isthmus or central connection positioned just caudal to the cricoid cartilage on the trachea. The gland normally weighs about 20 grams but is considerably larger in individuals from iodine deficient areas. An enlarged thyroid gland is a goiter, a term from the Latin *guttur*, meaning throat. Goiters may be diffuse and symmetrical, asymmetrical or nodular, and functioning or non functioning.<sup>13</sup> Goiters are classified by the World Health Organization (WHO) as palpable, visible, or both with the following staging criteria: Stage O-A: no goiter; Stage O-B: goiter detected only by palpation and not visible even when the neck is fully extended; Stage I: goiter palpable but visible only when the neck is fully extended; Stage II: goiter visible with the neck in normal position, palpation not needed for diagnosis; Stage III: very large goiter that can be recognized at a considerable distance.<sup>14</sup> Most goiters depicted in Renaissance and Baroque paintings would be classified as Stage II or diffuse goiters. In this chapter we have included examples of Stage I and II goiters, referred to here as "goiter beautiful." Examples of Stage III goiters, which we have termed "goiter grotesque," appear in **Chapter 2**.

Iodine deficiency is the most common cause of goiter worldwide. In 1958 the WHO reported approximately 7% of the world's population, or 200 million people, had goiters.<sup>15</sup> In areas of iodine deficiency or endemic goiter, up to 85% of persons have goiters.<sup>16</sup> Today in the United States, an iodine rich nation because of the presence of iodine in salt, the incidence of palpable goiter is about 4%.<sup>17</sup> In England, Tunbridge et al reported that in citizens from Wickham, County Durham goiters were present in 12.1% of women and 4.5% of men and that palpable nodules were found in 5.3% of women and in 0.8% of men.<sup>18</sup> About 6% of Scandinavian women over sixty years of age have thyroid nodules, whereas in West Germany, an iodine deficient country, the incidence of goiter is about 15% in young adults drafted for the military service.<sup>19</sup>

In iodine deficient areas, certain foods such as the cassava root, which contains the goitrogen thiocyanate, and millet increase the frequency of goiter development.<sup>20</sup> Certain vegetables of the Brassica family, such as turnips, kale, cabbage, mustard greens, and rutabaga contain glucosides, "which, after digestion, release [the goitrogens] thiocyanate and isoithiocyanate."<sup>21</sup> Millet, a popular food in the Sudan, is a flavonoid that has antithyroidal activity.<sup>22</sup>

Today in many iodine sufficient or iodine rich countries, however, chronic lymphocytic thyroiditis or autoimmune Hashimoto's thyroiditis is the most common cause of goiter. These goiters are usually small or Stage II

goiters, and about twenty percent of individuals with Hashimoto's thyroiditis develop hypothyroidism. In the Wickham survey, anti-thyroid peroxidase or microsomal antibodies, which document thyroiditis, were present in 10.3% of women and 2.7% of men; approximately one third of the women with positive antibodies had goiters (Tunbridge et al, 481). Autoimmune thyroiditis has been identified at autopsy or by antibody testing in about 15% of women in the United States and Japan.<sup>23</sup> Inborn errors of metabolism, resulting in abnormal thyroid hormone biosynthesis or dyshormonogenesis, are another cause of goiter formation. Exposure to low dose therapeutic radiation (6–2000 rads), especially in childhood, increases the risk of developing benign thyroid nodules, thyroiditis, and thyroid cancer.<sup>24</sup> Schneider et al have reported that nodular goiter develops in about 38% of individuals exposed to low dose therapeutic radiation and that about 11% have developed thyroid cancer.<sup>25</sup> After the disastrous nuclear accident near Chernobyl, Ukraine in 1986 there was a marked increase in thyroid cancer in children. Thyroid cancer is now the sixth most common cancer and the most rapidly increasing cancer in women.<sup>26</sup> It is also the second most common cancer in women under forty years of age.

Endemic goiters are characteristic of regions in which glaciation removed the natural iodine in the soil, leading to iodine deficiency in at least 10% of the inhabitants. Most endemic goiters begin as a diffuse swelling of

the thyroid gland, and some develop into large multinodular goiters, thus changing from “goiter beautiful” to “goiter grotesque.” In individuals consuming a normal iodine diet, urinary iodine excretion should be more than about 100 micrograms per gram of creatinine per day. In areas of severe iodine deficiency (excretion of less than 25 micrograms per day), goiter is often associated with clinical hypothyroidism and cretinism. In these same areas cretinism develops in about 10% of children with goiters. Myxedematous cretinism<sup>27</sup> is associated with mental retardation, growth retardation, delayed bone maturation, a large tongue, abnormalities in gait and thick skin.<sup>28</sup> Although most individuals with goiters are euthyroid with normal thyroid function, some are hypothyroid and others may be hyperthyroid with increased thyroid hormone levels.

When the thyroid gland enlarges or is a goiter, it is noticeable because of its relatively superficial position in the anterior neck. Although most commonly the thyroid gland can be diffusely or symmetrically enlarged, the enlarged thyroid can also contain one or more nodules. Diffuse or symmetrical enlargement, which occurs more often in younger people, is usually associated with benign or non-cancerous thyroid conditions and sometimes with increased or decreased thyroid function. Nodular thyroid glands are often indicative of multinodular goiter or of either benign or malignant thyroid tumors. Most patients with benign or malignant thyroid nodules, known as thyroid

neoplasms, are euthyroid or normal. In his *History of Endocrine Surgery*, British surgeon Richard Welbourn notes that prior to the nineteenth century goiters were often confused with other abnormalities in the neck such as enlarged lymph nodes, bronchial cleft cysts, neurofibromas, or tuberculous adenitis etc., and the term *bronchiocele*, meaning trachea, bronchus, and tumor in Greek, was used to describe these neck masses.<sup>29</sup> Other terms used to describe goiters were *struma*, from the Latin meaning swollen gland, *schilddrusen*, from the German meaning shield, and *oveos* from the Greek, also meaning shield.<sup>30</sup>

Goiters were observed 4000 years ago in China, Egypt, Greece, and other countries. Even though there are much earlier records of the observation of goiter, it was not until the eighteenth century in Europe that scientists discovered the association between iodine deficiency and the etiology of goiter. According to medical historian Victor Medvei in his *History of Endocrinology*, Julius Caesar (ca. 50 BCE) observed that one of the characteristics of the Gauls was a big neck.<sup>31</sup> Welbourn reports that goiters “were noted by non-medical Roman authors in the first three centuries CE (Common Era) in mountainous regions” and that both medical and non-medical writers continued to observe goiters in specific endemic regions (Welbourn 19–20).

There were numerous theories about the origin of goiter. For example, followers of the Greek physician Hippocrates (460–375 BCE) attributed

the cause of goiter to the drinking of melted snow (Medvei 45). The Roman Caius Plinius Secundus (23–79 CE), known as Pliny the Elder, recorded epidemics of goiter in the Italian Alps and attributed goiter to the impurities in the water, stating that “Only men and swine are subject to swellings in the throat, which are mostly caused by the noxious quality of the water they drink” (Medvei 59). In the seventh century CE, the Greek Paul of Aegina wrote about an aneurysmatic bronchiocele. In the eleventh century Abul Kasim (Albucacis) of Cordoba, Spain referred to an incurable “elephant of the throat” most frequently observed in women (Welbourn 20). In 1271 the Italian explorer Marco Polo also noted that goiters were common in people from the mountainous regions of Turkestan (Welbourn 20). Renaissance painter Michelangelo (1476–1564) apparently attributed his own goiter to the drinking of toxic substances in the water of the Apennine Mountains in Italy. Welbourn notes that Michelangelo’s goiter bothered him when he extended his neck while he was painting the ceiling of the Sistine Chapel (Welbourn 20). Medical historian Alfred Iason quotes an excerpt from a sonnet by Michelangelo, supposedly written while he was painting the ceiling: “I’ve grown a goiter by dwelling in this den/As cats from stagnant streams in Lombardy/Or in what other land they hap to be.”<sup>32</sup> In a recent exhibit of Michelangelo’s drawings in Rome we saw the original poem written on a piece of paper next to a line sketch of a man’s body with a prominent goitrous swelling on the neck.

Because the origins of thyroid disease were misunderstood and religious beliefs interfered with scientific diagnosis of disease in general, effective treatment of thyroid disease was slow to develop. Medvei states that during “the period of European Monastic Medicine from the 5th to the 10th century AD (CE) ... zeal for preserving the remains of ancient literature and the traditions of ancient and rational practice” was combined “with the newly developed cult of healing power of the Saints and Holy Relics” (Medvei 90). Medieval Christians took their ideas from the Hebrews, who had taken many of “their beliefs from ancient Mesopotamian cultures, among them the conviction that disease was a form of divine punishment and therefore a mark of sin.”<sup>33</sup> Medvei also notes that to the medieval mind, “[s]upernatural powers were responsible for the great epidemics and heavenly aid was necessary to obtain relief from them” (Medvei 90). Most diseases were “largely regarded as a divine visitation,” illustrated by a legend, which “according to Hubert (Life of St. Gudula) that the Bishop of Emebert (seventh century) hurled an anathema at the wicked persons who despoiled the tomb of that saint, the curse being that their offspring should be cripples (claudicati) and the women goitrous” (Iason 30). Although such theories may seem ridiculous in the twenty-first century, they are not too dissimilar to the proclamations in our own time of certain religious fundamentalists who even now consider sexually transmitted diseases such as AIDS and other illnesses as the consequences of sin.

Since the function of the thyroid and its anatomical details were unknown or misunderstood until the late nineteenth century, goiters were often mistakenly thought to belong to other neck masses. According to Iason, Hippocrates (460–377 BCE) referred to the “flesh of glands” as “different from that of the rest of the body, being spongy and full of veins; they are found in the moist parts of the body where they receive humidity ... the brain is a gland as well as the mammae” (Iason 15). Iason also notes that the Roman Aulus Cornelius Celsus (25 BCE–50 CE) was one of the first to distinguish differences among various forms of tumors of the neck (Iason 24).

Galen (130–200 CE) possibly described the normal thyroid gland, but it was not until the Renaissance that its identity was generally recognized, and the failure to differentiate goiter from reactive lymph nodes caused by carious or abscessed teeth, scrofula or other neck masses also continued until that time. Today we know that although most benign and malignant thyroid tumors occur sporadically, there are patients with familial benign goiter, familial autoimmune thyroid diseases such as Graves’ disease and Hashimoto’s thyroiditis, and familial thyroid cancer.<sup>34</sup>

The sixteenth century saw more advances in the understanding of the thyroid’s anatomy and symptoms of thyroid disease. Swiss physician Paracelsus (1493–1541) taught the importance of the unity of medicine and surgery and rejected the ideas

of Galen and his theory of the four humours.<sup>35</sup> A pioneer of chemistry and pharmacology and the founder of toxicology, like some before him, Paracelsus attributed the presence of “goiter to the impurities in drinking water, especially sulfides of iron (marchasita), and also postulated a hereditary element in it. He was the first to realize the connection between cretinism, endemic goitre, and congenital idiocy,” stating that “While goitre is not a characteristic of idiots yet it is most commonly found among them” (Medvei 98).

It is to artists, however, that we can attribute a broader dissemination of knowledge concerning the anatomy of the thyroid gland. During the Italian Renaissance artists demonstrated a serious interest in human anatomy that led to investigative drawings of organs and glands. The most well known of artists who demonstrated a profound interest in and knowledge of science was Leonardo da Vinci (1452–1519). “In about 1500 Leonardo da Vinci drew the thyroid as a globular, bilobate structure, which he regarded as two glands, filling up empty spaces in the neck that separated the trachea from the clavicle, but his drawings were unknown for three centuries” (Medvei 102). Da Vinci most likely used the thyroid gland of a dog for his model because, in contrast to humans, dogs do not have an isthmus in their thyroid glands. We can see a direct application of da Vinci’s mostly accurate but limited knowledge in a few of his drawings and paintings (Medvei 102).<sup>36</sup>

Da Vinci’s drawings continue to inspire contemporary artists and scientists who value the marriage of art and science that came about in the Renaissance and eventually led to a regard for anatomical drawings. One of those artist/scientists was Andreas Vesalius (1514–64), a Flemish professor of surgery and anatomy at the University of Padua, Italy. Vesalius’ illustrations were “a collaboration between artist and anatomist” exemplifying the strong links between art and science and evincing a “degree of artistic sophistication” considered “new even to artists in the Renaissance” (Lyons and Petrocelli 416). In 1543 Vesalius illustrated the thyroid gland in his book *De Humani Corporis Fabrica*. He stated that there were

[t]wo glands, one on each side of the root of the larynx, and these large and somewhat fungus and almost the color of flesh, but rather darker, with prominent veins.... These glands be at the root of the trachea, since they moisten its orifice with a humor not indeed fluid, but rather viscous and thick, for the glands themselves are thicker and denser than the rest of the gland which secrete a humor (Iason 37).

There has been considerable speculation about whether “the degree of artistic sophistication and the knowledge of techniques new even to artists in the Renaissance were too great for Vesalius to have been the sole person responsible” (Lyons and Petrocelli 416). Current research suggests that Stephan van Calcar (1499–1546/50), a former student of Titian, may have

contributed many of the drawings based on Vesalius’ dissections even though neither he nor any other artist was acknowledged by Vesalius in *De Fabrica* (Lyons and Petrocelli 416). Nonetheless, we can credit Vesalius’ writings and illustrations for revolutionizing not only human anatomy but also scientific teachings in the Renaissance. Although he remained a follower of Galen, he identified numerous errors in Galen’s discoveries, including the limitations of “Galen’s texts ... based on dog and monkey anatomy.”<sup>37</sup>

Working during the same period as Vesalius, the Roman Bartolomeus Eustachius (also known as Bartolommeo Eustachio, 1520–74), “who also discovered the adrenals,” more accurately described the thyroid as “a single ‘glandulam thyroideam’ (L = shield-shaped) with an isthmus connecting its lobes, but his work was not published until the eighteenth century” (Welbourn 20). Eustachius was the first to use “the term ‘isthmus’ for the part connecting the two lobes” (Medvei 109). A short time after Eustachius, Julius Casserius (Padua, 1545–1616) reported that the thyroid gland was “shaped like a horseshoe, and regarded it as a lubricating and space-filling organ, which also made the neck pleasing to the eye” (Welbourn 20). Fabricius ab Aquapendente (Padua, Italy, 1537–1619) was the first to localize the thyroid gland definitively as the anatomical seat of goiter (Iason 33).

Like Vesalius, Casserius, and Fabricius ab Aquapendente, British physician Thomas Wharton (1614–73) thought that the function of the thyroid was to lubricate the larynx. Perhaps because of the prevalence of diffuse goiters in pubescent and pregnant women, Wharton associated the diffuse goiter with female attractiveness. In his *Adenographia: Sive Glandularum Totius Corporis Descriptio* (1656) about the thyroid and other glands Wharton attempts to explain the purpose of the thyroid gland. According to Medvei, Wharton “did not clearly separate the thyroid gland from the submaxillary glands, but gave it its modern name, based on a wrong deduction. He chose ... (thyreos) = oblong shield, because it ‘contributes much to the rotundity and the beauty of the neck, filling up the vacant spaces around the larynx ... making its protuberant parts almost to subside and become smooth, particularly in females, to whom for this reason a larger gland has been assigned, which renders their necks more even and beautiful’” (Medvei 131). Although he accurately identified the form of the thyroid gland, Wharton misunderstood the function.

Wharton’s ideas were partly correct, however. Since the seventeenth century medical scientists have observed and documented that in both man and animals the thyroid attains its relative maximum size just prior to the onset of puberty (Means 2). Women have proportionately larger thyroid glands than men, and “thyroid nodules appear more frequently in multiparous women.”<sup>38</sup> Sir William Osler

noted that at the time of “puberty, in girls, often at the onset of menstruation, the gland enlarges;” and in some women, especially in areas of iodine deficiency, “the neck becomes fuller at each menstruation.”<sup>39</sup> During pregnancy the thyroid gland may become goitrous and rarely “a bruit, reflecting the increased blood flow, may be present.”<sup>40</sup> This temporary change may explain why the Roman Catullus (30 BCE–50 CE) referred to the woman’s “honeymoon” enlargement of the neck.<sup>41</sup> The ancient Romans often placed a thread around the neck of young women to determine whether they had lost their virginity and/or were pregnant (Medvei 57). The Greek Soranos of Ephesus (98–138 CE) also noted swelling of the neck after pregnancy during the period of lactation (Medvei 57–58).

These theories continued to dominate explanations for the full and rounded neck until “thyroid deficiency was recognized” in the nineteenth century (Welbourn 21). Subsequent remedies were followed to treat disfiguring goiters or “goiter grotesque” (see **Chapter 2**), but in much earlier times the full and rounded neck was apparently regarded by artists as well as scientists as a sign of beauty. It was this characteristic above all others that probably inspired so many pictorial representations of the diffuse goiter.



**Figure 1-30**

Jan Steen, *The Doctor and the Patient* (1670, Prague, National Gallery) (see p. 44)



**Figure 1-2**

Paolo Veneziano, *The Doge Dandolo and the Dogaressa Being Presented to the Virgin* (1339, Venice, Frari Church)



---

### The Goiter Beautiful in art

---

Wharton's accurate observation that women have larger thyroid glands than men and his theory, echoing that of Casserius, that the enlarged thyroid "renders their necks more even and beautiful" is especially applicable to portraits of the Virgin Mary in the late Middle Ages and throughout the Renaissance in Europe. The tradition of painting portraits of the Virgin Mary as "objects of veneration" originated in the early Byzantine period.<sup>42</sup> According to art historians H. W. and Anthony Janson, the accepted Christian belief of the time included "the claim that Christ had appeared with the Virgin to St. Luke and permitted him to paint their portrait, and that other portraits of Christ or of the Virgin had miraculously appeared on earth by divine fiat," thus becoming "the source for the later, man-made" portraits (Janson 256). Early Byzantine portraits of the Virgin draw the viewer primarily to the face and neck, which is often delineated by a prominent horizontal line at its base as if the head and neck were painted separately and attached to a paper cutout body covered in drapery. Such delineation of the neck with a slight swelling above the "Venus line" (a curved crease or natural skin line) is also apparent in Roman mosaics and in Roman paintings on Egyptian mummy covers, medieval paintings, and Byzantine mosaics and frescoes. For example, in the large Byzantine mosaic of *The Last Judgement* in the Cathedral of Santa Maria Assunta on the island of Torcello (13th century,

Torcello, Venice, Cathedral of Santa Maria Assunta), the necks of almost all of the figures, both male and female, have prominent Venus lines. The uniformity of detail, which is similar to the stylization used in many medieval frescoes and mosaics, would suggest that the artist is following stylistic convention rather than accentuating an anatomical anomaly.

By the fourteenth century in Italy, however, early Renaissance paintings of the Virgin Mary began to deviate from such consistent stylization even though some of the features of Byzantine iconography lingered. Frescoes painted in Tuscany, Umbria, and the Veneto depict the Virgin Mary with a more individualized expression and a more graceful flow between the head and the body, so that the neck no longer seems attached with its characteristic bulge but rather appears to grow out of the Virgin's body as if she is all of one piece. The Venetian fourteenth century painter Paolo Veneziano's portrait of the Virgin Mary in *The Doge Dandolo and the Dogressa Being Presented to the Virgin* (Figure 1-2, 1339, Venice, Frari Church) deviates from the Byzantine style in its portrayal of the Virgin's facial expression. Although the Virgin's head and shoulders are leaning to the left, as is the convention in Byzantine icons, she appears to be looking toward the viewer with more emotion than is revealed in most Byzantine portraits. The slightly lifted chin reveals a swelling and Venus lines in her neck. Despite his use of the draped cowl from Byzantine tradition, Veneziano's portrait and those by Giotto, Duccio,

di Segna, Martini, and Piero della Francesca replace the stylized neck and Venus line with a more realistic swelling that suggests the presence of a diffuse goiter.<sup>43</sup>

In two Italian Renaissance paintings that represent the Virgin Mary in the traditional pose as mother of the church, the artists portray Mary with a small diffuse goiter. Sieneese painter Niccolò di Segna's *Madonna of the Misericordia* (1331–32, Siena, National Picture Gallery) features the Virgin in a frontal pose, directly facing the viewer. The viewer is drawn to the pronounced swelling in the Madonna's lower central neck that, with her head, bisects the portrait at the apex of a triangle created by her robe and the triangular top of the painting. Symmetrically placed on both sides within the folds of the robe is a gathering of pilgrims, most of them in ecclesiastical garb, whose diminutive size in contrast to the Virgin's emphasizes her strength, concern, and sympathy. Like di Segna's Virgin, Piero della Francesca's *Madonna of the Misericordia* (**Figure 1-3**, 1445, Sansepolcro, Tuscany, Museo Civico) also appears to have a diffuse goiter. It is difficult, however, to determine whether the figure's diffuse goiter also has nodules in the lower portion of the right and left lobes of the thyroid. What appear to be nodules could be the artist's representation of the sternocleidomastoid muscles stretched over a diffuse goiter. In both works on the subject of the older, maternal Madonna the moderately goitrous swelling in the center of the painting

seems to be a positive attribute of the figure's strength. As in Veneziano's painting, the Virgin's physical strength symbolizes her maternal role in the church.<sup>44</sup>

**Figure 1-3**

Piero della Francesca, *Madonna of the Misericordia* (1445, Sansepolcro, Tuscany, Museo Civico)



Less bold but with equal emphasis on the Virgin's maternal expression are several fifteenth and early sixteenth century portraits in which a young Virgin Mary is often shown with the Christ Child and other holy figures. Typically, the mother figure is shown with eyes downcast as she contemplates her child. In Andrea del Verocchio's *Virgin and Child with Two Angels* (Figure 1-4, 1470–80, London, National Gallery, see p. 15) the low neckline of the Virgin's robe reveals a swollen neck with diffuse goiter. The triangular composition of the painting with the head and neck at the apex of the triangle accentuates the fullness of the figure's neck. In contrast to the Virgin in the *Misericordia* paintings, del Verocchio's Virgin does not look directly at the viewer and is portrayed in a state of maternal but youthful contemplation.<sup>45</sup>

A similar expression of maternal concentration appears in Leonardo da Vinci's *Madonna and Child* (Figure 1-5, 1473, Munich, Alte Pinakothek, see p. 14) and in Andrea Mantegna's *The Virgin and Sleeping Child* (Figure 1-6, 1465–70, Berlin, Gemaldegalerie). In both paintings the artists have portrayed the Virgin with a full rounded neck signifying a diffuse goiter. Da Vinci's figure of the Virgin, however, reveals a slight asymmetry with a more prominent swelling in the right neck. His use of the *sfumato* technique<sup>46</sup> also more finely nuances the subtleties of the model's neck than is apparent in other paintings of the Virgin.



**Figure 1-6**

Andrea Mantegna, *The Virgin and Sleeping Child* (1465–70, Berlin, Gemaldegalerie)

Although artists such as da Vinci incorrectly thought of the thyroid gland as two separate lobes,<sup>47</sup> the shape of the gland in his painting of the Virgin is clearly one in which the two lobes are connected by a central isthmus. The contrast between theory and practice suggests that he painted the model for the Virgin the way he saw her and thus accurately illustrates the anatomical description made by Eustachius later in the 16th century.<sup>48</sup> Mantegna's Virgin also has a noticeably shield-like swelling accentuated by the turning of her face "so that it brings a diagonal into the composition."<sup>49</sup> The enlarged thyroid gland is partly in shadow, the contrast in lighting further emphasizing the perfectly symmetrical growth in the neck that mimics the volume and protrusion of the figure's chin. Like that of da Vinci's Virgin, the feminine innocence of Mantegna's Virgin is highlighted by her delicate curls and soft downward glance. Her serious expression of contemplativeness and the strength apparent in her neck mass, however, belie the youthfulness suggested by the simple dress and the monochromatic pattern of headdress and bodice.

Da Vinci's and Mantegna's Virgin figures appear to be young women whose maternity may have followed quickly on the heels of pubescence, that period in which the thyroid is proportionately larger in comparison to the rest of the body. The existence of the full rounded neck in the two portraits thus seems closely associated with both fertility and young maternity.

The importance of fertility and maternity in images of the Virgin Mary is

especially noticeable in paintings of the *Annunciation* that depict the Virgin before childbirth. Characteristically, the painter places the Virgin in a modest, almost deferential, pose, head lowered and body leaning toward the Angel Gabriel, eyes downcast and arms crossed in modesty or held out as if in self-defense. Melozzo da Forlì's *Annunciazione* (Figure 1-7, Rome, The Pantheon) portrays the Virgin directly

opposite the Angel Gabriel, creating symmetry in the composition that gives equal weight to both figures.

**Figure 1-7**

Melozzo da Forlì, *Annunciazione* (Rome, The Pantheon)





**Figure 1-8**

Botticelli, *Annunciation* (1489–90, Florence, Uffizi Gallery)

The Virgin figure's diffuse goiter is noticeable in its contrast to the angel's thicker, more muscular neck. Both Botticelli's *Annunciation* (**Figure 1-8**, 1489–90, Florence, Uffizi Gallery) and Fra Filippo Lippi's *Annunciation* (**Figure 1-9**, 1440's, Rome, National Museum of Antique Art, Palazzo Barberini) show the Virgin in a more

humble pose. In both, the slight turning of the neck to the Virgin's left draws attention to its goitrous swelling and distracts the viewer's gaze from the figure of the Angel Gabriel, shifting the focal point along the right diagonal to the Virgin. Both Virgins also have prominent eyes (exophthalmos), suggesting that the goiter



could be related to Graves' disease, that is, autoimmune thyroid disease.<sup>50</sup> Botticelli's *Annunciation* in particular, uses the swollen neck as the most prominent feature of the Virgin's figure, as if the neck mass provides physical balance for the graceful dance-like pose of the

**Figure 1-9**

Fra Filippo Lippi, *Annunciation* (1440's, Rome, National Museum of Antique Art, Palazzo Barberini)





young woman who has just received such startling news from the angel. The model for this painting appears to be the same as that for Botticelli's *Madonna with the Book* (ca 1485, Milan, Poldi Pezzoli) in which a three-quarter pose places a similar emphasis on the swollen neck.<sup>51</sup> In contrast to Botticelli's painting on the same subject, Lippi's *Annunciation* shows a more pensive, youthful figure whose full neck reflects her imminent womanhood and strength.

An unusual sixteenth century portrait of the Virgin, Parmigianino's *Madonna with the Long Neck* (Figure 1-10, 1534-40, Florence, Uffizi Gallery) calls attention to the female neck in more Mannerist terms with exaggerated contours, sensual color tones and dramatic gestures.<sup>52</sup> The neck of Parmigianino's Virgin is, at most, indicative of a Stage I or II goiter, but its rotundity seems pronounced in contrast to the figure's slenderness, also emphasized by her long thin fingers. Her snake-like curls and the neck's serpentine or swan-like length and curve, echoed in the contours of the ribbon on her dress, accentuate the neck's Venus lines, suggesting the Virgin's sensual attractiveness and, recalling Botticelli's Virgin in the *Annunciation*, the grace of a dancer.<sup>53</sup>

---


#### Figure 1-10

Parmigianino (Girolamo Francesco Maria Mazzola, also known as Francesco Mazzola), *Madonna with the Long Neck* (1534-40, Florence, Uffizi Gallery)

Almost sixty years later, beauty, modesty and a dancer's grace are reflected in much earthier tones in Caravaggio's Baroque painting of the *Madonna of the Pilgrims* (Figure 1-11, 1603-4, Rome, Church of San Agostino), also known as the *Madonna of Loreto*. Here the Virgin's left-leaning head and her neck with its diffuse goiter form the top of an arc completed by her arm and that of the Christ child she holds. The painting's *chiarascuro*<sup>54</sup> lighting and circular motion further accentuate her beautiful full neck. The sensuality of Mary in Caravaggio's *Madonna of the Pilgrims* is also noticeable in his painting of the *Madonna of the Palafrenieri* (Figure 1-12, 1605-6, Rome, Galleria Borghese) for which the artist probably used the same model.<sup>55</sup> In this painting the Madonna's diffuse goiter is equally visible, and the sensuality of her neck is heightened by her revealing pose. According to art historian Catherine Puglisi, the pose may have caused "the cardinals of the Fabbrica di San Pietro" to reject the painting as inappropriate for the church because of its "indecenty."<sup>56</sup> As Puglisi notes, the problem resides in "Mary's attire: instead of her customary matronly veil, mantle, and robes, she wears contemporary dress of a simple design and fabric, with skirt hitched up for the work at hand, and her stooping pose reveals rather too much breast" (Puglisi 195). The dramatic *chiarascuro* lighting of the Madonna's neck and breasts further suggests an association between neck and breasts in one erogenous zone. The Madonna of the Palafrenieri's Mary stands with her

foot on a gleaming serpent, which, according to Puglisi, alludes to a "mistranslation from the Hebrew" of Genesis 3 in the Vulgate Bible in which "God would send a second Eve to redeem the original sin of the first" (Puglisi 192). The pose therefore invites the observer to speculate about Caravaggio's intentions and the sexual as well as religious ambiguity of his earthy Virgin.

Unlike the Parmigianino Virgin, Caravaggio's Madonnas are less elegantly clothed and more self-effacing in their downward gaze. The humble pose of the Virgin in *The Madonna of the Pilgrims* is in keeping with the presence of the humble pilgrims in the right foreground of the painting. Similarly, the modest dress of St. Anne in the *Madonna of the Palafrenieri* emphasizes the domestic simplicity of the scene. Despite differences in clothing and the contrast between Parmigianino's use of a more formal pose and background and Caravaggio's more natural poses and settings, the Virgins in the three paintings share a sensuality less subtle than that in *quattrocento* (fifteenth century) paintings of the Virgin. It is probable that Caravaggio and Parmigianino have boldly incorporated into their portraits of the Virgin the female neck's function as an erogenous zone, made all the more noticeable by its sensual curve and swelling.





**Figure 1-11, facing page**

Caravaggio, *Madonna of the Pilgrims*, also known as the *Madonna of Loreto* (1603-4, Rome, Church of San Agostino)

**Figure 1-12**

Caravaggio, *Madonna of the Palafrenieri* (1605-6, Rome, Galleria Borghese)



**Figure 1-13**

Mariotto Albertinelli, *The Creation and Fall of Man* (1513–14, London, Courtauld Gallery)

If Mannerist and Baroque paintings of the Virgin Mary with a full rounded neck draw attention to the sensual beauty of their models, numerous works featuring biblical and classical themes go a step further in suggesting the erotic and seductive powers of a woman with a diffuse goiter. An obvious example of the connection between goiter and seduction appears in Mariotto Albertinelli's *The Creation and Fall of Man* (Figure 1-13, 1513–14, London, Courtauld Gallery). In the right half of this narrative painting, a seated, naked Adam accepts the fruit from Eve, who grasps a branch of the tree, thus encircling the human head and neck of the serpent spiraled around the tree's trunk. A prominent goiter on the serpent's neck appears in the V-shaped space between Eve's head and arm. Eve's gaze is focused on Adam, but the serpent's gaze is directed above the compliant Adam, perhaps to hint at the consequences of seduction depicted in the continuing

narrative. Most likely, the artist intended to portray the serpent of Genesis 3 as a female, a common practice in the Renaissance. The serpent's gender is less obvious, however, than the association it suggests between goiter and sexuality, similar to Catullus's association of goiter with puberty and pregnancy 1600 years earlier. The phallic imagery of the snake's body coiled around the tree, the juxtaposition of Eve's head and that of the serpent, and the serpent's prominent goiter all convey the artist's emphasis on the sexual potency of the scene.

Sexual potency is evident in sixteenth and seventeenth century works featuring biblical and mythological themes. A diffuse goiter accentuates the sensual curve of Delilah's neck in Rubens's *Samson and Delilah* (Figure 1-14, 1609/10, London, National Gallery). In this painting of a well-known Old Testament story, the pale-fleshed Delilah is shown half-seated, half supine on a bed draped with sumptuous fabrics and rugs, her red gown providing an ample lap for Samson's head while "she made

him sleep upon her knees; and she called for a man, and she caused him to shave off the seven locks of his head; and she began to afflict him, and his strength went from him" (Judges 16:19). The role of the seductress in Rubens's painting is further adumbrated by the presence of an old woman in the background, who, along with the extravagantly decorated room, is evidence of the "brothel" setting.<sup>57</sup> Delilah's full neck, which appears to have an asymmetrical thyroid nodule on the right, adds to the voluptuousness of her "bulbous breasts" (Belkin 155), clearly connecting the fleshy goiter with the painting's atmosphere of eroticism. This atmosphere is further suggested by the display of Samson's muscular virility in the painting's foreground. The hero's image of strength is eclipsed, however, by the artist's powerful portrayal of the beautiful and sensual seductress, who has been exhorted by the lords of the Philistines to "entice him, and see wherein his great strength lieth, and by what means we may prevail against him, that we may bind him to afflict him" (Judges 16:5).



**Figure 1-14**

Rubens, *Samson and Delilah* (1609/10, London, National Gallery)

The association of sexual prowess and the full rounded neck with a diffuse goiter is apparent in Italian Renaissance paintings that feature female mythological figures. Dosso Dossi's *Maga Circe o Melissa* (**Figure 1-15**, ca. 1518, Rome, Galleria Borghese) portrays the Greek mythological enchantress Circe with a full rounded neck and bold frontal pose,

enhanced by the juxtaposition of Circe and the lion, representing Circe's power to tame and command. The painting's use of sensual detail links sorcery and eroticism with the prominent focal point of the woman's diffuse goiter.<sup>58</sup> Giacinto Campana's *The Rape of Helen* (**Figure 1-16**, 1631, Rome, Galleria Spada) shows a more modest female figure than



**Figure 1-15**

Dosso Dossi, *Maga Circe o Melissa* (ca. 1518,  
Rome, Galleria Borghese)



**Figure 1-16**

Giacinto Campana, *The Rape of Helen* (1631, Rome, Galleria Spada)

Dossi's Circe or Rubens's Delilah. Helen's gaze is cast toward some unknown horizon as Paris leads her to Troy. Her three-quarter pose draws attention to her weak chin and a prominent diffuse goiter, the neck and head leaning toward an indifferent Paris whose military garb portends the war that will follow. This is a sensual but seemingly obedient Helen whose full rounded neck reminds us of her youth and vulnerability as the abducted wife of Menelaus. Despite the violence suggested in the title, she is portrayed as submissive rather than rebellious.<sup>59</sup>

The paradox of female modesty and eroticism is apparent in many artists' representations of The Three Graces, Greek goddesses who, as their name indicates, were associated with female grace and most often represented in the act of dance. Both Botticelli's rendering of The Three Graces in *La Primavera* (Figure 1-17, 1481–82, Florence, Uffizi Galleria, see p. 10) and Rubens's painting of *The Three Graces* (Figure 1-18, mid-1630's, Madrid, Museo del Prado) feature women whose diffuse goiters accent the sensuality of their dancers' poses, flowing hair, and partial nudity. The blond figure on the left of Rubens's painting exposes a full rounded neck whereas the presence of goiter is partially obscured in the other two women.<sup>60</sup> All of Botticelli's Three Graces are endowed with diffuse goiters, but the most pronounced is in the figure on the left. Again, the full rounded neck is a prominent feature that suggests an association with feminine sexuality.



**Figure 1-18**

Rubens, *The Three Graces* (mid-1630's, Madrid, Museo del Prado)

It is not surprising that in their attempt to emulate the early Italian Renaissance painters who preceded Raphael and “to paint their pictures with a complete fidelity to nature,”<sup>61</sup> the English pre-Raphaelite painters of the nineteenth century revived the Renaissance association of the full rounded neck with female beauty and sensuality. This association is most noticeable in works from the 1860's and later during the period of English painting known as the Aesthetic

Movement. Painters like Dante Gabriel Rossetti and Edward Burne-Jones eschewed the idealism and formality of their eighteenth century predecessors, practicing “a deliberately romantic, introspective art, the aim of which, if it has one at all, is to awaken our sense of beauty” (Wood 119). Rossetti's *Monna Vanna* (Figure 1-19, 1866, London, Tate Gallery), *The Bower Meadow* and *Veronica Veronese* all use the model Alexa Wilding whose swan like neck has a moderate sized diffuse goiter. Perhaps best known among Rossetti's female models was Jane Morris, the wife of his friend and colleague William Morris and a well known figure in the pre-Raphaelite





**Figure 1-19**

Dante Gabriel Rossetti, *Monna Vanna* (1866, London, Tate Gallery)

Equally alluring yet submissive but even more overtly sensual than the women in the Pre-Raphaelite paintings is the female figure in a painting by the French artist Jean August Dominique Ingres, *Angelica Saved by Ruggiero* (**Figure 1-21**, 1819, London, National Gallery) in which a helpless naked maiden looks upward for aid while her rescuer Roger arrives on an eagle headed winged creature to slay the dragon about to devour her. A huge goiter that resembles a third breast obstructs her neck and calls

**Figure 1-21**

Jean August Dominique Ingres, *Angelica Saved by Ruggiero* (1819, London, National Gallery)

circle of artists and poets; she eventually became Rossetti's lover and was known as "the femme fatale of his life as well as his art" (Wood 98). Morris was the model for *The Day Dream* (**Figure 1-20**, 1880, London, Victoria and Albert Museum, see p. 12) as well as *Astarte Syriaca*, among other works. A photograph of Morris taken by Rossetti suggests that the artist was painting the model's neck exactly as he saw it through the camera's lens. Rossetti's prominent exposure of Wilding's and Morris's diffuse goiters is gracefully integrated with familiar romantic references to sensuality conveyed by abundant hair, complementary color tones, luxurious drapery and, in *The Daydream*, a background of voluptuous nature in full bloom. Rossetti's numerous paintings of these and other models with long broad necks imbued with sensuous flesh tones and his signature focus on the smooth diffuse goiter undoubtedly reveal his fascination with the female neck as an erogenous zone.



attention to her innate sensuality and the underlying eroticism of the painting. The painting also illustrates the idea of the full rounded neck and the breasts as one erogenous zone, a notion that first appeared in Renaissance paintings.

As we have noted in several examples, paintings by Renaissance artists and their nineteenth century counterparts of classical, biblical, and secular female figures with full rounded necks suggest a bolder or more obvious sensuality than paintings of the Virgin Mary. Although these works may call to mind the *femme fatales* of the late Victorian period, the boundaries between virgin purity and feminine sensuality are ambiguous at best. Many genre paintings from the Dutch Renaissance depict sensual and licentious women with large, diffuse goiters, some bordering on disfigurement. A typical example from the seventeenth century is Willem de Mieris's *The Escaped Bird* (1687, Hamburg, Kunsthalle) in which a pale fleshed woman with partly exposed breasts and a large, rotund goiter looks in wonder at the fact of the escaped bird, "a metaphor for lost virginity."<sup>62</sup> Similarly, allegorical paintings such as Jacob de Gheyn II's *Temperantia* (early 17th century, Amsterdam, Rijksmuseum) portray the female symbol of temperance as a sensual bare breasted woman with a disfiguring goiter.<sup>63</sup> Throughout the Renaissance and Baroque periods, artists often used the same models for religious, secular, allegorical, and classical figures. It is understandable that such a prominent feature as the

exposed neck, especially in paintings that show only the upper third of a woman's body, draws the viewer to question whether the painter intended a certain eroticism in the work and whether viewers of European art during a period of more than five hundred years naturally associated the full rounded neck with female sensuality.

In addition to ambiguous notions of femininity suggested in paintings of women with full rounded necks, the association of the diffuse goiter with a woman's designated gender role is apparent to the modern viewer of Renaissance paintings. As early as the Imperial period in Roman art, the marriageable woman and the newly married woman were the subjects of formal portraits. In many of these portraits the full rounded neck figures as a prominent feature and is often the focal point of the painting. Whether the female figure's present or future function as wife or mother is the subject of the painting, Roman portraits of women exude an air of confidence and definition of their presumed roles. A Roman pavement mosaic titled *Summer* (detail of the full pavement on the subject of the four seasons) features a direct frontal portrait of a young woman (**Figure 1-22**, 4th–5th century, Rome, Museo Nazionale Romano, Palazzo Massimo alle Terme). The woman looks boldly at the viewer; the large rounded neck revealing a sizeable goiter is part of the focal point. As a representation of summer in a painting on the four seasons, her figure would naturally be associated with fertility.



**Figure 1-22**

*Summer*, detail of the full pavement on the subject of the four seasons (4th–5th century, Rome, Museo Nazionale Romano, Palazzo Massimo alle Terme)

Similarly, the Roman painting on an Egyptian mummy cover *Portrait of a Young Woman with a Gilded Wreath* (Figure 1-23, 120–140 CE, New York, Metropolitan Museum) reveals a full neck with prominent Venus lines, which are parallel to the line created by the young woman’s necklace. The museum’s object label notes “Venus rings on her neck call attention to her youthful plump body,”<sup>64</sup> further evidence of the neck as focal point in a domestic portrait. More significant, however, is the symmetrical swelling in the young woman’s central neck, quite suggestive of a pubescent goiter and possibly a reflection of a pubescent diffuse goiter and imminent fertility. Art historians have long noted the connections between portraits from Roman and Egyptian antiquity and those from the Byzantine and Renaissance eras in Europe. Berenice Geoffroy-Schneiter writes about the startling almost “hypnotic gaze, as if suspended in an eternal present” characteristic of the mummy portraits, a stylistic technique that invites the viewer to engage with the artist’s subject.<sup>65</sup> In the *Portrait of a Young Woman with a Gilded Wreath*, the direct frontal gaze also accentuates the prominence of the goitrous neck. Goiters were at one time endemic in the Nile Valley, a fact that may explain why there is a significant number of mummy portraits of women with full rounded necks. The contrast between those paintings with



**Figure 1-23**

*Portrait of a Young Woman with a Gilded Wreath* (120–140 CE, New York, Metropolitan Museum)

apparent diffuse goiters and those with slender necks suggests that the artists who used realistic anatomical details to represent their subjects' idiosyncrasies were well aware of the difference. In both of the above Roman/Egyptian images the fertility theme is enhanced by the artists' emphasis on the women's youth and graceful swelling of their diffuse goiters.

By contrast, in Botticelli's fifteenth century *Portrait of a Young Woman* (**Figure 1-24**, 1475, Florence, Pitti Palace, Palatine Gallery), a lateral view draws attention to the full rounded neck of a young woman believed to be Simonetta Vespucci. It also separates the viewer from the painting's subject, who is looking in the distance. The side view emphasizes the sensual fluidity and curve as well as rotundity of the neck in contrast to the angular facial features of the woman.<sup>66</sup> The band around her neck may allude to the ancient tradition of testifying to a woman's fertility (the "honeymoon neck") by overtly demonstrating the effect on a necklace of an enlarged thyroid gland or goiter associated with pubescence and fertility.



**Figure 1-24**

Botticelli, *Portrait of a Young Woman* (1475, Florence, Pitti Palace, Palatine Gallery)

Among Baroque examples of the formal portrait, Rubens painted several of his second wife, one of which is *Helene Fourment* (Figure 1-25, 1630–32, Munich, Alte Pinakothek). He also painted a wedding portrait of his wife's sister in *Portrait of Susanna Lunden* sometimes known as *The Straw Hat* (Figure 1-26, 1622–25, London, National Gallery).<sup>67</sup> Both portraits depict upper class women/brides in engaging frontal poses that emphasize the subjects' femininity and status as marriageable women. The plunging necklines also reveal the erogenous zone of a full bosom and full rounded neck associated with fertility and maternity. Since Helene and Susanna

Fourment were sisters, by portraying both women with prominently diffuse goiters, Rubens may have unwittingly documented the presence of familial thyroid disease, a phenomenon that appears in other sixteenth and seventeenth century paintings. Rubens made numerous paintings of his wife posing as herself or as erotic figures such as the blond dancer in *The Three Graces* (see Figure 1-18), or as *Venus in a Fur Wrap*. Considering these and other examples of his consistent depiction of Helene Fourment's goiter in all his paintings of her, he seems also to have associated the full rounded neck with feminine, and possibly erotic, beauty.<sup>68</sup>



**Figure 1-26**

Rubens, *Portrait of Susanna Lunden* sometimes known as *The Straw Hat* (1622–25, London, National Gallery)



**Figure 1-25**

Rubens, *Helene Fourment* (1630–32, Munich, Alte Pinakothek)



**Figure 1-27**

Piero della Francesca, *Madonna del Parto*  
(1460, Monterchi, Tuscany)

Following the theory (see notes 39 and 40) about the enlarged size of the thyroid gland at the time of puberty and other theories about its prevalence during pregnancy and lactation, the modern viewer cannot help associating these women's enlarged thyroids or full rounded necks with the marriage and maternity themes suggested in the

paintings. According to the theory, one might expect to see the full rounded neck in paintings of women shown during and after pregnancy. If the artists' models lived in iodine deficient regions and were also pregnant or lactating, the presence of goiter would have been even more likely. Several paintings fall into this category. According to Guglielmo Bilancioni, Piero della Francesca's *Madonna del Parto* (Figure 1-27, 1460, Monterchi, Tuscany) faithfully includes "the languid pallor of the expectant mother

in a turgid and full neck" (Bilancioni 52–53). Similar attention to the enlarged neck of pregnant women before and after childbirth is apparent in the portrait of the lactating Virgin Mary in *The Virgin and Child Before a Firescreen* by a follower of Robert Campin who was known as the Master of Flémalle (Figure 1-28, 1440, London, National Gallery) and in Fra Filippo Lippi's painting of the post-partum St. Anne in *The Madonna and Child with Stories of the Life of Saint Anne* (Figure 1-29, 1452, Florence, Pitti Palace, Galleria Palatina).<sup>69</sup> In each of the three paintings the female figure has a prominent swelling in the neck, but Piero della Francesca's *Madonna del Parto* best illustrates an asymmetrical goiter. Lippi and the follower of Campin portray the diffuse goiter more common to early motherhood.<sup>70</sup>

A later work by Dutch artist Jan Steen *The Doctor and the Patient* (Figure 1-30, 1670, Prague, National Gallery, see p. 21) reveals the goitrous neck of an older pregnant woman, presumably discussing her pregnancy with the doctor in the picture. The artist's satirical humor is suggested in the darkened setting of the scene, as if there is an attempt to hide the pregnancy despite the telltale signs of swollen neck, swollen abdomen, and

**Figure 1-28, facing page**

Follower of Robert Campin (the Master of Flémalle), *The Virgin and Child Before a Firescreen* (1440, London, National Gallery)





**Figure 1-29**

Fra Filippo Lippi, *The Madonna and Child with Stories from the Life of Saint Anne* (1452, Florence, Pitti Palace, Galleria Palatina)



the flask of urine held by the servant in the background, symbols that would have been easily recognized by seventeenth century viewers familiar with the popular graphic allegories of that period.

*The Resting Horseman*, a genre painting of homely realism (**Figure 1-31**, 17th century, London, Victoria and Albert Museum) by the French artist Louis Le Nain may be less cynical than Steen's painting but still ambiguous in its sexual references in a portrayal of a young woman with

an enlarged goiter. The painting focuses on a female peasant figure, presumably a wife or lover and either the mother or older sister of the young boys in the picture. She is carrying a large urn across a meadow. In the right foreground of the painting a horseman, who is possibly her husband but more likely a possible lover, rests on a rock, holding his horse's lead. The peasant woman's full rounded neck speaks of fertility and maternity, much as the animals in the pastoral scene suggest fecundity. The puzzling contrast between the barefoot, burden-laden

young woman with ragged children and the horseman, who wears shoes and rides rather than walks, raises a question about their relationship. Is the woman's apparent sexuality also a sign of her vulnerability in the face of masculine power? Does her noticeable neck mass draw more attention to that vulnerability to the seventeenth century viewer who may read a message in the narrative?

---

**Figure 1-31**

Louis Le Nain, *The Resting Horseman* (17th century, London, Victoria and Albert Museum)





Considering the strong association between the full rounded neck and fecundity and maternity, one might expect most Renaissance and Baroque paintings of women with goiters to represent younger women at the peak of their fertility. As we have noted, many of the Virgins in the paintings already discussed and numerous others reveal a young woman who may not be more than fifteen or sixteen years old and whose goiter may be especially enlarged because she is barely post-pubescent or because she is pregnant or lactating. The Virgin Mary as a grieving (older) mother in paintings of the deposition or pietà, or as a saint after her own death, however, is an exception. Seventeenth-century Dutch painter Anthony Van Dyck features an older looking Mary in two of his paintings both of which are titled *The Deposition* or *The Lamentation*. Both works depict a grieving mother in mourning clothes, her covered head and upward gaze accentuating a thick, goitrous neck.<sup>71</sup> Titian's painting of the *Assumption* (Figure 1-32, 1518, Venice, Church of Santa Maria della Gloriosa dei Frari) also portrays a mature Virgin in the glory of her heavenly journey, her full neck reminiscent of the strength suggested in Piero della Francesca's painting of *The Virgin of the Misericordia*. In Titian's painting, Mary holds her arms out as she gazes upward almost in a state of rapture, her sumptuous red gown set off by a deep blue saint's cloak fastened by a brooch beneath the goitrous swelling.

**Figure 1-32**

Titian, *Assumption* (1518, Venice, Church of Santa Maria della Gloriosa dei Frari)



**Figure 1-33**

Il Sodoma, *Life of Saint Benedict: Benedict leaves his father's home to study in Rome* (1505, Monte Oliveto Maggiore, Tuscany)

Similarly, the mother of Saint Benedict depicted in one of the frescoes of Il Sodoma's *Life of Saint Benedict* (**Figure 1-33**, *Benedict leaves his father's home to study in Rome*, 1505, Monte Oliveto Maggiore, Tuscany) looks toward her departing son with motherly affection, her prominent diffuse goiter a reminder of her maternal, humble status and possibly of a region of endemic goiter. Interestingly, although the title refers only to the "father's home," the painting depicts

the grieving women who must part with Benedict. In both paintings the artist has emphasized the shield-like shape of the thyroid gland.

More youthful models with diffuse goiters appear in paintings of female saints and biblical heroines. Several portraits of the Magdalen reveal a young, beautiful woman with a diffuse goiter, among them Roger Van der Weyden's *The Magdalen Reading* (**Figure 1-34**, 1438, London, National Gallery). In the New Testament parables the Magdalen was considered a sinner "healed of evil spirits and infirmities ... out of whom went seven devils" (Luke 8:2). She was present at the crucifixion, stayed by the tomb

of Jesus after his death, and was the one to whom Jesus "appeared first" after the resurrection (Mark 16:9). Van der Weyden's painting portrays a diminutive and modest Magdalen rather than a victim of evil spirits. Captured in the act of reading (presumably scripture), eyes cast down, she is fully covered except for her face and her neck. The neck is noticeable for its subtle swelling similar to the diffuse goiters in many paintings of the Virgin Mary. The suggestion of youth, possibly on the cusp of puberty, reveals the artist's emphasis on the fragility of this singular woman in the biblical narrative.



**Figure 1-34**

Roger Van der Weyden, *The Magdalen Reading*  
(1438, London, National Gallery)

**Figure 1-36**

Artemisia Gentileschi, *St. Cecilia* (1616, Rome, Spada Gallery)

evident by the outlining of its shield like shape. As a queen, Catherine of Alexandria was tortured by the Roman Emperor Maxentius for her refusal to marry him, choosing instead to become a “bride of Christ.”<sup>72</sup> The goitrous swelling of the saint’s neck seems to reflect the ambiguity of purity and sensuality evident in paintings of the Virgin Mary with a similar feature.

Similar to Catherine in her vow of celibacy, *St. Cecilia* is portrayed in a frontal pose in the Baroque painting of the saint by Artemisia Gentileschi (**Figure 1-36**, 1616, Rome, Spada Gallery). Luxuriously arrayed in a gold robe and holding the lute associated with her role as patroness of music, the figure of Cecilia is looking upward, chin lifted, to reveal a strong as well as full rounded neck. Unlike Catherine, Cecilia at first received a gentler fate from the suitor whom she refused to marry, and she succeeded in converting her husband to Christianity, only later to be suffocated, then beheaded for “refusing an act of idolatry.”<sup>73</sup> Artemisia Gentileschi’s portrait of *St. Cecilia* suggests a strong, self-sufficient woman who knows how to control her own destiny.

Three female saints, Saint Catherine of Alexandria, Saint Cecilia, and Saint Agatha, whose stories of martyrdom would have been familiar to the Renaissance viewer, are frequently depicted with full rounded necks indicating the presence of a diffuse goiter. The stylized pose and beauty of Vittore Crivelli’s *St. Catherine of Alexandria* (**Figure 1-35**,

1491, Oxford, Ashmolean Museum, see p. 11) reflects the influence of the aesthetic idealism of the early Renaissance, but anatomical realism is also apparent. Leaning to the right and gazing into the distance, Crivelli’s *St. Catherine* is framed in gilt that contrasts dramatically with the pale flesh of her face and full rounded neck. The enlarged thyroid gland is made more



**Figure 1-37**

Sebastiano del Piombo, *The Martyrdom of Saint Agatha* (1520, Florence, Pitti Palace, Palatine Gallery)

Sebastiano del Piombo's *The Martyrdom of Saint Agatha* (**Figure 1-37**, 1520, Florence, Pitti Palace, Palatine Gallery) portrays a strong woman who refuses to give in to the sexual advances of the Roman consul Quintian and the torture executed by the brothel-keeper to whom he sends her (Attwater and John 28).<sup>74</sup> Del Piombo's Agatha confronts her adver-

saries with a bold stare as one of them pulls at her breast with huge pliers. Her full rounded neck, which suggests the presence of a diffuse goiter, and her bared breasts powerfully convey the artist's emphasis on the female strength of a saint who chose death over marriage and renunciation of religious faith.

In the stories of all three saints, the powerful appeal of celibacy is pitted against the threat of a forced marriage or rape, or in the case of Cecilia, unwanted consummation of her marriage. Catherine and Cecilia devoted

themselves to the cause of religious conversion, and Catherine and Agatha were also victims of Roman persecution of Christians. Although the portrayals of these saints as young, sexually fertile and beautiful women, attributes further emphasized by their smooth, diffuse goiters, suggest female vulnerability, the stereotype is undercut by a powerful paradox. Each of the saints in these portraits has a distant gaze, suggesting an ethereal rather than corporal relationship to her fate.



Similar moral strength and self-sufficiency are characteristics of a number of biblical heroines whom Renaissance painters portray with full and rounded necks: Zipporah, Susanna, and Judith. Botticelli's *The Daughters of Jethro* from *Scenes from the Life of Moses in the Sistine Chapel* (**Figure 1-38**, 1481–82, Rome, Vatican) features a scene from the biblical narrative in which Moses, having “fled from the face of Pharaoh, and dwelt in the land of Midian” (Exodus 2:15) aided the daughters of Jethro, the priest of Midian, in providing water for their flocks. In the painting, one of the daughters, who carries a large water urn on her head, looks plaintively toward Moses, her exposed neck revealing a large diffuse goiter, which the viewer might associate with her youth and fertility. In the story, Jethro gives his daughter Zipporah to Moses as “compensation” for his help with the flocks. Presumably the woman with the goitrous neck is a reminder of the family legacy that is to follow as Moses attempts to free the “children of Israel” from their bondage in Egypt (Exodus 2:25).

**Figure 1-38**

Botticelli, *The Daughters of Jethro* from *Scenes from the Life of Moses in the Sistine Chapel* (1481–82, Rome, Vatican)





Alluding to a more dramatic scene in the biblical story from the Book of Daniel in the Apocrypha, Rubens's *Susanna and the Elders* (**Figure 1-39**, 1607–8, Rome, Borghese Gallery) features a fully nude Susanna in the act of bathing, approached by the spying Elders who, according to the story, attempt to blackmail her into sexual submission by bearing false witness against her. Susanna's courage in the face of difficult choices is conveyed by Rubens's rendering of the strong gesture of her arm in which she clearly rejects the advances of the Elders as she looks up at one of them. But her sensuality, beauty, and consequent vulnerability are also openly revealed in her nudity, her long flowing hair and her neck with its full diffuse goiter.

**Figure 1-39**

Sir Peter Paul Rubens, *Susanna and the Elders*  
(1607–8, Rome, Borghese Gallery)



**Figure 1-40**

Botticelli, *Judith's Return to Bethulia* (1472, Florence, Uffizi Gallery)

A more familiar biblical heroine, Judith from the Book of Judith in the Apocrypha, is represented in numerous paintings that explore different interpretations of Judith's femininity. Botticelli's *Judith's Return to Bethulia* (Figure 1-40, 1472, Florence, Uffizi Gallery) portrays a contemplative Judith after she has beheaded Holofernes in an attempt to save her people. Like Botticelli's Virgins discussed earlier, his Judith stands with eyes cast down, her head tilting slightly to the right, revealing a full, rounded neck that seems synonymous with her sensual beauty, an attribute that Judith used in order to deceive Holofernes into thinking he would have a romantic relationship with her.<sup>75</sup> Botticelli's painting suggests a contrite and even melancholy expression of Judith in the final scene of the narrative from the Apocrypha after she has picked up the head of the dead Holofernes. Here her maidservant is carrying it away in a basket, presumably for Judith to show her people in Bethulia where she went "according to their custom unto prayer" (Apocrypha, Judith 12:10).

In contrast to Botticelli's sensual but maidenly Judith, Caravaggio's Judith in *Judith Beheading Holofernes* (Figure 1-41, 1599, Rome, Museo Nazionale d'Arte Antica, Palazzo Barberini) is portrayed as a strong, aggressive woman, able to exploit her femininity and commit murder at the same time. According to Puglisi, the model for *Judith Beheading Holofernes* was probably the same woman that Caravaggio painted in his *St. Catharine of Alexandria* and



in his *Conversion of Mary Magdalene* (131). In both of those works, the model's neck is more visibly exposed for the viewer to see the woman's diffuse goiter. In the painting of *Judith*, however, the neck is partly obscured by a shadow, the light reflected instead in her distraught facial expression and chest. The painting's background of rich drapery, the intense *chiaroscuro* lighting that links Judith with her antagonist and ultimate victim, and the shocked expression on the peasant woman's face all dramatize the heroic narrative.<sup>76</sup> Beautiful and ruthless at once, this Judith also exhibits the

artist's faithful attention to realistic detail, as demonstrated in the subtle rendering of her strong, goitrous neck. Caravaggio's emphasis is on the virtual action of murder, executed by a beautiful but obviously courageous woman. The narrative intensity of the painting endows his heroine with epic strength and aggressiveness rather than the idealized and gentler contemplativeness of Botticelli's *Judith*.

#### Figure 1-41

Caravaggio, *Judith Beheading Holofernes*  
(1599, Rome, Museo Nazionale d'Arte Antica,  
Palazzo Barberini)



**Figure 1-42, facing page**

Caravaggio, *The Supper at Emmaus*  
(1481–82, London, National Gallery)

Ambiguity of intention in the numerous representations of “beautiful” or “enhancing” goiters is also apparent in paintings of male figures whose goiters are more diffuse than disfiguring. While some paintings of the Christ Child reveal a small diffuse goiter similar to that of the Virgin Mary figure in the same paintings, one of the few works to depict the adult Christ with a large diffuse goiter is Caravaggio’s *The Supper at Emmaus* (**Figure 1-42**, 1481–82, London, National Gallery). Like Caravaggio’s “pretty boys pretending to be Eros or Bacchus,”<sup>77</sup> his figure of Christ is youthful and unencumbered by a beard or other noticeable male characteristics such as strong sternocleidomastoid muscles. Instead, Caravaggio’s Christ figure has a diffuse goiter that rounds out and beautifies his neck, much as it would the neck of a Virgin Mary or baby Jesus. Caravaggio’s painting alludes to the New Testament story from the Gospel of St. Luke, in which the followers of Christ have just discovered that Christ was missing from his sepulcher (Luke 24:12) and later, unaware of the resurrection, meet him on their way to Emmaus where they dine together and where his identity is revealed when he “expounded unto them in all the scriptures the things concerning himself” (Luke 24:27). The painting is especially remarkable for its lack of hierarchical composition and the humanism evinced in the rent clothing of the disciples and in their expression of wonder and surprise. Caravaggio’s familiar use of *chiaroscuro* lighting illuminating the figure of Christ and the circular composition of Christ’s

outstretched arms suggest both holiness and humbleness. It is also possible, however, that Caravaggio attempted to represent the ethereality of the resurrected Christ who was reminding his disciples of their role as witnesses before he would again be “carried up into heaven” (Luke 24:51). As such, Caravaggio’s Christ figure is represented with feminine grace accentuated by a smooth diffuse goiter similar to that of a pubescent girl.



**Figure 1-43**

Melozzo da Forlì, *An Angel Playing the Viola da Braccio* from *Musical Apostles and Angels* (c. 1480, Vatican State, Pinacoteca, Vatican Museums)

These qualities of Caravaggio's resurrected Christ figure are similar to those conveyed in several Renaissance and Baroque paintings of angels that reveal a full rounded neck in male figures whose delicate, blonde curls, youthful faces, and luxurious robes often suggest a feminizing of male characteristics, similar to the androgynous representations of mythological figures such as Apollo and Cupid in paintings from the same period. The presence in males of diffuse goiter that enhances rather than disfigures further confuses the viewer who may associate the "goiter beautiful" with the various categories of women already discussed in this chapter. To the Renaissance painter and viewer, were angels considered asexual, androgynous or inherently effeminate, or did artists wish to accentuate their otherworldliness or ethereality with such feminine characteristics? Is the prominently diffuse goiter simply a sign of their heavenly role or idealized and perhaps, feminine, beauty or a suggestion of sensuality, sensitivity, and adolescence? Some of the angels depicted in Renaissance paintings appear to be young boys who are feminized in their dress and soft facial features. Melozzo da Forlì's *An Angel Playing the Viola da Braccio* from *Musical Apostles and Angels* (**Figure 1-43**, c. 1480, Rome, Vatican Pinacoteca) focuses on a young boy whose flaxen curls and goitrous neck suggest feminine characteristics, yet whose broad shoulders and large hands appear more male than female. Another musical angel at the base of Bartolomeo Vivarini's *Saint Mark Enthroned Surrounded by Musical Angels* (detail of angels in

central triptych) (**Figure 1-44**, 1474, Venice, Santa Maria della Gloriosa dei Frari) looks like a pubescent youth, but beneath his delicate, almost feminine, face a prominent goitrous lump verges on the “goiter grotesque” like those shown in paintings of mature male figures.<sup>78</sup>

Considering the range of examples of figures with diffuse goiters in the paintings described in this chapter, it is reasonable to conclude that the full rounded neck was thought to be a sign of beauty, and therefore associated with a variety of values important to the artist and viewer of the Renaissance and Baroque periods in Europe: purity, fertility, maternity, sensuality, moral or heroic strength, and holiness or ephemerality. The use of live models that became customary in the Renaissance, and the coincidental existence of goiters in several artists’ models—especially those used multiple times by Piero della Francesca, Botticelli, Caravaggio, and Rubens—and the growing interest in anatomical realism and naturalistic detail may have contributed to the abundance of paintings that feature figures, especially women, with diffuse goiters.

Unaware of the function of the thyroid gland or the significance of the goiter, artists working in iodine deficient areas such as the Alps and the Tuscan or Umbrian hills were likely to use female models with full rounded necks because of the prevalence of endemic goiter in those regions. Less prevalent, but equally interesting and more noticeable to the viewer, the large, often asymmetrical, disfiguring goiter, which we term here the “goiter grotesque,” appears in folk art as well as in the work of professional painters in the same regions of Italy and in other parts of Europe known to have endemic goiter. In the next chapter, we explore artists’ representations of Stage III goiters and other manifestations of thyroid disease, such as cretinism and exophthalmos.



**Figure 1-44**

Bartolomeo Vivarini, *Saint Mark Enthroned Surrounded by Musical Angels*, detail of angels in central triptych (1474, Venice, Santa Maria della Gloriosa dei Frari)





## Chapter 2

## The Goiter Grotesque: Power, Treachery, or Humbleness?

### Introduction

As we discussed in Chapter 1, the numerous examples of a full rounded neck in Renaissance art, especially in paintings of women with diffuse goiters, reveal a broad range of aesthetic choices that may have coincided with the presence of endemic goiter in specific regions of Europe during the fourteenth through seventeenth centuries. During this period and as late as the 1960s, up to 85 percent of the world's population in iodine deficient areas had goiters. Whether artists working in or near such areas revealed their models' goiters by chance or consciously

accentuated them for artistic reasons is unknown. We have found few examples, however, of women with diffuse goiters represented in a negative light. It is thought that in many rural areas, large, even disfiguring, goiters were regarded with endearment.

The origin of the painter's representation of the goiter remains aesthetically ambiguous to the modern viewer, especially in the repeated representation of

an idealized female beauty in figures with diffuse goiters. Although the appearance of a noticeably enlarged and disfiguring goiter occurs occasionally in paintings of women, there are many examples of disfiguring goiters in paintings of male figures. In such cases the association between the dramatically enlarged, often multinodular, goiter and the painting's subject more commonly reflects the painter's emphasis on anatomical realism than on aesthetic idealism. Two paintings created almost three hundred years apart remind us of the disfiguring appearance of a greatly enlarged goiter in portraits of women who might otherwise be considered beautiful: Artemisia Gentileschi's *Judith and*

*her Maidservant with the Head of Holofernes* (Figure 2-1, 1614–20, Florence, Pitti Palace, Galleria Palatina) and Picasso's *Half-Length Female Nude* (Figure 2-2, 1906, Chicago, Illinois, Art Institute).

Gentileschi's painting of *Judith* is a particularly dramatic example of such realism. The viewer is drawn to the painting's high focal point in which Gentileschi's use of light accentuates Judith's neck. A large bulbous goiter detracts from traditional notions of feminine beauty in the otherwise elegant and aristocratically attired figure. The painting alludes to a passage in The Book of Judith that describes the Hebrew Judith's use of feminine power and craftiness in her role as a wealthy widow determined to save her people: She "braided the hair of her head ... and put on her garments of gladness," and "she decked herself bravely "with

#### Figure 2-2

Pablo Picasso, *Half-Length Female Nude* (1906, Chicago, Illinois, Art Institute)



#### Figure 2-1, facing page

Artemisia Gentileschi, *Judith and her Maidservant with the Head of Holofernes* (1614–20, Florence, Pitti Palace, Galleria Palatina)

jewels “to allure the eyes of all men that should see her” (Judith 10: 3–4). Although true to the biblical description of Judith’s adornment, Gentileschi’s emphasis on the physical symbols of Judith’s courage and strength eclipses the sensuality in the painting suggested by the heroine’s elaborate hairdo, gown, and jewels. Like a seasoned warrior, she grips the sword’s hilt with its head of Medusa, an allusion to the legendary Gorgon whose stare and serpent like hair turned any who looked at her into stone. The “meat basket” in which Judith has hidden the results of her courageous act is barely visible in the maidservant’s arm and looks more like a market basket than the container of the enemy’s head, an example of Judith’s careful use of disguise in her departure from Holofernes’ tent. Judith’s proud but stern gaze presumably directed toward the gate of Bethulia where she will be received as a heroine, her slightly flushed complexion and her strong goitrous neck all become associated with her unquestionable ability to accomplish her quest.

In Gentileschi’s *Judith* the grotesque size of the heroine’s goiter and the distortion of her neck reveal the existence of thyroid pathology.<sup>79</sup> Unlike many of the heroic female figures with diffuse goiters in paintings that we discussed in **Chapter 1**, the figure of Gentileschi’s robust heroine may have shocked seventeenth century viewers in its suggestion of brute physical strength rather than feminine delicacy or self-effacement. The modern viewer with an understanding of the

signs of thyroid disease may be more inclined to see Gentileschi’s painting as a realistic portrayal of an aggressively vengeful but righteous heroine rather than that of a masculinized female. The realism of Caravaggio and Artemisia Gentileschi among others during the Baroque period in Italy and northern Europe intensified the degree of anatomical accuracy and naturalistic detail in painting. Both features reflected the growing interest in human anatomy and science during the seventeenth century.<sup>80</sup>

The representation of enlarged disfiguring goiters in art such as Gentileschi’s portrayal of Judith thus coincided with a growing interest in the pathology of the goiter but preceded an accurate understanding of thyroid disease, its causes and consequences. Although such features are infrequently seen in art after the nineteenth century, portraits of women by modernist painters such as Modigliani, Matisse and Picasso often focus on the female neck as an erogenous zone. As late as 1905, Picasso’s *Half-Length Female Nude* confirms the continued fascination with the neck and aesthetics in portraiture. The painting’s subject is shown to be more vulnerable than Gentileschi’s *Judith* because there are no external signs of her status such as the elegant costume and jewels in Gentileschi’s portrait. The neck of Picasso’s nude and its proximity to and possible unity with the erogenous zone of the breasts reminds the viewer of the ambiguous effect of both beauty and distortion that a disfiguring goiter can create.

---

### **Etiology and treatment of disfiguring (surgical) goiter, Graves’ disease, and cretinism**

---

However flattering and/or interesting small diffuse goiters may have seemed to Renaissance and Baroque artists, modern medicine has taught us that small diffuse goiters often continue to enlarge and become multinodular with aging, eventually causing cosmetic as well as physical problems for the patient with thyroid disease. Such goiters can also be disfiguring if their size is disproportionate to an individual’s body, and especially if they are asymmetrical, nodular or substernal. In the latter situation there is less space for the goiter to enlarge without causing symptoms such as shortness of breath or difficulty swallowing. Although most goiters occur in individuals with normal thyroid function, some patients may have too little or too much thyroid hormone.

Graves’ disease is an autoimmune disease that occurs as the result of thyroid antibodies that stimulate the function and growth of the thyroid gland, causing the patient to become hyperthyroid, usually with a goiter. Another form of autoimmune thyroid disease is Hashimoto’s thyroiditis, which occurs when the antibodies may or may not lead to the development of goiter but often inhibit the function of the thyroid gland, causing the patient to be hypothyroid. Relatives of a patient with Graves’ disease or Hashimoto’s thyroiditis are at a higher risk of developing these conditions. In areas of severe iodine deficiency goiters are often associated with hypothyroidism, or rarely, hyperthyroidism.



### Figures 2-11

Il Sodoma (Giovanni Bazzi), *The Life of St. Benedict: Benedict frees a peasant, shackled by the Goths* (1509, Monte Oliveto Maggiore, Tuscany) (see p. 80)

When hypothyroidism occurs in the newborn or in young children, most commonly in areas of endemic goiter, it is associated with short stature and mental deficiency (cretinism).<sup>81</sup> In addition to a large disfiguring goiter, “mental retardation, growth retardation, delayed bone maturation, thick tongue, thick skin, and, frequently, deafmutism,” as well as difficulty with gait, are also associated with the most common form of cretinism.<sup>82, 83</sup>

Goiters may be diffuse and symmetrical, especially in patients with Graves’ disease because the follicular thyroid cells are uniformly responsive to growth stimulating antibodies. We have viewed such goiters in the paintings discussed in **Chapter 1**. Multinodular goiters or thyroid glands with solitary nodules, however, are usually asymmetrical and may be either benign or malignant. Such goiters sometimes cause not only cosmetic problems but also medical symptoms, such as shortness of breath, pain, or dysphasia reflecting tracheal or esophageal compression or, in the case of malignant goiter, invasion of the trachea, larynx or

esophagus. The most common type of malignant goiter or thyroid cancer is a papillary tumor, and this tumor may metastasize to the regional lymph nodes or, less commonly, to distant sites such as the lungs or bones. Thus a person with thyroid cancer may have a visible mass (primary tumor) in the central neck and also in the regional lymph nodes in both the central and lateral neck. Thyroid masses caused by embryologic abnormalities such as thyroglossal duct cysts occur in the central neck above the thyroid gland. Such masses move upward when the tongue is protruded forward. Some small and large goiters are only partially or not at all observed in the neck because they are predominantly

situated beneath the sternum.

Persons with Graves' disease or autoimmune thyroiditis have not only thyroid related problems such as goiters but also hyperthyroidism with increased basal metabolism. They may also have extra thyroidal manifestations such as protruding eyes (exophthalmos) and potential loss of vision, and anterior subcutaneous leg swelling known as pre tibial myxedema with thickened skin usually situated over the shins and sometimes mistaken for insect bites.<sup>84</sup> Men or adolescent males with Graves' disease commonly have gynecomastia, that is, small female-like breasts.

Other causes of neck masses not associated with thyroid disease include scrofula, lymphoma, neurofibromatosis (multiple subcutaneous nerve tumors known as "elephant man syndrome") reactive lymphadenopathy due to carious teeth, other head and neck infections, or other benign and malignant tumors. The viewer of paintings of figures with large disfigured necks can easily confuse such masses with goiters.

On physical examination to the observer's eye the thyroid gland and thus the goiter move up and down with swallowing because the thyroid is attached to the trachea, whereas virtually all other neck masses extrinsic to the thyroid gland do not. Until the late nineteenth century, however, neither clinicians nor artists would have distinguished between goiters and other neck masses. In addition to the telltale movement of the goiter during swallowing, patients with either hypo-

thyroidism or hyperthyroidism may have an altered behavior as well as an altered appearance. Symptoms of hypothyroidism or myxedema include lethargy, drowsiness, weakness, slow speech, memory loss, shortness of breath, low body temperature, depression, and rarely, confusion, mania, and paranoia. Symptoms of Graves' hyperthyroidism include increased nervousness, irritability, fatigue, weakness, insomnia, apprehensiveness, mood swings, and inability to concentrate.

Because of the large size of some goiters and their progressive symptoms such as shortness of breath, medical and surgical therapies have been proposed from ancient times to the present. "*The Arthora Veda*, an ancient Hindu collection of incantations dating from 2000 BC (BCE), contains extensive forms of exorcisms for goiter."<sup>85</sup> In 340 CE, Ko Hung, the great Chinese alchemist, recommended using seaweed for individuals with goiter, a treatment that reappeared during the Middle Ages in China and during the twelfth century in Europe (Medvei 86 and 189). Paracelsus recommended treatment of goiter with the "application of toad blood, the stroking of a cadaver's hand, and other therapies rather than surgery."<sup>86</sup>

Since thyroid abnormalities were initially not distinguished from other neck masses, it is difficult to know when the first thyroid operation for goiter was performed. Some medical historians suggest that the non-medical Roman writer Aulus Cornelius Celsus (25 BCE–50 CE) and the Greek physician Galen (129–200 CE) were among

the first to describe operations on the human thyroid gland, but this information is speculative. The supposed description by Celsus of an operation on goiter, presumably derived from a report by a physician, more likely pertained to surgery on "cervical cysts, dermoid cysts, atheromas" and to "tuberculosis of the cervical lymph nodes" than to an actual goiter (Merke 94). Merke notes that in the first century CE, one hundred years before Galen, the Greek educated physician Leonides worked in Rome where he recorded medical observations. Leonides describes "the recurrent laryngeal nerves, the necessity of not damaging them in the operation on the glands, and the impairment of the voice that follows their injury" (Merke 86). The Greek Soranos, "who lived in Rome about the same time as Galen, mentioned the recurrent branches of the vagus nerve but did not call them recurrent nerves" (Merke 86).

The often repeated story that Galen operated on goiters probably arose from Galen's report on "two cervical gland operations. These operations were intended not only to be drastic illustrations of the dangers of this surgery but also to show [Galen's] reputed 'discovery' of the recurrent laryngeal nerves in the proper light" (Merke 85). According to Welbourn and others, Galen must have been near the thyroid gland during his anatomical dissections because he identified the recurrent laryngeal nerves and seven of the twelve cranial nerves, and he correctly suggested that in pigs and man the recurrent laryngeal nerves were responsible for phonation

(ability to make a sound) (Welbourn 21 and Garrison 115). Merke, however, disagrees, arguing that Galen “never gave a really accurate description of a *bronchiocele*<sup>87</sup> and still less did he ever operate upon one” (Merke 86). The Greek Paul of Aegina (625–690 CE) was one of the first to suggest surgery for a form of *bronchiocele*. He cautioned against it, however, because of the vascularity of the thyroid gland which caused considerable technical problems in the operations (Welbourn 21).

It is generally accepted that the first thyroid operation was performed in the latter part of the tenth century by Abul Kasim or Albucasis in Baghdad (Merke 104). Abul Kasim was also “the first physician to supply documentary evidence of endemic goiter” (Merke 107). In 1170 Roger Frugardi, known as Roger of Palermo, from the Bamberg School in Salerno, Italy, also recommended operations for selected patients with goiter when medical treatment including seaweed failed (Welbourn 21). Frugardi was probably the first to provide “a credible description of operations for goiter” (Welbourn 6).

Medical progress was slow during the Middle Ages because of the limited application of scientific principles in the practice of medicine and surgery and because of restrictions on anatomical dissection imposed by the Catholic Church.<sup>88</sup> In 1240 CE Frederic II, Emperor of the Holy Roman Empire, granted permission for human dissection. In 1316 Mundinus of Bologna, Italy published his book titled *Anathomia*, which, according to

Medvei, “was more a manual of dissection than a textbook of anatomy” (Medvei 93). In 1345 in France, Guy de Chauliac considered goiter to have both a “local and hereditary” etiology (Medvei 109). In his *Chirurgia Magna* (1363) he states, “the goiter consists of a ‘humour’ transformed into ‘bad matter’” (Merke 147). He recommends surgical removal of the diseased gland (Medvei 91). These scarce examples, however, are anomalies in the history of medicine and surgery that remained more closely linked to the Dark Ages than to the enlightened development of knowledge in other scientific fields during the Renaissance. Unfortunately, “[u]ntil the Renaissance there was neither induction nor experiment,” and physicians did not draw conclusions based on physical evidence (from Sir Thomas Allbut, *The Thyroid Gland: Medical History* (quoted in Medvei 89–90, note 20).

Human dissection became more popular after 1482 when Pope Sixtus IV “issued a bull that allowed local clergy to permit” it (Medvei 72). This proclamation enabled artists and surgeons, who often dissected the same cadavers at the same time, to understand human anatomy more accurately. With Vesalius’ publication of *De Humani Corporis Fabrica* in 1543, the knowledge of human anatomy increased dramatically, thus leading the way to more accurate diagnosis and eventually more effective surgery.<sup>89</sup>

In the early sixteenth century the French barber surgeon Ambroise Paré attempted a diagnosis of goiter, which, though incorrect, documented his use

of physical evidence rather than theory in the scientific process. He attributed a probable Graves’ disease goiter to an aneurysm in the neck (Medvei 72). He did so most likely because of an associated “bruit” (noise) and “thrill” (vibration) caused by its rich blood supply. In the seventeenth and eighteenth centuries medical observations began to include with some degree of accuracy the association of thyroid disease with specific European regions, thus suggesting the existence of endemic goiter. Lorenz Heister (1683–1758), known as the father of scientific surgery in Germany, observed that “Some nations are quite free from this disorder” (*bronchiocele* or *tracheocele* or goiter) “while others are grievously afflicted therewith,” including “inhabitants of Spain, Germany, Sweedland, Bavaria, France, Helvetia (Switzerland) and especially inhabitants of the Tirole.”<sup>90</sup> He observed that persons from the Tirole sometimes had goiters that “extend to the navel even down to their knees” (Heister, quoted in Medvei 157).

There was little doubt that the environment of inland regions and of mountainous regions of Europe contributed to the development of goiters and cretinism. There were conflicting theories about the origin of goiter, however, because some people from mountainous areas had goiters and others did not. Subsequent investigations documented that the iodine content of the soil in mountainous areas varied considerably because of glacial development of these areas (Merke 18). In 1863 Rudolf Virchow (1821–1902), the founder of cellular

pathology in Berlin, wrote about goiter and cretinism, and thought “the deficiency of certain substances has been regarded as the cause of goitre” (Merke 232). The pathophysiology of Graves’ disease or autoimmune thyroid disease and other types of goiter, however, continued to be unknown at the end of the nineteenth century. There was also no known treatment for the various types of goiter or for hypothyroidism or hyperthyroidism. Despite the growing development of theories based on observation and experimentation, most medical doctors and surgeons were reluctant to test their theories.

One such theorist, Theophile de Bordeu (1722–1776), came closer than most of his contemporaries to understanding the mechanisms of endocrine glands, demonstrated in his book *Anatomical Research on the Position of the Glands and their Action* published in 1752. De Bordeu, one of the founders of the vitalist school of Montpellier, France and a physician in the Court of Louis XV, favored developing an “argument starting from fundamental truths” (Medvei 156–157) rather than from inductive reasoning in response to experimentation. Because de Bordeu’s last book on chronic disease published in 1775 proposed the theory that “all the organs of the body discharge their secretions into the blood” (Medvei 714), some medical historians consider him to be the father of endocrinology. His theories, such as the above example, were generally correct: we know today that many organs, including the traditional endocrine

glands and the non traditional endocrine glands, such as the kidneys and heart, secrete hormones into the blood stream and regulate the function of other organs. De Bordeu accurately observed that more women than men have goiters and recorded the prevalence of enlarged thyroid glands among people living in the Pyrenees; he also noted that the presence of goiter was sometimes associated with a “hoarse voice” (Medvei 151). The latter observation suggests an association of goiter with hypothyroidism and edema of the vocal cords, or an invasive thyroid cancer with loss of function of the recurrent laryngeal nerve. Ironically, however, because the vitalists thought “experiments were rather crude and dangerous procedures ... because they so easily upset what was known to be true on *a priori* grounds” (Medvei 154), de Bordeu’s theories were not generally accepted by other scientists in the eighteenth century.

Partly because of the lack of experimentation and dissection and partly because the function of endocrine glands is more subtle than that of other systems in the body, endocrinology and endocrine surgery lagged far behind other medical and surgical specialties. Surgical treatment of goiter was dangerous and slower to progress than medical theories about the function and physiology of the thyroid gland, and it was equally looked upon with skepticism. The majority of physicians, therefore, persisted in using other treatments besides surgery for patients suffering from large symptomatic goiters.

From the sixteenth century until the early nineteenth century obtaining cadavers for human dissection was difficult, and therefore bodies were taken illegally from graves. Initially, the only legal autopsies were usually performed on executed murderers.<sup>91</sup> Because of these restrictions surgeons’ progress in properly identifying the anatomy of the thyroid glands was limited. With the Anatomy Act of 1836 the English Parliament legalized the selling of unclaimed bodies from workhouses and hospitals to accredited anatomy schools, thus discouraging grave robbery and making anatomical dissection more available.

Despite the contributions of Vesalius, Paré, Paracelsus and others who challenged cherished medical beliefs, it wasn’t until the experimentation of British surgeon John Hunter (1728–1793) that surgery began to emerge from the depths of medieval thought. Because learned doctors adhered to the doctrines of Hippocrates, Aristotle and Galen, primitive medical practices impeded the development of medicine as a science. Thanks to Hunter’s anatomical studies and research, surgery was gradually regarded as a science rather than a trade (Medvei 90). By transplanting organs from one animal to another or from one site to another in the same animal (auto transplant), both Hunter and later, Arnold Adolf Berthold (Germany, 1803–61), provided important information regarding a “vital” substance (Hunter) or a blood borne substance (Berthold), thus leading to the definition of an endocrine gland as a gland that secretes a sub-

stance that works at a distant site. Their surprisingly successful transplantations demonstrated that if one could alleviate or prevent the symptoms and clinical manifestations that developed after an organ was removed by being transplanted to another site, the organ must function by means of an “internal secretion into the blood” (Medvei 193). This “vital principle” was supposed to work independently of the nervous system.

---

### The development of thyroid surgery and treatment of thyroid cancer

---

In 1791 during the French Revolution, Pierre-Joseph Desault (1744–1795) of Paris recorded the first known published account of the successful removal of a goiter (Welbourn 6). During the operation to remove a 4 cm thyroid tumor, Desault used a vertical incision and ligated the superior and inferior arteries before removing the mass (Welbourn 22). He packed the wound, which suppurated and healed in about one month. In 1821 Johann Hedenus of Germany reported the successful removal of six “suffocating” goiters by ligation of all the arteries and the dividing of and transfixing of the isthmus (Welbourn 23). Fortunately, these operations were successful because the surgeons removed only part of the thyroid. Their decision to leave some of the thyroid gland in the patient, however, was not based on knowledge of its function. They still did not understand the function of the thyroid gland. They also did not know of the existence of thyroid hormone or of the dependence of the body on this hormone to sustain life.

Although physicians such as Caleb Hillier Parry (Bath, England, 1755–1822), Robert Graves (Dublin, 1796–1853), and Carl von Basedow (Germany, 1799–1854) described patients with exophthalmic goiter and hyperthyroidism, the pathophysiology of Graves’ disease or autoimmune thyroid disease was still unknown in the middle of the nineteenth century. Thyroid operations were rarely performed before the second half of

the nineteenth century. The mid-century discoveries of local and general anesthesia followed by Joseph Lister’s (Glasgow/Edinburgh/London, 1827–1912) documentation in 1867 of the benefits of antiseptics and asepsis made surgical procedures more acceptable to the patient and surgeon, with a marked decrease in post-operative mortality. Until the mid nineteenth century the mortality rate for thyroid operations approached 50%.

In his treatise titled “The Operative Story of Goiter” William Halsted (1852–1922), the famous American surgeon from Johns Hopkins Medical Center in Baltimore, could identify only eight thyroid operations using the scalpel between 1596 and 1800. From 1800 until 1848, however, sixty-nine operations using the scalpel were performed, thirty-one in Germany, Austria, and Switzerland, fifteen in France, fourteen in Great Britain, twelve in Italy, and five in the United States (Welbourn 22). Despite this progress the overall mortality rate of thyroid operations remained high, and many leading surgeons, including Robert Liston (London, 1794–1847), Johann Dieffenbach (Berlin, 1794–1847), Theodore Billroth (Zurich, 1829–94), and Samuel Gross (Philadelphia, 1805–1884) advised against thyroid operations (Welbourn 22). It is therefore not surprising that the French Academy of Medicine condemned thyroid operations in 1850 (Welbourn 27).

Even with pronouncements against thyroid surgery, progress in surgery and medicine developed dramatically in the second half of the nineteenth century. The findings of Paul Sick (Germany, 1836–1900), Jacques Louis Reverdin (Geneva, 1849–1908), Theodore Kocher (Switzerland, 1841–1917), Victor Horsley (London, 1857–1916), George Murray (Newcastle-upon-Tyne, England, 1865–1939), and others reported that the behavior of patients after total thyroidectomy changed significantly and suggested that the thyroid gland was essential for normal life. Paul Sick reported that an energetic and happy ten-year-old boy became “quiet and dull” following removal of his thyroid gland by Wilhelm Hahn (Stuttgart, Germany, 1796–1874) and Karl Bockshammer (Stuttgart, Germany, 1828–91). In 1882 Reverdin described several patients who became feeble and anemic two to three months after removal of the thyroid gland. Two of these patients developed edema of the hands and face and looked cretinoid.

Theodore Kocher’s surgical results for patients with symptomatic goiters illustrate his technical expertise and the medical and surgical advances that occurred during the second half of the nineteenth century. Kocher was a student of Theodore Billroth (Zurich, 1829–94) and Bernard Langenbeck (Berlin, 1810–94) in Germany. From 1872 to 1882 as a surgeon in Berne, Switzerland, Kocher excised 101 goiters with a mortality rate of 12.8%. He obviously learned from this experience since his mortality rate was 2.4% during his next 250 thyroidectomies.

By 1895 his operative mortality for surgery on benign thyroid lesions had declined to about 1%, and by 1898 it had decreased to less than 0.2%. In 1883 Kocher reviewed the medical literature and reported that 268 thyroid operations had been performed since 1877 and that the mortality for benign goiters had decreased to 12%, whereas it was 57% for patients with malignant tumors. Sepsis and hemorrhagic complications had dramatically decreased, but complications of recurrent laryngeal nerve injury with hoarseness, tetany from removal of the parathyroid glands and myxedema from removal of the thyroid gland were now recognized (Welbourn 31).

Kocher, Moritz Schiff (Berne, 1823–96), Sir Victor Horsley, Reverdin and others were especially instrumental in recognizing the metabolic complications that occurred after thyroid operations. Their observations helped surgeons determine the function not only of the thyroid gland, but also of the adjacent parathyroid glands. Kocher operated upon “a spirited and joyous eleven year old girl Maria Bichsel on January 8, 1874” who became “peevish and dull and reluctant to work” after her total thyroidectomy (Welbourn 32). “Kocher’s observations led to his evaluation of other patients who had been treated by total, and less than total, thyroidectomy. In 1883 Kocher reported that 28 of 30 patients who had partial thyroid resections were well, whereas 16 of 18 patients who had total thyroidectomies were dull and some looked cretinoid. Of interest is that two patients did not develop hypothyroidism even though

they were treated by presumed total thyroidectomy, and both had persistent pyramidal lobes. “Patients of all ages were affected, but they were most obvious in children, whom Kocher again likened to cretins” (Welbourn 32). Kocher named the condition that developed after total thyroidectomy “cachexia struma priva.”<sup>92</sup> These observations documented that the thyroid gland was necessary for normal human function and earned Kocher the epithet “father of thyroid surgery.” For “his work in physiology, pathology, and surgery on the thyroid gland,” in 1909 Kocher “was the first surgeon to receive the Nobel Prize, and the only surgeon at that time ever to win it for purely clinical exploits.”<sup>93</sup>

Johann Mikulicz (Zurich, 1850–1905), an assistant to Theodore Billroth, was aware of the serious complications of total thyroidectomy, including myxedema, nerve injury with loss of voice or difficulty breathing, and hypoparathyroidism with tetany. He therefore proposed leaving the posterior portion of the thyroid gland in the neck bilaterally, thus decreasing the frequency of the above complications. A treatment for hypothyroidism was not known until 1891 when George Murray subcutaneously injected a preparation of sheep thyroid extract in a forty-six year old hypothyroid woman with symptoms of myxedema. She made a remarkable recovery from her symptoms. One year later (1892) Edward Fox (Plymouth, England, 1859–1938) reported that myxedema could be successfully treated by feeding the patient “half a sheep’s thyroid, lightly fried and taken with currant jelly once a



week.”<sup>94</sup> These important observations enabled surgeons to remove the entire thyroid gland since the consequent hypothyroidism could be treated by hormone therapy. Fox’s case was the first medical example of successful organotherapy.

During the early part of the twentieth century in the United States, Charles H. Mayo (1865–1939) and Henry Plummer (1874–1936) at the Mayo Clinic, George Washington Crile (1864–1943) at the Cleveland Clinic, Frank H. Lahey (1880–1953) at the Lahey Clinic, and William S. Halsted (1852–1926) at the Johns Hopkins Medical Center contributed greatly to advances in thyroidology and thyroid surgery. Because surgery on the thyroid gland was now considered to be relatively safe, thyroidectomy became one of the most commonly performed operations, even for relatively small goiters. In 1923 Henry Plummer at the Mayo Clinic introduced iodine preoperatively for patients with Graves’ disease and hyperthyroidism. His documentation of an increased basal metabolic rate in hyperthyroid patients, which decreased after treatment with iodine, established the benefits of the preoperative treatment with iodine for patients with hyperthyroidism. Such treatment made thyroid operations for patients with Graves’ disease considerably safer. George Crile had previously recommended “stealing” the toxic thyroid gland to prevent death from the initiation of “thyroid storm” (the condition of high temperature, rapid heart rate and confusion caused by increased catecholamine response to thyroid hormone during illness or surgery)

precipitated by the stress of surgery.<sup>95</sup> Crile was also the first surgeon to perform radical neck operations for head and neck tumors, including malignant tumors of the thyroid.<sup>96</sup> Lahey did much to educate others about the surgical diseases of the thyroid gland and emphasized the value of identifying the recurrent laryngeal nerves and parathyroid glands to decrease the risk of injury.<sup>97</sup> Because thyroid operations were now considered relatively safe, thyroidectomy became one of the most commonly performed operations.

In “The Operative Story of Goiter” William Halsted states, “the extirpation of the thyroid gland for goiter typifies, perhaps better than any operation, the supreme triumph of the surgeon’s art.”<sup>98</sup> It is an art that continues to be perfected as endocrine surgeons explore new techniques and clinical research to determine the most effective treatment for their patients. During the early twentieth century thyroidectomy was used to treat patients with hyperthyroidism even when their goiters were small. At this time there were no other effective treatments. As thyroidectomy became safer, it also began to be used for cosmetic purposes, that is, removal of the swelling in the central neck (Welbourn 50).

### The goiter grotesque in art

As we saw in the numerous paintings of women with diffuse goiters discussed in **Chapter 1**, the representation of large disfiguring goiters in art reflects the growing interest in realism during the late Renaissance. The sometimes asymmetrical and bulbous goiter created a challenge for artists who attempted to render such abnormalities with accurate anatomical detail. Although the seventeenth century saw a flourishing marriage of science and art, the emphasis on naturalistic detail as a way of representing the “other,” or those outside the boundaries of society, had its origins in a much earlier period. Medieval and early Renaissance representations of disfiguring goiters appear in numerous examples of European folk art, such as wood carvings in churches, manuscript engravings and illustrations intended to instruct or entertain the viewer. Often such figures are caricatures of cretinous dwarfs with bulbous or nodular goiters.<sup>99</sup> The dramatic enlargement of such goiters is disproportionate to the rest of the body. Merke notes that the writings of the thirteenth century encyclopedists such as Thomas de Cantimpré in his *De Monstruosis Hominibus* include miniatures of both men and women with huge, pendulous goiters illustrating the following text:

Further this account tells us/That in some ancient regions/People live in desolate places./Everywhere in the Alps, I believe, /There are women with goiters/Of a strange and curious kind:/For it hangs down to their belly ... /Which is held to be beauty (Merke 136).

In the same period work by other encyclopedists such as Bartholomaeus Anglicus and Jacob van Maerlant includes illuminated manuscripts in which appear primitively drawn caricatures of men with disfiguring goiters. The goitrous figures are holding large clubs known as the “fool’s club”<sup>100</sup> in somewhat belligerent poses. Other manuscripts of the period feature similar curiosities that emphasize the grotesque. In Shakespeare’s *Tempest* the character of Gonzalo refers to men afflicted with large goiters that he compares to the throats of bulls, as if they are a wonder from a world of half-human, half-beast inhabitants. Identifying the goitrous men as mountaineers, Shakespeare reveals the correct assumption that goiters are associated with mountainous terrain, the terrain of endemic goiter:

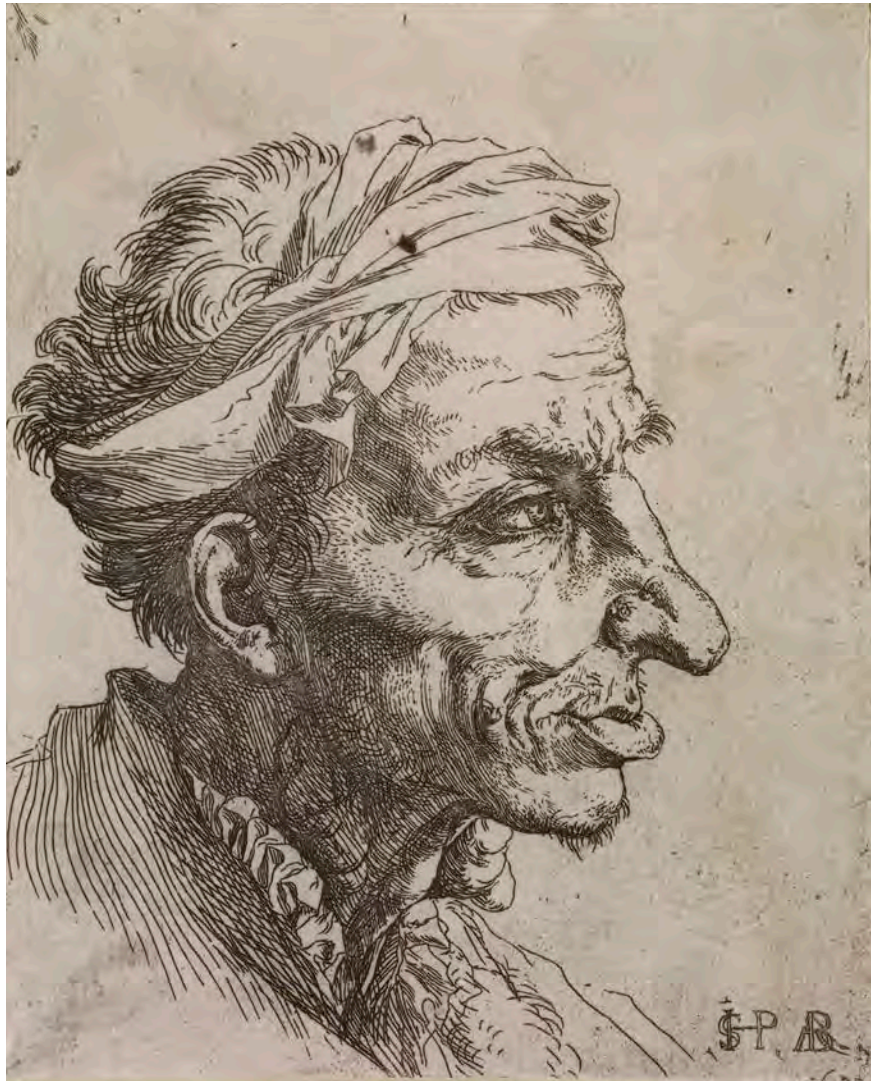Faith, sir, you need not fear. When we were boys, /Who would believe that there were mountaineers/Dew-lapp’d like bulls, whose throats had hanging at ‘em/Wallets of flesh? (*The Tempest*, III.3)<sup>101</sup>

Literature and folk art suggest that the physical signs of endemic goiter were commonly recognized and often the source of humor. In an article on the goiter in art, Italian patholo-

gist Antonio Giampalmo includes an illustration of wooden puppets from the story of Gioppino in Bergamo, Italy, a small city in the foothills of the Italian Alps, a region known for endemic goiter.<sup>102</sup> The puppets were probably carved in the ninth century. All of the puppets have goiters that exaggerate their disproportionately large heads. Examining the traditional view of the disfiguring goiter as a mark of a fool, historian Barry Wind notes that “Aristotle considered those afflicted with goitres to be dull-witted” and that “[l]iterary descriptions ... underscored the association of goiters with fools, a perception corroborated in the medical literature of the period by Paracelsus.”<sup>103</sup> The viewer of such caricatures, which seem intended to shock or even frighten, cannot help making similar associations. Such associations imply a natural tendency toward classification far removed from the boundaries of conventional ideas of beauty suggested by paintings of figures with diffuse goiters.

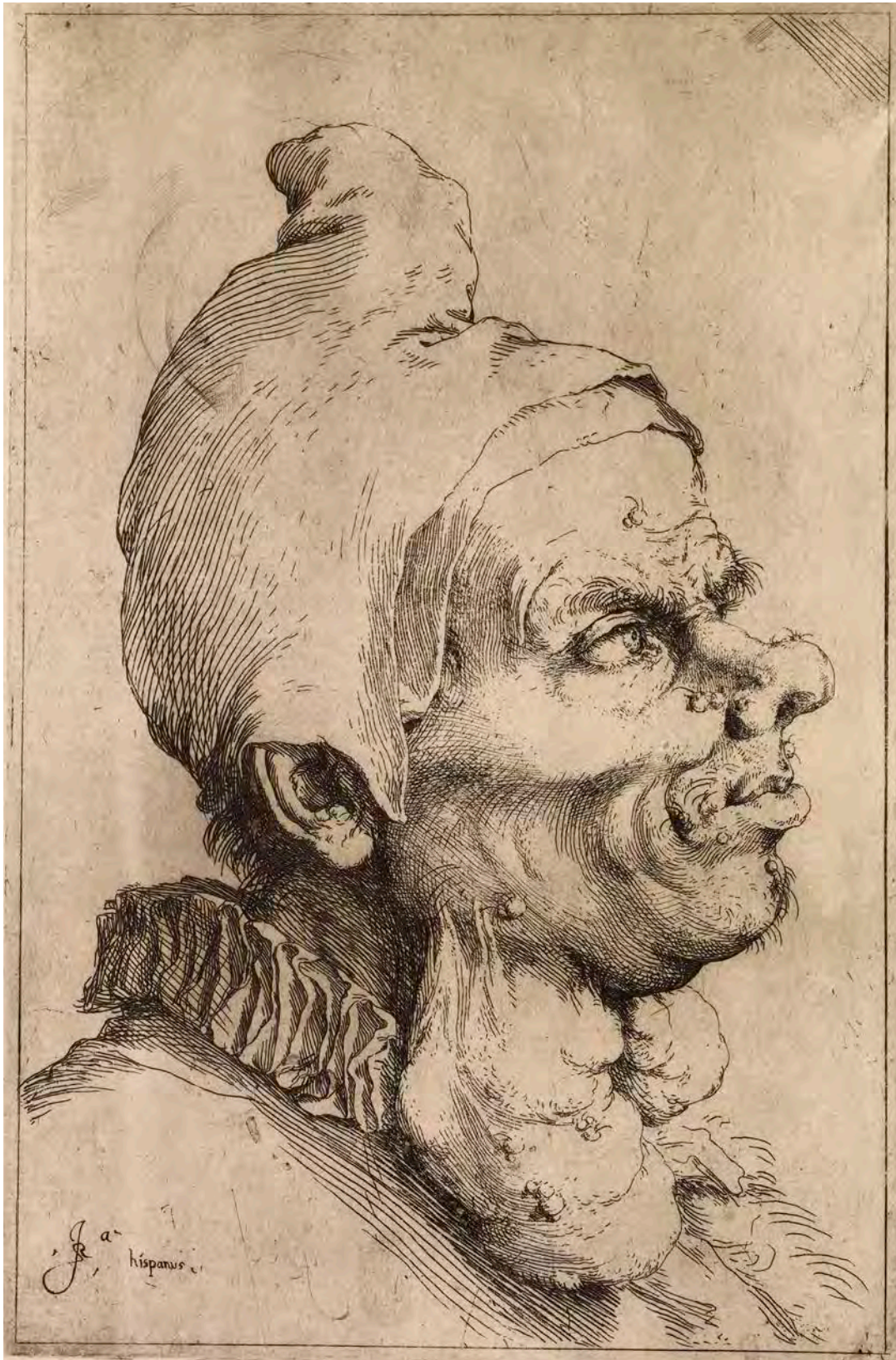The emphasis on naturalism during the Baroque period of the seventeenth century is evident in two of Spanish painter Jusepe de Ribera’s etchings, *The Small Grotesque Head* (**Figure 2-3**, 1622, San Francisco, California, Fine Arts Museums of San Francisco, Achenbach Foundation for Graphic Arts) and *Large Grotesque Head* (**Figure 2-4**, 1622, San Francisco, California, Fine Arts Museums of San Francisco, Mr. and Mrs. Marcus Sopher collection). Both etchings “reflect his fascination with the unusual” and the influence of Leonardo da Vinci and

possibly of Annibale Carracci (Wind 49). Completed almost one hundred years before Ribera's drawings, the drawing by a follower of da Vinci of the *Grotesque Man with Goitre* (Figure 2-5, 16th century, Milan, Italy, Veneranda Biblioteca Ambrosiana) reveals bestial facial features and a large disfiguring goitre. Ribera's *Small Grotesque Head* indicates a left-sided nodular mass protruding from the man's neck, compatible with a nodular goiter, which is possibly malignant. *The Large Grotesque Head* also suggests a large multi-nodular goiter on the right and left sides of the neck, but other small nodules on the figure's face. The more superficial subcutaneous position of the neck masses suggests the possibility of neurofibromatosis or Von Recklinghausen's disease. Although Ribera's etchings were "originally part of a series of instructional anatomical exercises for students," Barry Wind notes that the existence of warts and hairs, along with the "bulbous nose" and the man's Pulcinello collar, similar to "the costume of *commedia dell'arte* clowns" identify the figure in the etching as the "persona" of a *commedia* clown (Wind 53).



**Figure 2-3**

Jusepe de Ribera, *The Small Grotesque Head* (1622, San Francisco, California, Fine Arts Museums of San Francisco, Achenbach Foundation for Graphic Arts)



**Figure 2-4, facing page**

*Large Grotesque Head* (1622, San Francisco, California, Fine Arts Museums of San Francisco, Mr. and Mrs. Marcus Sopher collection)

**Figure 2-5**

A follower of da Vinci, *Grotesque Man with Goitre* (16th century, Milan, Italy, Veneranda Biblioteca Ambrosiana)





**Figure 2-6**

Jean Vespini, polychrome terracotta sculpture (1600, Varallo, Italy, chapel of Salita al Calvario, Sacro Monte di Varallo Sesia)


The figure's multinodular goiter "underscore[s] the connection to folly, stupidity and the *commedia*. This deformity had a long association with the slow-witted and with clownish behaviour" (Wind 53). The remarkable physical and mental abnormalities found in many individuals with hyperthyroidism and hypothyroidism, such as myxedema madness, certainly fascinated many artists.

From the goiter beautiful and its mostly lofty, idealized iconography the pendulum swings to exaggerated naturalism and almost scientific realism in the goiter grotesque. Since disfiguring goiters would have been more noticeable to the naked eye and those afflicted by large goiters had more noticeable symptoms of thyroid dis-

ease, it was more likely for individuals with large goiters than for those with diffuse goiters to attract the attention of physicians and artists. Even so, without an understanding of the function of the thyroid gland until the end of the nineteenth century, physicians often mistook the thyroid gland for other neck masses and made no more specific distinctions than the artists of the same time period.

Closely allied with the representation of fools and clowns with grotesque goiters are paintings that use noticeably goitrous figures to represent anti-social, negative or violent behavior. Giampalmo cites the well known example in a church in the Val Sesia (mountainous region of northern Italy) of Jean Vespini's polychrome terracotta sculpture of a man with a huge pendulous goiter (Figure 2-6, 1600, Varallo, Italy, chapel of Salita al Calvario, Sacro Monte di Varallo Sesia). The figure of the man, whom Merke describes as "a Negroid henchman flailing away with a stick" (Merke 303), is engaged in the flagellation of Christ (Giampalmo 101). His enormous goiter with prominent veins and vacant stare suggests the intellectual deficiency of cretinism.<sup>104</sup> The anger expressed in his eyes and in his aggressive stance with the murderous weapon further implies the demeanor of a negative persona. In a fresco of the *Last Supper* (1400) found in another church in the same region the figure of Judas is depicted with a large goiter as well as a similar expression of antipathy (Giampalmo 101–102). Both examples illustrate the association of disfiguring goiters with brutal or treacherous behavior.

The grotesque goiter's reflection of negative behavior is more ambiguous, however, in some Renaissance paintings with religious themes in which either a grotesquely large goiter or a thyroglossal duct cyst or clinical evidence of hyperthyroidism is visible. Giampalmo cites several examples of figures with grotesque goiters in paintings on the subject of the passion of Christ. For example, he notes that one of the sleeping soldiers in Piero della Francesca's *Resurrection* (Figure 2-7, 1458, Sansepolcro, Italy, Pinacoteca Comunale) is the same model as the one who appears as a patron of the confraternity represented in Piero's *Madonna of the Misericordia* in the same museum (See Figure 1-3 in Chapter 1). Giampalmo posits the theory, popularized by Vasari, that the figure might be a self-portrait of Piero (Giampalmo 100).<sup>105</sup> In Piero's *Resurrection*, therefore, the viewer may read more than was intended in the artist's rendering of the sleeping sentry's probable thyroglossal duct cyst, associating the disfigurement with the guard's negative role as a persecutor of Christ. On the other hand, Piero's use of a figure with such a condition may be the coincidence of a practical choice—the artist using himself as a model.



**Figure 2-7**

Piero della Francesca, *Resurrection* (1458, Sansepolcro, Italy, Pinacoteca Comunale)



**Figure 2-8**

Neroccio di Bartolomeo Landi, *Saint Bernardino Performing an Exorcism*, right panel (late 15th century, Siena, Italy, Palazzo Pubblico)

A similar negative association between the grotesquely enlarged goiter and sin is apparent in paintings of women who are in the process of being exorcised of the devil. Neroccio di Bartolomeo Landi's painting *Saint Bernardino Performing an Exorcism*, right panel (**Figure 2-8**, late 15th century, Siena, Italy, Palazzo Pubblico) illustrates the exorcism of the devil from the mouth of a woman who is apparently affected by seeing the body of the saint (shown in the right quadrant of the painting). As in several Renaissance paintings featuring women with large necks, bulging eyes are sometimes an indication of thyroid disease. The neck's size and the proximity of the neck and mouth suggest

that the painter may be illustrating the common belief of the time that there was a connection between diabolical "possession" and a grotesque goiter.

Representation of the disfigurement caused by thyroid disease is less common in twentieth century art, but two examples serve to illustrate artists' continuing fascination with the anatomy of the enlarged diffuse goiter and its symbolic value. The surrealist effect of a woman's grotesquely enlarged neck being "liberated" of the devil is repeated in the symbolism of the modern surrealist painter Max Ernst's *The Attirement of the Bride* (**Figure 2-9**, 1940, Venice, Italy, Peggy Guggenheim Collection). Behind and to the right of the central "bride" who is robed in brilliant red feathers and resembles a bird of prey, is another female figure, completely nude except for her elaborate headdress of bird-like red feathers. She looks away from

the viewer in an almost contorted pose that reveals a hugely swollen, inflamed, and elongated neck that might be observed in someone with acute thyroiditis (inflammation of the thyroid gland). Ernst scholar David Hopkins identifies the figure as a "sorceress" whose "motif of her headdress or hair lifted by the wind, and the positions of her arms are related to" other witch like figures in Ernst's work.<sup>106</sup> Hopkins traces "the visual precedent for such imagery" to German woodcuts of witches and to the medieval association of an enlarged neck with diabolical possession: "we are consequently made aware that the overall composition of *La toilette de la mariée* (French title for *The Attirement of the Bride*) could be read as a scene of exorcism—the heron/stork on the left corresponding to one of the inquisitors whose job it was to strip suspected witches and examine their bodies for 'witch



marks', and the peculiar detail of the swollen red throat of the sorceress on the right corresponding to the swellings alleged in witches' bodies before the expulsion of demons."<sup>107</sup> The phallic symbolism of the stork-like figure on the left and the hermaphroditic imagery of the homunculus on the right further complicate the meaning of Ernst's sexual symbolism in the painting.<sup>108</sup> Is the enlarged goiter simply a reminder of old religious myths transformed by the twentieth century context of war and genocide, or does it reflect the "significance of alchemy for Ernst ... in its function as an alogical sign system"?<sup>109</sup>

### Figure 2-9

Max Ernst, *The Attirement of the Bride* (1940, Venice, Italy, Peggy Guggenheim Collection)



**Figure 2-10**

Paul Klee, *The Hero with the Wing* (1906, San Francisco, California, Museum of Modern Art, Carl Djerassi Trust I)

German artist Paul Klee's etching *The Hero with the Wing* (Figure 2-10, 1906, San Francisco, California, Museum of Modern Art, Carl Djerassi Trust I) draws the viewer's attention to a large disfiguring goiter in the central neck of a tall heroic looking male figure whose helmet, right sided wing, and unilateral, right gynecomastia (enlarged male breast) suggest a super hero whose powers are incomplete. A comparable mass in the hero's right neck and the mass in his central neck suggest the presence of metastatic thyroid cancer in his cervical nodes. The association of Graves' disease with gynecomastia leads to the speculation that the hero's goiter and enlarged breast are related. Whether Klee purposely included these examples of thyroid disease in order to emphasize the hero's limitations is questionable. We do know, however, that Klee described his hero in his diary:

Perhaps a Don Quixote of ancient times ... The man born only with one wing in contrast with divine creatures, makes incessant efforts to fly. In doing so, he breaks his arm and leg but persists under the banner of his idea. The contrast between his statue like solemn attitude and his already ruined state needs especially to be captured.<sup>110</sup>

The presence of disfiguring disease in the would-be hero's neck further magnifies the "tragicomic" role and "absurd plight" of a man who is not

only powerless to take flight but also further encumbered by his goiter and neck mass, his paralysis "a bleak commentary on the condition of man" (Lanchner 84).

But not all artists' representations of goiter grotesque hint at failed ideas or negative associations. Some paintings with religious themes include figures whose social class as well as a disfiguring goiter might distinguish them from other figures in the painting. In such paintings the disfiguring goiter is often an indica-

tion of low or humble social status such as that associated with manual laborers or peasants. In his fresco series titled *The Life of St. Benedict* in the cloister of the Benedictine monastery of Monte Oliveto Maggiore in Tuscany, the Renaissance artist Il Sodoma (Giovanni Bazzi) (Figures 2-11 and 2-12, 1509, Monte Oliveto Maggiore, Tuscany) painted a number of male peasants with large disfiguring goiters. In the panel *Benedict releases a peasant shackled by the Goths* (Figure 2-11) (see p. 65), the figure of the bound peasant is portrayed with a



large bulbous goiter and pronounced sternocleidomastoid muscles. His upward gaze reveals a skepticism possibly provoked by his disbelief at the miracle he is about to experience. In another panel *Benedict completes the building of twelve monasteries* (Figure 2-12), a robust peasant with a grotesque goiter and musculature similar to that of the peasant in the aforementioned panel is depicted in the act of applying mortar to the masonry supervised by St. Benedict.

---

**Figure 2-12**

Il Sodoma (Giovanni Bazzi), *The Life of St. Benedict: Benedict completes the building of twelve monasteries*, detail (1509, Monte Oliveto Maggiore, Tuscany)

Since it is possible that Il Sodoma used models from the mountainous area of southern Tuscany where the monastery is located, it is interesting to note that the male figures with grotesque goiters in these and in other panels in the series all represent the peasant class whereas the monks in the frescoes do not appear to have such deformities. This distinction leads to the question of whether the artist consciously used anomalous anatomical features to represent class difference, or possibly, in the example of the bound peasant, to emphasize the difference between the saint and the beneficiary of the miracle. One could also conjecture that if Il Sodoma used local peasants as models for the peasant figures, the

coincidence of the peasants having endemic goiter is not surprising. Since monks often moved from one monastery to another, the absence of goiter in these figures may reflect the fact that endemic goiter was less common in persons who moved from place to place and were therefore less likely to be iodine deficient. Benedictine monks were also known to have been selected for their physical strength, a fact that might have eliminated novitiates with swollen necks. More likely, however, is the factor of geography. Since the monastery is located in a mountainous region, Il Sodoma's portrayal of the goiter may be merely an example of faithful rendering of naturalistic detail in local peasants.



Dramatic focus on an unusually large goiter distinguishes some of the more humble figures in a major work by Raphael that features the New Testament narrative of the transfiguration from Matthew 17. In Raphael's large altarpiece of the *Transfiguration* (**Figure 2-13**, 1520, Vatican State, Italy, Pinacoteca, Vatican Museums) a prominent goiter draws the viewer's eye toward the central figure of a young adolescent boy clothed in a bright yellow tunic. The focal point of the painting, the boy is presumably part of a family group of mother, father, and son in the foreground of the painting. The boy being supported by the father figure has a large bulbous goiter, cross eyed gaze or squint, bulging eyes (exophthalmos), and gynecomastia, all features of Graves' disease. The father figure has a distinct stare that could be related to exophthalmos, and both mother and father figures have smoother diffuse goiters than the son. To the contemporary endocrinologist familiar with genetics, the grouping of these three figures might suggest the presence of familial autoimmune thyroid disease. Although the nature of thyroid disease and the incidence of familial disease would have been unknown to Raphael, it is possible that the painter used members of an actual family group as models for the figures in the story from Matthew. As with the work of Piero della Francesca and Il Sodoma, it is possible that Raphael's models lived in a mountainous region of central Italy with endemic goiter. Thus by coincidence Raphael might have represented the physical manifestations and the familial associations of thyroid disease.

The subject of Raphael's painting is the miraculous cure of the lunatic child, who also happens to have physical signs of a disease associated with behavioral manifestations such as temporary psychological disorders. In the story from Matthew 17, Christ "was transfigured" before disciples Peter, James, and John on a mountain. After he appears to his disciples, they come to a large crowd of people where he encounters "a certain man, kneeling down to him, and saying Lord, have mercy on my son: for he is lunatick [sic], and sore vexed: for oftimes he falleth into the fire, and oft into the water. And I brought him to thy disciples, and they could not cure him" (Matthew 17:14-15). Jesus then asks the father to bring the child to him, "And Jesus rebuked the devil; and he departed out of him: and the child was cured from that very hour" (Matthew 17:18). Like the woman being exorcized in Landi's painting (**Figure 2-8**), the child has his "lunacy" exorcized by a religious miracle. Both figures also have prominent, symptomatic goiters that are linked to temporary mania.

**Figure 2-13, facing page**

Raphael, *Transfiguration* (1520, Vatican State, Italy, Pinacoteca, Vatican Museums)



Without knowing the etiology or clinical and psychological manifestations of hyperthyroidism or Graves' disease, Raphael might have seen physical signs of the disease in the model he used for the central figure of the boy. Raphael renders the physical manifestations of thyroid disease—bulging eyes, squint, large goiter, and gynecomastia—with anatomical accuracy. The constellation of a number of physical signs of disease might explain the prominent position of the boy in the painting and the flailing gestures of him and others in the crowd who point toward him or toward the transfigured Christ. Since Raphael has compressed two parts of the narrative in Matthew 17 into one painting and has placed the boy in the center foreground, the artist may be suggesting the boy's symbolic role as a demonstration of the power of faith, the subject of Christ's admonition to his disciples in Matthew 17:20. If one accepts this interpretation of the painting, one must conclude that the viewer is therefore meant to associate the boy with the dramatic revelation of the transfigured Christ. That the boy's goiter verges on the grotesque and that he also looks mentally disturbed further distinguishes him from the adult figures in the painting and dramatically singles him out as a "lunatic" singularly blessed and cured.

Raphael's *Transfiguration* is the subject of an essay written in 1888 by two French psychiatrists, J. M. Charcot and Paul Richer, on the depiction of psychological illness in art.<sup>111</sup> In the chapters titled "Le Jeune Possédé," the authors include an analysis of the representation of "lunacy" as it

pertains to the figure of the "cured" boy in Raphael's *Transfiguration*. Interestingly, Charcot and Richer do not acknowledge the presence of the boy's obvious goiter and other signs of Graves' disease but instead posit another diagnosis of the boy's condition: epilepsy or hysteria. They question whether Raphael intentionally exaggerated the physical manifestations of a "possessed" state of epilepsy or hysteria (Charcot and Richer 28) in order to idealize the young hero of the biblical story in a more conventional manner than was characteristic of the artist's usual realism.<sup>112</sup> Although the diagnosis of Graves' disease and its psychological effect on behavior was described in the 1830's, the information was not widely known and was therefore probably not a factor in Charcot and Richer's "diagnosis" of Raphael's figure of the boy.

But to a contemporary physician aware of the connection between severe Graves' disease and temporary mental instability, a symptom that existed in Raphael's time and still persists in undiagnosed individuals with Graves' disease, a more accurate "diagnosis" is available. In representing the story of a lunatic who was miraculously cured, Raphael may have found a model who, though suffering from hysteria caused or aggravated by a severe thyroid disorder, also demonstrated periods of remission from the ailment. (In some uncommon cases, even the physical manifestations of Graves' disease as well as its psychological effects may spontaneously disappear.) In addition to inadvertently documenting the connection between aberrant

psychological behavior and a severely enlarged goiter, or "goiter grotesque," Raphael may have observed the model's bulging eyes also associated with such behavior and disfigurement. The fact that he repeated the features of bulging eyes and swollen neck (though less disfiguring) in the father figure who supports the boy and that he painted the mother figure's neck with a diffuse goiter suggests that Raphael may have seen examples of familial hyperthyroidism or familial goiter in Renaissance Italy. Even though precise scientific knowledge of the disease would not have been available to the artist, the accuracy of anatomical details illustrates Raphael's skill in rendering the pathology of disease. Here is an example in which the artist's eye is more acutely observant than that of the physicians of his time, or even, perhaps, of physicians like Charcot and Richer in the late nineteenth century.

A similar example of the accuracy of the artist's eye in detecting thyroid pathology is evident in Caravaggio's painting of *The Crucifixion of St. Andrew* (Figure 2-14, 1607, Cleveland, Ohio, Cleveland Art Museum) in which an old peasant woman in the lower left corner of the painting gazes up at the crucified saint. The woman has a pronounced goiter. According to Irish physician J. Barry Ferriss, "iodine

---

**Figure 2-14, facing page**

Caravaggio, *The Crucifixion of St. Andrew* (1607, Cleveland, Ohio, Cleveland Art Museum)





**Figure 2-15**

Jan Sanders van Hemessen, *The Prodigal Son* (1536, Brussels, Belgium, Musée des Beaux-Arts de Belgique)

deficiency was common among the poor around Naples, where the picture was painted; art historians believe that the old woman's goiter was used to indicate her humble origins."<sup>113</sup> Ferris also notes that the old woman's "goiter is rounded rather than multinodular," and that "there are two discrete swellings on the right side" of her neck, indicating "enlarged lymph nodes, raising the possibility that the picture is an unwitting illustra-

tion of metastatic thyroid carcinoma" (Ferris 518). We know that there are several paintings by Caravaggio of young women with diffuse goiters as well as other paintings that seem to have used the same or similar elderly female peasant figure as a model. The grotesque goiter represented in *The Crucifixion of St. Andrew* is therefore consistent with Caravaggio's adherence to naturalistic detail and practice of using local peasants as models.<sup>114</sup>

Naturalistic details are also evident in northern European paintings that reflect the influence of Italian Baroque artists. Dutch and Flemish genre paintings from the sixteenth and seven-

teenth centuries display anatomical realism as a way of defining character traits in the morally didactic works of the period. The genre paintings depict homely domestic narratives as well as bawdy tavern and brothel scenes, often with implied moral symbolism or allegorical content. In such scenes physical deformities are quite common and often exaggerated or accentuated by the artist's use of light and composition, especially the foreshortening of figures in the foreground, and thus, distortion of size and proportion. The setting in a genre painting also calls attention to the physical deformities of the human figures because the figures are often contained within a small



domestic space similar to a theater's stage set. In addition to the use of setting to frame the narrative, whether it is the interior of a public house, a tavern or a home as an enclosure for women of questionable morality, several paintings in this category portray women in the act of frolicking with men. Frequently, the women have voluminous breasts and large diffuse, and sometimes disfiguring, goiters. Both seem to be associated with aggressive sexuality and illicit behavior.

In the biblical painting of *The Prodigal Son* (Figure 2-15, 1536, Brussels, Belgium, Musée Royaux des Beaux-Arts de Belgique), Dutch genre painter Jan Sanders van Hemessen depicts a bordello scene that alludes to the theme of debauchery in Luke 15: 11–32 in which the notorious young son, after inheriting money from his father “wasted his substance with riotous living.” In the foreground of the painting a peasant woman with coarse features and a large nodular goiter seems to be encouraging the coupling of the young woman and man on the left while in the background a younger woman, who has a large diffuse goiter and leans seductively to her right, seems to be courting the man sitting next to her. The goiter is a noticeable feature of both procuress and prostitute.

---

**Figure 2-16**

Jacob Duck, *The Sleeping Woman* (mid 17th century, Rotterdam, Holland, Kunsthalle)

The use of caricature and realism in sixteenth century paintings to depict the world of the bordello and the physical abnormalities associated with it is replaced by a more ambiguous realism in paintings by seventeenth century Dutch artists. Art historian Wayne Frantis notes the evolution in style that reflects “widespread changes in taste after 1650” when “comic themes also shifted from their traditional focus upon the peasantry and related low-life types toward persons and situations drawn from a higher social milieu” (Frantis 206). The influence of Rubens and

Caravaggio is apparent in the paintings of Dutch artists such as Jan Steen, Jacob Duck, and others who studied in Italy or worked in Utrecht, Holland where “strong Catholic traditions” made “Caravaggio’s realism and ‘lay Christianity’” appealing (Janson 581). It is a realism that juxtaposes symbols of prosperity with frank narratives of debauchery and licentiousness. In seventeenth century Dutch genre paintings, the procuresses and the prostitutes are clothed in more aristocratic clothing than their counterparts in works of the previous century, and the homely, sometimes grotesque,



faces of female peasants are replaced with those of more attractively groomed middle class women. Steen's *The Dissolute Household* (1661–64, London, Wellington Museum), for example, juxtaposes a maternal figure “in an alcoholic stupor ... while her husband cavorts with a busty strumpet” (Frantis 207). The strumpet, elegantly clothed in velvet and furs, is noticeable for her large, though not especially disfiguring, goiter.

Beneath the appearance of respectability, however, the painter's satirical tools expose a cutting, ironic tone. The large goiter, if shown at all, seems to be associated with sensuality rather than with a physical abnormality and almost looks like a third breast. For example, Jacob Duck's *The Sleeping Woman* (Figure 2-16, mid 17th century, Rotterdam, Holland, Kunsthalle) portrays a woman who seems to be asleep and possibly drunk. Framed by an erotically charged interior of red velvet, the woman is sitting with her head thrust back, a position that accentuates her large goiter. An empty glass in her disproportionately dainty hand implies her drunken state and the familiar relationship of drinking, gambling, and prostitution. The artist's focus on the woman's large neck with its pronounced nodular goiter seems in keeping with intimations of her low character and drunken state, thus associating the disfiguring goiter, as well, with her licentious behavior. In the evolution of European social history as it is reflected in art, the artist's rendition of the large or grotesque goiter as a reference to the lower classes, to immoral or disrespectful behavior or

to those on the margin of society now includes examples from the middle class. Duck's painting also blurs the line between the association of the diffuse goiter with romantic sensuality that we saw in some of the paintings discussed in **Chapter 1** and with the more frank display of debauchery demonstrated here.

The use of realism and caricature evident in northern European genre paintings was adopted by English artists whose work was made more accessible to the middle classes through publication in the popular press or through prints based on their paintings. In the eighteenth and nineteenth centuries, William Hogarth, Thomas Rowlandson, James Gillray, and George Cruikshank exploit the viewer's tendency to associate medical abnormalities of all kinds with behavior that was commonly termed “freakery.”<sup>115</sup> Graphic distortions of conditions such as goiter, cretinism, and dwarfism (see **Chapter 3**), gigantism and acromegaly (see **Chapter 4**), exophthalmos and gout (see **Chapter 5**) are useful tools for satire.

Among the English caricaturists of the late eighteenth century, James Gillray was known for his “savage” political satire.<sup>116</sup> Gillray often used medical abnormalities as metaphors for the disease of state, or corruption in politics. Among the most famous of Gillray's works is *The Monstrous Craws at a New Coalition Feast* (Figure 2-17, 1787, London, British Museum), a hand-colored etching with aquatint whose subject is, according to art historian Richard Godfrey, “the

greed and miserliness of the King and Queen, and the perpetual need for funds of the Prince of Wales.”<sup>117</sup> The boldly colored print features the three royal figures of Queen Charlotte, the Prince of Wales (later George IV), and King George III (dressed as a woman) seated around a bowl of gold coins from which each ladles large quantities of coins into his or her mouth. All three figures have large pendulous goiters (the “craws” shaped like sacks of money) hanging from their necks. Those of the King and Queen hang with such weight that the “craws” or goiters touch the bowl of coins and clearly dominate the scene. Gillray's caricature uses the grotesquely enlarged goiter to deliver his criticism of the gluttony and greed of the monarchy. Queen Charlotte's bulging eyes not only suggest exophthalmos, which along with the enlarged goiter may indicate a further manifestation of Graves' disease, but also dramatize the extremity of her avarice and willingness to sacrifice public funds for the sake of her son.<sup>118</sup> The Prince of Wales's fool's cap and “symbolically empty” craw in contrast to the King's and Queen's full craws, and the feminine dress of the King imply weakness associated with feminine traits, thus emasculating the power of king and heir and implying the manipulative tendencies of Charlotte.<sup>119</sup>

From anatomical realism to caricature, allegory and political satire, the enlarged goiter is a prominent feature in art that draws attention to human disfigurement and the singular identity, vulnerability, humbleness or notoriety associated with it. A

disfiguring goiter might identify an individual as “the other,” someone who stands out in a crowd, whether his or her distinction is negative or positive. Unlike Botticelli’s idealized, sylph-like female subjects with diffuse goiters that complement their graceful figures and young, innocent faces, the female subjects of paintings that expose disfiguring goiters are often depicted in compromising settings that suggest moral failure. Male subjects with disfiguring goiters or thyroglossal duct cysts represent a greater variety of social status and moral character. Perhaps the discrepancy is a reminder

of a double standard between the sexes in the association of physical beauty with feminine virtue and disfigurement with masculine ruggedness. Only Gillray’s caricature places equal emphasis on the culpability of both sexes when he depicts the grotesque goiter as a symbol of greed in high places.

#### Figure 2-17

James Gillray, *The Monstrous Craws at a New Coalition Feast* (1787, London, British Museum)





## Chapter 3

## Little People: Fascination or Exploitation?

### Introduction

Renaissance and Baroque paintings of people with large disfiguring goiters or the enlarged facial features and shortened limbs of cretins must have appealed to collectors who were curious about deformity or found humor in art that called attention to physical abnormalities. For others such depictions of disfigurement might have served as a warning against sin. The association of physical deformity with both the comic and the sinister is also apparent in paintings of little people or dwarfs from the sixteenth and seventeenth centuries. The range of attitudes

toward the condition of dwarfism encompasses an even greater spectrum when one compares the implied mockery in Jusepe de Ribera's painting of *The Dwarf and a Dog* (1643) with a less derisive presentation of a dwarf in Diego de Velasquez's portrait of *Calabazas* (1638, Madrid, Prado), which many critics find sympathetic to the plight of the dwarf (Wind 67).<sup>120</sup> The Ribera painting uses foreshortening to emphasize the comparative size of the dwarf next to a large dog whose head is the height of the dwarf's chest. The dog's chain, which the dwarf holds, is a reminder of the dwarf's status similar to that of the dog: both are someone else's property to be kept chained and controlled. The

frontal pose of the Calabazas portrait and the absence of a canine or human figure for comparison suggest an attempt to present the dwarf with more dignity than one can find in Ribera's work.

Nonetheless, as Wind and others note, an attitude of sympathy toward dwarfs did not prevail in the Spanish court of Velasquez's time.

Throughout the seventeenth and eighteenth centuries the noticeable contrast in size between a dwarf and an average European citizen set little people apart from humanity as a curiosity or as a source of entertainment and a subject for derision. Court painters and other artists who catered to the tastes of their patrons, especially in Spain and northern Italy, represented dwarfs in both narrative and portrait paintings. Many of these paintings provide insight into attitudes among the aristocracy of those regions. The use of deformity as a source of entertainment continued into the early twentieth century when little people were displayed in freak shows and circuses on a level similar to that of performing animals. Although a more humane attitude toward little people is apparent in late nineteenth century portraits, unfortunately the stigma of size continues to marginalize little people in contemporary society.

#### Figure 3-9, facing page

Jan Molenaer, *Stone-throwing Dwarf* also known as *Scene with Dwarfs* (1646, Eindhoven, Netherlands, Van Abbemuseum) (see p. 106)

---

### Types of dwarfism; pituitary dysfunction and other etiologies

---

There are more than one hundred types of dwarfs or little people, and one dwarf is born in every 10,000 births.<sup>121</sup> A dwarf or little person is usually less than four feet in height, and most dwarfs are born to parents of normal size. In the United States newborn babies weighing less than 2,500 grams at term are considered “small for gestational age,” but not all unusually small babies are considered dwarfs.<sup>122</sup> The causes of dwarfism are both endocrine and non-endocrine.

Short stature is usually marked in individuals with endocrine, primordial or gonadal dysfunction or from an unknown or idiopathic cause. Growth retardation in individuals with illnesses and familial growth retardation, however, are usually less severe. Among the endocrine causes of short stature, abnormalities originate from inadequate secretions of growth hormone, thyroid hormone, and androgen or estrogen.<sup>123</sup> Non-endocrine causes include genetic or constitutional origins of short stature; growth hormone receptor dysfunction (Laron’s dwarfs); post growth hormone receptor defects in insulin-like growth factor known as IGF, a condition found in pygmies; inadequate nutrition; illnesses or conditions such as chronic renal failure; excess intake or production of corticosteroids and chemotherapy (Styne 180).

In the human fetus growth hormone is present in high concentrations, whereas growth hormone receptors are more limited in number. Growth hormone is secreted by the pituitary gland in a pulsatile manner. It functions by binding to the insulin-like growth factors and their binding proteins. Growth hormone will not increase growth rate without adequate nutrition and normal thyroid function. In cases of malnutrition growth hormone levels increase whereas insulin-like growth factor levels decrease. With advancing age, growth hormone and some insulin-like growth factor levels in the blood decrease.

Other hormones such as thyroid hormone are also important for normal growth and development. Children born with congenital hypothyroidism are of normal length at birth, but if left untreated, they will develop cretinism characterized by severe mental retardation and delayed growth, especially of the arms and legs.<sup>124</sup> Gonadal and adrenal steroids are also essential for normal growth and are of major importance during prepubertal growth and development of secondary sexual features. With the augmentation of insulin like growth factor (IGF-I) production, increased sex steroids result in increased bone growth but also cause premature epiphysial fusion and, consequently, short adult stature. Excess glucocorticoids, whether of endogenous or exogenous nature, also quickly result in growth retardation.

Among the non-endocrine causes of dwarfism, poor maternal nutrition is the most important condition leading to low birth weight and length. Maternal height correlates better than paternal height with fetal size, but eventually there is a positive correlation between the average of the two parents’ heights and the height of the child (Styne 184). Smoking, alcoholism, chronic illness and uterine abnormalities in the pregnant mother can also result in poor fetal growth (Styne 173).

Other types of dwarfism affected by growth hormone receptor defects but not influenced by the pituitary gland include pygmies and individuals with Laron’s dwarfism (Styne 180). Infants with reduced or absent growth hormone receptors, such as those that occur in Laron’s dwarfism, are small at birth, have elevated growth hormone and low serum insulin-like growth factor (IGF-I) (Styne 180). The short stature of African pygmies is caused by post-growth hormone receptor abnormalities. Pygmies have normal growth hormone levels but low insulin-like growth factor (IGF-I) and normal insulin-like growth factor (IGF-II) concentrations. They also have a normal body habitus or proportions. Pituitary dwarfs somewhat resemble African pygmies in their size and skeletal proportions. They differ from pygmies in their lack of truncal obesity and in the presence of micro phalluses and wrinkled skin. Pygmies are unresponsive to growth hormone administration, and despite low IGF-I levels, they have normal serum IGF-I activity.<sup>125</sup>

Unlike the normal body habitus of the pygmies, an abnormal body habitus is found in achondroplastic dwarfs, who have normal or enlarged heads and trunks but short arms and legs. Cretins, that is, dwarfs with congenital hypothyroidism are characterized by short stature and disproportionately short extremities, mental retardation, thick tongue, deafness, protuberant abdomen, and a broad flat nose. Other causes of short stature include mongolism, elephant man syndrome or neurofibromatosis, Turner's syndrome or female chromosomal defects, Noonan's syndrome or male chromosomal defects, and other disorders.<sup>126</sup>

Insulin-like growth factors known as IGF's are important for growth and are regulated by growth hormone as well as metabolic factors other than growth hormone. Insulin-like growth factor binding proteins are also required for normal growth and development. A recent study by N.B. Sutter et al documents the importance of IGF as a single allele on Chromosome 15 responsible for the small size of canine breeds:<sup>127</sup> "A single IGF-1 single-nucleotide polymorphism haplotype is common to all small breeds and nearly absent from giant breeds, suggesting that the same causal sequence variant is a major contributor to body size in all small dogs" (Sutter et al 112). The IGF defect in small dogs is similar to that in pygmies. The variation in the size of humans, however, is significantly smaller in range than that of dogs (the latter ranging in weight from two pounds to over 200 pounds).

Some children with severe short stature and high levels of growth hormone have growth hormone receptor abnormalities and growth hormone insensitivity. Many of these children have defects in the growth hormone receptor or growth hormone response pathway. They have a growth response to treatment with insulin like growth factor. In the United States today, a significant number of short children are being treated with recombinant growth hormone to help make them grow.

Chernausek, *et al*, recently reported the long term effects of treatment of 76 small children with growth hormone resistance.<sup>128, 129</sup> Thirty-nine of these children had growth hormone receptor defects. Twenty-three had a defined molecular defect of the growth hormone receptor, and five had absence of growth hormone binding proteins, suggesting a defect in the growth hormone receptor or its intracellular signaling pathway. Nine others had neutralizing levels of growth hormone antibodies and consequently were relatively growth hormone deficient. Growth hormone resistance in the children was defined as failure to increase serum IGF levels after four injections of human growth hormone (0.1 mg/kg) (Levitsky 813). In response to treatment with growth hormone most short children initially had a growth spurt during the first year, but subsequent growth rate only approximated the normal growth rate. Catch-up was lower than observed when growth hormone was administered to growth hormone deficient children. Such treatment,

however, resulted in adverse effects in many children such as coarsening of facial features, hypoglycemia, and minor changes in blood lipid levels (Chernausek et al 905-906).

**Figure 3-18**

*Bertholde, a dwarf* (Engraving by A. Walker. Courtesy of the Wellcome Trust) (see p. 116)



The variation in the life expectancy of little people depends on the cause of the dwarf's short stature. For many little people the life expectancy is normal, but persons with short stature secondary to illness and hypopituitarism have a decreased life expectancy. Dasen states, "the life span of short statured persons is generally reduced in comparison to that of normal sized individuals because of their greater vulnerability to infections, diseases, and accidents" (Dasen 8). Controversial recent studies document that female individuals of four to twenty years who have growth hormone deficiency have a shortened lifespan.<sup>130</sup> Males of all ages and women over twenty years of age with growth hormone deficiency appear to have a normal life span. The sexual function of dwarfs also depends on the causes of short stature and is usually normal. Short stature caused by illness or hypopituitarism, however, results in decreased sexual activity and, in the latter case, small genitalia.

---

### History of diagnosis and treatment of dwarfism

---

Observations of dwarfism have been recorded in writing and art since antiquity. These records reveal that attitudes toward little people range from acceptance to curiosity, fear, and rejection. Aristotle described the Pygmies as "a race of men of small stature" (Medvei 75). The emperor "Augustus, according to [the Roman historian] Suetonius, despised dwarfs and other malformed creatures ... [believing] that the misshapen were augurs of the malign" (Wind 8). Wind notes that the Roman Pliny and the fifth century religious scholar St. Augustine expressed curiosity toward little people, seeing dwarfs "and other *terata* as a manifestation of variety, acknowledging that deviations from the norm occurred in humanity" (Wind 8). The Hebrews considered dwarfs to be "misfits" and denied them "access to the temple" (Medvei 36). During the Middle Ages when physical or mental abnormalities were considered "creations of the devil," the thirteenth century "Pope Gregory IX denied higher orders to any candidate disfigured by a blemish or deformity" (Wind 9). Thirteenth century medieval scholar Albertus Magnus in *De Animalibus* "considered pygmies as imperfect and sub-human ... shameless ... and dishonest" and therefore "not to be considered human" (Wind 9). Wind also notes the ironic view of the thirteenth century Franciscan monk Alexander of Hales, who not only regarded deformities such as dwarfism as the "consequence of sin" but also believed that the

existence of individuals with deformities "heightened the idea of beauty and perfection" in those who were spared such problems (Wind 9). His view, shared by others in the Middle Ages, uses the illogical circular argument that deformity exists to provide a contrast to perfection and that perfection therefore requires the existence of its opposite or imperfection.

In the late Renaissance the negative religious association of dwarfs with sin and the devil changed to a more secular view of dwarfs as curiosities designed for the entertainment of the wealthy. As quoted in evolutionary biologist Armand Marie Leroi's *Mutants*, "the French scholar Isidore Geoffroy Saint-Hilaire states, "it was necessary to dream up amusements of a special sort for the leisure of princes and it was to dwarfs that fell the sad privilege of serving as the toys of the world's grandees."<sup>131</sup> Leroi notes, however, that the tradition began in the sixteenth century, possibly by "Catherine de Medici (1519–1589) ... [who with] the hope of breeding a race of miniature humans ... [purposely] arranged a marriage between a pair of dwarfs." (Leroi 170). Religious skepticism also prevailed even among medical scientists in the more enlightened ages. To the French sixteenth century surgeon Ambrose Paré, "[m]aimed persons include the ... humpbacked, ... [those having] arms too short, or the nose too sunken" and "any other thing that is against Nature" were "[m]onsters or things that appear outside the course of Nature."<sup>132</sup> The association of dwarfs with humpbacked people (*gobbi* in Italian) was made popular in prints and



engravings of the seventeenth and eighteenth century and by the *commedia dell'arte* that featured such physically deformed characters as Pulcinello.

As with general attitudes toward all manifestations of endocrine abnormalities, religious beliefs, mythology, and speculation eclipsed medical knowledge, which was, at best, incomplete if not inaccurate. Medical scientists did not recognize the function of the pituitary gland until the end of the nineteenth century or the beginning of the twentieth century, therefore remaining unaware of a major cause of dwarfism.

Because of its significant control of other endocrine glands, the pituitary gland has been referred to as the “conductor of the orchestra” (Medvei 4). Early ideas about the gland’s function date from Galen (129–201 CE), who thought that the secretions of the pituitary gland “discharged into the nasal cavities” (Medvei 138). Medvei quotes the French physician Theophile de Bordeu (1722–1776), who wrote that “Galen honored it [the pituitary] by calling it ‘the gland’ above all.... The Ancients believed that the pituitary existed for the retention of the animal spirits; it served, they said, as a plug to the funnel, and without it, all the spirits contained in the ventricles would easily disperse” (Medvei 151). One might wonder whether Galen’s theory about the function of the pituitary and its role in discharging brain secretions originated from his observation of soldiers who had cerebrospinal fluid leaking from their noses after head injuries.

Other strange theories persisted throughout the sixteenth and seventeenth centuries. In 1543 Vesalius was the first to describe the pituitary gland “as a separate entity” (Medvei 65). According to Thomas Wharton, Swiss professor of anatomy and medicine Caspar Bauhin (1550–1624) also believed in Galen’s theory that the pituitary served to “drain out the moisture of the brain,” and in Vesalius’s theory that “the waste material excreted by the brain (a glandular organ) passes through the *infundibulum* into the pituitary and then into the nasopharynx” (Medvei 131). This hypothesis promoted the use of “sneezing powders ‘to purge the brain’” (Medvei 131).

In 1660, however, physiologists Conrad Victor Schneider (1614–1680) of Wittenberg, Germany and Richard Lower, of Cornwall, England (1631–1691) rejected the generally accepted Galenic idea about the function of the pituitary and the belief “that the nasal secretions originate in the pituitary body (1672).”<sup>133</sup> This new information, which localized catarrh in the air-passages rather than in the brain or in the pituitary gland, helped do away with dependence on “endless recipes for ‘purging the brain’” (Garrison note 2, 268). Five years later, in his *Liber primus de catarrhis* (Wittenberg 1660) Schneider reported that although “only the macerated ethmoid bone displays pores,” these pores do not serve as a filter but are occupied by vessels and there is no “cavity or any liquid” in the pituitary gland (Medvei 138).

Thomas Gibson (1647–1722), a physician educated at Cambridge and Leiden, thought that the pituitary secreted “cerebro-spinal fluid, as believed also by Sylvius and Raymond Vieussens (1641–1715) of Montpellier” (Medvei 140). The latter’s book *Neurographia universalis* was “perhaps the best illustrated work of the 17th century on the configuration of the brain, spinal cord, and nervous system” (Medvei 140). British physician Thomas Willis (1621–75) thought that the pituitary was a receptive organ. According to medical historian Hans Sinner, “When [Willis] injected ink into a carotid artery, part of the ink appeared in the pituitary tissue,” thus documenting the existence of uptake by the gland and rejecting the “conception of an internal secretion” (Medvei 139). Because little evidence supporting the function of the pituitary gland was available, until the twentieth century the pituitary gland was “regarded as little more than a vestigial relic” (Medvei 304).

In 1724 Venetian anatomist Giovanni D. Santorini (1681–1737) inaccurately described the anterior pituitary, which he called “glandula ptui-potior,” and the posterior pituitary, which he named the “neuro-hypophysis, the pars nervosa, the infundibular body” (Medvei 303, ref. 56). In 1888 the German surgeon N. Rogowitsch noted that the pituitary glands became enlarged and hyperplastic after he removed thyroids from rabbits (Sawin 179). Rogowitsch incorrectly hypothesized that the pituitary took over the function of the thyroid. In 1898

German pathologist L. Comte noted that the size of the pituitary gland increased in females during pregnancy and in males after castration (Medvei 304). Unfortunately these observations were not appreciated and had no real impact on the scientific thinking of the day (Sawin 179). Ignorance about the true function of the pituitary gland persisted through the late nineteenth century. In 1889 and 1895 in his famous textbook of physiology British physiologist Michael Foster (1836–1907) stated, “concerning ... the purposes of the organ (the pituitary gland) ... we know absolutely nothing” (Sawin 179).

Several experiments in the late nineteenth and early twentieth centuries documented that the pituitary gland is necessary for life. Early experiments relating to partial removal of the pituitary gland, known as hypophysectomy, were difficult to interpret because the operation itself resulted in a high mortality rate. Medvei reports that in 1886 Sir Victor Horsley successfully removed the pituitary from two dogs (Medvei 315). Surprisingly, the dogs survived. In 1907 the Romanian physiologist Nicolas C. Paulesco (1869–1931), reported the work of a colleague with whom he collaborated in experiments on the pituitary gland in dogs: his colleague, the surgeon Balacesco, removed the pituitary gland from 22 dogs and 12 cats. All of the dogs in these experiments died within three days of the operation. “Separating the pituitary stalk produced the same result,” and

“[r]emoval of the posterior lobe only had negative results” such as diabetes insipidus (Medvei 315).

Swiss German surgeon Bernard Aschner (1883–1960) improved the technique of hypophysectomy by using a “trans buccal approach” that caused less disruption to the brain; he documented “genital hypoplasia” (decreased number of cells) and, from “X-ray studies the cessation of growth of the long bones” in dogs after hypophysectomy (Medvei 316). His findings showed that partial hypophysectomy also resulted in atrophy of the adrenal cortex and atrophy of the thyroid, supporting the concept that the pituitary is the “conductor” of the other endocrine glands. (Medvei 319 and 323, ref. 114).

In 1910 the findings of experiments on over 100 dogs were presented by the American neurosurgeon Harvey Cushing (1869–1939) in collaboration with James Crowe at the American Association for the Advancement of Science. Their findings confirmed Paulesco’s previous observations regarding the essential function of the pituitary gland for life. In 1914–18 German pathologist Morris Simmonds (1855–1925) described pituitary dwarfism resulting from anterior pituitary lobe deficiency (Garrison 695–696). Cushing and his associates also observed that growth slowed or stopped and “sexual infantilism remained” in young dogs subjected to partial removal of their pituitary glands (Medvei 316).

Cushing initially thought that the pituitary functioned like the thyroid, secreting one or two hormones essential for growth and sexual development. He believed the pituitary gland was important for many functions, including normal sexual activity and sleep. He eventually changed his mind, however, because pituitary extracts failed to work effectively and several of his experiments initially failed to confirm his hypotheses. Eventually, Cushing became critical about the peddling of endocrine extracts and other hormonal concoctions (used for organotherapy). He subsequently described this practice as “endo-criminology.”<sup>134</sup>

### Little people in mythology, art, and history

Although negative or derisive images of dwarfs were represented in antiquity as well as in the late Renaissance and Baroque periods in Europe, ancient Egyptian and Greek dwarf figures on painted pottery or in the form of small sculptures or amulets often appear in a positive light. Dasen notes that in Egypt from the period of “the New Kingdom on and probably also earlier, [dwarfs] emerge as popular deities, best known in their forms of Bes and Ptah-Pataikoi, who are invoked in a host of magical practices to protect the living and the dead” (Dasen 46). Numerous versions of the dwarf God Bes are visible in the antiquities collections of major museums, including the Metropolitan Museum of Art, the Louvre, the Vatican, and the British Museum. In the catalogue of a 2005 Metropolitan Museum exhibit titled *The Art of Medicine in Egypt*, five variations on the dwarf god Bes illustrate Bes’s diverse functions as protector of women (especially women in childbirth) and children;<sup>135</sup> as musician, “perhaps because of the songs mothers have always sung to their children”; as protector against dangerous and evil forces; and as protector against disease.<sup>136</sup> Usually wearing “an animal pelt” (Allen 23) and depicted with a “large, frontal, mask-like face” (Dasen 60) sometimes representing a lion, “Bes has a grotesque, malformed, and mostly naked body” that, with its disproportionately short limbs, is clearly that of an achondroplastic dwarf (Dasen 60). On a plaque from the Ptolemaic-Early Roman Period, the *Stela of the God Bes* (Figure 3-1, c. 304



BCE–364 CE, New York, Metropolitan Museum), Bes “is shown grasping a serpent, demonstrating his control over the inimical elements of the Egyptian world, and brandishing a sword, warding off danger from unseen and malevolent forces” (Allen 23). Dasen notes that such features clearly distinguish Bes from the “normal image” of Egyptian gods (Dasen 60), but that the dwarf’s “physical malformation was not regarded as a disquieting attribute, but as a divine

one. This symbolic correspondence seems to have passed beyond dynastic Egypt into the Greek world” (Dasen 53). Most of the representations of the dwarf God Bes seem to celebrate his unique appearance and body habitus.

**Figure 3-1**

*Stela of the God Bes* (Egypt, c. 304 BCE–364 CE, New York, Metropolitan Museum)

Like their Egyptian counterparts, Greek representations of dwarfs (in vase paintings and friezes) “are not fully naturalistic” and “may reflect folk-beliefs about dwarfs” (Dasen 173), but neither do they fall into the category of “traditional stock figures of vase-painting and statuary” (Dasen 166). For example, Dasen notes that the “fact that [the dwarfs’] bodies are complete” (Dasen 166) may explain why Greek artists were seemingly comfortable about representing the physical abnormality of short stature despite their aversion toward showing “disfigured” bodies in art. Many of the dwarfs represented in Greek art appear to be achondroplastic, and “often have larger or more conspicuous genitals than normal-sized Athenians” (Dasen 173). Among the more famous depictions of dwarf figures in Greek vase paintings are those of pygmies battling cranes. As noted earlier, pygmies are not true pituitary dwarfs and have normal growth hormone levels. They owe their short stature to inadequate amounts of insulin-like growth factor I (IGF-I), yet they have normal IGF-II concentrations. To the artists of the classical world, however, they may have resembled undeveloped children. As Leroi observes, such artists “were depicting the fabulous by appealing to the familiar” (Leroi 185).

The mythological battle between the pygmies and the cranes appears in literature from as early as Homer’s *Iliad* (800 BCE) and Pliny’s *Natural History* (77–79 CE) and as late as the period of neo-classical English literature in the early eighteenth century. Whether the fearless men who climbed up the side

of Hercules’ wine goblet in order “to drink from it” or the feisty Lilliputians of *Gulliver’s Travels* (1726), literary and artistic representations of pygmies have traditionally emphasized their pugilistic tendencies yet the ineffectual consequences of their attempts at warfare.<sup>137</sup> The stocky and fierce-looking pygmies in some Greek vase paintings illustrate the comparable heights of the pygmy and the crane but display the superior physical strength of the pygmy warrior.<sup>138</sup> Other vase paintings of the battle between pygmies and cranes depict pygmies with weaker looking bodies, obviously incapable of fighting their enemies. Dasen suggests that the “legend of the fight between cranes and small men might also have translated into a mythical language the fact that pygmies have hostile relationships with their tall black neighbours, the Nuer, Dinkas, and Chillouks, who are used to stand on one leg like birds” (Dasen 177). Such iconography invariably links the pygmies with the animal world or with the half-human, half-animal world of satyrs (Dasen 173).<sup>139</sup> As Dasen notes, “[some] dwarfs are equated with animals, like the puny pygmies who hardly resist the attacks of the birds, or they transform into animals, like the Cercopes, who are changed into monkeys, or they have a mixed appearance, like the Telchines. Little people are also closely associated with childhood in the myths of pygmies and of Cercopes” (Dasen 243).

The Greek attitude toward dwarfs, then, vacillates between acceptance of short stature and a tendency to marginalize the position of dwarfs in society. According to Dasen, this

paradox is especially apparent in Aristotle’s comparison of dwarfs with children and the association of dwarfs with satyrs in “Dionysiac scenes ... while keeping their human form. They stand between the real and the transcendental world, as privileged intermediaries to the deity” (Dasen 244). A Roman fresco from Pompei titled *Fight between Pygmies and Animals in a Nilotic Landscape* (1st–3rd century CE, Naples, Museo Archeologico Nazionale) illustrates the tradition of comparing pygmies and dwarfs to the animal world. Here the artist creates a comic atmosphere in which the helpless pygmy flails at a huge crocodile whose head is larger than the pygmy’s body. In another scene of the same series of frescoes, pygmies play in the river Nile, seemingly undaunted by the large animals that reside there. In both frescoes, the artist’s rendering implies that pygmies are childlike in behavior as well as size.

The association of dwarfs or little people with the animal world also appears in Germanic and Nordic mythologies and folktales that often convey a deprecating view of little people. Dehumanizing images of dwarfs are common in Renaissance paintings and sculpture, particularly those that allude to the underworld or hell. Best known among the early Renaissance painters of the Last Judgment and other subjects related to man’s inherent depravity, the paintings of fifteenth-century Flemish painter Hieronymus Bosch include dwarf like figures with animal limbs.



Two hundred years after Bosch, David Teniers's painting of *The Rich Man Being Led to Hell* (Figure 3-2, 1647, London, England, National Gallery of Art) incorporates a similar conflation of human and animal characteristics. The focal point of the Teniers painting is the figure of an old and frightened looking man, presumably the "rich man" in the title. To his left is a diabolical figure with wings accompanied by two dwarf-like figures, a man, and a woman with disproportionately large human heads (suggesting achondroplasia); the female figure is shown with human arms and reptilian legs. The presence of other anthropomorphic creatures, including a fish with

human limbs, suggests the devolution of man into an animal state, further adumbrated by the diminished stature of the human figures in the painting. Whether or not Teniers associated dwarfs with bestial or evil behavior, the painting strongly suggests the connection between short stature and sub-human status, much like that of the serpent in Genesis 3 condemned to slither on his belly. The painting alludes indirectly to the parables in Mark 10:17-31 and Luke 16:19-31 in which Jesus decries the evils of rich men. (In the latter parable the rich man is surprised to find himself in the torments of hell after his death.) As many critics have recognized, Teniers's

**Figure 3-2**

David Teniers, *The Rich Man Being Led to Hell* (1647, London, England, National Gallery of Art)



**Figure 3-3**

Paolo Veronese, *Feast in the House of Levi*, detail (1573, Venice, Galleria dell'Accademia)

painting may reflect the influence of Bosch's paintings in which half-human, half-animal creatures, some of short stature, encounter the pains of hell.

The association of dwarfs and animals appears in more subtle ways in Venetian and Florentine art of the sixteenth and seventeenth centuries. Barry Wind notes, "dwarfs appear as decorative motifs on fountains or retain their diminutive size in small bronzes" (Wind 27). One of several examples in

the Boboli Gardens of the Pitti Palace in Florence is "the paunchy, immobile dwarf Morgante [who] is perched on a sluggish tortoise" (Wind 34), suggesting an obvious comparison of size between man and reptile.<sup>140</sup> Possibly reflecting the influence on the Venetian aristocracy of the Ottoman Empire and its practice of keeping dwarfs in the seraglio,<sup>141</sup> several Venetian narrative paintings include court dwarfs and court pets in intricately detailed crowd scenes. In a detail from Paolo Veronese's *Feast in the House of Levi* (Figure 3-3, 1573, Venice, Galleria dell'Accademia), for example, a dwarf dressed in the costume of a clown entertainer appears on the same plane

as the dog in the foreground (not shown here), as if both are pets of the aristocratic family gathered in the background. A black servant, possibly a pygmy, is handing the dwarf a bird, further connecting him with the animal world. It is worth noting that Veronese was admonished by the church fathers for the obvious secularism of the painting that was originally titled *The Last Supper* and destined for the refectory of the Venetian monastery of Saints Giovanni and Paolo.<sup>142</sup> The alteration of the title, and by implication, the subject, apparently made the display of wealth and debauchery less offensive to the church fathers since it alludes to the



story of the publican Levi in the gospel of Luke 5. In the parable Levi serves a great feast to Jesus, much to the dismay of the “scribes and Pharisees [who] murmured against his disciples, saying, Why do ye eat and drink with publicans and sinners?” (Luke 5:30). The association of dwarf servants with excesses of wealth (represented in the figures of publicans and sinners) and a similar theatrical composition characterizes Veronese’s *The Marriage at Cana* (1563, Paris, Louvre). In this painting a dwarf and dogs are shown in the foreground near the musicians who entertain the wedding party. In both banquet scene paintings, the dwarf appears to be interacting with black servants, suggesting his servile position in the household. The juxtaposition of regally attired dwarfs and dogs in both paintings further confirms the artist’s representation of the common mockery of the dwarfs’ low status in comparison to that of the guests at the feasts.

#### Figure 3-4

Bonifaccio de’Pitati (sometimes also called Veronese) *The Parable of the Rich Man and the Beggar Lazarus or Il Ricco Epulone* (1543–45, Venice, Galleria dell’Accademia)

On a smaller scale but with a similar reference to Venetian royalty who treated dwarfs as property, Bonifaccio de’Pitati’s (sometimes also called Veronese) painting *The Parable of the Rich Man and the Beggar Lazarus or Il Ricco Epulone* (Figure 3-4, 1543–45, Venice, Galleria dell’Accademia) has been characterized as a “pretext for an extraordinary description of Venetian aristocratic life” (*The Accademia Galleries in Venice* 102). In the painting a pygmy appears in the center foreground as an aid to the musicians entertaining the richly dressed figures on the left. Alluding to the same parable in Luke 16 to which Teniers refers, in *The Rich Man* Pitati illustrates the rich people’s indiffer-

ence to the beggar Lazarus on the right whose wounds are being licked by dogs. As in Paolo Veronese’s paintings, the wealthy family members also appear oblivious of the entertainment provided by the musicians and the dwarf. The painting’s theatrical display of marble pillars and rich tapestries and garments draws further attention to the opulent household that includes dwarf servants in its retinue, thus illustrating the lesson of the parable.



**Figure 3-5**

Anthony Van Dyck, *Queen Henrietta Maria and her Dwarf Jeffrey Hudson* (1633, private collection)

Anthony Van Dyck's portrait of *Queen Henrietta Maria and her Dwarf Jeffrey Hudson* (Figure 3-5, 1633, private collection) includes a pyramidal hierarchy of animal/dwarf/aristocrat similar to that depicted in paintings by northern Italian artists. Van Dyck's portrait is an example of the artist's attempt to use little people to exaggerate the height and dignity of the aristocracy; in this case, the contrast suggests Queen Henrietta's physical superiority. According to legend, Jeffrey Hudson was a gift to Queen Henrietta Maria (the wife of English King Charles I). Arriving at court "concealed in a cold baked pie," he was subsequently involved in a series of royal adventures that contributed to his reputation as courageous and loyal.<sup>143</sup> In the painting the presence of the monkey on the dwarf's arm and other props in the scene suggest a "hint of mockery in the portrait"<sup>144</sup> and direct the viewer to the queen's image of authority. In addition, in the background of the painting "the lion's head decoration may have monarchical significance ..." and is "emblematic of custody, suggesting the Queen's proprietary rights over her exotic entourage, the dwarf and the monkey. Her hand resting on the monkey confirms her dominance. Of course, the monkey picking at Hudson's head denotes the midget's traditional role as a fool" (Wind 102). Despite Hudson's reputation as a significant member of the court,





**Figure 3-6**

Raphael, *The Cross Appearing to Constantine the Great Flanked by Two Popes* (1520, Vatican State, Vatican Palace, Stanze de Raffaello)

Van Dyck's painting focuses almost exclusively on the view of the dwarf as an exotic possession or plaything of the aristocrat, clothed in regalia that emphasize his role as an entertainer on the same level as a pet. This demeaning representation of dwarfs in paintings continued to be a familiar subject for court painters in the seventeenth century.

Some Italian Renaissance painters feature dwarfs in both formal portraits and narrative paintings that emphasize aristocratic or military power. In his

series of frescoes for the Sala of Constantine in the Vatican Palace Raphael's painting of *The Cross Appearing to Constantine the Great Flanked by Two Popes* (Figure 3-6, 1520, Vatican State, Vatican Palace, Stanze de Raffaello) includes a dwarf in the right foreground. The painting's narrative tells the story of the first Christian emperor Constantine's vision of the cross as a sign of imminent victory in the next day's battle of the Milvian bridge (depicted in the fresco adjacent to *The Cross*). As art historian Richard Cocke notes, the "initial programme [of the frescoes] reflected humanist hyperbole" to emphasize a flattering comparison between the emperor and Pope Leo, who commissioned the frescoes.<sup>145</sup> With the implied parallels between rulers, the

frescoes depict Constantine "defeating the impious, under the inspiration of the cross, while displaying his generosity to captured troops and to young children" (Cocke 95). Almost outside the action of the scene, the "court dwarf of Ippolito de Medici, Gradasso Berratai, comically intrudes upon the sudden revelation of the cross to Constantine" (Wind 23). Despite his marginal placement in the painting's right foreground, the dwarf stands out as a frolicking character, playfully donning his military headdress and disrespectfully urinating in front of the soldiers who flank Constantine and are focused on the vision of the cross. Raphael's purpose in distracting the viewer with the vulgarly comic dwarf




**Figure 3-7**

Francesco Trevisani, *Banquet of Antony and Cleopatra* (late 17th century, Rome, Italy, Spada Gallery)

is unclear, but its inclusion adds an element of humanism to the hyperbole of the scene, suggesting that even at solemn moments for great heads of state, society's misfits, here represented by the dwarf, may “steal the show” (Wind 23).<sup>146</sup> Whether representing vulgar behavior or a mere curiosity, such depictions of dwarfs call attention to their marginal position in society even though, or indeed, partly because, their dress may mimic that of the aristocracy or military.

As demonstrated in the earlier work by Raphael and in paintings of Domenichino,<sup>147</sup> Italian artists of the seventeenth century continued to convey derision in their portrayals of dwarfs in comic roles. Francesco Trevisani's *Banquet of Antony and Cleopatra* (Figure 3-7, late 17th century, Rome, Italy, Spada Gallery), for example, includes a dwarf pulling a reluctant small dog in the foreground of the painting. The dog's apparent strength in contrast to his small size implies that the dwarf is physically weaker than the weakest dog. The dwarf's position below the table of dining aristocrats also confirms his low status. His costume and head-dress suggest an exotic origin further marginalizing his position in the court. Trevisani's painting may hark back to earlier paintings in which dwarfs were frequently included in formal paintings of the aristocracy to display the rich panoply of the court retinue. Vittore Carpaccio's *Arrival of the English Ambassadors at the Court of the King of Brittany from The Legend of St. Ursula* (c. 1495, Venice, Galleria dell'Accademia), for example, includes



an achondroplastic dwarf in the grand entourage of the court. The painting's juxtaposition of a clown/dwarf with two dogs about half his height reminds the viewer of his low and, perhaps lonely, position in the Venetian court.

**Figure 3-8**

Andrea Mantegna, *Ludovico Gonzaga and Family with Courtiers* (1471–1474, Mantova, Italy, Palazzo Ducale, Camera degli Sposi)

A painting by Andrea Mantegna of *Ludovico Gonzaga and Family with Courtiers* at the ducal palace in Mantova (**Figure 3-8**, 1471–1474, Mantova, Italy, Palazzo Ducale, Camera degli Sposi) suggests a slightly different interpretation of the role of the dwarf in royal households. Here a female dwarf who is probably achondroplastic stands close to her mistress. Her position suggests a more inclusive treatment of

dwarfs in the Gonzaga family's royal household. Mantegna's placement of the dwarf in a frontal pose affirms her position of dignity and pride within the family enclave. Her head, though lower than that of the children next to her, is on a higher plane than that of the dog under the Duke of Mantova's chair, perhaps referring to her social position as less than that of the heirs of the family but more than that of a mere pet.<sup>148</sup> The Gonzaga family's "predilection for dwarfs" and the frequent appearance of dwarfs in paintings from the Veneto, Lombardia and Piemonte may reflect a long tradition of fascination with dwarfism in northern Italy (Merke 311).<sup>149</sup>



**Figure 3-10**

Jan Molenaer, *The Artist's Studio* (1631, Berlin, Germany, Gemaeldegalerie, Staatliche Museen)

Not all artists represented dwarfs in formal settings. Cartoonish dwarf figures appear in the form of garden sculpture and in numerous prints of the period in northern Europe as well as in Italy. Wind notes that artists such as the French “Jacques Callot, [who] worked in Florence from 1614–17 ... had a lively interest in the commedia dell’arte and the grotesque” (Wind 27), often recalling the image of Pulcinello and other familiar figures

of the stage (Wind 29). Callot’s “series of comic ‘gobbi’—dwarfs and hunchbacks” (Wind 27) represents dwarfs with the caricaturist’s technique of foreshortening, an emphasis on round features and military costume, all for the entertainment of the viewer. Such prints made available to the Italian public have their counterparts in the work of northern European artists such as Dutch painters Jan Molenaer and Jan Steen, who depict dwarfs in compromising social scenes. In Molenaer’s *Stone-throwing Dwarf* also known as *Scene with Dwarfs* (**Figure 3-9**, 1646, Eindhoven, Netherlands, Van Abbemuseum) (see p. 90),

for example, a male dwarf in a hat standing in front of two female dwarfs appears to be throwing rocks at children who are taunting him. Although the dwarf figure is distinguished from the children in the scene by his adult garb, his hat and his bulbous nose, the adult facial features yet child-like proportions of other figures in the scene suggest an ambiguity of normal and abnormal in which children resemble dwarfs and dwarfs resemble children in appearance and behavior.<sup>150</sup> Ambiguously, the artist may be suggesting that the behavior of the dwarf is childlike and harmless or that the behavior of chil-

dren is potentially dangerous. Molenaer's *The Artist's Studio* (Figure 3-10, 1631, Berlin, Germany, Gemaeldegalerie, Staatliche Museen) also infantilizes the role of the dwarf by showing him dancing with a dog in the foreground of the painting, apparently oblivious of the adult activity in the background. The "negative response" toward dwarfs that the two paintings seem to provoke is similar to that elicited by Steen's paintings in which dwarfs perform as entertainers in scenes of debauchery, thus reinforcing the stereotype of immoral and foolish behavior associated with dwarfs (Wind 111).<sup>151</sup>

Among the numerous seventeenth century paintings of dwarfs, those created in Spain by Spanish, Flemish and Dutch artists have contributed to a rich collection. The lost Ribera painting of *The Dwarf and the Dog* (discussed on the first page of this chapter) may hark back to the work of Flemish painter Anthonis Mor's (also known as van Dashort) *The Dwarf of Cardinal Granvelle* (Figure 3-11, 1560, Paris, Louvre) in which the dog appears to be larger than the regally dressed dwarf who holds him. The gaze of the large-headed dog turning to look at his diminutive master dramatizes the irony of the dwarf/animal juxtaposition.



**Figure 3-11**

Anthonis Mor (also known as van Dashort),  
*The Dwarf of Cardinal Granvelle*  
(1560, Paris, Louvre)

Probably the most well known painter of dwarfs is the Spanish artist Diego Velasquez, who, as a court painter during the reign of Phillip IV in Madrid, executed several portraits of the royal family. Art historian Jonathan Brown notes that in contrast to Velasquez's "official portraits [which] provided no opportunity to examine the inner life of the sitters," in his "portraits of jesters and dwarfs, who were on the margins of court society, he was free to experiment."<sup>152</sup> The marginal status of dwarfs thus may have contributed indirectly to the advance of psychological realism in art. Realism of expression reminiscent of Caravaggio's paintings of peasant figures with goiters is apparent in Velasquez's portraits of dwarfs: *Don Diego de Acedo* or *El Primo*, *Sebastiano de Morra*, *Portrait of Baltasar Carlos with Dwarf* and *Francisco Lezcano*.

The subject of *Don Diego de Acedo* or *El Primo* (**Figure 3-12**, 1644, Madrid, Museo del Prado) appears to be a dwarf with normally proportioned torso and limbs. "Represented among large books, alluding to his appointment in the office of royal seals, the dwarf is captured in the paradoxical situation of an intelligent and sad buffoon and also a libertine...."<sup>153</sup> The ironic juxtaposition of *El Primo* and the large books suggests a possible comic emphasis on the dwarf's small stature in contrast to the weighty tomes and the serious bearing and costume of the scholar. As Wind notes, the presence of the pen in the inkwell implies "libidinous connotations," assuming "a highly

charged sexual significance" that may be associated with *El Primo*'s reputation as a "notorious ladies' man" (Wind 85). Given the assumption at the time that male dwarfs were sexually non-threatening,<sup>154</sup> Velasquez may also be challenging such notions by placing the phallic pen and inkwell in the center of the foreground. Yet despite these symbols that might also have suggested sexual mockery and "amusement for the court" (Wind 85), *El Primo*'s serious facial expression with eyes cast down invites empathy that makes Velasquez's intention ambiguous, as if the painting is meant to mock and empathize at the same time.



**Figure 3-12**

Diego Velasquez, *Don Diego de Acedo* or  
*El Primo* (1644, Madrid, Museo del Prado)

**Figure 3-13**

Velasquez, *Portrait of Baltasar Carlos, son of Philip IV, with a Dwarf* (1631, Boston, Museum of Fine Arts)

---

A less sympathetic and more pronounced emphasis on the features of an achondroplastic dwarf is apparent in Velasquez's *Portrait of Baltasar Carlos, son of Philip IV, with a Dwarf* (Figure 3-13, 1631, Boston, Museum of Fine Arts). Here, the contrast between the normal and the abnormal is created by the juxtaposition of the young prince's "erect posture" (Wind 72) and the slouch of the large headed dwarf holding an apple and a rattle that resembles a royal orb. Barry Wind interprets the placement of the dwarf "on a lower physical plane" and objects held by the dwarf as indicative of a "derisive contrast" in which "Velasquez may be following an established court tradition" (Wind 77).







**Figure 3-14**

Alonso Sánchez Coello, *Portrait of Infanta Isabel Clara Eugenia and Magdalena Ruiz (dwarf with monkeys)* (c. 1585–90, Madrid, Museo del Prado)

Wind compares the portrait of Baltasar with court painter Alonso Sánchez Coello's *Portrait of Infanta Isabel Clara Eugenia and Magdalena Ruiz (dwarf with monkeys)* (Figure 3-14, c. 1585–90, Madrid, Museo del Prado), which similarly applies the “formula of contrast” (Wind 74) to illustrate the difference between royalty and the servile, physically inferior dwarfs. In this painting, the contrast in size between the Infanta and her dwarf servant Magdalena emphasizes the significant difference in status between the two women. Furthermore, the marginal placement of Magdalena next to the royal figure but partially cut off by the right border of the painting underlines that difference. Wind also notes the important placement of the *Infanta's* hand on the head of the dwarf, “a gesture that implies not only protection but also dominance”; the *Infanta's* dwarf “is like some court pet, and the monkeys that alight on her arms confirm the dwarf's base nature” (Wind 74). Similar to Van Dyck's portrait of Queen Henrietta and her dwarf, in its use of antitheses, Coello's portrait seems intended to glorify royalty at the expense of the dwarf.



Velasquez's painting of *Francisco Lezcano* (**Figure 3-15**, 1636–38, Madrid, Museo del Prado) invites more speculation about the ambiguity of the artist's intention in depicting a highly recognizable endocrine abnormality such as dwarfism. In this portrait Velasquez draws attention to the dwarf's bulbous nose and relatively coarse features, which Jonathan Brown labels as indicative of "Down's Syndrome," but which, in our view more likely resemble the features of a dwarf who is also a cretin (Brown 126). It is also possible that the subject could have both Down's Syndrome and cretinism, both of which might explain the vacuous expression on the boy's face, suggesting decreased intellectual capacity. Wind posits that the "dark precipice" in the background of the painting "may localize the figure in the mountainous region around the Torre de la Parada" (Wind 82). The prevalence of cretinism in mountainous areas such as the Pyrenees or in the mountains near Madrid depicted in the painting supports our belief that Lezcano is a cretin whose dwarf like features resemble those of other cretins severely deprived of thyroid hormone at a young age. In this example, we agree with Jonathan Brown that the presence of derisive symbols mocks Lezcano's low status as a fool and a plaything.<sup>155</sup> Nonetheless, we argue that Velasquez creates a sympathetic tone in the painting, especially in the boy's expression of pain or anxiety, as he does in the portrait of *Calabazas*.

**Figure 3-15**

Diego Velasquez, *Francisco Lezcano* (1636–38, Madrid, Museo del Prado)



**Figure 3-16**

Diego Velázquez, *Las Meninas*, detail (1656, Madrid, Museo del Prado)

Velasquez's famous court painting *Las Meninas* or *The Maids of Honor*, detail (Figure 3-16, 1656, Madrid, Museo del Prado) takes the concept of royal portraiture to another level of irony and implied narrative, a component of which is the presence of two different types of dwarfs in the right foreground of the painting, María Bárbola and Nicholas Pertusato, both members of the royal household.

There are numerous theories about the painting's ambiguities. One suggests that the images of the king and queen reflected in the mirror to the left of the painting's focal point reveal their approval of the artist (Brown 186). Wind speculates that the presence of dwarfs in the painting illustrates Velázquez's effort to present "the traditional formula of antithesis between firm and infirm" as well as the artist's "facility in portraying all facets of nature, ranging from the lower life-forms—the dog, María Bárbola, and Nicholas Pertusato—to the august—the *infanta*, and the king and queen"

(Wind 89). The two dwarfs stand to the right of the *infanta* behind the dog in the foreground of the painting.

María Bárbola appears to be an achondroplastic dwarf whereas Nicholas Pertusato is a normally proportioned dwarf. Both are dressed in regal clothing, but María has a more noticeable position in the painting's composition. The tall maid between her and the *infanta* forms the apex of a triangle for which the dwarfs and dog form the right angle. Nicholas's figure is more obscure than María's, cut off by the right margin of the



painting and therefore appearing less the subject of a portrait than a figure in action as he moves playfully toward the dog. By association, the viewer can't help linking the dwarfs with the family pet, but at the same time, María Bárbola's prominent position suggests the importance of dwarfs in the royal household, much as does the female dwarf in Mantegna's Gonzaga family portrait. María stares directly at the viewer with an almost overt awareness and presence that historian Kenneth Clark finds especially disturbing: "While the other protagonists in the *Meninas*, out of sheer good manners,

take their parts in a sort of tableau vivant, she affronts the spectator like a blow from a muffled fist."<sup>156</sup> María's strong frontal pose may reflect Velasquez's attempt to convey in *Las Meninas*, as he does in other paintings of dwarfs, the "physical humiliations [which] gave them a reality which his royal sitters lacked" (Kenneth Clark). Even the volume of Bárbola's short but developed body and large head invites a comparison with the more fragile figure of the *infanta*, who appears to be of a similar height.

#### Figure 3-17

Pablo Picasso, *Las Meninas*, No. 1, after Velasquez (1957, Barcelona, Museo Picasso)

In the twentieth century Pablo Picasso's *Las Meninas*, No. 1, after Velasquez (Figure 3-17, 1957, Barcelona, Museo Picasso) is first in a series comprising fifty-eight oil paintings. The series alludes to and parodies Velasquez's painting, exaggerates the static pose and pumpkin shaped facies of María Bárbola and depicts Nicholas Pertusato with a simple line drawing

that emphasizes his clownish movement toward the dog. In the large group painting of the series, which is colored in monochromatic greys, whites, and blacks, there is also an implied comparison between the volume of the *infanta's* wide skirt and that of Bárbola's large head (both painted white), thus reducing both figures to substantive masses within the royal portrait. In both Velasquez's and Picasso's paintings the eyes of María Bárbola and the *infanta* gaze directly at the viewer whereas the other figures of the painting gaze in varying directions.

By singling out and linking the *infanta* and the female dwarf are both Velasquez and Picasso suggesting that this achondroplastic dwarf is an object of ironic power on a level with the *infanta*, a concept that challenges notions of traditional royal hierarchy? Perhaps Velasquez moved from his earlier, more literal attempts at contrasting dwarfs with royal children to a more ambiguous questioning of the meaning of power. It is possible that both artists use the achondroplastic dwarf figure of María Bárbola to hint at the unexpected presence of power in the "abnormal." In his twentieth century interpretation of royal power, Picasso focuses more directly than Velasquez on the agony of the dwarf's position, especially that of María Bárbola. One of the smaller paintings in Picasso's series that includes only Isabel de Velasco and María Bárbola examines that relationship between the two. According to Claustre Rafar I Planas, Picasso put "all the drama of the work into the dwarf, who adopts

a clearly defiant attitude to the viewer whom her hands, like claws, seem to want to check. Her monstrous face is covered by a veil while a *menina*, in a mixture of surprise and fear, watches her out of the corner of her eye."<sup>157</sup> The entire series of Picasso's *Las Meninas* not only challenges perceived hierarchies but also reflects the complexity and political upheavals of the twentieth century in which fascist regimes supplanted monarchies and the boundaries between normal and abnormal are no longer clear.

Although the tradition of keeping dwarfs for entertainment or as companions/helpers for children continued to be practiced at royal European courts well into the eighteenth century, especially in Russia, the representation of dwarfs in painting is quite rare after the seventeenth century. Nevertheless, engravings and lithographs in popular journals abound in caricatures of dwarfs, many of them from the world of entertainment, especially circuses and freak shows. Frequently, the technique of caricature popularized by Jacques Callot and others is apparent in such engravings and tends to reduce the humanity of the dwarf to his or her physical characteristics. There are also portraits of specific individuals who gained public fame for their singular abilities related to their dwarfism. Among these individuals, two achieved recognition not only as dwarfs but also as cultured, civic minded men who made a significant contribution to society.

The subject of a well-known nineteenth century engraving is a dwarf

who achieved legendary fame in aristocratic circles during the Dark Ages of European history: the sixth century Bertholde of Bertagnona. According to popular legends, Bertholde's

ready wit greatly impressed Alboin, first King of Lombardy but his tricks made an enemy of the Queen. He so annoyed her that she had him seized and put in a sack, like a kitten, to await drowning the following day. He survived and later rose in favour so highly that Alboin appointed him Prime Minister. What Bertholde's ultimate fate was we do not know but legend says the murderous queen eventually poisoned her husband.<sup>158</sup>

The frequently reproduced nineteenth-century engraving by A. Walker, *Bertholde, a Dwarf* (**Figure 3-18**) (see p. 93) is a formal portrait of a small, wizened man standing against the northern Italian landscape of rocks and hills. The dwarf has normally proportioned limbs and torso but an exceptionally large head and hands. His feet also appear large in the peasant style clogs he is wearing. His serious visage and mysterious finger pointing suggest a man of determination and focus, a noticeable contrast to the images of dwarf fools and gobby caricatured by Jacques Callot.<sup>159</sup>

---

**Figure 3-19, facing page**

Philip Reinagle, *Count Joseph Boruwlaski* (1782, London, Royal College of Surgeons, Hunterian Museum)



Although Bertholde's "story has been shown to be a folk tale" (Adelson 46), its emphasis on a dwarf's distinct wit and intelligence and his rise to fame and prominence as a distinguished prime minister, a position further adumbrated by the engraving, reflects the growing interest during the eighteenth and nineteenth centuries in examining the lives of dwarfs beyond the stereotype of court pet or curiosity.

The most famous dwarf associated with eighteenth century European courts was Joseph Boruwlaski, often referred to as "the last of the court dwarfs" (Leroi 175). Boruwlaski was born in 1739 in Poland to poor parents who eventually allowed him to live with his mother's "patron, a young local noblewoman, the Staorina de Caorliz," who saw to his education; later he became the ward of the Comtesse de Humiecka, who introduced Boruwlaski to European society (Leroi 171). Boruwlaski's parents were of normal size, but two of his five siblings, a sister and a brother, were dwarfs like Joseph. Boruwlaski married a noblewoman, Isalina Borboutin, of normal size, who at first rejected Joseph because of his dwarfism (Leroi 173). The marriage produced children of normal size, and Boruwlaski lived a celebrated life in England where he was the favorite of several aristocrats. In an eighteenth century painting by Philip Reinagle (**Figure 3-19**, *Count Joseph Boruwlaski*, London, Royal College of Surgeons, Hunterian Museum), Boruwlaski is represented in a formal portrait that calls attention to the dwarf's normal proportions

but diminutive size in comparison to the chair against which he leans his right arm. Dressed in aristocratic finery and carrying a sword proportioned to his size, he has the appearance of a dignified gentleman at ease in the public world.

Boruwlaski's life is recorded in *The Life and Love Letters of a Dwarf: Being the Memoirs of a Celebrated Dwarf, Joseph Boruwlaski, a Polish Gentleman*. Despite the evidence of social progress in the acceptance of Boruwlaski in aristocratic circles, his writings reflect the humiliation he still felt as an object of curiosity. The memoirs express Boruwlaski's pride in his considerable accomplishments as a well-educated man with musical talents, but they also reveal the darker side of his life as a dwarf. For example, he writes,

[W]ere I upon a footing with other mortals, I could, like them, have supported myself by honest industry; but my size excludes me irrevocably from the common circle of society. There are many persons who seem to pay no regard, nor even to consider me as a man, and an honest man endued [sic] with the most tender sensibility—how painful a reflection.<sup>160</sup>

Boruwlaski, who documented his growth record in his memoirs, continued to grow until he was thirty years old and lived until the age of ninety-eight, an unusual example of longevity for the time. Leroi notes, his "body the size and proportions of a four-year-old's, delayed puberty, and

a briskly adult intellect" indicate "the signatures of growth-hormone failure typical of pituitary dwarfs" (Leroi 176). Twelve hundred years after Bertholde's dramatic story began to be circulated, the more authentic documentation of Boruwlaski's experience affirms social progress in the lives of dwarfs in western society. Boruwlaski's story reminds us, however, that even in the age of Enlightenment dwarfs continued to be victims of social marginalization.

The "collecting" of dwarfs as objects to whet the appetite of the curious public was not confined to European citizens. North American audiences also found entertainment value in freak shows, circuses, Lilliputian touring companies and "dime museums" where little people and others with physical abnormalities performed (Adelson 25–27). If a performing company could claim exotic origins for their performers, so much the better for business. Engravings and lithographs in popular journals featured such exotica. In a lithograph titled *Two miniature people, known as the Aztec Lilliputians, with their manager* by G. Wilkinson (**Figure 3-20**, London, Wellcome Library, no. 26171) two little people named Bartola and Maximo flank a normal sized man who holds one of the little people in his hand. The lettering on the lithograph reads as follows:

These wonderful beings were brought to North America in 1849, by Valasquez a Spaniard, who states that he carried them off at the hazard of his life from the



mysterious and unknown city of Ixamaya, in central south America, where this Lilliputian race has for many centuries been worshipped by the inhabitants as sacred objects.

The greatly exaggerated diminution of the little people in the lithograph suggests that the dwarfs were considered mere playthings, no different from children's toys that might be exhibited in a museum. In fact, however, medical investigation revealed that the so-called Aztecs were actually twin children from a village in San Salvador, who "had small but long heads and ... an utter lack of intelligence."<sup>161</sup> The double bias against little people and people of indigenous cultures is also apparent in the lithograph's title. According to Adelson, "J. Mason Warren, a physician renowned for his research in anesthesia who published 'An Account of Two Remarkable Indian Dwarfs' in 1851 accepted at face value the exhibitor's statement" (Adelson 26). In the article summarized in Adelson's book Warren goes on to describe the dwarfs as "resembling ... intelligent individuals of the canine race" (Adelson 26). As his description illustrates and as we have seen in numerous examples of paintings from earlier centuries, the belief that little people were less than human and closely allied with animals continued even among those in the medical profession.

**Figure 3-20**

G. Wilkinson, *Two miniature people, known as the Aztec Lilliputians* (London, Wellcome Library, no. 26171)

Among the dwarfs to gain fame and fortune in the United States, General Tom Thumb achieved legendary popularity and wealth that illustrate the paradoxical position of the little person's fate in the public eye. Born Charles Stratton in 1838 in Bridgeport, Connecticut, Tom Thumb was of normal birth weight until the age of eighteen months when, according to an anonymously authored biography published in 1863, "Nature put a veto on his further upward progress."<sup>162</sup> Like Boruwlaski, Tom Thumb was introduced to royalty and became the wonder of a voyeuristic society. Sponsored by





Mr. P. T. Barnum (of later circus fame), he was exhibited in Barnum's traveling Museum and Menagerie and was lauded for his ability as an actor when he played "the role of Tom Tit, the comic negro boy in Mrs. H. B. Stowe's work, 'Dred: a tale of the Dismal Swamp'" ("A Chapter on Giants and Dwarfs" 3).

The double irony of a marginalized "other" in the form of a dwarf playing the role of a marginalized African American child in a drama that indulges racial stereotypes underlines the limitations of social progress for dwarfs in the nineteenth century.

Although no longer kept as court pets in a position similar to that of a valued slave, the dwarf whose fate put him in the public eye was still viewed as a curiosity, an aberrant product of Nature gone awry. Later, Tom Thumb settled into married life after courting the equally famous dwarf Lavinia Warren described in the New York Commercial Advertiser as "one of the most extraordinary little ladies at any time seen in this age of extraordinary beings" ("A Chapter on Giants and Dwarfs" 3). The wedding of Tom Thumb and Lavinia Warren was recorded in newspapers as "a grand national event" carefully controlled by "the presiding genii, P. T. Barnum" ("A Chapter on Giants and Dwarfs" 5).

Nonetheless, as the biography reports, descriptions of the wedding used patronizing language such as "little lady" or "diminutive Stratton-Warren bridal pair" ("A Chapter on Giants and Dwarfs" 5). Such language has its artistic counterpart in the engravings of the wedding that appeared in the Sketch. The presence of wedding guests of "normal" size in the foreground of the picture exaggerates the size of the dwarf pair in the chancel of the church. Like molded figures atop a wedding cake, Tom Thumb and Lavinia Warren look more like dolls than human beings.

Scenes of the Bohemian world of arts and entertainment appear in works by European artists of the impressionist and post-impressionist periods, notably those of Toulouse-Lautrec, himself a dwarf. Lautrec most likely suffered from bone disease resulting in frequent fractures and thus short stature.<sup>163</sup> Lautrec's *Marcelle Lender Dancing the Bolero in "Chilpéric"* (Figure 3-21, 1895, New York, private collection) includes an elf-like male dwarf dressed in black and sitting next to an animated dancer. The dwarf's wizened figure is reminiscent of Lautrec's self-portrait in which the bowler-hatted artist with large head, slim figure and short arms barely reaches the middle of his canvas on an easel. Both Lautrec figures represent the dwarf as voyeuristic, perhaps in an ironic role reversal of the stereotypical position of the dwarf as a subject of interest for the voyeuristically curious.

Impressionist painter Paul Cézanne's *Portrait of the Artist's Friend, Achille Empeiraire* (1869, Paris, Musée d'Orsay) is a more serious and dignified representation of a dwarf who also happened to be the artist's friend. Cézanne's depiction of Empeiraire's thoughtful expression and elegant dress does not dwell on the man's dwarfism despite the accurate representation of Empeiraire's disproportionately long fingers.<sup>164</sup>

---

**Figure 3-21, facing page**


Toulouse-Lautrec, *Marcelle Lender Dancing the Bolero in "Chilpéric"* (1895, New York, private collection)

Finally, on the cusp of the twentieth century, we can look to Picasso for a more modern and open-minded representation of a dwarf in the entertainment world of Paris. The female dwarf *La Nana* (**Figure 3-22**, 1901, Barcelona, Picasso Museum) stands in the foreground of the pointillist painting, seemingly in a state of contemplation. Her right arm is confidently bent at the elbow with hand on hip as if she intends to face the world straight on. Unlike the almost faceless figures of dwarf entertainers in seventeenth century paintings or the derisive caricatures of later periods, *La Nana* confronts the world with aplomb and without irony or cynicism. In the organic composition of the flower bedecked dancer against a flowered background, Picasso accentuates her self importance by having her occupy the whole canvas without the vanishing point of perspective to suggest a larger world around her.<sup>165</sup> The dancer appears to be an achondroplastic dwarf because of her short limbs in contrast to a normally proportioned torso.

These few but significant examples of more humane portraits of dwarfs represent a more enlightened attitude toward physical deformity and a psychological empathy toward little people more characteristic of modern and postmodern art than was apparent in the Renaissance. Nonetheless, twentieth century history is seriously marred by a continued marginalization of little people, most hideously exemplified by Nazi Germany's attempts to exterminate those who fell outside the definition of Aryan perfection.<sup>166</sup>

**Figure 3-22, facing page**

Pablo Picasso, *La Nana* (1901, Barcelona, Picasso Museum)





## Chapter 4


## Giants and Acromegalics: Stigma or Stature?

### Introduction

Among the many wonders of the Hunterian Museum collection at the Royal College of Surgeons in London is a display of the skeletons of the “Irish Giant” Charles Byrne and the “Sicilian Dwarf” Caroline Crachami. The skeleton of Byrne was acquired by eighteenth century surgeon and anatomist John Hunter and that of Crachami by Sir Everard Home. Both were given to the Royal College of Surgeons.<sup>167</sup> The contrast in size between the giant and the dwarf is impressive. Similarly, the photograph by Deanne Fitzmaurice of *Gibson and Zoie* (Figure 4-1), a Great Dane

and a Chihuahua, dramatizes the significantly large range of sizes in the canine species.<sup>168</sup> Although the display at the Hunterian Museum and the photograph are similar in their juxtaposition of contrasting sizes, the difference in size between the human giant and dwarf is the result of endocrine disorders whereas that between the two dogs is the result of selective breeding.<sup>169</sup> Both examples, however, illustrate the effects of growth hormone and growth hormone receptors.

In our super-sized twenty-first century culture, we are both fascinated and repelled by the concept of size. What appears outside the normal range of adult proportions and height has, throughout history, become an object of curiosity and sometimes alienation. Just as their short stature and, in some cases, disproportionately large heads and short limbs have determined the status of dwarfs or little people, aberrations in size have also determined the fate of giants. Children’s fairy tales abound in stories of evil giants like Jack in the Beanstalk who are outsmarted by normal sized persons, even by children. Throughout European history, giants, like dwarfs, were ostracized, exoticized, and collected, much



**Figure 4-1**

Deanne Fitzmaurice, *Gibson and Zoie*

as one would collect specimens of unusual creatures. Monarchs such as René of Anjou and Philip the Good of Burgundy (fifteenth century) collected exotic animals along with “dwarfs, giants, and other human prodigies” (Daston 101) and used them for entertainment in their courts.

### Figure 4-9, facing page

Francisco José de Goya y Lucientes,  
*The Colossus* (1810–12, Madrid, Prado)  
(see p. 138)

### **Causes of gigantism and acromegaly**

Most forms of gigantism and some forms of dwarfism are manifestations of abnormal over—or under—secretion, respectively, of growth hormone by the pituitary gland. Giants and acromegalics are easily recognizable because of their large size and prominent facial features. Like dwarfs, giants have been featured in classical, Renaissance, and Baroque art. In addition to their representation in paintings with mythological and religious themes, figures of actual living giants appear in satirical caricatures, especially those by British artists in the eighteenth and nineteenth centuries. Giants have a prominent place in world mythologies, assuming both heroic and anti-heroic roles, and it is these mythologies that are most commonly represented in art.

Similar to the source of some kinds of dwarfism—the lack of growth hormone or abnormalities of the growth hormone receptor—as we have discussed in the previous chapter, tumors in the pituitary gland that secrete growth hormone are responsible for most forms of gigantism and acromegaly. Gigantism occurs in children when the epiphyses or growth plates of bones are open and therefore capable of enlarging. The bodies of most giants maintain normal proportions. Acromegaly, on the other hand, has an adult onset when the epiphyses are closed and the bones become heavier and broader rather than longer. The condition of acromegaly creates an appearance of disproportionately large heads, jaws, hands, and feet.<sup>170</sup> Many

childhood giants also develop features of acromegaly when they become adults and their growth plates have become fixed.

Most individuals with gigantism and acromegaly have pituitary tumors that secrete growth hormone. Pituitary tumors account for nearly 15% of intracranial tumors and occur in four to five persons per million persons.<sup>171, 172</sup> Pituitary tumors can secrete prolactin, growth hormone, adrenocortical stimulating hormone, gonadotrophic stimulating hormone or thyroid stimulating hormone. They can also be non functional. The secretion of these various hormones results in different clinical syndromes. Acromegaly and gigantism are caused by excess secretion of growth hormone and usually occur sporadically, but they also occur in association with multiple endocrine neoplasia Type I (MEN-1). This inherited syndrome is characterized by tumors of the parathyroid and pituitary glands and by the pancreas, the result of an abnormality of the MENIN gene on Chromosome 11. Familial gigantism or acromegaly without other syndromes is rare. Ectopic secretion of growth hormone may also rarely occur in persons with neuroendocrine tumors of the pancreas or in patients with lymphoma (Melmed ref 29,30).

As already noted, gigantism results from the increased secretion of growth hormone in children and adolescents. Growth hormone is secreted by the pituitary somatotrophic cells in a pulsatile fashion. About 90% of patients with gigantism or acromegaly have a

benign monoclonal growth hormone secreting tumor known as an adenoma (Melmed ref 23). Growth hormone-releasing hormone from the hypothalamus induces the synthesis and secretion of growth hormone, whereas the hormone somatostatin suppresses the secretion of growth hormone. Another hormone, ghrelin, also influences growth hormone secretion and acts via growth hormone-releasing-hormone, predominately on the hypothalamus (Melmed 2558). Growth hormone binds to and activates the growth hormone receptor, which is primarily expressed in the liver and in cartilage.<sup>173</sup> Growth hormone stimulates the synthesis of peripheral insulin-like growth factor I (IGF-1), which induces cell proliferation and inhibits programmed cell death or apoptosis (Melmed ref 11). Fasting increases growth hormone secretion whereas obesity and aging are associated with suppressed secretory bursts of the hormone (Melmed 2560). Liver disease, hypothyroidism, and poorly controlled diabetes mellitus inhibit the production of insulin-like growth factor (IGF-1) and thus inhibit growth.



---

### Medical history and treatment of gigantism and acromegaly

---

As noted in **Chapter 3**, until the late nineteenth century, progress in the understanding of the function of the pituitary gland in relation to dwarfism was slow to develop and impeded by unproven speculation and erroneous theories. An understanding of the causes of gigantism was thus also lacking. Abnormally enlarged pituitary glands were noted as early as 1679 when “Theophile Bonet (1620–1669) ... referred to enlargement of the pituitary ..., as did Raymond Vieussens (1641–1715) in 1705” (Rolleston 75). In 1851 the French physician Bernard Niepce (1826–1918) found enlarged pituitary glands at autopsy in seven patients with cretinism.<sup>174</sup> In 1864 the Italian Andrea Verga (1811–95) observed at autopsy that a pituitary tumor “had destroyed the sphenoid bone and pressed upon the optic chiasma” (Medvei 305) of a woman with an abnormally large face. Rolleston notes that “Verga’s case was the first to connect the pituitary with acromegaly” (Rolleston 78). Symptoms in many patients with pituitary tumors were caused by “pressure on adjacent parts” of the brain near the pituitary rather than from excessive or inadequate endocrine secretion from these tumors (Rolleston 76). In 1888 N. Rogowitsch reported that rabbit pituitary glands became hyperplastic and larger after thyroidectomy (Sawin 179).

A better understanding of pituitary disease dates from 1886 when the French neurologist Pierre Marie (1853–1940) published his first observations regarding the relation of the pituitary gland to acromegaly. In 1890 Marie’s student Dr. Souza-Leite published “A Thesis on Acromegaly” (known as Marie’s Malady) in which he included forty-five patients (ten of them his own) with acromegaly and differentiated gigantism from acromegaly (Medvei 306–307). Dr. Souza-Leite noted that the *sella tursica* (where the pituitary gland is situated at the base of the brain) was enlarged and varied in size from “a pigeon’s egg to that of a hen’s egg or even an apple” (Medvei 307). (The normal human *sella tursica* is smaller than a dime in size.) In 1887 shortly after Marie and Souza-Leite’s publication, German-Latvian physician Oskar Minkowski (1858–1931) discussed a patient with acromegaly. Minkowski appears to have “definitely connected acromegaly with disease of the pituitary” (Rolleston 86).

In 1891 Scottish anatomist D. J. Cunningham wrote about enlarged pituitary glands or pituitary tumors in the Irish giant Cornelius Magrath (1742–68) and in another Irish giant Charles Byrne or O’Brien.<sup>175</sup> Because of “the large size of the pituitary fossae in Magrath’s skull capable of holding ‘half of a small tangerine orange,’” Cunningham concluded that the two giants were also acromegalics (Rolleston 83–84). In 1782 the skeletal remains of Mr. Byrne or O’Brien were obtained at considerable cost by British surgeon John Hunter

(1728–1793), who personally and illegally escaped with O’Brien’s body (Rolleston 84).<sup>176</sup>

Much of our knowledge of the pituitary gland is the result of clinical observations of patients with either over function of the pituitary gland manifested as gigantism or acromegaly or with the under function of the pituitary gland manifested as dwarfism.

Another rare cause of acromegaly or gigantism is the excessive secretion by the thymus or acro-trophoneurosis (Rolleston 86). In 1889 W. A. Freund (1833–1917) of Berlin suggested that the appearance of acromegaly with kyphosis and prominent facial features resembled anthropoid apes and “an atavistic reversion” in human development (Rolleston 87). German pathologist Ludwig Virchow (1821–1902), however, soon dismissed the idea of reversion (Rolleston 87).

In 1900 German pathologist Carl Benda (1857–1933) documented that acromegalics have an increase in eosinophilic (pink staining) cells in the lateral portions of the anterior pituitary, a discovery confirmed in 1905 (Rolleston 87). It was also noted that compression of other pituitary cells or structures adjacent to the pituitary gland could be responsible for the loss of menstruation in young women and the loss of strength and onset of impotence in men (Rolleston 87–88).

The secondary or trophic effects of the pituitary gland on other endocrine glands were soon recognized by many medical investigators. In 1908

surgeon Julius von Hochenegg of Vienna removed a pituitary tumor from a patient with acromegaly. Five days later von Hochenegg surprisingly noted some improvement in skeletal deformities, as reported by Kocher and Cushing (Rolleston 103). Unfortunately, despite the finding that 52% of patients with gigantism or acromegaly improved after removal of pituitary tumors, at this time the mortality rate for such surgery was 70% (Rolleston 103). In 1928 Berkeley physiologist Herbert Evans (1882–1971) reported that the anterior pituitary has eosinophil cells that secrete growth hormone and basophil cells that secrete gonad-thyroid-cortico-adrenal-promoting hormone. In 1933 Canadian biochemists James Collip (1892–1968), E. M. Anderson, and Thomson chemically separated the pituitary cells that secrete adrenotropic hormone (ACTH) and thyrotrophic hormone (TSH). As Rolleston notes, the separation “was obviously important as in some of the experimental results ... the atrophy of the adrenal cortex, following removal of the anterior pituitary gland (hypophysectomy), was accompanied by atrophy of the thyroid and other endocrine glands” (Rolleston 64).

In the early twentieth century Harvey Cushing “founded the first school of neurosurgery” and contributed much to our understanding of surgery of the pituitary gland (Welbourn 10). In 1932 Cushing reported that a basophilic adenoma of the pituitary was responsible for Cushing’s disease characterized by central obesity, purple

stretch marks, a buffalo hump on the posterior lower neck and hypertension (Welbourn 10). Berkeley scientist Brailsford Robertson “was credited with isolating the ‘active principle’ of the pituitary” (Sawin, “Defining Thyroid Hormone” 179). Robertson found that feeding anterior pituitary glands to mice at first slows their growth and then accelerates it (Sawin 179). Although these observations could not initially be confirmed, in 1921 Herbert Evans reported that the injection of “a crude pituitary extract” as well as pituitary growth hormone resulted in “giant rats” whereas the oral administration of the same extract was ineffective (Sawin 179–180).

More information about the function of the pituitary was provided by Philip E. Smith (1884–1970), first at the University of California at Berkeley and subsequently at Stanford and Columbia. He developed “a technique of removing the pituitary gland without damaging the brain in tadpoles, and later in rats” (Sawin 182). He observed that after the removal of the pituitary gland, “tadpoles ... grew more slowly, were much lighter in color, had small and atrophied thyroid glands and did not metamorphose” (Sawin 182). At the University of Kansas Bennet M. Allen (1877–1963) confirmed Smith’s observations and noted that when he removed the tadpoles’ thyroid glands, they also “failed to become frogs” (Sawin 182). Subsequent studies by Smith documented that removal of the pituitary gland caused “almost complete growth stasis and a rapid regression in the size of the adrenals ... the thyroid, and sex

apparatus. Furthermore, injections of rat or bovine pituitary restores growth and effects a partial repair of the adrenals, thyroids, and sex glands” (Sawin quoting Smith 184).

In 1926 Smith reported to the American Association of Anatomists that by using “the surgical parapharyngeal approach to hypophysectomy in rats ... he did not damage the hypothalamus” (the base of the brain that controls the pituitary gland). It was a discovery that helped solve one of the problems of partial hypophysectomy (Sawin 184). In addition, Smith reported that hypophysectomized rats had a low basal metabolic rate that could be corrected by the administration of rat pituitary or thyroid extract (Sawin 184). Unfortunately, although rat pituitary implants were effective in reversing the effects of hypophysectomy, his pituitary extracts were ineffective (Sawin 184). Besides these discoveries, other scientists reported that hypophysectomy in dogs caused atrophy of the adrenal cortex (Rolleston 64).

Today the diagnosis of acromegaly and gigantism is usually made by measuring IGF-1 levels because growth hormone secretion is pulsatile, even in hypersecreters. The failure to suppress growth below 1 ng/ml after glucose administration helps confirm the diagnosis. It is also wise to measure levels of prolactin (a pituitary hormone that stimulates the secretion of milk and can cause impotence and infertility) because pituitary tumors may co-secrete growth hormone and prolactin. Magnetic resonance imaging (MRI) of

the pituitary gland helps localize not only the site of the pituitary tumor but also its size and invasiveness. Selective surgical removal of the pituitary tumor in patients with gigantism or acromegaly is successful in correcting this endocrine disorder in about 85% of patients with micro adenomas (small benign pituitary tumors) and in about 55% of patients with macro adenomas. For example, surgical resection of growth hormone secreting pituitary tumors normalizes IGF-1 levels in about 70 to 90% of patients with micro adenomas and in less than 50% with invasive tumors. An experienced pituitary neurosurgeon is necessary for the best results.

Unfortunately, patients with a persistently elevated IGF-1 have a 1.8-fold increase in mortality compared to that of the normal population (Seaborg 20). When IGF-1 levels return to normal, long-term survival rates are comparable to those of the normal population. Medical therapy includes medications such as dopamine agonists (stimulus) including cabergoline and somatostatin analogues that inhibit growth hormone secretion, and growth hormone antagonists such as Pegvisomant, which block growth hormone receptors. About half of the patients treated with somatostatin and about 20% of those treated with cabergoline develop normal IGF-1 levels. Better results occur with cabergoline treatment in those patients whose tumors secrete both growth hormone and prolactin. Growth hormone receptor antagonists block the growth hormone receptors. About 90% of patients develop normal IGF-1

levels while receiving this medication. Because abnormal liver function develops in some patients receiving Pegvisomant, liver function tests are advised. Radiation therapy is recommended for those with incompletely resected tumors, for non-surgical candidates and for those who do not respond to surgical and medical therapy (Seaborg 20). The response to radiation therapy may take years to lower growth hormone levels. In about 60% of patients with growth hormone secreting tumors IGF-1 levels do normalize within six years of radiation treatment.

Because about 15% of patients with growth hormone secreting tumors have persistent or recurrent disease, IGF-1 levels should be monitored postoperatively. New and improved medications are being developed that will improve the care of patients with gigantism and acromegaly.

---

### Giants in mythology, art, and history

---

Similar to the representation of dwarfs, the representation of giants in art reveals a broad spectrum of positive and negative associations, but the extremes of both valuations are more noticeable in paintings of giants than in those of dwarfs. In the vase paintings of classical antiquity and in Renaissance and Baroque paintings that allude to antiquity, giants are represented according to narrative details in classical myths from Homer, Hesiod, Ovid, and others. In some examples, the artists use exaggeration and caricature to suggest the physical manifestations of specific character traits.

More often characterized as negative rather than positive, the mythological Titan Saturn and the Cyclops Polyphemus, for example, are depicted with monstrous proportions and bestial facial features and behavior that reflect their anger and destructive powers. The mythological noble giants such as Prometheus and Heracles (Hercules), however, are often represented with more normal proportions enhanced by highly developed muscles in the torso and limbs and a strong noble face. Paintings of giants that allude to biblical stories and to legends about Christian saints also focus on the distorted features of the “bad” giants and the noble features of the “good” giants. The biblical giant Goliath is represented most often as a huge angry decapitated head with closed eyes and dark, bushy hair and beard, a marked contrast to the delicate features of the boy David, his heroic slayer. On the other

**Figure 4-2**

Black-figure oinochoe (vase), *Ulysses (Odysseus) and his Companions Blinding Polyphemus* (Athens, Greece, 6th to 5th century BCE, Paris, Louvre)



hand, St. Christopher, whose story in *The Golden Legend* emphasizes the devotion and courage of a man who “sought Christ” (Attwater 84) and carried him on his shoulders across a river, is often represented as an abnormally tall man with long limbs, gentle features and humble expression. As in the paintings of dwarfs, contrast between the “normal” and “abnormal” is established by depicting the giant’s body or the giant’s head next to the bodies of ordinary mortals. In our research of paintings that depict giants, we have found more artistic representations of fictional rather than historic giants.

In Greek antiquity, the story of the Gigantes or Giants was especially popular as a subject for vase painting. The Giants were

born when the blood from the mutilation of Uranus fell upon the ground; these monstrous creatures are called Gegeneis, which means ‘earth-born.’ Details of the battle are many and varied, but it is generally agreed that the struggle was fierce, ending with the imprisonment of the giants under the earth, usually in volcanic regions where they betray their presence by the violence of their natures.<sup>177</sup>

The animal, reptile and insect imagery of various classical Greek vase paintings that narrate the stories of fierce giants such as Polybotes and Porphyriion suggests the association of giants with bestiality, but the proportions of the giants in the paintings are similar to those of the Olympian gods, and there is no evidence of the serpent like legs found in Roman sculpture and mosaic scenes of the Gigantes.<sup>178, 179</sup>

Perhaps the most famous of giants in classical mythology is Polyphemus, the son of Poseidon and the nymph Thoosa. Polyphemus belongs to the one-eyed race of Cyclopes, “a gigantic, insolent, and lawless race of shepherds, who lived in the south-western part of Sicily, and devoured human beings.”<sup>180</sup> In Homer’s *Odyssey* Polyphemus is portrayed with graphic imagery that emphasizes his size and strength. Homer describes him as a vengeful and headstrong giant, a

“piece of work, by god, a monster/ built like no mortal who ever supped on bread,/no, like a shaggy peak, ... a man-mountain/rearing head and shoulders over the world.”<sup>181</sup> Polyphemus is easily tricked by the wily Odysseus whom Polyphemus imprisoned with his fellow sailors in a cave. Odysseus later brags that, having planned their escape but making the giant drunk, he and his men

seized our stake with its fiery tip/ and bored it round and round in the giant’s eye/till blood came boiling up around that smoking shaft/and the hot blast singed his brow and eyelids round the core/ and the broiling eyeball burst—/its crackling roots blazed/and hissed ... (*Odyssey* 9, ll.433–9).

Odysseus’ craftiness enables him and his men to hide under the bellies of Polyphemus’s sheep, thus freely

**Figure 4-3**

Sebastiano del Piombo, *Polyphemus* (1512, Rome, Villa Farnesina)

A Renaissance fresco of *Polyphemus* by Sebastiano del Piombo (**Figure 4-3**, 1512, Rome, Villa Farnesina) portrays a more intimidating giant with the appearance of brute strength in his arms and legs. The large nose and protuberant chin as well as unusually large hands suggest that del Piombo's Polyphemus may have been based on a model with acromegaly, hence the broader rather than longer bones. Although there is no other figure in the painting to invite comparison, del Piombo's giant seems to dwarf the trees in the surrounding landscape. Like the suggestion of weakness in the vase painting of Polyphemus, his shepherd's lute and stick hint at a gentleness not associated with Odysseus' antagonist.

A similar irony associated with the paradox of the weak giant is apparent in paintings of the biblical story of David and Goliath in the book of Samuel. The first biblical reference to giants appears in Genesis 6:4: "There were giants in the earth in those days," who, according to the story, disappeared for the most part after Noah's Flood with a few notable exceptions. The exception made famous in the story of David and Goliath in Samuel I attracted numerous Renaissance and Baroque artists.<sup>182</sup> The giant Goliath is described as "a champion out of the camp of the Philistines, ... whose height was six cubits and a span" (I Samuel 17:4) (approximately nine feet tall). Calling for a challenge from Saul,

escaping through the cave's opening, from which Polyphemus has removed a large rock that had kept the men imprisoned. An Athenian vase painting on a black-figure oinochoe of *Ulysses (Odysseus) and his Companions Blinding Polyphemus* (**Figure 4-2**, 6th to 5th century BCE, Paris, Louvre) shows the huge Polyphemus seated in the reclining position of the victim, his long limbs and torso almost double those of Odysseus and his companions. In this example, the artist's emphasis on Polyphemus' helplessness

suggests the relative and ironic weakness of the drunk and slow-witted giant in the face of cleverness. The fact that Polyphemus was incapacitated by a stake thrust into his one eye underlines the giant's lack of peripheral or lateral vision perhaps caused by a pituitary tumor. The problem would have been made worse by the existence of only one eye, and slow reflexes, the latter caused by his alcoholic state.

the leader of the Israelites, Goliath intimidates the army of the Israelites. Eventually David, the young son of Jesse, claims that because as a shepherd he rescued his father's sheep from a lion and a bear, he can fight Goliath without the aid of armor:

And he took his staff in his hand and chose him five smooth stones out of the brook, and put them in a shepherd's bag which he had, even in a scrip; and his sling was in his hand; and he drew near to the Philistine. And the Philistine came on and drew near unto David, and the man that bore the shield went before him. And when the Philistine looked about, and saw David he disdained him; for he was but a youth, and ruddy, and of a fair countenance.... And it came to pass, when the Philistine arose, and came and drew nigh to meet David, that David hasted, and ran toward the army to meet the Philistine. And David put his hand in his bag, and took thence a stone, and slang it, and smote the Philistine in his forehead, that the stone sunk into his forehead; and he fell upon his face to the earth (I Samuel 17:40–42, 49–50).

After wounding the giant Goliath with only a slingshot, David uses the giant's sword to cut off his head and "took the head of the Philistine, and brought it to Jerusalem" (I Samuel 17:54).

The details of the biblical story accentuate the contrast between the giant's advantage of age, large size, and armor and the shepherd boy's disadvan-

tage of youth, small size, and lack of armor, thus magnifying David's role as a hero. To the physician with knowledge of pituitary function, however, David's victory is not so surprising, considering the fact of a giant's natural disability. In addition to the lack of peripheral vision caused by a pituitary tumor, other metabolic manifestations of gigantism and acromegaly could have impeded Goliath's ability to fight. For example, he might have had symptoms of arthritis, of carpal tunnel syndrome manifested in numbness in the hand with difficulty in tightly holding his sword, of a weakened heart from cardiomyopathy, or of diabetes mellitus possibly manifested in nerve pain and hyperglycemia. These ailments, which are especially common in giants, could have given the giant a significant disadvantage against the agility and wit of a young, fearless boy whose quick movements may not have been seen clearly by Goliath.

Although little was known about the causes of gigantism until the late nineteenth century, the biblical story was a favorite among Baroque artists who made effective use of the dramatic and visible features of the abnormality. In works by Caravaggio, Orazio Gentileschi, and Gian Domenico Cerrini, the oversized decapitated head of the giant is juxtaposed with the slight figure of the boy David, and it is almost a third of the size of the young shepherd's entire body. Goliath's bushy hair and beard also distinguish him from the boy's innocent, beardless appearance. The giant's closed eyes and evidence of a wound on the forehead clearly

announce Goliath's death at the hands of the delicate, youthful David.

The face of Caravaggio's Goliath in *David with the Head of Goliath* (Figure 4-4, 1610, Rome, Galleria Borghese) shows the giant's downcast eyes as if expressing regret, a wrinkled forehead accentuating the consternation of the eyes, and an open mouth caught in its agonizing last breath. It is well known that in the tradition established by Giorgione, Caravaggio "inserted himself into the biblical story" (Puglisi 363), not as David, however, but as Goliath. Caravaggio created two other paintings of the David and Goliath story, both of them less dramatic than the Borghese work.<sup>183</sup> Scholars have speculated about the dating of the Borghese painting, "most likely ... subsequent to Caravaggio's murder of Tommasoni—which occurred on 29 May 1606—perhaps also because of the dramatic nature of this picture" (Moreno and Stefani 198). Further speculation invites the idea that the use of self-portraiture reflects Caravaggio's self-condemnation as a murderer. Caravaggio scholars also subscribe to the hypothesis that "David is a portrait of the painter rejuvenated, which makes the painting a double self-portrait" (Moreno and Stefani 198). The painting is fraught with overt symbolism representing the giant's pride in oversized dimensions.<sup>184</sup>

---

#### Figure 4-4, facing page

Michelangelo Merisi da Caravaggio,  
*David with the Head of Goliath* (1610, Rome,  
Galleria Borghese)





The face of Goliath resembles the face in Caravaggio's painting *Medusa* (1598, Florence, Uffizi) in which a monstrous female head with gigantic proportions is also thought to be a self-portrait of the artist. Although scholars explain the self-portraiture in the *Medusa* as an experiment in the use of realism, the artist's fascination with the character of the villain, and specifically, the villain represented as giant, is apparent in both paintings.<sup>185</sup>

#### Figure 4-5

Orazio Gentileschi, *David with Goliath's Head* (1610, Rome, Galleria Spada)

Another Baroque work that conveys a more sympathetic view of Goliath and a sobered, meditative David is Orazio Gentileschi's *David with Goliath's Head* (Figure 4-5, 1610, Rome, Galleria Spada). This painting shows "David in absorbed meditation after decapitating the giant ... almost as if he commiserates with Goliath who has dared to challenge divine

power" (Vicini 81). In comparison to the more effeminate youths of many paintings on this subject, Gentileschi's David is older and stronger looking, and his hefty leg juxtaposed with Goliath's head emphasizes the size of the giant to an even greater extent. The greenish yellow hue of the giant's face may be intended to show post-mortem changes but could also represent the pre-mortem condition of Addison's disease secondary to insufficient secretion of adrenal cortical stimulating hormone (ACTH) that stimulates adrenal cortical secretion caused by pressure from a pituitary tumor that secretes growth hormone.<sup>186</sup>

A later seventeenth century painting of the biblical story in I Samuel employs Caravaggio's technique of exaggerated contrast between the giant's head and the slim, almost effeminate body of David. Gian Domenico Cerrini's *David with Goliath's Head* (Figure 4-6, 1653, Rome, Galleria Spada) portrays a more youthful looking David with stunned, upward looking eyes suggesting a state of shock or perhaps fear at his accomplishment. Here the giant's head is at least a third of the size of David and rests precariously on the base of a broken classical pillar. The giant's wrinkled forehead, downcast eyes and barely visible wound suggest his recent anger and perhaps incredulosity that such a delicate, smooth-faced boy could pose a threat and kill him with a single small blow. David's lavish sash and partially rent shepherd's tunic further the contrast. A serpent shaped slingshot and the cast aside sword are the only evidence, apart from the wound, of the boy hero's act of violence.



Cerrini's painting has been described as similar in style to Guido Reni's *David, Conqueror of Goliath* (1638, Paris, Louvre) (Vicini 218). Reni places the boy David in a theatrical dancer's pose, elegantly draped with furs and feathers and a red feathered cap that signify his early vocation as a hunter. Looking into the distance, Reni's David seems oblivious to his bounty of the giant's head, which rests on a pedestal, eyes closed, the hand of David grasping a forelock just above the wound on the giant's forehead. As in the Caravaggio painting, the giant's head appears to be overly large in proportion to the size of David's body, thus drawing attention to the boy's remarkable feat. As in Cerrini's painting, the elegantly braided leather slingshot that comes to a triangular head mimicking that of a cobra seems inadequate, though symbolically intimidating, for the job of giant killing.

In all of these Italian Baroque paintings of David and Goliath, the contrast between a youth on the verge of manhood and the older and larger giant begs the question of the story's credibility. How could such a boy have defeated such a "monster" with a boy's weapon? Even though the typical loss of peripheral vision caused by a pituitary tumor and other associated medical problems in giants could have impeded the giant's awareness of David's presence, neither the biblical writer nor the painters of this story would have had any knowledge of the endocrine abnormalities associated with gigantism. Furthermore, the artist's placement of the wound in the center of the forehead would



suggest that Goliath's loss of peripheral vision was not a factor in David's victory. Did the story originate from an actual incident in which, unbeknownst to the storyteller, the physical impediments of gigantism led to a memorable heroic defeat by a seemingly ill matched adversary?

**Figure 4-6**

Gian Domenico Cerrini, *David with Goliath's Head* (1653, Rome, Galleria Spada)



**Figure 4-7**

Francisco José de Goya y Lucientes, *Saturn Devouring his Son* (1821–23, Madrid, Museo del Prado)

Whereas the paintings of Polyphemus and Goliath emphasize the paradoxically intimidating, yet relatively helpless, appearance of mythical or legendary giants, two paintings of giants by the nineteenth century Spanish artist Goya y Lucientes suggest a more symbolic rather than narrative reference to the endocrine

condition of gigantism. Goya's *Saturn Devouring his Son* (Figure 4-7, 1821–23, Madrid, Museo del Prado) alludes to the classical myth in which Saturn, the father of the Olympian gods in Roman mythology (Cronus in Greek mythology), eats his children because he fears they will overtake him. Goya's use of the myth, however, has a more complex purpose than mere representation of a familiar story. In Goya's painting, completed before the artist went into self-imposed exile, the giant is portrayed with expressionistic detail: huge prominent eyes and long bony limbs, all in exaggerated contrast to the humanlike figure he is devouring.

Considering Goya's anti-monarchist sympathies and the painting's overtly expressionistic image of a deranged and violent father, the figure of the giant Saturn may represent Goya's negative views on war. In his essay "The Mystery of Goya's *Saturn*" Jay Scott Morgan questions whether the painting is the artist's "sardonic commentary on Spain's recent war with France," possibly "a symbol of war itself, the culminating portrait of the horrors he chronicled in his series of etchings, *The Disasters of War*, in 1810–1820."<sup>187</sup> In an effort to dramatize the inhumanity of war and/or political violence, Goya uses some of the characteristics of the endocrine abnormality of gigantism to emphasize the negative power of tyranny and destruction. The familiar classical myth also adds a layer of meaning in its reference to the consequences of "fear and jealousy" (Morgan) in the child of a father figure who may represent a more generalized form

**Figure 4-8**

Sir Peter Paul Rubens, *Saturn Devouring His Son* (1636, Madrid, Museo del Prado)

of patriarchal power of government authorities over the masses. In his monograph on Goya, art historian Robert Hughes sees the figure of Saturn as “the combination of uncontrollable appetite and overwhelming shame that comes with addiction— Saturn goggle-eyed and gaping, tormented by his lust for human meat, for an unthinkable incest.”<sup>188</sup> Saturn’s gnarled hands and startled, prominent eyes also illustrate the association of arthritis and goiter in gigantism. The disproportionately long bony limbs call attention to his size and awkwardness. While these visual features of gigantism have scientific validity, the general effect is that of a sub-human, almost animalistic form, again suggesting the symbolic rather than realistic intent of Goya’s painting.

In a comparison between Rubens’s *Saturn Devouring His Son* (Figure 4-8. 1636, Madrid, Museo del Prado) and Goya’s *Saturn*, the Rubens painting, “which was the origin of Goya’s idea” (Hughes 383), makes clear the difference between Rubens’ Baroque naturalism and Goya’s expressionism in depicting the endocrine abnormality of gigantism. In Rubens’s more humanistic painting of the classical myth, an aging Saturn struggles in the act of devouring his child. Stooped over the struggling child, he frowns with a concentration that has none of the agony of Goya’s Saturn but expresses the dooming vengefulness of the



Roman god. Known for his tendency to convey Ovid's stories "simply as stories about love and passion and their sequels of betrayal, loss and vengeance" (Belkin 396), Rubens portrays the god's determination to seek revenge against one of his progeny who have threatened to supersede him. The broad limbs, disproportionately large hands and evidence of large bones suggest that the model for Rubens's giant may have been an acromegalic, yet giants and acromegalics seldom reach old age because of cardiomyopathy with cardiac failure and other complications. Whether or not Rubens used an actual giant for his model is therefore questionable, but he does convey the emotion of a once powerful god who has become angry and vengeful, grasping to maintain control. Rubens may have aimed to portray the unusual muscularity and large bone structure of an otherwise normal elderly man in order to dramatize his subject's role as a jealous father and his goal to protect himself from his children.

More abstract than either Rubens's or Goya's paintings of Saturn is Goya's controversial painting *The Colossus* (Figure 4-9, 1810–12, Madrid, Prado) (see p. 124). Originally titled *The Giant*, the painting is dominated by the large muscular figure presented in three-quarter pose with his back to the viewer over a vast landscape. Proportionately muscular and strong looking, this dark-haired giant with closed eyes, whom Hughes compares to "a blind boxer" (287) has only the gnarled hand of an acromegalic without evincing other more exag-

gerated features of gigantism. As in Goya's *Saturn*, however, the use of contrast in size between the Colossus and other human figures in the painting suggests the association of gigantism with intimidation, violence, and power. As in the other paintings of "bad" giants discussed in this chapter, the exaggeration of size characteristic of this endocrine abnormality gave artists a natural image for gigantism as a metaphor for political tyranny.<sup>189</sup>

Although artistic representations of giants figure more prominently as intimidating, vengeful, and monstrous entities, stories of "good" giants or of superhuman men with stature of heroic and epic proportions also abound in paintings with classical or religious themes. The demi-god Hercules and the Titan Prometheus are frequently portrayed with giant-like features although neither is technically referred to as a giant in classical literature. Both Hercules and Prometheus were popular subjects for Greek and Roman vase paintings and for Renaissance and Baroque paintings that emphasize strength, size and perseverance as masculine virtues that enable these god/heroes to overcome almost impossible obstacles. An Etruscan hydria (vase) (530–525 BCE, Paris, Louvre) depicts Hercules behind Cerberus, the ferocious dog of Hades in the center of the narrative panel. Fetching Cerberus from Hades and taking him to Hercules' master Eurystheus and back to Hades again, Hercules thus completes the final (twelfth) and most difficult labor under the command of Eurystheus. Here the painter uses the juxtaposi-

tion of man and beast to emphasize Hercules' size and strength. Behind the three-headed dog, Hercules easily overpowers his foe while demonstrating, by contrast, his superior strength and size to that of his master Eurystheus, who hides in a pot.

Paintings of classical themes in the Renaissance and Baroque periods exaggerate the size of Hercules to a greater degree than is seen in ancient art. A painting in two panels, *The Labors of Hercules: Hercules and the Hydra* (Figure 4-10, 1460, Florence, Galleria Uffizi) by Italian painter Antonio Pollaiuolo, portrays a brawny Hercules pursuing his second labor, overcoming the Lernean Hydra. Large shoulders and a broad back suggest extraordinary muscular development. Pollaiuolo is thought to have regarded Hercules as "an expression of the pure force of nature, conceived as a total and self-sufficient reality ... ready to fight its bestial aspects," a metaphorical, if not clinical, giant, in fact.<sup>190, 191</sup>

Similar to figures of Hercules in size and strength, the figure of Prometheus presents a dramatic image of a Titan as a giant with human proportions. A symbol of both humanity and suffering, Prometheus was associated with his role as creator of the human race, and was to the "Athenians ... the benefactor of mankind and the father of all the arts and sciences" (Larousse 95). Although few images of Prometheus appear in classical vase paintings, he was a popular subject in the Baroque period. In the Greek myth, Prometheus is punished by Zeus for having stolen fire from the

god Hephaestus and having given it to man. Zeus sends Hephaestus and others to bind Prometheus with indestructible chains to one of the crests of Mount Caucasus, There “an eagle with outstretched wings, sent by Zeus, fed upon his immortal liver; as much as the winged monster devoured during the day, that much grew again during the night.”<sup>192</sup> Only Hercules, an equally powerful demi-god with human proportions, manages to rescue Prometheus. Both Prometheus and Hercules later achieve immortality in the Olympic pantheon.



**Figure 4-10**

Antonio Pollaiuolo, *The Labors of Hercules: Hercules and the Hydra* (1460, Florence, Galleria Uffizi)

The painting of *Prometheus Bound* by Rubens (and the eagle painted by Frans Snyders) (Figure 4-11, 1611–18, Philadelphia, Philadelphia Museum of Art), dramatizes Prometheus' impressive size by "showing Prometheus in strong foreshortening, his massive thighs drawn up in pain" (Belkin 132), a technique that also draws attention to the giant's well developed musculature. Prometheus' protuberant jaw suggests the presence of acromegaly despite his otherwise normal proportions. Rubens's drawings and paintings of both Hercules and Prometheus show similar strength and cunning on a gigantic scale. The painting seems to equate Prometheus' gigantism expressed in the size, physical force and energy of the Titan with his power to challenge the fierce eagle and still endure the severe punishment Zeus exacts. Yet, despite the image of Prometheus' superhuman powers, the painting's use of normal human proportions creates a representation of human virtue similar to that of Hercules.

In contrast to the muscularity and strength evident in paintings of Hercules and Prometheus, the features of gigantism apparent in figures of another good giant, St. Christopher, usually reflect the saint's height rather than his muscularity. According to legend,

Christopher was a man of gigantic stature who wished to serve the mightiest of masters. A king and Satan having both disappointed him, he sought Christ, living alone by a ford where many travelers

passed. One night he was carrying a child across the river when the child became so heavy that Christopher could hardly get across. 'No wonder!' said the child. 'You have been carrying the whole world. I am Jesus Christ, the king you seek' (Attwater and John 84).

Like Prometheus and Hercules, Christopher is depicted in art as a symbol of strength and human virtue.

**Figure 4-11**

Sir Peter Paul Rubens (the eagle painted by Frans Snyders), *Prometheus Bound* (1611–18, Philadelphia, Philadelphia Museum of Art)



Dutch and Flemish Renaissance paintings of St. Christopher portray a man whose exceptional height rather than brawn conveys the strength required to carry “the whole world” and whose facial features and a meditative expression convey a contemplative mind dwelling on his mission. Dutch painter Dieric Bouts’s panel of *St. Christopher Carrying the Christ Child* in the *Pearl of Brabant* altarpiece, right wing (Figure 4-12, 15th century, Munich, Germany, Alte Pinakothek) portrays the giant crossing the river with sturdy limbs and a facial expression of deep concentration. His considerable height is accentuated by his long, exposed thighs, and the verticality of the rocky landscape that frames the portrait. An unusually large head further amplifies the giant’s size. The pained expression on the saint’s face and broad expanse of his brow suggest that Bouts may have focused on this feature of the giant using more realistic detail than he did on the rest of the body, which appears more wooden in its conception.<sup>193</sup>



**Figure 4-12**

Dieric Bouts, *St. Christopher Carrying the Christ Child* in the *Pearl of Brabant* altarpiece (15th century, Munich, Germany, Alte Pinakothek)



**Figure 4-13**  
Hans Memling, The Moreel Triptych,  
*St. Christopher Carrying the Christ Child*  
(1484, Bruges, Belgium, Groeninge Museum)

More detailed symbolism crowds the background of the Flemish painting of *St. Christopher Carrying the Christ Child* by Hans Memling in the *Moreel Triptych* (**Figure 4-13**, 1484, Bruges, Belgium, Groeninge Museum) in which the height of the saint in contrast to the landscape is the primary evidence of his gigantism. The lankiness of Memling's St. Christopher is emphasized by the tall staff he carries and his towering stance in the rocky landscape. Evidence of a goiter in the saint's neck is a reminder of the medical association of gigantism with

an enlarged thyroid gland. No other features of the abnormality besides the giant's height are evident, however. Memling's St. Christopher is portrayed with the serious cerebral mien of a man on a grave mission rather than with the brawn and physical energy of the Rubens saint described below.



Like his paintings of *Prometheus and Hercules*, Rubens's portrayal of the saint in *St. Christopher and the Hermit* (Figure 4-14, 1611, Cathedral, Antwerp, Belgium) depicts Christopher as a symbol of strength and humanistic virtue. Unlike the earlier northern European paintings of St. Christopher that represent this icon of religious faith as a tall, gaunt figure with long limbs and questionable muscular strength, Rubens's painting of the saint suggests that the artist could have substituted Hercules for St. Christopher, so robust is his demeanor. Like his ancient forebear, Rubens's St. Christopher seems almost encumbered by his exceptional musculature as he leans on a staff to complete his task of carrying the Christ child across a dangerous river. In this example, however, it is more likely that Rubens used an actual giant for a model or at least observed such features in an actual giant or acromegalic. The saint figure's exceptionally large hands suggest acromegaly. He also appears to have a prominent left breast, similar to the abnormality caused by a pituitary co-secretion of both growth hormone and prolactin.

Fascination with size as an indication of grotesqueness or "otherness" was at its height in the sixteenth and seventeenth centuries when artists displayed their knowledge of human anatomy, especially in the paintings of mythological, biblical, and legendary giants. Although many of the paintings discussed here suggest derision and disdain of "bad" giants such as Polyphemus and Goliath and solemn respect for "good giants"

such as Prometheus, Hercules, and St. Christopher, some artists used images of gigantism to convey playful humor or satire. It should come as no surprise that the Parco di Mostri near Viterbo, Italy, built in 1552 by Pirro Ligorio for the Prince Orsini, includes larger than life sculptures of mythological and fantastic figures with gigantic proportions, playfully situated in a park setting that invites visitors to compare themselves to the giant figures' huge dimensions, maybe even tremble at their monstrous features.

**Figure 4-14**

Sir Peter Paul Rubens, *St. Christopher and the Hermit* (1611, Cathedral, Antwerp, Belgium)



By the late eighteenth century an interest in anatomical anomalies took a turn toward realistic documentation, giving rise to numerous prints—engravings, etchings, and lithographs of dwarfs and giants as well as anatomical deformities that could be reproduced in popular journals for the public. A common type of print from this period was one that shows a giant and a dwarf side by side. Much like the Velasquez paintings that use juxtaposition to draw attention to a dwarf's short stature, the side by side pictures of dwarfs and giants emphasize their remarkable differences, implying that both are "exotic" or "different," belonging to that classification of "the other" that designates them as "freaks" of nature. Fascination with the concept of classification was particularly prevalent in the eighteenth century when scientists and philosophers attempted to create a modern adaptation of the medieval and Renaissance concepts of the Great Chain of Being in which each species and each social class has its niche in a linear construct.<sup>194</sup>

Among the eighteenth century collectors of "freakery" was John Hunter, the British surgeon who sought specimens from the dead, robbing graves and secretly assembling skeletons, aborted fetuses, and organs of both humans and animals in order to study anatomy, physiology and the mechanisms of normality and abnormality. Almost 14,000 specimens from Hunter's collection, originally kept in the private museum in his house at Leicester Square, were acquired by the Royal College of Surgeons in 1799 and are currently housed in the

Hunterian Museum at Lincoln's Inn Fields in London. Three thousand of those specimens are on display for the public. The skeleton acquired in Hunter's most notorious grave robbery was that of Charles Byrne, the Irish giant whose fame had made him a source of entertainment and wonder throughout the British Isles.

Although no evidence in the form of a will has been found, newspaper reports at the time stressed Byrne's horror at the thought of his body falling into the hands of one of the many anatomists who were keen to acquire it. He arranged with friends to seal his body in a lead coffin, for burial at sea. But, while his casket was buried at sea, Byrne's body was not in it. The undertaker had been bribed and the body was removed from the coffin. Competition among anatomists to obtain the body was widely reported in the press, driving up the price. John Hunter obtained the body for a sum rumoured to be over £500. To avoid detection, he hurriedly chopped the body into pieces, and boiled it down into the bones. Only after four years did Hunter admit to having the skeleton of Charles Byrne.<sup>195</sup>

At the Hunterian Museum today one can imagine the extent of Hunter's fascination with the extremes of the human form. The museum's display we noted at the beginning of this chapter resembles that of a modern art installation in which the contrast of size between the Irish giant and the Sicilian dwarf is the artistic message


of the juxtaposition and raises the question of what is "normal."

Thomas Rowlandson's satirical Drawing of *Charles Byrne, The Irish Giant with an Admiring Audience* (Figure 4-15, 1782-3, Hunterian Museum, Royal College of Surgeons) is also displayed at the museum. As was the custom for such pictures, Rowlandson "compares his (Byrne's) size with that of normal individuals who view him with curiosity. A youth is trying on one of the giant's boots and a young lady is comparing one of her dainty feet with the larger version."<sup>196</sup> Byrne stands above the crowd of curious onlookers, almost haughty and patronizing as he reaches his hand to touch the head of one of them. Many eighteenth and nineteenth century journals featured prints of the Irish giant and other popularly known giants usually shown standing next to average sized people or dwarfs.



**Figure 4-15**

Thomas Rowlandson, Drawing of *Charles Byrne, the Irish Giant with an Admiring Audience* (1782-3, Hunterian Museum, Royal College of Surgeons)



**Figure 4-16**

Paul Serusier, *Louise or The Breton Servant*  
*Serusier* (1890, private collection)

Although artistic representations of dwarfs and giants were rare after the eighteenth century, a late nineteenth century painting by the French artist Paul Serusier evinces dignity rather than mockery in its portrait of a woman giant or acromegalic. In *Louise or The Breton Servant* (**Figure 4-16**, 1890, private collection) Serusier uses naturalistic detail to reveal the characteristics of an acromegalic woman portrayed in a frontal pose. Her prominent chin, spade like hands, and enlarged thyroid are all accurate representations of the physical manifestations of adult onset gigantism or acromegaly. Serusier was one of the founders of the French Nabis group of painters who during the last decades of the nineteenth century “met regularly to discuss theoretical problems of art, symbolism, occult sciences, and esotericism.”<sup>197</sup> The close up portrait of the maidservant draws attention to her size, solidity, and robustness, qualities among the Breton peasantry that Serusier admired (Olga’s Gallery). Here, the simplicity of composition and use of color to define space magnify the large dimensions of the acromegalic in a domestic setting without using another figure for contrast, thus inviting the viewer to regard Louise as an individual rather than as a freak of nature. The effect is similar to that of Picasso’s representation of the dwarf dancer *La Nana* (**Figure 3-22**).

Given the history of artistic representation of giants—the “bad” and the “good” giants immortalized in paintings of mythological and biblical stories, the freak show figures dehumanized in the lithographs and engravings of popular journals—it is tempting to think of gigantism represented in art as an exaggerated concept of size rather than as an anatomically correct depiction of an endocrine disorder of the pituitary gland. Fascination with size prevailed in political and military arenas as well as in art. As late as the eighteenth century, giants, like little people, were exploited for political power and material gain. In *Berlin Rising, Biography of a City* historians Anthony Read and David Fischer write that the Prussian emperor Fredrich Wilhelm (1688–1714) “was constantly on the lookout for taller and taller men” for his army.<sup>198</sup> Receiving gifts of giants from other monarchs, at “one point, he even tried breeding his own giants, forcing very tall men to marry very tall women in the hope that their children would be even taller than their parents” (Read and Fischer 37). But Frederick Wilhelm’s greed backfired when not only the goal of his attempts at breeding failed but the giants “tended to be slow, simple-minded, physically fragile, and in some cases actually deformed. They were useless as soldiers,” but “Friedrich Wilhem regarded them as far too valuable to risk in a real fight” (Read and Fischer 37). Despite the ostensibly deserved ironic outcome of the emperor’s experiment, Read and Fischer’s assessment of Fredrich Wilhelm’s ineffectual giants seems exaggerated.

Although gigantism may cause slow movement because of its association with arthritis or cardiac dysfunction, giants are usually of normal intelligence because most giants and acromegalics reach normal brain development and maturity before the onset of a pituitary tumor. Some giants are agile enough to play basketball in the National Basketball Association. Perhaps Read and Fisher’s exaggeration is a sobering reminder of the temptation to generalize and classify those whose appearance falls outside what most consider “normal.”

ET IVERVM LAC TANS CVLIS MIRABILE MASTRAME



EN MAGNVM NATVRA  
MIRACVIVM

MALDALENA VEN TVRA EX  
QVANDO ALI PVLLI AB D.  
SANNITES VVLGO ELV  
BRVZZO FECHT N' APCH  
TANI ANNOVM 1577  
QVOD INSOLENS EST CV  
ANNVM 37 ACEPIE COL  
MT PVBI SCIPRE FOQVE  
BARBA DESSINA AC HOV  
LIXA EST VIT POTIVS

ALICVIVS MAGETRI BARRATI  
ESSE VIDEATVRE QVARI MV  
LIERIS QVAL TRES FILIOS  
ANTE VIDERIT QVOS EX  
VIBO SVO FELICI DE AMICI  
QVEM ADESSE VIBES HA  
BYERAT

IOSEPHVS DERIBERA HIS  
PANVS CHRISTI CIVAE  
INSIGNITVS SVI TEM  
PORIS ALTEP APILLES  
IVSSV FERDINANDI II  
DVCIS IN DHALC ALA  
MAROLI PROREGIS AD  
A IVVM NIRE DEPVXIT  
XIII KALEND MART  
ANNO 1610

## Chapter 5

## “An Excess of Seed”: Endocrine Disorders of the Sex Glands, Adrenal Glands, and Parathyroid Glands

### Introduction

In the first four chapters we have documented that endocrine disorders, including hypo- and hyper-function of the thyroid gland and pituitary gland can result in abnormal metabolic activity, glandular enlargement with physical and psychological manifestations, and growth disorders. Abnormal function of the testes, ovaries, adrenal glands, and parathyroid glands can also result in physical and psychological abnormalities, changes in appearance and behavior.<sup>199</sup> Such abnormalities can raise questions about sexual identity and sexual function and the

psychological and social effects of both. It should come as no surprise that sexual disorders, aberrations and variations have been of particular interest to past as well as contemporary endocrinologists, pediatricians, psychologists, urologists, and plastic and reconstructive surgeons who treat patients with such conditions.

#### Figure 5-8

Jusepe de Ribera, *The Bearded Woman Breastfeeding* (1631, Toledo, Hospital de Tavera, Museo Fundación Duque de Lerma) (see p. 166)

Since antiquity sexual ambiguity has been a topic of fascination in western literature, art, and science. Classical myths frequently suggest such ambiguity in the figures of Apollo and Cupid, for example. Both male figures are often feminized in sculpture and painting because of their mythological association with poetry, music, and love. Sexual ambiguity is also suggested in the artistic representation of male angels whose rosy cheeks, full rounded necks and feminine curls defy traditional male classification. In the figures of Greek male deities or Christian angels, delicate calf muscles and arms, the absence of facial hair and the frequent appearance of gynecomastia hint at sexual

ambiguity. A particularly humorous example of an artist's play on gender appears in a sculpture of *Amore and Psyche* in the National Museum of Antique Art at the Palazzo Altemps in Rome in which the male Amore or Cupid figure is sculpted with a female head, and the figure of the female Psyche has a male torso but female breasts. As the sculpture's object label attests, this “baroque pastiche” of Hellenistic sculpture challenges traditional notions of what is “normal” or “natural” in human sexuality, as exemplified by demigods: “The desire to oppose nature quite deliberately is also seen in Psyche's attitude toward Amore, which repeats in reverse the gesture that is usually represented of Amore leaning toward Psyche.”<sup>200</sup> Instead of the more conventional passive stance of the female lover, the figure of Psyche takes on the aggressive male posture of leaning toward the love partner.

Similar to the way this Baroque sculpture teases the viewer by reversing sexual orientation in mythological figures, the Baroque fascination with naturalism reveals anomalies in sexual development in the guise of sexual normalcy. A dual intention seems to inform the revelation of the masculine appearance of a hirsute woman in seventeenth century Spanish artist Jusepe Ribera's portrait of Magdalena Ventura *The Bearded Woman Breastfeeding*.<sup>201</sup> The work challenges traditional notions of gender roles, in this case, that of the lactating mother as the epitome of femininity and maternity.

Although ancient Greek art may have embraced sexual ambiguity and androgyny as part of a larger spectrum of sexual identity, attitudes in ancient Rome and throughout Europe from the Middle Ages through the nineteenth century reflected a tendency to discriminate against individuals with sexual differences considered to be outside the “normal.” Individuals who physically manifested overt sexual ambiguity were treated with disrespect and disdain, often ostracized, punished or even eliminated for the aberrations over which they had no control. In Christian societies physical abnormalities, including sexual anomalies, were often associated with sin and punished as such. For example, according to Judaic tradition in the book of Leviticus 22:24, the presence of an undescended testicle in a boy child “made a man unfit to approach the altar directly,” and “[m]en with hypospadias were not regarded fit for marriage ... because the ejaculate could not achieve conception” (Medvei 32). Mothers who gave birth to hirsute children, especially females, were thought to have had vivid imaginations, and their children were thus considered tainted, even less than human.<sup>202</sup>

Despite many examples of sexually tolerant views in today’s western society, sexual ambiguity is still problematic. Contemporary literature such as Jeffrey Eugenides’ novel *Middlesex* or Diane Middlebrook’s biography *The Double Life of Billy Tipton* reveals the obstacles encountered by those whose sexual differences exclude or isolate them in society. Transvestitism,

trans sexuality, bisexuality, and homosexuality may be common terms and concepts in our language, but those who fall into such categories are not always readily welcomed in the more conservative or traditional social enclaves of the western world, even in the twenty first century.

---

### Sexual disorders controlled by the endocrine glands

---

The categories of sexual disorders controlled by the endocrine glands (testes, ovaries, and adrenal glands) include the following: hermaphroditism, pseudohermaphroditism, lateral hermaphroditism, gynecomastia, hirsutism, and virilism. A hermaphrodite is defined as “a person whose genital organs have the characters of both male and female in greater or less degree.”<sup>203</sup> A “true” hermaphrodite is characterized as “possessing both ovarian and testicular tissue as well as external sexual features of both sexes” (Stedman 700), whereas a false or pseudohermaphrodite “is distinctly of one sex (i.e. possessing either testes or ovaries) although having superficial characteristics of both,” in other words, ambiguous or atypical external genitalia (Stedman 1236). Lateral hermaphroditism is “a form of true hermaphroditism in which a testis is present on one side and an ovary on the other” (Stedman 700). Gynecomastia is the “excessive development of male mammary glands” in breasts that resemble those of females (Stedman 668). Hirsutism, which is the “abnormal presence of excessive hair, especially in women” (Stedman 709), can be one of the external signs of virilism, which is the development or presence of male secondary sex characteristics in a woman. Virilism may appear at birth or later.<sup>204</sup>

The origin of the word hermaphrodite derives from the ancient Greek Hermaphroditos, “a minor deity who had the physical characteris-



tics of both sexes” and evolved from “a combination of the names of [Hermaphroditos’] parents, Hermes and Aphrodite, who were the embodiment of ideal manhood and womanhood.”<sup>205</sup> In his *Metamorphoses*, a collection of myths from antiquity, the Roman poet Ovid tells of the nymph Salmacis who fell in love with the young god Hermaphrodite when he was hunting in a wooded area near Mt. Ida. When he rejected her advances, she pleaded with the gods to unite him with her. The gods answered her prayers and the two were united into “one person with the features of both sexes” (Kiefer 121). As a result “of this event the waters of the lake received the property of causing those who bathed therein to lose their virility.”<sup>206</sup>

According to historian Kathleen Long, from this conclusion it is apparent that the hermaphrodite in Ovid’s myth “expresses the fear of dissolution into the other, the fear that those boundaries created at the dawn of time may at any moment be transgressed.”<sup>207</sup> Long explains that the

hermaphrodite’s dual nature, at once divine and monstrous in the more menacing sense of that word (from the Latin *monstrare*, meaning to show, but also to indict or condemn) stemmed from long philosophical and religious traditions, already well-established by classical times. The hermaphrodite’s central role in early Gnostic thought, as Creator of the universe, is the most



**Figure 5-2**

Jan Gossaert, *The Metamorphosis of Hermaphroditus and Salmacis* (1517, Rotterdam, Museum Boijmans Van Beuningen) (see p. 161)

striking example of divine hermaphroditism. The hermaphrodite as subhuman or weakened figure dominates Greek and Roman depictions (Long 7).

Thus the range of artistic representations of hermaphroditism reflects philosophies that run the gamut from idealization to satire, and from naturalism to symbolism.

Compared to other endocrine abnormalities, examples of hermaphroditism in art are rare and most prevalent in works of antiquity. According to Kiefer, “one of the few representations which might have been modeled from life” is the Greek bronze statue of the “so-called Hermaphrodite of Mirecourt ... whose genitalia show a hypospadiac penis (Kiefer 121).”<sup>208</sup> Kiefer notes that “the first pictures of a hermaphrodite appeared in the textbook of Realdus Columbus published in 1559 and in the work of Ambrose Paré published in 1573” (Kiefer 121). Kiefer and others point out the “unrealistic” nature of these illustrations, but history would argue that Paré was disinclined to provide examples of any medical condition he did not personally observe.

---

### Attitudes toward sexual ambiguity in medicine, religion, and history

---

According to Daston and Park, Renaissance medical attitudes toward hermaphrodites reveal “contrasting sensibilities of wonder and repugnance,” such as those expressed, respectively, by the Italian anatomist Realdo Columbo (a follower of Vesalius) and the French anatomist Jean Riolan the Younger (Daston and Park 203).

Both anatomists wrote in the purely naturalistic vein of medical tradition, ... as academic anatomists, interested in the internal as well as external conformation of bodily organs. But whereas Columbo saw hermaphrodites as the wonder of anatomical wonders, a male and female combined in one body, Riolan, half a century later in 1614, described them as merely deformed men or (mostly) women (Daston and Park 203).<sup>209</sup>

According to Long, Renaissance views of hermaphroditism may have stemmed from Aristotle’s work on the *Generation of Animals* in which he argues that an “explanation for such deformities of excess as hermaphroditism” is “the quantity of material provided by the mother” (Long 14). Following Aristotle’s logic, “if the material supplied by the maternal womb overcomes the male seed, then a female will be born. But if the male seed should only dominate in part, and the material maintain some power, then a hermaphrodite will result” (Long 14). As in the Ovidian myth, a

negative view of the hermaphrodite seems to reflect the fear of loss of male power or dominance.

Kiefer notes “in many rabbinical commentaries on the Old Testament story of the creation of man it is held that Adam was a hermaphrodite and that the biblical story of the creation of Eve signifies separation of the two sexes” (Kiefer 121). This story supports the legend of the hermaphrodite as the divine creator of human life. Traditional Judaic culture established restrictions for hermaphrodites. The laws of the Talmud state that a hermaphrodite “had to be circumcised when eight days old, [that] he could legally marry a woman, and divorce proceedings had to be carried out according to the law. Marriage to a man was, however, not permissible” (Medvei p 35). Caspar Bauhinus, who wrote about hermaphrodites in 1614, “reviewed the Jewish laws regarding hermaphrodites, namely that they are like men in several respects and are therefore unclean after a seminal emission ... like women in that they are unclean after menstrual flow and they may not converse with men in a private place” (Kiefer 123). From these examples one can conclude that the marginalization of hermaphrodites as something less than human stems from the observation that they did not belong to either sex.

Early observations of external sex characteristics and sexual functions in humans may have provoked erroneous theories but nonetheless established significant data on sexual disorders. For example, Medvei

records observations by Wilhelm Falta in 1913 of “the effect of human castration, known in antiquity, when eunuchs played an important role” (Medvei 8) and the effect of animal castration that led to questions about the way “the gonads influence the distribution of body fat” (Medvei 8). He also notes that according to the Book of Esther 1:10, in Egyptian history the “castrate was described as of soft hair, smooth skin, unable to urinate in an arc; his ‘sperm’ is watery, his voice soft and feminine” (Medvei 32). Similarly “women who had under- or undeveloped genitalia, lacked breast development, and “had a deep voice and suffered pain when attempting intercourse were called ‘rams’” by the ancient Jews (Medvei 33), a derogatory categorization connoting both masculine and bestial associations. In the sixteenth century Ambroise Paré suggested that young women who do not menstruate become more masculine “and are called masculine women or—in Latin—viragines,<sup>210</sup> because they are robust, aggressive and arrogant, and have a man’s voice and become hairy and develop beards” caused by retention of blood and secretions.<sup>211</sup> All of the above examples imply a negative association with aberrant sexual characteristics or functions.

Perhaps the most significant breakthrough of seventeenth century observations and treatment of hermaphrodites was revealed in the discoveries and arguments made by the French surgeon Jacques Duval “who practiced at Paris and Rouen, and contended with Jean Riolan, a well-pub-

lished professor of medicine ... over the celebrated case of Marin Lemarcis, the Rouen man who had been raised as a girl” (Long 78). Duval’s conclusions were based on his observations of Marin Lemarcis, who had grown up as a girl named Marie, secured a post as a laundress in a private home and eventually became a prisoner condemned to burn at the stake for alleged sodomy in his/her relationship with Jeanne Lefebvre, a midwife who worked in the same household. Following Duval’s discovery of Marin/Marie’s male genitalia, a lengthy trial ensued at which Duval argued for the defense against the prosecution, which was supported by Jean Riolan. Riolan claimed that Marin/Marie Lemarcis was not a true hermaphrodite and was therefore guilty of sodomy. Duval’s insistence on physical examination of Lemarcis led to the conclusion that Marin/Marie was a hermaphrodite, thus saving him/her from execution because he/she was not, therefore, guilty of sodomy.

In his medical legal dossier of *Des hermaphrodites, accouchemens des femmes, e traitement qui est requis pour les relever en santé e bien elever leurs enfants* (On Hermaphrodites, Childbirth, and the Treatment That is required to Return Women to Health and to Raise Their Children Well, Rouen 1612), Duval’s account includes depositions of both parties in sixteen statements. The story begins with the confession that Lemarcis and Lefebvre met while working as domestic (female) laborers in the same household where they were required to share a bed, a common practice of the

time. When Lefebvre discovered what appeared to be the penis of Lemarcis, she naturally thought he was a man who disguised himself in woman’s dress. Lemarcis asked Jeanne Lefebvre to marry him, but Lefebvre would not engage in sexual intercourse with Lemarcis until the proposed marriage was approved by her parents. When Lemarcis changed his dress and name to those of a man and proceeded to the local church to declare his faith and apply for a marriage license, the two lovers were accosted and arrested for allegedly committing sodomy since it was thought that they were two women engaging in a homosexual relationship. After Lemarcis was imprisoned and initially condemned to die for acts of sodomy, Duval’s physical examination of Lemarcis’s genitalia provided evidence of Lemarcis’s male anatomy. The discovery of Lemarcis’s retracted penis and testicles helped explain the misidentification of his/her sex as a child.<sup>212</sup>

Duval’s defense not only saved the life of Lemarcis but also established the need for and value of physical examination for an accurate diagnosis and for objective evidence in the courtroom. It served to reinforce the tradition of the surgeon’s preference for physical evidence rather than theory to determine a medical condition. Duval’s dossier on the trial also reveals how religious dogma and the traditional physician’s reliance on theories of Aristotle, Plato, Galen, etc. obstructed scientific advancement. Duval’s stance on the Marin/Marie case marks a “significant shift being prepared in the medical profession from reliance

on classical sources to more empirical methods of inquiry; those treatises on sex, sexuality, and childbearing show that these shifts are significant for the early modern elaboration of sexual difference and of gender roles” (Long 29). Along with those of Paré, the publications of Duval “called into question (the) conservative approaches” recommended by the Sorbonne that “advocated Aristotelian and Thomistic thought over any other” (Long 29).<sup>213</sup>

---

### Medical history and etiology of sexual disorders

---

The observations by Paré and Duval indirectly led to further study and experimentation regarding sexual abnormalities. In the second half of the seventeenth century the British physician Thomas Willis (1621–1675) documented the presence of internal secretion of the male hormone testosterone via the bloodstream. Willis’s results were based on the result of castration in a young man, who then became a eunuch. They confirmed Aristotle’s observation that eunuchs differed from men (Medvei 139 ref 69). The French vitalist Theophile de Bordeu (1722–1776) was also aware of the masculinizing effects of testicular secretions and the feminizing effects of ovarian secretions and their importance to secondary sex characteristics after castration (Iason 59).

The British surgeon John Hunter (1728–1793) took experimentation further when he published a treatise in 1782 on the freemartin known to farmers as a virilized bovine female, “the first really scientific attempt to explain the occurrence of hermaphroditism” (Kiefer 126). Hunter recognized that the problem of the freemartin occurs when a cow delivers twin male and female calves, a phenomenon documented in his 1779 publication *An Account of the Freemartin in Philosophical Transactions of the Royal Society*. Because of his interest in this phenomenon, Hunter dissected three such animals and was the first to report that in the case of a

freemartin the male calf is normal, but the sterile female calf is a hermaphrodite with virilized female reproductive organs. In Hunter’s time the generally accepted doctrine was that all species were created with a fixed and never changing sexual state. Hunter’s experiments suggested to the contrary, “every animal and every part of every animal possessed an innate propensity to malformation.”<sup>214</sup> Hunter thus documented that sexual development of the external genitalia can be influenced by fetal “surroundings” (Kiefer 126).

Hunter also noted that removal of one testis failed to alter the size of the seminal vesicles and that “unilateral” ovariectomy in a “sow did not prevent twinning” (Medvei 195). He proved that bilateral castration, however, “prevented the re-growth of antlers in stags” (Medvei 195). In his treatise *The Natural History of Human Teeth* Hunter also documented that a spur of a hen, when transplanted to a cock would grow to the size of a cock spur, whereas it would not grow when transplanted to a hen (Medvei 204). These experiments were designed to study the “vital principle” (Medvei 204) independent of the nervous and endocrine systems.<sup>215</sup> Although Hunter’s experiments and observations reflected his ability as an early surgical scientist, unfortunately, neither Hunter nor his colleagues appeared to understand the importance of the experiments’ results.<sup>216</sup>

Hunter's observations, however, led to experiments by German physician Arnold Berthold (1803–1861), who was aware of his predecessor's work. Berthold documented that autotransplantation of a cock's testis to the back of the cock prevented the atrophy that occurred after orchiectomy without transplantation.<sup>217</sup> Thus transplanted testes "could produce secondary sex characteristics" through the bloodstream; this information provided evidence supporting the function of internal secretions (Medvei 218). Subsequent experiments by Berthold's colleague Rudolf Wagner (1805–1864) during the late nineteenth century failed to confirm the findings of Hunter and Berthold concerning transplantation of testes (Medvei 218).

Among those who challenged Berthold's theories about the function of the testes were scientists who studied seemingly hermaphroditic conditions in birds with "male plumage on one side of the body and female plumage on the other" (Medvei 219). Such lateral hermaphroditism must have confused the eminent German pathologist and anatomist Johann Meckel the Younger (1781–1833), Scottish obstetrician James Simpson (1811–1879), and others because, in theory, hormones should function bilaterally. In the case of some birds, however, one side has masculine plumage and the other feminine.

The existence of lateral hermaphroditism as illustrated in the above example has been documented as a medical interest since ancient times, which adhered to the belief that the "right side is the side of heat, activity, and masculinity. The left side is the side of coldness, passivity, and femininity. Normally one side or the other predominates but if the forces are very equally balanced a hermaphroditic child might result" (Kiefer 124). It is worth noting that certain plants including "[m]ost angiosperms have hermaphroditic flowers having both male and female organs."<sup>218</sup> Andromonoecy, in which plants carry both pistillate and staminate or male and female sex organs and are perfect bisexual flowers, has evolved independently numerous times and is found in approximately 4,000 species in 33 angiosperm families (Miller and Diggle 707).<sup>219</sup> Studies of flora and fauna both contributed to and obstructed progress in the understanding of the endocrinology of the sex organs.

Lateral hermaphroditism is extremely rare in humans, but the presence of dual sex characteristics has been documented.<sup>220</sup> According to contemporary endocrinologists, an absolute distinction between men and women is not always the case, since abnormal expression of bipotential precursors in the embryo may result in alterations in sexual differentiation especially when a female embryo is exposed to male hormones as in the freemartin. Thus the presence of masculinizing hormones in females may interfere with normal female sexual development and behavior. It can result in virilization

of the external genitalia. The embryo, whether it is xy or xx, grows up in a "sea" of estrogen, and there is no evidence that estrogen *per se* can cause genital abnormalities in any individual. Chromosomal errors can occur during spermatogenesis (development of sperm) or oogenesis (development of eggs).

Contemporary American pediatric endocrinologists Felix Conte and Melvin Grumbach note that female and male embryonic gonads are indistinguishable at about forty-two days of gestation and differentiate in either direction. The gonads begin to differentiate from forty-three to fifty days of gestation. Leydig cells can be identified at about sixty days with subsequent early development of male external genitalia by sixty-five to seventy-seven days of gestation (Conte and Grumbach 569). Surprisingly, female development does not require an ovary, and normal development of the mullerian ducts and uterus will occur even when "no gonad is present" (Conte and Grumbach 572). "SRY (sex-determining region of the Y chromosome) remains the acknowledged primary testis-determining gene—the one gene that can induce testis development when introduced experimentally into a chromosomal female. The SRY protein acts as a dominant inducer of testis development in mammals."<sup>221</sup> In patients with ambiguous male genitalia, well differentiated male genital ducts form only when testosterone from the testes is present (Conte and Grumbach 572).

True hermaphrodites or ovotesticular DSD (Disorders of Sexual Development) patients have both testes and ovaries. Testosterone and other androgenic hormones are required for the differentiation of the male external genitalia. Although controversial, “the most likely reason for this [the freemartin] would seem to be that male gonadal inductor substance has leaked into the female’s circulation via the placental anastomosis and interfered with ovarian development” (Medvei 203). In humans, pituitary gonadotrophins are not required to initiate prenatal testicular activity, as shown by the fact that anencephalic babies without pituitary glands have normal genitalia. For the six months following birth, male children have higher mean levels of testosterone than female children after which testosterone levels are similar in males and females until puberty. In children of about 11 or 12 years of age, in response to an increased pituitary secretion of leutinizing hormone, the testes mature with an increase in testosterone secretion in the male that continues until late adolescence. Testosterone is also required for the maturation of the seminiferous tubules (tubules that make secretions that carry sperm) that lead to a deepening voice, male hair pattern, growth of the penis, prostate, and seminal vesicles as well as an increase in muscle mass.

Along with the gonads, the adrenal glands are also involved with hormonal secretion of estrogens and androgens that can influence sexual characteristics, hair growth and distribution. Serum estradiol (estrogen)

levels are similar in male and female fetuses. In females, however, postnatal infant mammary tissue is more pronounced and usually persists longer than in the male. At pubescence the ovaries mature and estrogen secretion increases, resulting in breast and nipple development, uterine enlargement, and cornification (thickening) of the vulvar and vaginal epithelium.

The adrenal glands are remarkably enlarged during fetal life primarily because of hypertrophy of the outer part of the adrenal gland, or the adrenal cortex. The enlargement of the cortex of the adrenal glands requires pituitary secretion, a fact proven by autopsies on anencephalic infants who lack a pituitary gland. The outermost area of the adrenal cortex, the *zona glomerulosa*, produces aldosterone; the middle area, the *zona fasciculata*, produces cortisol and androgens; the inner layer that surrounds the medulla also produces cortisol and is the primary source of adrenal androgens. Following birth, there is rapid involution of the fetal adrenal cortex, and adrenal secretion of androgen precursors. The secretion of adrenal hormones causes the premature development of pubic hair before other signs of sexual development.<sup>222</sup>

Unlike the androgynous presence of both gonadal organs in true hermaphrodites, pseudo hermaphrodites have only testes or ovaries. A female pseudohermaphrodite has exclusively ovarian gonadal structures, although she may have masculinized external characteristics such as a prominent clitoris and virilism in addition to amen-

orrhea. The clinical spectrum of the feminization of the male ranges from only mild hypospadias or undescended testes to a small penis, or to a female appearance such as gynecomastia. Hypospadias occurs in 1 in 125 newborn males (Conte and Grumbach 601). A small number of affected individuals with hypospadias have chromosomal abnormalities (Conte and Grumbach 601).

Gynecomastia is also common during adolescence in the general male population, especially in mesomorphic males, and it occurs more frequently in men who smoke marijuana or take other drugs, especially those containing estrogens or those that inhibit testosterone action.<sup>223</sup> It can also occur in men with Klinefelter’s syndrome (individuals who have an extra x chromosome = xxy) and in men with estrogen secreting adrenal or testicular tumors.<sup>224</sup>

The most common cause of female pseudohermaphroditism is congenital adrenal hyperplasia (CAH) that accounts for about 50% of all patients with ambiguous genitalia (Conte and Grumbach 589). When there is an inadequate production of cortisol, adrenal cortical stimulating hormone (ACTH) rises, and the adrenal glands produce increased amounts of precursor steroids. When increased amounts of androgens are produced, virilizing congenital adrenal hyperplasia (CAH) results. Children with CAH may appear quite ill during the first few weeks of life and must be suspected of having the salt-losing type of adrenal hyperplasia. The presence

of a high potassium level, a decreased sodium level (hyponatremia), and high acidity, with low plasma cortisone levels confirms the diagnosis. Immediate treatment with cortisone, salt and hydration is necessary to prevent death.

Individuals with adrenal, testicular or ovarian hyperplasia (excess of cells) or tumors can develop male or female characteristics. “A common clinical manifestation of hyperandrogenism is hirsutism. It is defined as the presence of excess hair growth in centrally located regions, not commonly found in women.”<sup>225</sup> Hirsutism is most frequently associated with polycystic ovarian syndrome but may also be caused by other conditions including adrenal hyperplasia or tumors, with increased androgen secretion, and it may have no known explanation (Rosen and Cedars 529). Excessive ovarian or adrenal secretion of androgens or the excessive conversion of androgens in peripheral tissues causes hirsutism or virilism—increased hair growth with a male distribution and the development of other male characteristics. The adrenal hormones DHEA, DHEA sulfate, and androstenedione are weak androgens that are peripherally converted to testosterone and dihydrotestosterone by extragonadal tissues.

---

### Disorders of the adrenal glands and the parathyroid glands

---

Apart from sexual disorders, malfunction (both hypo- and hyperfunction) of the adrenal glands can be manifested in other symptoms. In 1850 British physician Thomas Addison (1793-1860) was the first to document the association of adrenal hypofunction and symptoms of weakness, salt craving, and a peculiar yellowish discoloration of the skin, now known as Addison’s disease.<sup>226</sup> Among Addison’s eleven patients, five had bilateral tuberculosis involving the adrenal glands, several had bilateral metastatic cancer, and one had atrophy and fibrosis of the adrenal glands. In 1855 British American physiologist Brown Sequard (1817-1894) documented that the adrenal glands were necessary for life in dogs, cats, hares, and guinea pigs, a fact realized when he observed that animals died at about three days after bilateral adrenalectomy.

Although not everyone accepted the ideas concerning adrenal hypofunction or Addison’s disease, most experts agreed with Brown Sequard. In 1927 R. L. Zwemer provided data confirming that the adrenal cortex, which secretes corticosteroids, was necessary for life.<sup>227</sup>

In contrast to adrenal cortical hypofunction, adrenal cortical hypersecretion caused by increased production of cortisol from the adrenal glands results in Cushing’s syndrome, named after the neurosurgeon Harvey Cushing. Patients with Cushing’s syndrome have central or centripetal obesity, and weight gain, with thin extremi-

ties, a buffalo hump on the upper back, enlarged supraclavicular fat pads, hirsutism, acne, and purple stria (stretch marks) on their protuberant abdomens, weakness, hypertension, diabetes mellitus and virilization.<sup>228</sup> Cushing’s syndrome may also be associated with abnormal behavior, including mania and paranoia. In 1932, Cushing reported that pituitary tumors occurred in some patients with adrenal hyperplasia and removal of the pituitary tumor resulted in a cure of the disease (Nelson 108). This syndrome is usually the result of excess pituitary secretion of ACTH (adrenal cortical stimulating hormone) that secondarily stimulates adrenal cortical secretion (Cushing’s disease). Cushing’s syndrome may also result from excessive secretion of cortisol by benign and malignant adrenal tumors or by the ectopic secretion of ACTH by neuroendocrine tumors of the bronchus, thymus, pancreas, thyroid or other glands.

Pituitary tumors that secrete ACTH develop in about thirty percent of patients after removal of both adrenal glands, as first described by American endocrinologist Don Nelson and colleagues in 1951. These tumors are among the most aggressive and rapidly growing pituitary tumors. Patients present with visual field defects with loss of lateral vision, headaches, extraocular muscle abnormalities, sometimes, pituitary infarction, and a characteristic yellowish hyperpigmentation. The hyperpigmentation that occurs in patients with Nelson’s syndrome and Addison’s disease is thought to be caused by the binding

of ACTH to melanocyte stimulating hormone cells. Treatment of Nelson's syndrome includes surgical removal of the pituitary tumor with post operative radiation therapy.

Tumors or neoplasms (new growth) in the adrenal and pituitary glands usually occur sporadically but can also develop in patients with Multiple Endocrine Neoplasia Type I (MEN-1) syndrome. This syndrome is associated with tumors of the parathyroid, pituitary, pancreas, and adrenal glands. Multiple fatty subcutaneous masses or lipomas and cutaneous angiomas may also be present. Patients suspected of having this syndrome should be tested for hypercalcemia since primary hyperparathyroidism is the most common endocrine disorder in such patients; they should also be tested for the presence of the menin gene on chromosome 11.<sup>229</sup>

Another Multiple Endocrine Neoplasia (MEN syndrome) is found in patients with MEN 2A syndrome who have medullary thyroid cancer (98%), pheochromocytomas (50%) or hyperparathyroidism (25%). Patients may also have MEN 2B syndrome with medullary thyroid cancer and pheochromocytomas without hyperparathyroidism but with a marfanoid body habitus, poor dentition, puffy lips, ectopic lenses, multiple mucosal, and gastrointestinal ganglioneuromas and often, marked hyperextensibility of the joints. Babies who carry the MEN 2B gene are observed to cry without tears.<sup>230</sup> Pheochromocytomas are tumors derived from the adrenal medullary tissue that secretes exces-

sive amounts of catecholamines (the "fright, flight, or fight" syndrome) causing hypertension, increased perspiration and headaches. Patients with MEN 2B unfortunately have the most aggressive medullary thyroid cancers, and few live beyond the age of twenty-one (Gardner 836).

Patients with pheochromocytomas of the adrenal gland, whether sporadic or familial in nature, may experience sudden death caused by cardiovascular events. Some patients with familial medullary thyroid cancer have medullary thyroid cancer without other endocrinopathies. All patients with medullary thyroid cancer should therefore be tested for the RET (rearranged during transfection) oncogene on Chromosome 10 since about 25% of patients with medullary thyroid cancer will have a germ line RET mutation. About ten percent of patients with MEN 2A who have no family member with medullary thyroid cancer have a new or *de novo* germ line mutation; their children, but not their parents or siblings, are therefore at increased risk for developing this syndrome and medullary thyroid cancer.

The parathyroid glands were the last endocrine glands to be discovered. In 1850 British surgeon Sir Richard Owen (1804-92) first identified a parathyroid gland in an Indian one horned rhinoceros (Welbourn 217). German physician Robert Remak (1815-65) also described "a small, compact, yellow, glandular body attached to the thyroid where the veins emerge" (Rolleston 275). In 1879 Swedish histologist Viktor Ivar

Sandstrom (1852-89) described the parathyroid glands both grossly and microscopically in man and animals. He regarded them as embryonic thyroid tissue that served as a reserve for the main thyroid gland. (Rolleston 275). Subsequently, British surgeons Cresswell Baber (1850-1910) and Sir Victor Horsley (1857-1916) independently described the parathyroid glands in sheep, seals, pigs, kittens, pigeons, and dogs (Rolleston 275). The function of the parathyroid glands remained unknown until the beginning of the twentieth century. Before that time, however, surgeons observed that some patients developed tetany after total or near total thyroidectomy when the parathyroid glands were inadvertently removed or damaged.

The parathyroid glands became of greater interest in 1891 after French physiologist Eugene Gley (1857-1930) documented that removal of all four parathyroid glands caused tetany and was fatal (Garrison 695). This observation was confirmed by Italian pathologists Giulio Vassale (1862-1912) and Francesco Generali in 1896 (Garrison 695). In 1895 and 1898 German histologist Alfred Kohn reported that the parathyroid glands are anatomically and physiologically distinct from the thyroid gland (Rolleston 276). In 1906 William Halsted (1852-1922) successfully treated tetany by injecting parathyroid tissue from cattle into humans (Garrison 695). Halsted reported that tetany would occur after the removal of an autotransplanted parathyroid gland in animals (Garrison 695). In 1908, American pathologist George



MacCallam (1874–1944) and chemist and pharmacologist Carl Voegtlin (1879–1960) documented that the administration of calcium successfully treated tetany in man and animals. These observations helped make the connection between the parathyroid glands and calcium metabolism (Garrison 695). Parathyroid hormone was the last of the non-steroidal hormones to be identified and was extracted and isolated from parathyroid glands in 1925 by Canadian biochemist James Collip (1892–1965) (Garrison 695).

In 1925 primary hyperparathyroidism was first diagnosed and treated surgically by Austrian surgeon Felix Mandl (1892–1957) in Vienna with the removal of a parathyroid tumor from a patient with hypercalcemia, white urine and a crippling bone disease caused by osteitis fibrosa cystica (Medvei 486). From 1925 to 1932 all such patients diagnosed with primary hyperparathyroidism had bone deformities caused by osteitis fibrosa cystica, and about 80% of these patients also had kidney stones or nephrocalcinosis with renal dysfunction. In 1932 the first patient with primary hyperparathyroidism and kidney stones without osteitis fibrosa cystica was diagnosed and successfully treated at Massachusetts General Hospital with the removal of a parathyroid tumor. The existence of kidney stones became the main clue to the underlying diagnosis of primary hyperparathyroidism (PHPT) until routine screening of blood calcium levels became available and patients with primary hyperparathyroidism without other metabolic

conditions or symptoms were diagnosed.<sup>231</sup> Primary hyperparathyroidism then became a common endocrine disorder. Osteitis fibrosa cystica is now a rare presenting clinical manifestation in patients with primary hyperparathyroidism, as most patients are treated before it develops and vitamin D deficiency is uncommon in children. Today, most patients who are diagnosed with primary hyperparathyroidism are relatively asymptomatic although about 25% have kidney stones and many have osteopenia or osteoporosis and hypertension.<sup>232</sup>

Currently, most patients with primary hyperparathyroidism have mild to moderate metabolic problems including hypertension, left ventricular hypertrophy, gout and pseudo gout, history of fractures, and rarely, pancreatitis and peptic ulcer disease. Probably the most clinically identifiable endocrine disorders associated with hyperparathyroidism are hypertension, gout and pseudo gout. The latter are conditions associated with increased levels of uric acid or calcium pyrophosphate crystals in the joints, respectively. Patients with hyperparathyroidism appear to have more somatic symptoms such as musculoskeletal aches and pains and neurocognitive disorders such as increased fatigue, depression, and weakness as well as increased thirst and urination, nocturia and constipation than do control patients with benign goiters. Patients with primary hyperparathyroidism are also more likely to have “painful bones, kidney stones, abdominal groans, psychic moans and fatigue overtones.”<sup>233</sup> Following successful parathyroidectomy, many

of these symptoms in patients with primary hyperparathyroidism become less severe or disappear, but the precise mechanisms for clinical improvement in neurocognitive disorders remain unknown.

Primary hyperparathyroidism is currently one of the most common endocrinopathies with about 100,000 cases occurring in the United States each year.<sup>234</sup> It usually develops sporadically but also occurs familiarly in association with other endocrine neoplasms, including patients with multiple endocrine neoplasia MEN-I syndrome and multiple endocrine neoplasia MEN type II A syndrome. It can also occur in patients with isolated familial hyperparathyroidism with or without jaw tumor syndrome or as an isolated form without other endocrinopathies.<sup>235</sup> About 93% of patients with primary hyperparathyroidism have sporadic rather than familial disease.

Primary hyperparathyroidism, caused by parathyroid tumors and both benign and malignant thyroid tumors develop more often in patients who have been exposed to low dose therapeutic radiation, a treatment that was formerly used to treat children with enlarged tonsils, enlarged thymus glands, birth marks, ring worm and other conditions. The latency period from radiation exposure associated with the development of parathyroid tumors is longer than for the development of thyroid tumors.<sup>236</sup> Although this treatment with low dose radiation has been discontinued, there is still concern about the increasing exposure of patients, and especially, children, to diagnostic radiation such as CT scans.<sup>237</sup>

### The gonads, adrenal glands, and the parathyroid glands in art

Drawings in early collections of “monstrosities” such as those in fourteenth century John Mandeville’s *Travels and Voyages* and in medical books such as those by the sixteenth century surgeon Ambroise Paré provide ample, if somewhat unrealistic or fanciful, illustrations of hermaphroditism that reflect the continuing fascination with the “other” manifested in sexual abnormalities. “Among the marvels [Mandeville] describes are various types of monsters such as dog-headed cannibals, flat faced people without noses or mouths, a race of hermaphrodites, people with ears hanging to their knees, and men whose heads grow beneath their shoulders.”<sup>238</sup> In a chapter that describes giants, dwarfs, and humans who resemble beasts, Mandeville includes a description of hermaphrodites observed in his travels:

And they have members of generation of man and woman, and they use both when they list, once that one, and another time that other. And they get children, when they use the member of man and they bear children, when they use the member of woman.<sup>239</sup>

From Mandeville’s standpoint, hermaphrodites are to be viewed as more bestial than human, as “marvels” for the entertainment of their “human” observers. Although Paré’s more clinical view of hermaphroditism recognizes the conditions of a phys-

ical disorder, it nevertheless echoes erroneous theories on the subject that reveal the inaccurate medical knowledge of the sixteenth century. Paré writes,

Now as for the cause, it is that the woman furnished as much seed as the man proportionately, and for this [reason] the formative virtue [property], which always tries to make its likeness—to wit, a male from the masculine matter and a female from the feminine—operates so that sometimes two sexes, called hermaphrodites, are found in the same body (Paré 26).

The theory of “excess of seed” implies that the error lies in the woman’s reproductive organs, not in those of the male.

It is doubtful that individuals with hermaphroditism would have been visible to artists or even to most physicians in the sixteenth century, even though Paré claims to have observed this endocrine abnormality in patients. Most non-medical representations of hermaphroditism are idealized references to the mythological figure of Hermaphrodite, representing a beautiful woman with both female and male sex characteristics. More subtle manifestations of curiosity about androgyny, virilism, and sexual ambiguity are nevertheless noticeable in Renaissance and modern paintings. Artistic references to hermaphroditism and androgyny include a wide range of styles from antique statuettes to idealized classical sculptures and modernist references to

the association between alchemy and hermaphroditism.

Among the numerous examples of classical sculptures of Hermaphrodite, the Greek deity who encompassed both sexes, the marble sculpture of the *Sleeping Hermaphrodite* in Rome (**Figure 5-1**, 138–192 CE, Museo Nazionale Romano, Palazzo Massimo alle Terme [Antonine copy of the 2nd century, BCE Hellenistic original.]) illustrates the idealism of Hellenistic and early Roman periods in which Hermaphrodite “was seen as an erotic figure, combining the physical beauties and attractions of both sexes.”<sup>240</sup> The Roman marble sculpture of Hermaphrodite, like the earlier Hellenistic version in the Louvre, shows the deity in a seductive pose, lying partly on his/her side with the torso exposed sufficiently to reveal a breast, penis, and testes. The head is turned away as if in ambiguous modesty, and the calf of the left leg bent backwards calls attention to the femininely curvaceous lines of the figure.

A similar figure is the centerpiece of Room V in the Galleria Villa Borghese in Rome where a Roman copy of an original Greek Hermaphrodite is turned almost in contraposto pose so that the genitalia appear on one side and the right breast on the other but can never be seen together, as they can in the sculpture at the Palazzo Massimo. The Borghese sculpture is complemented by the ceiling decoration in Room V where the myth of Hermaphroditus and Salmacis from Ovid’s *Metamorphosis* is the narrative feature.



**Figure 5-1**

*Sleeping Hermaphrodite* (138–192 CE, Rome, Museo Nazionale Romano, Palazzo Massimo alle Terme, Antonine copy of the 2nd century, BCE Hellenistic original)

In these examples as well as in the Hellenistic version of Hermaphrodite in the Louvre, the sculptors have embodied both feminine delicacy and male virility in the nude figure whose scant drapery serves merely to romanticize the seemingly perfect proportions and sensual appeal of the hermaphrodite. In the story of Hermaphroditus and Salmacis in Ovid's *Metamorphoses* there is pathos in the young boy's discovery of his sex change, eventually leading to revenge:

When tamed Hermaphroditus  
learned his fate, / Knew that his  
bath had sent him to his doom, /  
To weakened members and a girlish  
voice, / He raised his hands and  
prayed, 'Father, Mother, / Hear  
your poor son who carried both  
your names: / Make all who swim


these waters impotent, / Half men,  
half women,' Which his parents  
heard /And gave the fountained  
pool its weird magic.<sup>241</sup>

The ancient sculptures of Hermaphroditus (Hermaphrodite) continue to tease the viewer who marvels at the mythical figure's sensual beauty. Yet equally arresting is the sculpture's evidence of sexual duality that also implies sexual impotence, as if Hermaphrodite exists for the purpose of perpetually enticing and disappointing. It is tempting to speculate too that the myth's popularity as a subject for sculpture may derive from its attempt to explain sexual ambiguity and androgyny, in short, the broad spectrum of secondary sex characteristics from effeminate males to masculine females.

The innate sensuality of the hermaphrodite is apparent in one of the earliest Renaissance paintings alluding to Ovid's myth, *The Metamorphosis of Hermaphroditus and Salmacis* by Dutch artist Jan Gossaert (**Figure 5-2**,

1517, Rotterdam, Museum Boijmans Van Beuningen) (see p. 151). Gossaert uses the foreground of the painting to represent the first part of the narrative in which Salmacis embraces the young man Hermaphroditus, who appears wary of her intent. The second part of the narrative shows a fanciful "evolving" figure, "both male and female" in the left background of the painting.<sup>242</sup> Confirming the result of the union is a small human figure with two heads, two joined torsos and only two legs. Hidden behind a garland of greenery, the hermaphrodite's genitalia are difficult to determine.

Some small figures of hermaphrodites from Greek, Roman and Etruscan antiquity display the common practice of artists of the late Hellenistic and early Roman periods in which the body is draped or clothed in a way that reveals the sexual organs, thus making clear the sexual ambiguity of the hermaphrodite. Representations of the hermaphrodite as a victim of sexual aggression is also apparent in some Greek and Roman sculptures.



Some of the sculptures treat evidence of the sexual disorder with mockery. Art historian Edward Lucie-Smith notes that a Graeco-Roman sculpture “of a hermaphrodite struggling with a satyr ... is especially typical of the rather gamy taste of the time—more than fifty examples are known.”<sup>243</sup> It would seem from these examples that although a true hermaphrodite is a unification of both sexes, social practice has tended to treat people who manifest sexual ambiguity as more female than male by placing him/her in the position of victim or passive receiver of male aggression.

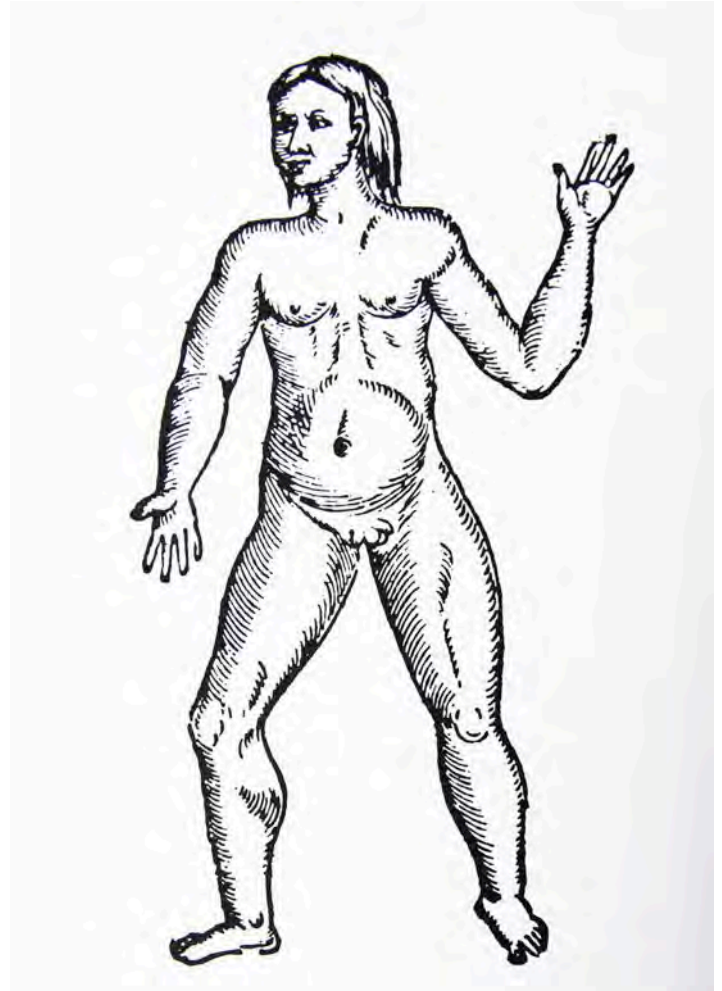
---

**Figure 5-3**

*Hermaphrodite* (1st–3rd century CE, London, British Museum)

Another early example of a sensual representation of a hermaphrodite is found in a small Roman bronze statuette of *Hermaphrodite* (Figure 5-3, 1st–3rd century CE, London, British Museum). Here the artist has covered Hermaphrodite’s upper female body and head with modest drapery, which she is lifting, almost as if in wonder at the discovery of a protruding penis. Some statuettes of hermaphrodites found in museum antiquity collections display more mesomorphic, less idealistic, proportions and place less emphasis on sensual or erotic associations with the mythical figure than those from the Hellenistic period in Greece or in Roman copies of works from that period. In other sculptures depicting hermaphrodites, the association of hermaphroditism and bestiality is apparent in the ambiguous human/animal, male/female features as if a dual sexed human is considered less than human. The treatment of hermaphroditism as a subject for exaggeration and satire is closely allied with the Renaissance attitude toward this endocrine abnormality as a sign of depravity.

In his treatise *On Monsters and Marvels* (originally published in 1575), Ambroise Paré included illustrations of the various kinds of hermaphrodites, among them one that would now be described as a lateral hermaphrodite because in addition to breasts, the figure is shown to have a vulva in the right pelvic area and male genitalia in the left (Figure 5-4, Ambroise Paré, *Oeuvres complètes d’Ambroise Paré*, ed. J. –F. Malgaigne (Paris: Baillière, 1841). Female breasts and a slightly



swollen abdomen suggest female sex characteristics. According to Paré such a hermaphrodite would be one of those described as “neither one or the other ... those who are totally excluded from and void of reproduction, and their sexual organs are wholly imperfect and are situated alongside one another and sometimes one on top and other beneath, and they can use them only to eject urine” (Paré 27).<sup>244</sup> Paré’s illustration is more clinical than artistic, clearly featuring the ambiguities that continued to puzzle men of science and without the teasing aesthetic and erotic qualities of the earlier ancient sculptures.

**Figure 5-4**

Ambroise Paré, *Oeuvres complètes d’Ambroise Paré*, ed. J. –F. Malgaigne (Paris: Baillière, 1841)

Although Paré may have observed such a hermaphrodite, his clinical drawings seem to be derived from his general knowledge of anatomy rather than from an actual observation of a hermaphrodite.



**Figure 5-5**

Hieronymus Bosch, detail from *The Garden of Earthly Delights* (1470, Madrid, Museo del Prado)

In the fifteenth century paintings of Hieronymus Bosch the representation of hermaphroditism is closely allied with theories of alchemy that were still popular in Renaissance Europe. According to art historian Laurinda Dixon,

Bosch's exuberant youths ... stand on their heads, but ... also spread their legs, forming human 'Y' shapes. This accords with the doctrine of the thirteenth-century chemist Raymond Lull, whose treatises were collected, copied and printed in the fifteenth century. Lull ascribed letters of the alphabet to various stages of the work, and reserved the letter 'Y' for the 'hermaphrodite', a symbol for the coming together of diverse substances that occurred during alchemical conjunction.

In the left wing detail from *The Garden of Earthly Delights* (Figure 5-5, 1470, Madrid, Museo del Prado), the 'Y' configuration "suggest[s] the union of opposites necessary for transmutation."<sup>245</sup>

Just as figures of hermaphrodites took on symbolic value in antiquity and continued to do so in the paintings of such early Renaissance artists as Bosch, the references to hermaphroditism that appear in two works by modern surrealist Max Ernst also reflect the semiotics of sexual abnormality. In his painting *Men Shall Know Nothing of This* (Figure 5-6, 1923, London, Tate Modern) Ernst puzzles the viewer by placing the focal point on the central image of the lower half of a four-legged human figure, including both male and female genitalia. The figure is shown below a crescent moon and a sun. Familiar associations of the moon (Artemis or Diana) with the female sex and the sun with the male sex (Apollo) further the ambiguous dichotomy yet fusion of the

sexes in the painting.<sup>246</sup> Here, according to Stalabrass, the images suggest that "the movements of moon and earth are related to sexual activity" and that the overt references to hermaphroditism seem to reflect the "alchemical language and imagery" of sexual identity, the sexual duality or androgyny of all humans (Stalabrass 54). Ernst's juxtaposition of the 'Y' configuration of legs with moon and sun seems to allude to Bosch's similar configuration, suggesting that hermaphroditism reflects balance between male and female, albeit in one person.

**Figure 5-6**

Max Ernst, *Men Shall Know Nothing of This* (1923, London, Tate Modern)



In his painting *The Attirement of the Bride* Max Ernst (see **Figure 2-9**, p. 79) conveys a similar ambiguity in the green figure of a hermaphroditic homunculus in the lower right foreground. With four breasts, a phallus, webbed feet, and a protuberant abdomen that implies the figure is pregnant, the homunculus manifests both human and animal characteristics as well as male and female sex characteristics. The large figures in the painting who appear to be female, but ambiguously so, stand in opposition to each other as if the robed “bride” is the aggressor and the naked woman with the large headdress is the passive one playing the “female” role.<sup>247</sup> The presence of a third eye turning toward the naked female figure hints at voyeurism on the part of the more aggressive sexually ambiguous robed figure.<sup>248</sup> Turpin also notes that the figure of the stork serves as a “symbol of fertility and the broken arrow a familiar phallic symbol,” which along with the homunculus may suggest “merged sexual identity” (Turpin 98). Both paintings underline the significance of hermaphroditism as a puzzling endocrine condition in the twentieth century, one that has taken on symbolic meaning in both art and literature.

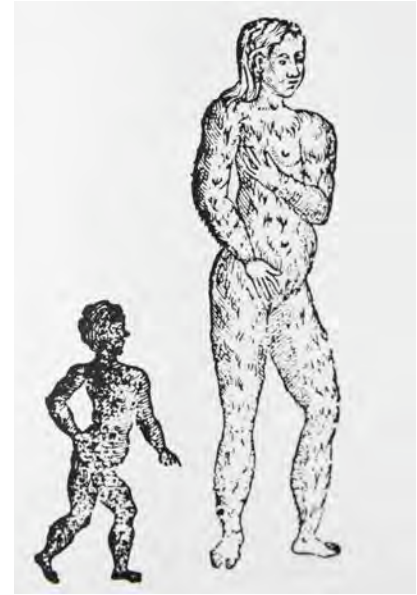
Along with curiosity about sexual ambiguity in figures of hermaphrodites, it should come as no surprise that the subject of hirsutism has attracted attention in the realm of freakery, a term especially popular in Britain that encompasses a wide range of physical and mental abnormalities. Paré’s book includes a picture of

a hairy female child next to a black child, both of whom were designated as such “because of the imagination of their parents” (**Figure 5-7**, Paré, *Oeuvres complètes d’Ambroise Paré*, ed. J. –F. Malgaigne (Paris: Baillière, 1841). Paré’s explanation of hirsutism includes the following reference to antiquity:

Damascene, a serious author, attests to having seen a girl as furry as a bear, whom the mother had bred thus deformed and hideous, for having looked too intensely at the image of Saint John [the Baptist] dressed in skins, along with his [own] body hair and beard, which picture was attached to the foot of her bed while she was conceiving (Paré, *Of Monsters and Marvels* 38).

This type of religious and fantastical explanation based on fear and superstition about a physical abnormality was still prevalent in the sixteenth century, even among well educated physicians such as Paré.

Fascination with sexual anomalies was also popular in the seventeenth century. Probably the most famous portrait of a hirsute woman named Magdalena Ventura is Jusepe de Ribera’s *The Bearded Woman Breastfeeding* (**Figure 5-8**, 1631, Toledo, Hospital de Tavera, Museo Fundación Duque de Lerma) (see p. 148). The work was painted “[a]t the request of Alcalá,” the duke who was one of Ribera’s “major viceregal patrons” (Brown 152). According to Jonathan Brown, the lengthy Latin



**Figure 5-7**

Ambroise Paré, *Oeuvres complètes d’Ambroise Paré*, ed. J. –F. Malgaigne (Paris: Baillière, 1841)

inscription that appears on the right side of the painting and “describes the circumstances of the commission, implies that it was executed to record a wonder of the natural world. Magdalena Ventura was from the Abruzzi, a region in the Kingdom of Naples, and began to grow a beard when she was thirty-seven” (Brown 152). When Magdalena was fifty-two years old, she gave birth to the child shown in the picture. In the portrait, Magdalena is dressed in a robe that could easily be that of a man rather than a woman. Her close fitting cap, sideburns, and dark beard all suggest a male persona, yet she is visibly nursing a robust looking baby, and her large engorged breast appears almost as a central appendage. Magdalena’s stern expression and her husband’s



more disconcerted appearance suggest the anomalous nature of her position as an elderly nursing mother. Similar in appearance to Magdalena Ventura is the subject of an earlier painting (not shown here) by Spanish painter Juan Sánchez Cotán, *La Barbuda de Peñaranda* (1590, Madrid, Museo del Prado). Because Cotán's portrait lacks the identifying evidence of female breasts, however, it is almost impossible to tell that the stern bearded face of *La Barbuda* is that of a woman.

Hirsutism in both men and women was a source of wonder to Renaissance royalty who "imported" them from faraway places. Historic records document that hirsute individuals were "collected" as curiosities much as dwarfs and giants were collected by European courts. Among the more famous of these "marvels of nature" was the "hairy family" of Petrus Gonsalvus. The patriarch of the family is represented by an unknown German artist in a portrait *The "Hair Man" Petrus Gonsalvus* (Figure 5-9 1582, Innsbruck, Austria, Schloss Ambras). The portrait depicts Gonsalvus in aristocratic robes. Because his delicate hands are the only visible parts of his body except for his head, they contrast dramatically with his hairy, almost animal-like face. Leroi notes that in 1556 "Petrus Gonsalvus arrived at the court of Henri II of France, brought there possibly as a slave from Tenerife.



**Figure 5-9**

An unknown German artist, *The "Hair Man" Petrus Gonsalvus* (1582, Innsbruck, Austria, Schloss Ambras)



He could not have been more than twelve, but already a thick pelt of facial hair obscured his features. He seems to have been treated kindly there and was even given some education” (Leroi 271).<sup>249</sup> Gonsalvus’ son Arrigo Gonsalvus appears in the center of a painting by Agostino Carracci, *Composition with Figures and Animals*, also known as *Arrigo Peloso*, *Pietro Matto e Amon Nano (Hairy Arrigo, Insane Pietro and Dwarf Amon)* (Figure 5-10, 1599, Naples, Museo Nazionale di Capodimonte). The painting features a madman and a dwarf looking at Arrigo whose

entire face is covered with hair. The juxtaposition of the men and animals reminds the viewer of a similar practice in paintings of dwarfs; here the artist seems to imply that the hairy man and the dwarf, and perhaps even the madman Peter, are regarded as more beast than human.<sup>250</sup> Barry Wind infers that Carracci is purposely mocking the three subjects of the portrait rather than “depicting a kind of ideal harmony of men and animals” (Wind 20).

#### Figure 5-10

Agostino Carracci, *Composition with Figures and Animals*, also known as *Arrigo Peloso*, *Pietro Matto e Amon Nano (Hairy Arrigo, Insane Pietro and Dwarf Amon)* (1599, Naples, Museo Nazionale di Capodimonte)

Wind's interpretation is supported by the theories of "Cardinal Gabriele Paleotti ... whose treatise was published in 1582, [and who] distinguished between portraits that were made for mockery and those of dignified sitters" (Wind 20). All of the paintings of hirsute individuals discussed here raise questions about the ambiguous intentions of the artists, similar to the ambiguity in paintings of dwarfs by Velasquez and others.

In various archives of nineteenth century photographs that include "freaks" or "remarkables" pictured in journals and books, the question of ambiguous gender seems to have created considerable interest in the popular press. For example, a photograph in Harvard University's Houghton Library of a married couple features a husband seated next to his elaborately dressed wife. The bodice of the wife's Victorian gown is covered by her flowing black beard. The otherwise ordinary wedding portrait may lead one to question whether the photographer intended mere documentation of a marriage or invited satire of both ambiguous gender and traditional marriage.

Similarly, Jan Bondeson writes of the interesting history of a hirsute child named Julia Pastrana who was discovered in a part of the Sierra Madres of Mexico that "was said to be 'a region of country abounding in monkeys, baboons, and bears'" (Bondeson 219). Pastrana was eventually persuaded by "an American named M. Rates" to travel "to the United States, to be exhibited for money" (Bondeson 219). A circus poster depicting Pastrana emphasizes her curvaceous femininity, especially large, voluptuous breasts, a tiny waist, and graceful shapely legs, all of which make the large masculine features of her face, including thick hair, hairy ears, mustache and beard, seem incongruous. After frequent travels with Rates and appearances in his freak shows, Pastrana attracted numerous curious audiences and fans in both the United States and Europe where her "dancing shows were apparently regarded as a slightly obscene and scandalous public amusement as evidenced by the caricature drawing of her by the (Polish) artist Kostrzewski" (Bondeson 228). Interestingly, although popular culture exemplified by such posters may focus on the titillating sexual appeal of the "freak" in a hirsute woman, men of science such as the New York physician Alexander Mott went a step further in degrading her as "'one of those extraordinary beings of the present day,' a hybrid between human and orangutan" (Bondeson 219). Mott's narrow delineation of what it means to be human may remind us of the famous Scopes monkey trials in which Darwin's theory of evolution made some people feel uncomfortable about their ancestry.

---

### Other endocrinopathies in art

---

In comparison to the more recognizable physical manifestations of hermaphroditism and hirsutism, artists would be less likely to capture individuals with mild hyperparathyroidism, adrenocortical insufficiency (Addison's disease) or adrenocortical excess (Cushing's syndrome). Patients with mild hyperparathyroidism would have had few obvious clinical manifestations such as bone deformities, renal colic and gout or pseudo gout, and those with Addison's or Cushing's syndrome would often have been quite ill because of a shortened life expectancy, therefore rarely seen in public.



**Figure 5-11**

Raphael, *The Fire in the Borgo in the Stanze dell'Incendio* (1517, Vatican State, Vatican Palace, Stanze di Raffaello)

In our research we have discovered two possible examples of an artistic reference to Addison's disease. The first is in a work by Raphael, which may be the only one in the Borgo Vecchio apartment of the Vatican executed by Raphael, rather than his workshop. Richard Cocke notes that the fresco uses "an inventive reworking of a widely-used late Quattrocento formula in which foreground figures are set in a recognizable architectural setting" (Cocke 88), here one of the papal apartments. The fresco of *The Fire in the Borgo in the Stanza dell'Incendio* (Figure 5-11, 1517, Vatican State, Vatican Palace,

Stanze di Raffaello) alludes to a scene from the Trojan War recounted in Virgil's *Aeneid*. In Virgil's epic poem the hero Aeneas rescues his father Anchises from a fire the Greek enemy has started in the royal palace of Troy (Cocke 88).<sup>251</sup> The viewer's eye is especially drawn to the left foreground of the fresco depicting the ailing father and his strong, courageous son. Recreating the famous scene of filial piety and pathos in the Virgilian narrative, the painting portrays the figure of the old man Anchises with skin of a yellow hue, possible hyper-pigmented creases on the palms of his hands and darkening of the skin on



the elbow. The apparent absence of scleral icterus (yellowed eyes) makes Addison's disease a more likely diagnosis than jaundice, although jaundice could be part of the differential diagnosis of Raphael's Anchises. (Jaundice is caused by liver failure whereas Addison's disease is the result of adrenal failure. Both diseases are recognizable by the yellowish pallor of the skin.) Whatever the cause of the old man's weakness, his signs of illness make him an especially sympathetic figure presented with appropriate pathos in Raphael's fresco.

Another example of Addison's disease found in a painting is Dante Gabriel Rossetti's painting *The Beloved or The Bride* (Figure 5-12, 1865-66, London, Tate Gallery). The pale but slightly yellow hue of the bride's complexion is a possible sign of tuberculosis with consumption and Addison's disease. It should be noted that the tall woman to the bride's right has a noticeable goiter, an endocrine abnormality frequently documented in Rossetti's paintings, as we discussed in Chapter 1.

**Figure 5-12**

Dante Gabriel Rossetti, *The Beloved or The Bride* (1865-66, London, Tate Gallery)



**Figure 5-13**

Bartholomeus van der Helst, *Gerard Andriez Bicker* (1670, Amsterdam, Rijksmuseum)

In our research we have discovered only one questionable example of Cushing's syndrome in a painting. The portrait of *Gerard Andriez Bicker* by Bartholomeus van der Helst (**Figure 5-13**, 1670, Amsterdam, Rijksmuseum) portrays a portly young man with obvious centripetal obesity characteristic of Cushing's syndrome. Whether the subject of the painting had other indications of the disease is question-

able since his voluminous costume would have hidden such signs as supraclavicular fat pads, abdominal stria, hirsutism, or the "buffalo" hump.

More often represented in paintings, the disease of gout, which is more common than Addison's disease and Cushing's syndrome, may occur sporadically but more frequently in patients with hyperparathyroidism. In the eighteenth and nineteenth centuries, the more obvious physical signs of gout provided an opportunity for exaggeration and social satire in numerous caricatures. Because gout

was thought to be caused by indulgence in excess or luxury, namely a rich diet and large quantities of alcohol, the rotund gentleman with a gouty foot is a prominent image in satirical caricatures and cartoons with a political or social message. The condition was less controversial and more obvious to the public than the other endocrine disorders discussed in this chapter. William Hogarth's famous series of engravings titled *Marriage a la Mode* includes *The Marriage Contract* (**Figure 5-14**, 1743, London, National Gallery) in which the viewer's eye is drawn to the lower right quadrant of the picture where a man's gout diseased foot rests on a stool. The picture illustrates a scene in which the marriage contract "between the daughter of a rich, miserly alderman merchant and the son of an impoverished earl" is being negotiated (Langmuir 295). The earl points "to his family tree rooted in William the Conqueror" while

he rests his gouty foot—a sign of degeneracy—on a footstool decorated with his coronet. Behind him is a lavish building in the new classical style, unfinished for lack of money; a creditor is thrusting bills at him. But on the table in front of him is a pile of gold—the bride's dowry just handed to him by the bespectacled alderman, who holds the marriage contract (Langmuir 295).



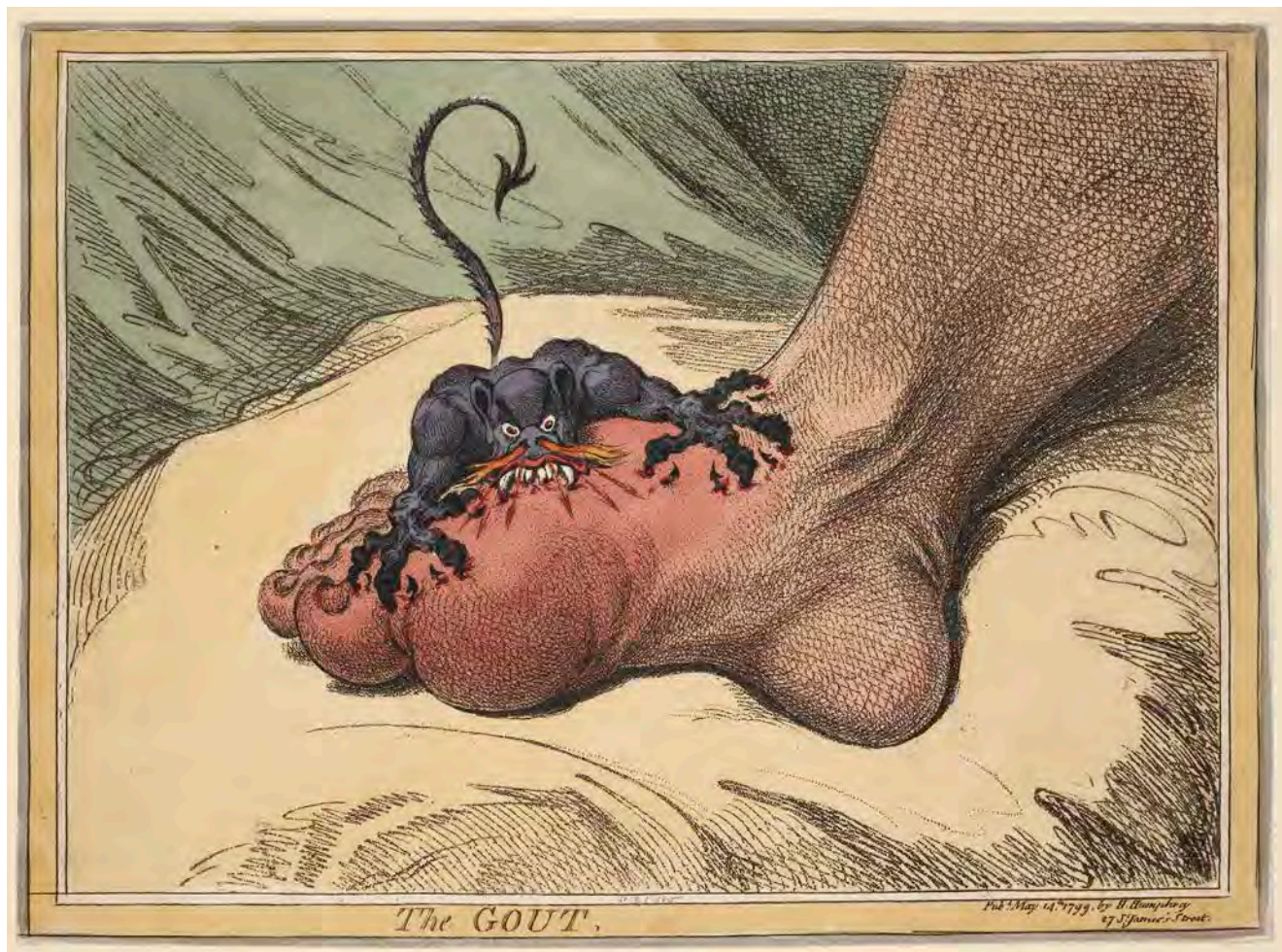**Figure 5-14**

William Hogarth, *The Marriage Contract* from *Marriage a la Mode* (1743, London, National Gallery)

Other images such as the paintings on the wall foreshadow a pessimistic outcome for the married couple, which the remaining paintings of the series in *Marriage a la Mode* explicate. The prominence of the earl's gouty foot, symbol of excess, against images of irresponsible spending and greed makes clear the moral message of Hogarth's painting: irresponsible indulgence has its price.

Although Hogarth's intention was to "cast himself as the engraver of 'moral subjects,'" <sup>252</sup> his contem-

poraries such as George Cruikshank, Thomas Rowlandson, and James Gillray focused more specifically on political and social satire represented in colorful caricatures. James Gillray's etching/aquatint (not shown here) titled *Visiting the Sick* (1806, Washington, DC, Library of Congress) features the politician Charles James Fox with large gouty feet and limbs swaddled in bright yellow cloth and "surrounded by comforters including the Prince of Wales" and others who may have benefited from their sycophantic attentions to Fox. <sup>253</sup>



The artist's focus on Fox's condition suggests an association between the ailment of gout and political "sickness," hence the title that alludes as well to the sickness of state. A more famous representation of gout is Gillray's *The Gout* (Figure 5-15, 1799, London, British Museum), an etching of a bare gouty foot being attacked by a rat like creature that appears to be feasting on the blood swollen joint of a grotesque foot. According to his biographers, "[a]s a result of his heavy drinking Gillray suffered from gout throughout his later life. People who have shared his affliction often

comment that his etching interpreting this ailment is a very apt and imaginative illustration of the agony that gout sufferers endure."<sup>254</sup> On the political/social level, the etching seems to imply that the dangers of excess lead to self-punishing agony represented by the swollen gouty foot and involve punishment from the lowest orders symbolized by the rat.

The association of disfiguring endocrine diseases such as gout with moral depravity continued to have credence throughout the nineteenth century. Even today those who suffer from

gout are sometimes considered to be the victims of a life of excess and indulgence. Such associations remind us that society is quick to judge those whose disfigurement or discomfort draws attention to their ailments.

---

**Figure 5-15**

James Gillray, *The Gout* (1799, London, British Museum)



The tendency throughout history for disease and disfigurement to be associated with sin, immoral or aberrant behavior, or lack of intelligence reflects the influence of fear and ignorance on those who consider good health a reward for acceptable behavior and moral righteousness. As we have noted throughout our discussion of the relationship between endocrine disorders and aesthetic, religious, and social history, aberrations in appearance and behavior have led those in positions of power (including those in the medical profession) to marginalize individuals who fall outside the accepted boundaries of “normal.” The practice of categorizing, classifying, and adhering to a narrow definition of what is human also reflects a desire for control in a time when science had not yet developed the tools for understanding the causes and effects of disease. Disease thus became a metaphor for “the other,” its implications of immorality, and even for bestiality.

Despite the advancement of medical science in the twenty-first century, the dangers of such categorization continue to undermine the more egalitarian and inclusive social environment of our times. Scientific discoveries made accessible to the general public help demystify the ramifications of disease and disfigurement, gradually promoting a more inclusive social environment for those who would otherwise be excluded from society. Although increasingly sophisticated experimentation and careful observation by medical scientists eventually led to an understanding of the endocrine system, the complex and rare nature of endocrine disorders continues to require more research and address unanswered questions.

In our view the remarkable intricacies and interdependencies of the endocrine system are a reminder of the wonders and varieties of human biology. Furthermore, artists’ visual documentation of endocrine disorders has contributed a lasting record of the nature of disease within the larger context of European history, thus verifying the relationship between art and science throughout time. Such a relationship can only become more significant in our age of fast-paced interactive technology. When medical students observe paintings in order to improve their powers of observation, they are demonstrating the value of breaking down arbitrary boundaries between the humanities and sciences, thus helping themselves and others to acquire new and more profound ways of seeing and understanding the human condition.

---

**List of Illustrations**


---

**Dust Jacket**

Ribera, Jusepe de (lo Spagnoletto) (c.1590–1652). *The Bearded Woman Breastfeeding*, 1631. Oil on canvas. Hospital de Tavera, Toledo, Spain/ Peter Willi/ The Bridgeman Art Library.

**Chapter 1**

**Figure 1-1.** Holbein, Hans the Younger (1497–1543). *Adam and Eve*.

Photo Credit: Art Resource, NY/Kunstmuseum, Basel, Switzerland.

**Figure 1-2.** Veneziano, Paolo (fl.1324–1358). *The Doge Dandolo and the Dogaressa Being Presented to the Virgin*.

Photo Credit: Cameraphoto Arte, Venice / Art Resource, NY / S. Maria Gloriosa dei Frari, Venice, Italy.

**Figure 1-3.** Piero della Francesca (c.1420–1492). *Polptych of the Madonna della Misericordia*.

Photo: George Tatge.

Photo Credit: Alinari/Art Resource, NY/ Pinacoteca Comunale. Sansepolchro, Italy.

**Figure 1-4.** del Verocchio, Andrea (1436–1488) and assistant (Lorenzo di Credi, 1458–1537). *The Virgin and Child with Two Angels*, ca 1470–80. Tempera on wood, 96.5 x 70.5 cm. Bought, 1857 (NG296).

© National Gallery, London / Art Resource, NY / National Gallery, London, Great Britain.

**Figure 1-5.** Leonardo da Vinci (1452–1519). *Madonna and child (with carnation)*. 1473. Oil on wood, 62 x 47.5 cm. Inv. No. 7779.

Photo Credit: Bildarchiv Preussischer Kulturbesitz / Art Resource, NY / Alte Pinakothek, Bayerische Staatsgemaeldesammlungen, Munich, Germany.

**Figure 1-6.** Mantegna, Andrea (1431–1506). *Madonna and Sleeping Child*. Distemper on canvas, 43 x 32 cm. Inv. S.5.

Photo: Joerg P. Anders. Photo Credit: Bildarchiv Preussischer Kulturbesitz / Art Resource, NY / Gemaeldegalerie, Staatliche Museen, Berlin, Germany.

**Figure 1-7.** Melozzo da Forlì, *Annunciation*.

Archivio Fotografico della Soprintendenza Speciale per il Patrimonio Storico, Artistico ed Etnoantropologico e per il Polo Museale della Città di Roma. The Pantheon, Rome.

**Figure 1-8.** Botticelli, Sandro (1444–1510). *Annunciation*. Tempera on wood, 150 x 156 cm. Inv. 1608.

Photo Credit: Erich Lessing / Art Resource, NY / Uffizi, Florence, Italy.

**Figure 1-9.** Fra Filippo Lippi, *Annunciation*.

Museo Nazionale d'Arte Antica, Palazzo Barberini, Rome. Archivio Fotografico della Soprintendenza Speciale per il Patrimonio Storico, Artistico ed Etnoantropologico e per il Polo Museale della Città di Roma.

**Figure 1-10.** Parmigianino (Francesco Mazzola) (1503–1540). *Madonna with the long neck* (post-restoration). 1535–40. Oil on wood. 86 1/4 x 53 1/8 in. (219 x 135 cm).

Photo Credit: Scala/Ministero per i Beni e le Attività culturali / Art Resource, NY / Uffizi, Florence, Italy.

**Figure 1-11.** Caravaggio (Michelangelo Merisi da) (1573–1610). *Madonna of the Pilgrims*.

Archivio Fotografico della Soprintendenza Speciale per il Patrimonio Storico, Artistico ed Etnoantropologico e per il Polo Museale della Città di Roma. Church of San'Agostino, Rome.

**Figure 1-12.** Caravaggio (Michelangelo Merisi da) (1573–1610). *Madonna of the Palafrenieri*.

Archivio Fotografico della Soprintendenza Speciale per il Patrimonio Storico, Artistico ed Etnoantropologico e per il Polo Museale della Città di Roma. Galleria Borghese, Rome.

**Figure 1-13.** Albertinelli, Mariotto. *Creation and Fall*.

Credit: The Samuel Courtauld Trust, The Courtauld Gallery, London.

**Figure 1-14.** Rubens, Peter Paul (1577–1640). *Samson and Delilah*, about 1609–10. Oil on wood, 185 x 205 cm. Bought, 1980 (NG6461).

© National Gallery, London / Art Resource, NY / National Gallery, London, Great Britain.

**Figure 1-15.** Dosso Dossi. *Maga Circe*.

Archivio Fotografico della Soprintendenza Speciale per il Patrimonio Storico, Artistico ed Etnoantropologico e per il Polo Museale della Città di Roma. Galleria Borghese, Rome.

**Figure 1-16.** Campana, Giacinto and Guido Reni, copy of Guido Reni, *The Rape of Helen*.

Archivio Fotografico della Soprintendenza Speciale per il Patrimonio Storico, Artistico ed Etnoantropologico e per il Polo Museale della Città di Roma. Galleria Spada, Rome.

**Figure 1-17.** Botticelli, Sandro (1444–1510). *La Primavera*. Detail of 40-07-01/60. Tempera on wood (1477), 203 x 314 cm. Inv. 8360.

Photo Credit: Erich Lessing / Art Resource, NY / Uffizi, Florence, Italy.

**Figure 1-18.** Rubens, Peter Paul (1577–1640). *The Three Graces*.

Photo Credit: Scala / Art Resource, NY / Museo del Prado, Madrid, Spain.

**Figure 1-19.** Rossetti, Dante Gabriel (1828–1882). *Monna Vanna*. Dated 1866. Oil on canvas, 88.9 x 86.4 cm.

Photo Credit: Tate, London / Art Resource, NY / Tate Gallery, London, Great Britain.

**Figure 1-20.** Rossetti, Dante Gabriel (1828–1882). *The Daydream*, 1880. Oil on canvas, 158.7 x 92.7 cm. Inv.: CAI.3.

Photo Credit: V&A Images, London

Art Resource, NY.

Victoria and Albert Museum, London, Great Britain.

**Figure 1-21.** Ingres, Jean Auguste Dominique (1780–1867). *Angelica saved by Ruggiero*, 1819–39. Oil on canvas, 47.6 x 39.4 cm. Bought, 1918 (NG3292).

© National Gallery, London / Art Resource, NY / National Gallery, London, Great Britain.

**Figure 1-22.** *Summer*. Detail of a floor mosaic depicting the Four Seasons. Imperial Roman, 4th–5th century CE. From the area of Le Capannelle, Rome.

Photo Credit: Vanni / Art Resource, NY / Museo Nazionale Romano (Palazzo Massimo alle Terme), Rome, Italy.

**Figure 1-23.** *Portrait of a young woman with a gilded wreath*.

Egyptian. Roman Period, 120–140 CE. Encaustic, wood, gilding. H. 36.5 x W. 17.8 cm (14 3/8 x 7 in.).

Art Resource, NY. Rogers Fund, 1909.

(09.181.7.)

The Metropolitan Museum of Art, NY.

**Figure 1-24.** Botticelli, Sandro (1444–1510). *Portrait of a young woman* (Simonetta Vespucci or Clarice Orsini). Oil on wood, 61 x 40 cm.

Photo Credit: Scala / Art Resource, NY / Galleria Palatina, Palazzo Pitti, Florence, Italy.

**Figure 1-25.** Rubens, Peter Paul (1577–1640). *Helene Fourment in her Wedding Dress*. 1630. Oil on oak, 163.5 x 136.9 cm. Inv. 340.

Photo Credit : Bildarchiv Preussischer

Kulturbesitz / Art Resource, NY

Alte Pinakothek, Bayerische

Staatsgemaeldesammlungen, Munich, Germany.

**Figure 1-26.** Rubens, Peter Paul (1577–1640). *Portrait of Susanna Lunden* ('Le Chapeau de Paille'), ca 1622–5. Oil on oak, 79 x 54.6 cm. Bought, 1871 (NG852).

© National Gallery, London / Art Resource, NY  
National Gallery, London, Great Britain.

**Figure 1-27.** Piero della Francesca (c.1420–1492). *The Madonna del Parto (Virgin with two angels)*. Ca. 1460. Fresco, 260 x 203 cm. Post-restoration.

Photo Credit: Scala / Art Resource, NY  
Cappella del Cimitero, Monterchi, Italy.

**Figure 1-28.** Campin, Robert (ca.1375/9–1444), follower of. *The Virgin and Child before a Firescreen*, about 1440. Oil with egg tempera on oak with walnut additions, 63.4 x 48.5 cm. Salting Bequest, 1910 (NG2609).

© National Gallery, London / Art Resource, NY  
National Gallery, London, Great Britain.

**Figure 1-29.** Lippi, Fra Filippo (1406–1469). *Madonna and Child with Stories of the Life of Saint Anne* (Tondo Bartolini). Ca. 1452. Oil on panel, diam. 53” (135 cm).

Photo Credit: Scala/Ministero per i Beni e le Attività culturali / Art Resource, NY / Galleria Palatina, Palazzo Pitti, Florence, Italy.

**Figure 1-30.** Steen, Jan (1626–1679). *The Doctor and the Patient*.

Oil on canvas, ca. 1670. 49 x 46 cm. Inv. DO 4598.

Photo: Lutz Braun. Photo Credit: Bildarchiv Preussischer Kulturbesitz / Art Resource, NY / National Gallery, Prague, Czech Republic.

**Figure 1-31.** Le Nain, Louis (1593–1648). *Landscape with Figures (La Halte du Cavalier or The Resting Horseman)*. Oil on canvas, 21 ½ x 26 ½ in. (54.6 x 67.3 cm). Inv.: CA.117.

Photo Credit: V&A Images, London / Art Resource, NY / Victoria and Albert Museum, London, Great Britain.

**Figure 1-32.** Titian (Tiziano Vecellio) (c.1488–1576). *Assumption of the Virgin*.

Photo Credit: Cameraphoto Arte, Venice / Art Resource, NY / S. Maria Gloriosa dei Frari, Venice, Italy.

**Figure 1-33.** Sodoma (Bazzi), Giovanni Antonio. In 1497 Signorelli began painting the *Vita of Saint Benedict da Nurcia as told by Saint Gregory*. The work, 36 scenes in all, was completed 1505–1508 by Sodoma. *Saint Benedict leaves his father's house to study in Rome* (in the background the town of Nurcia).

Detail. Photo Credit: Erich Lessing / Art Resource, NY / Abbey, Monte Oliveto Maggiore, Italy.

**Figure 1-34.** van der Weyden, Rogier (Roger) (ca.1399–1464). *The Magdalen Reading*, before 1438. Oil on mahogany, transferred from another panel, 62.2 x 54.4 cm.

Bought, 1860 (NG654).

© National Gallery, London / Art Resource, NY / National Gallery, London, Great Britain.

**Figure 1-35.** Crivelli, Vittore. *St. Catherine of Alexandria*. Tempera and gilding on panel, 73.7 x 41 cm.

Bequest of CDE Fortnum, 1899, Ashmolean Museum, Oxford, England.

**Figure 1-36.** Gentileschi, Artemisia. *Santa Cecilia*.

Archivio Fotografico della Soprintendenza Speciale per il Patrimonio Storico, Artistico ed Etnoantropologico e per il Polo Museale della Città di Roma. Galleria Spada, Rome, Italy.

**Figure 1-37.** Sebastiano del Piombo (1485–1547). *The Martyrdom of Saint Agatha*. 1520. Oil on wood, 127 x 178 cm.

Photo Credit: Scala/Ministero per i Beni e le Attività culturali / Art Resource, NY / Galleria Palatina, Palazzo Pitti, Florence, Italy.

**Figure 1-38.** Botticelli, Sandro (1444–1510). *Scenes from the Life of Moses*, detail of woman bearing urn. (Sistine Chapel walls).

Photo Credit: Scala / Art Resource, NY  
Sistine Chapel, Vatican Palace, Vatican State.

**Figure 1-39.** Rubens, Peter Paul (1577–1640). *Susanna and the Elders*.

Photo Credit: Scala / Art Resource, NY / Galleria Borghese, Rome, Italy.

**Figure 1-40.** Botticelli, Sandro (1444–1510). *Judith with the head of Holofernes*. Ca. 1472. Tempera on wood. 12 ¼ x 9 ½ in. (31 x 24 cm). Photo: Nicola Lorusso. Photo Credit: Alinari / Art Resource, NY / Uffizi, Florence, Italy.

**Figure 1-41.** Caravaggio (Michelangelo Merisi da) (1573–1610). *Judith and Holofernes*. Archivio Fotografico della Soprintendenza Speciale per il Patrimonio Storico, Artistico ed Etnoantropologico e per il Polo Museale della Città di Roma. Museo Nazionale d'Arte Antica, Palazzo Barberini, Rome, Italy.

**Figure 1-42.** Caravaggio (Michelangelo Merisi da) (1573–1610). *The Supper at Emmaus*, 1601. Oil and tempera on canvas, 141 x 196.2 cm. Presented by the Hon. George Vernon, 1839 (NG172). © National Gallery, London / Art Resource, NY / National Gallery, London, Great Britain.

**Figure 1-43.** Melozzo da Forlì (1438–1494). *Angel playing the viola da braccio*, c. 1480. Detached fresco, 113 x 91 cm. Photo Credit: Scala / Art Resource, NY / Pinacoteca, Vatican Museums, Vatican State.

**Figure 1-44.** Vivarini, Bartolomeo (c. 1432–c. 1499). *Saint Mark Enthroned surrounded by musical angels*, detail of angels. Central panel of triptych. 1474. Photo Credit: Cameraphoto Arte, Venice / Art Resource, NY / S. Maria Gloriosa dei Frari, Venice, Italy.

## Chapter 2

**Figure 2-1.** Gentileschi, Artemisia (1597–c. 1651). *Judith and her maidservant with the head of Holofernes*. Ca. 1614–1620. Oil on canvas, 117 x 93 cm. Photo Credit: Scala/Ministero per i Beni e le Attività culturali / Art Resource, NY / Galleria Palatina, Palazzo Pitti, Florence, Italy.

**Figure 2-2.** Picasso, Pablo (1881–1973), *Half-Length Female Nude* autumn, 1906. Oil on canvas, 32 3/16 x 26 in. (81.8 x 66 cm). Gift of Florence May Schoenborn and Samuel A. Marx, 1959.619, The Art Institute of Chicago, Chicago, Illinois. © 2011 Artists Rights Society (ARS), New York / ADAGP, Paris.

**Figure 2-3.** de Ribera, Jusepe (1591–1652). *Small Grotesque Head*, ca. 1622. Etching with some engraving, image: 217 x 143 mm. Fine Arts Museums of San Francisco, Mr. and Mrs. Marcus Sopher collection, 2000.212.1.

**Figure 2-4.** de Ribera, Jusepe (1591–1652). *Large Grotesque Head*, 1622. Etching, 13.8 x 10.4 cm. Fine Arts Museums of San Francisco, Achenbach Foundation for Graphic Arts, 1963.30.17826.

**Figure 2-5.** Vinci, Leonardo da (1452–1519), follower of, *Grotesque man with goiter*. Red chalk on white paper. Biblioteca Ambrosiana, Milan, Italy/ © Veneranda Biblioteca Ambrosiana, Milano/ De Agostini Picture Library/ The Bridgeman Art Library.

**Figure 2-6.** Vespini, Jean. (Public Domain). Capella Salita di Calvario. Sacro Monte di Varallo, Varallo Sesia, Italy. Polychrome terracotta sculpture. Photo credit: Mattana.

**Figure 2-7.** Piero della Francesca (c.1420–1492). *Resurrection. Christ steps from the tomb while the guards sleep*. Ca. 1458. Photo Credit: Erich Lessing / Art Resource, NY / Pinacoteca Comunale, Sansepolcro, Italy.

**Figure 2-8.** Landi, Neroccio di Bartolomeo (1447–1500). *Saint Bernardino of Siena Preaching* (left) and *Saint Bernardino performing an exorcism* (right). Photo Credit: Scala / Art Resource, NY / Palazzo Pubblico, Siena, Italy.

**Figure 2-9.** Ernst, Max (1891–1976). *The Attirement of the Bride (La Toilette de la Mariée)*, 1940. Oil on canvas, 129.6 x 96.3 cm. Photo Credit: Cameraphoto Arte, Venice / Art Resource, NY / The Solomon R. Guggenheim Foundation, Peggy Guggenheim Collection, Venice, Italy. © 2011 Artists Rights Society (ARS), New York / ADAGP, Paris.

**Figure 2-10.** Klee, Paul. *Der Held mit dem Flügel (The Hero with the Wing) [Invention 2]*, 1905, etching 10 ⅛ in. x 6 ⅝ in. Credit: San Francisco Museum of Modern Art, Extended loan and promised gift of the Carl Djerassi Trust I; photo: courtesy of SF MOMA, San Francisco, CA.

**Figure 2-11.** Sodoma (Bazzi), Giovanni Antonio. In 1497 Signorelli began painting the *Vita of Saint Benedict da Nurcia as told by Saint Gregory*. The work, 36 scenes in all, was completed 1505–1508 by Sodoma. *Benedict frees a peasant, shackled by the Goths*. Photo Credit: Erich Lessing / Art Resource, NY / Abbey, Monte Oliveto Maggiore, Italy.

**Figure 2-12.** Sodoma (Bazzi), Giovanni Antonio. In 1497 Signorelli began painting the *Vita of Saint Benedict da Nurcia as told by Saint Gregory*. The work, 36 scenes in all, was completed 1505–1508 by Sodoma. *Benedict completes the building of twelve monasteries*. Photo Credit: Erich Lessing / Art Resource, NY / Abbey, Monte Oliveto Maggiore, Italy.

**Figure 2-13.** Raphael (Raffaello Sanzio) (1483–1520). *The Transfiguration*, 1520. Oil on wood, 410 x 279 cm. Photo credit: Scala / Art Resource, NY / Pinacoteca, Vatican Museums, Vatican State.

**Figure 2-14.** Caravaggio (1573–1610). *The Crucifixion of Saint Andrew*, 1606–1607. Oil on canvas. 202.5 x 152.7 cm. Credit: The Cleveland Museum of Art, Leonard C. Hanna, Jr. Fund 1976.2, Cleveland, Ohio.

**Figure 2-15.** van Hemessen, Jan Sanders (c.1504–66). *The Prodigal Son*, 1536. Oil on panel. Musees Royaux des Beaux-Arts de Belgique, Brussels, Belgium/ Giraudon/ The Bridgeman Art Library.

**Figure 2-16.** Duck, Jacob (c.1600–67). *Sleeping woman*. Oil on canvas. Kunsthalle, Rotterdam, Holland/ Artothek/ The Bridgeman Art Library.

**Figure 2-17.** Gillray, James. *The Monstrous Craws at a New Coalition Feast*, Credit © The Trustees of the British Museum.

---

### Chapter 3

**Figure 3-1.** *Stela of the God Bes*. 304 BCE–364 CE. Limestone, paint, h. 38.7 cm, w. 17.7 cm Rogers Fund, 1922 (22.2.23). Image copyright © The Metropolitan Museum of Art / Art Resource, NY / The Metropolitan Museum of Art, New York, NY, USA.

**Figure 3-2.** Teniers, David the Younger (1610–1690). *The Rich Man being led to Hell*, about 1647. Oil on oak, 48 x 69 cm. Bought, 1871 (NG863). © National Gallery, London / Art Resource, NY / National Gallery, London, Great Britain.

**Figure 3-3.** Veronese, Paolo (1528–1588). *Feast in the House of Levi*, detail. Photo Credit: Scala / Art Resource, NY / Accademia, Venice, Italy.

**Figure 3-4.** Pitati, Bonifacio de' (1487–1553). *The Parable of the Rich Man (Epulone) and the Beggar Lazarus*. Photo Credit: Cameraphoto Arte, Venice / Art Resource, NY / Accademia, Venice, Italy.

**Figure 3-5.** van Dyck, Sir Anthony (1599–1641). *Queen Henrietta Maria and her Dwarf Sir Jeffrey Hudson*, ca.1633. Private Collection/ The Bridgeman Art Library.

**Figure 3-6.** Raphael (Raffaello Sanzio) (1483–1520). (School of). *The Cross Appearing to Constantine the Great*, flanked by portraits of two popes (Clement I on the right). Photo Credit: Scala / Art Resource, NY / Stanze di Raffaello, Vatican Palace, Vatican State.

**Figure 3-7.** Trevisani, Francisco. *The Banquet of Mark Anthony and Cleopatra*.

Archivio Fotografico della Soprintendenza Speciale per il Patrimonio Storico, Artistico ed Etnoantropologico e per il Polo Museale della Città di Roma. Galleria Spada, Rome, Italy.

**Figure 3-8.** Mantegna, Andrea (1431–1506). *Lodovico Gonzaga and family with courtiers*. Fresco in the Camera degli Sposi. 1471–1474.

Photo Credit: Erich Lessing / Art Resource, NY / Camera degli Sposi, Palazzo Ducale, Mantua, Italy.

**Figure 3-9.** Molenaer, Jan Miense (1610–1668). *Scene with Dwarfs*, 1646, oil on canvas, 108 x 112.9 x 3.5 cm.

Credit: Collection Van Abbemuseum, Eindhoven, The Netherlands, Photograph: Peter Cox, Eindhoven, The Netherlands.

**Figure 3-10.** Molenaer, Jan Miensz (1610–1668). *The Artist's Studio*. 1631. Oil on canvas, 96.5 x 134 cm. Inv. 3754.

Photo: Joerg P. Anders. Photo Credit: Bildarchiv Preussischer Kulturbesitz / Art Resource, NY Gemaeldegalerie, Staatliche Museen, Berlin, Germany.

**Figure 3-11.** Mor, Anthonis (1519–1576). *The Dwarf of Cardinal Granvelle* (1517–1586).

Photo Credit: Erich Lessing / Art Resource, NY / Louvre, Paris, France.

**Figure 3-12.** Velazquez, Diego Rodriguez (1599–1660). *The court jester. Don Diego de Acedo “El Primo.”* 107 x 82 cm.

Photo Credit: Erich Lessing / Art Resource, NY Museo del Prado, Madrid, Spain.

**Figure 3-13.** Velazquez, Diego Rodriguez. *Prince Baltasar Carlos (1629–1646), son of Philip (Felipe) IV, with a dwarf*. 1632. Oil on canvas, 128.0 x 101.9 cm (50 3/8 x 40 1/8 in.).

Photo Credit: Erich Lessing / Art Resource, NY / Museum of Fine Arts, Boston, MA.

**Figure 3-14.** Sánchez Coello, Alonso (1515–1590). Studio of. *Infanta Isabella Clara Eugenia (1566–1633) and Magdalena Ruiz (dwarf with monkeys)*. Canvas; 207 x 129 cm. Cat. 861.

Photo Credit: Erich Lessing / Art Resource, NY / Museo del Prado, Madrid, Spain.

**Figure 3-15.** Velazquez, Diego Rodriguez (1599–1660). *Portrait of the boy of Vallecas, Francisco Lezcano*, 1637. Oil on canvas, 107 x 83 cm.

Photo Credit: Scala / Art Resource, NY / Museo del Prado, Madrid, Spain.

**Figure 3-16.** Velazquez, Diego Rodriguez (1599–1660). *Las Meninas*. Detail of central group. 1656.

Photo Credit: Scala / Art Resource, NY / Museo del Prado, Madrid, Spain.

**Figure 3-17.** Picasso, Pablo (1881–1973). *Las Meninas*, after Velazquez, No. 1. 1957.

Photo Credit: Bridgeman-Giraudon / Art Resource, NY / Museu Picasso, Barcelona, Spain. © 2011 Artists Rights Society (ARS), New York / ADAGP, Paris.

**Figure 3-18.** *Bertholde, a dwarf*. Engraving by A. Walker. Courtesy of the Wellcome Trust.

**Figure 3-19.** Reinagle, Philip. *Portrait of Joseph Borulawski, the Polish dwarf*, before 1793, unsigned.

Credit: The Royal College of Surgeons of England, Hunterian Museum.

**Figure 3-20.** *Two miniature people, known as the Aztecs. Lilliputians*. Credit: Wellcome Library, London.

**Figure 3-21.** Toulouse-Lautrec, Henri de (1864–1901). *Marcelle Lender dancing the Bolero in ‘Chilperic,’* 1895.

Private Collection: Mrs. John Hay Whitney, NY / The Bridgeman Art Library.

**Figure 3-22.** Picasso, Pablo (1881–1973). *La Nana*, 1901. Oil on card. Museo Picasso, Barcelona, Spain / Giraudon / The Bridgeman Art Library Nationality / copyright status: Spanish / in copyright until 2054. © 2011 Artists Rights Society (ARS), New York / ADAGP, Paris.

## Chapter 4

**Figure 4-1.** Gibson and Zoie (Great Dane and Chihuahua). Originally appeared as cover on *Science* 316 (April 2007).

Photo credit: Deanne Fitzmaurice, San Anselmo, California

**Figure 4-2.** Theseus painter (6th–5th BCE), attributed to. *Ulysses and his companions blinding Polyphemos*. Small black figure oinochoe, h. 22 cm. F342.

Photo: Chuzeville. Photo Credit: Réunion des Musées Nationaux / Art Resource, NY / Louvre, Paris, France.

**Figure 4-3.** del Piombo, Sebastiano. (1485–1547). *Polyphemus*. 1512. Fresco.

Photo: Alessandro Angeli, 2003. Franco Cosimo Panini Editore. © Management Fratelli Alinari. Photo Credit: Alinari / Art Resource, NY / Villa Farnesina, Rome, Italy.

**Figure 4-4.** Caravaggio (Michelangelo Merisi da) (1573–1610). *David with the Head of Goliath*.

Archivio Fotografico della Soprintendenza Speciale per il Patrimonio Storico, Artistico ed Etnoantropologico e per il Polo Museale della Città di Roma. Galleria Borghese, Rome, Italy.

**Figure 4-5.** Gentileschi, Orazio. *David*. Archivio Fotografico della Soprintendenza Speciale per il Patrimonio Storico, Artistico ed Etnoantropologico e per il Polo Museale della Città di Roma. Galleria Spada, Rome.

**Figure 4-6.** Cerrini, G.D. *David with the Head of Goliath*.

Archivio Fotografico della Soprintendenza Speciale per il Patrimonio Storico, Artistico ed Etnoantropologico e per il Polo Museale della Città di Roma. Galleria Spada, Rome.

**Figure 4-7.** Goya y Lucientes, Francisco de (1746–1828). *Saturn devouring one of his sons*, detail. From the series of “Black paintings.” Oil on canvas (1819–1823), 146 x 83 cm. Inv. 763. Photo Credit: Erich Lessing / Art Resource, NY / Museo del Prado, Madrid, Spain.

**Figure 4-8.** Rubens, Peter Paul (1577–1640). *Saturn Devouring His Son*, 1636.

Photo Credit: Scala / Art Resource, NY / Museo del Prado, Madrid, Spain.

**Figure 4-9.** Goya y Lucientes, Francisco de (1746–1828). *The Colossus*. Canvas, 116 x 105 cm. Cat. 2785.

Photo Credit: Erich Lessing / Art Resource, NY / Museo del Prado, Madrid, Spain.

**Figure 4-10.** Pollaiuolo, Antonio del (1433–1498). *Hercules and the Hydra*, 1460. Tempera on wood, 17 x 12 cm. Inv. 8268.

Photo Credit : Erich Lessing / Art Resource, NY Uffizi, Florence, Italy.

**Figure 4-11.** Rubens, Peter Paul (1577–1640). *Prometheus Bound*, begun ca 1611–12, completed by 1618 (The eagle was painted by Frans Snyders). Oil on canvas, 95 ½ x 82 ½ inches (242.6 x 209.5 cm).

Purchased with the W. P. Wiltach Fund, 1950. Photo Credit: The Philadelphia Museum of Art / Art Resource, NY / Philadelphia Museum of Art, Philadelphia, PA.

**Figure 4-12.** Bouts, Dieric the Elder (c.1415–1475). *The Pearl of Brabant*. Right wing with *Saint Christopher Carrying Christ Child*. Detail. Oak panel, 62.6 x 28.1 cm. Inv. WAF 78.

Photo Credit: Bildarchiv Preussischer Kulturbesitz / Art Resource, NY Alte Pinakothek, Bayerische Staatsgemaldesammlungen, Munich, Germany.

**Figure 4-13.** Memling, Hans (1425/40–1494). *Saint Christopher Carrying the Christ Child, flanked by Saints Maurus and Gilles*. Center panel of the Moreel Triptych, 1484.

Photo Credit : Erich Lessing / Art Resource, NY Groeningemuseum, Bruges, Belgium.

**Figure 4-14.** Rubens, Peter Paul (1577–1640). *Altar: Descent from Cross*, closed, left side: Saint Christopher. Right: a hermit. Canvas.

Photo Credit: Erich Lessing / Art Resource, NY Cathedral, Antwerp, Belgium.

**Figure 4-15.** Rowlandson, Thomas. *Drawing of Charles Byrne, the Irish giant, with an admiring audience*, 1782–3, unsigned.

Credit. The Royal College of Surgeons of England, Hunterian Museum.

**Figure 4-16.** Serusier, Paul (1864–1927). *Louise, or The Breton Servant*, 1890 (gouache on board).

Private Collection/ Photo. Christie's Images/ The Bridgeman Art Library.



---

**Chapter 5**

**Figure 5-1.** *Sleeping hermaphrodite.* Marble statue, Antonine copy from 138–192 CE of a 2nd century BCE Hellenistic original.

Photo Credit: Vanni / Art Resource, NY / Museo Nazionale Romano (Palazzo Massimo alle Terme), Rome, Italy.

**Figure 5-2.** Gossaert, Jan. *The Metamorphosis of Hermaphrodite and Salmacis.*

Credit: Museum Boijmans Van Beuningen, Rotterdam, Netherlands.

**Figure 5-3.** *Hermaphrodite*, Roman Imperial period.

Credit © The Trustees of the British Museum.

**Figure 5-4.** Paré, Ambroise. *Oeuvres completes d’Ambroise Paré, ed. J. –F. Malgaigne* (Paris: Baillière, 1841).

Image courtesy UC Regents.

**Figure 5-5.** Bosch, Hieronymus. *Garden of Delights.* Left wing: *Garden of Earthly Delights*, detail. Triptych with shutters Wood; Central panel 220 x 195cm, wings 220 x 97cm. Cat. 2823.

Photo Credit: Erich Lessing / Art Resource, NY / Museo del Prado, Madrid, Spain.

**Figure 5-6.** Ernst, Max (1891–1976). *Men Shall Know Nothing of This*, 1923. Oil on canvas, 80.3 x 63.8 cm.

Photo Credit: Tate, London / Art Resource, NY / Tate Gallery, London, Great Britain.

© 2011 Artists Rights Society (ARS), New York / ADAGP, Paris.

**Figure 5-7.** Paré, Ambroise. *Oeuvres completes d’Ambroise Paré, ed. J. –F. Malgaigne* (Paris: Baillière, 1841).

Image courtesy UC Regents.

**Figure 5-8.** Ribera, Jusepe de (lo Spagnoletto) (c.1590–1652). *The Bearded Woman Breastfeeding*, 1631. Oil on canvas, detail.

Hospital de Tavera, Toledo, Spain/ Giraudon/ The Bridgeman Art Library.

**Figure 5-9.** School, German. 16th c. *The “Hair Man,” Petrus Gonzalvus*, born 1556 on Teneriffa.

Photo Credit: Erich Lessing / Art Resource, NY / Schloss Ambras, Innsbruck, Austria.

**Figure 5-10.** Carracci, Agostino (1557–1609). *Composition with figures and animals.*

Photo Credit: Scala / Art Resource, NY / Museo Nazionale di Capodimonte, Naples, Italy.

**Figure 5-11.** Raphael (Raffaello Sanzio) (1483–1520). *Fire in the Borgo* in the Stanze dell’Incendio in the Vatican Museums.

Photo Credit: Alinari / Art Resource, NY / Stanze di Raffaello, Vatican Palace, Vatican State.

**Figure 5-12.** Rossetti, Dante Gabriel (1828–1882). *The Beloved* (“The Bride”), 1865–66. Oil on canvas, 82.5 x 76.2 cm.

Photo Credit: Tate, London / Art Resource, NY / Tate Gallery, London, Great Britain.

**Figure 5-13.** van der Helst, Bartholomeus. *Gerard Andriesz Bicker* (1622–66), *Heer van Engelenburg. Drost van Muiden.*

Credit: Rijksmuseum, Amsterdam, The Netherlands.

**Figure 5-14.** Hogarth, William (1697–1764). *Marriage A-la-Mode: 1, The Marriage Settlement*, about 1743. Oil on canvas, 69.9 x 90.8 cm.

© National Gallery, London / Art Resource, NY National Gallery, London, Great Britain.

**Figure 5-15.** Gillray, James. *The Gout.*

Credit © The Trustees of the British Museum

---

**Bibliography**


---

- Adelson, Betty. M. *The Lives of Dwarfs: Their Journey from Public Curiosity toward Social Liberation*. New Brunswick, NJ: Rutgers University Press, 2005.
- “Advertisement” in Caulfield, James. *Remarkable Persons*. London: H.R. Young, 1820.  
<http://books.google.com/books?id=n5tIAAAMAAJ&ots=VFqtE6Cat&dq=james%20caulfield%2C%20remarkable%20characters&pg=PR6&output=text>.
- Aguiar-Oliveira, M. H., F. T. Oliveira, R. M. C. Pereira, et al. “Longevity in Untreated Congenital Growth Hormone Deficiency due to a Homozygous Mutation in the GHRH Receptor Gene.” *Journal of Clinical Endocrinology and Metabolism* 95.2 (2010): 714–721.
- Ainsworth, Maryann and Keith Christianson, eds. *From Van Eyck to Brueghel: Early Netherlandish Painting in the Metropolitan Museum of Art*. New York: Metropolitan Museum of Art/Abrams, 1998.
- Ainsworth, Maryann, Stijn Alsteens, and Nadine Orenstein, eds. *Man, Myth and Sensual Pleasures; Jan Gossart’s Renaissance, The Complete Works*. New York: Metropolitan Museum of Art, Yale University Press, 2010.
- Allen, James P. *The Art of Medicine in Ancient Egypt*. New York: Metropolitan Museum of Art, Yale University Press, 2005.
- Art Encyclopedia*: James Gillray, Answers .com,  
<http://www.answers.com/topic/james-gillray>
- Azziz, Ricardo, “A Brief History of Androgen Excess.” *Androgen Excess Disorders in Women: Polycystic Ovary Syndrome and Other Disorders*, ed. R. Azziz, J. Nestler, D. Dewailly. 2nd ed. Totowa, NJ: Humana Press, 2006. 1–16.
- Aron, D. C., J. W. Findling, and J. Blake Tyrrell. “Hypothalamus and Pituitary Gland.” *Greenspan’s Basic and Clinical Endocrinology*, ed. D. G. Gardner and D. Shoback. 8th ed. New York: McGraw Hill, 2007. 101–56.
- Attwater, Donald and Catherine Rachel John. *The Penguin Dictionary of Saints*. London: Penguin, 1995.
- Baillie, Martin. “Early Picasso.” *New Left Review* (November–December 1960). <http://newleftreview.org/?view=100>.
- Becker, W. F. Presidential Address: “Pioneers in Thyroid Surgery.” *Annals of Surgery* 185 (1977): 493–504.
- Belkin, Kristin Lohse. *Rubens*. London: Phaidon Press, 1998.
- Benson, Bernard. *Italian Painters of the Renaissance*. London: Phaidon Press, 1956.
- Bilancioni, Guglielmo. “Le figurazioni della glandola tiroide in Leonard da Vinci: Le prime iconografie del gozzo cretinico ed esoftalmico.” *Archivio di storia della scienza* 4 (1923): 33–58. Coll Misc 4/34 estratto.
- Bilezikian, D. and J. T. Potts. Summary Statement from a Workshop on Asymptomatic Primary Hyperparathyroidism, Perspectives of the 21st Century. *Journal of Clinical Endocrinology and Metabolism* 87.12 (2003): 523–61.
- Bliss, Michael. “Harvey Cushing and ‘Endo-Criminology,’” *Endocrine News* (August 2007): 34–36.
- Bondeson, Jon. *A Cabinet of Medical Curiosities*. Ithaca: Cornell Univ. Press, 1997.
- Boruwaski, Joseph. *The Life and Love Letters of a Dwarf: Being the Memoirs of a Celebrated Dwarf, Joseph Boruwaski, a Polish Gentleman*. Trans. E. Freeman. Birmingham, England: J. Thompson, 1792.
- Boualem, A., M. Fergang, R. Fernandez et al. “A Conserved Mutation in an Ethylene Biosynthesis Enzyme Leads to Andromonoecy in Melons,” *Science* (2008) 321: 836–838.
- Branckhof, B. M. and O. Grim. “Extrathyroidal Manifestations of Multiple Endocrine Neoplasia Type 2,” *Thyroid* 19 (2009): 555–557.
- Brewer’s Dictionary of Phrase and Fable*, ed. Ivor H. Evans. London: Cassell, 1981.

- Bronstein, Glen. "Gynecomastia." *New England Journal of Medicine* 357 (2007): 1229-1237.
- Brown, Jonathan. *Painting in Spain*. New Haven: Yale University Press, 1998.
- Brown, R. J., J. J. Adams, R. Pelekanos et al "Model for Growth Hormone Receptor Activation Based on Subunit Rotation within a Receptor Dimer." *Natural Structure and Molecular Biology* 12 (2005): 814-21.
- "A Chapter on Giants and Dwarfs." *Sketch of the Life, Personal Appearance, Character and Manners of Charles S. Stratton, etc., Robert Bogdan Collection I*. New York: Wynkoop and Hallenbeck, 1863. <http://www.disabilitymuseum.org/lib/docs/693.htm>
- Charcot, J. M. and Paul Richer. *Les Démoniaques Dans L'Art*. Paris: Editions Macula, 1984.
- Chernausek, S. D., P. F. Backeljauw, Franc Jetel. "Long-term Treatment with Recombinant Insulin-like Growth Factor (IGF-I) in Children with Severe IGF-I Deficiency due to Growth Insensitivity." *Journal of Clinical Endocrinology and Metabolism* 92 (2007): 902-10.
- Cheung, P. "Medical and Surgical Treatment of Endemic Goiter." *Textbook of Endocrine Surgery*, ed. Orlo H. Clark, Quan Yang Duh, Electron Kebebew. 2nd ed. Philadelphia: Elsevier/Saunders, 2005. 16-23.
- Christopoulou-Aletra, Helen, Niki Papavramidou, and Paolo Pozzilli. "Goitrous Beauty in Artemisia Gentileschi's Judith and her Maidservant." *Thyroid*, 17.1 (2007): 37-38.
- Clark, Kenneth. from *Looking at Pictures*. <http://www.artchive.com/meninas.htm>
- Clark, Orlo H. "'Asymptomatic' Primary Hyperparathyroidism: Is Parathyroidectomy Indicated?" *Surgery* 116 (1994): 943-56.
- . "The Influence of Endocrine Surgery on General Surgery and Surgical Science." Presidential Address delivered at the Pacific Coast Surgical Association, February 14, 2009, in San Francisco. *Archives of Surgery* 144 (2009): 800-09.
- Cocke, Richard. *Raphael*. London: Chaucer Press, 2004.
- Colcock, Bentley P. "Lest We forget: A Story of Five Surgeons." *Surgery* 64. 6 (December 1968): 1162-72.
- Coleco, S. M., M. Si, E. Reiff, and O. H. Clark. "Hyperparathyroidism after Radioactive Iodine Therapy." *American Journal of Surgery* 194.3 (2007): 323-277.
- Conte, Felix and Mel Grumbach. "Disorders of Sexual Discrimination and Differentiation." *Greenspan's Basic and Clinical Endocrinology*, ed. 8th ed. 562-610.
- Crile, G. W. "Excision of Cancer of the Head and Neck." *Journal of the American Medical Association* 47 (1906): 1780.
- Dasen, Veronique. *Dwarfs in Ancient Egypt and Greece*. Oxford: Clarendon Press, 1993.
- Daston, Lorraine and Katherine Park. *Wonders and the Order of Nature, 1150-1750*. New York: Zone Books, 2001.
- Dixon, Laurinda. *Bosch*. London: Phaidon Press, 2003.
- Egelberger, M. S., et al, "The NIH Criteria for Parathyroidectomy in Asymptomatic Primary Hyperparathyroidism: Are they too limited?" *Annals of Surgery* 239 (2004): 1-8.
- Fazel, R. et al, "Exposure to Low Dose Imaging Radiation from Medical Imaging Procedures." *New England Journal of Medicine* (2009) 361: 849-857.
- Ferriss, J. Barry. "Letter to the Editor on *The Crucifixion of St. Andrew* by Caravaggio." *Thyroid* 16. 5 (2006): 518.
- . "The Many Reasons Why Goiter is Seen in Old Paintings." *Thyroid* 18.4 (2008): 387-94.
- Fiedler, Leslie. *Freaks: Myths and Images of the Secret Self*. New York: Simon and Schuster, 1978.

- Fox, E. L. "Myxedema treated by extract of thyroid by mouth." *British Medical Journal* 2 (1892):941.
- Frantis, Wayne. *Dutch Genre Painting in the Seventeenth Century*. New Haven: Yale Univ. Press, 2004.
- Frantz, A. G. and J. D. Wilson. "Endocrine Disorders of the Breast." *Williams Textbook of Endocrinology*, ed. J.D. Wilson and D.W. Foster. 7th ed. Philadelphia: 1985. 402-21.
- Friedlander, Max. *Early Netherlandish Painting: From Van Eyck to Brueghel*. New York: Phaidon Publishers, 1956.
- Gaitan, E., ed. *Environmental Goitrogenesis*. Boca Raton, Florida: CRC Press, 1989.
- Gaitan, E., H. Lindsay, R. D. Reichert et al, "Antithyroid and Gastrogenic Effects of Millet: Role of C-Glycosylflavones." *Journal of Clinical Endocrinology and Metabolism* 68 (1989): 707-714.
- Gardner, D. G. "Multiple Endocrine Neoplasia." *Greenspan's Basic and Clinical Endocrinology*. 8th ed. 831-43.
- Garrison, Fielding. *An Introduction to the History of Medicine*. Philadelphia: S. B. Saunders, 1929.
- Geoffroy-Schneiter, Berenice. *Fayum*. New York: Assouline Publishing, 2004.
- Gerson, Horst. *Rembrandt's Paintings*, trans. Heinz Norden. Amsterdam: Meulenhoff, 1968.
- "Gigantes." *Theoi Greek Mythology: Exploring Mythology in Classical Literature and Art*. <http://www.theoi.com/Gigante/Gigantes.html>
- Giampalmo, Antonio. "Il Gozzo nell'Arte." *Medicina nel Secoli: Arte e Scienza, Giornale di Storia della Medicina*. 8.1 (1996): 85-103.
- Godfrey, Richard. *James Gillray: The Art of Caricature*. London: Tate Publishing, 2001.
- Goldfarb, Hillard. *The Isabella Stewart Gardner Museum: A Companion Guide and History*. New Haven: Yale Univ. Press, 1995.
- Gombrich, Ernst. *The Preference for the Primitive: Episodes in the History of Western Taste and Art*. New York: Phaidon, 2002.
- Greenspan, Frank. "Medical Treatment of Nodular Goiters." *Endocrine Surgery of the Thyroid and Parathyroid Glands*, ed. O. H. Clark. St. Louis: C.V. Mosby Co., 1985. 35-55.
- . "Radiation Exposure and Thyroid Cancer." *Journal of the American Medical Association* 237 (1977): 2089.
- Guerido, A. et al. "Definitions of Endemic Goiter and Cretinism, Classification of Goiter Size and Severity of Endemias, and Survey Techniques." *Endemic Goiter and Cretinism: Continuing Threats to World Health*, ed. J. T. Dunn and G. A. Medeiros—Net.# 292. Washington, DC: PAHO, 1974.
- Guirand, F. "The Mythology of Classical Greece." *New Larousse Encyclopedia of Mythology*. London: Hamlyn Publishing, 1974. 87-139
- Harwick, R. D. "Our Legacy of Thyroid Surgery," *American Journal of Surgery* 156 (1988): 230-34.
- Haslam, Fiona. *From Hogarth to Rowlandson: Medicine in Art in Eighteenth-Century Britain*. Liverpool, England: Liverpool Univ. Press, 1996.
- Hermitte, Guido Barbieri. *Il Gozzo*. Venosa, Italy: Edizioni Osanna Venosa, 1996.
- Hopkins, David. "Max Ernst's La Toilette de la Marieé." *The Burlington Magazine*, 133.1057 (April, 1991): 237-44.
- Huang, S. M. "Familial Hyperparathyroidism," *Textbook of Endocrine Surgery*, ed. 2nd ed. 493-501.
- Hughes, Robert. *Goya*. New York: Knopf, 2002.
- Huet, Marie-Hélène. *Monstrous Imagination*. Cambridge, MA: Harvard University Press, 1993.
- Iason, Alfred. *The Thyroid Gland in Medical History*. New York: Frobin Press, 1946.
- Ingbar, Sidney. "The Thyroid Gland." *Williams Textbook of Endocrinology*. 7th ed. 682-815.

- Janson, H. W. and A. F. Janson. *History of Art*. 5th ed. New York: Abrams, 1997.
- Johns, Catherine. *Sex or Symbol: Erotic Images of Greece and Rome*. London: British Museum Press, 1989.
- Kelly, F. C. and W. W. Snedden. "Prevalence of Distribution of Endemic Goiter." *Bulletin WHO* 18.5 (1958):173.
- Kennedy, Randy. "At Some Medical Schools, Humanities Join the Curriculum." *The New York Times* (April 17, 2006), <http://www.nytimes.com/2006/04/17/arts/sina.html?pagewanted=1>"using art to train doctors&sq&st=nyt"&scp=1' eyes.
- Kiefer, J. H. "The Hermaphrodite as Depicted in Art and Medical Illustration," *Trans American Association Genito-Urinary Surgeons* 58 (1966): 121-7.
- "James Gillray." <http://www.answers.com/topic/james-gillray>
- Lal, Geeta and Orlo H. Clark. "Endocrine Surgery." *Greenspan's Basic and Clinical Endocrinology*. 8th ed. 911-32.
- Lanchner, Carolyn, ed. *Paul Klee*. New York: Museum of Modern Art, 1987.
- Langmuir, Erika. *The National Gallery Companion Guide*. London: National Gallery Publications, 1994.
- Leroi, Armand Marie. *Mutants*. New York: Viking, 2003.
- Levitsky, L. L. Editorial: "Defining the Role of IGF-1 Therapy for Short Children." *Journal of Clinical Endocrinology and Metabolism* 92 (2007): 813-14.
- Long, Kathleen. *Hermaphrodites in Renaissance Europe*. Burlington, VT: Ashgate Press, 2006.
- Lucie-Smith, Edward. *Sexuality in Western Art*. London: Thames and Hudson, 1991.
- Lyons, A. S. and R. J. Petrucelli, R. J. *Medicine, An Illustrated Art History*. New York: H. N. Abrams, 1987.
- Mandel, Susan and Gerard Burrow. "Diagnosis and Treatment of Thyroid Disease During Pregnancy" *Endocrinology*, ed. Leslie J. DeGroot and J. Larry Jamison. 4th ed. Philadelphia: Saunders, 2001. 2446-53.
- Mandeville, John. *The Travels of John Mandeville*. Memphis, Tennessee: General Books, 2010.
- Marchetti, Valerio, ed. *Jacques Duval, L'Ermafrodito di Rouen, una Storia Medico-legale del XVII Secolo*. Venice, Italy: Marsilio Editori, 1988.
- McCarrison, R. "Observations on Endemic Cretinism in the Chitral and Gilgit Valleys." *Lancet* 2 (1908):1275-80.
- Means, J. H. *The Thyroid and its Diseases*. Philadelphia: J. B. Lippincott, 1948.
- Medvei, Victor Cornelius. *History of Endocrinology*. London: MTP Press, Ltd., 1982.
- Melmed, Schlomo. "Acromegaly," *New England Journal of Medicine* 355 (December 14, 2006): 2558-73.
- Merke, F. *History and Iconography of Endemic Goiter*. Boston: MTP Press, 1984.
- Metropolitan Museum, New York: object label for *Young Woman with a Gilded Wreath*.
- Miles, M. "Signing in the Seraglio: mutes, dwarfs and jestures at the Ottoman Court 1500-1700." *Disability and Society* 1 (2000): 115-34.
- Miller, J. S. and P. K. Diggle. "Diversification of Andromonoecy in Solanum Section Lasiocarpa (Solanaceae): The Roles of Phenotypic Plasticity and Architecture." *American Journal of Botany* 90 (2003): 707
- Moore, Wendy. *Knife Man*. New York: Broadway Books, 2005.
- Moreno, Paolo and Chiara Stefani. *The Borghese Gallery*. Milan, Italy: Touring Club Italiano, 2006.
- Morford, Mark and Robert Lenardon. *Classical Mythology*. 4th ed. New York: Longman, 1991.

- Morgan, Jay Scott. "The Mystery of Goya's Saturn." *New England Review* (2003).  
<http://community.middlebury.edu/~nereview/22-3/morgan.html>.
- Morgan, Tom. *Saints: A Visual Almanac of the Virtuous, Pure, Praiseworthy, and Good*. San Francisco, CA: Chronicle Books, 1994.
- Museo Nazionale d'Arte Antica, Rome, Palazzo Altemps: object label for *Amore and Psyche*.
- Nelson, D. H. "Pituitary Adrenal System." *Endocrinology: People and Ideas*, ed. S.M. McCann. Bethesda, Maryland: American Physiological Society, 1988, 87–115.
- Néret, Gilles. *Rubens: The Homer of Painting*. London: Taschen, 2004.
- Nuland, Sherwin. *Medicine: The Art of Healing*. New York: Hugh Lauter Levin Associates, 1992.
- Osler, Sir William. *The Principles and Practice of Medicine*, rev. Thomas McCrae. 11th ed. New York: D. Appleton, 1931.
- Ovid. *The Metamorphoses, Book IV*. Trans. Horace Gregory. New York: Viking, 2001.
- Paré, Ambroise. *On Monsters and Marvels*, Trans. J.C. Pallister. Chicago: University of Chicago Press, 1982.
- Park, Katharine. *Doctors and Medicine in Early Renaissance Florence*. Princeton, NJ: Princeton Univ. Press, 1985.
- Pasieka, J. L. and L. C. Parsons. "Prospective Surgical Outcome Study of Relief of Symptoms Following Surgery in Patients with Primary Hyperparathyroidism." *World Journal of Surgery* 22 (1998): 513–19.
- "Polyphemos." *Theoi Greek Mythology: Exploring Mythology in Classical Literature and Art*.  
<http://www.theoi.com/Gigante/GigantePolyphemos.html>.
- Porter, Roy. *Bodies Politic*. London: Reaktion Books, 2001.
- . *The Greatest Benefit to Mankind*. New York: Norton, 1997.
- "Poseidon and the Giant Polybotes." *Theoi Greek Mythology: Exploring Mythology in Classical Literature and Art*.  
<http://www.theoi.com/Gallery/K2.6.html>.
- Puglisi, Catherine. *Caravaggio*. New York: Phaidon Press, 1998.
- "Pygmaioi." *Theoi Greek Mythology: Exploring Mythology in Classical Literature and Art*. <http://www.theoi.com/Phylos/Pygmaioi.html>.
- Quigley, C. A. "Genetic Basis of Sex Determination and Sex Differentiation," *Endocrinology*. 4th ed. 1926–46.
- Rafart i Planas, Claustre. *Picasso's Las Meninas*, Trans. Valerie Collins. Barcelona: Editorial Meteora, 2001.
- Read, Anthony and David Fischer. *Berlin Rising*. New York: W. W. Norton and Co., 1994.
- Read, Herbert, ed. *The Thames and Hudson Dictionary of Art and Artists*. New York: Thames and Hudson, 1994.
- "Renaissance." Adapted from *A Guide to the Study of Literature: A Companion Text for Core Studies 6, Landmarks of Literature*, ©English Department, Brooklyn College.  
<http://academic.brooklyn.cuny.edu/english/melani/cs6/ren.html>
- Roach, Mary. *Stiff: The Curious Lives of Human Cadavers*. New York: Norton, 2003.
- Roehrer, Hans and Peter Goretzki. "Management of Goiter and Thyroid Nodules in an Area of Endemic Goiter." *Surgical Clinics of North America* 67.2 (1987): 233–49.
- Rolleston, Sir Humphrey Davy. *The Endocrine Organs in Health and Disease with an Historical Review*. London: Oxford University Press, 1936.
- Rosen, M. P. and M. I. Cedars. "Female Reproductive Endocrinology and Infertility." *Greenspan's Basic and Clinical Endocrinology*. 8th ed. 502–61.

- Rosenfield, R. L. and L. Cutler. "Somatic Growth and Maturation," *Endocrinology*, ed. De Groot and Jamison. 4th ed. 477-502.
- Sánchez, Julian and Pérez, Alfonso E. eds. *Velasquez*. Madrid, Spain: Museo del Prado, 1990.
- "Saturn Devouring His Son." [http://en.wikipedia.org/wiki/Saturn\\_Devouring\\_His\\_Son](http://en.wikipedia.org/wiki/Saturn_Devouring_His_Son)
- Sawin, Clark. "Defining Thyroid Hormone: Its Nature and Control," *Endocrinology: People and Ideas*, ed. S.M. McCann. 149-99.
- Schleier, Erich. "Italian Painting of the Thirteenth to the Eighteenth Century." *The Gemaldegalerie, Berlin: A History of the Collection and Selected Masterworks*, ed. H. Bock, R. Grosshans, J. Kelch, W. Köhler, and E. Schleier. London: Weidenfeld and Nicolson, 1990. 267-392.
- Schneider, A. B. "Radiation-induced Thyroid Tumors." *Endocrinology and Metabolism Clinics of North America* 19 (1990): 495-508.
- Sciré, Giovanna Nepi, ed. *The Accademia Galleries in Venice*. Milan, Italy: Electa, 1998.
- Seaborg, E. "Catching Acromegaly Early," *Endocrine News* 18 (March 2008): 18-21.
- Sedgwick, C. E. and H. S. Filtzer. "Operative History of Goiter." *Major Problems in Clinical Surgery* 15 (1974): 1-4.
- "Serusier," *Olquls Gallery*. <http://www.abcgallery.com/s.serusier/serusierbio.html>.
- Sherman, S. and J. Phagin. "Why Thyroid Cancer?" *Thyroid* 15 (2005): 303-4.
- "Sir John Mandeville," Novelguide.com, [http://www.novelguide.com/a/discover/ewb\\_10/ewb\\_10\\_04161.html](http://www.novelguide.com/a/discover/ewb_10/ewb_10_04161.html)
- Sokal, J.E. "The Problem of Malignancy in Nodular Goiter: Recapitulation and a Challenge." *JAMA* 170 (1959): 402-12.
- Solomon, Nanette. *Shifting Priorities: Gender and Genre in Seventeenth Century Dutch Paintings*. Stanford: Stanford University Press, 2004.
- Stalabrass, Julian. Notes on "The Robing of the Bride" and "Men Shall Know Nothing of This." *Max Ernst*, ed. Ian Turpin. London: Phaidon Press, 1979. 54, 98.
- Stedman's Medical Dictionary*. Baltimore: Williams and Wilkins Co., 1961.
- Sturgeon, Cord and Orlo Clark. "Familial Non-medullary Thyroid Cancer." *Thyroid* 15 (2005): 588 - 93.
- Styne, Dennis. "Growth." *Greenspan's Basic and Clinical Endocrinology*. 8th ed. 171-208.
- Sutter, N. B., C. D. Bustamante, and K. Chase et al, "A Single IGF-1 Allele is a Major Determinant of Small Size in Dogs," *Science* 316 (April 6, 2007): 1112-1115.
- Tazartes, Maurizia. *Velasquez*. Firenze, Italy: Giunti Gruppo Editoriale, 1996
- Thompson, C. J. S. *The Mystery and Lore of Monsters*. London: Williams and Norgate, 1930.
- Tunbridge, W. M., D.H. Evered. R. Hall et al. "The Spectrum of Thyroid Disease in a Community: the Wickham Survey." *Clinical Endocrinology* 7 (1977): 481-93.
- Turpin, Ian, ed. *Max Ernst*. London: Phaidon Press, 1979.
- Udelsman, R. et al, "Surgery for Asymptomatic Primary Hyperparathyroidism: Proceedings of the Third International Workshop." *Journal of Clinical Endocrinology and Metabolism* 94 (2009): 366-72.
- Uffizi Florence*. New York: Newsweek: Great Museums of the World Milan, Italy: Mondadori Editore, 1979.
- Underwood, L.E. and J. J. Van Wyk. "Normal and Aberrant Growth," *Williams Textbook of Endocrinology*. 7th ed., 155-205.
- Vellar, I. D. and T. P. Dunhill. "The Forgotten Man of Thyroid Surgery," *Medical History* 18 (1974): 22-50.

Vicini, Maria Lucrezia. *Guide to the Spada Gallery*. Rome: Bedart, 2002.

Victoria and Albert Museum. *English Caricature: 1620 to the Present*.

London: Victoria and Albert Museum, 1984.

Weetman, A. P. "Autoimmune Thyroid Disease," *Endocrinology*. 4th ed. 1409-21.

Welbourn, Richard. *The History of Endocrine Surgery*. London: Praeger, 1990.

Wheeler, Susan. *Five Hundred Years of Medicine in Art*. Aldershot, England: Ashgate, 2001.

Whitehead, James Beswick. *Reflections of Rigoletto*, 2001  
[www.bjornetjenesten.dk/teksterdk/Rigoletto/reflections\\_of\\_rigoletto.htm](http://www.bjornetjenesten.dk/teksterdk/Rigoletto/reflections_of_rigoletto.htm).

WHO/UNICEF/ICCIDD, "Progress Towards The Elimination Of Iodine Deficiency Disorders (Idd)," *Document WHO/SHD*. 99.4. Geneva, Switzerland: World Health Organization, 1999.

Wind, Barry. 'A Foul and Pestilent Congregation': *Images of 'Freaks' in Baroque Art*. Aldershot, England: Ashgate, 1998.

Wood, Christopher. *The Pre-Raphaelites*. New York: Viking Press, 1981.

Yampolsky, C. and H. Yampolsky. "Distribution of Sex Forms in the Phanerogamic Flora," *Bibliotheca Genetica* 3 (1922): 1-22.

Zwemer, R. L. "An Experimental Study of the Adrenal Cortex: The Survival Value," *American Journal of Physiology* 79 (1927): 641-657.



---

## Endnotes

---

### Introduction

1. Katharine Park, *Doctors and Medicine in Early Renaissance Florence* (Princeton, NJ: Princeton Univ. Press, 1985) 221.
2. The anatomy theater of Padua was built in 1594, that of Leiden in 1596 and that of Bologna in 1637. Although the tiered seating resembled that of Greek and Roman theaters, the anatomy theater seats were arranged in concentric circles so that the dissection table could be viewed from all angles.
3. Randy Kennedy, "At Some Medical Schools, Humanities Join the Curriculum," *The New York Times* (April 17, 2006), <http://www.nytimes.com/2006/04/17/arts/sina.html?pagewanted=1&st=nyt&scp=1> eyes. Kennedy quotes from a 2001 article in *Journal of the American Medical Association*.
4. A. S. Lyons and R. J. Petrocelli, *Medicine: An Illustrated Art History* (New York: H. N. Abrams, 1987) 416.
5. da Vinci's drawing of the thyroid gland was flawed, however, because the drawing shows the gland without an isthmus, probably because it was based on the findings of animal rather than human dissection.

6. Portraits painted when low necklines were the fashion suggest a connection between neck and breasts as one erogenous zone.
7. Horst Gerson, *Rembrandt's Paintings*, trans. Heinz Norden (Amsterdam: Meulenhoff, 1968) 50. Gerson compares Rembrandt's painting with others on the subject of the anatomy lesson common in seventeenth century Netherlands. He notes that Rembrandt's rendition of the familiar theme, however, "looks more like a history painting than a portrait" and that the "patron" (Nicholas Tulp, a well known anatomist who had studied with a student of Vesalius) "had a voice in determining what was to be painted, and how it was to be done" (50). The fact of the commission may explain the dramatic and somewhat public or officially documentary nature of the painting.
8. Marie-Hélène Huet, *Monstrous Imagination* (Cambridge: Harvard Univ. Press, 1993) 22.
9. Barry Wind, 'A Foul and Pestilent Congregation': *Images of 'Freaks' in Baroque Art* (Burlington, Vermont: Ashgate, 1998) 6.
10. "Advertisement" from James Caulfield, *Remarkable Persons* (London, H. R. Young, 1820, iii–vii <http://books.google.com/books?id=n5tIAAAAMAAJ&ots=VFqtE6Cat&dq=james%20caulfield%2C%20remarkable%20characters&pg=PR6&output=text>).

### Chapter 1

11. See **Figure 22**, *Summer, Mosaico Pavimentale*, (4th–5th century CE, Rome, Museo Nazionale Romano, Massimo alle Terme); **Figure 35**, Vittore Crivelli, *St. Catherine of Alexandria* (1494, London, National Gallery); **Figure 14**, Peter Paul Rubens, *Delilah in Samson and Delilah* (1609, London, National Gallery); **Figure 17**, Sandro Botticelli, *La Primavera* (1477–78, Florence, Uffizi Gallery); **Figure 20**, Dante Gabriel Rossetti, *A Daydream* (1878, London, Victoria and Albert Museum).
12. We know that both Michelangelo and da Vinci made sketches of the goiter, and Michelangelo wrote about the condition. Neither, however, depicted the goiter in formal paintings as much as some of their predecessors or followers. In addition to anatomical drawings of the thyroid gland, da Vinci's painting *Madonna and Child* depicts a goiter. See **Figure 1–5**. Michelangelo's fresco of *The Last Judgment* in the Sistine Chapel includes the head of a man with exophthalmos, a feature of Graves' disease or autoimmune thyroid disease.
13. Frank S. Greenspan, "Medical Treatment of Nodular Goiters" in *Endocrine Surgery of the Thyroid and Parathyroid Glands*, ed. O.H. Clark (St. Louis: CV Mosby Co., 1985) 35.
14. A. Guerido et al, "Definitions of Endemic Goiter and Cretinism, Classification of Goiter Size and Severity of Endemias, and Survey Techniques in Endemic Goiter and

- Cretinism”: *Continuing Threats to World Health*, ed. J. T. Dunn and G. A. Medeiros—Net. # 292 (Washington, DC: PAHO, 1974).
15. F. C. Kelly and W. W. Snedden, “Prevalence of Distribution of Endemic Goiter,” *Bulletin WHO* 18.5 (1958) 173.
16. WHO/UNICEF/ICCIDD, “Progress Towards The Elimination Of Iodine Deficiency Disorders (Idd),” *Document WHO/SHD*. 99.4 (Geneva, Switzerland: World Health Organization, 1999).
17. Reported by J. E. Sokal, “The Problem of Malignancy in Nodular Goiter: Recapitulation and a Challenge” *JAMA* 170 (1959): 402–412.
18. W. M. Tunbridge, D. H. Evered, R. Hall et al, “The Spectrum of Thyroid Disease in a Community: the Wickham Survey,” *Clinical Endocrinology* 7 (1977): 481.
19. H. Roeher and Peter Goretzki, “Management of Goiter and Thyroid Nodules in an Area of Endemic Goiter,” *Surgical Clinics of North America* (1987): 223.
20. E. Gaitan, ed. *Environmental Goitrogenesis* (Boca Raton, Florida: CRC Press, 1989).
21. P. Cheung, “Medical and Surgical Treatment of Endemic Goiter,” *Textbook of Endocrine Surgery*, ed. Orlo H. Clark, Quan Yang Duh, Electron Kebebew (Philadelphia: Elsevier/Saunders, 2005) 19.
22. E. Gaitan, R. H. Lindsay, R. D. Reichert et al, “Antithyroid and Gastrogenic Effects of Millet: Role of C-Glycosylflavones,” *Journal of Clinical Endocrinology and Metabolism* 68 (1989): 707.
23. A. P. Weetman, “Autoimmune Thyroid Disease,” *Endocrinology*, 4th ed., ed. L. J. De Groot and J. L. Jameson (Philadelphia W.B. Saunders, 2001) 1409.
24. Frank Greenspan, “Radiation Exposure and Thyroid Cancer,” *Journal of the American Medical Association* 237 (1977):2089.
25. A. B. Schneider, “Radiation-induced Thyroid Tumors,” *Endocrinology and Metabolism Clinics of North America* 19 (1990): 499
26. S. Sherman and J. Phagin, “Why Thyroid Cancer?” *Thyroid* 15 (2005): 303–304.
27. Cretinism is the condition of severe hypothyroidism in children. It results in abnormal body habitus, short stature, swelling and intellectual deficiency. Myxedematous cretinism describes a swelling with mucus. According to *Brewer’s Dictionary of Phrase and Fable*, ed. Ivor H. Evans (London: Cassell, 1981), the word cretin derives from “the Crétins of the Alps” and “is a corruption of Christian (Chrétien) because being baptized, and only idiots, they were ‘washed from original sin,’ and incapable of actual sin” (286).
28. R. McCarrison, “Observations on Endemic Cretinism in the Chitral and Gilgit Valleys,” *Lancet* 2 (1908):1275–1280.
29. Richard Welbourn, *The History of Endocrine Surgery* (London: Praeger, 1990) 19.
30. J. H. Means, *The Thyroid and its Diseases* (Philadelphia: J. B. Lippincott, 1948) 3.
31. Victor Cornelius Medvei, *History of Endocrinology* (London: MTP Press, Ltd., 1982) 846.
32. Quoted in Alfred Iason, *The Thyroid Gland in Medical History* (New York: Frobin Press, 1946) 37
33. A. S. Lyons and R. J. Petrucelli, 71.
34. Cord Sturgeon and Orlo Clark, “Familial Non-medullary Thyroid Cancer,” *Thyroid* 15 (2005): 588.
35. Fielding Garrison, *History of Medicine*, 4th ed. (Philadelphia: W. B. Saunders, 1960) 206–207.
36. See **Chapter 2** for an illustration and more detailed discussion of da Vinci’s anatomical knowledge of the thyroid gland and thyroid disease.
37. Sherwin Nuland, *Medicine: The Art of Healing* (New York: Hugh Lauter Levin Associates, 1992) 42. Nuland claims that with the publica-

- tion of *De Fabrica* and the work of Van Calcar and Vesalius, “Modern anatomy, and therefore modern medical knowledge, begins on these pages” (42).
38. Susan Mandel and Gerard Burrow, “Diagnosis and Treatment of Thyroid Disease During Pregnancy,” in *Endocrinology* 4th ed. 2457.
39. Sir William Osler, *The Principles and Practice of Medicine* 11th ed., rev. Thomas McCrae (New York: D. Appleton, 1931) 889.
40. Sidney Ingbar, “The Thyroid Gland” in *Williams Textbook of Endocrinology* 7th ed., ed. Jean Wilson and Daniel Foster (Philadelphia: W. B. Saunders) 706.
41. Medvei quotes Catullus’ reference to the enlarged neck of a new bride as follows: “At dawn her nurse will not be able to wind/The same thread round the bride’s neck/that was there last night” [From *Catullus*, trans. James Michie (London: Panther Books, 1972), lines 376–377] quoted in Medvei 38.
42. H. W. Janson and Anthony F. Janson, *History of Art* 5th ed. (New York: Abrams, 1997) 254.
43. Although we do not show examples here, subtly rendered diffuse goiters are visible in some of the female figures in Giotto’s frescoes in the Scrovegni Chapel in Padua and in some of Duccio’s and Martini’s portraits of the Virgin Mary in Siena.
44. A similar diffuse goiter is more visible in the figure of the Virgin in Piero’s *Madonna del Parto* for which he presumably used the same model. (See **Figure 1–26**).
45. Giovanni Battista Cima da Conegliano’s *Madonna of the Orange between Saints Ludovico of Tolosa and Saint Jerome* (early 16th century, Venice, Accademia Galleries) and several other paintings of the Virgin by the same artist use a similar composition that draws attention to the young Virgin’s diffuse goiter.
46. *Sfumato* technique is defined as the “rendering of form by means of subtle tonal gradations so as to eliminate any sharply defined contours” (*Thames and Hudson Dictionary of Art and Artists*, ed. Herbert Read (London: Thames and Hudson, 1994) 331).
47. See Welbourn 20.
48. See Welbourn 20 and Medvei 107–109.
49. Erich Schleier, “Italian Painting of the Thirteenth to the Eighteenth Century,” *The Gemaldegalerie, Berlin: A History of the Collection and Selected Masterworks* (London: Widenfeld and Nicolson, 1990) 316.
50. See **Chapter 2** for a full explanation of Graves’ disease.
51. Bernard Berenson, *Italian Painters of the Renaissance* (London: Phaidon, 1956) goes further to suggest that every anatomical detail in Botticelli’s paintings “appeals so vividly to the sense of touch that our fingers feel as if they had everywhere been in contact with [the] body,” but he also claims that Botticelli’s paintings have “a way of rendering even tactile values with almost no body, ... by translating them as faithfully ... into values of movement” (68). The contrast between Botticelli’s emphasis on the Virgin’s movement that animates her face and neck and Lippi’s more static emphasis on the Virgin’s face and neck is apparent when one views the two Annunciation paintings side by side.
52. Mannerist painting refers to “Italian painting ... from the period between the Renaissance and the Baroque period.” It “is characterized by a search for novelty and excitement leading to capriciously elongated figures” (*Thames and Hudson Dictionary of Art and Artists* 227–228).
53. Janson sees Parmigianino’s Virgin as an example of typical Mannerist artifice, “elongated ... embodying an ideal of a beauty as remote from nature as any Byzantine figure,” 485.
54. *Chiaroscuro* refers to “the use of strong contrasts of light and shade for dramatic impact,” *Thames and Hudson Dictionary of Art and Artists* 82.
55. Paolo Moreno and Chiara Stefani, *The Borghese Gallery* (Milan: Touring Club Italiano, 2006) 190.
56. Catherine Puglisi, *Caravaggio* (New York: Phaidon, 1998) 195.

57. Kristin Lohse Belkin, *Rubens* (London: Phaidon, 1998) 155. Belkin suggests that all of the picture's details noted above "contribute to the atmosphere of eroticism, which provides the moral of the story" 155.

58. Paolo Moreno and Xhiara Stefani, *The Borghese Gallery* note that "recent conservation work has revealed ... the presence of various pentimenti" in the original work such as "a male figure toward which the sorceress was turning her eyes," a detail that may have called more attention to the subject's sensual appeal (117).

59. In the original painting on the same subject of which Campana's painting was a commissioned copy, the figure of Helen has a less noticeable goiter. Although Campana's copy is otherwise faithful to Reni's original in The Louvre, the choice to add the detail of a diffuse goiter may reflect the artist's familiarity with this anatomical anomaly in the Emilia Romana region of Italy in which he was painting. According to Maria Lucrezia Vicini in *Guide to the Spada Gallery* (Rome: Bedart, 2002), the painting was "executed for Cardinal Bernardino Spada ... and touched up by Reni himself" 64.

60. Belkin notes that the model for this figure was most likely Rubens's second wife Helene Fourment whom he frequently painted in dramatic roles such as this (244).

61. Christopher Wood, *The Pre-Raphaelites* (New York: Viking Press, 1981) 10.

62. Wayne Frantis, *Dutch Seventeenth-Century Genre Paintings* (New Haven: Yale Univ. Press, 2004) 226.

63. In her book *Shifting Priorities: Gender and Genre in Seventeenth-Century Dutch Paintings* (Stanford: Stanford Univ. Press, 2004) Nanette Solomon points out that such paintings were not viewed as "pejorative" in their reference to alcohol (32). Thus the voluptuous woman representing temperance seems ambiguously to epitomize the benefits of moderation rather than abstinence.

64. New York, Metropolitan Museum, object label for *Young Woman with a Gilded Wreath*.

65. Berenice Geoffroy-Schneider, *Fayum* (New York: Assouline Publishing, 2004) 16. Geoffroy-Schneider also points out the "paradoxical duality" of such realism in portraits intended to be buried with the dead (16).

66. In his article "Le figurazioni Della glandola Tiroide in Leonard da Vinci: Le prime iconografie del gozzo cretinico ed esoftalmico," *Archivio di storia della scienza* 4 (1923): 33-58. Coll Misc 4/34 estratto Guglielmo Bilancioni's comment on this painting of Simonetta Vespucci further explains the way in which the artist achieved such contrast: "La donna avrebbe un collo da Niobe se non fosse un poco

lungo e prominente per l'ipertrofia della tiroide; ma ci piace come una cosa giovane intatta, circondata di un'aria limpida e vibrata" (53). ("The woman would have a neck like Niobe's if it were not a bit long and prominent in its hypertrophy of a thyroid" (our translation). Comparing Botticelli's *Simonetta to Niobe* [a mother figure who personifies maternal sorrow in Greek mythology], Bilancioni suggests that the Renaissance ideal of feminine beauty required an elongated neck even if a frontal pose might reveal the diffuse swelling of the thyroid gland.

67. Erika Langmuir, *The National Gallery Companion Guide* (London 1994) 238.

68. It is interesting to observe that Rubens's series of paintings on Marie de Medici in the Louvre also reveals a diffuse goiter in various representations of the queen. The work was executed long before Rubens used Helene Fourment as a model. Belkin notes that although "Juno, patroness of marriage, may have been a more appropriate symbol [for Helene Fourment], her image was a matronly one, without the erotic connotations of Venus" (249).

69. There are at least three women with diffuse goiters in the Lippi painting. Besides St. Anne, the figure of the Virgin Mary also has a diffuse goiter as does the figure of the turbaned woman on the stairs at the right of the painting.

70. Presumably, the same model with the same goiter in *The Virgin and Child Before the Firescreen* also appears in *The Annunciation Triptych* by Robert Campin and workshop (New York, Metropolitan Museum of Art). See *From Van Eyck to Breugel: Early Netherlandish Painting in The Metropolitan Museum of Art*, ed. Maryan W. Ainsworth and Keith Christiansen (New York: Metropolitan Museum of Art/Abrams, 1998) 96 for a discussion on the connection between the two paintings.

71. Van Dyck appears to have used the same model (with the same goitrous neck) for the grieving Virgin Mary in *The Deposition*, Oxford, Ashmolean Museum and *The Deposition* in Munich, Alte Pinakothek.

72. Tom Morgan, *Saints: A Visual Almanac of the Virtuous, Pure, Praiseworthy, and Good* (San Francisco, CA: Chronicle Books) 142.

73. Donald Attwater with Catherine Rachel John, *The Penguin Dictionary of Saints* (London, Penguin, 1995) 80.

74. In his book *The Preference for the Primitive: Episodes in the History of Western Taste and Art* (New York, Phaidon, 2002) Ernst Gombrich describes Del Piombo's work as "a painting that borders on the sadistic" (106). We would argue, however, that in his anatomical realism, as in that revealed in many of the paintings discussed in our book, the artist invites us to look at the brutal, the ugly, and sadistic tendencies of humanity as one

aspect of the wide spectrum of the human condition.

75. Judith is described in the Apocrypha as "of a goodly countenance, and very beautiful to behold" (Judith 8:7).

76. The peasant woman is shown with thyroid nodules, similar to those of the peasant woman in *The Crucifixion of St. Andrew* (See Figure 14 in Chapter 2). This figure is another example of Caravaggio's use of naturalistic details, in this case calling attention to the humble status of the woman assisting the more noble Judith.

77. Langmuir 180.

78. See **Chapter 5** for a discussion of androgyny and hermaphroditism in paintings that portray men and boys with both male and female characteristics.

## Chapter 2

79. In their article "Goitrous Beauty in Artemisia Gentileschi's *Judith and her Maidservant*" in *Thyroid*, 17 (2007) 1 37–38 authors Helen Christopoulou-Aletra, Niki Papavramidou, and Paolo Pozzilli argue that "most paintings representing female figures with goiter are of either patrician women or of the sacred figure of the Virgin Mary" (37). They note that "In Gentileschi's painting Judith is elevated both to the status of patrician, as seen by her attire, and to a Virgin Mary-like role ... chosen by God" (37). We would argue, however, that Gentileschi departs from the image of a humble self-effacing Virgin Mary (37) and that Gentileschi's perspective is more humanistic than religious.

80. In a later painting of Judith by Gentileschi (1625, Detroit, Institute of Arts) with the same title as the painting discussed above, a goiter in Judith's neck is also visible but less overtly grotesque, and the painting seems to focus more on Judith's "inner drama" than on her external role (Janson 552). Janson describes this later painting as "uniquely" Gentileschi's rather than indicative of the influence of Artemesia's father Orazio Gentileschi or of Caravaggio, an influence he sees in the earlier painting (Janson 552). Considering the number of paintings in Gentileschi's oeuvre that depict strong looking women with noticeable goiters, however, the earlier painting seems to have Artemisia Genetileschi's individual stamp.

81. F. Merke, *History and Iconography of Endemic Goiter* (Boston: MTP Press, 1984) 4.
82. Francis Greenspan, "Medical Treatment of Nodular Goiters" 37.
83. See **Figure 2-6** for an example of cretinism.
84. See **Figure 2-13** for an example of exophthalmos and gynecomastia in male figures.
85. I. D. Vellar and Thomas Peele Dunhill, "The Forgotten Man of Thyroid Surgery," *Medical History* 18 (1974): 22.
86. C. E. Sedgwick and H. S. Filtzer, "Operative History of Goiter," *Major Problems in Clinical Surgery* 15 (1974): 1-4.
87. *Bronchiocele* was the term used for goiter in ancient Greece and Rome.
88. See **Chapter 1** for the discussion on Monastic Medicine.
89. See **Chapter 1** for a full account of Vesalius' work.
90. Lorenz Heister, *Chiurgia, in welcher alles, was zur Wund-Artzney gehøret, nach der neusten and besten Art* (Nurenberg: J. Hoffman 1718, English translation: London, 1742) quoted in Medvei 156-157.
91. Mary Roach, *Stiff: The Curious Lives of Human Cadavers* (New York: Norton, 2003) 40-41.
92. B. P. Colcock, "Lest We forget: A Story of Five Surgeons," *Surgery* 6 (December, 1968) : 1163.
93. W. F. Becker, Presidential Address: "Pioneers in Thyroid Surgery," *Annals of Surgery* 185 (1977): 495.
94. E. L. Fox, "Myxedema treated by extract of thyroid by mouth," *British Journal of Medicine* 2 (1892): 941
95. W. F. Becker, *Presidential Address* 502.
96. G. W. Crile, "Excision of Cancer of the Head and Neck," *Journal of the American Medical Association* 47 (1906): 1780.
97. W. F. Becker, *Presidential Address* 502.
98. R. D. Harwick, "Our Legacy of Thyroid Surgery," *American Journal of Surgery* 156 (1988): 230.
99. See **Chapter 3** on the topic of cretinism and dwarfism.
100. See Merke 141, Figures 43 and 44.
101. In an article on "The Discovery of Thyroid Replacement Therapy, Part 1: In the Beginning," *Journal of the Royal Society of Medicine* 104.1 (January 2011), Stefan Slater quotes the lines from *The Tempest* as well as the comments of a character in Mark Twain in *A Tramp Abroad*, who after traveling claims that he has seen "the principal features of Swiss scenery—Mont Blanc and the goiter" (16).
102. Antonio Giampalmo, "Il Gozzo nell'Arte," *Medicina nel Secoli: Arte e Scienza, Giornale di Storia della Medicina*, 8.111 (1996): 99.
103. Wind 53.
104. See **Chapter 3** of our book for more discussion of the characteristics of cretinism.
105. Guido Barbieri Hermitte does the same in his book *Il Gozzo*.
106. David Hopkins, *The Burlington Magazine*, 133. 1057 (April, 1991): 244.
107. Hopkins 244. Hopkins (244, note 60) also cites an account of such sorcery, "which Ernst may well have known" in J. Michelet, *La Sorciere* (1862), tr. Allinson, *Satanism and Witchcraft: A Study in Medieval Superstition*, London (1965) 47.
108. Alluding to Leonardo da Vinci's painting of *Leda and the Swan*, Hopkins speculates that "Ernst would surely have seen a connexion [sic] between the phallic nature of Zeus as swan in Leonardo's depiction and Freud's concern with the 'mythological' significance of the stork fable" 241.
109. Julian Stalabrass, notes on *The Robing of the Bride* in Ian Turpin, *Ernst* (London: Phaidon, 1979) 98.
110. *Paul Klee*, ed. Carolyn Lanchner (New York: Museum of Modern Art, 1987) 84.

111. J. M. Charcot and Paul Richer, “Le Jeune Possédé,” *Les Démoniaques Dans L’Art* (Paris: Editions Macula, 1984) 28–31.
112. In *Medicine: The Art of Healing*, contemporary surgeon and medical historian Sherwin Nuland also diagnoses the boy’s “fit” as indicative of “a complex partial seizure, or epilepsy, and in Raphael’s time “many came to believe that the devil had gotten into patients who convulsed in an epileptic fit” (38). We maintain, however, that the presence of so many signs of Graves’ disease makes this autoimmune disorder of the thyroid gland a more likely diagnosis.
113. J. Barry Ferriss, “Letter to the Editor on *The Crucifixion of St. Andrew* by Caravaggio,” *Thyroid* 16.5: 518. Ferriss also cites H. Hibbard, *Caravaggio* (London: Thames and Hudson, 1983) 221 and K. Christiansen, *Caravaggio: The Final Years* (catalogue) (Napoli: Electa, 2005), 109 concerning the figure of the old woman.
114. Ferris, “The Many Reasons Why Goiter is Seen in Old Paintings,” *Thyroid* 18.4: 387–394 notes a contrast between the old woman in *The Crucifixion of St. Andrew* and another elderly woman in a now lost painting by Caravaggio of *Judith and Holofernes*, a copy of which is in the Museo Pignatelli, Naples. The latter painting depicts a peasant woman standing next to Judith as they contemplate the head of Holofernes. As Ferris notes, “the maid has a large multinodular goiter, almost certainly the result of iodine deficiency” 394.
115. We first became aware of the common usage of this term in our research at the Wellcome Library in London where an assistant suggested it as a key word in our investigation of the library’s electronic files. Subsequent research has revealed that “freakery” is more readily used in British historical texts than in comparable American texts in reference to the representation of human physical abnormalities.
116. Roy Porter, *Bodies Politic: Disease, Death and Doctors in Britain, 1650–1900* (London: Reaktion Books, 2001).
117. Richard Godfrey, *James Gillray: The Art of Caricature* (London: Tate Publishing, 2001) 169.
118. Godfrey (169) also notes how “Charlotte thrusts her body forward with almost sexual avidity,” a reminder of the association of sexual deviancy and goiter seen in Dutch genre paintings. He points out, too, that Queen Charlotte was “the subject of some of Gillray’s most brutal personal caricatures” (169).
119. Godfrey compares their full craws to “massive breasts culminating in nipple like knots” (169), another example of sexualizing endocrine abnormalities.
- Chapter 3**
120. Wind argues that Ribera’s painting of *The Dwarf and the Dog* (now lost but reproduced in Wind’s book in plate 3.7) “is not meant to elicit thoughts of charity” and that it reflects the “mirth-provoking formula practiced by court artists North and South of the Alps” (63). The portrait of Calabazas is reproduced in Wind’s plate 4.1.
121. Veronique Dasen, *Dwarfs in Ancient Egypt and Greece* (Oxford: Clarendon Press, 1993) 7–8.
122. Dennis Styne, “Growth,” *Greenspan’s Basic and Clinical Endocrinology* (New York, McGraw Hill, 2007), 8th ed. 171.
123. R. L. Rosenfield and L. Cutler, “Somatic Growth and Maturation,” *Endocrinology*, 4th ed. 477–479.
124. S. H. Ingbar, “The Thyroid Gland,” *Williams Textbook of Endocrinology*, 7th ed. 782.
125. Styne 195.
126. Robert Rosenfield and Leona Cutler, “Somatic Growth and Maturation,” *Endocrinology*, 4th ed. 477.
127. N. B. Sutter, C. D. Bustamante, K. Chase et al, “A Single IGF-1 Allele is a Major Determinant of Small Size in Dogs,” *Science* 316 (2007): 115.

128. S. D. Chernausek, P. F. Backeljauw, F. Jetel, "Long-term Treatment with Recombinant Insulin-like Growth Factor (IGF-1) in Children with severe IGF-1 Deficiency due to Growth Insensitivity," *Journal of Clinical Endocrinology and Metabolism* 92.3 (2007): 907.
129. L. L. Levitsky, Editorial: "Defining the Role of IGF-1 Therapy for Short Children," *Journal of Clinical Endocrinology and Metabolism* 92 (2007): 813.
130. M. H. Aguiar-Oliveira, F. T. Oliveira, R. M. C. Pereira et al, "Longevity in Untreated Congenital Growth Hormone Deficiency due to a Homozygous Mutation in the GHRH Receptor Gene," *Journal of Clinical Endocrinology and Metabolism* 95.2 (2010): 716.
131. Armand Marie Leroi, *Mutants* (New York: Viking, 2003) 169–170.
132. Ambroise Paré, *On Monsters and Marvels*, J. C. Pallister trans. (Chicago: Univ. of Chicago Press, 1982) 3. Paré lists "thirteen causes of monsters," including heredity, God's "glory" and "wrath," "the imagination" and "Demons and Devils" (3–4).
133. C. V. Schneider, *De catarrhis*, Wittenberg, 1660–1662 and R. Lower: "Dissertio de origine catarrhi in qua ostenditur illum non provenire a cerebro," in his *Tractatus de corde*, (London edition of 1680) 163–175, as quoted in Fielding Garrison, 268.
134. Michael Bliss, "Harvey Cushing and 'Endo-Criminology,'" *Endocrine News* (August 2007) 35.
135. James P. Allen, *The Art of Medicine in Ancient Egypt* (New York: Metropolitan Museum of Art, Yale University Press, 2005) 24.
136. Dasen also notes that dwarfs were apparently "regarded as persons in the full legal sense, who could marry and inherit civil and religious functions" (157).
137. "Pygmaioi," *Theoi Greek Mythology: Exploring Mythology in Classical Literature and Art*, <http://www.theoi.com/Phylos/Pygmaioi.html>
138. An example of this motif in a Greek vase painting is reproduced in Dasen, plate 67.2 (Lekythos, Paris, Louvre).
139. Dasen also suggests that the "inelegant attribute" of "conspicuous genitals" could reflect the belief that dwarfs had "affinities with satyrs," a notoriously libidinous half man-half goat species in Greek mythology (173).
140. The Pitti Palace museum to which the Boboli Gardens are attached includes other examples of dwarf statuary as well as Bronzino's famous painting of the dwarf Morgante, a character in a fifteenth century Florentine tale by L. Pulci.
141. M. Miles, "Signing in the Seraglio: mutes, dwarfs and jestures [*sic*] at the Ottoman Court 1500–1700," *Disability and Society* 1, (2000): 115–134, Miles claims that "mutes and dwarfs had their own quarter in the seraglio of the 1580's" and continued to be part of the sultan's household for four centuries.
142. *The Accademia Galleries in Venice* ed. Giovanna Nephi Scare (Milan: Electa, 1998) 85. Scare writes, "According to the writing at the base of the pillar bottom left, the work was completed on April 20, 1573, but three months later the artist was accused of heresy for this vast composition which contained what were considered to be excessive anti-conformist elements" (85).
143. Betty M. Adelson, *The Lives of Dwarfs: Their Journey from Public Curiosity toward Social Liberation* (New Brunswick, NJ: Rutgers Univ. Press, 2005) 15.
144. Leslie Fiedler, *Freaks: Myths and Images of the Secret Self* (New York: Simon and Schuster, 1978) 56.
145. Richard Cocke, *Raphael* (London: Chaucer Press, 2004) 95.
146. Wind also notes seventeenth century painter Domenichino's "debt to Raphael's *Repulse of Attila*" and suggests a "turning also to the Raphaelesque Vision of Constantine" in Domenichino's *Meeting of St. Nilus and Otto III* (1610, Italy, Grottaferrata Abbey) (23). We also see parallels between Raphael's *Vision of the True Cross* and Domenichino's *Apollo Killing Two Cyclopes* (1616, London, National Gallery). In both paintings the placement of the dwarf



in the right foreground, as if in the position of a jester on the stage set of a theater, suggests the painter's mockery of the dwarf's role.

147. See note 146 above on Domenichino's two paintings that feature dwarfs.

148. Merke notes, "At that time such a cretinous dwarf could not have been such a great rarity in Lombardy, where goiter and cretinism were so rife" (310), but we do not see evidence of cretinism in the facial features of the figure.

149. Merke also notes that in the Palazzo Ducale at Mantova the Gonzaga family built an "'appartamento dei nani' (apartment of the dwarfs) the architecture and dimensions of which are scaled throughout to the diminutive stature of the inmates: the rooms, stairs, doors, windows and seating accommodation are all adapted to dwarfs" (311).

150. Adelson argues that in this painting, "in a deviation from the norm, one is given a view of dwarfs who act on their own behalf and are not merely peripheral to the lives of others" (151-152). Wind also points out that Molenaer's painting "has defied analysis," citing three contrasting interpretations by Sutton, Haecht and Schama that see the painting as, respectively "not sympathetic to deformity," or as "a comment on immoderate behaviour" or as "a paradigm of malevolence" (110).

151. Wind cites Steen's *The Egg Dance* as an example of the "dwarf fiddler" illustrating "Steen's taxonomic depiction of intemperance" (114).

152. Jonathan Brown, *Painting in Spain* (New Haven, Yale University Press, 1998) 126.

153. Maurizia Tazartes, *Velasquez* (Firenze, Italy: Giunti Gruppo Editoriale, 1996) 27 (our translation).

154. Adelson claims, "traditionally, dwarfs have been portrayed as asexual, and their attentions as unwelcome" (221). She notes, however, that dwarfs in antiquity were more readily associated with libidinousness (111).

155. Wind further argues that the presence of cards in Lezcano's hands is "an appropriate attribute for this foolish clown" 82.

156. Kenneth Clark, from *Looking at Pictures* (<http://www.artchive.com/meninas.htm>)

157. Claustre Rafart i Planas, *Picasso's Las Meninas*, trans. Valerie Collins (Barcelona, Editorial Meteora, 2001) 88. The discussion refers specifically to Figure 45 in *Las Meninas* (Isabel de Velasco and María Bárbola) dated November 8, 1957.

158. James Beswick Whitehead, *Reflections of Rigoletto*, 2001, [www.bjornetjenesten.dk/teksterdk/Rigoletto/reflections\\_of\\_rigoletto.htm](http://www.bjornetjenesten.dk/teksterdk/Rigoletto/reflections_of_rigoletto.htm). Whitehead examines the possible origins of Verdi's notorious gobbo Rigoletto, one of which may have been Bertholde.

159. See Whitehead for a discussion on Callot's pictures of dwarfs.

160. Joseph Boruwlaski, *The Life and Love Letters of a Dwarf: Being the Memoirs of a Celebrated Dwarf, Joseph Boruwlaski, a Polish Gentleman*, trans. E. Freeman, (Birmingham, England: J. Thompson, 1792) 131.

161. C. J. S. Thompson, *The Mystery and Lore of Monsters* (London: Williams and Norgat) 240. Adelson states, however, that the children were eventually identified as "African Americans born in the United States" (26).

162. "A Chapter on Giants and Dwarfs," *Sketch of the Life, Personal Appearance, Character and Manners of Charles S. Stratton*, etc. Robert Bogdan Collection, (New York: Wynkoop and Hallenbeck, 1863) 1, <http://www.disabilitymuseum.org/lib/docs/693.htm>

163. The type and cause of Lautrec's dwarfism has been much debated. According to Leroi, "Lautrec was diagnosed with pycnodysotosis in 1962 by two French physicians, Pierre Maroteaux and Maurice Lamy, but their claim has not gone unchallenged"; pycnodysotosis "is caused by a deficiency in the enzyme that osteoclasts use to dissolve the protein matrix of bones. During adulthood the activity of this enzyme is partially repressed by hormones" (164).

164. Adelson notes, “Empereire was not a curiosity to Cézanne, but a friend whose complexity Cézanne recognized and understood and perhaps identified with” (162). She cites a similar interpretation of Cézanne’s identification with his subject in an article by Michael Gibson in “Cezanne: A Tenuous Triumph” available as article 14934 in *The World and I*, June 1966, 1. <http://www.worldandi.com/archive/arjune.htm> (n. 86, 396).

165. In a *New Left Review* (November–December 1960) article on the Tate Museum’s 1960 exhibit of Picasso’s work, art critic Martin Baillie reminds us that “La Nana, the dwarf dancer, is a clearly defined personality connecting with us through her aggressive attitude, and markedly different from the figures of the blue period” of Picasso’s early work. Martin Baillie, “Early Picasso” (<http://newleftreview.org/?view=100>)

166. Adelson points out that Dr. Josef Mengel’s “infamous laboratory at Auschwitz” included experimentation on dwarfs for the study of heredity (38).

#### Chapter 4

167. “Caroline Crachami,” <http://surgicat.rcseng.ac.uk/%28yk15yojgrn1wmnuqcnj0prig%29/detail.aspx#>

168. Fitzmaurice’s photograph originally appeared on the cover of *Science* 316 (April 6, 2007).

169. See N. B. Sutter et al, “A Single IGF-1 Allele is a Major Determinant of Small Size in Dogs,” *Science* 316 (April 6, 2007): 112.

170. Medvei notes that E. Launois and P. Roy reported that gigantism occurs “before the epiphyses are fused and acromegaly occurs after fusion” (313).

171. Schlomo Melmed, “Acromegaly,” *New England Journal of Medicine* 355 (2006): 2558.

172. E. Seaborg, “Catching Acromegaly Early,” *Endocrine News* (March 2008): 21.

173. R. J. Brown, J. J. Adams, R. Pelekanos, et al “Model for Growth Hormone Receptor Activation Based on Subunit Rotation within a Receptor Dimer,” *Natural Structure of Molecular Biology* 12 (2005): 814–21, quoted in S. Melmed, 2560.

174. Clark Sawin, “Defining Thyroid Hormone: Its Nature and Control,” *Endocrinology: People and Ideas*, ed. S.M. McCann (Bethesda, MD; American Physiological Society, 1988) 179.

175. Rolleston notes that the two names (Byrne and O’Brien) were used interchangeably. He also notes that the giant “Magrath when about 16 years of age and 6 feet 8 and ¾ inches in height was befriended by Bishop George Berkeley (1685–1753), ... and it was widely believed in Ireland that Magrath’s huge frame was the result of the bishop’s experiments in giant-rearing” 84.

176. In *Knife Man* (New York: Broadway Books, 2005) author Wendy Moore writes that “[a]lthough the true cause of Byrne’s extreme height was a mystery to Hunter ... he was certainly aware that the untreated condition generally spelled an early death. Giants had a reputation for short lives, and Byrne, as he freely declared in his advertisements, was already twenty-two” when Hunter began to follow him (207). “But death itself was no longer his greatest fear. The Irish giant’s worst dread was the anatomists, and especially the best-known anatomist of them all: John Hunter” (208).

177. Mark Morford and Robert Lenardon, *Classical Mythology*, 4th ed (New York: Longman, 1991) 61.

178. Poseidon and the Gigante Polybotes,” *Theoi Greek Mythology: Exploring Greek Mythology in Classical Literature and Art*, <http://www.theoi.com/Gallery/K2.6.html>

179. For a comparison, see “Gigantes,” <http://www.theoi.com/Gigante/Gigantes.html>

180. Polyphemus,” *Theoi Greek Mythology: Exploring Greek Mythology in Classical Literature and Art*, <http://www.theoi.com/Gigante/GigantePolyphemus.html>
181. Homer, *The Odyssey*, trans. Robert Fagles (New York: Penguin, 1997) 9, ll.211–14.
182. Jon Bondeson, *A Cabinet of Medical Curiosities* (Ithaca: Cornell Univ. Press, 1997) notes the belief “that the human race had steadily decreased in size and that before the Flood people had been at least fifty feet tall. The church was instrumental in spreading the doctrine of the antediluvian giants, which had support from the Old Testament,” even going so far as hanging “the giants’ bones in the churches for the inspection of all and sundry” (73).
183. Caravaggio’s earlier paintings of the story include *David* (Madrid, Museo del Prado) and *David with the Head of Goliath* (Vienna, Kunsthistorisches Museum). In both paintings the features of the giant are less exaggerated than those in the Borghese painting.
184. Puglisi notes that the markings on the sword held by David “have lately been interpreted ingeniously, if not conclusively, as deriving from an Augustinian commentary on the Psalms which equates David’s triumph over Goliath with Christ’s over Satan and, symbolically, with humility over pride” (360).
185. Puglisi speculates that “he perhaps studied his own features in the mirror—maybe the very same convex one that appears as a prop in *The Conversion of Mary Magdalen*,” (109) and “he more than likely used his own features for an intense scrutiny of extreme facial expression with bulging eyes and screaming mouth” (363).
186. See **Chapter 5** for a more complete discussion of Addison’s disease.
187. Jay Scott Morgan, “The Mystery of Goya’s Saturn,” *New England Review* (2003) <http://community.middlebury.edu/~nereview/22-3/morgan.html>
188. Robert Hughes, *Goya* (New York, Knopf, 2002) 383.
189. Hughes also notes that according to art historian Nigel Glendinning “cited in Manuela Mena Marques, ‘The Colossus,’ catalog #69 in *Goya and the Spirit of Enlightenment*” the image of the giant “illustrates a prophetic poem by the Basque writer Juan Bautista Arriaza, *La Profecía de los Pirineos* (*The Prophecy of the Pyrenees*), (1808), which envisions a guardian spirit rising from the mountains to crush Napoleon” (287 and n. 14, 407). In this sense, The Colossus might serve as a more positive symbol of the will of the Spanish people to fight back.
190. *Uffizi Florence* (New York and Milan, Italy: Newsweek: Great Museums of the World and Mondadori Editore, 1979) 56.
191. In a rare fresco that has been partially cut off, Piero della Francesca’s *Hercules* (ca. 1467, Boston, Isabella Gardner Museum) draws attention to strong limbs, a slightly bowed right leg and massive hands, the latter suggestive of acromegaly. The bone structure and size of Hercules’s head, however, do not reveal the characteristics of acromegaly. This head is so similar to male heads in other works by the painter that one might deduce that Piero simply exaggerated the body size in order to illustrate the abnormality of gigantism. Hillard Goldfarb in his *Isabella Stewart Gardner Museum: A Companion Guide and History* (New Haven: Yale Univ. Press, 1995) suggests that the work reflects “Piero’s ... study of classical proportions and perspective” (51); thus the exaggerated size of the giant challenges traditional theories of the “golden mean” in human proportions.
192. *New Larousse Encyclopedia of Mythology*, trans. R. Aldington and D. Ames (London; Hamlyn, 1974) 95.
193. Max Friedlander in *Early Netherlandish Painting: From Van Eyck to Brueghel* (New York: Phaidon Publishers, 1956) discusses the uneven skill with which Bouts represented human anatomy, an observation that may explain why the giant’s legs seem disconnected from his body and why the viewer’s eye is drawn to the giant’s head rather than the limbs: “Dieric’s talent was not sufficiently robust and comprehensive to create out of his own resources an outstandingly impressive group, to make a

movement flow through every limb of a body; but his devout and careful method of working could successfully fashion and animate a head or a hand” (31). As in the Goliath paintings discussed above, the head of the giant seems the most important feature in the work.

194. See “The Renaissance,” <http://academic.brooklyn.cuny.edu/english/melani/cs6/ren.html> for a full explanation of the concept of the *Great Chain of Being in the Renaissance*, highlighted as follows:

Among the most important of the continuities with the Classical period was the concept of the *Great Chain of Being*. Its major premise was that every existing thing in the universe had its “place” in a divinely planned hierarchical order, which was pictured as a chain vertically extended. (“Hierarchical” refers to an order based on a series of higher and lower, strictly ranked gradations.) An object’s “place” depended on the relative proportion of “spirit” and “matter” it contained—the less “spirit” and the more “matter,” the lower down it stood. At the bottom, for example, stood various types of inanimate objects, such as metals, stones, and the four elements (earth, water, air, fire). Higher up were various members of the vegetative class, like trees and flowers. Then came animals; then humans; and then angels. At the very top was God. Then within each of these large groups, there were other hierarchies. For example, among metals,

gold was the noblest and stood highest; lead had less “spirit” and more matter and so stood lower. (Alchemy was based on the belief that lead could be changed to gold through an infusion of “spirit.”) The various species of plants, animals, humans, and angels were similarly ranked from low to high within their respective segments. Finally, it was believed that between the segments themselves, there was continuity (shellfish were lowest among animals and shaded into the vegetative class, for example, because without locomotion, they most resembled plants).

195. Charles Byrne, *Brought to Life: Exploring the History of Medicine*, <http://www.sciencemuseum.org.uk/broughttolife/people/charlesbyrne.aspx>

196. Fiona Haslam. *From Hogarth to Rowlandson: Medicine in Art in Eighteenth-Century Britain* (Liverpool, England: Liverpool University Press) 285.

197. “Serusier,” *Olga’s Gallery* <http://www.abcgallery.com/S.serusier/serusierbio.html>

198. Anthony Read and David Fischer, *Berlin Rising* (New York: W. W. Norton and Co., 1994) 37.

## Chapter 5

199. “An Excess of Seed” in our chapter title refers to Paré’s theory that hermaphroditism occurs when the female partner produces as much “seed” as the male partner (Paré 26). See p. 160 in Chapter 5 of our book.

200. Museum object label for *Amore and Psyche*, Palazzo Altemps, Rome.

201. See **Figure 5-8** and the second part of this chapter for a full discussion of this painting.

202. See Lorraine Daston and Katherine Park, *Wonders and the Order of Nature, 1150–1750* (New York: Zone Books, 2001). Daston and Park note that among the “three kinds of monsters” were “those produced by the mother’s imagination (for example, hairy children)” (192).

203. *Stedman’s Medical Dictionary* (Baltimore, Williams and Wilkins Co, 1961) 700.

204. Today, these conditions are generally referred to as disorders of sexual development, a term that is thought to have less disparaging associations than specific terms in earlier usage such as those listed above. In our reference to art that depicts such disorders, however, we use the term hermaphroditism to reflect accurately the historical context of the works discussed here.

205. J. H. Kiefer, "The Hermaphrodite as Depicted in Art and Medical Illustration," *Trans American Association Genito-Urinary Surgeons* 58 (1966): 121.
206. F. Guirand, "The Mythology of Classical Greece," *New Larousse Encyclopedia of Mythology* (London: Hamlyn Publishing, 1974) 132.
207. Kathleen Long, *Hermaphrodites in Renaissance Europe* (Burlington, VT: Ashgate Press, 2006) 11. Long also notes the argument of Marie Delcourt in *Hermaphrodite: Mythes et rites de la bisexualité dan l'antiquité classique* "that in pre-historic cults, the hermaphrodite was a figure of divine power, of fertility and procreation, of the union of mother and child" (11). Long suggests, however, that the comic representation of hermaphrodites by the 4th century BCE Greek playwright Aristophanes is "ambiguous at best" (11) and that Renaissance philosophers such as Leone Ebreo (16th century) combine the idea of "the spiritual androgyne with the monstrous hermaphrodite," 9.
208. Kiefer's reference to the hypospadiac penis, that is, the end of the urethra at the base rather than at the end of the penis, suggests that the sculptor of the Hermaphrodite of Mirecourt most likely worked from direct observation because hypospadias is a relatively common congenital abnormality (121).
209. Daston and Park note that Riolan "scoffed at Columbo "for mistaking an enlarged clitoris for a penis" and "castigated even more severely the provincial physician Jacques Duval in Duval's defense "of the Rouen hermaphrodite Marie/Marin le Marcis" (203). Later in this chapter we discuss Duval's defense in more detail.
210. In modern usage, the word virago, derived from the Latin *viragine*, refers to a "bold, impudent woman" (OED), but in sixteenth century England the word had a more sexually pointed definition, referring to a "man-like, vigorous, and heroic woman"(OED). The term continues to have a negative connotation, suggesting that qualities considered traditionally male are never regarded as attractive in a woman.
211. Medvei 238, n. 115. Medvei quotes Ambroise Paré's *Les causes pourquoi le flux menstrual est retenu aux femmes, Vingt-troisième livre*, Chapter LX.
212. We have summarized here depictions of Marin/Marie Lemarcis and Jeanne Lefebvre recorded in sixteen statements included in "La Storia dell'ermafrodito di Rouen: Dossier medico-legale del 1601" in *Jacques Duval, L'Ermafrodito di Rouen, una Storia Medico-legale del XVII Secolo*, ed. Valerio Marchetti (Venice, Marsilio Editori, 1988) 69–103.
213. "Thomistic thought" refers to the followers of St. Thomas of Aquinas, who "drew a clear distinction between Faith and Reason and was considerably influenced by the philosophy of Aristotle" (*Brewer's Dictionary of Phrase and Fable* 1111).
214. Wendy Moore 204, quoted in Orlo H. Clark, "The Influence of Endocrine Surgery on General Surgery and Surgical Science," presidential address delivered at the Pacific Coast Surgical Association, February 14, 2009 in San Francisco, Archives of Surgery 144 (2009): 802.
215. In many ways it is surprising that Hunter's transplantation experiments were successful because in most situations transplants from one animal to another would be rejected without effective immunosuppressive therapy.
216. It wasn't until 1911 that Tandler and Keller explained that freemartins occur only when the female twin shares a common placental circulation with her male sibling. The changes that occur are caused by the exposure of the female twin to testosterone despite the absence of a Y-chromosome and anti-mullerian hormone (Medvei 200).
217. Roy Porter, *The Greatest Benefit to Mankind* (New York: Norton, 1997) 563.
218. A. Boualem, M. Fergang, R. Fernandez et al, "A Conserved Mutation in an Ethylene Biosynthesis Enzyme Leads to Andromonoecy in Melons," *Science* (2008) 321 (2008) 321: 836.

219. J. S. Miller and P. K. Diggle, "Diversification of Andromonoecy in Solanum Section Lasiocarpa (Solanaceae): The Roles of Phenotypic Plasticity and Architecture," *American Journal of Botany* (2003) 90: 707.
220. Felix Conte and Mel Grumbach "Disorders of Sexual Discrimination and Differentiation," *Greenspan's Basic and Clinical Endocrinology*, 8th ed. 568.
221. C. A. Quigley, "Genetic Basis of Sex Determination and Sex Differentiation," *Endocrinology*, 4th ed. 1931.
222. L. E. Underwood and J. J. Van Wyk, "Normal and Aberrant Growth," *Williams Textbook of Endocrinology*, 7th ed. 155.
223. A. G. Frantz, J. D. Wilson, and D. W. Foster "Endocrine Disorders of the Breast," *Williams Textbook of Endocrinology*, 7th ed. 415.
224. Glen Bronstein, "Gynecomastia," *New England Journal of Medicine* 357 (2007): 1229.
225. M. P. Rosen and M. I. Cedars, "Female Reproductive Endocrinology and Infertility," *Greenspan's Basic and Clinical Endocrinology*, 8th ed., 529.
226. D. H. Nelson, "Pituitary-Adrenal System," *Endocrinology: People and Ideas* 87.
227. R. L. Zwemer, "An Experimental Study of the Adrenal Cortex: The Survival Value," *American Journal of Physiology* 79 (1927): 656.
228. Geeta Lal and Orlo Clark, "Endocrine Surgery," *Greenspan's Basic and Clinical Endocrinology*, 8th ed. 924.
229. D. G. Gardner, "Multiple Endocrine Neoplasia," *Greenspan's Basic and Clinical Endocrinology*, 8th ed. 835.
230. B. M. Branchhof and O. Grim, "Extrathyroidal Manifestations of Multiple Endocrine Neoplasia Type 2," *Thyroid* 19 (2009): 555.
231. Orlo H. Clark, "'Asymptomatic' Primary Hyperparathyroidism: Is Parathyroidectomy Indicated?" *Surgery* 116 (1994): 943-956.
232. R. Udelsman, J. Pasiaka, C. Sturgeon et al, "Surgery for Asymptomatic Primary Hyperparathyroidism: Proceedings of the Third International Workshop," *Journal of Clinical Endocrinology and Medicine* 94.2 (Feb.2009): 368.
233. A common jingle familiar to endocrinologists and endocrine surgeons. See the following articles for a more detailed discussion of the symptoms of hyperparathyroidism summarized in the jingle: M. S. Egelberger et al, "The NIH Criteria for Parathyroidectomy in Asymptomatic Primary Hyperparathyroidism: Are they too limited?" *Annals of Surgery* 239.2 (2004): 1-8; J. L. Pasiaka and L. C. Parsons, "Prospective Surgical outcome study of relief of symptoms following surgery in patients with primary hyperparathyroidism," *World Journal of Surgery* 22 (1998): 513-528.
234. J. D. Bilezikian, J. T. Potts, Summary Statement from a workshop on Asymptomatic Primary Hyperparathyroidism, A Perspective for the 21st Century, *Journal of Clinical Endocrinology and Metabolism* 87.12 (2003): 5353.
235. S. H. Huang, "Familial Hyperparathyroidism," *Textbook of Endocrine Surgery*, 2nd ed.
236. S. M. Coleco, M. Si, E. Reiff, O. H. Clark, "Hyperparathyroidism after Radioactive Iodine Therapy," *American Journal of Surgery* 194.3 (2007): 326.
237. R. Fazel et al, "Exposure to Low Dose Imaging Radiation from Medical Imaging Procedures," *New England Journal of Medicine* 361 (2009): 849.
238. "Sir John Mandeville," Novelguide.com, [http://www.novelguide.com/a/discover/ewb\\_10/ewb\\_10\\_04161.html](http://www.novelguide.com/a/discover/ewb_10/ewb_10_04161.html)
239. Sir John Mandeville, 1300-1399, *The Travels of Sir John Mandeville* (Memphis, TN: General Books, 2010) 77.
240. Catherine Johns, *Sex or Symbol: Erotic Images of Greece and Rome* (London: British Museum Press, 1989) 105.
241. Ovid, *The Metamorphoses, Book IV*, trans. Horace Gregory (New York, Viking, 2001) 122.

242. Maryan W. Ainsworth with Lorne Campbell, "Mythological Themes," *Man, Myth, and Sensual Pleasures: Jan Gossart's Renaissance, The Complete Works*, ed. Maryan W. Ainsworth, Stijn Alsteens, and Nadine M. Orenstein, (New York: Metropolitan Museum of Art and Yale University Press, 2010) 224.
243. Edward Lucie-Smith, *Sexuality in Western Art* (London: Thames and Hudson, 1991) 25.
244. **Figure 5-4** is also reproduced as Paré's **Figure 19**, "Picture of a hermaphrodite man-and-woman" in *Of Monsters and Marvels* (28).
245. Laurinda Dixon, *Bosch* (London: Phaidon Press, 2006) 251.
246. J. Stalabrass refers to "Geoffrey Hinton's reading of this work in the light of Freud's Schreber case, where the sun stands for God and the father, the moon for the mother, where the sun's rays are attached to the body, and where Schreber saw himself as a hermaphrodite" (54).
247. See note above for a discussion on gender theory and the role of the female addressed in both Ernst paintings (54 and 98).
248. See **Chapter 2** for a full discussion of this painting. The presence of an enlarged goiter in the naked female figure further adumbrates evidence of her female characteristics, whereas the bright feathers suggesting male plumage and the large, almost masculine, hand covering the pubic area of the robed figure may imply that the figure is covering male genitalia. Furthermore, the presence of a mask-like face over the robed figure's breasts suggests the features of an old man.
249. Leroi documents that the Hapsburgs and the Farneses "could not get enough of" the "hairy" Gonsalvus clan. He also notes the portrait of Arrigo's sister Tognina, which "shows the little hairy girl dressed in silvery brocades, smiling sweetly as she holds a document recounting her history aloft" (271-272).
250. In his discussion of the painting, Leroi also notes that Arrigo wears a "tamarco," a cloak that alludes to the "Guanches, who once inhabited Tenerife in the Canary Islands but who had been briskly subjugated and largely exterminated by the Spanish a hundred years before" (270-271). These details further suggest that the Gonsalvus family members were kept almost as "pets" as well as curiosities in the court.
251. Cocke notes that the implied comparison between the Pope's Borgo apartment and the Trojan palace is used to "ennoble the Borgo" by suggesting the lineage from Aeneas, the mythical founder of Rome, to the papacy (88).
252. Roy Porter, *Bodies Politic*, 234.
253. *English Caricature: 1620 to the Present* (London: Victoria and Albert Museum, 1984) 89.
254. *Art Encyclopedia: James Gillray*, Answers.com, <http://www.answers.com/topic/james-gillray>

---

**GLOSSARY OF MEDICAL TERMS**


---

**Achondroplastic dwarfism:** A congenital disorder of bone formation that results in deformities of the skeleton with small stature. (NWD)

**Acidosis:** “A condition in which the body’s alkali reserve is below normal, because of faulty metabolism.” (NWD)

**Acromegaly:** A growth disorder characterized by progressive enlargement of the head and jaw, feet and thorax due to increased levels of growth hormone in the adult. (s 39)

**ACTH (Adrenocorticotrophic hormone):** A pituitary hormone that stimulates cortisol secretion and growth of the adrenal cortex.

**Addison’s disease:** A disease caused by cortisol deficiency with symptoms of weakness, fatigue, nausea, hypotension (low blood pressure) and classic yellowish skin pigmentation, and darkening of the palmar (hand) creases with hyponatremia, (low blood sodium), hyperkalemia, (high blood potassium) and acidosis.

**Adenoma:** A non cancerous or benign growth.

**Allele:** “Any of a group of possible mutational forms of a gene.” (AHD)

**Androgyny:** Existence of characteristics of both sexes in one person. The tendency to be “neither distinguishably masculine nor feminine, as in dress, appearance or behavior.” (AHD 108)

**Androdiocy:** A “sexual system in which males co-occur with hermaphrodites, which have both male and female function.” *Science* 327 (2010): 1648–1650, 2

**Androgen:** male sex hormone.

**Andromonoecy:** A “sexual system in which plants produce both hermaphroditic and female-sterile ... staminate flowers.... Andromonoecy is often considered a form of phenotypic plasticity.” *American Journal of Botany* 90 (2003). 5 707–715

**Androstenedione:** A precursor hormone involved in the synthesis of testosterone and secreted by the testis. (Williams 265)

**Angioma:** a benign vascular tumor.

**Aneurysmatic:** Relating to a dilated artery.

**Benign:** Describing the mild character of an illness or the non malignant character of a neoplasm or tumor. (S200)

**Bronchial cleft cyst:** A congenital, benign, usually cystic lateral neck mass.

**Bronchiocele:** “A circumscribed dilatation of a bronchus.” (S233)

**CAH:** Congenital Adrenal Hyperplasia. This condition is “responsible for most cases of female pseudo-hermaphroditism and about 50% of all causes of ambiguous genitalia. There are six major types of CAH all transmitted as autosomal (a non sex chromosome) recessive disorders.” (Greenspan 584)

**Cabergoline:** A dopamine agonist (stimulant) that normalizes IGF-I levels in about 30% of patients with acromegaly. It is usually used with somatostatin analogue therapy for better results. (Greenspan 150)

**Cardiomyopathy:** Weakness of the muscle of the heart.

**Carpal tunnel syndrome:** Numbness and weakness of the hand caused by entrapment of the median nerve at the wrist.

**Catecholamines:** Hormones secreted by the adrenal medulla, such as norepinephrine and dopamine, that affect blood pressure and are termed the “fright, flight and fight hormones.”

**Chromosomal:** “A rod-shaped or threadlike body of chromatin in the cell nucleus, which splits longitudinally as the cell divides, one half going to the nucleus of each of the daughter cells.” (S318)

**Cortisol (hydrocortisone):** “A hormone of the adrenal cortex ... active in carbohydrate metabolism.” (AHD 328)

**Cushing’s disease:** Pituitary secretion of ACTH, causing increased adrenal secretion of cortisol.

**Cushing’s syndrome:** A syndrome associated with increased cortisol levels. The increased cortisol is the result of one or more of the following: **a** increased secretion of ACTH by a pituitary tumor (Cushing’s disease); **b** ectopic secretion of ACTH by neuroendocrine tumors (ectopic Cushing’s);



increased cortisol secretion from benign or adrenal cortisol tumors. The syndrome is characterized by obesity with central fat distribution, moon and reddened facies, buffalo hump, hirsutism, supra clavicle fat pad enlargement, purple abdominal striae, weakness, psychological disturbances, gonadal dysfunction, and glucose intolerance.

**DSD:** Disorders of sexual development.

**Diabetes mellitus:** “Clinical diabetes mellitus is a syndrome of disordered glucose metabolism with inappropriate hyperglycemia due either to an absolute deficiency of insulin secretion or a reduction in the biological effectiveness of insulin (or both).” (Greenspan 672)

**Dopamine:** “An important neurotransmitter and a precursor of norepinephrine (a hormone found in the adrenal medulla and in adrenergic nerves).” (Greenspan 432).

**Dopamine agonists:** Agents, such as levodopa, apomorphine, and bromocriptine that increase growth hormone secretion, whereas dopamine antagonists such as phenothiazines inhibit growth hormone secretion. (Greenspan 118)

**Dysphasia:** Difficulty swallowing.

**Dyshormonogenesis:** Abnormal biosynthesis of thyroid hormone.

**Elephant man syndrome:** Neurofibromatosis type 1, also called Von Recklinghausen’s disease; an autosomal dominant (non-sex related) inherited disorder. Individuals with the syndrome have subcutaneous neurofibromas (nerve tumors), café au lait spots, freckles in the axilla, and adrenal medullary tumors (pheochromocytomas). The abnormal gene is located on Chromosome 17.

**Endemic goiter:** The presence of an enlarged thyroid gland prevalent in certain regions and usually due to iodine deficiency. (s 654 and Greenspan 658)

**Epiphysis:** The growth plate for the growth of long bones.

**Estrogen:** “The generic term suggested for all substances which produce estrus whether derived from the ovary or not. Estrogen also produces growth of female secondary sexual characteristics...” (s 543)

**Ethmoid:** “Resembling a sieve; cribriform [perforated with holes] ... relating to the ethmoid bone.” (s 545)

**Exophthalmos:** Bilateral or unilateral protrusion of the eyeballs often associated with Graves’ disease.

**Familial:** Common to a family. (NWD 505)

**Freemartin:** “A masculinized, female twin calf, caused by the twin fetuses being of opposite sexes. The chorions [vascular network] become fused at a very early stage of

embryonic development with the result that the sex hormone of the male is conveyed in the circulation to the female twin and influences its sexual development.” (s 614)

**Ganglioneuroma:** “A benign neoplasm composed of mature ganglionic neurons, in varying numbers, scattered singly or in clumps within a relatively abundant and dense stroma of neurofibrils and collagenous fibers.” (s 627)

**Genital hypoplasia:** Decreased or arrested growth of the external genitalia. (NWD 692)

**Glucocorticoids:** “Any principle in the adrenal cortex that affects the metabolism of glucose.” (s 649)

**Goiter:** An enlargement of the thyroid gland, which may be diffuse, nodular and hypo or hyperfunctioning. (s 654)

**Goitrogen:** Any substance that stimulates thyroid growth. (s 654)

**Gonadotrophic stimulating hormone:** Pituitary hormones including luteinizing hormone (LH) and follicle-stimulating hormone (FSH) that stimulate the breast and gonads.

**Gonad:** A sex gland, the ovary in females and testicle in man.

**Gonadotrophic hormone:**

A hormone from the hypothalamus that stimulates the gonadotrophs in the pituitary gland. The gonadotrophs are pituitary cells that secrete luteinizing hormone and follicle-stimulating hormone that regulate gonadal function and the secretion of sex hormones. (Greenspan 122)

**Gout:** A metabolic disorder due to deposition of sodium urate crystals in the joint spaces characterized by recurrent episodes of acute pain usually in the great toe but can occur at any joint. (S657)

**Graves' disease:** An autoimmune disease associated with hyperthyroidism and often exophthalmic goiter described by the Irish physician Robert Graves in 1835.

**Ghrelin:** Ghrelin is a gastrointestinal peptide that is an endogenous ligand or hormone for the GH receptor. "Ghrelin increases appetite, body weight, and GH secretion in both animals and humans, suggesting that it has an important role in energy homeostasis." Low IGF-I levels are associated with increased ghrelin levels. (A Uckum-Kitapei, A. Haqq, J. Purnell, et al, "Serum Ghrelin Concentrations are increased in Children With Growth Hormone Insensitivity and Decrease During Long-Term Insulinlike Growth Factor-I Treatment." *Journal of Investigative Medicine* 56 (2008) 1: 26-31

**Growth hormone receptor:** A binding site for growth hormone which is linked to IGF-I and IGF-II.

**Growth hormone:** A pituitary hormone required for normal growth. Insufficient GH results in short stature. Excess growth hormone results in acromegaly in adults and gigantism in children.

**Gynecomastia:** "Excessive development of the male mammary glands, sometimes secreting milk." It is usually asymptomatic and may be unilateral or bilateral. (S668)

**Hashimoto's thyroiditis:** An autoimmune disease of the thyroid also called chronic lymphocytic thyroiditis, which may result in a goiter and is the most common cause of hypothyroidism in the United States. (Greenspan 264)

**Hereditary:** "The transmission of characteristics from parent to offspring by means of genes in the chromosomes." (NWD)

**Hirsutism:** "Heavy growth of hair, often in abnormal distribution." (AH)

**Hermaphrodite:** "Androgyne; a person whose genital organs have the characters of both male and female in greater or less degree." (S700)

**Homunculus:** "A little man; dwarf; manikin." (NWD)

**Hyperglycemia:** A condition of elevated blood sugar.

**Hyperparathyroidism:** A disorder caused by the increased secretion of parathyroid hormone by one or more parathyroid glands sometimes causing "painful bones, kidney stones,

abdominal groans, psychic moans and fatigue overtones" usually associated with hypercalcemia (excessive blood calcium).

**Hyperplasia:** An increased number of cells.

**Hyperthyroidism:** A condition caused by inappropriately high circulating thyroid hormone levels.

**Hypoglycemia:** The condition of having low blood sugar.

**Hypopituitarism:** Decreased function of the anterior pituitary gland. (S744)

**Hypophysectomy:** Removal of the pituitary gland

**Hypospadias:** A developmental abnormality in which the urethra opens proximal to the end of the penis in males and in the vagina in females.

**Hypothalamus:** A part of the brain that forms the floor of the third ventricle. It regulates many body functions such as temperature. (NWD)

**Hypoparathyroidism:** A condition of too little parathyroid hormone, resulting in low blood calcium and increased phosphorus levels.

**Hypothyroidism:** A condition caused by inadequate amounts of thyroid hormone.

**Idiopathic:** Referring to a disease for which the cause is unknown

**Infundibulum:** The funnel shaped stalk of the brain (S770)

**Insulin-like growth factor 1 (IGF-1):** A substance that belongs to a family of polypeptides and stimulates cartilage DNA synthesis. “The major hormonal determinant of plasma IGF-I concentration is growth hormone.” (*Endocrinology*, 445)

**Intracranial:** Within the skull.

**Kyphosis:** An abnormal curvature of the spine with hump-back.

**Laron’s dwarfism:** The condition of small persons with growth hormone insensitivity with elevated GH levels due to absent or decreased IGF-I and lack of negative feedback inhibition. (*Greenspan* 195)

**Leydig cells:** Cells in the testes that secrete testosterone.

**Lipids:** Compounds such as fat that are insoluble in water. (S869)

**Lipoma:** A benign fatty tumor.

**Lymphadenopathy:** “Any disease process affecting a lymph node or lymph nodes.” (S885)

**Luteinizing hormone:** Secreted by the basophilic cells in the pituitary that regulate gonadal function. (*Williams* 262–263)

**Malignancy:** A cancer or sarcoma with uncontrollable growth and dissemination. (S896)

**Marfan’s syndrome:** A non-sexually related dominant abnormality of connective tissue caused by a mutation on chromosome 15, resulting in tall stature, long fingers, hyperextension of joints with other vascular abnormalities. (*Greenspan* 206)

**Medullary thyroid cancer:** Malignant tumors that originate from the parafollicular or calcitonin producing cells (C cells) of the thyroid gland.

**Melanocyte stimulating hormone:** A pituitary hormone mediated by hypothalamic factors and inhibited by melanocyte inhibiting factor. (*Williams* 518)

**MENIN gene:** This tumor suppressor gene on Chromosome 11 is responsible for MEN-I syndrome “Almost 300 independent mutations have been described in MEN-I kindreds to date.” (*Greenspan* 833)

**Mesomorphic:** Characterized by a muscular body habitus.

**Millet:** A small grain used for food in Europe and Asia that can be a goitrogen causing thyroid enlargement. (NWD 902)

**Mongolism:** “A congenital disease characterized by mental deficiency, a broad face, slanting eyes, a short fifth finger, etc.: the preferred term is now Down’s syndrome.” (NWD 919)

**Multiple Endocrine Neoplasia Type I:** Also known as Wermer’s syndrome is an autosomal dominant

disorder on Chromosome 11. Clinical abnormalities in families with MEN-I include: hyperparathyroidism, pancreatic neuroendocrine tumors, pituitary tumors, lipomas, angiomas and adrenal tumors.

**Multiple Endocrine Neoplasia Type II:** MEN-II is an autosomal (a non sexual chromosome) disorder due to a RET mutation on Chromosome 10. Family members with MEN-II-A have medullary thyroid carcinoma, pheochromocytomas, hyperparathyroidism, and lichen planus amyloidosis (thickened skin over the scapula). Individuals with MEN-II-B have medullary thyroid cancer, pheochromocytomas, a marfanoid habitus with multiple ganglioneuromas.

**Mullerian ducts:** Ducts that develop from mesodermal epithelium on the surface of urogenital folds and eventually become the oviducts, the uterus and the vagina. (W. Bloom and D. W. Fawcett, *The Textbook of Histology* (Philadelphia: Saunders, 1962) 621)

**Myxedematous cretinism:** Congenital hypothyroidism due to congenital thyroid hormone deficiency or lack of thyroid hormone in early childhood. It causes growth failure and mental retardation resulting in dwarfed idiots. (S372)

**Nasopharynx:** Also termed the rhinopharynx, it is the upper portion of the pharynx above the palate. (S1303)

**Neoplasm:** Any new growth of cells or tissues. The neoplasm can be benign or malignant.

**Neurofibroma:** A firm tumor originating in a nerve.

**Neurofibromatosis:** Also called von Recklinghausen disease, it is an inheritable disease characterized by individuals having several to numerous neurofibromas. (S1023)

**Noonan's syndrome (male Turner's syndrome):** These individuals are short with a webbed neck, hypertelorism and other deformities. Patients are genotypic and phenotypic males and have many of the clinical features of Turner's syndrome (characterized by short stature, sexual infantilism, amenorrhea, webbed neck, ovarian dysgenesis and other abnormalities with the absence of one x chromosome). (*Greenspan* 525)

**Organotherapy:** "The treatment of disease with extracts of animal organs, as of the glands of internal secretion." (NWD 1002)

**Oogenesis:** Production of eggs

**Osteitis fibrosis cystica:** High turnover bone disease associated with primary (rarely) and secondary hyperparathyroidism with skeletal abnormalities and brown tumors of bone. (*Greenspan* 302)

**Ovotesticular:** Referring to true hermaphrodites with both ovarian and testicular tissue in one or both gonads (*Greenspan* 583)

**Papillary:** Having small nipple like projections. Papillary thyroid cancer is the most common type of thyroid cancer.

**Parathyroid:** An endocrine gland adjacent to the thyroid that is important for the regulation of the blood calcium level.

**Pegvisomant:** A growth hormone receptor antagonist that when injected subcutaneously in patients with acromegaly reduces IGF-I levels to normal in about 90% of patients. It is new and expensive and is usually prescribed when surgery and somatostatin analogues have failed. (*Greenspan* 150)

**Pheochromocytoma:** Benign and malignant tumors arising from the medullary cells of the adrenal glands that secrete catecholamines usually causing hypertension and increased perspiration.

**Pre tibial myxedema:** Thickening of the skin usually on lower anterior leg (pre tibial), a dermopathy associated with Graves' disease. (*Greenspan* 250)

**Pseudogout:** A metabolic disorder similar to gout but caused by the deposition of calcium pyrophosphate crystals in the joint spaces.

**Pygmies:** Small persons with low IGF-I and normal growth hormone and IGF-II levels.

**Pyramidal lobe:** A midline protrusion of thyroid tissue extending towards the upper neck usually through the notch in the thyroid cartilage.

**Ret oncogene:** Specific proto-oncogenes found on chromosome 10, causing medullary thyroid cancer. (*Greenspan* 297)

**Scrofula:** "Tuberculosis of the lymphatic glands." (NWD)

**Single-nucleotide polymorphism haplotype (SNP):** "Single-nucleotide polymorphism (SNP, pronounced snip) is a DNA sequence variation occurring when a single nucleotide—A, T, C, or G—in the genome (or other shared sequence) differs between members of a species or paired chromosomes in an individual. For example, two sequenced DNA fragments from different individuals, AAGCCTA to AAGCTTA, contain a difference in a single nucleotide. In this case we say that there are two alleles: C and T. Almost all common SNPs have only two alleles." ([http://en.wikipedia.org/wiki/Single-nucleotide\\_polymorphism](http://en.wikipedia.org/wiki/Single-nucleotide_polymorphism))

**Somatostatin analogues:** Hormones that inhibit insulin release and its synthetic analogue octreotide are used to treat patients with hyperinsulinism.

**Somatostatin:** A hypothalamic hormone that inhibits the pituitary secretion of GH and TSH. Somatostatin cells are also present in the pancreas and gastrointestinal mucosa.

**Somatotrophic cells:** These are acidophilic GH-secreting cells situated laterally in the anterior pituitary. (Greenspan 105)

**Spermatogenesis:** Production of sperm in males.

**Sternocleidomastoid muscle:** A muscle in the neck that originates by two heads from the anterior surface of the manubrium (sternum) and sternal head of the clavicle and inserts on the mastoid process and outer half of the superior nuchal line of the occipital bone. It functions to turn and lower the head downward. (S982).

**Struma:** From the Latin meaning a swollen neck caused by tuberculous adenitis or scrofula or goiter. Formerly any distinct swelling in the neck. (S1431)

**Testosterone:** male hormone.

**Thiocyanate:** An antithyroid compound that causes hypothyroidism and goiter. (S 1528)

**Thyroid stimulating hormone:** A pituitary hormone that stimulates the secretion of thyroid hormone and growth of the thyroid gland.

**Thyroid storm:** “An acute exacerbation of all of the symptoms and signs of thyrotoxicosis, often presenting as a syndrome that may be of life-threatening severity.” It usually occurs in patients with Graves’ disease. (Greenspan 252–253)

**Trachea:** The windpipe that transmits air from mouth to lungs.

**Tumor:** A swelling in the body that may be benign or malignant.

**Turner’s syndrome:** See Noonan’s syndrome above.

**Undescended testicle:** Failure of the testicle or gonad to descend into the scrotum.

**Virilism:** “The presence of male secondary sexual characteristics: hypertrichosis [excessive body hair], small breasts, broad shoulders, etc. in a woman” (S 1643)

---

## Abbreviated References

---

**S=** *Stedman’s Medical Dictionary*, 20th ed.

**NWD** = *Webster’s New World Dictionary*, 2nd ed.

**AMH** = *American Heritage Dictionary*, 2nd ed.

**Greenspan** = *Greenspan’s Basic and Clinical Endocrinology*, ed. Gardner and Shoback, 8th ed.

**Endocrinology** = *Endocrinology*, ed. De Groot and Jamison, 4th ed.

**Williams** = *Williams Textbook of Endocrinology*, ed. Wilson and Foster, 4th ed.

---

**Index**


---

- A Daydream* (Rossetti), 11
- Abul Kasim  
First thyroid operation, 67
- acromegaly. *See* gigantism
- Adam and Eve* (Holbein), 13
- Addison, Thomas, 157
- Addison's disease, 5, 6, 134, 157, 169, 172
- Adonis, 7
- adrenal function, 5
- Albertinelli, Mariotto, 34  
*Creation and Fall*, 34
- Albucasis. *See* Abul Kasim
- Allbut, Sir Thomas  
*The Thyroid Gland: Medical History*, 67
- Allen, Bennet M., 128
- Alexander of Hales, 94
- Amore and Psyche*, referred to, 149
- An Angel Playing the Viola da Braccio from Musical Apostles and Angels* (da Forli), 60
- Anatomical dissection, 3
- Anatomy Act of 1836 (UK), 68
- Anatomy theaters, 3–8 *passim*, 19, 66, 67, 68  
Bologna, 3  
Leiden, 3  
Padova, 3
- Anderson, E. M., 128
- androgyny, 161
- Angelica Saved by Ruggiero* (Ingres), 39
- Anglicus, Bartholomaeus, and caricatures of goiters, 72
- Annunciation* (Botticelli), 28
- Annunciation* (da Forli), 27
- Annunciation* (Lippi), 28
- Apollo, 7
- Aristotle, 4, 7, 8, 68, 94, 98, 152–154  
*Generation of Animals*, 152
- Arthora Vega*, 66
- artist's studio, compared to anatomy theater, 3
- Aschner, Bernard, 96
- Assumption* (Titian), 48
- Baber, Cresswell, 158
- Balacesco, 96
- Banquet of Antony and Cleopatra* (Trevisani), 104
- Basedow, Carl von, 69
- Bauhinus, Caspar, 95, 152
- Benda, Carl, 127
- Berthold, Arnold Adolf, 68, 70, 155
- Bertholde, a Dwarf* (Walker), 116
- Bes (Dwarf God), 97
- Billroth, Theodore, 69, 70
- Bockshammer, Karl, 70
- Bonet, Theophile, 127
- Bordeu, Theophile de, 68, 95
- Boruwlaski, Joseph (eighteenth-century dwarf), 118
- Botticelli, 5, 89  
*Annunciation*, 28  
*Judith's Return to Bethulia*, 56  
*Madonna with the Book*, 31  
*Portrait of a Young Woman*, 42  
*Scenes from the Life of Moses*, 53  
*The Daughters of Jethro*, 53  
*The Three Graces (La Primavera)*, 12, 38
- bronchiocele, 17
- Brown, Jonathan, 108
- Burne-Jones, Edward, 38
- Byrne, Charles, 125, 127, 144
- Calabazas* (Velasquez), 91
- Callot, Jacques, 116
- Campana, Giacinto  
*The Rape of Helen*, 35
- Cantimpré, Thomas de  
*De Monstruosis Hominibus*, 72
- Caravaggio, 5, 8, 15, 31, 56, 57, 59, 60, 61, 64, 84, 86, 87, 132, 134  
*Conversion of Mary Magdalene*, 57  
*David with the Head of Goliath*, 132  
*Judith Beheading Holofernes*, 56  
*Madonna of the Palafrenieri*, 31  
*Madonna of the Pilgrims*, 31  
*Medusa*, 134  
*The Crucifixion of St. Andrew*, 84  
*The Supper at Emmaus*, 59
- Carpaccio, Vittore  
*Arrival of the English Ambassadors at the Court of the King of Brittany*, 104
- Carracci, *Composition with Figures and Animals*, 168
- Casseri, Julius  
description of thyroid, 19
- Caulfield, James, *Remarkable Persons*, 8
- Celsus, Aulus Cornelius, 18, 66
- Cerrini, Gian Domenico  
*David with Goliath's Head*, 134
- Cézanne, Paul, 121  
*Portrait of the Artist's Friend, Achille Empeire*, 121
- Charcot, J.M. and Paul Richer, essay on psychological illness in art, 84
- Charles Byrne, *The Irish Giant with an Admiring Audience* (Rowlandson drawing), 145

- Coello, Alonso Sánchez, 111  
*Portrait of Infanta Isabel Clara Eugenia and Magdalena Ruiz*, 111
- Collip, James, 128, 159
- Columbus, Realdus, 152  
*Composition with Figures and Animals* (Carracci), 165, 168
- Conte, Felix, 155  
*Conversion of Mary Magdalene* (Caravaggio), 57
- Cornell Medical School, and art appreciation, 3
- Cotân, Juan Sánchez  
*La Barbuda de Peñaranda*, 167
- Count Joseph Borowlaski (Reinagle), 117
- Crachami, Caroline, 125  
*Creation and Fall* (Albertinelli), 34
- cretinism, 4, 5, 6, 17, 19, 61, 65, 67, 68, 76, 88, 92, 113, 127
- cretins (dwarfs with congenital hypothyroidism), 93, 113
- Crile, George Washington, 71
- Crivelli, Vittore  
*St. Catherine of Alexandria*, 11, 51
- Crowe, James, 96
- Cruikshank, George, 8, 88, 173
- Cunningham, D.J., 212
- Cupid, 7
- Cushing, Harvey, 6, 96, 128, 157, 169, 172
- Cushing's disease, 128
- Cushing's syndrome, 6, 169
- da Forli, Melozzo, 27, 60  
*An Angel Playing the Viola da Braccio*, 60  
*Annunciation*, 27
- da Vinci, Leonardo, 5, 14  
*Grotesque Man with Goitre*, 73  
*Madonna and Child*, 14, 26  
drawings of thyroid, 19  
*David with Goliath's Head* (Cerrini) Figure 4-6, 134  
*David with Goliath's Head* (Gentileschi), 134  
*David with the Head of Goliath* (Caravaggio), 132  
*David, Conqueror of Goliath* (Reni), 135  
*De Fabrica* (Vesalius), 19
- de Geyn, Jacob  
*Temperantia*, 40
- de Medici, Catherine (breeding a race of dwarfs), 94
- de Mieris, William  
*The Escaped Bird*, 40
- del Piombo, Sebastiano  
*The Martyrdom of Saint Agatha*, 52  
*Polyphemus*, 131
- del Verocchio, Andrea, 26
- del Verocchio (workshop of)  
*The Virgin and Child with Two Angels*, 15, 26
- della Francesca, Piero, 5, 6, 24  
*Resurrection*, 77  
*Madonna del Parto*, 44  
*Madonna della Misericordia*, 25
- de'Pitati, Bonifaccio  
*The Parable of the Rich Man and The Beggar Lazarus (Il Ricco Epulone)*, 101
- Desault, Pierre-Joseph, 69
- di Segna, Niccolò, 24  
*Madonna of the Misericordia*, 14
- diabetes mellitus, 4
- Dieffenbach, Johann, 69
- Don Diego de Acedo or El Primo* (Velasquez), 108, 109
- Dossi, Dosso  
*Maga Circe or Melissa*, 35, 36
- Downs' syndrome, 113
- Duck, Jacob  
*The Sleeping Woman*, 88
- Duval, Jacques, *Des hermaphrodites, accouchemens des femmes, e traitement qui est requis pour les relever en santé bien elever leurs enfants*, 153
- dwarfism, 5  
and growth hormone (IGF-1), 93  
history of diagnosis, 94  
mechanisms of the pituitary gland, 92
- endocrine disease  
and morality in art, 7  
and religious explanation, 18
- "endo-criminology," 96
- endocrinology  
meaning of term, 4
- Ernst, Max  
*Men Shall Know Nothing of This*, 165  
*The Attirement of the Bride*, 78
- Etruscan art  
representing endocrine disease, 4
- Eugenides, Jeffrey, *Middlesex*, 150
- Eustachius, Bartolomeus  
description of thyroid, 19

- Evans, Herbert, 128  
exophthalmos (bulging eyes), 5, 6, 66
- Fabricius ab Acquapendente, 5  
*Feast in the House of Levi* (Veronese), 100
- Ferriss, J. Barry, 84  
*Fight between Pygmies and Animals in a Nilotic Landscape* (Roman fresco), 98
- Fitzmaurice, Deanne  
*Gibson and Zoie*, 125
- Foster, Michael, 96
- Fox, Edward, 70  
*Francisco Lezcano* (Velasquez), 113
- freemartin, 154
- Freund, W.A., 127
- Galen, 4, 5, 18, 66, 68  
on pituitary gland, 95
- Generali, Francesco, 158
- Gentileschi, Artemisia, 5  
*Judith and her Maidservant with the Head of Holofernes*, 63  
*St. Cecilia*, 51
- Gentileschi, Orazio, 6  
*David with Goliath's Head*, 134
- Gerard Andrieze Bicker* (van der Helst), 171
- giants, in mythology, art and history, 129
- Gibson and Zoie* (Fitzmaurice), 125
- Gibson, Thomas, 95
- gigantism, 5, 132, 140, 143  
causes of, 126  
medical history, 127  
therapy for, 128
- Gillray, James, 88  
*The Gout*, 174  
*Monstrous Craws at a New Coalition Feast*, 88
- Gley, Eugene, 158  
goiters, 5, 6, 13  
and challenges of surgical treatment, 68  
and iodine deficiency, 63  
and pregnant women, 44  
meaning of term, 16  
staging criteria, 16
- Gossaert, Jan  
*The Metamorphosis of Hermaphroditus and Salmacis*, 151, 161
- gout, 159, 173  
and pseudogout, 159
- Goya, Francisco, 5  
*The Colossus*, 123, 138  
*The Disasters of War*, 136  
*Saturn Devouring his Son*, 136
- Graves, Robert, 69
- Greek art  
representing endocrine disease, 4, 5
- Gross, Samuel, 69  
*Grotesque Man with Goitre* (da Vinci), Figure 2-5, 73
- Grumbach, Melvin, 155  
gynecomastia, 6, 66, 80, 150, 157
- Hahn, William, 70  
*Half-Length Female Nude* (Picasso), 63
- Halsted, William, 69, 71  
*The Operative Story of Goiter*, 71
- Hedenus, Johann, 69
- Heister, Lorenz, 67  
*Helene Fourment* (Rubens), 43
- Hemessen, Jan Sanders van  
*The Prodigal Son*, 87
- Hercules, represented as giant, 138  
*Hermaphrodite* (statuette), 162
- Hermaphrodite of Mirecourt, 152  
hermaphroditism, 150, 155, 156  
lateral, 150, 156  
pseudo-, 150, 156
- Hippocrates, 68  
on goiters, 17
- hirsutism (excessive body hair), 6, 151
- Hogarth, William, 88  
*The Marriage Contract from Marriage a la Mode*, 171
- Holbein, Hans the Younger  
*Adam and Eve*, 13
- Home, Sir Everard, 125
- Homer  
*Iliad*, 98  
*Odyssey*, 130
- Horsley, Sir Victor, 70, 96, 158
- Hunter, John, 5, 68, 125, 154
- Hunterian Museum, London, 118, 125, 144
- hyperparathyroidism, 6, 158, 159
- hyperthyroidism, 4
- hypophysectomy, 96
- hypospadias, 150, 157
- hypothyroidism, 4  
and iodine deficiency, 64
- IGF (insulin-like growth factor), 125
- Il Sodoma  
*Life of Saint Benedict*, 49, 65, 81  
using models from regions with endemic goiter, 81
- Ingres, Jean August Dominique  
*Angelica Saved by Ruggiero*, 39
- iodine deficiency and goiters, 16



- Johns Hopkins Medical Center  
and advances in thyroid surgery,  
71
- Judith and her Maidservant with the  
Head of Holofernes* (Gentileschi)  
63
- Judith Beheading Holofernes*  
(Caravaggio), 56
- Judith's Return to Bethulia*  
(Botticelli), 56
- Klee, Paul  
*The Hero with the Wing*, 80
- Klinefelter's syndrome, 156
- Ko Hung (Chinese alchemist), 66
- Kocher, Theodore, 5, 70
- Kohn, Alfred, 158
- La Nana* (Picasso), 122
- La Primavera* (Botticelli), 11
- Lahey, Frank H., 71
- Landi, Neroccio di Bartolomeo  
*Saint Bernardino Performing an  
Exorcism*, 78
- Langenbeck, Bernard, 70
- Large Grotesque Head* (Ribera), 72
- Laron's dwarfism, 92
- Las Meninas or The Maids of Honor*  
(Velasquez), 114
- Las Meninas* (Picasso), 115
- Le Nain, Louis  
*The Resting Horseman*, 47
- Life of Saint Benedict* (Il Sodoma), 49,  
65, 81
- Ligorio, Pirro, Parco di Mostri, 143
- Lippi, Fra Filippo, 28  
*Annunciation*, 28, 29  
*The Madonna and Child with  
Stories from the Life of St. Anne*, 46
- Lister, Joseph, 69
- Liston, Robert, 69
- Louise or the Breton Servant*  
(Serusier), 146
- Lower, Richard, 95
- Ludovico Gonzaga and Family with  
Courtiers* (Mantegna), 105
- lymphadenopathy, 66
- MacCallum, George, 158
- Madonna and Child* (da Vinci), 26
- Madonna del Parto* (Piero della  
Francesca)  
and iodine deficiency, 44
- Madonna of the Misericordia* (di  
Segna), 24
- Madonna of the Misericordia* (Piero  
della Francesca), 17, 24, 48, 77
- Madonna of the Palafrenieri*  
(Caravaggio), 31
- Madonna of the Pilgrims*  
(Caravaggio), 31
- Madonna with the Book* (Botticelli),  
31
- Madonna with the Long Neck*  
(Parmigianino), 31
- Maerlant, Jacob van, and caricatures  
of goiters, 72
- Maga Circe o Melissa* (Dossi), 35, 36
- Maggiore, Monte Oliveto  
*The Life of St. Benedict* (Il  
Sodoma fresco series), 80
- Magnus, Albertus  
*De Animalibus*, 94
- Magrath, Cornelius, 127
- Mandeville, John, *Travels and  
Voyages*, 160
- Mandl, Felix, 159
- Mantegna, Andrea  
*Ludovico Gonzaga and Family  
with Courtiers*, 105
- Marcelle Lender Dancing the Bolero  
in "Chilpéric"* (Lautrec), 121
- Marie's Malady, 127
- Marie, Pierre, 127
- Matisse, 64
- Mayo, Charles H., 71
- Meckel, Johann, 155
- medical theories of normality, 4, 5, 144  
in Enlightenment, 8
- medullary thyroid cancer, 158
- MEN (multiple endocrine neoplasia),  
126
- Men Shall Know Nothing of This*  
(Ernst), 165
- menstruation, 127, 153
- Michelangelo, 5, 7, 14  
on goiters, 18
- Middlebrook, Diane, *The Double Life  
of Billy Tipton*, 150
- Mieris, Willem de, 40
- Mikulicz, Johann, 70
- Minkowski, Oskar, 127
- Modigliani, 64
- Molenaer, Jan  
*Stone-throwing Dwarf*, 106  
*The Artist's Studio*, 107
- Monna Vanna* (Rossetti), 38
- Mor, Anthonis (aka van Dashort)  
*The Dwarf of Cardinal Granvelle*,  
107
- Morris, William, 38
- Mt. Sinai Medical School, 3
- Murray, George, 70
- myxedema, 17

- Nelson's Syndrome, 157, 158
- Niepcze, Bernard, 127
- Noonan's syndrome, 93
- Norman's Syndrome, 93
- Oeuvres Complète de Ambroise Paré*  
(Paré), 163, 166
- Osler, Sir William, 20
- Ovid, *The Metamorphoses*, 151
- Owen, Sir Richard, 158
- Paracelsus, 5, 18, 66
- Paré, Ambroise, 5, 7, 67  
on dwarfism, 94  
*Oeuvres Complète*, 163, 166
- Park, Katharine, 3
- Parry, Caleb Hillier, 69
- Paul of Aegina, 67
- Paulesco, Nicolas C., 96
- pheochromocytoma, 158
- Picasso, Pablo, 63, 64, 115, 116,  
122, 147  
*Half-Length Female Nude*, 63  
*La Nana*, 122  
*Las Meninas*, 115
- Piedmont  
prevalence of endemic goiter, 5
- pituitary gland and tumors, 126
- Pliny the Elder  
*Natural History*, 98  
on goiters, 18
- Plummer, Henry, 71
- Pollaiuolo, Antonio, 138  
*The Labors of Hercules*, 138
- polychrome terracotta sculpture of  
henchman with club (untitled), 76
- Polyphemus* (del Pombo), 131
- Polyphemus myth, 130
- Portrait of a Young Woman*  
(Botticelli), 42
- Portrait of a Young Woman with a  
Gilded Wreath*, 41
- Portrait of Baltasar Carlos, son of  
Philip IV, with a Dwarf*  
(Velasquez) Figure 3-13, 110
- Portrait of Infanta Isabel Clara  
Eugenia and Magdalena Ruiz  
(dwarf with monkeys)* (Coello),  
111
- Portrait of Susanna Lunden* (Rubens),  
43
- Prometheus, in Greek myth, 138
- Prometheus Bound* (Rubens), 140
- pygmies, 92  
and literary representation, 98  
and cranes, 98
- Queen Henrietta Maria and her Dwarf  
Jeffrey Hudson* (Van Dyck), 102
- Raphael, 5, 6, 38, 39, 82, 84, 103,  
170, 171  
*The Cross Appearing to  
Constantine the Great Flanked  
by Two Popes*, 103  
*Transfiguration*, 82
- Reinagle, Philip  
*Count Joseph Boruwlaski*, 117
- Remak, Robert, 158
- Rembrandt, 8  
*The Anatomy Lesson*, 8
- Reni, Guido, 135
- Resurrection* (Piero della Francesca), 77
- Reverdin, Jacques Louis, 70
- Ribera, Jusepe de, 5, 6, 91  
*Large Grotesque Head*, 72  
*The Bearded Woman  
Breastfeeding*, dust jacket,  
148, 166
- The Dwarf and the Dog*, 91
- The Small Grotesque Head*, 72
- Richer, Paul and J.M. Charcot, essay  
on psychological illness in art, 84
- Riolan, Jean, 153
- Robertson, Brailsford, 128
- Roger of Palermo (Frugardi), 67
- Rogowitsch, N., 95, 127
- Roman art  
representing endocrine disease, 4,  
5, 11
- Rossetti, Dante Gabriel, 38  
*Astarte Syriaca*, 39  
*A Daydream*, 11, 12  
*The Beloved*, 171  
*Monna Vanna*, 39  
*Veronica Veronese*, 39
- Rowlandson, Thomas, 88  
*Drawing of Charles Byrne, The  
Irish Giant with an Admiring  
Audience*, 143
- Rubens, Sir Peter Paul, 5, 11, 13, 34,  
38, 43, 55, 61, 87, 137, 138, 140,  
142, 143  
*Helene Fourment in her Wedding  
Dress*, 43  
paintings of subjects in iodine  
deficient areas, 43  
polychrome terracotta sculpture,  
76  
*Portrait of Susanna Lunden*, 43  
*Prometheus Bound*, 140  
*St. Christopher and the  
Hermit*, 143  
*Samson and Delilah*, 11, 34  
*Saturn Devouring His Son*, 137  
*Susanna and the Elders*, 55  
*The Three Graces*, 38
- Saint Bernardino Performing an  
Exorcism* (Landi), 78
- Saint Cecilia* (Artemisia Gentileschi), 51

- Saint Mark Enthroned Surrounded by Musical Angels* (Vivarini), 60
- Samson and Delilah* (Rubens), 11, 34
- Sandstrom, Viktor Ivar, 158
- Santorini, Giovanni D., 95
- Saturn Devouring his Son* (Goya), 136
- Saturn Devouring His Son* (Rubens), 137
- Schiff, Moritz, 70
- Schneider, Conrad Victor, 95
- scrofula, 66
- Sequard, Brown, 157
- Shakespeare, *The Tempest*, 72
- Sick, Paul, 70
- Simmonds, Morris, 96
- Simpson, James, 155
- Sleeping Hermaphrodite*, 160
- Smith, Philip E., 128
- Soranos of Ephesus, 20
- Souza-Leite, Dr.  
“A Thesis on Acromegaly,” 127
- St. Catherine of Alexandria* (Crivelli), 11, 51
- St. Christopher and the Hermit* (Rubens), 143
- St. Christopher Carrying the Christ Child* (Moreel Triptych) (Memling), 142
- St. Christopher Carrying the Christ Child* (Pearl of Brabant altarpiece) (Bouts), 141
- Stanford Medical School, and art appreciation, 3
- Starling, Ernest Henry, 4
- Steen, Jan, 106  
influence of Rubens and Caravaggio on, 87  
*The Doctor and the Patient*, 44  
*The Dissolute Household*, 88
- Stela of the God Bes*, 97
- Stone-throwing Dwarf* (Molenaer) Figure 3-9, 106
- Summer* (from *The Four Seasons*), 40
- Susanna and the Elders* (Rubens), 55
- Temperantia* (de Gheyn), 40
- Teniers, David, 99  
*The Rich Man Being Led to Hell*, 99
- The Anatomy Lesson* (Rembrandt), 8
- The Artist’s Studio* (Molenaer) Figure 3-10, 107
- The Attirement of the Bride* (Ernst), 78
- The Bearded Woman Breastfeeding* (Ribera), dust jacket, 148, 166
- The Beloved* (Rossetti), 171
- The Colossus* (Goya), 138
- The Cross Appearing to Constantine the Great Flanked by Two Popes* (Raphael), 103
- The Crucifixion of St. Andrew* (Caravaggio), 84
- The Doctor and the Patient* (Steen), 21, 44
- The Doge Dandolo and the Dogaressa Being Presented to the Virgin* (Veneziano), 23
- The Dwarf and a Dog* (Ribera), 91
- The Dwarf of Cardinal Granvelle* (Mor), 107
- The Escaped Bird* (de Mieris), 40
- The Fire in the Borgo in the Stanza dell’Incendio* (Raphael), 170
- The Garden of Earthly Delights* (Bosch), 164
- The Gout* (Gillray), 174
- The ‘Hair Man’ Petrus Gonsalvus*, 167
- The Hero with the Wing* (Klee), 80
- The Labors of Hercules: Hercules and the Hydra* (Pollaiuolo), 138
- The Lamentation* (Van Dyck), 48
- The Last Judgement* in the Cathedral of Santa Maria Assunta, 23
- The Life of St. Benedict* (Maggiore), 80
- The Madonna and Child with Stories of the Life of Saint Anne* (Lippi) goiters and motherhood, 44, 46
- The Madonna of the Misericordia* (Piero della Francesca), 48
- The Magdalen Reading* (Van der Weyden), 49
- The Marriage at Cana* (Veronese), 101
- The Marriage Contract* (Hogarth), 173
- The Martyrdom of Saint Agatha* (del Piombo), 52
- The Metamorphosis of Hermaphroditus and Salmacis* (Gossaert), 151, 161
- The Monstrous Craws at a New Coalition Feast* (Gillray), 88
- The Parable of the Rich Man and the Beggar Lazarus* or *Il Ricco Epulone* (de’Pitati), 101
- The Prodigal Son* (van Hemessen), 87
- The Rape of Helen* (Campana), 35
- The Resting Horseman* (Le Nain), 47
- The Rich Man Being Led to Hell* (Teniers), 99
- The Sleeping Woman* (Duck), 88
- The Small Grotesque Head* (Ribera), 72
- The Supper at Emmaus* (Caravaggio), 59
- The Three Graces* (Rubens), 38, 43
- The Transfiguration* (Raphael), 6
- The Virgin and Sleeping Child* (Mantegna), 26

- thyroid disorders  
 autoimmune disease (Hashimoto's disease), 16, 17, 64  
 Graves' disease, 5, 6, 28, 64, 65, 66, 68, 69, 71, 80, 82, 84, 88  
 nodules, 16, 17  
 multinodular goiter, 65, 76  
 physiological signs, 6  
 sixteenth-century advances in understanding, 18
- thyroid operations, 117  
 metabolic complications, 70  
 resistance to, 69
- Tom Thumb, 119, 121
- Transfiguration* (Raphael), 6, 82
- Trevisani, Francesco  
*Banquet of Antony and Cleopatra*, 104
- Turner's syndrome, 93
- Tuscany  
 prevalence of endemic goiter, 5
- Two miniature people, known as the Aztec Lilliputians, with their manager* (Wilkinson), 118
- Ulysses (Odysseus) and his Companions Blinding Polyphemus*, 131
- Umbria  
 prevalence of endemic goiter, 5
- Van der Weyden, Roger, 49
- Van Dyck, Anthony, 102, 111  
*The Deposition*, 48  
*Queen Henrietta with her Dwarf Jeffrey Hudson*, 102
- Vassale, Giulio, 158
- Velasquez, Diego de, 5, 6  
*Calabazas*, 91  
*Don Diego de Acedo, El Primo*, 109  
*Francisco Lezcano*, 113  
*Las Meninas*, 114  
*Portrait of Baltasar Carlos, son of Philip IV, with a Dwarf*, 100
- Veneziano, Paolo, 23  
*The Doge Dandolo and the Dogressa*, 23
- Verga, Andrea  
 on treatment for gigantism, 127
- Veronese, Paolo, 6  
*Feast in the House of Levi*, 100
- Vesalius, Andreas, 5  
*De Humani Corporis Fabrica*, 67  
 and connections between art and science, 19
- Vespin, Jean, 76  
*Polychrome terracotta sculpture*, 76
- Vieussens, Raymond and Sylvius, 127
- Virchow, Ludwig, 127
- Virchow, Rudolf, 67
- Virgil, *Aeneid*, 170
- Virgin and Child with Two Angels* (del Verocchio), 26
- virilism, 150
- vital principle  
 medical theory of, 69
- Vivarini, Bartolomeo  
*Saint Mark Enthroned Surrounded by Musical Angels*, 60
- Voegtlin, Carl, 159
- von Hocheneegg, Julius, 128
- von Recklinghausen's disease, 73
- Wagner, Rudolf, 155
- Wharton, Thomas  
 on function of thyroid, 20
- Wilkinson, G.  
*Two miniature people, known as the Aztec Lilliputians, with their manager*, 118
- Willis, Thomas, 95, 154
- Yale Medical School, and art appreciation, 3
- Zwemer, R. L., 157

**Carol Clark** (BA, Barnard College, MA in English, San Francisco State University) taught high school English at the Crystal Springs Uplands School, Hillsborough, California, from 1980–2005 and was English Dept. Chair from 1989–98. The co-author of three poetry anthologies, she has also edited several art catalogues for the Catharine Clark Gallery in San Francisco.

**Orlo H. Clark, MD** is Professor of Surgery at UCSF Medical Center. A graduate of Cornell University and Cornell Medical School, Dr. Clark joined the UCSF Department of Surgery in 1973 and was Vice Chair of the department and Chief of Surgery at UCSF/ Mt. Zion Hospital from 1990–2003. A founding member and past president of the International Association of Endocrine Surgeons and of the American Association of Endocrine Surgeons, he has also been president of the American Thyroid Association, the Pacific Coast Surgical Association and the San Francisco Surgical Society. The author of over 450 peer reviewed articles, sixteen books, and numerous book chapters, Dr. Clark has been the recipient of several teaching awards at UCSF and of the AAES Oliver Cope Meritorious Achievement Award.



It is truly fitting that Orlo Clark, considered a father of modern endocrine surgery and a world-renowned leader in the field, along with Carol Clark, a writer and scholar in art history, have enriched our legacy with their consummate atlas *The Remarkables: Endocrine Abnormalities in Art*; this work of scholarship will most certainly become a part of our unique heritage.

**Martha A. Zeiger, MD, FACS, FACE, The Johns Hopkins University School of Medicine**

A visual feast with a revelatory text, *The Remarkables* makes a brilliant contribution to contemporary explorations of science and art. The authors document artists' acute powers of observation and depiction as well as the aesthetic, spiritual, moral, and social meanings these glandular conditions connoted to their viewers. You will never look at a painting of a Renaissance Madonna or a portrait by Velasquez in the same way again.

**Marcia Tanner, Independent Curator, Leonardo**

In this unique exploration of the links between art and medicine, the Clarks focus on endocrinology, the field that best explains the shaping, and misshaping, of the human form. In clear and concise prose, they demonstrate how artists used a variety of endocrine diseases—dwarfism, gigantism, those with swollen goiters or ambiguous sexuality—as points of departure. The Clarks are not only meticulous in identifying the diseases but original in explaining the artists' fascination with the normal and abnormal. A “Must Read” for anyone who would understand the profound interactions of medicine and culture.

**David J. Rothman, Bernard Schoenberg Professor of Social Medicine and Professor of History, Columbia University**

**Cover**

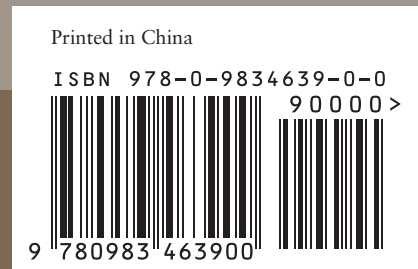Jusepe de Ribera, *The Bearded Woman Breastfeeding*, 1631, Toledo, Hospital de Tavera, Museo Fundación Duque de Lerma.

University of California  
Medical Humanities Consortium  
3333 California Street  
Suite 485  
San Francisco, CA 94143-0850



University of California Press  
[www.ucpress.edu](http://www.ucpress.edu)

BERKELEY — LOS ANGELES — LONDON



**The Remarkables** Endocrine Abnormalities in Art

Carol Z. Clark  
Orlo H. Clark, MD