

# UCSF

## UC San Francisco Previously Published Works

### Title

Comparison of radionuclide angiographic synchrony analysis to echocardiography and magnetic resonance imaging for the diagnosis of arrhythmogenic right ventricular cardiomyopathy.

### Permalink

<https://escholarship.org/uc/item/9w69360x>

### Journal

Heart rhythm, 12(6)

### ISSN

1547-5271

### Authors

Johnson, Colleen J  
Roberts, Jason D  
James, Jameze H  
[et al.](#)

### Publication Date

2015-06-01

### DOI

10.1016/j.hrthm.2015.02.033

Peer reviewed

# Comparison of radionuclide angiographic synchrony analysis to echocardiography and magnetic resonance imaging for the diagnosis of arrhythmogenic right ventricular cardiomyopathy



Colleen J. Johnson, MD,<sup>1\*</sup> Jason D. Roberts, MD,<sup>1\*</sup> Jameze H. James, BA,<sup>\*</sup> Kurt S. Hoffmayer, MD,<sup>\*</sup> Nitish Badhwar, MD,<sup>\*</sup> Ivy A. Ku, MD,<sup>†</sup> Susan Zhao, MD,<sup>†</sup> David M. Naeger, MD,<sup>‡</sup> Rajni K. Rao, MD,<sup>†</sup> John W. O'Connell, MS,<sup>2†</sup> Teresa De Marco, MD,<sup>†</sup> Elias H. Botvinick, MD,<sup>†</sup> Melvin M. Scheinman, MD, FHRS<sup>\*</sup>

From the <sup>\*</sup>Section of Cardiac Electrophysiology, Division of Cardiology, Department of Medicine, University of California, San Francisco, California, <sup>†</sup>Division of Cardiology, Department of Medicine, University of California, San Francisco, San Francisco, California, and <sup>‡</sup>Department of Radiology, University of California, San Francisco, San Francisco, California.

**BACKGROUND** Arrhythmogenic right ventricular cardiomyopathy (ARVC) is a heritable arrhythmia syndrome entailing a high risk of sudden cardiac death. Discernment from benign arrhythmia disorders, particularly right ventricular outflow tract ventricular tachycardia (RVOT VT), may be challenging, providing an impetus to explore alternative modalities that may facilitate evaluation of patients with suspected ARVC.

**OBJECTIVE** We evaluated the role of equilibrium radionuclide angiography (ERNA) as a diagnostic tool for ARVC.

**METHODS** ERNA measures of ventricular synchrony—synchrony (S) and entropy (E)—were examined in patients with ARVC (n = 16), those with RVOT VT (n = 13), and healthy controls (n = 49). The sensitivity and specificity of ERNA parameters for ARVC diagnosis were compared with those of echocardiography (ECHO) and cardiovascular magnetic resonance (CMR).

**RESULTS** ERNA right ventricular synchrony parameters in patients with ARVC (S = 0.91 ± 0.07; E = 0.61 ± 0.1) differed significantly from those in patients with RVOT VT (S = 0.99 ± 0.01 [P = .0015]; E = 0.46 ± 0.05 [P < .001]) and healthy controls (S = 0.97 ± 0.02 [P = .003]; E = 0.48 ± 0.07 [P = .001]). The sensitivity of ERNA synchrony parameters for ARVC diagnosis (81%) was higher than that for ECHO (38%; P = .033) and similar to that for CMR

(69%; P = .162), while specificity was lower for ERNA (89%) than that for ECHO and CMR (both 100%; P = .008).

**CONCLUSION** ERNA right ventricular synchrony parameters can distinguish patients with ARVC from controls with structurally normal hearts, and its performance is comparable to that of ECHO and CMR for ARVC diagnosis. These findings suggest that ERNA may serve as a valuable imaging tool in the diagnostic evaluation of patients with suspected ARVC.

**KEYWORDS** Arrhythmogenic right ventricular cardiomyopathy; Equilibrium radionuclide angiography; Cardiovascular magnetic resonance; Echocardiography; Diagnosis

**ABBREVIATIONS** ARVC = arrhythmogenic right ventricular cardiomyopathy; CMR = cardiovascular magnetic resonance; E = entropy; ECG = electrocardiographic; ECHO = echocardiography; ERNA = equilibrium radionuclide angiography; ICD = implantable cardioverter-defibrillator; LV = left ventricular; ROC = receiver operating characteristic; ROI = region of interest; RV = right ventricular; RVOT VT = right ventricular outflow tract ventricular tachycardia; S = synchrony

(Heart Rhythm 2015;12:1268–1275) © 2015 Heart Rhythm Society. All rights reserved.

This work was presented in part at the 2011 Heart Rhythm Society Meeting. This work was supported in part by a grant from Philips, Inc, Nuclear Medicine Division, Milpitas, CA. **Address reprint requests and correspondence:** Dr Jason D. Roberts, Section of Cardiac Electrophysiology, Division of Cardiology, Department of Medicine, University of California, San Francisco, Box 1354, 500 Parnassus Avenue, MUE-434, San Francisco, CA 94143. E-mail address: jason.roberts@ucsf.edu.

<sup>1</sup>Dr Johnson and Dr Roberts contributed equally to this work.

<sup>2</sup>Mr O'Connell died after the completion of the study.

## Introduction

Arrhythmogenic right ventricular cardiomyopathy (ARVC) is an inherited arrhythmia disorder pathologically characterized by fibrofatty replacement of the right ventricle.<sup>1</sup> Affected patients suffer from heart failure, malignant ventricular arrhythmias, and sudden cardiac death.<sup>2</sup> Accurate diagnosis and discernment from benign disorders, particularly idiopathic right ventricular outflow tract ventricular tachycardia (RVOT VT), is critical to guide appropriate

clinical care, given the high risk of sudden death.<sup>3</sup> There remains no single definitive diagnostic test for ARVC, and diagnosis currently relies on a composite of clinical, imaging, pathologic, and electrocardiographic (ECG) features outlined in the modified Task Force criteria.<sup>4,5</sup> Although the modified Task Force criteria are highly specific, they have modest sensitivity, especially in mild and early stages of the disease.<sup>5,6</sup>

Current diagnostic imaging modalities incorporated into the modified Task Force criteria include echocardiography (ECHO), cardiovascular magnetic resonance (CMR), and angiography. Although clearly valuable diagnostic tools, each of them has important limitations and may yield inconclusive findings.<sup>6–8</sup> The parametric evaluation of equilibrium radionuclide angiography (ERNA) has the potential to serve as an additional method that may help to further facilitate the diagnosis of ARVC. ERNA is a volume-based assay that has been shown to provide a graphical representation of the sequence of regional ventricular contraction.<sup>9–13</sup> In previous studies, ERNA phase analysis had higher sensitivity for the detection of right ventricular (RV) enlargement and systolic dysfunction than did angiography.<sup>14,15</sup> ERNA has also been shown to have prognostic value with respect to the risk of sudden cardiac death in patients with structurally abnormal RVs and arrhythmia.<sup>16</sup> The technique has recently been adapted to measure both RV and left ventricular (LV) synchrony, and in this context, our group has developed 2 parameters to characterize ventricular function: synchrony (S) and entropy (E).<sup>17–20</sup> These parameters provide an objective measure of RV and LV dysfunction in patients with ARVC and have been shown to reproducibly differentiate varying contraction patterns.<sup>17–20</sup>

Despite their potential, ERNA synchrony parameters have yet to be examined as a diagnostic tool for ARVC. In this study, we evaluated ERNA synchrony parameters in patients with ARVC, patients with RVOT VT, and controls with structurally normal hearts and compared the performance of ERNA with that of ECHO and CMR.

## Methods

### Study participants

The study enrolled consecutive patients with ARVC and RVOT VT and randomly selected control participants that were being clinically managed at the University of California, San Francisco Medical Center between July 2008 and May 2011. All cases of ARVC required a classification of “definite” as defined by the modified Task Force criteria. All cases of RVOT VT required the localization of their ventricular arrhythmia to be confirmed with an electrophysiological study and successful ablation. Cases of RVOT VT were excluded if they had evidence of scar on imaging or voltage mapping, ECG findings consistent with ARVC, or a positive family history of ARVC or sudden cardiac death. Control participants consisted of patients with cancer undergoing potentially cardiotoxic chemotherapy and an ERNA for assessment of cardiac function. Controls were excluded if

they had known structural heart disease or coronary artery disease. Clinical demographic characteristics and details were obtained through review of electronic medical records. All study participants signed an informed consent approved by the institutional review board of the University of California, San Francisco.

### Imaging protocols

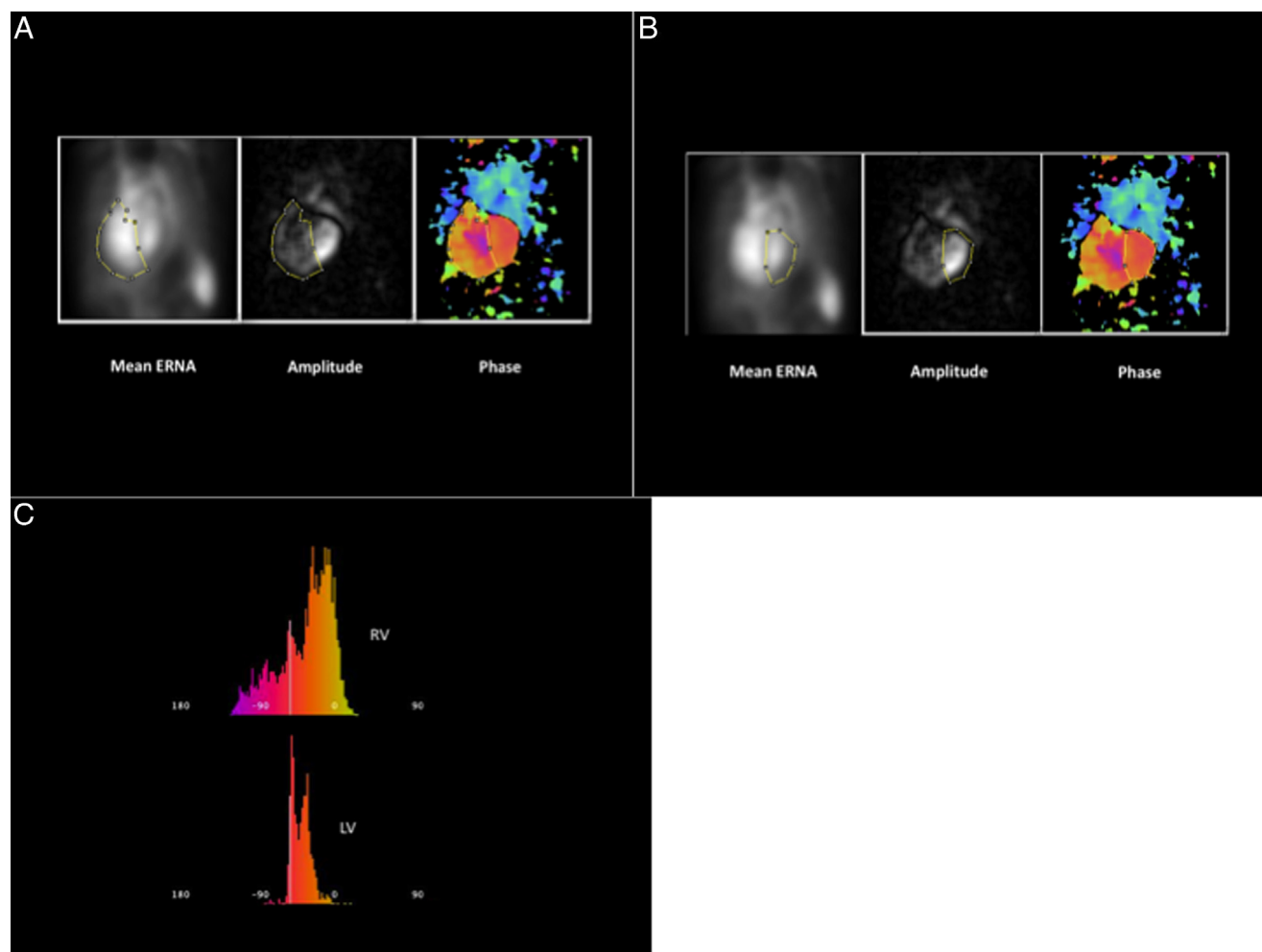
All enrolled patients underwent ERNA, and all patients with ARVC and RVOT VT underwent ECHO. CMR was performed in a subgroup of participants with ARVC and RVOT VT with standardized protocols using ECG triggering. The CMR protocol included stack cines in RVOT, axial, short-axis, and 4-chamber planes. All scans were performed within 6 months in each patient and were interpreted by physicians with expertise in cardiac imaging.

### ERNA

ERNA is a scintigraphic method that begins minutes after the intravenous administration of a radiolabeled agent confined to the blood, typically red blood cells, when the tracer is at “equilibrium,” and each cubic centimeter contains the same amount of radioactivity. An ECG gate senses the R wave and measures the mean duration of the cardiac cycle. Then, blood pool images are acquired with a standard scintillation camera over 16–32 evenly spaced temporal intervals between the R waves of several hundred cycles. Serial images display the ventricles at sequential intervals of the cardiac cycle, where counts are proportional to volume, and may be displayed as a movie to provide a graphical representation of the sequence of regional ventricular contraction. Background-corrected counts measured in computer-generated LV and RV regions of interest (ROIs) in the end-diastolic and end-systolic frames provide a common, accurate, and reproducible method for the calculation of LV and RV ejection fraction. The composite ventricular time vs radioactivity curve provides the basis for the parametric imaging method of phase imaging.

### ERNA measurements

ERNA measurements were acquired in 16 frames and processed by the standard laboratory protocol. ERNA relates image intensity, or counts, to chamber volume in a specific ROI. The phase image is a functional image composed of the regional phase angle generated from the first Fourier harmonic or cosine curve fit of the ERNA time vs radioactivity curve in each pixel of the “best septal” left anterior oblique projection. This projection was chosen to best separate the ventricular ROIs that were manually tailored to the ventricular base by the operator and cut off where the ventricles overlapped or were contaminated with atria or vascular structures. Fitted to the raw count data in each pixel, the first harmonic curve can be characterized by its amplitude (A), similar to regional stroke volume, and the phase angle ( $\emptyset$ ), measured in degrees, to express the timing of regional contraction with reference to the gating signal (the ECG R wave). Contraction onset at the R wave would have  $\emptyset = 0^\circ$ .



**Figure 1** Left anterior oblique view of ventricular phase images of a patient with arrhythmogenic right ventricular cardiomyopathy. **A and B:** Right ventricular (RV) (panel A) and left ventricular (LV) (panel B) regions of interest (ROIs): Panels from left to right illustrate the mean ERNA, the amplitude image, and the phase image with the RV and LV ROI simultaneously superimposed on each. **C:** Phase histograms with the phase angle on the abscissa and the number of pixels with each phase angle on the ordinate for the RV ROI (above) and the LV ROI (below). The broad RV histogram reflects dyssynchrony. A similar analysis of normal ventricles in a normal heart is shown in [Online Supplemental Figure 1](#).

**S (synchrony) parameter**

The first harmonic fit for each pixel can be represented as a vector with direction given by  $\emptyset$  and length by A. The characteristics of A and  $\emptyset$  correlate with measures of ventricular function and synchrony, respectively. The selection of an ERNA phase image RV ROI, within which all RV parameters are calculated, is shown in [Figure 1](#) and [Online Supplemental Figure 1](#). The standard deviation of the RV phase angle ( $SD\ RV\emptyset$ ) is calculated from the phase histogram, which plots the phase angle of each pixel vs the number of pixels with each phase angle within the RV ROI.

S expresses the degree of synchrony when the ROI, such as the RV, contains more than one  $\emptyset$ . As the vector is defined by A and  $\emptyset$  of any pixel, vector length  $|v_i|$  corresponds to the amplitude such that

$$S = \left| \sum_{i=1}^N v_i \right| / \left| \sum_{i=1}^N |v_i| \right|$$

Here, S is the vector sum of all amplitudes in the ROI based on the angular distribution of  $\emptyset$  divided by the scalar sum of

all vector lengths. S ranges from 0, in the presence of random contraction, to 1, in the case of perfect synchrony.

**E (entropy) parameter**

Alternatively, the measure of coordination of the ROI may be generated as the degree of disorder, or entropy (E). E is not the converse of S. When S is close to 0, S relates to the distribution of  $\emptyset$  in at least 2 ways: (1) if contraction is random and totally uncoordinated or (2) if the ROI consists of 2 areas, one 180° out of phase with the other, where each area is highly synchronous, but their sum is not. In order to distinguish the infinite range of the distribution of possible dyssynchrony, we used the normalized Shannon information measure such that

$$E = - \sum_{i=1}^M p_i \log_2(p_i) / \log_2(M)$$

where M is the number of phase angles ( $\emptyset$ ) in an ROI and  $p_i$  is the frequency of occurrence of  $\emptyset_i$ .<sup>21</sup> E measures the degree of disorder within the ROI and ranges from 0, with complete order and just one  $\emptyset$ , to 1, with fully random contraction.

We measured  $SD\emptyset$ , S, and E in both the RV and the LV and compared them between different study populations. Measurements and analyses for each imaging modality were performed by experts blinded to the clinical data.

### Statistical analysis

All variables are expressed as mean  $\pm$  SD. S and E for the 3 groups were compared using a 1-way analysis of variance test and then further analyzed using the Student *t* test to assess for differences among individual groups. Repeated-measures 1-way analysis of variance tests were performed comparing inter- and intraobserver reproducibility using the Spearman rank correlation coefficient and intraclass correlation coefficient, respectively. Receiver operating characteristic (ROC) curve analyses were performed using RV parameters S and E to compare ARVC and RVOT VT populations as well as ARVC and control populations. The sensitivity and specificity of ERNA S and E synchrony values, ECHO, and CMR were determined for the diagnosis of ARVC. The parameters outlined in the modified Task Force criteria were the reference standards for the diagnosis of ARVC using ECHO and CMR (major or minor criterion).<sup>5</sup> Classification of an ERNA measurement as positive required that both S and E be within abnormal limits. The accuracy of both S and E were compared with that of ECHO and CMR by calculating the  $\chi^2$  statistic using the McNemar test. Bivariate and multivariate logistic regression models were used to determine the association between abnormal ERNA synchrony parameters and VT in patients with ARVC. Covariates added to these models included age and sex. Two-tailed *P* values  $\leq .05$  were considered statistically significant.

## Results

### Study participants

Sixteen patients who met Task Force criteria for ARVC (classified as definite) were enrolled in the study (Online Supplemental Tables 1 and 2). All underwent ECHO and ERNA; however, 3 did not undergo CMR owing to the presence of an implantable cardioverter-defibrillator (ICD). Genetic testing was performed in all patients, and a pathogenic culprit was identified in 7 of the 16 patients (Online Supplemental Table 3). In order to exclude the possibility of clinical mimickers of ARVC, myocardial

biopsies were selectively performed in 6 patients as requested by the treating clinician and no evidence of an alternative diagnosis was found (Online Supplemental Table 3). A total of 13 patients with RVOT VT were recruited, including a single participant who also had a concomitant VT focus in the LV outflow tract (Online Supplemental Table 1). All the patients were followed longitudinally after their ablation procedure and none developed features of ARVC. All 13 patients with RVOT VT completed ECHO and ERNA; however, only 10 completed CMR because of clinical preference of the physician. Forty-nine randomly selected patients with cancer undergoing a clinically indicated ERNA assessment of cardiac function were enrolled in the study (Online Supplemental Table 1). The control group did not undergo CMR or ECHO.

### ERNA reference values

Normal values for S and E were derived from the previously described control group of 49 patients with normal ventricular size and function receiving cardiotoxic chemotherapy (Online Supplemental Figure 1). Within this group, 23 and 26 patients underwent ERNA before and after the initiation of chemotherapy, respectively. Analysis of the ERNA phase and synchrony parameters in these 2 subgroups revealed no statistical difference between any RV or LV measures, namely,  $SD\emptyset$ , S, or E (Table 1). The data from both subgroups were combined and used as normal reference values ( $S \geq 0.97$  and  $E \leq 0.47$ ).

### Population with idiopathic RVOT VT

All 13 patients with RVOT VT had normal echocardiograms and RV voltage maps at the time of their electrophysiological study. Ten of the 13 patients completed CMR, and 3 were reported to have a mildly reduced RV ejection fraction (40%, 41%, and 43%; normal  $\geq 45\%$ ); however, none had evidence of regional akinesia, dyskinesia, or dyssynchronous RV contraction. None of the patients with RVOT VT had ECHO or CMR findings consistent with ARVC on the basis of the modified Task Force criteria. All 13 patients underwent ERNA, and no statistical differences were observed for either RV or LV measures as compared to the control population (Table 2).

**Table 1** Comparison of ERNA synchrony parameters in the control population

Measurement	No previous cardiotoxic chemotherapy (n = 23)		Previous cardiotoxic chemotherapy (n = 26)		<i>P</i> *	
	RV	LV	RV	LV	RV	LV
$SD\emptyset$	17 $\pm$ 5	13 $\pm$ 3	18 $\pm$ 6	13 $\pm$ 4	.32	.99
S	0.97 $\pm$ 0.02	0.96 $\pm$ 0.12	0.97 $\pm$ 0.02	0.98 $\pm$ 0.01	.62	.43
E	0.47 $\pm$ 0.07	0.43 $\pm$ 0.13	0.49 $\pm$ 0.06	0.40 $\pm$ 0.1	.39	.38

E = entropy; ERNA = equilibrium radionuclide angiography; LV = left ventricle; RV = right ventricle; S = synchrony;  $SD\emptyset$  = standard deviation of the phase angle.

Measurements are expressed as mean  $\pm$  SD.

\* Comparison of between-group RV and LV values.



**Table 2** Comparison of ERNA synchrony parameters between the RVOT VT and control populations

Measurement	RVOT VT group (n = 13)		Control group (n = 49)		P*	
	RV	LV	RV	LV	RV	LV
SDØ	17 ± 8	12 ± 3	17 ± 6	13 ± 3	.83	.16
S	0.98 ± 0.01	0.99 ± 0.01	0.97 ± 0.02	0.97 ± 0.08	.17	.28
E	0.46 ± 0.05	0.4 ± 0.05	0.48 ± 0.07	0.41 ± 0.12	.21	.45

Measurements are expressed as mean ± SD.

E = entropy; ERNA = equilibrium radionuclide angiography; LV = left ventricle; RV = right ventricle; RVOT VT = right ventricular outflow tract ventricular tachycardia; S = synchrony; SDØ = standard deviation of the phase angle.

\*Comparison of between-group RV and LV values.

**Population with ARVC**

The characteristics of the 16 patients with ARVC in relation to the modified Task Force criteria are listed in Online Supplemental Table 2. All underwent ECHO, and 5 had findings that met a major criterion while 1 had a finding that met a minor criterion. A total of 13 of the 16 patients underwent CMR (the remaining 3 had a preexisting ICD), and 9 of these individuals had findings that met a major or minor criterion. The quantitative LV and RV volumes determined from CMR are listed in Online Supplemental Table 5.

ERNA synchrony analysis was completed in all 16 patients with ARVC. Figure 1 shows the left anterior oblique view of the phase images of a patient with ARVC, while Online Supplemental Figure 1 shows that of a control. Statistically significant differences in RV synchrony measures were observed relative to both the RVOT VT and the control group (Table 3). Specifically, patients with ARVC had statistically lower S and greater E than did either the RVOT VT or the control population (Table 3). The mean and SD values of RV measures SDØ, S, and E for the ARVC, RVOT VT, and control groups are presented in Figure 2. In contrast, LV phase and synchrony values in the population with ARVC were not statistically different as compared with both control and RVOT VT groups (Online Supplemental Table 4).

**ROC curve analysis**

ROC curves were generated by comparing the sensitivity of RV S and E for the diagnosis of ARVC vs RVOT VT

**Table 3** Comparison of ERNA RV phase and synchrony parameters between the ARVC, RVOT VT, and control populations

Measurement	ARVC group (n = 16)	RVOT VT group (n = 13)	P*	Control group (n = 49)	P†
SDØ	28 ± 15	17 ± 8	.019	17 ± 6	.015
S	0.91 ± 0.07	0.99 ± 0.01	.002	0.97 ± 0.02	.003
E	0.61 ± 0.10	0.46 ± 0.05	<.001	0.48 ± 0.07	.001

Measurements are expressed as mean ± SD.

ARVC = arrhythmogenic right ventricular cardiomyopathy; E = entropy; ERNA = equilibrium radionuclide angiography; LV = left ventricle; RV = right ventricle; RVOT VT = right ventricular outflow tract ventricular tachycardia; S = synchrony; SDØ = standard deviation of the phase angle.

\*Comparison of ARVC and RVOT VT groups.

†Comparison of ARVC and control groups.

(Online Supplemental Figure 2). The ROC curve of ARVC vs RVOT VT had an area under the curve of 0.9505 for S and 0.9479 for E.

**ERNA measurement reproducibility**

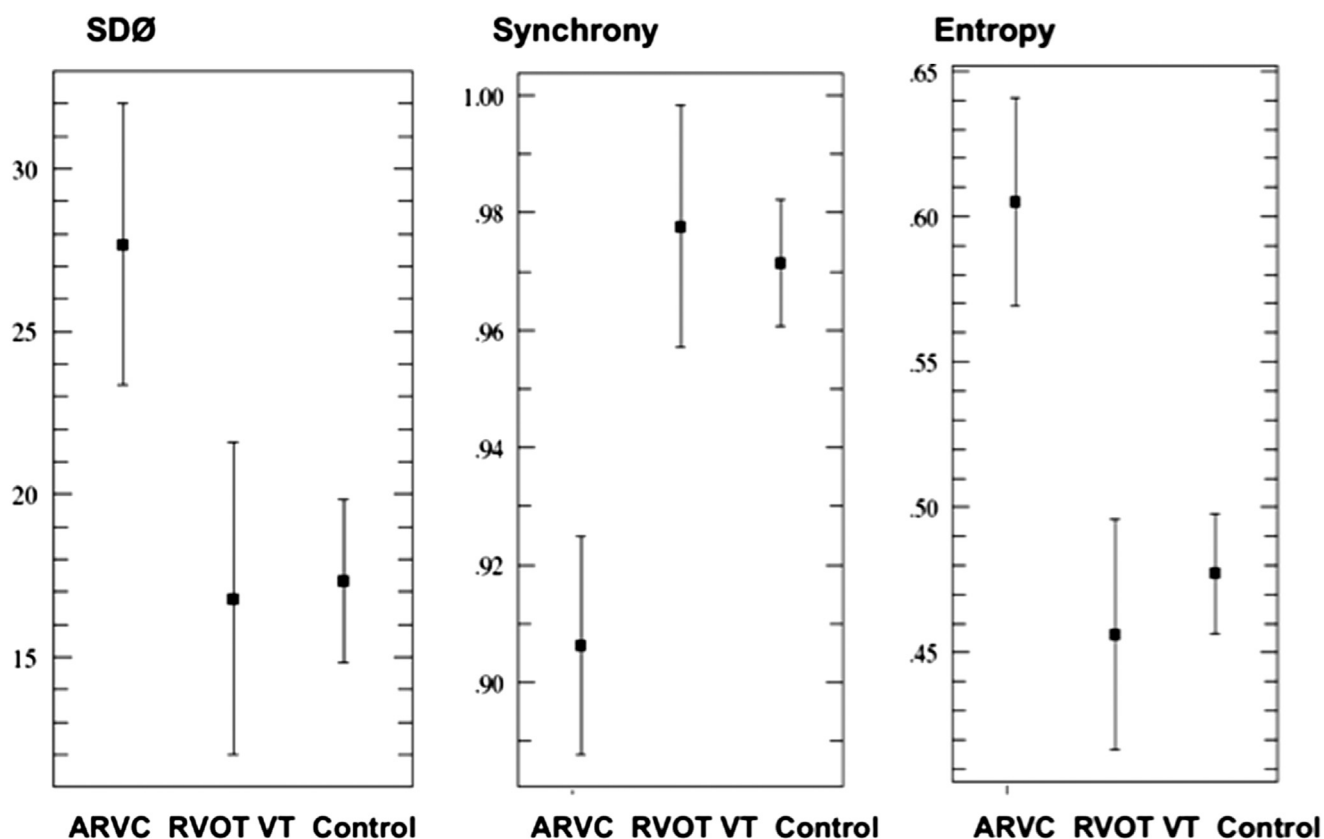
Two blinded observers measured ERNA RV synchrony parameters S and E and showed an interobserver variability of 0.8857 (P < .001) and 0.9193 (P < .001), respectively. Likewise, a blinded observer repeating the measurements showed an intraobserver RV S of 0.977 (P < .001) and RV E of 0.781 (P = .013).

**Comparison of imaging modalities**

ECHO had a sensitivity of 38% and a specificity of 100% for the diagnosis of ARVC based on the revised Task Force criteria in comparison with CMR, which had a sensitivity of 69% and a specificity of 100%. Based on the normal ERNA values determined from the control group in our study, defining a normal S as ≥0.97 and E as ≤0.47 yielded a sensitivity of 81% for ARVC diagnosis (13 of the 16 patients with ARVC) and a specificity of 89% (normal in 55 of the 62 patients without ARVC). ERNA synchrony parameters exhibited a statistically significant increase in sensitivity relative to ECHO (P = .033), but not CMR (P = .162). The specificity of ERNA (89%) was lower than that of ECHO and CMR (P = .008). If abnormal ERNA synchrony parameters were treated as a major criterion, all 16 patients would still be classified as definite cases of ERNA in the absence of ECHO and CMR findings. Treating the ERNA synchrony parameters as a minor criterion would result in 14 of the 16 cases being classified as definite.

**ERNA synchrony parameters and VT**

Twelve of 16 patients with ARVC experienced clinical VT before undergoing ERNA or during subsequent follow-up. The presence of an abnormal ERNA RV synchrony parameter (S < 0.97) was associated with a trend toward an increased odds of VT on unadjusted (odds ratio 11.0; 95% confidence interval 0.6–187.2; P = .097) and adjusted (odds ratio 7.5; 95% confidence interval 0.3–171.7; P = .206) analyses; however, the results did not reach statistical significance. Regression analysis was precluded for the ERNA RV synchrony parameter E (abnormal defined as E > 0.51) given that it was within normal limits in only 1



**Figure 2** Distribution of equilibrium radionuclide angiography right ventricular parameters among the arrhythmogenic right ventricular cardiomyopathy, right ventricular outflow tract ventricular tachycardia, and control populations. ARVC = arrhythmogenic right ventricular cardiomyopathy group; Control = control group; RVOT VT = right ventricular outflow tract ventricular tachycardia group; SDØ = standard deviation of the phase angle.

patient with ARVC. The only ARVC patient with a normal RV parameter E had no history of VT.

## Discussion

Our findings show that noninvasive assessment of RV function using ERNA synchrony parameters successfully distinguishes patients with ARVC from individuals with structurally normal hearts with high levels of sensitivity and specificity. The sensitivity of ERNA for detecting ARVC (81%) was higher than that of ECHO (38%;  $P = .033$ ) and trended toward increased sensitivity compared to CMR (69%;  $P = .305$ ). Although the specificity of ERNA (89%) was less than that of CMR and ECHO, it was still in a clinically reasonable range. These findings, coupled with additional advantages of ERNA, including its reproducibility and ability to be performed in patients with ICDs, emphasize its potential valuable role as a diagnostic test for ARVC.

Image measures of gross RV size and function suffer in their diagnostic sensitivity since these measures do not relate to the hallmark of ARVC, the patchy fibrofatty replacement of the RV myocardium.<sup>22</sup> Our findings revealed that a more detailed evaluation of the RV contraction pattern and sequence captured through ERNA measures of RV synchrony, S and E, effectively identified patients with ARVC from a cohort that also included patients with RVOT VT and controls with structurally normal hearts. The robust C

statistics observed on ROC analysis of S (0.9505) and E (0.9479) when using ERNA to distinguish ARVC from RVOT VT further serve to emphasize the diagnostic accuracy of the test.

A review of the ARVC registry data reveals inconsistent correlations among diagnostic tests in the evaluation of the RV.<sup>6-8</sup> Each of the imaging modalities currently included in the modified Task Force criteria, namely, ECHO, RV angiography, and CMR, subjectively evaluates RV regional morphological or functional changes. Owing to the subjective nature of reporting, significant differences in image interpretation have been observed, particularly among referring centers and core laboratories.<sup>22</sup> As a result, their routine use for ARVC diagnosis in general clinical practice may be problematic. In contrast, ERNA synchrony analysis is more objective with clear criteria for abnormal findings with results that have been shown to be highly reproducible by both our group and other investigators.<sup>20</sup> As a result, ERNA may be better suited for widespread application, particularly in referring centers that may not have dedicated expertise in this rare condition.

Previous work had suggested that ERNA was more sensitive than ECHO for the diagnosis of ARVC.<sup>5</sup> Our findings reinforce this notion and serve to emphasize that ERNA may be superior to ECHO for ARVC diagnosis. Of the 10 patients with ARVC classified as negative based on ECHO features delineated in the modified Task Force criteria, none

had a regional RV wall motion abnormality and only 3 had mild RV dilation on the basis of ECHO findings. In contrast, ERNA analysis identified RV dysfunction in 7 of these 10 patients, highlighting its higher sensitivity. The utility of ERNA is further bolstered by its reproducibility, which is a limitation of ECHO given the potential for significant interindividual variability in reporting on the basis of operator expertise and experience.<sup>22</sup> Furthermore, although the full analytical method applied here is new, phase image analysis is widely used and the current methodology can be easily and inexpensively implemented in current clinical systems with a simple software application.

No statistically significant differences between the ERNA synchrony parameters used in our study and CMR were observed with respect to sensitivity, though a trend toward increased sensitivity with ERNA was recorded. Although CMR serves as an effective diagnostic modality for ARVC, its role is often mitigated by the inability to perform CMR in many patients with ARVC having ICDs. In addition to limiting its use for diagnostic purposes, ERNA generally precludes the use of CMR for serial clinical evaluation of RV function. The effectiveness of ERNA compared to CMR, coupled with its ability to overcome certain limitations of CMR, further emphasizes the potential role of ERNA in the diagnostic evaluation of patients with ARVC.

Previous work had suggested that ERNA carried clinical prognostic value with respect to the risk of sudden cardiac death in patients with structurally abnormal RVs and arrhythmia. Although our results did not reach statistical significance, there was a strong trend toward an abnormal ERNA S parameter and the presence of VT in patients. The ability to predict arrhythmia risk using imaging could facilitate clinical management of affected patients, further emphasizing the potential value of ERNA as a clinical tool. These findings should be further investigated in larger cohorts of patients with ARVC.

### Study limitations

Although our findings are encouraging, our study was retrospective. Subsequent confirmation should be sought using larger prospective cohorts with a broader range of diseases. We restricted our initial study to comparator groups with RVOT VT and controls with structurally normal hearts as a first step toward validating the role of ERNA in ARVC diagnosis. We did not include patients with structural heart disease whose conditions may be mistaken for ARVC, including sarcoidosis and myocarditis. Future work will be necessary to explore these additional avenues of research. It should also be noted that the modified Task Force criteria were developed with the aim of maximizing specificity in order to avoid the potential for an excessive number of false positives.<sup>5</sup> As a result, the sensitivity of ECHO and CMR in the modified Task Force criteria is modest.<sup>6,7</sup> In order to avoid false-positive diagnoses with ERNA, it may also be necessary to have more stringent thresholds for diagnosis, which may result in both a reduced sensitivity and an

increased specificity compared to that reported in this study. Future work will be necessary to clarify optimal cutoff values for ERNA synchrony in ARVC diagnosis.

### Conclusion

ERNA synchrony analysis is a reproducible technique that analyzes new parameters that do not rely on subjective interpretation of morphological or functional changes within the ventricles. ERNA RV synchrony parameters can distinguish patients with ARVC from patients with RVOT VT and controls with structurally normal hearts, and the performance of ERNA is found to be comparable to that of ECHO and CMR. The findings from our study suggest that ERNA may be a valuable tool, complementing those already available, to provide a more accurate method for the diagnosis of ARVC.

### Appendix

#### Supplementary data

Supplementary data associated with this article can be found in the online version at <http://dx.doi.org/10.1016/j.hrthm.2015.02.033>.

### References

1. Awad MM, Calkins H, Judge DP. Mechanisms of disease: molecular genetics of arrhythmogenic right ventricular dysplasia/cardiomyopathy. *Nat Clin Pract Cardiovasc Med* 2008;5:258–267.
2. Corrado D, Basso C, Thiene G, McKenna WJ, Davies MJ, Fontaliran F, Nava A, Silvestri F, Blomstrom-Lundqvist C, Wlodarska EK, Fontaine G, Camerini F. Spectrum of clinicopathologic manifestations of arrhythmogenic right ventricular cardiomyopathy/dysplasia: a multicenter study. *J Am Coll Cardiol* 1997;30:1512–1520.
3. Corrado D, Leoni L, Link MS, et al. Implantable cardioverter-defibrillator therapy for prevention of sudden death in patients with arrhythmogenic right ventricular cardiomyopathy/dysplasia. *Circulation* 2003;108:3084–3091.
4. McKenna WJ, Thiene G, Nava A, Fontaliran F, Blomstrom-Lundqvist C, Fontaine G, Camerini F; Task Force of the Working Group. Myocardial and Pericardial Disease of the European Society of Cardiology and of the Scientific Council on Cardiomyopathies of the International Society and Federation of Cardiology. Diagnosis of arrhythmogenic right ventricular dysplasia/cardiomyopathy. *Br Heart J* 1994;71:215–218.
5. Marcus FI, McKenna WJ, Sherrill D, et al. Diagnosis of arrhythmogenic right ventricular cardiomyopathy/dysplasia: proposed modification of the Task Force criteria. *Circulation* 2010;121:1533–1541.
6. Verme E, Strohm O, Otmani A, Childs H, Duff H, Friedrich MG. Impact of the revision of arrhythmogenic right ventricular cardiomyopathy/dysplasia Task Force criteria on its prevalence by CMR criteria. *JACC Cardiovasc Imaging* 2011;4:282–287.
7. Szymański P, Klisiewicz A, Hoffman P. ARVC/D task force imaging criteria: it is difficult to get along with the guidelines. *JACC Cardiovasc Imaging* 2011;4:686.
8. Yoerger DM, Marcus F, Sherrill D, Calkins H, Towbin JA, Zareba W, Picard MH; Multidisciplinary Study of Right Ventricular Dysplasia Investigators. Echocardiographic findings in patients meeting Task Force criteria for arrhythmogenic right ventricular dysplasia: new insights from the multidisciplinary study of right ventricular dysplasia. *J Am Coll Cardiol* 2005;45:860–865.
9. Blomström-Lundqvist C, Selin K, Jonsson R, Johansson SR, Schlossman D, Olsson SB. Cardioangiographic findings in patients with arrhythmogenic right ventricular dysplasia. *Br Heart J* 1988;59:556–563.
10. Bomma C, Rutberg J, Tandri H, Nasir K, Roguin A, Tichnell C, Rodriguez R, James C, Kasper E, Spevak P, Bluemke DA, Calkins H. Misdiagnosis of arrhythmogenic right ventricular dysplasia/cardiomyopathy. *J Cardiovasc Electro-physiol* 2004;15:300–306.
11. Tandri H, Castillo E, Ferrari VA, Nasir K, Dalal D, Bomma C, Calkins H, Bluemke DA. Magnetic resonance imaging of arrhythmogenic right ventricular dysplasia: sensitivity, specificity, and observer variability of fat detection versus functional analysis of the right ventricle. *J Am Coll Cardiol* 2006;48:2277–2284.
12. Sen-Chowdhry S, Prasad SK, Syris P, Wage R, Ward D, Merrifield R, Smith GC, Firmin DN, Pennell DJ, McKenna WJ. Cardiovascular magnetic resonance in



- arrhythmogenic right ventricular cardiomyopathy revisited: comparison with Task Force criteria and genotype. *J Am Coll Cardiol* 2006;48:2132–2140.
13. Kiès P, Bootsma M, Bax J, Schalij MJ, van der Wall EE. Arrhythmogenic right ventricular dysplasia/cardiomyopathy: screening, diagnosis, and treatment. *Heart Rhythm* 2006;3:225–234.
  14. Le Guludec D, Slama MS, Frank R, Faraggi M, Grimon G, Bourguignon MH, Motte G. Evaluation of radionuclide angiography in diagnosis of arrhythmogenic right ventricular cardiomyopathy. *J Am Coll Cardiol* 1995;26:1476–1483.
  15. Casset-Senon D, Philippe L, Babuty D, Eder V, Fauchier L, Fauchier JP, Pottier JM, Cosnay P. Diagnosis of arrhythmogenic right ventricular cardiomyopathy by Fourier analysis of gated blood pool single-photon emission tomography. *Am J Cardiol* 1998;82:1399–1404.
  16. Le Guludec D, Gauthier H, Porcher R, Frank R, Daou D, Benelhadj S, Leenhardt A, Lavergne T, Faraggi M, Slama MS. Prognostic value of radionuclide angiography in patients with right ventricular arrhythmias. *Circulation* 2001;103:1972–1976.
  17. O'Connell JW, Schreck C, Moles M, Badwar N, DeMarco T, Olgin J, Lee B, Tseng Z, Kumar U, Botvinick EH. A unique method by which to quantitate synchrony with equilibrium radionuclide angiography. *J Nucl Cardiol* 2005;12:441–450.
  18. Badhwar N, Green D, O'Connell JW, Lee BK, Tseng ZH, Marcus GM, Lee RL, Rao R, DeMarco T, Olgin JE, Botvinick EH. Equilibrium radionuclide angiogram derived measures of dyssynchrony predict clinical outcomes in patients receiving cardiac resynchronization therapy. *Heart Rhythm* 2008;5:S335.
  19. Green D, O'Connell JW, Johnson C, DeMarco T, Badhwar N, Botvinick EH. Correlation of right ventricular synchrony with clinical outcomes in heart failure patients undergoing cardiac resynchronization therapy. *J Nucl Med* 2009;50:220P.
  20. Lalonde M, Birnie D, Ruddy TD, deKemp RA, Wassenaar RW. SPECT blood pool phase analysis can accurately and reproducibly quantify mechanical dyssynchrony. *J Nucl Cardiol* 2010;17:803–810.
  21. Shannon C.E. The mathematical theory of communication. 1963. MD Comput 1997;14:306–317.
  22. Marcus FI, Zareba W, Calkins H, et al. Arrhythmogenic right ventricular cardiomyopathy/dysplasia clinical presentation and diagnostic evaluation: results from the North American Multidisciplinary Study. *Heart Rhythm* 2009;6:984–992.

### CLINICAL PERSPECTIVES

Diagnosis of arrhythmogenic right ventricular cardiomyopathy (ARVC) can be challenging and is currently guided by the modified Task Force criteria, a composite of clinical, imaging, pathologic, and electrocardiographic features. Echocardiography, cardiovascular magnetic resonance, and angiography are the current imaging modalities incorporated into the modified Task Force criteria, though each has significant limitations in this context. Our group has previously developed and validated 2 parameters—synchrony and entropy—to characterize ventricular contraction patterns with equilibrium radionuclide angiography (ERNA). ERNA synchrony analysis is a reproducible technique that does not rely on subjective interpretation of morphological or functional changes within the ventricles. The present study examined the potential clinical utility of the parametric evaluation of ERNA for the diagnosis of ARVC. The results of our study revealed that ERNA synchrony parameters were capable of accurately identifying patients with ARVC from a cohort that also included individuals with right ventricular outflow tract ventricular tachycardia and controls with structurally normal hearts. Its performance characteristics, including both sensitivity and specificity, were comparable to those of echocardiography and cardiovascular magnetic resonance. The findings from our study suggest that ERNA may be a valuable tool, complementing those already available, to provide a more accurate method for the diagnosis of ARVC. Future studies using large prospective cohorts with a broader range of diseases should be pursued to validate our present findings and to provide further support for formally incorporating ERNA as an imaging modality for the diagnosis of ARVC.