

UC Davis

UC Davis Previously Published Works

Title

Spectral-Domain OCT Predictors of Visual Outcomes after Ranibizumab Treatment for Macular Edema Resulting from Retinal Vein Occlusion

Permalink

<https://escholarship.org/uc/item/9x94023x>

Journal

Ophthalmology Retina, 4(1)

ISSN

2468-6530

Authors

Yiu, Glenn

Welch, R Joel

Wang, Yinwen

et al.

Publication Date

2020

DOI

10.1016/j.oret.2019.08.009

Peer reviewed



Published in final edited form as:

Ophthalmol Retina. 2020 January ; 4(1): 67–76. doi:10.1016/j.oret.2019.08.009.

SD-OCT Predictors of Visual Outcomes after Ranibizumab Treatment for Macular Edema due to Retinal Vein Occlusion

Glenn Yiu, MD PhD¹, R. Joel Welch, MD¹, Yinwen Wang¹, Zhe Wang¹, Pin-Wen Wang, PhD², Zdenka Haskova, MD, PhD²

¹Department of Ophthalmology & Vision Science, University of California, Davis, Sacramento, CA

²Genentech, Inc. San Francisco, CA

Abstract

Objective/Purpose: To evaluate spectral domain optical coherence tomography (SD-OCT) features associated with baseline vision and visual outcomes after 7 monthly ranibizumab doses in the prospective, multicenter Study Evaluating Dosing Regimens for Treatment with Intravitreal Ranibizumab Injections in Subjects with macular Edema following Retinal Vein Occlusion (SHORE).

Design: Post-hoc analysis of prospective clinical trial data

Subjects/Participants/Controls: 202 participants in the 15-month, phase IV, SHORE study comparing monthly versus PRN (pro re nata, as-needed) ranibizumab after 7 monthly doses in eyes with retinal vein occlusions (RVO) with macular edema.

Methods/Intervention/Testing: The baseline SD-OCT images were assessed for 1) central subfield thickness (CST), 2) presence of vitreomacular adhesion, vitreomacular traction, or epiretinal membrane, 3) presence, location, and amount of intraretinal or subretinal fluid (IRF or SRF), 4) presence, location, and amount of hyperreflective foci (HF), 5) disorganization of retinal inner layers (DRIL), and 6) disruption of external limiting membrane (ELM), ellipsoid zone (EZ), and interdigitation zone (IZ). Univariate and multivariable regression analyses were performed to evaluate the association of these features with baseline BCVA and change in BCVA after 7 initial monthly ranibizumab injections.

Main Outcome Measure: Association of SD-OCT features with baseline BCVA and change in BCVA after 7 monthly ranibizumab injections.

Results: Prior to therapy, worse baseline BCVA was associated with ERM presence ($P=0.0045$), thicker SRF ($P=0.0006$), larger size of intraretinal cysts ($P=0.0015$), as well as higher % of DRIL ($P<0.0001$), % ELM disruption ($P<0.0001$), % EZ disruption ($P=0.0003$), and % IZ disruption ($P=0.0018$). In multivariate models, only % ELM disruption independently impacted baseline

Corresponding Author: Glenn Yiu, MD, PhD, Dept of Ophthalmology & Vision Science, University of California, Davis, 4860 Y Street, Suite 2400, Sacramento, CA 95817, gyiu@ucdavis.edu.

Publisher's Disclaimer: This is a PDF file of an unedited manuscript that has been accepted for publication. As a service to our customers we are providing this early version of the manuscript. The manuscript will undergo copyediting, typesetting, and review of the resulting proof before it is published in its final citable form. Please note that during the production process errors may be discovered which could affect the content, and all legal disclaimers that apply to the journal pertain.

BCVA ($P < 0.0001$). After 7 monthly ranibizumab injections, mean BCVA improved by 18.3 ± 12.6 ETDRS letters in treated eyes. The only factors independently associated with BCVA gain after 7 monthly ranibizumab treatments were younger age ($P < 0.0001$) and worse baseline BCVA ($P < 0.0001$).

Conclusion: While SD-OCT features may be associated with presenting vision in eyes with macular edema due to RVO, most eyes treated with ranibizumab experience substantial vision gains, and only older age and better baseline BCVA limited visual improvements.

Keywords

macular edema; retinal vein occlusion; SD-OCT; imaging biomarker; anatomical biomarker; visual acuity

INTRODUCTION

Macular edema is an important cause of visual impairment in patients with retinal vein occlusions (RVO), occurring in 5-15% of eyes with branch retinal vein occlusion (BRVO) and in the majority of those with central retinal vein occlusion (CRVO). Anti-vascular endothelial growth factor (anti-VEGF) pharmacotherapy is the current mainstay of therapy,¹ having demonstrated efficacy across several pivotal randomized clinical studies, although macular laser and intravitreal steroids are also used in some cases. Various demographic, clinical, and imaging factors may predict visual outcomes after treatment, such as patient age,² time to treatment initiation,^{3, 4} baseline visual acuity,^{2, 3} ischemic versus non-ischemic disease,⁵ and central subfield thickness,⁶ among others. Understanding these factors is important for guiding patient counseling and treatment strategy. However, early RVO clinical studies mostly employed time-domain optical coherence tomography (TD-OCT) images,⁶ and only recently have researchers begun evaluating potential predictive value of imaging biomarkers on high-resolution spectral-domain OCT (SD-OCT), which enables qualitative assessments including intraretinal hyperreflective foci (HF),⁷ disorganization of the retinal inner layers (DRIL),⁸⁻¹² external limiting membrane (ELM) disruption,^{13, 14} ellipsoid zone (EZ) disruption,^{14, 15} and choroidal thickness.¹⁶⁻²³ The relative predictive power of the imaging features on SD-OCT varies between studies, likely due to differences in measurement techniques, limited sample size,^{6, 7, 11, 24} selective focus on individual factors,^{7-13, 16, 17} and reliance on retrospective data with variable treatment patterns,⁷⁻¹⁶ resulting in controversy regarding the validity of these findings.^{10, 25-27}

To address these inconsistencies, we evaluated baseline SD-OCT characteristics in the prospective, phase 4, randomized, multi-center Study Evaluating Dosing Regimens for Treatment with Intravitreal Ranibizumab Injections in Subjects with Macular Edema following Retinal Vein Occlusion (SHORE) study.²⁸ During the two phase 3 clinical trials: Treatment of Macular Edema following Branch Retinal Vein Occlusion: Evaluation of Efficacy and Safety (BRAVO) and the Treatment of Macular Edema following Central Retinal Vein Occlusion: Evaluation of Efficacy and Safety (CRUISE) studies,^{29, 30} monthly treatment with 0.3mg or 0.5mg ranibizumab resulted in substantial best-corrected visual acuity (BCVA) gain at 6 months. However, mean BCVA decreased slightly between months 6 and 7, when patients switched to a pro re nata (PRN) regimen. To determine if visual

outcomes after 1 year could be further improved if patients continued to receive monthly injections after 7 initial monthly treatments, the phase 4 SHORE study was conducted.²⁸ The SHORE study evaluated 202 subjects with macular edema due to BRVO or CRVO to compare PRN versus monthly ranibizumab after a minimum of 7 monthly ranibizumab treatments. Patients were evaluated for disease stability each month starting from month 7, and were randomized to PRN or monthly regimen after they achieved a set of pre-specified BCVA/OCT criteria. Most patients achieved stability and were randomized at months 7 and 8, while those who did not meet stability criteria were not randomized and continued to receive monthly injections. At 15 months, mean BCVA improvement in Early Treatment Diabetic Retinopathy Study (ETDRS) letter score was 21.0 ± 14.1 in the PRN group ($n = 82$), 18.7 ± 14.1 in the monthly group ($n = 80$), and 14.5 ± 14.7 in eyes that did not achieve stability and were not randomized ($n = 13$), with no significant difference in visual gains between the PRN and monthly dosing groups (95% CI: -2.1 to 6.7 ETDRS letters).²⁸

In this study, we performed a comprehensive post-hoc assessment of SD-OCT images and analysis of SD-OCT features in anti-VEGF treatment-naïve eyes with macular edema due to BRVO or CRVO from the SHORE study. The SD-OCT features of interest included both qualitative and quantitative parameters characterizing vitreomacular interface abnormalities, macular fluid, HF, and inner and outer retinal layer abnormalities. We evaluated which factors may be associated with baseline visual acuity prior to treatment, and which can predict visual acuity outcomes after 7-monthly ranibizumab injections.

METHODS

Study Population

The SHORE study was a 15-month, phase 4, multicenter, randomized clinical trial to compare the efficacy and safety of monthly vs. PRN injections of 0.5mg ranibizumab in patients who had achieved BCVA and SD-OCT stability after 7 monthly injections. The study results have been previously reported.²⁸ Briefly, SHORE study enrolled patients 18 years of age or older with fovea-involving macular edema after BRVO (including hemiretinal vein occlusion, HRVO) or CRVO diagnosed within 12 months of screening, BCVA of 20/40 to 20/320 Snellen equivalent, and mean CST greater than $300 \mu\text{m}$ as measured on SD-OCT. Exclusion criteria include any prior anti-VEGF treatment, history of focal laser within 4 months, presence of an afferent pupillary defect, age-related macular degeneration more than stage 1 on the Age-Related Eye Disease Study (AREDS) severity scale, and a history of a cerebral vascular accident or myocardial infarction within 3 months on enrollment. Patients were seen monthly for examination, including BCVA measurements and SD-OCT imaging. From months 7 to 14, patients were assessed at each visit for BCVA and SD-OCT stability for randomization to monthly or PRN dosing arm. The criteria for BCVA stability were met when BCVA showed no change greater than 5 letters if BCVA was greater than 50 ETDRS letters (approximately 20/100 Snellen equivalent), greater than 10 letters if BCVA was between 35 and 50 ETDRS letters, and greater than 15 letters if BCVA was 35 ETDRS or less (approximately 20/200 Snellen equivalent). The stability criteria for SD-OCT were met if there was no disease activity, defined by absence of edema, thickening, intraretinal fluid (IRF) or cysts, or subretinal fluid (SRF) as determined by the study

investigator. After randomization, eyes in the monthly arm received a 0.5mg ranibizumab injections every month regardless of BCVA and SD-OCT status, while those in the PRN arm only received treatment if BCVA and SD-OCT stability criteria were not met. The primary endpoint was BCVA change between months 7 and 15, while secondary endpoints included the proportion of subjects who gained 15 letters or more from baseline, the proportion who lost fewer than 15 letters, the proportion of subjects with BCVA of 20/40 or better, mean BCVA change from baseline, VA change from the previous month in patients who met the VA and SD-OCT stability criteria, and proportion of subjects with IRF. The study was approved by the institutional review board at each site, and was conducted according to the International Conference on Harmonisation E6 Guideline for Good Clinical Practice. All patients provided informed consent before participation in the study.

For this post-hoc image analysis, we evaluated SD-OCT images captured at the first study visit from all enrolled subjects. Due to the variable treatment paradigm after month 7, we focused on predictors of BCVA outcomes after 7 monthly ranibizumab treatments that all subjects underwent. This post-hoc analysis followed the tenets of the Declaration of Helsinki and was approved by the Institutional Review Board at the University of California, Davis.

Image Grading

All patients in the SHORE study underwent SD-OCT imaging using the Cirrus HD-OCT device (Carl Zeiss Meditec, Dublin, CA), including 512 x 128 and 200 x 200 macular cube scans spanning a 6 x 6 mm region centered on the fovea, and 5-horizontal-line raster scans spanning 6 mm with 1024 A-scans per B-scan and 0.25 mm spacing between B-scans. Automated measurements of baseline central subfield thickness (CST) were determined by the Digital Angiography Reading Center (DARC) as part of the original study.²⁸ For evaluation of additional baseline SD-OCT biomarkers, horizontal-line raster scans from the randomization visit were analyzed by two masked, experienced OCT graders from the UC Davis Reading Center (YW, ZW) using Zeiss Cirrus Review software (version 9.5).

Image biomarkers analyzed included vitreomacular interface abnormalities such as the presence or absence of vitreomacular adhesion (VMA), vitreomacular traction (VMT), or epiretinal membrane (ERM)(Figure 1). VMA was defined as an elevation of perifoveal vitreous cortex from the retinal surface with attachment of the vitreous cortex within 3 mm of the foveal center, while VMT was defined as VMA accompanied by anatomic changes to the foveal contour, intraretinal pseudocyst formation, elevation of the fovea from the retinal pigment epithelium (RPE), or a combination of these factors, as defined by the International Vitreomacular Traction Study (IVTS) group.³¹ VMA status was considered ungradable if the posterior vitreous border could not be discerned as completely detached or completely attached.

SD-OCT images were also analyzed for the presence, location, and extent of macular fluid, including IRF and SRF (Figure 1). Eyes with IRF were graded for fluid location in the inner nuclear layer (INL) alone and/or outer plexiform / nuclear layers (OPL/ONL), based on the International Nomenclature for OCT panel consensus.³² The OPL and ONL were not separately analyzed because OCT imaging incorporates Henle's fiber layer, which is histologically part of the OPL, within the hyporeflective ONL layer.^{33, 34} The size of the

largest intraretinal cyst for each eye was also measured based on the horizontal diameter as described in previous studies of OCT biomarkers.^{35, 36} Eyes with SRF were quantified for SRF thickness based on the linear distance perpendicular to the RPE. SRF thickness was considered ungradable if signal attenuation, or “shadowing,” from overlying intraretinal fluid prevented accurate measurement of SRF thickness.

Eyes were also graded for the presence, location, and extent of vitreous or intraretinal HF (Figure 1), defined as discrete, dot-shaped lesions with similar or greater reflectivity than the RPE band, with approximate diameters of 20-40 μm to avoid the inclusion of noise.³⁷

Finally, we quantified disorganization of the retinal inner layers (DRIL), and disruption of the ELM, the inner/outer segment junction of the photoreceptors (IS/OS) or ellipsoid zone (EZ), and the cone outer-segment tips (COST) or interdigitation zone (IZ)(Figure 1). DRIL was defined as the presence of a region on the B-scan where the boundaries between the ganglion cell and inner plexiform layer complex, INL, and OPL could not be separately identified, as described by Sun et al..³⁵ ELM, EZ, and IZ disruption were measured as the percentage of discontinuity in the respective hyperreflective bands within the central 1 mm segment of the horizontal-line B-scan centered on the fovea.^{38, 39} Only areas of the outer retina in the central 1mm segment not obscured by overlying pathology were graded for layer disruption. Measurements of scale variables were averaged between the two OCT graders. Discrepancies in binary or categorical variable grading between the graders were resolved by adjudication by a senior retinal specialist grader (GY).

Statistical Analyses

Analyses were carried out in the study eye for all the intent-to-treat patients enrolled in the SHORE study (n = 202). All analyses were based on observed data without imputation for missing values. T-test was used to compare the distribution of continuous demographic characteristics or biomarkers between the BRVO versus CRVO population at baseline. Cochran-Mantel-Haenszel (CMH) χ^2 or Fisher’s exact tests were used to compare the distribution of categorical biomarkers between the BRVO versus CRVO populations, based on the anticipated proportion of subjects with the event, Fisher’s exact test was used. All statistical tests were two-sided.

Univariate linear regression analyses were used to examine the association between the biomarkers and the baseline BCVA and the BCVA change from baseline at month 7. Biomarkers with $P < 0.1$ in univariate analyses were included in a multivariate regression model. Final multivariate models were created by applying a backward selection procedure that retained only those predictors with $P < 0.05$. The final multivariate regression model was used to estimate the slope (β) and its 95% confidence intervals (CIs) to determine the association between the biomarker and BCVA endpoints. Data analyses were performed using SAS (version 9.4, SAS Inc, Cary, NC). Intergrader agreement was measured by intraclass correlation coefficients (ICC).

RESULTS

Subject Demographics

The SHORE study enrolled 202 patients with mean age of 66.3 years, 58.4% male, and mostly non-Hispanic, white subjects (Table 1). Mean baseline BCVA letter score was 56.2 ± 11.7 ETDRS letters in BRVO patients and 49.6 ± 14.0 ETDRS letters in CRVO patients ($P = 0.0004$). Mean CST at baseline was 472.6 ± 118.0 μm in BRVO patients and 597.4 ± 185.5 μm in CRVO patients ($P < 0.0001$). Among all enrolled subjects, 171 met VA and OCT stability criteria on or after month 7 and were randomized to monthly ($n = 85$) or PRN injections ($n = 86$), 12 exited the study before month 7, and 19 patients reached month 7 but did not meet stability criteria for randomization.

SD-OCT Biomarkers in SHORE Study

On baseline SD-OCT, mean CST was 472.6 ± 118.0 μm in those with BRVO and 597.4 ± 185.5 μm in eyes with CRVO ($P < 0.0001$; Table 1). Over 40% of the eyes had VMA, while many were ungradable and likely represented a complete posterior vitreous detachment (PVD) where the posterior hyaloid was not visualized on the OCT image. No eyes had signs of VMT, and 17% had an ERM. Almost all eyes demonstrated IRF, most located in both the INL and OPL/ONL, while 65% of eyes also showed SRF (Table 2). Mean diameter of the largest intraretinal cyst was 343.0 ± 150.0 μm , and mean SRF thickness was 170.9 ± 109.7 μm . Vitreous HF were rarely seen, but most demonstrated at least one intraretinal HF, with mean 5.4 ± 7.4 HF identified per eye (Table 2). Mean extent of DRIL was $70 \pm 32\%$, while mean disruption of the outer retinal layers ranged from 55 to 75% (Table 2). Overall, eyes with macular edema from CRVO showed greater intraretinal cyst size ($P < 0.0001$), greater likelihood of SRF ($P = 0.0064$), and more ELM disruption ($P = 0.0266$). Interrater reliability was extremely high (>0.9) across all scale measures, with the exception of HF, which were between 0.69-0.80 (Supplemental Table 1).

SD-OCT Predictors of Visual Acuity Before and After Ranibizumab

In univariate analyses of SD-OCT features associated with baseline vision, CST, presence of an ERM, size of intraretinal cysts, SRF thickness, DRIL extent, and disruption of outer retinal layers were all associated with poorer baseline visual acuity (Table 3). In multivariate models, however, only % ELM disruption was independently associated with vision before treatment ($P < 0.0001$) (Table 3).

After ranibizumab treatment, mean BCVA improved by 18.3 ± 12.6 ETDRS letters in the 188 eyes that reached month 7 of the study. In univariate analyses, BCVA gains between baseline and month 7 were associated with younger age, male sex, lower baseline BCVA, as well as ERM absence, greater SRF thickness, intraretinal HF presence, and greater DRIL extent (Table 4). Multivariate regression, however, showed that the only factors independently associated with BCVA gains after 7 monthly ranibizumab treatments were younger age ($P < 0.0001$) and lower baseline BCVA ($P < 0.0001$) (Table 4).

SD-OCT Predictors of Visual Acuity in CRVO vs. BRVO:

To determine if imaging features play a more important role in certain RVO subtypes, we evaluated the association of these SD-OCT biomarkers with baseline BCVA and 7-month BCVA outcomes in SHORE study patients with BRVO versus CRVO. At baseline, while ELM disruption was also associated with worse baseline BCVA in eyes with BRVO ($P=0.0007$), none of the imaging biomarkers were independently associated with presenting vision in eyes with CRVO on multivariate regression (Supplemental Table 2), possibly due to the ischemia and poorer baseline vision in these patients. After 7 monthly ranibizumab treatments, only age, sex, and baseline BCVA impacted visual gains in eyes with BRVO, while only age and sex affected visual outcomes in CRVO (Supplemental Table 3). None of the imaging biomarkers had an independent association with visual outcomes after 7 monthly ranibizumab injections in both CRVO and BRVO.

DISCUSSION

Anti-VEGF therapies have enhanced the management of exudative macular conditions, but it was the concurrent development of OCT imaging that has revolutionized our current treatment paradigm. By providing objective, qualitative and quantitative measures such as CST to monitor the anatomic response to treatment, OCT provides rapid visual feedback to help guide clinicians' treatment strategies. However, the relationship between retinal anatomy and visual function is complex, with poor correlation between BCVA and CST often noted across different retinal conditions including macular edema due to RVO.⁴⁰ Even more uncertain is the potential of OCT biomarkers to *predict* visual outcomes after treatment. In the SCORE 2 study comparing monthly aflibercept with bevacizumab for RVO-related macular edema, baseline CST was associated with 6-month BCVA outcomes on univariate regression, but only patient age and baseline BCVA were found to independently predict treatment response in multivariate models.²

The evolution of OCT technology from TD-OCT to higher-resolution SD-OCT has provided researchers and clinicians a variety of imaging features to evaluate as potential predictive biomarkers of visual outcomes after treatment of macular edema following RVO. Mimouni and colleagues correlated DRIL and ELM disruption with baseline visual acuity in 136 eyes, but only DRIL predicted visual outcomes after 8 months of bevacizumab therapy.⁹ Change in DRIL also predicted treatment response in patients receiving other types of anti-VEGF therapy for CRVO.^{8, 11, 12} Moon et al. focused on eyes with refractory BRVO-related macular edema, and noted a higher prevalence of ELM disruption compared with eyes that were responsive to therapy.¹³ Other groups have also implicated choroidal thickness as a predictor of visual outcomes in RVO.^{16, 17} However, many of these studies were retrospective chart reviews, with varying inclusion criteria and different treatment patterns between patients. Methodologies for image analysis also differed between studies, with many that only assessed the presence or absence of certain biomarkers as binary variables,^{8, 13} selectively focused on certain imaging biomarkers factors^{7-13, 16, 17} or failed to include clinical factors such as age, sex, and baseline BCVA in multivariate analyses.⁹⁻¹¹

In this study, we aimed to address these limitations by performing a comprehensive analysis of SD-OCT biomarkers in 202 patients with macular edema due to RVO who underwent 7

monthly ranibizumab injections in a large, prospective Phase IV clinical trial. We found that only ELM disruption was independently associated with baseline BCVA prior to treatment, while none of the SD-OCT features we evaluated predicted visual gains after 7 monthly ranibizumab treatments. The only factors limiting visual gains after ranibizumab therapy were older age and better baseline BCVA. Although the SHORE study was not designed or powered to assess the predictive power of SD-OCT features, our sample size of 202 eyes can detect a correlation coefficient (r) as low as 0.196, suggesting adequate power to determine even a weak relationship between BCVA outcomes and each SD-OCT biomarker. Our results suggest that while outer retinal morphology may help explain the extent of vision loss in RVO-related macular edema prior to treatment, these imaging biomarkers do not predict treatment outcomes, and most eyes undergo substantial visual gains after ranibizumab therapy regardless of these baseline SD-OCT features. We also noted that the associations were driven mostly by eyes with BRVO, and that SD-OCT features were more strongly associated with vision in BRVO than CRVO. We hypothesize that this is likely due to the greater likelihood of ischemia and poorer baseline vision in eyes with CRVO, and further reduces the predictive value of imaging biomarkers in this subgroup.

There are several important strengths of our study that may explain the discrepancy with prior reports supporting the role of DRIL or outer retinal layer integrity in predicting visual outcomes after anti-VEGF therapy.^{8, 9, 11–14} First, we analyzed a large cohort of RVO patients in a prospective clinical trial with well-defined inclusion/exclusion criteria, strict treatment regimen and follow-up schedule, and standardized protocols for SD-OCT imaging and visual acuity measurements. Also, rather than focusing on specific biomarkers or choosing arbitrary cut-offs to create categorical variables, we aimed at an unbiased, comprehensive analysis of major SD-OCT biomarkers, using standardized definitions and grading protocols consistent with published literature.^{31, 32} Although we employed manual grading of most features, intergrader reproducibility measures were mostly >0.9 , with the exception of HF which is a less precisely-defined feature and may be prone to inclusion of noise artifacts. Use of automated image analysis or machine learning algorithms may provide more objective support and help strengthen these findings in the future. Our study was limited by the use of only baseline SD-OCT images, in contrast to other studies that assessed changes in imaging biomarkers over time.^{8, 9} Also, we focused on only a single horizontal-line B-scan, rather than more robust topographic mapping of OCT features outside the central region.¹⁵ The goal of our study was to identify simple, clear predictors of visual outcomes using single SD-OCT B-scans which are commonly used in real-world clinical practice, and could be more easily adapted to guide the medical management of RVO with macular edema. Finally, our study did not incorporate other imaging modalities such as fluorescein angiography (FA) or OCT angiography (OCT-A), as SD-OCT biomarkers may have more predictive power, for example, if eyes with foveal ischemia and limited visual potential were excluded. However, the FA images in SHORE were not of enough quality to conclude the exact area of ischemia in at least one-third of data, and OCT-A was not obtained on study patients. Future studies employing multimodal imaging may improve the predictive power of SD-OCT biomarkers.

In summary, we found that while some SD-OCT features were associated with presenting vision in eyes with RVO and macular edema, they are poor at predicting visual gains after 7

monthly ranibizumab treatments. Newer OCT technologies has revealed novel imaging biomarkers that have the potential to improve treatment response stratification and guide medical management. However, differences in image analysis methodology, selective focus on individual biomarkers, and reliance on retrospective clinical data have resulted in inconsistent and sometimes diverging conclusions about the validity of their predictive power. Caution should be taken when making treatment decisions based on biomarkers that are not thoroughly validated. Greater focus on prospective clinical trial data, and more comprehensive multivariate analyses of imaging biomarkers will be necessary to take advantage of both the diagnostic and prognostic capabilities of SD-OCT imaging.

Supplementary Material

Refer to Web version on PubMed Central for supplementary material.

Acknowledgments

Financial Support: Dr. Yiu is supported by NIH K08 EY026101, E. Matilda Ziegler Foundation for the Blind, Barr Foundation for Retinal Research, Alcon Research Institute, ARVO Foundation, CITRIS/Banatao Institute, and Macula Society.

Disclosures: Dr. Yiu received grant support from Alcon, Clearside Biomedical, Genentech, and Iridex; and personal fees for consultancy from Alimera, Allergan, Carl Zeiss Meditec, Genentech, and Iridex.

REFERENCES

1. Todorich B, Yiu G, Hahn P. Current and investigational pharmacotherapeutic approaches for modulating retinal angiogenesis. *Expert Rev Clin Pharmacol* 2014;7(3):375–91. [PubMed: 24580084]
2. Scott IU, VanVeldhuisen PC, Ip MS, et al. Baseline Factors Associated With 6-Month Visual Acuity and Retinal Thickness Outcomes in Patients With Macular Edema Secondary to Central Retinal Vein Occlusion or Hemiretinal Vein Occlusion: SCORE2 Study Report 4. *JAMA Ophthalmol* 2017;135(6):639–49. [PubMed: 28492860]
3. Larsen M, Waldstein SM, Boscia F, et al. Individualized Ranibizumab Regimen Driven by Stabilization Criteria for Central Retinal Vein Occlusion: Twelve-Month Results of the CRYSTAL Study. *Ophthalmology* 2016;123(5):1101–11. [PubMed: 26896124]
4. Tadayoni R, Waldstein SM, Boscia F, et al. Sustained Benefits of Ranibizumab with or without Laser in Branch Retinal Vein Occlusion: 24-Month Results of the BRIGHTER Study. *Ophthalmology* 2017;124(12):1778–87. [PubMed: 28807635]
5. Calugaru D, Calugaru M. Intravitreal bevacizumab in acute central/hemicentral retinal vein occlusions: three-year results of a prospective clinical study. *J Ocul Pharmacol Ther* 2015;31(2):78–86. [PubMed: 25313921]
6. Ach T, Hoeh AE, Schaal KB, et al. Predictive factors for changes in macular edema in intravitreal bevacizumab therapy of retinal vein occlusion. *Graefes Arch Clin Exp Ophthalmol* 2010;248(2):155–9. [PubMed: 19763601]
7. Mo B, Zhou HY, Jiao X, Zhang F. Evaluation of hyperreflective foci as a prognostic factor of visual outcome in retinal vein occlusion. *Int J Ophthalmol* 2017;10(4):605–12. [PubMed: 28503435]
8. Babiuch AS, Han M, Conti FF, et al. Association of Disorganization of Retinal Inner Layers With Visual Acuity Response to Anti-Vascular Endothelial Growth Factor Therapy for Macular Edema Secondary to Retinal Vein Occlusion. *JAMA Ophthalmol* 2018.
9. Mimouni M, Segev O, Dori D, et al. Disorganization of the Retinal Inner Layers as a Predictor of Visual Acuity in Eyes With Macular Edema Secondary to Vein Occlusion. *Am J Ophthalmol* 2017;182:160–7. [PubMed: 28837790]

10. Eldeeb M, Chan EW, Sun V, Chen JC. Disorganization of the Retinal Inner Layers as a Predictor of Visual Acuity in Eyes With Macular Edema Secondary to Vein Occlusion. *Am J Ophthalmol* 2018;186:167–8. [PubMed: 29233533]
11. Berry D, Thomas AS, Fekrat S, Grewal DS. Association of Disorganization of Retinal Inner Layers with Ischemic Index and Visual Acuity in Central Retinal Vein Occlusion. *Ophthalmol Retina* 2018;2(11):1125–32. [PubMed: 30511035]
12. Chan EW, Eldeeb M, Sun V, et al. Disorganization of Retinal Inner Layers and Ellipsoid Zone Disruption Predict Visual Outcomes in Central Retinal Vein Occlusion. *Ophthalmol Retina* 2019;3(1):83–92. [PubMed: 30929820]
13. Moon BG, Cho AR, Kim YN, Kim JG. Predictors of Refractory Macular Edema after Branch Retinal Vein Occlusion Following Intravitreal Bevacizumab. *Retina* 2018;38(6):1166–74. [PubMed: 28489696]
14. Chatziralli I, Theodossiadis G, Chatzirallis A, et al. RANIBIZUMAB FOR RETINAL VEIN OCCLUSION: Predictive Factors and Long-Term Outcomes in Real-Life Data. *Retina* 2018;38(3):559–68. [PubMed: 28248827]
15. Banaee T, Singh RP, Champ K, et al. Ellipsoid Zone Mapping Parameters In Retinal Venous Occlusive Disease With Associated Macular Edema. *Ophthalmol Retina* 2018;2(8):836–41. [PubMed: 30221215]
16. Rayess N, Rahimy E, Ying GS, et al. Baseline Choroidal Thickness as a Predictor for Treatment Outcomes in Central Retinal Vein Occlusion. *Am J Ophthalmol* 2016;171:47–52. [PubMed: 27567889]
17. Okamoto M, Yamashita M, Sakamoto T, Ogata N. Choroidal Blood Flow and Thickness as Predictors for Response to Anti-Vascular Endothelial Growth Factor Therapy in Macular Edema Secondary to Branch Retinal Vein Occlusion. *Retina* 2017.
18. Vuong VS, Moisseiev E, Cunefare D, et al. Repeatability of Choroidal Thickness Measurements on Enhanced Depth Imaging Optical Coherence Tomography Using Different Posterior Boundaries. *Am J Ophthalmol* 2016;169:104–12. [PubMed: 27345731]
19. Willoughby AS, Vuong VS, Cunefare D, et al. Choroidal Changes After Suprachoroidal Injection of Triamcinolone Acetonide in Eyes With Macular Edema Secondary to Retinal Vein Occlusion. *Am J Ophthalmol* 2018;186:144–51. [PubMed: 29199012]
20. Wong SS, Vuong VS, Cunefare D, et al. Macular Fluid Reduces Reproducibility of Choroidal Thickness Measurements on Enhanced Depth Optical Coherence Tomography. *Am J Ophthalmol* 2017;184:108–14. [PubMed: 29038011]
21. Yiu G, Chiu SJ, Petrou PA, et al. Relationship of central choroidal thickness with age-related macular degeneration status. *Am J Ophthalmol* 2015;159(4):617–26. [PubMed: 25526948]
22. Yiu G, Manjunath V, Chiu SJ, et al. Effect of anti-vascular endothelial growth factor therapy on choroidal thickness in diabetic macular edema. *Am J Ophthalmol* 2014;158(4):745–51 e2. [PubMed: 24952275]
23. Yiu G, Pecun P, Sarin N, et al. Characterization of the choroid-scleral junction and suprachoroidal layer in healthy individuals on enhanced-depth imaging optical coherence tomography. *JAMA Ophthalmol* 2014;132(2):174–81. [PubMed: 24336985]
24. Wolf-Schnurrbusch UE, Ghanem R, Rothenbuehler SP, et al. Predictors of short-term visual outcome after anti-VEGF therapy of macular edema due to central retinal vein occlusion. *Invest Ophthalmol Vis Sci* 2011;52(6):3334–7. [PubMed: 21087958]
25. Calugaru D, Calugaru M. Re Berry et al.: Association of Disorganization of Retinal Inner Layers with Ischemic Index and Visual Acuity in Central Retinal Vein Occlusion (*Ophthalmol Retina*. 2018;2:1125-1132). *Ophthalmol Retina* 2019;3(1):e1. [PubMed: 30929821]
26. Schmidt-Erfurth U, Michl M. Disorganization of Retinal Inner Layers and the Importance of Setting Boundaries. *JAMA Ophthalmol* 2019;137(1):46–7. [PubMed: 30286233]
27. Calugaru D, Calugaru M. Disorganization of the Retinal Inner Layers as a Predictor of Visual Acuity in Eyes With Macular Edema Secondary to Vein Occlusion. *Am J Ophthalmol* 2017;184:190–1. [PubMed: 29025680]

28. Campochiaro PA, Wykoff CC, Singer M, et al. Monthly versus as-needed ranibizumab injections in patients with retinal vein occlusion: the SHORE study. *Ophthalmology* 2014;121(12):2432–42. [PubMed: 25060610]
29. Brown DM, Campochiaro PA, Singh RP, et al. Ranibizumab for macular edema following central retinal vein occlusion: six-month primary end point results of a phase III study. *Ophthalmology* 2010;117(6):1124–33 e1. [PubMed: 20381871]
30. Campochiaro PA, Heier JS, Feiner L, et al. Ranibizumab for macular edema following branch retinal vein occlusion: six-month primary end point results of a phase III study. *Ophthalmology* 2010;117(6):1102–12 e1. [PubMed: 20398941]
31. Duker JS, Kaiser PK, Binder S, et al. The International Vitreomacular Traction Study Group classification of vitreomacular adhesion, traction, and macular hole. *Ophthalmology* 2013;120(12):2611–9. [PubMed: 24053995]
32. Staurenghi G, Sadda S, Chakravarthy U, et al. Proposed lexicon for anatomic landmarks in normal posterior segment spectral-domain optical coherence tomography: the IN*OCT consensus. *Ophthalmology* 2014;121(8):1572–8. [PubMed: 24755005]
33. Lujan BJ, Roorda A, Knighton RW, Carroll J. Revealing Henle’s fiber layer using spectral domain optical coherence tomography. *Invest Ophthalmol Vis Sci* 2011;52(3):1486–92. [PubMed: 21071737]
34. Yiu G, Wang Z, Munevar C, et al. Comparison of chorioretinal layers in rhesus macaques using spectral-domain optical coherence tomography and high-resolution histological sections. *Exp Eye Res* 2018;168:69–76. [PubMed: 29352993]
35. Sun JK, Lin MM, Lammer J, et al. Disorganization of the retinal inner layers as a predictor of visual acuity in eyes with center-involved diabetic macular edema. *JAMA Ophthalmol* 2014;132(11):1309–16. [PubMed: 25058813]
36. Luu KY, Koenigsaecker T, Yazdanyar A, et al. Long-term natural history of idiopathic epiretinal membranes with good visual acuity. *Eye (Lond)* 2019;33(5):714–23. [PubMed: 31000833]
37. Lee H, Ji B, Chung H, Kim HC. Correlation between Optical Coherence Tomographic Hyperreflective Foci and Visual Outcomes after Anti-Vegf Treatment in Neovascular Age-Related Macular Degeneration and Polypoidal Choroidal Vasculopathy. *Retina* 2016;36(3):465–75. [PubMed: 26076214]
38. Chen X, Zhang L, Sohn EH, et al. Quantification of external limiting membrane disruption caused by diabetic macular edema from SD-OCT. *Invest Ophthalmol Vis Sci* 2012;53(13):8042–8. [PubMed: 23111607]
39. Coscas F, Coscas G, Lupidi M, et al. Restoration of Outer Retinal Layers After Aflibercept Therapy in Exudative AMD: Prognostic Value. *Invest Ophthalmol Vis Sci* 2015;56(6):4129–34. [PubMed: 26114491]
40. Ou WC, Brown DM, Payne JF, Wykoff CC. Relationship Between Visual Acuity and Retinal Thickness During Anti-Vascular Endothelial Growth Factor Therapy for Retinal Diseases. *Am J Ophthalmol* 2017;180:8–17. [PubMed: 28549848]

In the prospective SHORE study of RVO and macular edema, the only SD-OCT feature associated with baseline vision was ELM disruption, and no imaging biomarkers were independently associated with visual gains after monthly ranibizumab treatments.

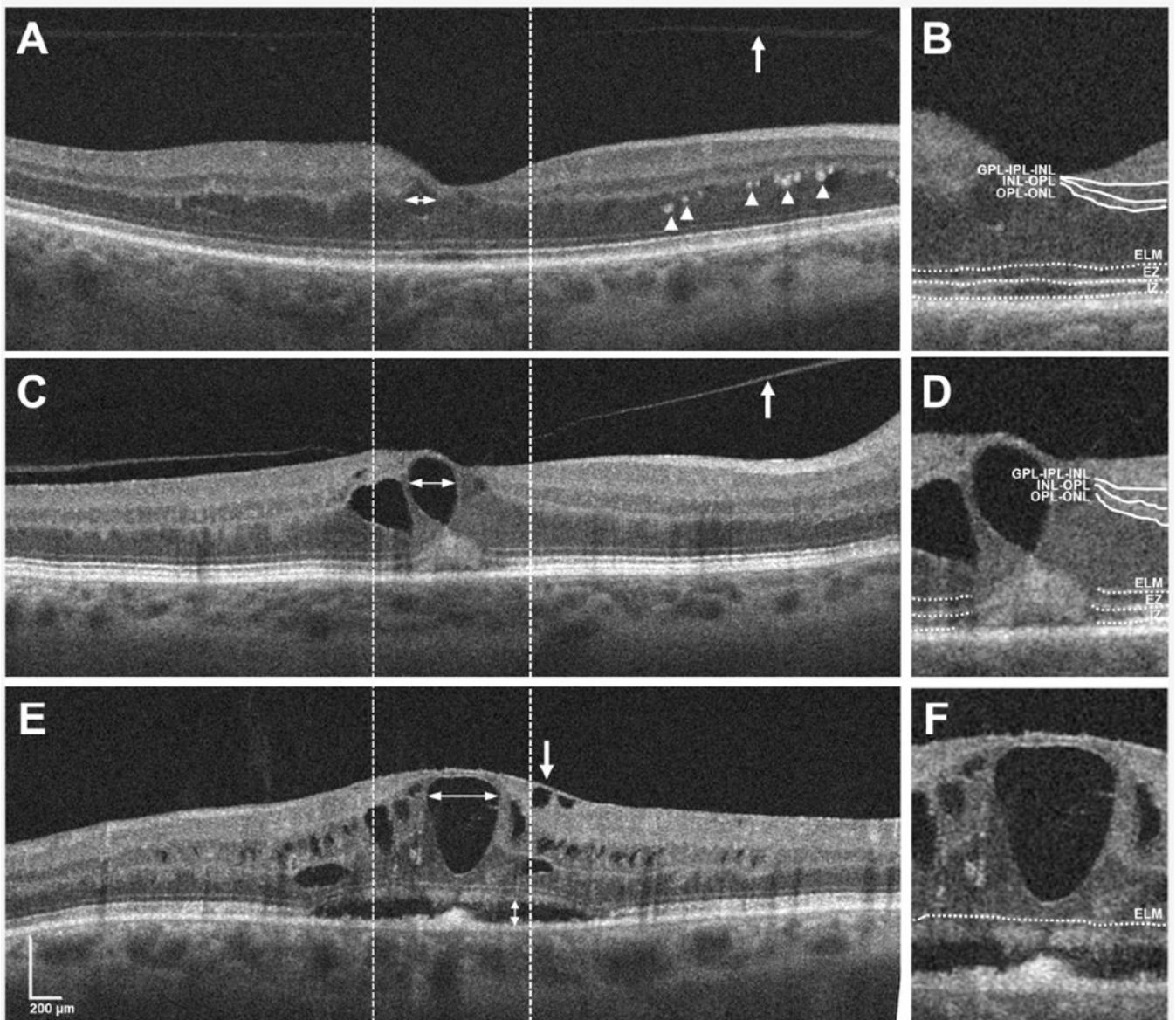


Figure 1. SD-OCT features in eyes with macular edema from RVO in the SHORE study
 SD-OCT horizontal line B-scans through the fovea of 3 patients with RVO in the SHORE study (A, C, E), demonstrating the presence of a posterior vitreous detachment (PVD)(A, arrow), vitreomacular adhesion (VMA)(B, arrow), epiretinal membrane (ERM)(C, arrow), presence and amount of intraretinal fluid (IRF) measured using the horizontal diameter of the largest cyst (A,C,E, horizontal double-arrow), presence and amount of subretinal fluid (SRF) measured by vertical height (E, vertical double-arrow), and presence and number of vitreous or intraretinal hyperreflective foci (HF)(A, arrowheads). Magnified view of the central 1mm region delineated by dashed lines in A,C,E (B,D,F) shows measurement of disorganization of the retinal inner layers (DRIL) defined as loss of distinction between the ganglion cell and inner plexiform layer complex (GCL-IPL), inner nuclear layer (INL), and

outer plexiform layer (OPL), and % disruption of the external limiting membrane (ELM), ellipsoid zone (EZ), and interdigitation zone (IZ). Scale bars 200 μ m.

Author Manuscript

Author Manuscript

Author Manuscript

Author Manuscript

Table 1.

Study demographics of SHORE participants.

	All SHORE subjects (N=202)	Subjects with BRVO/ HRVO (N=115)	Subjects with CRVO (N=87)	P-value*
Age (mean ± SD), years	66.3 ± 12.4	66.6 ± 12.7	65.8 ± 12.1	0.6548
Sex , n (%)				
Male	118 (58.4)	59 (51.3)	59 (67.8)	0.0184
Ethnicity , n (%)				0.1032
Hispanic or Latino	16 (7.9)	6 (5.2)	10 (11.5)	
Not Hispanic or Latino	183 (90.6)	106 (92.2)	77 (88.5)	
Race , n (%)				0.7425
Asian	6 (3.0)	4 (3.5)	2 (2.3)	
Black or African American	25 (12.4)	16 (13.9)	9 (10.3)	
Native Hawaiian / Other / Pacific Islander	2 (1.0)	1 (0.9)	1 (1.2)	
White	159 (78.7)	90 (78.3)	69 (79.3)	
Baseline BCVA (mean ± SD), ETDRS letters	53.4 ± 13.1	56.2 ± 11.7	49.6 ± 14.0	0.0004*
Baseline CST (mean ± SD), μm	526.4 ± 162.7	472.6 ± 118.0	597.4 ± 185.5	<0.0001*

* $P < 0.05$, statistically-significant

Abbreviations: BCVA, best-corrected visual acuity; BRVO, branch retinal vein occlusion; CST, central subfield thickness; ETDRS, Early Treatment Diabetic Retinopathy Study; HRVO, hemicentral retinal vein occlusion; CRVO, central retinal vein occlusion; SD, standard deviation

Author Manuscript

Author Manuscript

Author Manuscript

Author Manuscript

Table 2.

Summary of SD-OCT Biomarkers in the SHORE Study

	All SHORE subjects (N=202)	Subjects with BRVO/ HRVO (N=115)	Subjects with CRVO (N=87)	P-value*
Vitreomacular interface				
VMA (present / absent / ungradable), n	85 / 12 / 105	45 / 7 / 63	40 / 5 / 42	0.6173
VMT (present / absent), n	0 / 202	0 / 115	0 / 87	-
ERM (present / absent), n	34 / 168	15 / 100	19 / 68	0.0980
Macular fluid				
IRF (present / absent), n	200 / 2	114 / 1	86 / 1	1.0000
IRF location (INL / OPL-ONL / both), n	3 / 33 / 164	3 / 22 / 89	0 / 11 / 75	0.1721
Intraretinal cyst size (mean ± SD), μm	343.0 ± 150.0	303.6 ± 91.6	395.1 ± 191.5	<0.0001*
SRF (present / absent / ungradable), n	131 / 66 / 5	71 / 44 / 0	60 / 22 / 5	0.0064*
SRF thickness (mean ± SD), μm	170.9 ± 109.7	161.8 ± 103.0	181.7 ± 117.2	0.3045
Hyperreflective foci				
Vitreous HF (present / absent), n	15 / 187	5 / 110	10 / 77	0.0551
Vitreous HF (mean ± SD), n	0.2 ± 1.1	0.2 ± 0.9	0.4 ± 1.3	0.2280
Intraretinal HF (present / absent), n	121 / 81	65 / 50	56 / 31	0.2599
Intraretinal HF (mean ± SD), n	5.4 (7.4)	5.4 (8.4)	5.3 (5.7)	0.8724
Retinal layer disruption				
DRIL (mean ± SD), %	70.2 ± 32.0	68.2 ± 31.8	73.0 ± 32.3	0.2973
ELM disruption (mean ± SD), %	55.2 ± 45.1	48.8 ± 45.1	65.3 ± 43.6	0.0266*
IS/OS(EZ) disruption (mean ± SD), %	65.9 ± 42.4	61.9 ± 42.9	72.2 ± 41.4	0.1450
COST(IZ) disruption (mean ± SD), %	75.0 ± 39.1	70.8 ± 41.0	81.7 ± 35.3	0.0902

*p<0.05, statistically-significant

Abbreviations: BRVO, branch retinal vein occlusion; HRVO, hemicentral retinal vein occlusion; CRVO, central retinal vein occlusion; CST, central subfield thickness; COST(IZ): cone outer segment tips (interdigitation zone); DRIL, disorganization of the retinal inner layers; ELM, external limiting membrane; ERM, epiretinal membrane; HF, hyperreflective foci; IRF, intraretinal fluid; IS/OS(EZ): photoreceptor inner/outer segment junction (ellipsoid zone); SD, standard deviation; SRF, subretinal fluid; VMA, vitreomacular adhesion; VMT vitreomacular traction

Table 3.

SD-OCT Biomarkers associated with baseline BCVA in RVO

SD-OCT Biomarker	Category or Increment	β estimate (95% CI)	P-value
Univariate Regression			
Age	10-year increase	-0.09 (-1.56, 1.38)	0.9029
Sex	female vs. male	2.78 (-0.90, 6.46)	0.1375
CST	50 μ m increase	-1.01 (-1.55, -0.47)	0.0003*
Vitreomacular interface			
VMA presence	present vs. absent	1.74 (-6.92, 10.40)	0.6914
VMT presence	present vs. absent	---	---
ERM presence	present vs. absent	-6.96 (-11.74, -2.19)	0.0045*
Macular fluid			
IRF presence	present vs. absent	---	---
IRF location	OPL-ONL vs. INL	-6.21 (-21.86, 9.44)	0.4347
	both vs. INL	-8.54 (-23.66, 6.58)	0.2667
Intraretinal cyst size	50 μ m increase	-0.98 (-1.58, -0.38)	0.0015*
SRF presence	present vs. absent	1.63 (-2.21, 5.47)	0.4035
SRF thickness	50 μ m increase	-1.69(-2.63, -0.74)	0.0006*
Hyperreflective foci			
Vitreous HF presence	present vs. absent	-0.96 (-7.91, 6.00)	0.7866
Vitreous HF amount	5 HF increase	-2.78 (-11.08, 5.52)	0.5095
Intraretinal HF presence	present vs. absent	-1.82 (-5.54, 1.89)	0.3334
Intraretinal HF amount	5 HF increase	-0.72 (-1.95, 0.52)	0.2544
Retinal layer disruption			
DRIL	10% increase	-1.12 (-1.67, -0.56)	<0.0001*
ELM disruption	10% increase	-0.91 (-1.28, -0.54)	<0.0001*
IS/OS(EZ) disruption	10% increase	-0.76 (-1.17, -0.35)	0.0003*
COST(IZ) disruption	10% increase	-0.72 (-1.17, -0.27)	0.0018*
Multivariate regression			
ELM disruption, %	10% increase	-0.91 (-1.28, -0.54)	<0.0001*

* $P < 0.1$ for univariate regressions; $P < 0.05$ for multivariate regression

Abbreviations: CST, central subfield thickness; COST(IZ): cone outer segment tips (interdigitation zone); DRIL, disorganization of the retinal inner layers; ELM, external limiting membrane; ERM, epiretinal membrane; HF, hyperreflective foci; IRF, intraretinal fluid; IS/OS(EZ): photoreceptor inner/outer segment junction (ellipsoid zone); SRF, subretinal fluid; VMA, vitreomacular adhesion; VMT vitreomacular traction

Table 4.

SD-OCT Biomarkers associated with BCVA change at Month 7 in RVO

SD-OCT Biomarker	Category or Increment	β estimate (95% CI)	P-value
Univariate Regression			
Age	10-year increase	-2.92(-4.33,-1.53)	<0.0001 *
Sex	female vs. male	-6.77 (-10.30,-3.24)	0.0002 *
Baseline BCVA	5 letter increase	-1.42 (-2.09,-0.76)	<0.0001 *
CST	50 μ m increase	0.42 (-0.14, 0.98)	0.1411
Vitreomacular interface			
VMA presence	present vs. absent	2.19 (-5.46, 9.84)	0.5704
VMT presence	present vs. absent	---	---
ERM presence	present vs. absent	-4.61 (-9.52, 0.30)	0.0657 *
Macular fluid			
IRF presence	present vs. absent	---	N/A
IRF location	OPL/ONL vs. INL	1.70 (-13.43, 16.83)	0.8248
	both vs. INL	1.66 (-12.90,16.23)	0.8219
Intraretinal cyst size	50 μ m increase	0.13(-0.47, 0.73)	0.6632
SRF presence	present vs. absent	1.81 (-2.14, 5.76)	0.3664
SRF thickness	50 μ m increase	1.19(0.31, 2.07)	0.0087 *
Hyperreflective foci			
Vitreous HF presence	present vs. absent	3.10 (-4.04,10.23)	0.3931
Vitreous HF amount	5 HF increase	4.83 (-4.38, 14.03)	0.3024
Intraretinal HF presence	present vs. absent	3.09 (-0.59, 6.77)	0.0990 *
Intraretinal HF amount	5 HF increase	0.88 (-0.33, 2.09)	0.1513
Retinal layer disruption			
DRIL	10% increase	0.57(0.001, 1.13)	0.0495 *
ELM disruption	10% increase	0.07 (-0.37, 0.51)	0.7485
IS/OS(EZ) disruption	10% increase	0.22 (-0.25, 0.69)	0.3542
COST(IZ) disruption	10% increase	0.06 (-0.44, 0.56)	0.8028
Multivariate regression			
Age	10-year increase	-2.88 (-4.22, -1.55)	<0.0001 *
Baseline BCVA	5 letter increase	-1.40 (-2.04,-0.77)	<0.0001 *

* $P < 0.1$ for univariate regressions; $P < 0.05$ for multivariate regression

Abbreviations: BCVA, best-corrected visual acuity; CST, central subfield thickness; COST(IZ): cone outer segment tips (interdigitation zone); DRIL, disorganization of the retinal inner layers; ELM, external limiting membrane; ERM, epiretinal membrane; HF, hyperreflective foci; IRF, intraretinal fluid; IS/OS(EZ): photoreceptor inner/outer segment junction (ellipsoid zone); SRF, subretinal fluid; VMA, vitreomacular adhesion; VMT vitreomacular traction