

# UCSF

## UC San Francisco Previously Published Works

### Title

A case series of very slow atrioventricular nodal reentrant tachycardia resembling junctional tachycardia

### Permalink

<https://escholarship.org/uc/item/9zf9p54g>

### Journal

Journal of Cardiovascular Electrophysiology, 33(6)

### ISSN

1045-3873

### Authors

Higuchi, Koji  
Higuchi, Satoshi  
Baranowski, Bryan  
et al.

### Publication Date

2022-06-01

### DOI

10.1111/jce.15465

Peer reviewed

# A case series of very slow atrioventricular nodal reentrant tachycardia resembling junctional tachycardia

Koji Higuchi MD<sup>1</sup>  | Satoshi Higuchi MD<sup>2</sup> | Bryan Baranowski MD<sup>1</sup> |  
Oussama Wazni MD, FHRS<sup>1</sup> | Melvin M. Scheinman MD, FHRS<sup>2</sup> |  
Patrick Tchou MD, FHRS<sup>1</sup> 

<sup>1</sup>Robert and Suzanne Tomsich Department of Cardiovascular Medicine, Section of Cardiac Electrophysiology and Pacing, Sydell and Arnold Miller Family Heart and Vascular Institute, Cleveland Clinic, Cleveland, Ohio, USA

<sup>2</sup>Division of Cardiology, Section of Cardiac Electrophysiology, University of California San Francisco, San Francisco, California, USA

## Correspondence

Patrick Tchou, MD, FHRS, Robert and Suzanne Tomsich Department of Cardiovascular Medicine, Section of Cardiac Electrophysiology and Pacing, Sydell and Arnold Miller Family Heart and Vascular Institute, Cleveland Clinic, Desk J2-2, 9500 Euclid Ave, Cleveland, OH 44195, USA.  
Email: TCHOUP@ccf.org

**Disclosures:** None

## Abstract

**Introduction:** The surface electrocardiography of typical atrioventricular nodal reentrant tachycardia (AVNRT) shows simultaneous ventricular-atrial (RP) activation with pseudo R' in V1 and typical heart rates ranging from 150 to 220/min. Slower rates are suspicious for junctional tachycardia (JT). However, occasionally we encounter typical AVNRT with slow ventricular rates. We describe a series of typical AVNRT cases with heart rates under 110/min.

**Methods:** A total of 1972 patients with AVNRT who underwent slow pathway ablation were analyzed. Typical AVNRT was diagnosed when; (1) evidence of dual atrioventricular nodal conduction, (2) tachycardia initiation by atrial drive train with atrial-His-atrial response, (3) short septal ventriculoatrial time, and (4) ventricular-atrial-ventricular (V-A-V) response to ventricular overdrive (VOD) pacing with corrected post pacing interval-tachycardia cycle length (cPPI-TCL) > 110 ms. JT was excluded by either termination or advancement of tachycardia by atrial extrastimuli (AES) or atrial overdrive (AOD) pacing.

**Results:** We found 11 patients (age 20–78 years old, six female) who met the above-mentioned criteria. The TCL ranged from 560 to 782 ms. Except for one patient showing tachycardia termination, all patients demonstrated a V-A-V response and cPPI-TCL over 110 ms with VOD. AES or AOD pacing successfully excluded JT by either advancing the tachycardia in 10 patients or by tachycardia termination in one patient. Slow pathway was successfully ablated, and tachycardia was not inducible in all patients.

**Conclusions:** This case series describes patients with typical AVNRT with slow ventricular rate (less than 110/min) who may mimic JT. We emphasize the importance of using pacing maneuvers to exclude JT.

## KEYWORDS

junctional tachycardia, slow ventricular rate, typical AVNRT

**Abbreviations:** AES, atrial extrastimulus; AH, atrial-His; AOD, atrial overdrive pacing; AV, atrioventricular; AVNRT, atrioventricular nodal reentrant tachycardia; EPS, electrophysiological study; HV, His-ventricular; JT, junctional tachycardia; PPI, post pacing interval; TCL, tachycardia cycle length; VOD, ventricular overdrive pacing.

This is an open access article under the terms of the Creative Commons Attribution-NonCommercial-NoDerivs License, which permits use and distribution in any medium, provided the original work is properly cited, the use is non-commercial and no modifications or adaptations are made.

© 2022 The Authors. *Journal of Cardiovascular Electrophysiology* published by Wiley Periodicals LLC.

## 1 | INTRODUCTION

Dual atrioventricular (AV) nodal physiology is a common finding during an electrophysiologic study. This finding, first reported in human studies in the 1970s, provides a substrate for the common form of atrioventricular nodal reentrant tachycardia (AVNRT).<sup>1</sup> The typical form of AVNRT (slow-fast type) shows a short R-P or a simultaneous R-P during tachycardia with heart rates usually ranging from 150/min to 220/min.<sup>2</sup> Pseudo R' in V1 is a common feature. However, if the heart rate during tachycardia is relatively slow, junctional tachycardia (JT) or accelerated junctional rhythm emerges as part of the differential diagnosis. Notably, while catheter ablation of AVNRT has been reported with a very high success rate and low incidence of heart block,<sup>2</sup> catheter ablation of JT has a lower success rate and higher rates of complete heart block, and ablation of accelerated junctional rhythm can be even more problematic. Therefore, during the electrophysiological study, using maneuvers such as atrial overdrive pacing (AOD) and atrial extrastimulus (AES)<sup>3</sup> to differentiate AVNRT and JT is essential.

In this study, we reported a series of patients with slow, symptomatic typical AVNRT below 110 bpm resembling JT or accelerated junctional rhythms, which were successfully diagnosed and ablated.

## 2 | METHODS

### 2.1 | Study population

We retrospectively analyzed 1972 patients (1569 patients from Cleveland Clinic, 403 patients from the University of California, San Francisco) who underwent catheter ablation of AVNRT ablation between January 2013 to September 2021.

### 2.2 | Electrophysiologic study

After giving informed written consent, patients underwent electrophysiologic studies (EPS). AOD and extrastimulus were delivered to induce supraventricular tachycardia. Isoproterenol infusion was used to facilitate sustained tachycardia if needed. To demonstrate that the mechanism of this tachycardia is the typical slow-fast AVNRT, not automaticity (i.e., JT) or ventricular dependent reentry, AOD, AES, or ventricular overdrive (VOD) pacing were delivered during tachycardia. AVNRT was diagnosed using criteria as follows according to previous reports<sup>1,4-6</sup>: (1) evidence of dual AV nodal physiology, (2) tachycardia initiation by atrial drive train with A-H-A response, (3) short septal ventriculoatrial (VA) time (see Table), and (4) ventricular-atrial-ventricular (V-A-V) response to VOD pacing with corrected post pacing interval minus tachycardia cycle length (cPPI-TCL) > 110 ms. (5) Demonstration that both the slow pathway (SP) and fast pathway (FP) are capable of conducting faster than the TCL during entrainment. (6) During atrial entrainment via the SP, atrial septal

PPI-TCL is less than 50 ms. (7) Advancement or termination of the tachycardia via block in the SP was demonstrated by AES.<sup>3</sup> These maneuvers also serve to exclude concealed nodoventricular or nodofascicular pathways. Data obtained from the EPS are listed in the table.

### 2.3 | Catheter ablation

Catheter ablation was performed with a 4 mm tip nonirrigated radiofrequency ablation catheter or a 3.5 mm saline cooled catheter. For temperature-controlled delivery, power was titrated from 30 to 50 W with a temperature limit of 50–60° for a duration of 60–90 s to achieve accelerated junctional beats with intact AV and VA conduction. For the saline cooled catheter, power was initiated at 20–25 W and titrated up to 35 W while monitoring accelerated junctional beats. Ablation endpoints were lack of inducibility of AVNRT and no more than single slow-fast AV nodal echo beats with programmed stimulation in either the basal state or during isoproterenol infusion.<sup>6</sup>

## 3 | RESULTS

We identified five patients from Cleveland Clinic and six patients from the University of California, San Francisco, who had very slow (110 bpm or less) typical AVNRT. Three additional patients were excluded because they did not undergo AOD or AES pacing maneuvers as noted in the Section 2, although tachycardia was no longer inducible after their SP ablation. Therefore, a total of 11 patients were included in this analysis. Patient characteristics and electrophysiologic study data are shown in Table 1. Ages ranged from 20 to 78 years. There were six females and five males. One patient was undergoing a fourth ablation (Case 4), and two patients had their second ablations (Case 7 and 9). All other patients were undergoing their initial ablation. The tachycardia cycle length ranged from 560 to 782 ms. Septal VA times were all short and averaged  $31.9 \pm 22.6$  ms. All patients except for one demonstrated V-A-V response by VOD, and showed a corrected PPI-TCL well over 110 ms. VOD reproducibly terminated tachycardia in one patient (Case 8), and thus VOD entrainment could not be successfully performed.

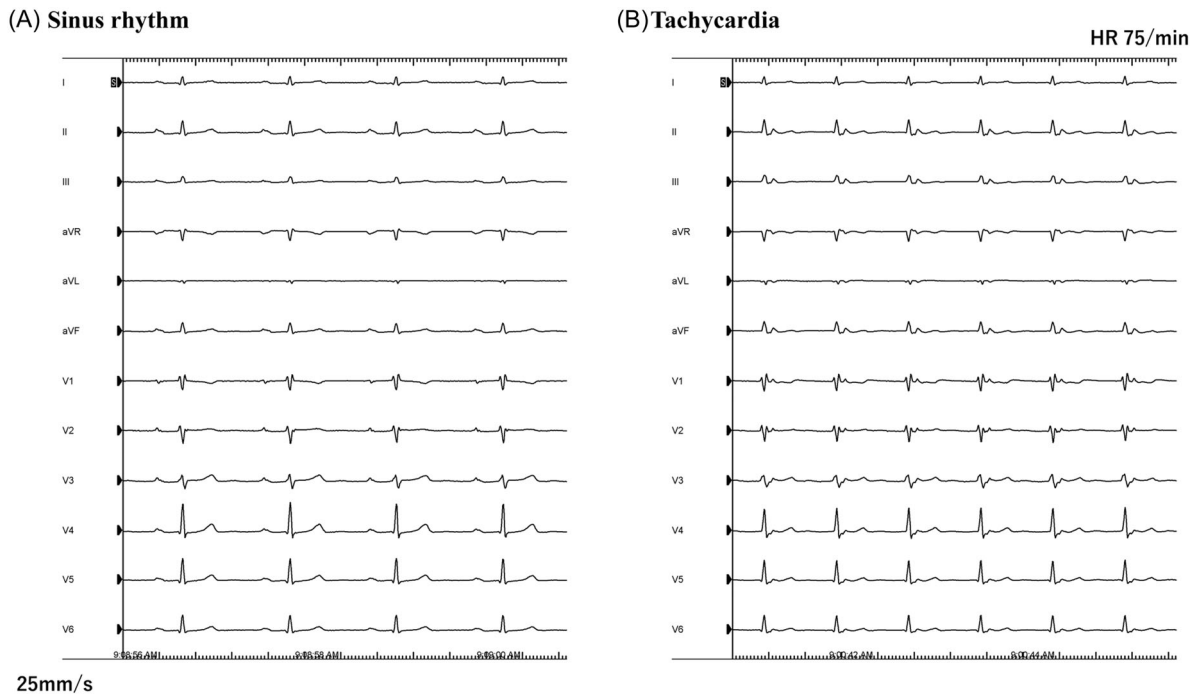
We delivered AOD or AES to distinguish this tachycardia from JT. Advancement of the tachycardia was recognized by overdrive pacing from at least one location of the atrium (usually from the coronary sinus ostium) in five patients. Termination of tachycardia was recognized in one patient by overdrive atrial pacing (Case 4). With regard to the response to AES, six patients showed an A-H-A response, while one patient (Case 1) showed atrial-His-His-atrial response with the advancement of the tachycardia, likely due to a double ventricular response.<sup>3</sup>

All patients underwent successful ablation targeting the SP region rendering their tachycardia not inducible after ablation.

**TABLE 1** Clinical and electrophysiologic characteristics

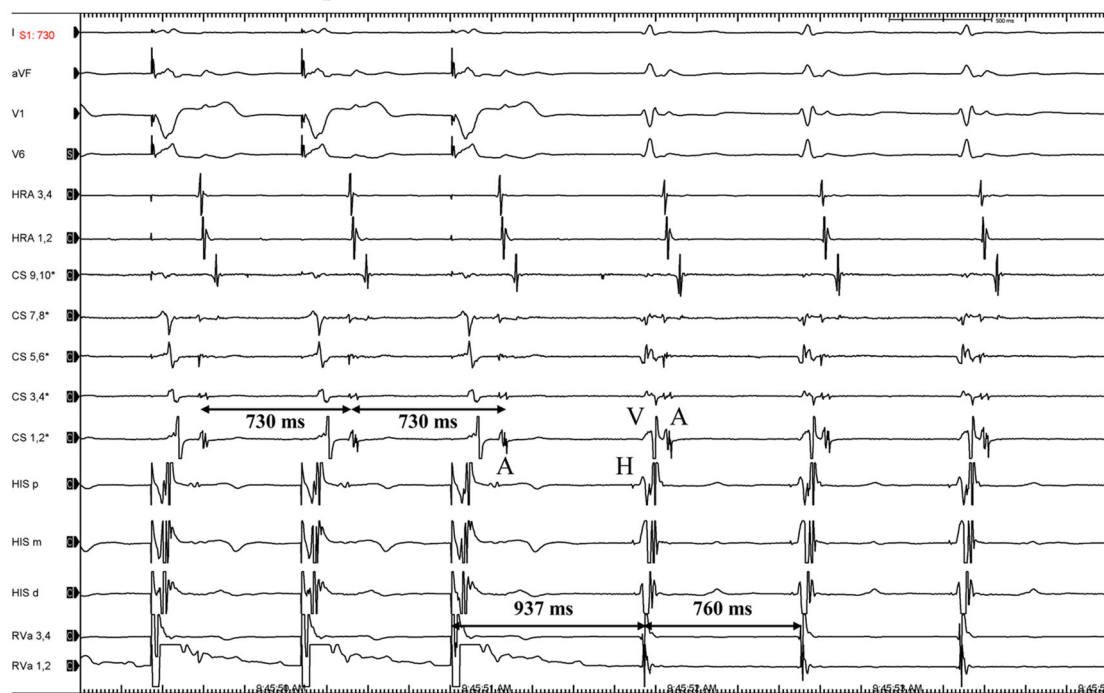
Case no	Institutions	Age	Gender	Times of SVT ablation	VA during SVT (ms)			TCL (ms)	QRS intervals during tachycardia (ms)			RP' sequence	FP ERP (ms)	Longest AH interval (ms)	Response to VOD	corrected		AES response	DVR
					HSA	VA	SVT		HA	AH	SVT					QRS morphology	PPI-TCL (ms)		
1	CCF	53	F	1	560	0	50	510	80	Narrow	A on V	500/340	603	V-A-V	145	127	Advancement	A-H-H-A (because of the DVR)	1
2	CCF	64	M	1	725	61	163	562	95	Narrow	Short RP'	700/620	868	V-A-V	142	213	Advancement	No attempt	0
3	CCF	74	M	1	660	0	69	591	97	Narrow	A on V	600/560	868	V-A-V	205	125	Advancement	No attempt	0
4	CCF	61	F	4	782	59	144	638	88	Narrow	Short RP'	800/600	960	V-A-V	190	110	Termination	A-H-A	0
5	CCF	69	M	1	629	54	99	530	144	RBBB	Short RP'	800/400	832	V-A-V	259	261	Advancement	No attempt	0
6	UCSF	78	M	1	611	33	78	533	131	RBBB	A on V	800/370	533	V-A-V	156	121	No attempt	A-H-A	0
7	UCSF	43	F	2	566	18	50	516	84	Narrow	A on V	600/390	516	V-A-V	135	142	No attempt	A-H-A	0
8	UCSF	20	F	1	596	11	56	540	74	Narrow	A on V	800/460	540	Termination	NA	NA	Advancement	A-H-A	0
9	UCSF	57	F	2	738	28	71	667	73	Narrow	A on V	800/370	731	V-A-V	162	135	Advancement	A-H-A	0
10	UCSF	40	M	1	607	50	87	520	74	Narrow	A on V	600/370	588	V-A-V	174	139	No attempt	A-H-A	0
11	UCSF	64	F	1	581	37	91	480	78	Narrow	A on V	600/410	528	V-A-V	166	116	Advancement	A-H-A	0

Abbreviations: AES, atrial extrastimulus; AH, atrial-His; AOD, atrial overdrive; CCF, Cleveland Clinic Foundation; DVR, double ventricular response; ERP, effective refractory period; FP, fast pathway; HA, His-atrial; PPI-TCL, post pacing interval minus tachycardia cycle length; RBBB, right bundle branch block; SA-VA, ventricular stimulus to atrial interval minus ventricular atrial interval during tachycardia; SVT, supraventricular tachycardia; TCL, tachycardia cycle length; UCSF, University of California San Francisco; V-A-V, ventricular-atrial-ventricular; VOD, ventricular overdrive.



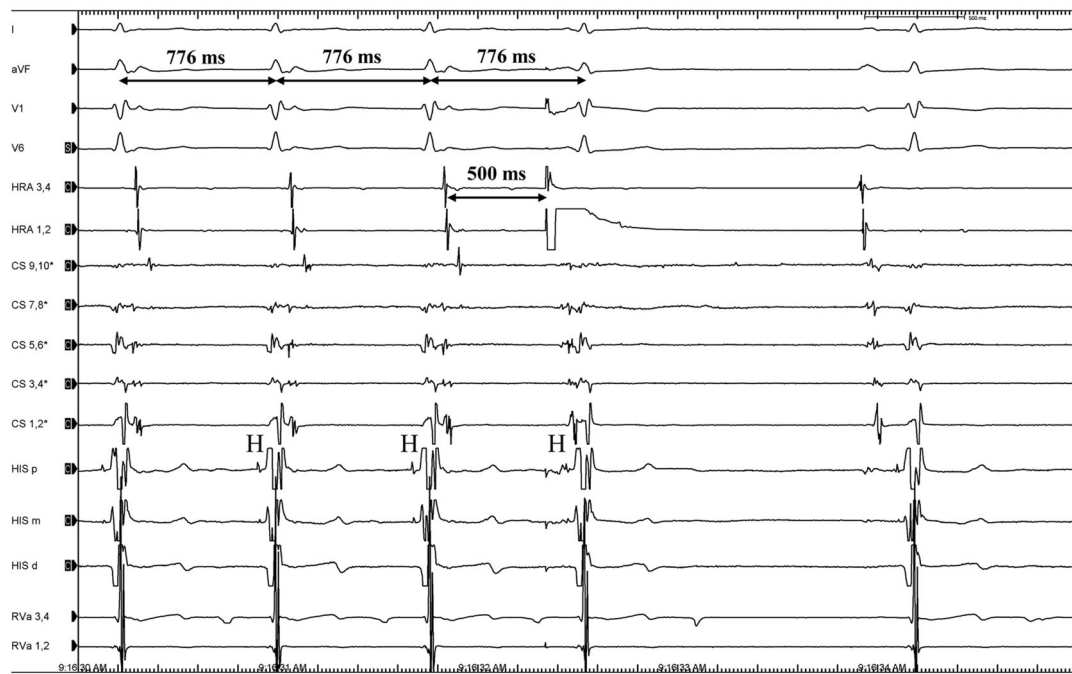
**FIGURE 1** Sinus rhythm and tachycardia electrocardiography (ECG). (A) Twelve-lead surface ECG of sinus rhythm. Note the prolonged PR interval of 290 ms consistent with poor or lack of anterograde conduction via the fast pathway. This likely explains the incessant nature of this patient's frequent tachycardia. (B) Twelve-lead surface ECG of the slow tachycardia. Pseudo R' can be recognized in V1. Time lines for both panels are 400 ms per large division

#### VOD from RVA with V-A-V response



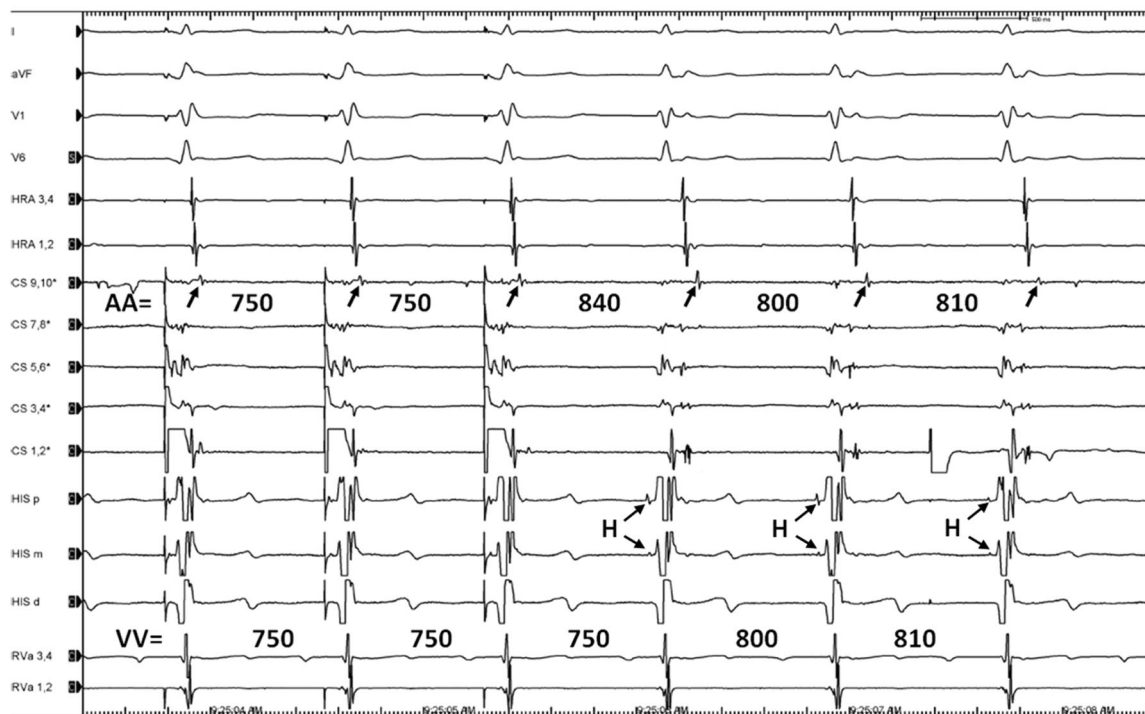
**FIGURE 2** Response during ventricular overdrive pacing. Overdrive pacing from right ventricular apex (RVa 1–2) during tachycardia resulted in a post pacing V-A-V response and a long corrected PPI-TCL of 162 ms. This maneuver excludes a ventricular nodal/Hisian mechanism. It also demonstrates that the retrograde fast pathway is capable of conducting faster than the TCL. Intracardiac electrograms as follows: CS, coronary sinus; HIS, His bundle; HRA, high right atrium; PPI-TCL, post pacing interval minus tachycardia cycle length; RVa, right ventricular apex; V-A-V, ventricular-atrial-ventricular; VOD, ventricular overdrive

**AES delivered during retrograde fast pathway conduction terminated the tachycardia**



**FIGURE 3** Atrial extrastimulus during tachycardia. AES delivered at the high right atrium (HRA 1–2) after His onset activating the septal regions during retrograde fast pathway conduction (i.e., collision with the retrograde fast pathway impulse) caused block in the slow pathway terminating the tachycardia. This termination demonstrates that the slow pathway is a part of the reentrant circuit. AES, atrial extrastimuli; CS, coronary sinus; HRA, high right atrium

**AOD from CS 1-2 advanced the tachycardia with A-H-A response**



**FIGURE 4** Atrial overdrive pacing from CS 1–2 advanced the tachycardia with an A-H-A response. Pacing was initiated after the slow pathway refractory so that it anterogradely captured and advanced the tachycardia via the slow pathway. Note that the PPI at the proximal CS electrograms (CS 9, 10) as a proxy for septal activation had a PPI-TCL of 30 or 40 ms depending on how one measures the TCL. This value confirmed that the atrial septum near the tricuspid annulus was part of the reentrant circuit. CS, coronary sinus; PPI-TCL, post pacing interval minus tachycardia cycle length

### 3.1 | Patient example (Case 4)

Figure 1 shows electrocardiography (ECGs) during sinus (A) and reentrant arrhythmia (B) of a patient example (Case 4) who underwent three SP ablations before the current study. This patient had been in this incessant arrhythmia shown in panel B after the third ablation. The surface ECG showed a very slow junctional type arrhythmia (HR 75/min), and the patient was significantly symptomatic when in this arrhythmia. The patient was treated as having a junctional arrhythmia, and beta-blocker therapy was prescribed, which did not improve her symptom. Due to the inefficacy of this treatment, the patient was referred for further possible ablation. Intracardiac studies showed simultaneous VA activation with septal VA timing of 59 ms. VOD showed V-A-V response with PPI-TCL 177 ms (Figure 2). AES delivered 10 ms after His onset (on time with retrograde FP depolarization) terminated the tachycardia with block in the SP, which proved that SP conduction was part of the tachycardia mechanism (Figure 3). AOD delivered from CS 1–2 successfully entrained the tachycardia. The septal PPI-TCL confirmed a reentrant mechanism (Figure 4). After the successful SP ablation, this tachycardia was not inducible, and the patient became asymptomatic.

## 4 | DISCUSSION

The typical form of AVNRT uses the SP as the anterograde limb and the FP as the retrograde limb with perinodal atrial tissue bridging the fast to the SPs. The ECG of typical AVNRT shows a short R-P or simultaneous R-P during tachycardia with pseudo R' in V1. While the usual heart rates of typical AVNRT during tachycardia ranges from 150/min to 220/min, some patients present with slow AVNRT if the conduction time of the SP is long and its effective refractory period is short (compared to FP). Modification of SP conduction during ablation may also result in such long AH intervals generating an exceedingly slow AVNRT.

In this setting, it is important to differentiate JT from AVNRT as the surface ECG and the internal electrograms of both arrhythmias may be quite similar. In these tachycardias, a patient may have significant symptoms even with the slow heart rate given the simultaneous atrial and ventricular activations, which generate atrial contraction during mitral and tricuspid valves closure resulting in palpitation, heart pounding, fatigue, or poor exercise tolerance. Such slow AVNRT may be mistakenly treated as a slow JT leading to drug therapies that are ineffective or

ablation approaches that are associated with higher risks. Thus, what may appear as a junctional rhythm may well be a slow AVNRT which can readily and safely be addressed with ablation. Only an EP study would provide a definitive answer.

## 5 | CONCLUSION

We report a case series of patients with slow typical AVNRT (less than 110/min), which may mimic JT. Comprehensive EPS are necessary to exclude JT and direct appropriate ablation treatment.

### ACKNOWLEDGMENTS

This study did not receive any specific grant from funding agencies in the public, commercial, or not-for-profit sectors.

### ORCID

Koji Higuchi  <http://orcid.org/0000-0002-9218-1966>

Patrick Tchou  <http://orcid.org/0000-0002-3983-3515>

### REFERENCES

1. Denes P, Wu D, Dhingra RC, Chuquimia R, Rosen KM. Demonstration of dual A-V nodal pathways in patients with paroxysmal supraventricular tachycardia. *Circulation*. 1973;48(3):549-555.
2. Jackman WM, Beckman KJ, McClelland JH, et al. Treatment of supraventricular tachycardia due to atrioventricular nodal reentry by radiofrequency catheter ablation of slow-pathway conduction. *N Engl J Med*. 1992;327(5):313-318.
3. Gilge JL, Bagga S, Ahmed AS, et al. Mechanism and interpretation of two-for-one response to premature atrial complexes during atrioventricular node re-entry tachycardia. *Europace*. 2021;23(4):634-639.
4. Katritsis DG, Camm AJ. Atrioventricular nodal reentrant tachycardia. *Circulation*. 2010;122(8):831-840.
5. Katritsis DG, Josephson ME. Differential diagnosis of regular, narrow-QRS tachycardias. *Heart Rhythm*. 2015;12(7):1667-1676.
6. Katritsis DG, Zografos T, Siontis KC, et al. Endpoints for successful slow pathway catheter ablation in typical and atypical atrioventricular nodal re-entrant tachycardia: a contemporary, multicenter study. *JACC Clin Electrophysiol*. 2019;5(1):113-119.

**How to cite this article:** Higuchi K, Higuchi S, Baranowski B, Wazni O, Scheinman MM, Tchou P. A case series of very slow atrioventricular nodal reentrant tachycardia resembling junctional tachycardia. *J Cardiovasc Electrophysiol*. 2022;33:1177-1182. doi:10.1111/jce.15465