

UC Davis

Dermatology Online Journal

Title

A case of pachydermodactyly in a seventeen year old associated with repetitive minor trauma

Permalink

<https://escholarship.org/uc/item/9zw0w33v>

Journal

Dermatology Online Journal, 22(8)

Authors

Abdelrahman, W
Walsh, MY
Smyth, A
et al.

Publication Date

2016

DOI

10.5070/D3228032187

Copyright Information

Copyright 2016 by the author(s). This work is made available under the terms of a Creative Commons Attribution-NonCommercial-NoDerivatives License, available at <https://creativecommons.org/licenses/by-nc-nd/4.0/>

Peer reviewed

Letter

A case of pachydermodactyly in a seventeen year old associated with repetitive minor trauma

W Abdelrahman¹, MY Walsh², A Smyth³, D Alderdice⁴

Dermatology Online Journal 22 (8): 15

¹Department of Dermatology, Royal Victoria Hospital, Belfast, Northern Ireland

²Department of Pathology, Royal Victoria Hospital, Belfast, Northern Ireland

³Department of Rheumatology, Ulster Hospital, Belfast, Northern Ireland

⁴ Department of Dermatology, Ulster Hospital, Belfast, Northern Ireland

Correspondence:

Dr Wedad Abdelrahman

Department of Dermatology, Royal Victoria Hospital, Belfast, Northern Ireland, UK BT12 6BA

Tel. 07927532773 Fax. 028 9031 2906

Email: wedadabdelrahman@doctors.org.uk

Abstract

A boy presented initially to a Rheumatology clinic with a three year history of asymptomatic swelling of the third to fourth proximal interphalangeal (PIP) joints bilaterally. A presumptive diagnosis of seronegative arthritis was made. Sulfasalazine was commenced without improvement and resulted in mood disturbance. Blood tests including ESR, lupus anticoagulant, rheumatoid factor and CCP antibodies were unremarkable. Hand radiographs were normal. MRI showed oedema within soft tissues around PIP joints. His care was transferred to the Rheumatology unit in our hospital and the rheumatological diagnosis was revised; sulfasalazine was stopped and skin biopsy organised. Onward referral to Dermatology was made. Examination revealed symmetrical swelling and thickening of soft tissues on PIP joints with no evidence of joint synovitis. He denied habitual behaviour but was noted to rub his fingers subconsciously. With this as a cause of repetitive minor trauma, a clinical diagnosis of *pachydermodactyly* was made. Skin biopsy was supportive showing a dermis with coarse collagen. Pachydermodactyly is rare. This case highlights the importance of prompt recognition to avoid invasive and excessive diagnostic procedures as well as unnecessary immunosuppression.

Keywords: *Pachydermodactyly*; swelling proximal interphalangeal joints; digital fibromatosis; repetitive trauma

Introduction

Pachydermodactyly (PDD) is a rare condition of localised fibromatosis presenting as symmetrical painless swelling of the tissues surrounding the proximal interphalangeal (PIP) joints of both hands. It is not known to many Rheumatologists, yet is an important diagnosis which should be considered in the differential of juvenile idiopathic arthritis or rheumatoid arthritis.

Case synopsis

A seventeen year old school boy presented initially to a Rheumatology clinic with a three year history of asymptomatic swelling of the III-IV PIP joints bilaterally. He denied any preceding trauma. A presumptive diagnosis of seronegative arthritis was made, although there was no diurnal variation to symptoms or benefit from oral steroids. Sulfasalazine was subsequently commenced without any improvement and resulted in profound mood disturbance. Blood tests including rheumatoid factor, CCP antibodies, ANA, ESR, CRP were unremarkable. Hand radiographs demonstrated no bone or joint

destruction; magnetic resonance imaging (MRI) showed oedema within the soft tissues particularly around the PIP joints (Figure 1).

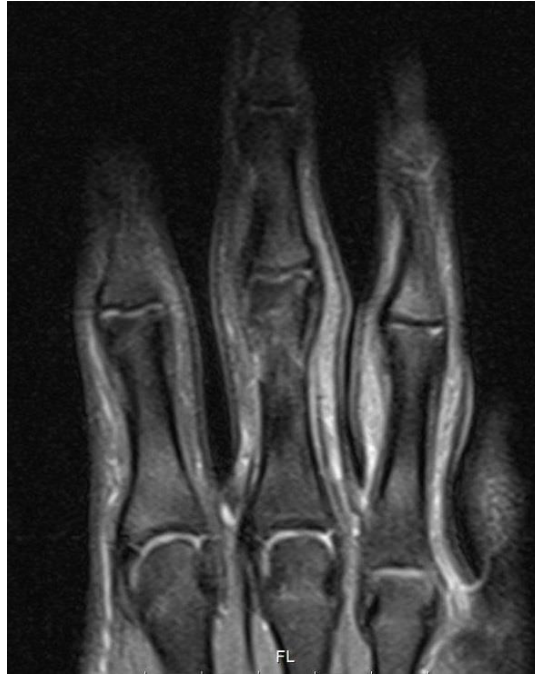

Figure 1. Oedema within the soft tissues around the proximal interphalangeal joints.

His care was transferred to the Rheumatology unit in our hospital and the rheumatological diagnosis was reviewed and revised; sulfasalazine was stopped and a skin biopsy organised. Due to diagnostic uncertainty, onward referral to Dermatology was made. On examination there was symmetrical swelling and thickening of the soft tissue on the lateral aspects of the PIP joints with no evidence of joint synovitis or involvement of thumbs, palms or feet (Figure 2).

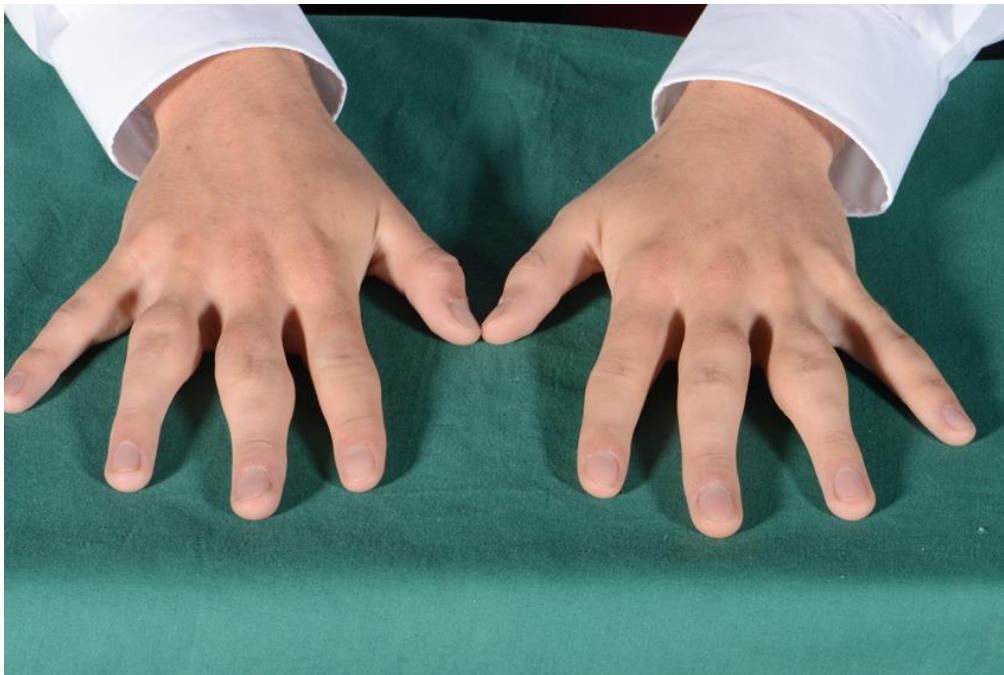

Figure 2. Swelling of the subcutaneous tissues involving the proximal interphalangeal joints of the second, third and fourth fingers both hands.

Hobbies included playing the guitar and when questioned directly, he denied any form of habitual behaviour. During consultations, however, he was noted to rub his fingers subconsciously. With this in mind as a probable cause of repetitive minor trauma, a clinical diagnosis of *PDD* was made. A skin biopsy was supportive showing hyperkeratosis and hyperplasia of the stratified squamous epithelium overlying a dermis with coarse collagen and increased vascularisation. There was no evidence of necrobiotic granuloma, granulomatous inflammation or vasculitis. No koilocytic atypia were seen to suggest verruca vulgaris (Figure 3).

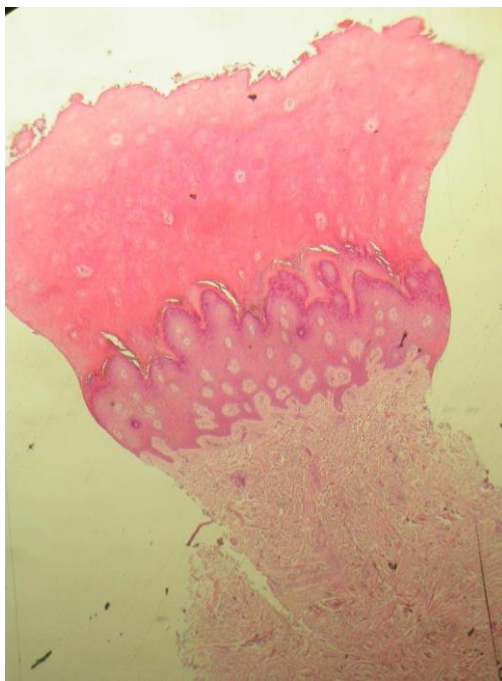


Figure 3. Hyperkeratosis and hyperplasia of the stratified squamous epithelium overlying a dermis with coarse collagen and increased vascularisation (haematoxylin and eosin, original magnification x 4).

Discussion

PDD was first described in 1973 by Bazex and Teillard [1]. It is a benign and non-progressive condition characterised by localised fibromatosis presenting as symmetrical painless swelling of the tissues surrounding the PIP joints of fingers II-IV of both hands. The distal interphalangeal joints as well as other joints are usually spared. It has been reported more commonly in young male patients, and has been suggested to originate from tic-like or ritualistic habits as well as repetitive movements linked to mechanical stress [2]. Such habits can be associated with neurobehavioural disorders such as Asperger's syndrome [3]. In 2015 a new subtype of PDD, termed *pachydermodactyly transgrediens* was described, where involvement of the hypothenar side of the hand was observed [4]. PDD can in some cases present a diagnostic challenge as patients often deny any kind of habits or repetitive behaviour and this can lead to the erroneous diagnosis of an inflammatory arthropathy with commencement of disease modifying therapy as demonstrated by our case and indeed by Carpentier et al. and El-hallak et al. [5, 6].

The diagnosis of PDD is usually a clinical one supported by radiological imaging whilst laboratory investigations and autoimmune screening are generally unremarkable. Radiography, ultrasonography and MRI demonstrate soft tissue swelling with no bone abnormality [7]. Whilst some authors state that histology is not necessary to confirm a diagnosis of PDD, the characteristic histological features of PDD include an increase in dermal collagen with varying degrees of hyperkeratosis and acanthosis [8]. Interestingly, collagen analysis is consistent with structure types III and V which differs to the collagen profile of normal skin and electron microscopy showed collagen fibres to be smaller and less uniform [9]. The patient in this reported case showed classical clinical and radiological findings supported by histological features consistent with PDD.

Juvenile rheumatoid arthritis and chronic arthritis can also present with PIP joint involvement and are important differentials to exclude as indeed both investigations and management differ [7]. Other differential diagnoses to consider include foreign body granuloma, collagenous plaques of the hands, juvenile digital fibromatosis, progressive nodular fibrosis of the skin, thyroid disease, pachydermoperiostosis (Touraine-Solente-Golé syndrome), acromegaly, connective tissue naevi, fibrosing inflammatory conditions, Garrod's pads in violinists, acropachydermodactyly in psoriasis, paraneoplastic acropachydermodactyly, Thiemann's disease, sarcomas and knuckle pads [8]. Despite the clinical similarities between PDD and knuckle pads, useful distinguishing factors between the two include the presence of diffuse swelling in PDD and absence of lateral finger involvement in knuckle pads. In Thiemann's disease on the other hand, joint swelling can be accompanied by pain often triggered by cold weather and an autosomal dominant pattern of inheritance with complete penetrance is observed [7].

Most patients with PDD do not require any specific treatment. In cases where repetitive trauma is a causative factor, cessation of contributing activities can result in resolution of the condition gradually over time. In patients whom PDD causes cosmetic distress surgery is an option. Kato et al. described a surgical intervention for the first time to excise hypertrophic soft tissue and redundant skin bilaterally which was both cosmetically and functionally effective [10].

In summary, we report a memorable case of PDD in a teenager secondary to repetitive hand rubbing. It highlights the importance of recognizing this condition promptly to avoid invasive and excessive diagnostic procedures as well as unnecessary immunosuppression.

References

1. Bazex ADA, Teillard J. Pachydermie digitale des premieres phalanges par hyperplasie conjonctive dermique et aplasie hypodermique. *Bull Soc Fr Dermatol Syphiligr.* 1973;80:455-458.
2. Pereira JM, Pereira FC, Pereira VC. Interphalangeal pads on pachydermodactyly. *An Bras Dermatol.* 2004;79(3):313-321.
3. Bardazzi F, Neri I, Raone B, Patrizi A. Pachydermodactyly: seven new cases. *Ann Dermatol Venereol.* 1998;125(4):247-250. [PMID: 9747260]
4. Nicolay JP, Faulhaber J, Kutzner H, Schneider SW. A new subtype of pachydermodactyly: unilateral pachydermodactyly transgrediens. *Clin Exp Dermatol.* 2015;40(6):633-635. [PMID: 25893660]
5. Woodrow SL, Burrows NP. Pachydermodactyly in association with Asperger syndrome. *Clin Exp Dermatol.* 2003;28(6):674-675. [PMID:14616845]
6. Lo WL, Wong CK. Localized Pachydermodactyly in tuberous sclerosis. *Clin Exp Dermatol.* 1993;18(2):146-147. [PMID:8481991]
7. Sandobal C, Kuznietz A, Varizat A, Roverano S, Paira S. Pachydermodactyly: four additional cases. *Clin Rheumatol* 2007; 26: 962-964. [PMID:16552467]
8. Beltraminelli H, Itin P. Pachydermodactyly--just a sign of emotional distress. *Eur J Dermatol.* 2009;19:5-13. [PMID:19059823]
9. Seo SH, Sung HW. A case of pachydermodactyly. *Ann Dermatol* 2011 May; 23(2): 258-261. [PMID: 21747635]
10. Kato N, Niitsu M, Kawabe T, Arai E, Fukumoto K. Surgical Management of Unilateral Soft Tissue Swelling around the Proximal Interphalangeal Joint in an Adolescent: A Case Report of Pachydermodactyly. *Case Rep Orthop* Published online 2015 Nov 24. doi: [10.1155/2015/242078](https://doi.org/10.1155/2015/242078)