

UC Davis
Dermatology Online Journal

Title

Mycobacterium porferae infection in a psoriasis patient on anti-tnf-a therapy

Permalink

<https://escholarship.org/uc/item/0b57j0cn>

Journal

Dermatology Online Journal, 19(9)

Authors

Laquer, Vivian
Ta, Tuan
Nguyen, Tien
et al.

Publication Date

2013

DOI

10.5070/D3199019609

Copyright Information

Copyright 2013 by the author(s). This work is made available under the terms of a Creative Commons Attribution-NonCommercial-NoDerivatives License, available at <https://creativecommons.org/licenses/by-nc-nd/4.0/>

Peer reviewed

Case Presentation

Mycobacterium porferae infection in a psoriasis patient on anti-tnf-a therapy

Vivian Laquer MD, Tuan Ta MD, Tien Nguyen MD, Belinda Tan MD PhD

Dermatology Online Journal 19 (9): 2

University of California, Irvine

Correspondence:

Vivian T Laquer MD
University of California, Irvine
Irvine, CA USA

Introduction

Psoriasis is a chronic, auto-inflammatory disease affecting millions of individuals worldwide. In addition to classic cutaneous manifestations, the condition is linked to significant co-morbidities including cardiovascular disease, metabolic syndrome, melanoma and non-melanoma skin cancer, and psychiatric disease [1,2]. Therefore, more aggressive treatment and multi-disciplinary care is critical. Measures of disease burden (quantified by anatomic location, body surface area (BSA) of involvement, and impact on daily life) assist in determining the severity of disease and have been integral in objective assessment of treatment regimens and new drug therapies [1]. Biologic agents have entered the clinical armamentarium as treatment options for patients with moderate-to-severe psoriasis who have failed traditional systemic therapies. Three of the four FDA-approved biologic agents for psoriasis suppress TNF α mediated pathways [2], which are essential for granuloma formation and maintenance, key components of host defenses against intracellular pathogens [3]. Subsequently, the increased use of these agents is accompanied by increased reporting of granulomatous infectious diseases such as tuberculosis, histoplasmosis, nocardia, and nontuberculous mycobacteria [4]. Report of any unusual infection is therefore vitally important in the care of this immune suppressed patient population.

Key Words: psoriasis, biologic, mycobacteria, poriferae

Case synopsis

A 43-year old woman with a long history of psoriasis presented to our dermatology practice for treatment of her disease. The patient was previously treated by other dermatologists and was currently doing well on etanercept and topical triamcinolone. She had been using etanercept for over ten years and wished to continue treatment. Her review of systems was negative, including absence of fevers, night sweats, cough, and shortness of breath. Her past medical history included schizoaffective disorder that was stable and treated with valproic acid and olanzapine.

On physical examination, she was a well-appearing adult female with a skin exam showing erythematous plaques with thick white scale on the scalp, face, trunk, and all extremities. Her involved body surface area was <10%. Her prior medical records lacked documentation of prior *Mycobacterium tuberculosis* (M.tb) screening and she denied previous bacillus Calmette-Guérin (BCG) vaccination. We performed a Mantoux tuberculin skin test (TST) and she developed 10 mm of induration. She then stopped etanercept and was referred to an infectious disease specialist.

Within one month of stopping etanercept, she developed a severe papulopustular eruption on her lower legs. In addition, the patient described intermittent aching pains, but denied itching and other systemic symptoms such as fevers or cough. A quantiferon-TB Gold Test (QFTB) was negative. In addition to topical triamcinolone, she started cyclosporine (50mg PO BID, 1.7mg/kg/day) to treat presumed pustular psoriasis. Despite the negative QFTB, she also started daily isoniazid and pyridoxine for latent M.tb. For several weeks, her skin exam on the treatment regimen was stable but did not improve significantly. Her complaints of lower extremity aching were not relieved by the addition of brief courses of antibiotics (doxycycline and minocycline, separately). When her clinical exam began to show worsening, with erythema, ulceration, tenderness, and yellow discharge (Figure 1), a left leg skin biopsy was performed for routine hematoxylin and eosin stain as well as bacterial and fungal

cultures. Histopathology revealed an ulcer with superficial granulation tissue and dermal fibrosis extending to the fat (Figure 2). There was a plasma cell and eosinophil-rich mixed cell infiltrate with focal vascular fibrinoid degeneration and a granulomatous infiltrate (Figure 3). Organisms were not identified with Ziehl-Neelsen and periodic acid-Schiff stains. At eight weeks, however, acid-fast bacilli were identified on tissue cultures, with final results at 12 weeks identifying *M. poriferae* by DNA sequencing. By that time, the patient had completed 9 months of anti-tuberculous therapy. To account for the rapid growing mycobacteria, her antimicrobial regimen was changed to clarithromycin (500 mg BID) and ciprofloxacin (750 mg BID). Because of nausea, she then switched a month later from clarithromycin to azithromycin. At this time, the patient was initiated on a non-TNF α biologic agent, ustekinumab. Her leg eruption improved significantly after 6 months (Figure 4) and cleared after a total of 9 months on ciprofloxacin and azithromycin. At her last clinical follow-up 2 months after finishing antimycobacterial therapy, her papulopustular eruption had completely resolved and her psoriasis was well-controlled on ustekinumab.

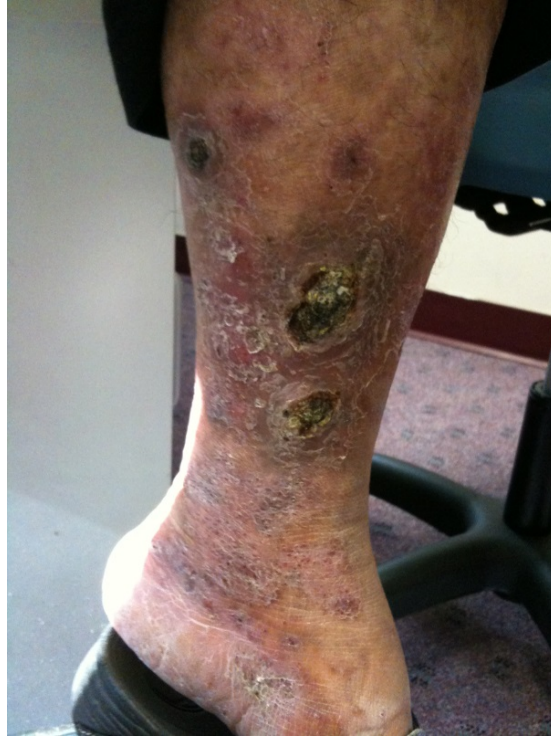

Figure 1. The left lower leg showed ulcers with yellow brown hemorrhagic crust on a background of thick pink and red plaques.

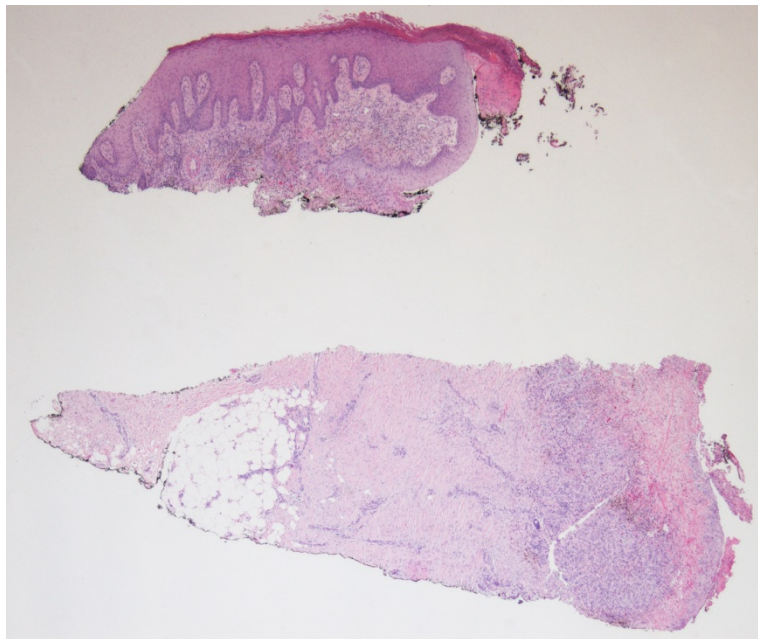


Figure 2. Left lower leg punch biopsies sampling ulcer as well as non-ulcerated border showed acanthosis with superficial granulation tissue and extensive dermal fibrosis extending to the fat layer (hematoxylin and eosin, original magnification x20).

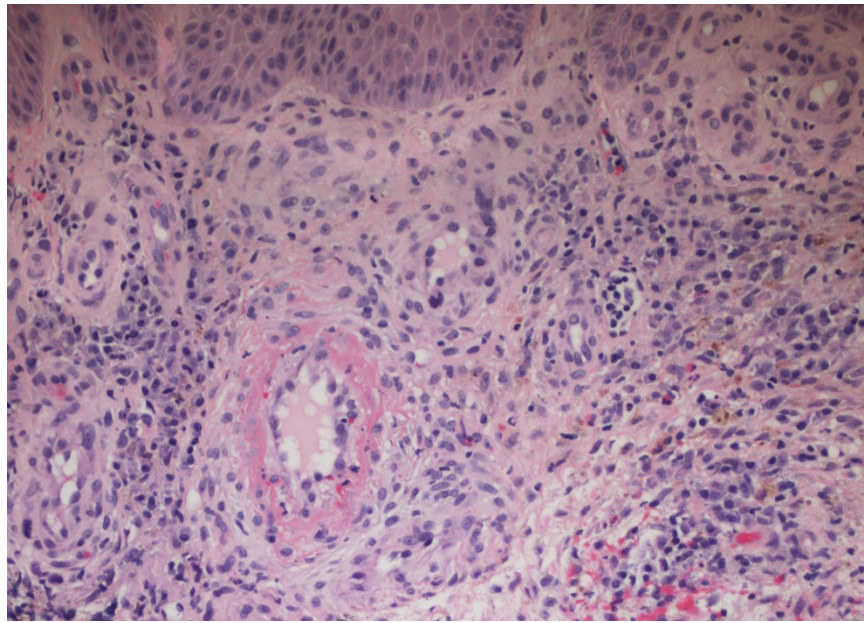


Figure 3. A superficial vessel below intact epidermis demonstrates fibrinoid degeneration with a granulomatous infiltrate. There is a surrounding plasma cell and eosinophil-rich mixed cell infiltrate (hematoxylin and eosin, original magnification x200).

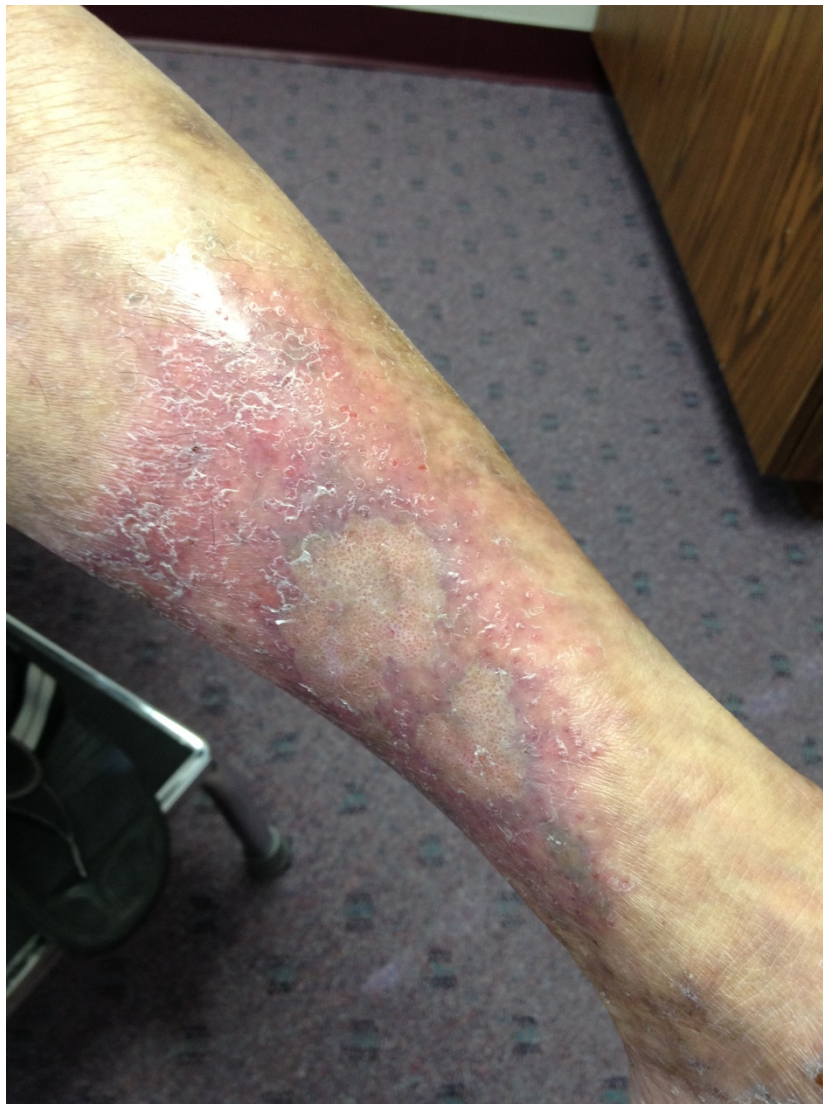

Figure 4. After 6 months of antimycobacterial therapy, the left lower leg showed scaly pink plaques with skin colored atrophic areas representing healed ulcers.

Discussion

Infections with non-tuberculous mycobacteria (NTM) have become more prevalent in the immunosuppressed population. NTM emerged as human pathogens in the 1950s, coinciding with the human immunodeficiency virus (HIV) epidemic and prevalent use of immunosuppressive therapies [5]. Defects in interleukin (IL)-12 and interferon- γ production increase the risk for NTM disease [6]. Therapies that block TNF- α , a critical cytokine in the IL-12 mediated host defense pathway, predispose patients to NTM infections [4]. All three of the commonly used anti-TNF- α therapies are linked to these infections. Of 105 confirmed NTM cases reported to the US Food and Drug Administration from 1999-2006, 75% were associated with infliximab, 17% with etanercept, and 8% with adalimumab [7]. NTM infections are predicted to outnumber cases linked to *M.tb* with the increasing use of immunosuppressive therapies [8].

M.poriferae is a recently discovered bacterium, isolated in 1987 from the marine sponge *Halichondria bowerbanski* [9]. The organism can also be cultured from the freshwater fish *Channa striatus* [10]. To date, there is only one published report of a human host. The organism was cultured and sequenced from sputum samples of an immune competent patient with a history of tobacco use and chronic bronchitis who presented with hemoptysis [11]. Following susceptibility testing of the organism, the patient received amoxicillin-clavulanate treatment and the respiratory symptoms resolved. Whether the organism represented a true pathogen or a bystander remains uncertain. In our case reported here, the organism was identified by culture and PCR sequencing from a skin biopsy. Our patient's cutaneous symptoms only resolved following a prolonged course of therapy directed at rapidly growing mycobacteria. This is the second reported case of *M. poriferae* isolated from human tissue and the first case of a cutaneous infection.

Our case raises the question of how to best screen for NTM infections. TSTs routinely screen for *M.tb* infection, indicating active or latent infection, but require careful interpretation with appropriate clinical context. Anergy in the setting of immunocompromise may yield a negative result, whereas NTM infection or BCG vaccination can give a positive. In high-risk patient populations, interferon- γ release assays (IGRAs) have gained popularity and may replace the TST for *M.tb* screening [12]. IGRAs are highly sensitive and specific serum assays that measure IFN- γ release from T cells specific to *M.tb*, indicating active infection or latency [13]. There is increasing evidence suggesting that IGRAs may be more sensitive for detecting *M.tb* in the setting of HIV infection. However, the Centers for Disease Control and Prevention (CDC) does not currently recommend replacing TSTs with IGRAs in immunosuppressed individuals [14]. Swiss, French, and Bulgarian guidelines do recommend use of IGRAs alone for the HIV infected. The literature comparing IGRAs to TSTs in patients using TNF- α inhibitors is limited and debate continues on what will be the best screening test [15]. [12,16]. Our patient denied prior BCG vaccination, but had a TST measuring 10mm and a negative IGRA (via the QFTB). Our patient's reaction to the TST may reflect cross-reactive immunity to NTM. Larson et. al. found that 16% (21 of 135) of patients with a positive TST had *M. avium* rather than *M.tb* infection. They observed that TST reactions measuring less than 15mm were less specific for *M.tb* [17]. Perhaps the combination of TST and IGRA may be useful to screen for NTM while also excluding *M.tb*.

Despite the fact that NTM infections are less common than *M.tb* infections, they represent a significant number of reported infectious complications associated with biologic agents. Many medical and non-medical procedures performed on immunocompetent individuals have been linked to NTM infections. These include cutaneous surgery, laser resurfacing, liposuction, acupuncture, body piercing, tattoos, and pedicures [18]. In the setting of immunosuppression, medical necessity must be carefully weighed against the risks of NTM infections. Although the appearance of a new eruption can be attributed to the natural progression of the underlying skin condition, NTM infection must be excluded when this occurs in patients on TNF α -blocking or other immunosuppressive biologics.

References

1. Menter A, Gottlieb A, Feldman SR, Van Voorhees AS, Leonardi CL, Gordon KB, Lebwohl M, Koo JY, Elmetts CA, Korman NJ, Beutner KR, Bhushan R. Guidelines of care for the management of psoriasis and psoriatic arthritis: Section 1. Overview of psoriasis and guidelines of care for the treatment of psoriasis with biologics. *J Am Acad Dermatol* 2008;58:826-850. [PMID: 18423260]
2. Menter A, Korman NJ, Elmetts CA, Feldman SR, Gelfand JM, Gordon KB, Gottlieb A, Koo JY, Lebwohl M, Leonardi CL, Lim HW, Van Voorhees AS, Beutner KR, Ryan C, Bhushan R. Guidelines of care for the management of psoriasis and psoriatic arthritis: Section 6. Guidelines of care for the treatment of psoriasis and psoriatic arthritis: Case-based presentations and evidence-based conclusions. *J Am Acad Dermatol* 2011;65:137-174. [PMID: 21306785]
3. Harris J, Keane J. How tumour necrosis factor blockers interfere with tuberculosis immunity. *Clin Exp Immunol* 2010;161:1-9. [PMID: 20491796]
4. Wallis RS, Broder MS, Wong JY, Hanson ME, Beenhouwer DO. Granulomatous infectious diseases associated with tumor necrosis factor antagonists. *Clin Infect Dis* 2004;38:1261-1265. [PMID: 15127338]
5. Lee WJ, Kang SM, Sung H, Won CH, Chang SE, Lee MW, Kim MN, Choi JH, Moon KC. Non-tuberculous mycobacterial infections of the skin: A retrospective study of 29 cases. *J Dermatol* 2010;37:965-972. [PMID: 21039785]

6. Rosenzweig SD, Holland SM. Defects in the interferon-gamma and interleukin-12 pathways. *Immunol Rev* 2005;203:38-47. [PMID: 15661020]
7. Winthrop KL, Chang E, Yamashita S, Iademarco MF, LoBue PA. Nontuberculous mycobacteria infections and anti-tumor necrosis factor-alpha therapy. *Emerg Infect Dis* 2009;15:1556-1561. [PMID: 19861045]
8. Iseman MD. Mycobacterial infections in the era of modern biologic agents. *Am J Med Sci* 2011;341:278-280. [PMID: 21378550]
9. Padgett PJ, Moshier SE. *Mycobacterium poriferae* sp. Nov., a scotochromogenic, rapidly growing species isolated from a marine sponge. *Int J Syst Bacteriol* 1987;186-191.
10. Tortoli E, Bartoloni A, Bozzetta E, Burrini C, Lacchini C, Mantella A, Penati V, Tullia Simonetti M, Ghittino C. Identification of the newly described mycobacterium poriferae from tuberculous lesions of snakehead fish (*channa striatus*). *Comp Immunol Microbiol Infect Dis* 1996;19:25-29. [PMID: 8654042]
11. Ballester F, Pujol I, Alcaide F, Pizarro I, Simo JM, Joven J, Camps J. First human isolate of mycobacterium poriferae in the sputum of a patient with chronic bronchitis. *J Clin Microbiol* 2011;49:3107-3108. [PMID: 21653776]
12. Denkinger CM, Dheda K, Pai M. Guidelines on interferon-gamma release assays for tuberculosis infection: Concordance, discordance or confusion? *Clin Microbiol Infect* 2011;17:806-814. [PMID: 21682801]
13. Matulis G, Juni P, Villiger PM, Gadola SD. Detection of latent tuberculosis in immunosuppressed patients with autoimmune diseases: Performance of a mycobacterium tuberculosis antigen-specific interferon gamma assay. *Ann Rheum Dis* 2008;67:84-90. [PMID: 17644549]
14. Mazurek GH, Jereb J, Vernon A, LoBue P, Goldberg S, Castro K. Updated guidelines for using interferon gamma release assays to detect mycobacterium tuberculosis infection - united states, 2010. *MMWR Recomm Rep* 2010;59:1-25. [PMID: 20577159]
15. Amerio P, Amoroso G, Bardazzi F, Campanati A, Cassano N, Conti A, Gisondi P, Guarneri C, Mazzotta A, Piaserico S, Prestinari F, Prignano F, Zane C, de Simone C. Detection and management of latent tuberculosis infections before biologic therapy for psoriasis. *J Dermatolog Treat* 2012. [PMID: 22208431]
16. Smith R, Cattamanchi A, Steingart KR, Denkinger C, Dheda K, Winthrop KL, Pai M. Interferon-gamma release assays for diagnosis of latent tuberculosis infection: Evidence in immune-mediated inflammatory disorders. *Curr Opin Rheumatol* 2011;23:377-384. [PMID: 21519268]
17. Larson EM, O'Donnell M, Chamblee S, Horsburgh CR, Jr., Marsh BJ, Moreland JD, Johnson LS, von Reyn CF. Dual skin tests with mycobacterium avium sensitin and ppd to detect misdiagnosis of latent tuberculosis infection. *Int J Tuberc Lung Dis* 2011;15:1504-1509, i. [PMID: 22008764]
18. Drage LA, Ecker PM, Orenstein R, Phillips PK, Edson RS. An outbreak of mycobacterium chelonae infections in tattoos. *J Am Acad Dermatol* 2010;62:501-506. [PMID: 19733936]