

# UC Davis

## Dermatology Online Journal

### Title

Subcutaneous sarcoidosis without systemic involvement

### Permalink

<https://escholarship.org/uc/item/0hd858q9>

### Journal

Dermatology Online Journal, 20(8)

### Authors

O'Neill, Jenna L  
Moustafa, Farah  
Teague, Daniel  
et al.

### Publication Date

2014

### DOI

10.5070/D3208023528

### Copyright Information

Copyright 2014 by the author(s). This work is made available under the terms of a Creative Commons Attribution-NonCommercial-NoDerivatives License, available at <https://creativecommons.org/licenses/by-nc-nd/4.0/>

Peer reviewed

**Case Presentation**

**Subcutaneous sarcoidosis without systemic involvement**

**Jenna L. O'Neill MD, Farah Moustafa BS, Daniel Teague MD, William W. Huang MD MPH**

**Dermatology Online Journal 20 (8): 5**

**Department of Dermatology, Wake Forest School of Medicine, Winston-Salem, North Carolina**

**Correspondence:**

Jenna O'Neill MD  
Department of Dermatology  
Wake Forest School of Medicine  
4618 Country Club Road  
Winston-Salem, NC 27104  
Phone: 336-716-3926 Fax: 336-716-9258  
Email: jeoneill@wakehealth.edu

**Abstract**

Subcutaneous sarcoidosis is a rare variant of cutaneous sarcoidosis, which typically presents as single or multiple, indurated, ill-defined plaques, typically on the upper extremities. Granulomas consisting of macrophages with multinucleated giant cells and sparse lymphocytic inflammation are confined to the subcutaneous tissue, rather than to their usual location within the dermis in typical lesions of cutaneous sarcoidosis. An association between subcutaneous sarcoidosis and systemic involvement has been reported, although response to treatment and prognosis remain good. We report a case of a middle-aged woman with subcutaneous sarcoidosis, with negative work-up for systemic involvement of sarcoidosis. Interestingly, family history was significant for a son who died from complications of pulmonary sarcoidosis. The patient was successfully treated with a tapering course of oral prednisone in combination with hydroxychloroquine.

**Keywords: sarcoidosis, subcutaneous, cutaneous, systemic involvement**

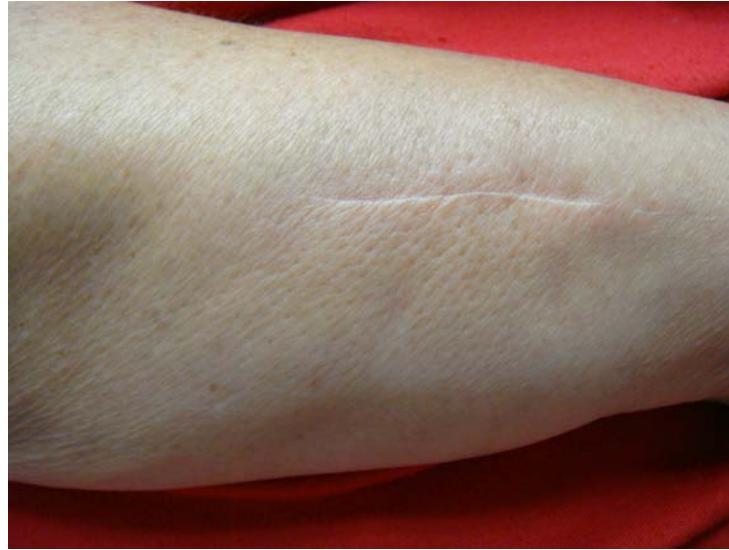**Introduction**

Subcutaneous sarcoidosis is an unusual variant of sarcoidosis, in which epithelioid granulomas are confined to the subcutaneous tissue rather than their typical location within the dermis [1]. Lesions of subcutaneous sarcoidosis typically present as indurated ill-defined plaques, often multiple and involving the upper extremities. An association between subcutaneous sarcoidosis and systemic involvement has been noted, yet the response to treatment and prognosis remain good [2-4].

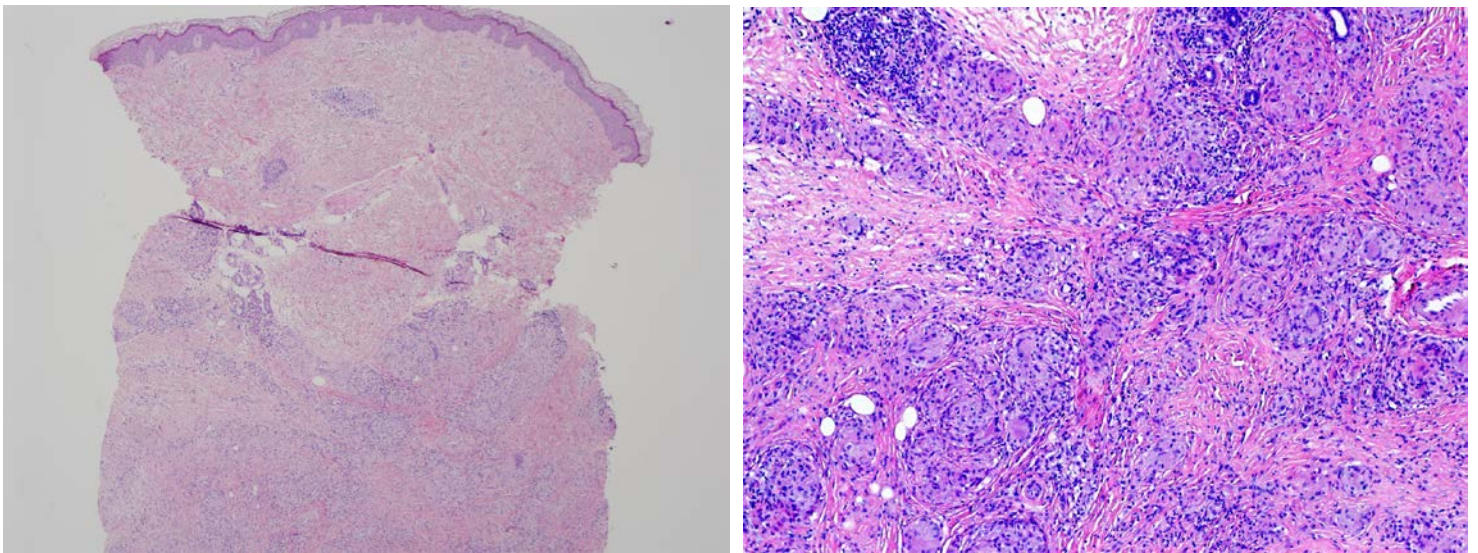
**Case synopsis**

A 64-year-old woman presented to the dermatology clinic complaining of a 3 month history of a firm plaque on her right forearm, which had been gradually increasing in size. She denied tenderness, itching, or other symptoms and had no similar lesions elsewhere. She had been initially referred to an orthopedic specialist who performed two deep excisional biopsies, which revealed non-necrotizing epithelioid granulomas; however, a specific diagnosis was not made.

At the time of presentation to the dermatology department, her skin examination revealed a deep, indurated plaque with peau d'orange changes of the skin and no epidermal changes (Figure 1). The patient underwent a 4 mm punch biopsy, which revealed a granulomatous panniculitis consistent with sarcoidosis, confined to the subcutis (Figure 2). There were multiple, deep granulomas composed of epithelioid macrophages with scattered multinucleated giant cells (Figure 3). A peripheral, sparse lymphocytic infiltrate was also present.



**Figure 1.** Indurated plaque on the forearm with overlying peau d'orange appearance: The scar is the site of previous incisional biopsy.



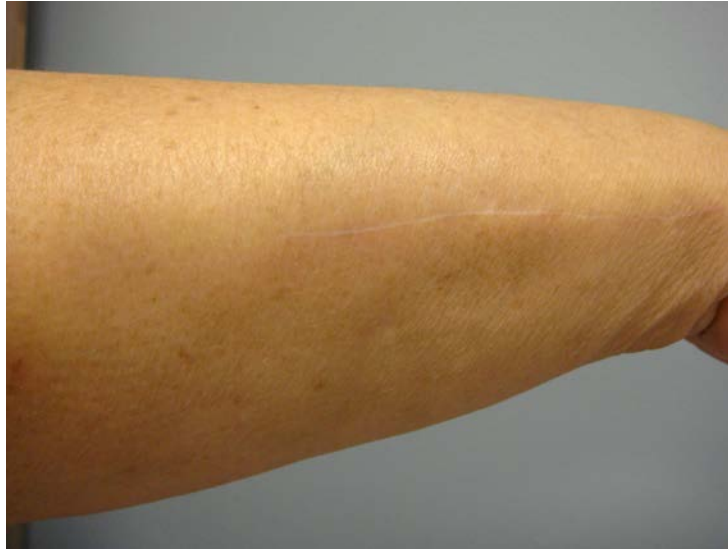**Figure 2.** Granulomatous panniculitis confined to the subcutis in hematoxylin and eosin stain Magnification 2x.

**Figure 3.** Higher magnification demonstrating epithelioid granulomas with multinucleated giant cells and a sparse lymphocytic infiltrate in hematoxylin and eosin stain Magnification 20x

No other concerning lesions suspicious for sarcoidosis were noted on the remainder of her examination. The patient underwent laboratory work-up including a complete blood count with differential, complete metabolic panel, and erythrocyte sedimentation rate (ESR). Work-up was unrevealing with the exception of a mild leukopenia (white blood cell count 4.0 billion cells/L; normal range 4.8 to 10.8) and anemia (hemoglobin 11.6 g/dL; normal range 12.0 to 16.0). Angiotensin converting enzyme (ACE) level was within normal limits. On review of systems, she had nonspecific complaints of shortness of breath. She underwent computed tomography (CT) imaging of the chest, which did not reveal hilar adenopathy or an acute cardiopulmonary process. Pulmonary Function Tests (PFTs) were within normal limits except for a mildly reduced diffusing capacity of the lung for carbon monoxide (DLCO), which was consistent with a previous DLCO. Family history was positive for a son who died from pulmonary complications of sarcoidosis.

After histologic confirmation of the diagnosis of subcutaneous sarcoidosis, treatment was initiated with an oral prednisone taper (starting at 20 mg/day) as well as hydroxychloroquine 200 mg twice per day. The patient rapidly improved after initiation of treatment, with nearly complete clearance of the plaque (Figure 4). The patient remained clear for several months, but

unfortunately she experienced recurrence with rapid reappearance of the indurated plaque over the course of four days, after tapering of prednisone to 2.5 mg daily. She complained of associated tenderness. A prednisone taper was re-initiated at a dose of 20 mg daily. The patient continued to be managed on 5 mg daily and experienced one recurrence 6 months later. She is currently asymptomatic and managed on 10mg prednisone daily and 200 mg hydroxychloroquine twice daily. The patient's shortness of breath was self-limited and given normal PFTs and radiographic imaging, was most likely related to anemia.



**Figure 4.** Clearance of the plaque after treatment; The scar is the site of previous incisional biopsy.

## Discussion

Sarcoidosis is a multisystem granulomatous disease characterized by upregulation of the cell-mediated immune response. An unknown antigen is thought to trigger activation of CD4+ T helper cells of the Th1 subtype [5]. Cutaneous lesions of sarcoidosis are present in 25% of patients [6] and are divided into specific and nonspecific lesions based on the presence or absence of sarcoidal granulomas. The prototypical nonspecific cutaneous lesion associated with sarcoidosis is erythema nodosum, which is associated with an acute presentation of sarcoidosis and portends a favorable prognosis. Specific sarcoidal lesions are protean and often present as infiltrative red-brown papules or plaques, which favor the face and upper trunk.

Subcutaneous sarcoidosis, also known as Darier-Roussy sarcoidosis, is an uncommon variant in which sarcoidal lesions are limited to the subcutaneous tissues [1]. Painless, firm, mobile plaques and nodules are typically observed clinically, with no overlying epidermal change or erythematous or violaceous color change. The upper extremity is commonly affected and multiple lesions may be observed.

An association between subcutaneous sarcoidosis and systemic involvement has been observed [2-4]. In a series of 21 patients with subcutaneous sarcoidosis, 80% had a systemic disease component, most frequently bilateral hilar adenopathy [2]. In the same series, review of the literature demonstrated a similar rate of systemic involvement, with 29 of 31 patients (88%) having systemic involvement at disease outset. The most frequent systemic disease manifestations were lymphadenopathy, parotitis, conjunctivitis, abnormal pulmonary function tests, lacrimal gland involvement, and hepatosplenomegaly. Elevated ACE level was noted in 85% of patients and correlated with systemic involvement.

In another series of 86 patients with systemic sarcoidosis with cutaneous lesions, maculopapular and subcutaneous sarcoidal lesions were associated with more acute disease with good prognosis, as well as with erythema nodosum and radiological stage I (chest radiograph classification of pulmonary sarcoidosis), which designates hilar or mediastinal nodal enlargement only. In contrast, sarcoidal plaques and lupus pernio lesions correlated with more chronic disease and requirement for treatment with systemic corticosteroids [3]. This variability in disease course and systemic involvement suggests that a different immune responses or other underlying factors may dictate cutaneous manifestations among different patients.

Histopathologic diagnostic criteria have been established for subcutaneous sarcoidosis by Vainsencher and Winkelmann [7] and are defined as the presence of noninfectious sarcoidal or epithelioid granulomas with minimal lymphocytic inflammation involving predominantly the panniculus. Fibroplasia is another reported histopathologic feature of subcutaneous sarcoidosis [8]. Other granulomatous processes should be excluded including Blau syndrome in children, a foreign body reaction, subacute granuloma annulare, traumatic panniculitis, drug-related granulomatous panniculitis, secondary syphilis, Sezary syndrome, and

some lymphomas [9]. Less common diagnoses worth consideration include: rheumatoid nodule, necrobiosis lipoidica, and epithelioid sarcoma.

We have also seen a case of metastatic melanoma, which histologically looked like sarcoidal granulomas in the dermis and subcutis. Diagnosis of melanoma was confirmed with immunohistochemical stains. In contrast, sarcoidosis-like granuloma formation has been reported to mimic metastatic melanoma [10]. Special stains, including acid fast bacillus (AFB), Gomori methenamine silver (GMS), and periodic acid schiff (PAS) are typically performed to rule out infectious etiologies; polarization may be performed to exclude a foreign body granuloma.

Given the propensity toward systemic involvement in patients with subcutaneous sarcoidosis, work-up should include laboratory screening with complete blood count, calcium, and ACE level, as well as chest radiography. Longitudinal follow-up is important because cutaneous lesions of sarcoidosis may develop prior to, at the time of, or subsequent to systemic manifestations [2, 11].

Protean systemic symptoms of sarcoidosis may be manifest owing to granulomatous inflammation of any organ system. Up to one third of patients may present with non-specific constitutional symptoms of fever, malaise, or weight loss [7, 12]. Pulmonary complications of sarcoidosis are a major cause of morbidity, most frequently hilar and/or paratracheal lymphadenopathy [6, 13] and parenchymal granulomatous inflammation with end-stage fibrosis [14]. Autoimmune disease associations have also been observed, including Hashimoto thyroiditis. Patients with collagen-vascular diseases may be more prone to develop sarcoidosis [2, 15]. Hypercalcemia is an endocrine manifestation of sarcoidosis induced by secretion of 1,25 dihydroxy-vitamin D3 by alveolar macrophages [16].

The presence of a family history of sarcoidosis in the reported patient's son is an interesting facet of this case. Support for an inherited etiology of sarcoidosis lies in the presence of familial clusters and in the association of sarcoidosis with certain human leukocyte antigen (HLA) alleles [17]. In 233 European patients with sarcoidosis, a positive association was observed with HLA-1, -B8, and -DR3 [18]. Polymorphisms in the angiotensin converting enzyme gene have also been implicated in sarcoidosis [19]. Genetic variations in genes regulating immune function, T cell function, or antigen presentation may play a role in sarcoidosis susceptibility [20].

Oral corticosteroids are the mainstay of treatment of subcutaneous sarcoidosis. In 21 patients with subcutaneous sarcoidosis, response to treatment was good, with complete remission of skin lesions noted in 86% [2]. The usual dose of prednisone was 20 to 40 mg daily, with response observed within 4 to 8 weeks of initiation of therapy. In a series of 10 patients with subcutaneous sarcoidosis, none developed serious complications [21]. Anecdotal reports have demonstrated success in the treatment of patients with subcutaneous sarcoidosis with oral minocycline, allopurinol, and adalimumab [22-24]. The use of hydroxychloroquine has also been reported, with response noted in 12 of 17 patients within 4 to 12 weeks in one series [25]. The use of corticosteroid-sparing agents may be necessary in patients who respond slowly to therapy or who relapse on tapering of oral corticosteroids.

In this report, we present a patient with subcutaneous sarcoidosis confined to the subcutis. Interestingly, work up for this patient did not reveal any systemic involvement (as has been reported with subcutaneous sarcoid). The presentation of a firm, indurated plaque in a female with a positive family history should raise the concern for this disease. However, other conditions presented in the discussion should be considered in the differential diagnosis. Assessment for systemic involvement should be carried out to ensure no other organ systems are involved. To date, our patient continues to do well with treatment of small dose oral prednisone (10mg daily) and hydroxychloroquine (200 mg twice daily).

## References

1. Young RC, Jr., Rachal RE, Cowan CL, Jr. Sarcoidosis--the beginning: historical highlights of personalities and their accomplishments during the early years. *Journal of the National Medical Association*. 1984;76(9):887-96. Epub 1984/09/01. [PMID: 6387158]
2. Ahmed I, Harshad SR. Subcutaneous sarcoidosis: is it a specific subset of cutaneous sarcoidosis frequently associated with systemic disease? *Journal of the American Academy of Dermatology*. 2006;54(1):55-60. Epub 2005/12/31. doi: 10.1016/j.jaad.2005.10.001. [PMID: 16384755].
3. Marcoval J, Mana J, Rubio M. Specific cutaneous lesions in patients with systemic sarcoidosis: relationship to severity and chronicity of disease. *Clinical and experimental dermatology*. 2011;36(7):739-44. Epub 2011/07/28. doi: 10.1111/j.1365-2230.2011.04128.x. [PMID: 21790725].
4. Dalle Vedove C, Colato C, Girolomoni G. Subcutaneous sarcoidosis: report of two cases and review of the literature. *Clinical rheumatology*. 2011;30(8):1123-8. Epub 2011/04/05. doi: 10.1007/s10067-011-1731-4. [PMID: 21461650].
5. Kataria YP, Holter JF. Immunology of sarcoidosis. *Clinics in chest medicine*. 1997;18(4):719-39. Epub 1997/12/31. [PMID: 9413655].



6. Newman LS, Rose CS, Maier LA. Sarcoidosis. *The New England journal of medicine*. 1997;336(17):1224-34. Epub 1997/04/24. doi: 10.1056/nejm199704243361706. [PMID: 9110911].
7. Vainsencher D, Winkelmann RK. Subcutaneous sarcoidosis. *Archives of dermatology*. 1984;120(8):1028-31. Epub 1984/08/01. [PMID: 6465908].
8. Resnik KS. Subcutaneous sarcoidosis histopathologically manifested as fibrosing granulomatous panniculitis. *Journal of the American Academy of Dermatology*. 2006;55(5):918-9. Epub 2006/10/21. doi: 10.1016/j.jaad.2006.04.080. [PMID: 17052515].
9. Chow KF, Ritchie E, Husain S, Alobeid B, Bhagat G, Lethal T- and NK-cell lymphomas mimicking granulomatous panniculitides: a clinicopathologic study of three cases. *Journal of cutaneous pathology*. 2011;38(6):483-91. Epub 2011/03/08. doi: 10.1111/j.1600-0560.2011.01697.x. [PMID: 21375563].
10. North J, Mully T. Alpha-interferon induced sarcoidosis mimicking metastatic melanoma. *Journal of cutaneous pathology*. 2011;38(7):585-9. Epub 2011/04/28. doi: 10.1111/j.1600-0560.2011.01702.x. [PMID: 21521359].
11. Meyer-Gonzalez T, Suarez-Perez JA, Lopez-Navarro N, Hidalgo A, Herrera-Ceballos E. Subcutaneous sarcoidosis: a predictor of systemic disease? *European journal of internal medicine*. 2011;22(6):e162-3. Epub 2011/11/15. doi: 10.1016/j.ejim.2011.07.005. [PMID: 22075313].
12. Statement on sarcoidosis. Joint Statement of the American Thoracic Society (ATS), the European Respiratory Society (ERS) and the World Association of Sarcoidosis and Other Granulomatous Disorders (WASOG) adopted by the ATS Board of Directors and by the ERS Executive Committee, February 1999. *American journal of respiratory and critical care medicine*. 1999;160(2):736-55. Epub 1999/08/03. doi: 10.1164/ajrccm.160.2.ats4-99. [PMID: 10430755].
13. Crystal R. Sarcoidosis. In: Fauci AS, Braunholtz D, Isselbacher KJ, et al., editor. *Harrison's principles of internal medicine*. New York: McGraw-Hill; 1998. p. 1922-8.
14. Sheffield EA. Pathology of sarcoidosis. *Clinics in chest medicine*. 1997;18(4):741-54. Epub 1997/12/31. [PMID: 9413656].
15. Nakamura H, Genma R, Mikami T, Kitahara A, Natsume H, Andoh S, et al. High incidence of positive autoantibodies against thyroid peroxidase and thyroglobulin in patients with sarcoidosis. *Clinical endocrinology*. 1997;46(4):467-72. Epub 1997/04/01. [PMID: 9196610].
16. Sharma OP. Vitamin D, calcium, and sarcoidosis. *Chest*. 1996;109(2):535-9. Epub 1996/02/01. [PMID: 8620732].
17. Rybicki BA, Harrington D, Major M, Simoff M, Popovich J, Jr., Maliarik M, et al. Heterogeneity of familial risk in sarcoidosis. *Genetic epidemiology*. 1996;13(1):23-33. Epub 1996/01/01. doi: 10.1002/(SICI)1098-2272(1996)13:1<23::AID-GEPI3>3.0.CO;2-7. [PMID: 8647376].
18. Martinetti M, Tinelli C, Kolek V, Cuccia M, Salvaneschi L, Pasturenzi L, et al. "The sarcoidosis map": a joint survey of clinical and immunogenetic findings in two European countries. *American journal of respiratory and critical care medicine*. 1995;152(2):557-64. Epub 1995/08/01. doi: 10.1164/ajrccm.152.2.7633707. [PMID: 7633707].
19. Furuya K, Yamaguchi E, Itoh A, Hizawa N, Ohnuma N, Kojima J, et al. Deletion polymorphism in the angiotensin I converting enzyme (ACE) gene as a genetic risk factor for sarcoidosis. *Thorax*. 1996;51(8):777-80. Epub 1996/08/01. [PMID: 8795663].
20. English JC, 3rd, Patel PJ, Greer KE. Sarcoidosis. *Journal of the American Academy of Dermatology*. 2001;44(5):725-43; quiz 44-6. Epub 2001/04/20. doi: 10.1067/mjd.2001.114596. [PMID: 11312418].
21. Marcoval J, Mana J, Moreno A, Peyri J. Subcutaneous sarcoidosis--clinicopathological study of 10 cases. *The British journal of dermatology*. 2005;153(4):790-4. Epub 2005/09/27. doi: 10.1111/j.1365-2133.2005.06815.x. [PMID: 16181462].
22. Voelter-Mahlknecht S, Benez A, Metzger S, Fierlbeck G. Treatment of subcutaneous sarcoidosis with allopurinol. *Archives of dermatology*. 1999;135(12):1560-1. Epub 1999/12/22. [PMID: 10606082].
23. Bachelez H, Senet P, Cadranet J, Kaoukhov A, Dubertret L. The use of tetracyclines for the treatment of sarcoidosis. *Archives of dermatology*. 2001;137(1):69-73. Epub 2001/02/15. [PMID: 11176663].
24. Burns AM, Green PJ, Pasternak S. Etanercept-induced cutaneous and pulmonary sarcoid-like granulomas resolving with adalimumab. *Journal of cutaneous pathology*. 2012;39(2):289-93. Epub 2011/09/09. doi: 10.1111/j.1600-0560.2011.01795.x. [PMID: 21899592].
25. Jones E, Callen JP. Hydroxychloroquine is effective therapy for control of cutaneous sarcoid-like granulomas. *Journal of the American Academy of Dermatology*. 1990;23(3 Pt 1):487-9. Epub 1990/09/01. [PMID: 2212149].