

UC Davis

Dermatology Online Journal

Title

White fibrous papulosis of the neck

Permalink

<https://escholarship.org/uc/item/289705qx>

Journal

Dermatology Online Journal, 20(12)

Authors

Schaffer, Panta Rouhani
Tran, Kathleen
Kaplan, Jennifer
et al.

Publication Date

2015

DOI

10.5070/D32012025054

Copyright Information

Copyright 2015 by the author(s). This work is made available under the terms of a Creative Commons Attribution-NonCommercial-NoDerivatives License, available at <https://creativecommons.org/licenses/by-nc-nd/4.0/>

Peer reviewed

Case Presentation

White fibrous papulosis of the neck

Panta Rouhani MD PhD MPH, Kathleen Tran MD MSc, Jennifer Kaplan MD, Rishi Patel MD, Hideko Kamino MD, Sarika Ramachandran MD, and Andrew G. Franks Jr MD

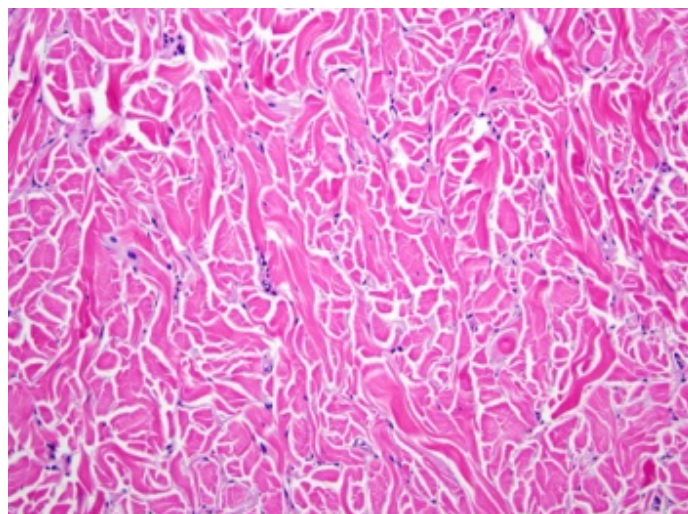
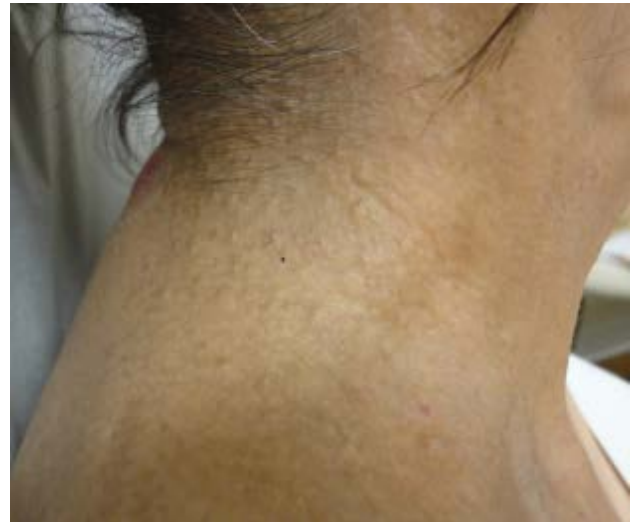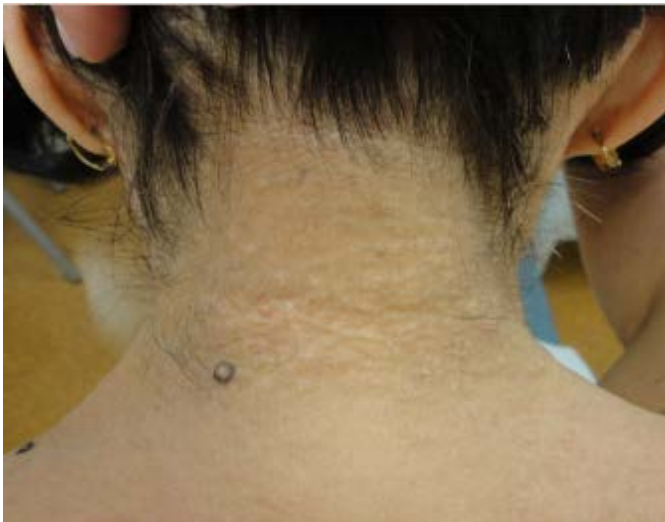Dermatology Online Journal 20 (12): 6

New York University School of Medicine

Special Guest Editor: Nicholas A. Soter, MD

Abstract

We present a 76-year old woman with a five-year history of asymptomatic, white papules that were grouped on the lateral and posterior aspects of the neck, inferior axillae, and central mid-back. The histopathologic findings showed thickened collagen bundles. A diagnosis of white fibrous papulosis of the neck was made, which is believed to be a manifestation of intrinsic aging. There are no treatments for white fibrous papulosis of the neck. One hypothesized approach is the application of a topical anti-oxidant to reduce free-radical induced aging.



Case synopsis

History: A 76-year old woman presented to the Skin and Cancer Unit with a five-year history of asymptomatic papules. She first noted the papules on the lateral aspects of her neck. She reported gradual spread to the posterior aspect of the neck over the next two years. She sought care with a dermatologist, who suspected a diagnosis of pseudoxanthoma elasticum. A punch biopsy was obtained. The patient received a possible diagnosis of scleromyxedema. She reported to our department for evaluation.

Past medical history was not contributory. Her current medications include a multivitamin. She denied a smoking history. She denied any family members with similar skin findings.

Two punch biopsies from the posterior neck and the left inferior axilla were obtained.

Physical examination: Multiple, 3-mm, white, round papules were located at the base of the posterior aspect and on the lateral aspect of the neck. There were similar papules grouped below the axillae and on the central position of the mid-back.

Laboratory data: A complete blood count, complete metabolic panel, serum protein electrophoresis, and urine protein electrophoresis were normal. Anti-nuclear antibodies; anti-topoisomerase, anti-Smith, anti-small nuclear ribonucleoproteins, anti-Ro/SSA, anti-La/SSB, anti-aminoacyl-tRNA synthetase, anti-centromere, anti-thyroglobulin, and anti-thyroid peroxidase antibodies; and rheumatoid factor were negative. The serum angiotensin-converting-enzyme level was normal.

Histopathology: There are slightly thickened, haphazardly-oriented, collagen bundles within the dermis. A colloidal iron stain fails to show increased connective-tissue mucin.

Discussion

Diagnosis: White fibrous papulosis of the neck

White fibrous papulosis of the neck (WFPN) was first described in 16 patients in 1985 [1]. In a subsequent case series, 32 cases of asymptomatic, white papules mainly around the neck of elderly Japanese patients were clinically, histopathologically, and ultrastructurally examined [2]. The papules were described as approximately two-to-three millimeters in diameter, round-to-oval, clearly-marginated, and unrelated to the hair follicles [1-2]. The histopathologic features showed thick collagen bundles in the papillary to mid-dermis. Ultrastructurally, variations in the diameters of collagen fibrils within the lesions were reported when compared to perilesional normal skin [2]. This entity has since been described in patients of different ethnic backgrounds, which included Iranian, Saudi Arabian, Chinese, Korean, South American, Sicilian, and European patients [3-9].

WFPN is a rare condition that has been reported in both men and women older than 40 years of age at the time of presentation [10]. The etiologic factor has been attributed to intrinsic cutaneous aging as well as to ultraviolet radiation exposure [1-10,12-14]. Dermoscopy of the lesions shows clearly circumscribed, homogenous, white areas, which include dotted or short, thin vessels without follicular involvement [12]. The differential diagnosis includes dermatofibromas, acrochordons, anetoderma, trichodiscoma, connective-tissue nevi, eruptive vellus-hair cysts, milia, eruptive xanthomas, dermatofibrosis lenticularis disseminata, molluscum contagiosum, and pseudoxanthoma elasticum (PXE) [1,6,9,12]. Of great importance in the differential diagnosis is PXE because of its systemic involvement. PXE causes calcification of the elastic fibers in the skin, retina (angioid streaks), and cardiovascular system, which leads to serious complications. However, PXE is a rare genetic condition that is caused by a mutation in the ABC6 gene and usually develops during childhood [14].

Pseudoxanthoma-like elasticum papillary dermal elastolysis (PXE-PDE), which is a second age-related fibroelastolytic syndrome, was described in 1989. Patients are typically elderly women who present with yellow papules that often coalesce to form cobblestone plaques that predominantly involve the neck, supraclavicular regions, and flexural areas [13-14]. The absence or loss of elastic fibers in the papillary dermis and the absence of calcifications or fragmentation of the elastic fibers are characteristic of PXE-PDE. Similar to WFPN, this entity also has been associated with intrinsic aging [12-14]. As a result, the name fibroelastolytic papulosis of the neck (FEPN) was proposed in 1997 to include both WFPN and PXE-PDE [6].

Although FEPN has been proposed to include both WFPN and PXE-PDE, there are additional elastolytic disorders that should be noted. These include mid-dermal elastolysis (MDE), linear focal elastolysis (LFE), and papillary dermal elastolysis (PDE) [14]. MDE is a rare condition that is induced or aggravated by ultraviolet light exposure and presents with clinical features of fine wrinkles on the trunk, lateral neck, and upper extremities [14]. In MDE, there is loss of elastic fibers in the mid-dermis whereas the elastic tissue of the papillary and deep dermis are unaffected [14]. LFE is another uncommon condition that presents as asymptomatic palpable yellow striae-like bands across the lower back of elderly men [14]. Histopathologic features include

increased, clumped, and fragmented elastic fibers in the mid and deep dermis, which are separated by normal collagen [14]. Papillary dermal elastolysis is characterized by the presence of focal clumps of elastic fibers that alternate with areas that lack oxytalan and eulanin fibers in the papillary dermis [15].

WFPN is described as an age-related dermatosis. Although there is no natural regression of this condition, there are no treatments. One hypothesized approach is the application of a topical anti-oxidant to reduce free-radical induced aging [10].

References

1. Shimuzu H, et al. White fibrous papulosis of the neck: review of our 16 cases. *Nippon Hifuka Gakkai Zasshi* 1985; 95: 1077 [PMID: 4079076]
2. Shimizu H, et al. White fibrous papulosis of the neck: a new clinicopathologic entity? *J Am Acad Dermatol* 1989;20: 1073[PMID: 2666457]
3. Cerio R, et al. White fibrous papulosis of the neck. *Clin Exp Dermatol* 1991;16:224 [PMID: 1934580]
4. Joshi RK, et al. White fibrous papulosis of the neck. *Br J Dermatol* 1992;127:295 [PMID: 1390177]
5. Wang DG, Zhu WY. White fibrous papulosis of the neck: a Chinese case. *J Dermatol* 2005 Jun;32:497 [PMID: 16043928]
6. Balus L, et al. Fibroelastolytic papulosis of the neck: a report of 20 cases. *Br J Dermatol* 1997;137:461 [PMID: 9349351]
7. Siragusa M, et al. White fibrous papulosis of the neck in three Sicilian patients. *Australas J Dermatol* 1996;37:202 [PMID: 8961589]
8. Kim HS, et al. White fibrous papulosis of the neck. *J Eur Acad Dermatol Venereol* 2007; 2:419 [PMID: 17309485]
9. Moreira AP, et al. White fibrous papulosis of the neck: the first South American case. *Dermatol Online J* 2009; 15;15:9 [PMID: 19281714]
10. Song YC, et al. A case of fibroelastolytic papulosis on the neck of a young man. *Ann Dermatol* 2011;23:193 [PMID: 21747618]
11. Gencoglan G, et al. White fibrous papulosis of the neck. *Cutan Ocul Toxicol* 2011;30:69 [PMID: 20954818]
12. Minagawa A, et al. Dermoscopy of white fibrous papulosis of the neck. *Arch Dermatol* 2010;146:220 [PMID: 20157048]
13. Rongioletti F, Rebora A. Fibroelastolytic patterns of intrinsic skin aging: pseudoxanthoma-elasticum-like papillary dermal elastolysis and white fibrous papulosis of the neck. *Dermatology* 1995;19:19 [PMID: 8589477]
14. Alves R, et al. Pseudoxanthoma elasticum papillary dermal elastolysis: a case report. *Dermatol Res Pract Epub* 2010 Aug 16 ahead of print [PMID: 20827433]
15. Wang AR, et al. Papillary dermal elastosis: a unique elastic tissue disorder or an unusual manifestation of pseudoxanthoma elasticum-like papillary elastolysis? *J Cut Pathol* 2009;36:1010 [PMID:19210582]