

## **UC Davis**

### **UC Davis Previously Published Works**

**Title**

Dermatology Eponyms - sign -Lexicon (K)

**Permalink**

<https://escholarship.org/uc/item/4qj837q8>

**Journal**

Our Dermatology Online, 5(1)

**Author**

Brzezinski, Piotr

**Publication Date**

2014

Peer reviewed

**DERMATOLOGY EPONYMS – SIGN – LEXICON – (K)**

Piotr Brzeziński<sup>1</sup>, David F. Fiorentino<sup>2</sup>, Pavai Arunachalam<sup>3</sup>,  
Ioannis Katafigiotis<sup>4</sup>, Łukasz Matuszewski<sup>5</sup>, Masashi Narita<sup>6</sup>,  
Yuko Ono<sup>7</sup>, Rahul Shetty<sup>8</sup>, Anca Chiriac<sup>9</sup>, Ahmad Abdulaziz<sup>10</sup>

<sup>1</sup>*Dermatological Clinic, 6th Military Support Unit, Ustka, Poland*

<sup>2</sup>*Division of Immunology and Rheumatology, Stanford University, USA*

<sup>3</sup>*Department of Pediatric Surgery, PSG Medical College Hospital, Coimbatore, Tamil Nadu, India*

<sup>4</sup>*1st University Urology Clinic Laiko Hospital, University of Athens, Athens, Greece*

<sup>5</sup>*Pediatric Orthopedic and Rehabilitation Department, Medical University of Lublin, Lublin, Poland*

<sup>6</sup>*Department of Medicine, Ohta Nishinouchi General Hospital, Nishinouchi 2-5-20 Koriyama, Fukushima, Japan*

<sup>7</sup>*Critical Care Center, Ohta General Hospital Foundation, Ohta Nishinouchi Hospital 2-5-20 Nishinouchi, Koriyama, Fukushima, Japan*

<sup>8</sup>*Department of Plastic and Reconstructive Surgery, Christian Medical College, Vellore, India*

<sup>9</sup>*Dermato-Physiology Department, Apollonia University Iasi, Strada Muzicii nr 2, Iasi-700399, Romania*

<sup>10</sup>*Department of General Surgery, District Hospital, Ilawa, Poland*

Source of Support:

Nil

Competing Interests:

None

**Corresponding author:** Piotr Brzezinski, MD PhD

[brzezo77@yahoo.com](mailto:brzezo77@yahoo.com)

Our Dermatol Online. 2014; 5(1): 95-102

Date of submission: 15.09.2013 / acceptance: 20.12.2013

**Abstract**

Eponyms are used almost daily in the clinical practice of dermatology. And yet, information about the person behind the eponyms is difficult to find. Indeed, who is? What is this person's nationality? Is this person alive or dead? How can one find the paper in which this person first described the disease? Eponyms are used to describe not only disease, but also clinical signs, surgical procedures, staining techniques, pharmacological formulations, and even pieces of equipment. In this article we present the symptoms starting with (K) and other. The symptoms and their synonyms, and those who have described this symptom or phenomenon.

**Key words:** eponyms; skin diseases; sign; phenomenon

**Cite this article:**

Piotr Brzezinski, David F Fiorentino, Pavai Arunachalam, Ioannis Katafigiotis, Łukasz Matuszewski, Masashi Narita, Yuko Ono, Rahul Shetty, Anca Chiriac, Ahmad Abdulaziz. *Dermatology Eponyms – Sign – Lexicon – (K)*. *Our Dermatol Online*. 2014; 5(1): 95-102.

**KAPOSI'S SIGN**

Syn. Xeroderma pigmentosum (Fig. 1) [1].

**MORITZ KAPOSI KOHN**

Austrian dermatologist (1837-1902) (Fig. 2). Kaposi was an important Hungarian dermatologist, discoverer of the skin tumor that received his name (Kaposi's sarcoma). Born to a Jewish family, originally his surname was Kohn, but with his conversion to the Fig. 22 Moritz Kaposi Catholic faith he changed it to Kaposi. In 1855 Kaposi began to study medicine at the University of Vienna and attained a doctorate in 1859. In his dissertation, titled *Dermatologie und Syphilis* (1866)

he made an important contribution to the field. Kaposi was appointed as professor at the University of Vienna in 1875, and in 1881 he became member of the board of the Vienna General Hospital and director of its clinic of skin diseases. He was authored the book *Lehrbuch der Hautkrankheiten* (Textbook of Skin Diseases) in 1878. Kaposi's main work, however, was *Pathologie und Therapie der Hautkrankheiten in Vorlesungen für praktische Ärzte und Studierende* (Pathology and Therapy of the Skin Diseases in Lectures for Practical Physicians and Students), published in 1880, which became one of the most significant books in the history of dermatology.

He is credited with the description of xeroderma . pigmentosum („Ueber Xeroderma pigmentosum. Medizinische. Jahrbücher, Wien, 1882: 619-633”). In all, he published over 150 books and papers [2-5].

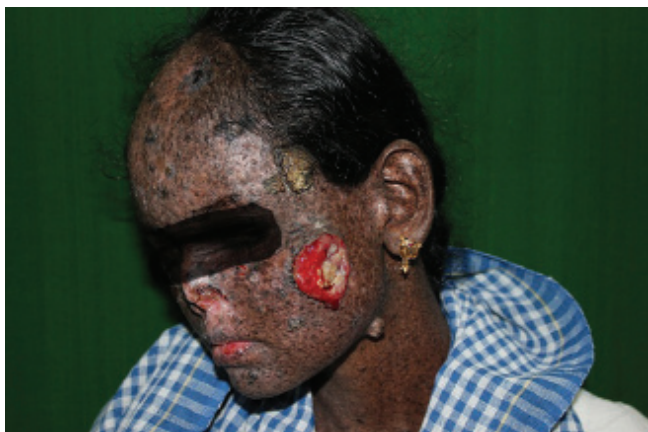

Figure 1. Kaposi’s sign. Xeroderma pigmentosum in a 19 years of age female.



Figure 2. Moritz Kaposi Kohn.

#### THE KASABACH-MERRITT PHENOMENON

Large congenital hemangiomas may result in shunting of blood and high-output cardiac failure or entrapment of platelets and a thrombocytopenic coagulopathy and a potentially life-threatening hemorrhage (the Kasabach–Merritt syndrome or phenomenon) (Fig. 3). The pathogenesis of congenital hemangiomas is poorly understood. There is an association with prematurity. Kasabach-Merritt phenomenon is a rare, life-threatening condition in which either of two specific vascular tumors (tufted angioma or kaposiform hemangioendothelioma) traps and destroys platelets, which are a component of blood that helps clotting. This condition is also associated with other abnormal clotting conditions in which there is excessive consumption of clotting factors. Kasabach-Merritt phenomenon does not occur in children with infantile hemangiomas.

Tumors usually occur shortly after birth and are equally common in males and females. These tumors can involve any area of the body but most commonly involve the extremities. They are usually associated with skin changes. In the area of the lesions, the skin appears firm, warm, and purple.

Tumors also can involve internal organs and can be serious

when they occur deep within the retroperitoneum (abdomen). As the tumor grows, it causes more platelet trapping. This is associated with abnormal clotting and utilization of clotting proteins, creating a deficiency in these proteins. Because of this, bleeding can occur and can be fatal [6].

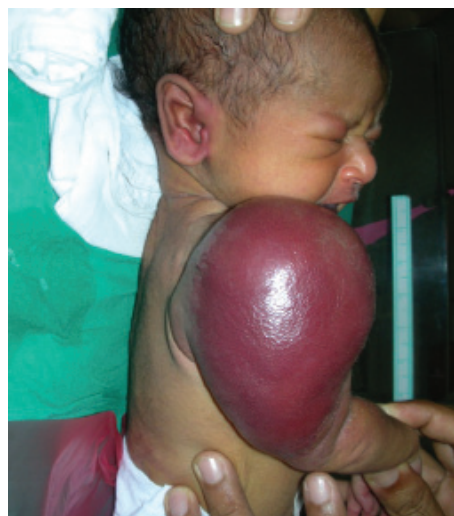

Figure 3. Kasabach–Merritt phenomenon.

---

#### KATAYAMA SIGN

Anemia with painful enlargement of the spleen and liver caused by the zoonotic microorganism *Schistosoma japonicum* [7].

---

#### KEDANI SIGN

An epidemic disease of Japan due to a zoonotic proteus implanted by the bite of a mite (kedani). It is marked by fever, swelling of the lymph-glands, and an exanthematous eruption fever [8,9]. Synonym: akamushi disease, flood fever, inundation fever, island disease, island fever, Japanese river fever, kedani fever, mite typhus, scrub typhus (Fig. 4,5), shimamushi disease, tropic typhus, tsutsugamushi.

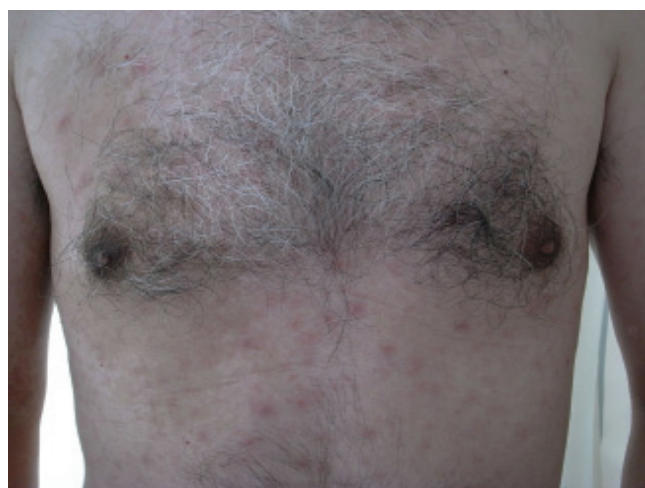
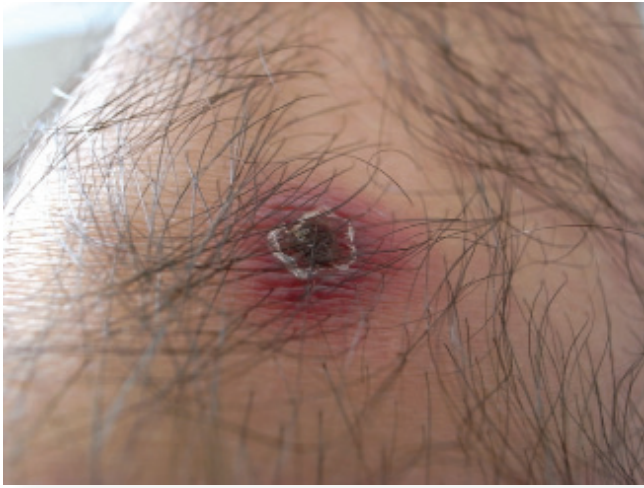

Figure 4. Scrub typhus. Rash on trunk: macular, not popular, without itchiness, pain nor tenderness.



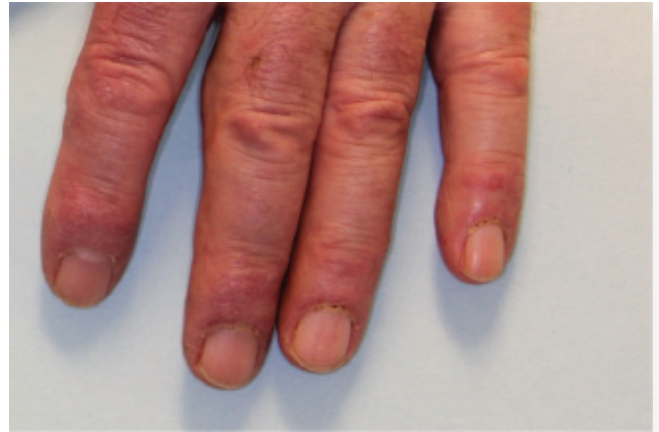**Figure 5. Scrub typhus. Eschar with surround peered scale and erythema inside of the right knee.**

### KEINING SIGN

bleeding nail fold in dermatomyositis [10] (Fig. 6).

“Classic” DM in adults has various clinical and pathological features, which do not always appear simultaneously or with the same severity. Dermatomyositis is identified by a characteristic rash, which appeared simultaneously or, more commonly, preceded muscle weakness. In addition to manifesting clinical and laboratory evidence of myositis, adult patients with classic DM develop the hallmark cutaneous findings. Cutaneous manifestations of DM could be classified as photosensitive, hyperkeratotic, and vascular. Photosensitive lesions consist of heliotrope rash, a periorbital, dusky, violaceous erythema of one or both eyelids. Heliotrope rash could be a component of a more confluent erythema involving the entire face in many cases associated with edema, and erythematous exanthemas on discrete areas of the body: the neck, and anterior chest (in a V-sign) or the nape of the neck and the posterior aspect of the shoulders (shawl-sign), knees, elbows, and malleoli. An erythematous rash may also be found on the face in a limited malar distribution, or more extensively with perioral sparing. This erythema can extend to the ears and scalp. The lesions are pruritic, and can be exacerbated after exposure to the sunlight. Gottron rash is a characteristic feature, with violaceous to dusky, red, flat-topped papules and plaques prominent on dorsal interphalangeal joints, elbows, and knees and, rarely, the malleoli. These papules evolve over time to have depressed, atrophic, porcelain white centers and prominent telangiectasias known as Gottron’s sign over bony prominences.

A rare subgroup of patients have follicular hyperkeratosis, which may occur as a pit-yriasis rubra pilaris-like eruption (Wong-type DM). The lateral and palmar areas of the fingers may become rough with cracked, “dirty” horizontal lines, resembling “mechanic’s hands”, and dilated capillary loops with punctate infarcts at the base of the fingernails with irregular, thickened, and distorted cuticles could be prominent. Scalp involvement is frequently evident as a diffuse, erythematous, scaly, atrophic dermatosis with mild-to-moderate alopecia. Cutaneous vasculitis is seen as palpable purpura and digital or oral ulcerations [11-13].



**Figure 6. Keining sign.**

### EGON KEINIG

German dermatologist (1892-1971). [14] (Fig. 7).



**Figure 7. Egon Keining.**

His interest in medicine woken early by the medical profession of his father. During his medical studies he created through his special study of botany and zoology, and his practical activity in the serological and bacteriological department of the Hygiene Institute of the University of Bonn

all requirements for a successful career in the field of Dermato-Venereology. In 1927, he accepted an offer from Mulzer at the Department of Dermatology in Hamburg-Eppendorf, where he worked as a senior physician from 1930 to 1940. This period also fell Habilitation (1929) and the appointment as Adjunct Professor. His unpublished habilitation thesis on „The atypical myxedema of the skin”, also known as „Myxoedema circumscriptum basedowianum (Keining )” has entered the literature. In 1940 he was appointed deputy professor of dermatology in Rostock, where he returned for a short time back in its old sphere of influence in Hamburg-Eppendorf to 1944 to take over the chair of dermatology in Greifswald, where he remained until 1946. His particular interest was in clinical morphological issues. Recall the initial recognition of the „Spring perniosis”, the description of the nail phenomenon in dermatomyositis, his works, which were concerned with the prominence of the seasonally -bound type of Erythema exsudativum multiforme of the type annuus, also his contributions over Lymphocytoma cutis circumscripta, scleroedema, Scleromyxoedema, Zoster generalisatus, Epidermolysis bullosa hereditaria hyperplastica, Cutis marmorata congenita, Epithelioma calcificans Malherbe, Graham -Little syndrome, miliary Lymphocytome, keratosis verrucosa Weidenfeld, Acrodermatitis continua suppurativa, nail lesions in psoriasis, etc. To him we owe the clear detection of the importance of skin constitutional types (seborrhea, sebastasis) for an adequate dermatotherapy .

He contributed significant contributions, was particularly interested again and again of syphilis therapy to their problems he often remanded position particularly after the introduction of penicillin in publications and presentations and has developed practical guidelines, as well as a look at the textbook by Keining and Braun-Falco reveals (1961).

### KERANDEL'S SIGN

Deep hyperesthesia accompanied by pain, often retarded, after some slight blow upon a bony projection of the body; seen in zoonotic African trypanosomiasis [15,16].

Kerandel's sign = Hyperreflexia ± ataxia and unsteadiness ± behavioural abnormalities, psychosis.

### JEAN FRANÇOIS KÉRANDEL

French physician in Africa (1873-1934). The author sign of Kerandel and Kerandel's symptom (deep-seated hyperesthesia observed in cases of sleeping sickness).

In 1913 Dr Kerandel, a trainee of the Passeur course on Microbes established a Microbiology laboratory in Phnom Pehn (Cambodia).

### KIDNEY WORM SIGN

Renal colic, hematuria, and flank pain, associated with infection from the giant zoonotic roundworm *Diocotophyma renale*. Caused by the ingestion of frog's liver and infected fish [17] (Fig. 8 a-c). Histologic sections showed a cyst with a fibrous wall, covered focally of a single epithelial layer. The content of the cyst was consistent with hemorrhagic, necrotic elements, containing some "ring" shaped structures, necrotic as well. The outer cover of them was Periodic acid-Schiff (PAS) and Giemsa positive. Within the structures, there was a material, which could not be further evaluated (Fig ). These findings were not pathognomonic, but were consistent with the presence of a dead nematodes parasite, likely of *Diocotophyma renale* type, as it is indicated by the lesion's site.

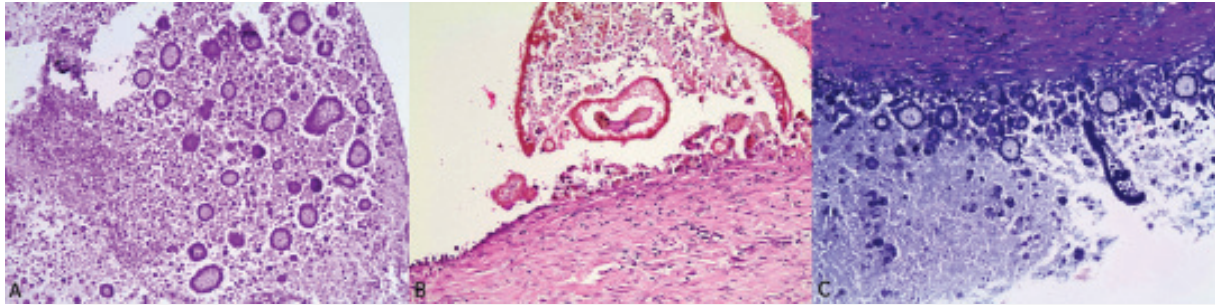


Figure 8 A-C. Fibrous wall of a cyst with necrotic material, which contains small "ring" shaped structures. An almost longitudinal sectioned structure is also seen, filled with a material, not further identified. (H+E, X100).

### KILLER X SIGN (c. 1940, South Eastern USA)

A hemorrhagic disease carried by tiny biting gnats commonly called „no-see-ums” or midges that can infect wildlife. Also called blue or black tongue death [18].

*Ceratopogonidae* (Fig. 9), or biting midges (including what are called, in the United States and Canada, no-see-ums, midgies, sand flies, punkies, and others), are a family of small flies (1–4 mm long) in the order Diptera. In Spain they are referred to as Flying Teeth. They are closely related to the Chironomidae, Simuliidae (or black flies), and Thaumaleidae.



Figure 9. *Ceratopogonidae*.

### KIRMISSON'S SIGN

Transverse striated ecchymoses at the elbow (Fig. 10 a, b). A sign seen in fractures of the humerus with displacement of the proximal fragment [19].

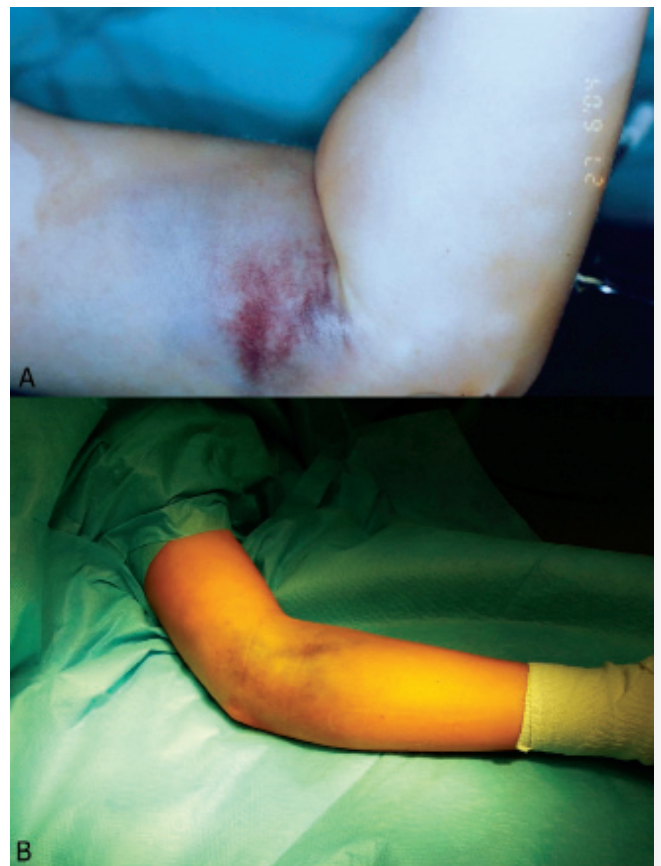


Figure 10 A, B. Kirmisson's sign.

### EDOUARD FRANCIS KIRMISSON

French paediatric surgeon (1848-1927) (Fig. 11). He specialized in pediatric and orthopedic surgery. Kirmisson studied medicine at the École de Médecine in Paris, and later worked as an externe under Noël Guéneau de Mussy (1813–1885) at the Hôtel-Dieu. In 1879 he earned his medical doctorate, obtaining his agrégation in 1883. He spent the following years as a surgeon of Parisian hospitals, becoming a professor of pediatric surgery and orthopedics at Hôpital des Enfants-Malades in 1901. In 1890 Kirmisson founded the journal *Revue d'orthopédie*. In 1903 he became a member of the Académie de Médecine [20].



Figure 11. Kirmisson's sign.

### KOCH'S PHENOMENON SIGN

If a guinea pig which has been previously infected with tuberculosis organisms is reinjected intracutaneously, the skin over the injected area undergoes necrosis and a superficial ulcer develops. The ulcer heals quickly and infection of regional lymph nodes is retarded. The phenomenon demonstrates development of ability to localize tubercle bacilli [21].



Figure 12. Robert Koch.

### ROBERT KOCH

German bacteriologist (1843-1910) (Fig. 12). The founder of modern bacteriology, is known for his role in identifying the specific causative agents of tuberculosis, cholera, and anthrax and for giving experimental support for the concept of infectious

disease. In addition to his pioneering studies on these diseases, Koch created and improved significant laboratory technologies and techniques in the field of microbiology, and made a number of key discoveries pertaining to public health. His research led to the creation of Koch's postulates, a series of four generalized principles linking specific microorganisms to particular diseases which remain today the "gold standard" in medical microbiology. As a result of his groundbreaking research on tuberculosis, Koch received the Nobel Prize in Physiology or Medicine in 1905 [22].

### KOEBNER SIGN

The appearance of isomorphic lesions at the site of an injury in lichen planus, warts, molluscum contagiosum (Fig. 13), psoriasis, or lichen nitidus along a site of injury [23-27].

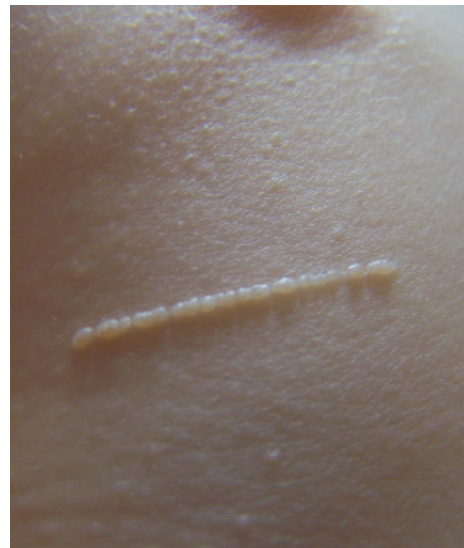

Figure 13. Koebner sign in molluscum contagiosum.

### HEINRICH KOEBNER (HEINRICH KÖBNER)

German dermatologist (1838-1904) (Fig. 14). Heinrich Köbner was one of the outstanding dermatologists of the nineteenth century. He studied in Berlin from 1855 to 1859 and obtained his medical doctorate at Breslau in 1859. After hospital service in Vienna with Ferdinand von Hebra (1816-1880) and Paris with Alfred Hardy (1811-1893) he settled in Breslau where he initiated the first policlinic for syphilis and diseases of the skin in 1861.

Köbner received his *venia docendi* (habilitation) at the University of Breslau in 1869 and in 1872 was appointed to the newly established chair. In 1876 he also became director of the university policlinic for diseases of the skin and syphilis which had been established at his initiative. However, due to health problems, he was forced to make a sustained stay at southern health resorts and to lay down his positions. He then moved to Berlin where in 1884 he built a new policlinic at which he gave courses for physicians.

His initial observations and studies of the phenomenon that bears his name resulted from having seen patients who had developed psoriasis at sites of excoriations, horse bites, and tattoos.

He presented the phenomenon at a meeting of the Silesian Society for National Culture in 1872.

In 1893 Heinrich Köbner was elected member of the German Academy of Natural Scientists Leopoldina. In 1897 he was appointed Geheimer Medicinalrat [28,29].



Figure 14. Heinrich Köbner.

---

### KONZO SIGN

Irreversible paralysis of the legs, caused by ingesting cassava, a Nigerian fruit containing the glycoside linamarin (Fig. 15) [30].



Figure 15. *Manihot esculenta*.

---

### KOOL-AID SIGN

Reported sweet fruity grape odor of *Pseudomonas aeruginosa* [31].

---

### KOPLIK'S SIGN

The appearance of a crop of buccal macules consisting of small dark red spots surrounded by minute white specks (Fig. 16). A sign found in the prodromal stage of measles [32].

---

### HENRY KOPLIK

American paediatrician (1858-1927) (Fig. 17). Henry Koplik

graduated M.D. from Columbia University, New York in 1881 and then studied in Berlin, Vienna, and Prague. He took a postgraduate course at the universities of Leipzig, Prague, and Vienna, and upon his return to America, established himself as a physician in New York in 1883. There, he became connected with Bellevue Hospital, the Good Samaritan Dispensary, and other medical institutions. In 1899, he was hired as an assistant professor of pediatrics at Bellevue Medical College. He worked for 25 years at the Mount Sinai Hospital, where he established a children's pavilion. He also introduced the free delivery of Pasteurized milk to the needy poor, in which he was followed later by Nathan Straus. Koplik was the first to describe an early diagnostic sign in measles, since known as „Koplik's spots”; and he found, too, the bacillus of whooping-cough. Henry Koplik was one of the founders of the American Paediatric Society. Besides essays in the medical journals, Koplik published his „Diseases of Infancy and Childhood” in 1902 [33].

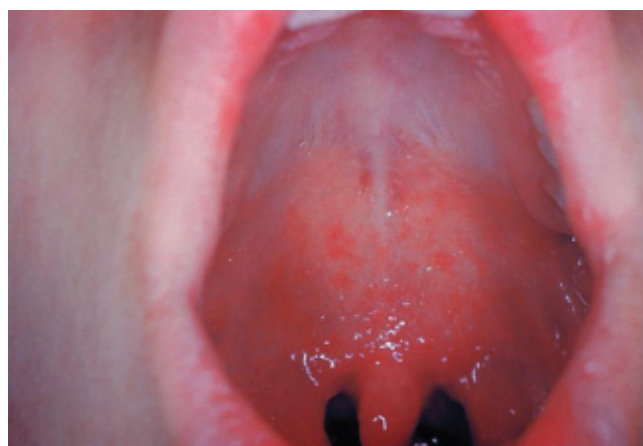

Figure 16. Koplik's sign.



Figure 17. Koplik's sign.

---

### KRISKOWSKY'S SIGN

The presence of cicatricial lines which radiate from the mouth. A sign of inherited syphilis. Also known as Krisovski's sign and Krisowski's sign.

---

### MAX KRISOVSKI

late 19th century German physician.

---

## KRISOVSKI'S SIGN

See - Kriskowsky's sign.

---

## KURU SIGN

Trembling, loss of the ability to walk, talk, and eat. Eventually ending with death. A sign of the fatal brain disease Kuru caused by cannibalism. Kuru means trembling with fear in the Fore language [34,35]. Also known as Laughing Death sign.

Vincent Zigas discovered kuru in 1956, a very rare degenerative brain disorder that occurred primarily among the Fore natives in Papua New Guinea (ZIGAS, 1981). One year later he was joined by Carleton Gajdusek who initiated systematic investigation of kuru and received the Nobel prize of Physiology or Medicine for his work in 1976.

William Hadlow noticed similarities between kuru and scrapie at a neuropathological and clinical level. He recommended transmission experiments to apes in 1959. Gajdusek succeeded in the transmission of kuru via intracerebral inoculation of chimpanzees with kuru infected brain homogenates a few years later

The by far the most investigated form of acquired human prion diseases is kuru which

occurred among the Fore people in the highlands of eastern Papua New Guinea. The spread of disease was based on ritual cannibalism of deceased members of the community and reached epidemic proportions.

## DANIEL CALTON GAJDUSEK

Hungarian-Slovak-American physician and medical researcher (virologist and paediatrician) (1923-2008) (Fig. 18). In 1976 won the Nobel Prize for his work on kuru.



Figure 18. Daniel Calton Gajdusek.

## MICHAEL PHILIP ALPERS

Australian medical researcher (Fig. 19), and John Curtin distinguished Professor of International Health, at Curtin University. He is an eminent scientist who has spent half a century conducting medical research in Papua New Guinea (PNG). Best known for his research on the brain disease, kuru, Alpers was made a Fellow of the Royal Society in 2008. Alpers graduated from University of Adelaide with a B.Sc. and M.B.B.S. and from University of Cambridge with an M.A. After graduating, he commenced a career, ultimately resulting

in investigating kuru disease. He is Honorary Senior Research Associate University College London [36].



Figure 19. Michael Philip Alpers.

---

## KYASANUR SING (India)

Rash, fever, bradycardia, the patient then appears to be getting better and is then attacked by meningoencephalitis. Caused by the bite of a tick infected with the zoonotic Kyasanur forest Flaviviridae virus [37].

---

## Acknowledgement

- for informations about EGON KEINIG:  
Prof. Gerd Plewig - Department of Dermatology and Allergology, Ludwig-Maximilian-University, Munich, Germany.
- Dr Khalid Al Aboud - Department of Public Health, King Faisal Hospital, Makkah, Saudi Arabia.
- for Figure of Xeroderma pigmentosum:  
Dr Aashish Shashidharan, Dr Elvino Barreto and Dr Kingsly Paul M - Department of Plastic and Reconstructive Surgery, Christian Medical College, Vellore, India
- for information about Kirmisson's sign:  
Ass. Prof. Julfiqar - Department of Orthopaedics, Teerthanker Mahaveer Medical College & Research Centre (TMMCRC); Moradabad, UP, India

## REFERENCES

1. Shetty R, Sashidharan S, Barreto E, Paul KM. Varied Malignant presentations in a single case of xeroderma pigmentosum. *Our Dermatol Online*. 2013;4:493-5.
2. Brzeziński P, Wass J, White K, Daboul MW, Arlt W, van den Hombergh P, et al. Dermatology eponyms – phenomenon / sign – Dictionary (A) – continued. *N Dermatol Online*. 2011;2:27-34.
3. Al Aboud K, Al Aboud A. Eponyms in the dermatology literature linked to Austria. *Our Dermatol Online*. 2013;3(Suppl.2):433-4.
4. Al Aboud K, Al Aboud A. Eponyms in the dermatology literature linked to the skin and soft tissue tumors. *Our Dermatol Online* 2013;4:389-91.
5. Al Aboud K, Al Aboud A. Eponyms in the dermatology literature linked to the vascular tumors. *Our Dermatol Online*. 2013;4:392-4.



6. Choi JW, Na JI, Hong JS, Kwon SH, Byun SY, Cho KH, et al. Intractable Tufted Angioma Associated with Kasabach-Merritt Syndrome. *Ann Dermatol*. 2013;25:129-30.
7. Ross AG, Vickers D, Olds GR, Shah SM, McManus DP. Katayama syndrome. *Lancet Infect Dis*. 2007;7:218-24.
8. Ono Y, Ikegami Y, Tasaki K, Abe M, Tase C. Case of scrub typhus complicated by severe disseminated intravascular coagulation and death. *Emerg Med Australas*. 2012;24:577-80.
9. Yoshimoto T, Yoshimoto T. Scrub typhus without eruption. *Am J Trop Med Hyg*. 2012;86:559.
10. Kunte Ch, Plewig G. [The „Keining sign” in dermatomyositis]. *Hautarzt*. 1998;49:596-7.
11. Jeetun O, Jeewon R. A survey of nail infection and awareness among non-diabetic patients in Mauritius. *Our Dermatol Online*. 2013;4:265-71.
12. Ajili F, Bousseta N, Msakni I, Metoui L, Gharsallah I, Laabidi J, et al. Symptomatic macroglossia and tongue myositis in Dermatomyositis. *Our Dermatol Online*. 2013;4:176-8.
13. Dhavalshankh G, Dhavalshankh A, Masvekar V. Cutaneous manifestations of dermatomyositis in male patient: a rare report. *Our Dermatol Online*. 2013;4:168-71.
14. Weber G. [75th birth anniversary of Egon Keinig]. *Dermatol Wochenschr*. 1967; Nov 18;153(46):1258-9.
15. Brzezinski P, Sinjab AT, Masferrer E, Gopie P, Naraysingh V, Yamamoto T, et al. Dermatology Eponyms – sign –Lexicon (G). *Our Dermatol Online* 2012;3:243-57.
16. Lejon V, Bentivoglio M, Franco JR. Human African trypanosomiasis. *Handb Clin Neurol*. 2013;114:169-81.
17. Gu Y, Li G, Zhang J, Zhang Y. *Dioctophyma renale* infection masquerading as a malignancy. *Kidney Int*. 2012;82:1342.
18. Veronesi E, Antony F, Gubbins S, Golding N, Blackwell A, Mertens PP, et al. Measurement of the infection and dissemination of bluetongue virus in culicoides biting midges using a semi-quantitative rt-PCR assay and isolation of infectious virus. *PLoS One*. 2013;8:e70800.
19. Solberg BD, Moon CN, Franco DP, Paiement GD. Locked plating of 3- and 4-part proximal humerus fractures in older patients: the effect of initial fracture pattern on outcome. *J Orthop Trauma*. 2009;23:113-9.
20. [http://en.wikipedia.org/wiki/%C3%89douard\\_Kirmisson](http://en.wikipedia.org/wiki/%C3%89douard_Kirmisson)
21. Kato S, Tokunaga O, Yoshiyama T. [Analysis of Koch’s phenomenon by BCg vaccination with the multi-puncture method in Japan]. *Kekkaku*. 2010;85:777-82.
22. Schultz MG. Robert Koch. *Emerg Infect Dis*. 2011;17:547-9.
23. Puri N, Puri A. A study on lichen planus in children. *Our Dermatol Online*. 2013;4:303-5.
24. Chukwudi NL. Does pityriasis rosea Koebnerise? *Our Dermatol Online*. 2013;4:189-90.
25. Puri N. Infantile psoriasis treated successfully with topical calcipotriene. *Our Dermatol Online*. 2013;4:205-7.
26. Puri N, Puri A. Strict anatomical co existence and colocalization of vitiligo and psoriasis – a rare entity. *Our Dermatol Online*. 2013;4:202-4.
27. Rather PA, Hassan I. Blaschkoid lichen planus in an adult Kashmiri male: a rare presentation. *Our Dermatol Online*. 2013;4:79-82.
28. Kuner N, Hartschuh W, Khan-Durani B. [Heinrich Köbner and the „isomorphic phenomenon”. History and review of the literature]. *Hautarzt*. 2003;54:274-8.
29. Al Aboud K, Al Aboud D. Eponyms in the dermatology literature linked to Germany. *Our Dermatol Online* 2013;3(Suppl.2):429-32.
30. Yang Z, Wang Y, Xu S, Xu C, Yan C. Molecular evolution and functional divergence of soluble starch synthase genes in cassava (*Manihot esculenta* crantz). *Evol Bioinform Online*. 2013;9:239-49.
31. Cox CD, Parker J. Use of 2-aminoacetophenone production in identification of *Pseudomonas aeruginosa*. *J Clin Microbiol*. 1979;9:479-84.
32. Jiménez Gómez N, Ballester Martínez MA, Alcántara González J, Jaén Olasolo P. [Koplik spots as a diagnostic clue in a case of measles]. *Med Clin (Barc)*. 2012;139:560.
33. Markel H. Henry Koplik, MD, the Good Samaritan Dispensary of New York City, and the description of Koplik’s spots. *Arch Pediatr Adolesc Med*. 1996;150:535-9.
34. Liberski PP, Sikorska B, Lindenbaum S, Goldfarb LG, McLean C, Hainfellner JA, et al. Kuru: genes, cannibals and neuropathology. *J Neuropathol Exp Neurol*. 2012;71:92-103.
35. Gajdusek DC, Gibbs CJ, Alpers M. Experimental transmission of a Kuru-like syndrome to chimpanzees. *Nature*. 1966;209:794-6.
36. Spark C. Michael Alpers (FRS), Kuru, and Papua New Guinea: The Combined Allure of Problem, People, and Place. *Health History*. 2012;14: 26-45.
37. Mackenzie JS, Williams DT. The zoonotic flaviviruses of southern, south-eastern and eastern Asia, and Australasia: the potential for emergent viruses. *Zoonoses Public Health*. 2009;56:338-56.