

UC Davis

Dermatology Online Journal

Title

Trauma-related papular granuloma annular

Permalink

<https://escholarship.org/uc/item/7615b2nn>

Journal

Dermatology Online Journal, 19(12)

Authors

Hu, Stephanie W
Kaplan, Jennifer
Patel, Rishi R
et al.

Publication Date

2013

DOI

10.5070/D31912020719

Copyright Information

Copyright 2013 by the author(s). This work is made available under the terms of a Creative Commons Attribution-NonCommercial-NoDerivatives License, available at <https://creativecommons.org/licenses/by-nc-nd/4.0/>

Peer reviewed

Case Presentation

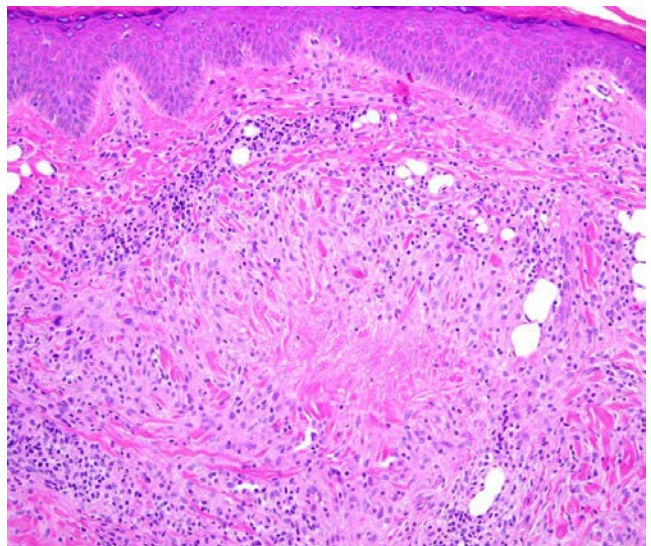
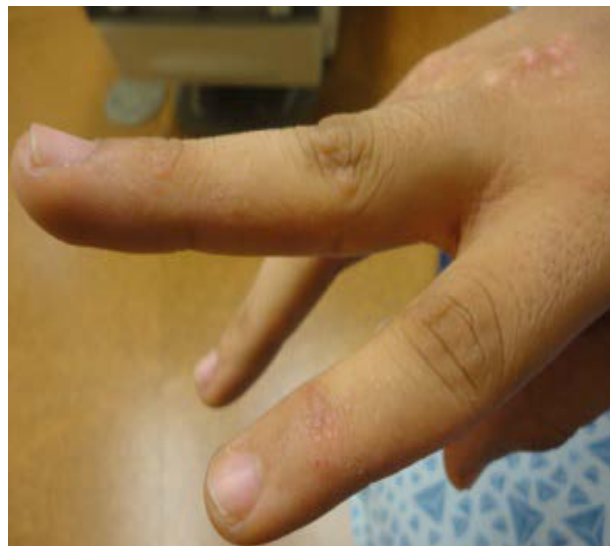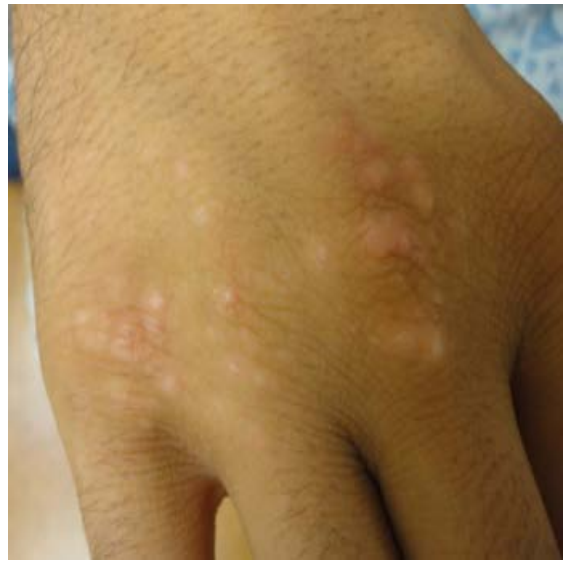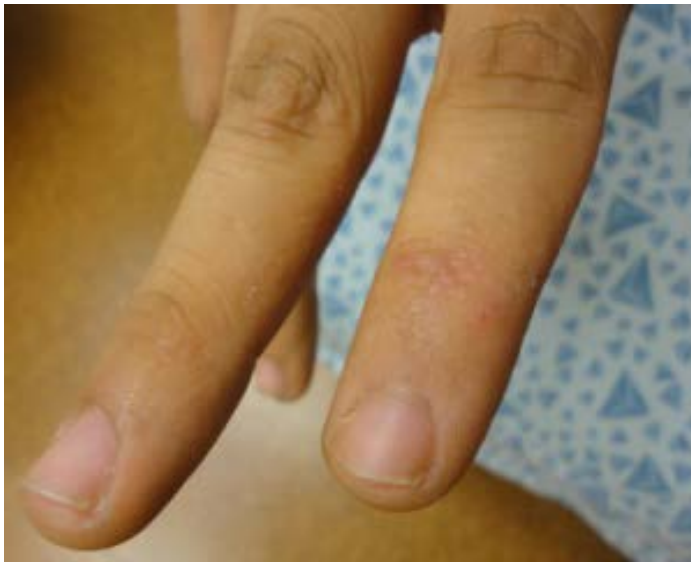Stephanie W. Hu, MD, Jennifer Kaplan, MD, Rishi R. Patel, MD, and Hideko Kamino, MD

Dermatology Online Journal 19 (12): 15

New York University School of Medicine

Abstract

Granuloma annulare (GA) is a benign, granulomatous disease with several clinical manifestations, which include localized, generalized, perforating, subcutaneous, patch, papular, and linear forms. We report a case of papular GA of the dorsal aspects of the hands that arose after repeated, direct trauma to the site of subsequent involvement. Although multiple etiologies for GA have been proposed, which include ultraviolet light, arthropod bites, trauma, tuberculin skin tests, viral infections, and PUVA photochemotherapy, the underlying pathogenesis of the disorder remains unclear. However, owing to the key histopathologic findings of focal collagen and elastic fiber degeneration and mucin deposition in GA, it is not surprising that cutaneous trauma may have played a role in connective tissue injury, subsequent degeneration, and the production of a granulomatous response with increased mucin deposition.



Case synopsis

A 21-year-old man presented with numerous skin-colored-to-hypopigmented papules over the dorsal aspects of the hands. The lesions were not associated with pain, pruritus, paresthesias, or bleeding. The lesions first appeared approximately three years prior to presentation after the patient punched the side of a refrigerator for fun. The lesions have slowly increased in number since that time and have become more elevated.

The patient is otherwise healthy and past surgical history included a broken wrist for which the patient was being followed by orthopedic surgery. According to the patient, no one else in the family had similar lesions.

Physical Examination: Numerous, discrete, skin-colored-to-hypopigmented, rubbery papules were present over the dorsal aspects of the metacarpal phalangeal joints of the hands.

Histopathology: A shave biopsy was performed on a representative papule. There is palisaded, granulomatous inflammation around deposits of connective-tissue mucin, which is highlighted with a colloidal iron stain.

Diagnosis: Papular granuloma annulare induced by trauma

Discussion: Granuloma annulare (GA) is a benign, relatively common, inflammatory dermatosis. Two-thirds of patients with GA are less than 30 years of age and the female-to-male ratio is approximately 2:1.

Clinically, GA classically presents as arciform-to-annular plaques that are located on the extremities. Recognized clinical variants include generalized GA, perforating GA, deep dermal or subcutaneous GA, and patch GA. GA also has been described as a paraneoplastic, granulomatous reaction to solid organ tumors, Hodgkin disease, non-Hodgkin lymphoma, and granulomatous mycosis fungoides [1-4]. In these patients, the clinical pattern frequently is atypical, with painful lesions in unusual locations, which include the palms and soles. In a retrospective study of 1383 patients, diabetes mellitus was diagnosed in 21% of patients with generalized GA compared with 9.7% of patients with localized GA [5]. Classic GA and perforating GA may occur in herpes zoster scars [6]. Atypical variants of GA have been associated with human immunodeficiency virus infection [7].

Papular GA occurs as asymptomatic, skin-colored or hypopigmented firm papules, 1-to-3 mm in size, on the dorsal aspects of the hands and most commonly affects children [8]. Perforating GA is a clinical form that is associated with central umbilication and presents as small, flesh-colored papules on the extremities, commonly in a localized distribution on the hands and fingers [8]. Papular umbilicated GA is considered to be a special subtype of papular GA [9]. The central umbilication of the lesions may correlate with focal collagen degeneration. However, in most cases, the degenerated connective tissue does not perforate. It is for this reason that a spectrum from papular GA to perforating GA has been proposed, with papular umbilicated GA being the intermediate form [8].

The precise etiology of GA is unknown. Trauma, insect bite reactions, tuberculin skin tests, sun exposure, PUVA photochemotherapy, and viral infections have been proposed as inciting factors. Proposed pathogenic mechanisms for GA include cell-mediated immunity, immune complex vasculitis, and an abnormality of tissue monocytes [8]. In our patient, the lesions arose at the site of direct trauma; a possible mechanism includes primary degeneration of the connective tissue at the site of cutaneous injury, which stimulated granulomatous inflammation, a lymphocyte-mediated immune reaction with macrophage activation, and cytokine-mediated degradation of connective tissue with increased deposition of mucin.

Localized GA is often not symptomatic and has a tendency towards spontaneous resolution. Whereas reassurance is often all that is necessary, various treatments have been employed, which include potent topical glucocorticoids with or without occlusion for four to six weeks and intralesional glucocorticoids. Cryotherapy using liquid nitrogen or nitrous oxide as refrigerants has been shown in a prospective, uncontrolled trial to be an effective treatment for localized GA. Secondary dyschromia may be a complication of cryotherapy [10]. Other anecdotal therapies for both localized and generalized GA include tacrolimus and pimecrolimus [11-13] and imiquimod cream [14].

References

1. Barksdale SK, *et al.* Granuloma annulare in patients with malignant lymphoma: clinicopathologic study of thirteen new cases. *J Am Acad Dermatol* 1994; 31: 42
2. Ono H, *et al.* Granuloma annulare in a patient with malignant lymphoma. *Dermatology* 1997; 195: 46

3. Cohen PR. Granuloma annulare associated with malignancy. *Southern Med J* 1997; 90: 1056
4. Wong WR, *et al.* Generalized granuloma annulare associated with granulomatous mycosis fungoides. *Dermatology* 2000; 200: 54
5. Studer EM, *et al.* Precipitating factors and associated diseases in 84 patients with granuloma annulare: a retrospective study. *Dermatology* 1996; 193: 364
6. Ohata C, *et al.* Granuloma annulare in herpes zoster scars. *J Dermatol* 2000; 27: 166
7. O'Moore EJ, *et al.* HIV-associated granuloma annulare (HAGA): a report of six cases. *Br J Dermatol* 2000; 142: 1054
8. Cho E, *et al.* Unusual presentations of papular umbilicated granuloma annulare. *J Dermatol* 2011; 38: 402
9. Lucky AW, *et al.* Papular umbilicated granuloma annulare: a report of four pediatric cases. *Arch Dermatol* 1992; 128: 1375
10. Blume-Peytavi U, *et al.* Successful outcome of cryosurgery in patients with granuloma annulare. *Br J Dermatol* 1994; 130: 494
11. Harth W, Linse R. Topical tacrolimus in granuloma annulare and necrobiosis lipoidica. *Br J Dermatol* 2004; 150: 792
12. Jain S, Stephens CJ. Successful treatment of disseminated granuloma annulare with topical tacrolimus. *Br J Dermatol* 2004; 150: 1042
13. Rigopoulos D, *et al.* Pimecrolimus 1% cream in the treatment of disseminated granuloma annulare. *Br J Dermatol* 2005; 152: 1364
14. Badavanis G, *et al.* Successful treatment of granuloma annulare with imiquimod cream 5%: a report of four cases. *Acta Derm Venereol* 2005; 85: 547