

UC Davis

Dermatology Online Journal

Title

Correspondence: The association between morphea profunda and monoclonal gammopathy:
A case series

Permalink

<https://escholarship.org/uc/item/857261f5>

Journal

Dermatology Online Journal, 22(3)

Authors

Endo, Justin
Strickland, Nicole
Grewal, Simer
[et al.](#)

Publication Date

2016

DOI

10.5070/D3223030372

Copyright Information

Copyright 2016 by the author(s). This work is made available under the terms of a Creative Commons Attribution-NonCommercial-NoDerivatives License, available at <https://creativecommons.org/licenses/by-nc-nd/4.0/>

Peer reviewed

Case presentation

Correspondence: The association between morphea profunda and monoclonal gammopathy: A case series

Justin Endo MD¹, Nicole Strickland BS², Simer Grewal BS², Travis Vandergriff MD², Thomas Keenan MD PhD¹, B Jack Longley MD¹, Heidi Jacobe MD²

Dermatology Online Journal 22 (3): 13

¹Department of Dermatology, University of Wisconsin, 1 South Park Street, 7th Floor, Madison, WI 53715, USA.

²Department of Dermatology, UT Southwestern Medical Center, 5323 Harry Hines Blvd., Dallas, TX 75390-9069, USA.

Correspondence:

Dr. Justin Endo.
Tel +1-608-287-2620
jendo@dermatology.wisc.edu

Abstract

It is known that eosinophilic fasciitis can be associated with monoclonal gammopathy. There is clinical similarity between eosinophilic fasciitis and morphea profunda, but it is unclear whether morphea profunda might be associated with monoclonal gammopathy. The temporal quantification of gammopathy in morphea profunda has not been well characterized. We describe four patients with morphea profunda that were associated with monoclonal gammopathy. Three were associated with monoclonal IgG protein and one with IgM. No patients in our series developed myeloma. In conclusion, the association of monoclonal gammopathy is not unique to eosinophilic fasciitis and scleromyxedema. Further studies are necessary to characterize further the relationship between the two conditions.

Keywords: morphea, gammopathy, gammaglobulinemia, eosinophilic fasciitis, fibrosing disorder, M-spike, plasma cell dyscrasia, monoclonal gammopathy of unknown significance, MGUS

Introduction

Disorders of cutaneous sclerosis are characterized by increased collagen deposition in the dermis and subcutis, leading to skin and tissue hardening, joint contracture, pain, and disability[1]. Deep morphea encompasses morphea profunda (MP), eosinophilic fasciitis (EF), and disabling pansclerotic morphea in children, which share common features including involvement of the underlying panniculus, fascia, or skeletal muscle[2]. In MP, sclerosis involves the subcutaneous fat, with development of a septal panniculitis with a predominately lymphoplasmacytic infiltrate[1]. Table 1 contrasts MP and EF. Progression of disease may lead to near-complete replacement of the subcutis with hyalinized connective tissue, leading to sclerosis and lipoatrophy. The etiology of MP remains poorly described [3].

Table 1. Contrasting features of morphea profunda and eosinophilic fasciitis[4-7].

	Morphea profunda	Eosinophilic fasciitis
--	------------------	------------------------

Histologic findings	Lymphocytes and/or plasma cells, absent or rare eosinophils. Mostly dermal or subcutaneous inflammation and sclerosis.	Lymphocytes and/or plasma cells, more abundant eosinophils. Mostly fascial inflammation and sclerosis.
Peripheral eosinophilia	No	Usually
Groove sign overlying vessels	No	Yes
Association with hypergammaglobulinemia	Not well characterized	Yes

Plasma cell dyscrasias have been reported as an association and possible pathophysiologic factor in a number of fibrosing skin disorders [8-13]. Monoclonal gammopathy of undetermined significance (MGUS) is the most common type of plasma cell dyscrasia [14]. It is an asymptomatic condition that is defined by the presence of a monoclonal protein (M-protein) < 3 g/dL, < 10% monoclonal plasma cells within the bone marrow, and absence of end-organ disease. The prevalence has been estimated to be approximately 4% and about 1% per year of MGUS patients might progress to myeloma over a lifetime.

Multiple myeloma patients with scleroderma-like changes have been reported, with skin change felt to be the result of direct infiltration by malignant cells [15]. Likewise, multiple myeloma leading to light chain amyloidosis and scleroderma-like illness has been reported. Although the majority of EF cases have a polyclonal expansion of immunoglobulin, there has been an association with hematologic malignancies and monoclonal gammopathy, particularly in EF that is refractory to therapy [13, 16]. To our knowledge, there is only 1 report describing MGUS associated with an unspecified type of morphea [10]. The temporal relationship between monoclonal protein quantity changes and morphea treatment has not been well characterized. We have identified four patients with MGUS and biopsy-proven MP.

Methods

Case definitions

Cases were retrospectively identified as having MP and documented gammopathy from the University of Wisconsin-Madison, the University of Texas Southwestern Medical Center, and Parkland Memorial Hospital. Patients with features of other sclerosing skin conditions (e.g., sclerodactyly, peripheral and tissue eosinophilia, polyneuropathy, organomegaly) were excluded. This project was considered institutional review board (IRB) exempt because it was a small case series.

Table 2. Patient demographic and clinical characteristics. n/a indicates data not available

	Case #1	Case #2	Case #3	Case #4
Sex	Female	Female	Male	Male
Age (y)	68	58	76	39
Race	White	Asian	White	White
BMI (kg/m²)	33.6	25.22	30.19	22.4
Tobacco use	No	No	Former Smoker, 20 pack years	No
Distribution of lesions	Bilateral upper and lower extremities, sparing palms, feet, and abdomen	Bilateral upper extremities, back, neck and cheeks	Chest, back, and bilateral upper and lower extremities	Near total body involvement, sparing face and scalp
Monoclonal protein (g/dL)	0.27	0.39	0.2	2.4
Immunofixation	IgM kappa	IgG lambda	IgG lambda	IgG lambda

Total protein (g/dL)	7.6	7.4	6.2	7.9
Hemoglobin (g/dL)	13.2	10.8	13.0	12.0
Total white blood cells (x 10³/μL)	6.7	4.37	9.9	8.7
Absolute peripheral eosinophils (x10³/μL)	0.0278	0.01	0.1	0.1
Erythrocyte sedimentation rate (mm/hr)	35	14	42	15
C-reactive protein (mg/dL)	2.9	0.1	n/a	1.6
Antinuclear antibody	Negative	Negative	n/a	Negative
Urine protein electrophoresis	Negative	Negative	n/a	Negative
Anti-SCL70 IgG	Negative	Negative	n/a	Negative
Lyme IgG, IgM	Negative	n/a	n/a	Negative
Bone marrow biopsy	n/a	Negative	n/a	Negative
Creatinine (mg/dL)	0.7	0.62	1.1	0.5
Calcium (mg/dl)	10.7	9.5	8.6	8.8
Skeletal survey	Negative	n/a	Negative	Negative

Table 3. Histologic features of four cases. SQ = subcutis, L=lymphocytes, P=plasma cells, E=eosinophils

Case #	Site	Compartments present	Compartments with sclerosis	Inflammatory infiltrate	Constituents of infiltrate	Lichen sclerosis
1	left forearm	dermis, SQ	dermis, SQ	mild	L, P, E	yes
1	right chest	dermis, SQ	dermis, SQ	mild	L, P	yes
1	left antecubital	dermis	dermis	mild	L	no
1	right antecubital	dermis, SQ	dermis, SQ	mild	L, P	no
2	left calf	SQ, fascia	SQ, fascia	dense	L, P, E	no
2	left neck	dermis, SQ	dermis, SQ	mild	L, P	yes
2	left thigh	dermis, SQ, fascia	dermis, SQ, fascia	moderate	L, P	yes
3	left thigh	dermis, SQ	atrophy in dermis	mild	L, P	no
3	left shin	dermis, SQ	atrophy in dermis	mild	L	no
4	left arm	dermis, SQ	none	mild	L	no
4	upper back	dermis, SQ	dermis	none	none	no
4	left arm	dermis, SQ	dermis	none	none	no

Case synopsis

Case #1

The patient is a 68-year-old woman, with a previous diagnosis of morphea involving the abdomen who was referred for acute onset of progressive induration of her forearms and legs, sparing the face, hands, and feet. She denied preceding injury, strenuous activity, or new medication or supplements. There was no history of chemotherapy, radiation therapy, or gadolinium exposure. She did not have Raynaud phenomenon, arthritis, or evidence of pulmonary or gastrointestinal involvement.

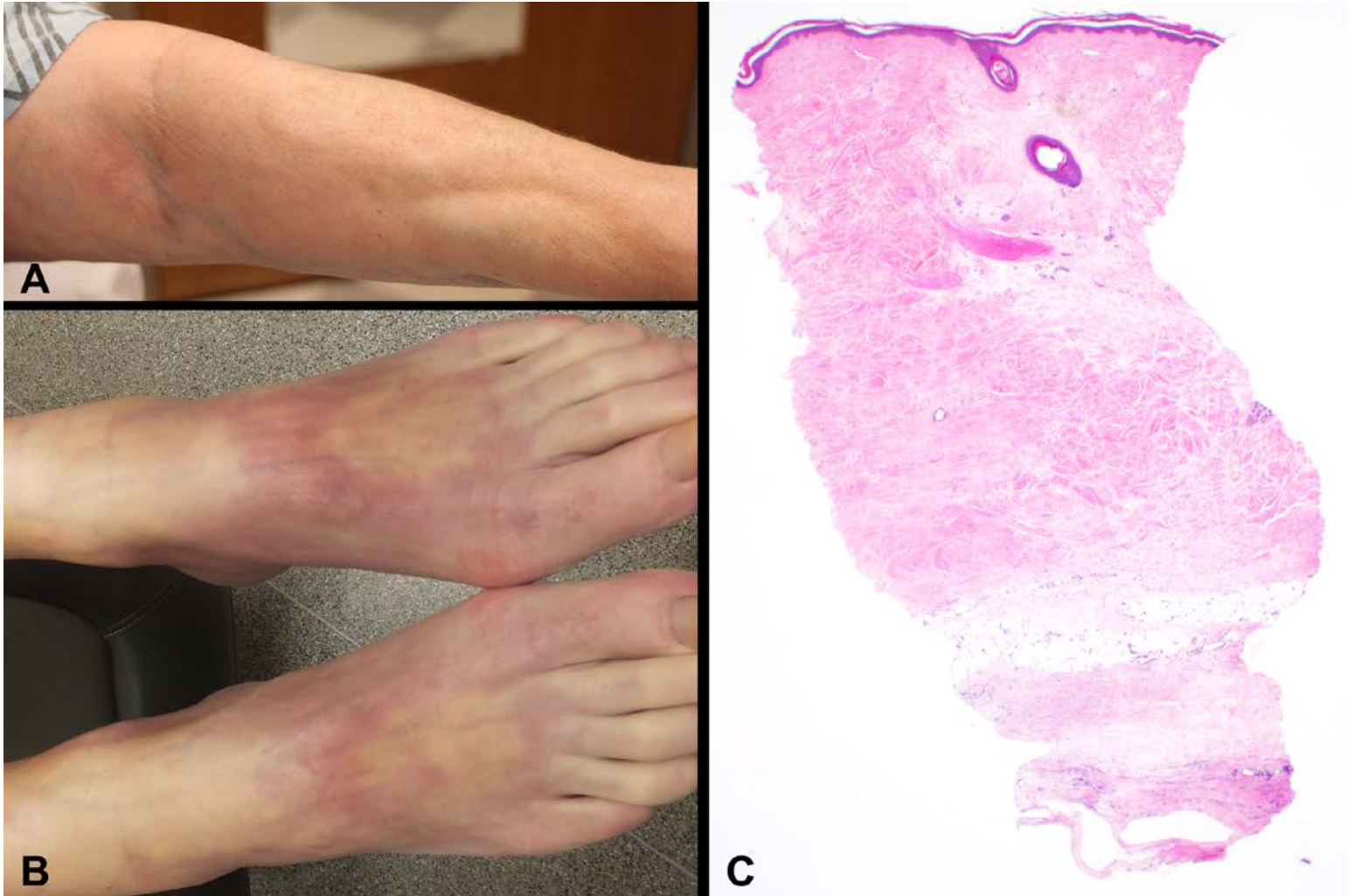


Figure 1. Representative clinical and histologic features of morphea profunda. A and B: violaceous plaques with induration and atrophy of the arms and feet of case #1, C: Histologic section stained with hematoxylin and eosin, 20x original magnification, reveals dense sclerosis extending from the papillary dermis to the subcutis

Clinical exam was notable for sclerosis of skin over the bilateral forearms from the antecubital fossae to the wrists, with similar changes over the bilateral shins and calves (Figure 1A and 1B). There was brawny induration at the periphery and within the areas of sclerosis. On the left shoulder there was thumbtack-like fibrosis and dimpling at sites of prior vaccination. Involving the abdomen there were multiple 2-3 cm ill-defined hyperpigmented somewhat atrophic plaques. The face, hands, and feet were spared; there were no telangiectasias, periungual changes, or calcinosis. IgM kappa M-protein was identified (0.27 g/dL) on serum protein electrophoresis (SPEP) with immunofixation, and skeletal survey was negative. Tables 2 and 3 summarize the laboratory and histologic findings, respectively.

She was diagnosed with MP with IgM MGUS. She was tapered off prednisone 60 mg daily and has remained on a maintenance dose of oral methotrexate 15 mg weekly. She also received physical therapy (PT) to maintain joint mobility. Disease progression halted. Symptoms including skin tightening significantly improved and prednisone was slowly tapered without disease flare. She was referred to the hematology department for evaluation after a coincidental M-protein was identified; X-ray skeletal survey was negative and she was given a diagnosis of IgM MGUS. She has been regularly monitored over 2 years without evidence of disease progression and her M-protein has remained lower than baseline.

Case #2

The patient is a 58-year-old woman with firm, indurated plaques over the back, bilateral upper extremities, neck, and bilateral cheeks. There was sparing of the breasts, abdomen, and legs. She had decreased range of motion of her upper extremities but denied pain or tenderness to palpation. There were no sclerodactyly, periungal capillary changes, or telangiectasias. She denied shortness of breath, difficulty swallowing, or Raynaud phenomenon. Serum protein electrophoresis with immunofixation was notable for IgG lambda M-protein (0.39 g/dL) and bone marrow biopsy was negative for increased plasma cells. Tables 2 and 3 summarize the laboratory and findings, respectively. A slight increase in interstitial mucin was noted in the skin biopsy.

She was diagnosed with pansclerotic morphea with IgG MGUS. She was started on prednisone 60 mg oral daily and methotrexate was initiated with plan to titrate to 20-25 mg oral weekly, along with physical therapy to maintain joint mobility. The patient reported softening of skin and improved range of motion of the upper extremities on these treatments. Prednisone was slowly tapered and discontinued after 4 months of treatment. Methotrexate dosage was increased to 17.5 mg weekly, then was slowly tapered to the current dose of 7.5 mg weekly owing to elevated liver function tests and improvement of sclerosis. She was referred to hematology/oncology department. It has been two years since her diagnosis; she continues regular monitoring by the dermatology, rheumatology, and hematology/oncology departments, with improving M-protein and no evidence of disease progression.

Case #3

The patient is a 76-year-old man who presented with porcelain white plaques with follicular plugging and cigarette paper atrophy over the posterior neck and sternum. The lower chest, abdomen, and lower back had poorly circumscribed erythematous reticulated, indurated plaques with varied degrees of sclerosis. The bilateral forearms showed deeply sclerotic, hidebound skin with a groove sign extending to proximal arm flexor surface with dimpling and *peau d' orange* changes with induration. These findings extended distally before abruptly stopping at the bilateral wrists. The bilateral calves had induration circumferentially and hyperpigmentation with venous varicosities. There was mild limitation of range of motion in the wrists, fingers and ankles. Serum protein electrophoresis with immunofixation revealed monoclonal IgG lambda (0.2 g/dL) M-protein and skeletal survey was negative. Tables 2 and 3 summarize the laboratory and histologic findings, respectively.

This patient was diagnosed with MP and IgG MGUS. He was started on methotrexate 20 mg once weekly and prednisone 60 mg daily, subsequently tapered to 25 mg daily. The plaques stopped spreading and the patient noted softening of previously involved areas. His skin disease remained stable for almost 2 years until he expired owing to metastatic lung cancer.

Case #4

This patient is a 38 year old man who presented with near total body involvement of xerosis and fissures at skin tension points, with sparing of face and scalp. Varying degrees of sclerosis were present with continuous involvement of trunk, upper and lower extremities, and dorsum of hands and feet. Limited range of motion was present in knees, ankles, feet, toes, and wrists. He denied any other complaints. He was found to have IgG lambda M-protein (2.4 g/dL) on SPEP with immunofixation and skeletal survey was negative. Tables 2 and 3 summarize the laboratory and histologic findings, respectively.

The patient was diagnosed with pansclerotic morphea and IgG MGUS. He was treated with methotrexate 20 mg per week and prednisone 10 mg daily. He was also started on UVA₁ phototherapy and has received 30 treatments owing to the severity of his lesions and symptoms. He was referred to PT and pain management. For 1.5 years, his morphea has improved with gradual softening of trunk lesions and stable area of involvement.

Discussion

Our case series demonstrates an association between MP and MGUS. Where data were available, a positive association between clinical disease activity and M-protein level were noted after initiation of therapy for MP (Figure 2). No patients have developed multiple myeloma over the 2-year follow up period.

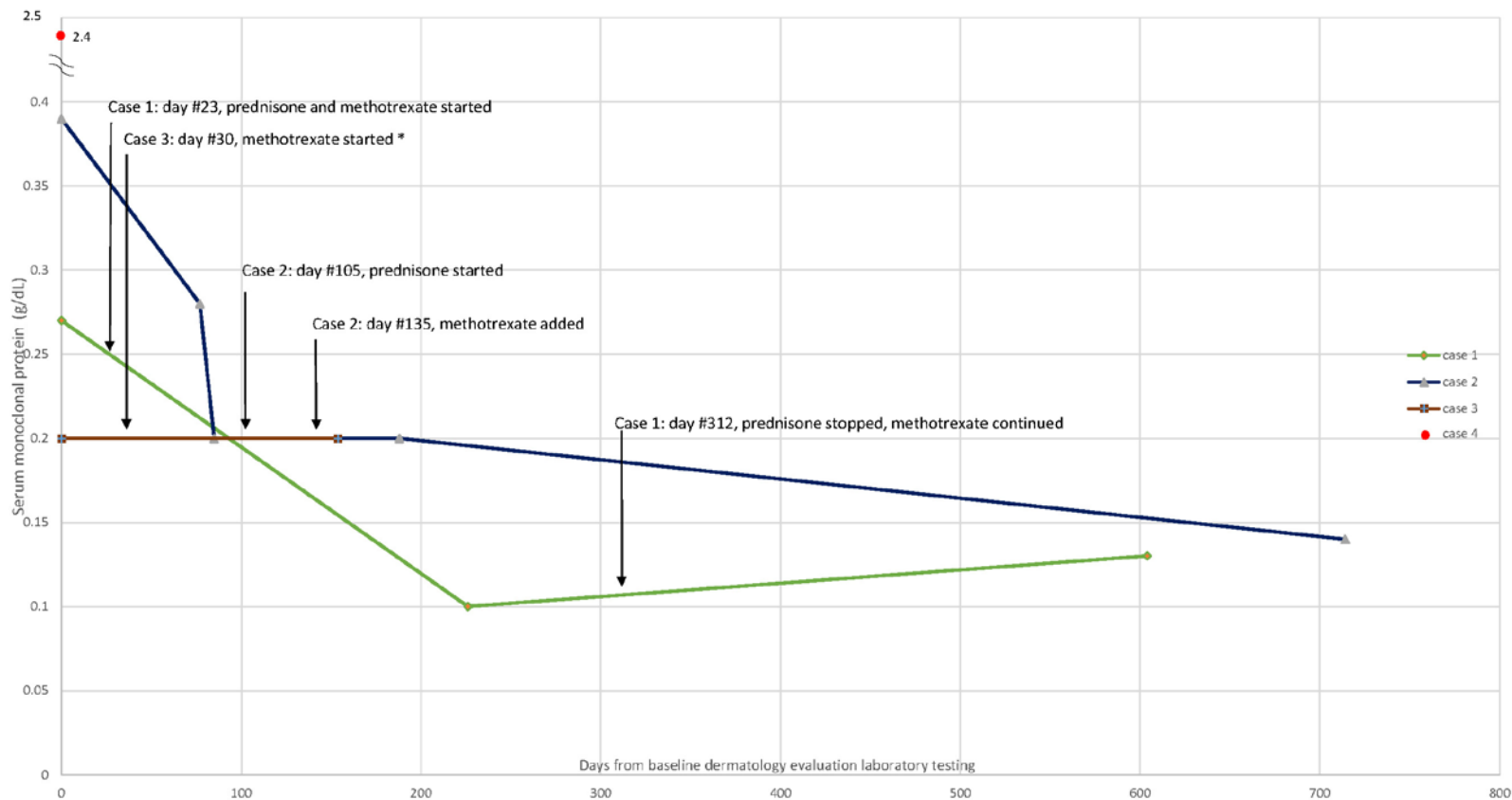


Figure 2. Monoclonal protein quantification among four reported cases with respect to morphea profunda treatment over time, where available. Note break in y-axis value labeling at double tilde. * indicates that case 3 was already on prednisone prior to initial monoclonal protein value. Case 4 did not have additional lab monitoring.

A case series of plasma cell dyscrasias occurring in sclerosing skin conditions was previously published by Magro et al. They described only 1 patient with an unspecified type of morphea being diagnosed after a lambda light chain restriction dyscrasia [10]. However, this case had no long-term follow-up. Our cases and that reported by Magro et al. raise the possibility that there may be a common link in pathogenesis between MP and MGUS. Autoimmune disorders arising in the context of M-proteins are thought to occur through complex mechanisms including: excess autocrine and paracrine factor secretion, local inflammation, non-specific immune dysregulation, or direct production of auto-antibodies by malignant cells [10].

There is some debate in the literature whether MP is a form of eosinophilic fasciitis, which was previously reported to be associated with MGUS [17]. The patients in this series, however, lacked the features typically associated with EF including peripheral eosinophilia and the presence of fascial eosinophils. The association between the presence of MP and MGUS may have occurred by chance alone. However, the trend of the M-protein levels improvement with treatment of the morphea implicates an association with the active phase of morphea. Owing to the small number of cases identified with both MP and MGUS, inferential statistical analysis could not be performed.

Based on our results, providers should be aware that the presence of MGUS is not unique to EF but may be found in MP. Although none of our patients have developed overt malignancy or extracutaneous symptoms to date, and a 2010 consensus statement recommended against routinely screening patients for MGUS, further research is necessary to determine the long-term clinical significance and potential pathogenesis of paraproteinemia in patients with MP. This would allow better characterization of the cost-benefit ratio of initial and serial immunoelectrophoresis screening in these patients [18].

References

1. Connolly M. Dermatology. In: Bologna JL, Jorizzo JL, Rapini RP, editors. 2e ed. St. Louis, MO: Elsevier; 2008.
2. Peterson LS, Nelson AM, Su WP. Classification of morphea (localized scleroderma). Mayo Clinic proceedings Mayo Clinic. 1995;70(11):1068-76. doi: 10.1016/S0025-6196(11)64442-X. PubMed PMID: 7475336.

3. Toulouei K, Wiener A, Glick BP. Solitary morphea profunda following trauma sustained in an automobile accident. *Cutis; cutaneous medicine for the practitioner*. 2015;95(1):32-6. PubMed PMID: 25671442.
4. Lakhanpal S, Ginsburg WW, Michet CJ, Doyle JA, Moore SB. Eosinophilic fasciitis: clinical spectrum and therapeutic response in 52 cases. *Seminars in arthritis and rheumatism*. 1988;17(4):221-31. Epub 1988/05/01. PubMed PMID: 3232080.
5. Endo Y, Tamura A, Matsushima Y, Iwasaki T, Hasegawa M, Nagai Y, et al. Eosinophilic fasciitis: report of two cases and a systematic review of the literature dealing with clinical variables that predict outcome. *Clin Rheumatol*. 2007;26(9):1445-51. doi: 10.1007/s10067-006-0525-6.
6. Shulman LE. Diffuse fasciitis with eosinophilia: a new syndrome? *Trans Assoc Am Physicians*. 1975;88:70-86. Epub 1975/01/01. PubMed PMID: 1224441.
7. Shulman LE. Diffuse fasciitis with hypergammaglobulinemia and eosinophilia: a new syndrome? *The Journal of rheumatology*. 1984;11(5):569-70. Epub 1984/10/01. PubMed PMID: 6542592.
8. Doyle JA, Connolly SM, Hoagland HC. Hematologic disease in scleroderma syndromes. *Acta Derm Venereol*. 1985;65(6):521-5. Epub 1985/01/01. PubMed PMID: 2420117.
9. Khanna D, Verity A, Grossman JM. Eosinophilic fasciitis with multiple myeloma: a new haematological association. *Annals of the rheumatic diseases*. 2002;61(12):1111-2. Epub 2002/11/14. PubMed PMID: 12429547; PubMed Central PMCID: PMC1753970.
10. Magro CM, Iwenofu H, Nuovo GJ. Paraneoplastic scleroderma-like tissue reactions in the setting of an underlying plasma cell dyscrasia: a report of 10 cases. *Am J Dermatopathol*. 2013;35(5):561-8. doi: 10.1097/DAD.0b013e31827adbc8. PubMed PMID: 23669187.
11. Nakanishi H, Takehara K, Soma Y, Ishibashi Y. Atypical scleroderma associated with multiple myeloma. *Dermatologica*. 1989;178(3):176-8. PubMed PMID: 2721808.
12. Simman R, Magro C, Russ A, Peterson W. Gammopathy-associated acrosclerosis as a cause of flexion contractures in an older adult patient: a case report and literature review. *Advances in skin & wound care*. 2010;23(1):25-8. doi: 10.1097/01.ASW.0000363488.01977.4d. PubMed PMID: 20101112.
13. Goldner B, Furie R. Eosinophilic fasciitis associated with a monoclonal immunoglobulin. *Clin Exp Rheumatol*. 1994;12(5):574. PubMed PMID: 7842540.
14. Richardson PG, Laubach J, Mitsiades CS, Schlossman RL, Ghobrial IM, Munshi NC, et al. MGUS and smoldering myeloma: the most prevalent of plasma cell dyscrasias. *Oncology (Williston Park, NY)*. 2011;25(7):594, 6. Epub 2011/09/06. PubMed PMID: 21888257.
15. Reyes CM, Rudinskaya A, Kloss R, Girardi M, Lazova R. Scleroderma-like illness as a presenting feature of multiple myeloma and amyloidosis. *Journal of clinical rheumatology : practical reports on rheumatic & musculoskeletal diseases*. 2008;14(3):161-5. Epub 2008/06/06. doi: 10.1097/RHU.0b013e3181775a15. PubMed PMID: 18525436.
16. Al-Ghamdi KM, Al-Ajlan AM, Wadi W, Alballa SR, Al-Arfaj A. Eosinophilic fasciitis (Shulman's syndrome): case reports and review of the literature. *Ann Saudi Med*. 2001;21(1-2):68-72. PubMed PMID: 17264595.
17. Laxer RM, Zulian F. Localized scleroderma. *Current opinion in rheumatology*. 2006;18(6):606-13. doi: 10.1097/01.bor.0000245727.40630.c3. PubMed PMID: 17053506.
18. Berenson JR, Anderson KC, Audell RA, Boccia RV, Coleman M, Dimopoulos MA, et al. Monoclonal gammopathy of undetermined significance: a consensus statement. *British journal of haematology*. 2010;150(1):28-38. Epub 2010/05/29. doi: 10.1111/j.1365-2141.2010.08207.x. PubMed PMID: 20507313.

